

We are IntechOpen, the world's leading publisher of Open Access books Built by scientists, for scientists

4,800

Open access books available

122,000

International authors and editors

135M

Downloads

Our authors are among the

154

Countries delivered to

TOP 1%

most cited scientists

12.2%

Contributors from top 500 universities



WEB OF SCIENCE™

Selection of our books indexed in the Book Citation Index
in Web of Science™ Core Collection (BKCI)

Interested in publishing with us?
Contact book.department@intechopen.com

Numbers displayed above are based on latest data collected.
For more information visit www.intechopen.com



Genitourinary Hydatid Disease

Santosh Kumar and Shivanshu Singh

Additional information is available at the end of the chapter

<http://dx.doi.org/10.5772/60904>

Abstract

Genitourinary echinococcosis is an uncommon cyclo-zoonotic disease. It is caused by *Echinococcus* species. Kidneys are the common target organs in the genitourinary tract. Clinical presentation is usually non-specific. Pre-operative diagnosis requires a high index of suspicion. It should be considered in differential diagnosis of cystic mass of genitourinary tract, especially in endemic regions. Computed tomography, ultrasonography, and antibody testing aid in diagnosing and classifying the stage of the cyst. Although a number of operative techniques have been described, complete removal of germinal layer with daughter cysts without spillage of viable cyst contents with perioperative medical therapy provides an optimum chance of cure with minimal morbidity. Considering the benign nature of the disease, organ preservation is feasible in majority of the cases. The conventional open surgical treatment has evolved into minimally invasive laparoscopic, endoscopic, and even robotic techniques with concomitant improvement in postoperative and cosmetic outcome. Given the rarity of the disease, no randomized control trial comparing the treatment modalities for genitourinary hydatid exists. Moreover, long-term follow up in many cases is unavailable. Overall, the incidence of local and systemic recurrence is low.

Keywords: Genitourinary hydatid, echinococcosis, laparoscopic management

1. Introduction

Echinococcosis or hydatid disease in humans is caused by larval forms of cestode *Echinococcus granulosus* and rarely by *E. multilocularis* [1]. It's a cyclozoonotic parasitic infection with the liver (45%–75%) and the lung (10%–50%) being the most commonly involved organs [2]. The

disease is endemic in Middle East Asia, South America, Australia, New Zealand, and Alaska where sheep and cattle rearing are common [3]. Genitourinary tract infestation is rare, with kidneys being the most common target. Renal involvement accounts for 1%–5% of all cases [4]. Cases of adrenal, prostatic, vesicle, retro-vesicle, and even testicular hydatid cyst have been reported in the literature. Imaging plays a key role in the diagnosis and staging of hydatid disease [5, 6]. Definitive therapeutic options include surgical excision or cyst aspiration with instillation of scolical agents. Laparoscopy and image guided percutaneous techniques have decreased the morbidity associated with open surgical excision. Medical therapy is commonly used as an adjunct in the perioperative period and as a primary modality in disseminated disease or in patients with poor surgical risk [7].

2. Etiopathogenesis and clinical presentation

Echinococcosis is a zoonotic disease. Definitive hosts are carnivores such as dogs, wolves, and foxes [8]. The adult worms mature in the small intestine of definitive hosts and shed proglottids in their feces. Upon ingestion of these eggs by intermediate hosts (herbivores such as sheep, horses, cattle, pigs, goats, camel, and humans), the oncosphere larva is released in the small intestine and penetrates the mucosa to enter the lamina propria. From there, passive transport occurs to target organs by hematogenous or lymphatic route, disseminating primarily to the liver, secondarily to the lung, and finally to other organs where it forms the hydatid cyst. The triple layered cyst consists of an inner germinal layer that gives rise to protoscoleces, a middle acellular laminated layer and an outer host-tissue derived fibrous layer. As life cycle depends on carnivores eating infected intermediate hosts, humans are usually a dead end for the parasite.

2.1. Clinical presentation of renal echinococcosis

Hydatid cysts are typically slow growing and clinical presentation seldom suggests diagnosis [9]. Renal echinococcosis usually presents between the third and fifth decades of life and accounts for 2%–3% of all cases [10]. Renal involvement can occur by hematogenous route or larval migration through retroperitoneal lymphatics [3]. Due to the slow-growing nature of the cyst, the renal echinococcosis remains asymptomatic for years. Most common symptoms are palpable mass, flank pain, hematuria, malaise, and fever [11]. Secondary infection can cause high-grade fever, rigors, malaise, and pain [12]. The only hallmark sign of genitourinary echinococcosis is the presence of hydaturia (presence of daughter vesicles in urine), but this is found in 10%–20% of the cases [13]. Reports suggest that left renal involvement is more common than right probably due to the smaller renal artery [4]. Renal lesions are usually found in the cortex and can be uni- or multilocular [9].

2.2. Clinical presentation of adrenal echinococcosis

Adrenal involvement is rare and accounts for less than 1% of the cases [14]. It accounts for 6%–7% of all adrenal cysts [15, 16]. Mostly they are diagnosed incidentally, however, patients may

present with vague non-specific dull aching pain in flank. Adrenal hydatid may cause hypertension, known as Goldblatt phenomenon, due to irritation of the functional tissue of the adrenal by the growing cyst [17]. Many authors believe that adrenal involvement is usually secondary and part of a generalized echinococcosis [14, 18].

2.3. Clinical presentation of pelvic echinococcosis

Primary pelvic hydatid cyst is rare with an incidence of 0.2%–2.25% [19]. Among the pelvic organs, ovaries are most commonly involved [20]. Symptomatology of pelvic echinococcosis is non-specific and can include abdominal pain, menstruation irregularities, infertility, and urinary disturbances [21]. Ovarian echinococcosis can mimic polycystic disease or malignancy [22]. Ovarian echinococcosis can also mimic endometriosis [23]. Although ovarian cysts are usually uni-locular, multilocular cysts have also been described [24]. Uterine echinococcosis can present with menorrhagia, and may be misdiagnosed as molar pregnancy [25]. Due to their large size, they can cause prolonged and obstructed labour requiring caesarean section [26]. Primary hydatid cyst of the broad ligament is extremely rare and may be misdiagnosed as pedunculated fibroid or a paraovarian cyst [27]. In one study of echinococcosis in an endemic region, the incidence of broad ligament echinococcosis was 0.37% among all cases of hydatid cyst [28].

Bladder hydatid cysts are characterized by clinical latency. Acute urinary retention is a commonly reported symptom [29] apart from frequency, urgency, and nocturia. Hydaturia, although specific, is uncommonly reported. Pelvic retrovesicle hydatidosis occurs by peritoneal dissemination, hematogenous or lymphatic seeding or spread from rectal mucosa to the perivesicle and pelvic venous plexus [30]. This site is unusual, even in endemic regions [31], accounting for 2% of all genitourinary echinococcosis [32]. They may present with pelvic pain, dysuria, membranuria, lower urinary tract symptoms, and hematospermia or may mimic ovarian cysts in females [32, 33]. Larger cysts may lead to urinary retention, ureteric compression with renal atrophy [34], renal failure, constipation, and even obstructed labour [35] or may develop fistulous communication with the rectum and bladder [36].

Prostatic cysts can be classified in to six categories: 1) isolated medial cysts; 2) cysts of the ejaculatory duct; 3) simple or multiple cysts of the parenchyma; 4) complicated infectious or hemorrhagic cysts; 5) cystic tumors; and 6) cysts secondary to a parasitic disease. Hydatid cyst of the prostate is a rare differential diagnosis of prostatic cyst [37]. Prostatic involvement occurs by hematogenous dissemination with cyst development within the prostatic stroma. They can clinically present as intraprostatic cystic mass. Growing cyst may rupture into the urethra causing hydaturia. Intracystic stone formation can occur due to urinary stagnation.

2.4. Other genitourinary sites of involvement

Rare case reports of scrotal, testicular, epididymal, and seminal vesicle hydatid cysts exist in literature [38-41]. Blood-testis barrier may account for testicular resistance to echinococcosis [42]. It mimics testicular mass, with diagnosis being proven on final histopathology of orchidectomy specimen. Testicular infestation can be primary or secondary to rupture of an

intra-abdominal hydatid cyst [43]. Testicular echinococcosis, although rare, should be remembered as a differential diagnosis of testicular mass. Seminal vesicle hydatid cysts may present with lower urinary tract symptoms [44].

3. Diagnostic investigation

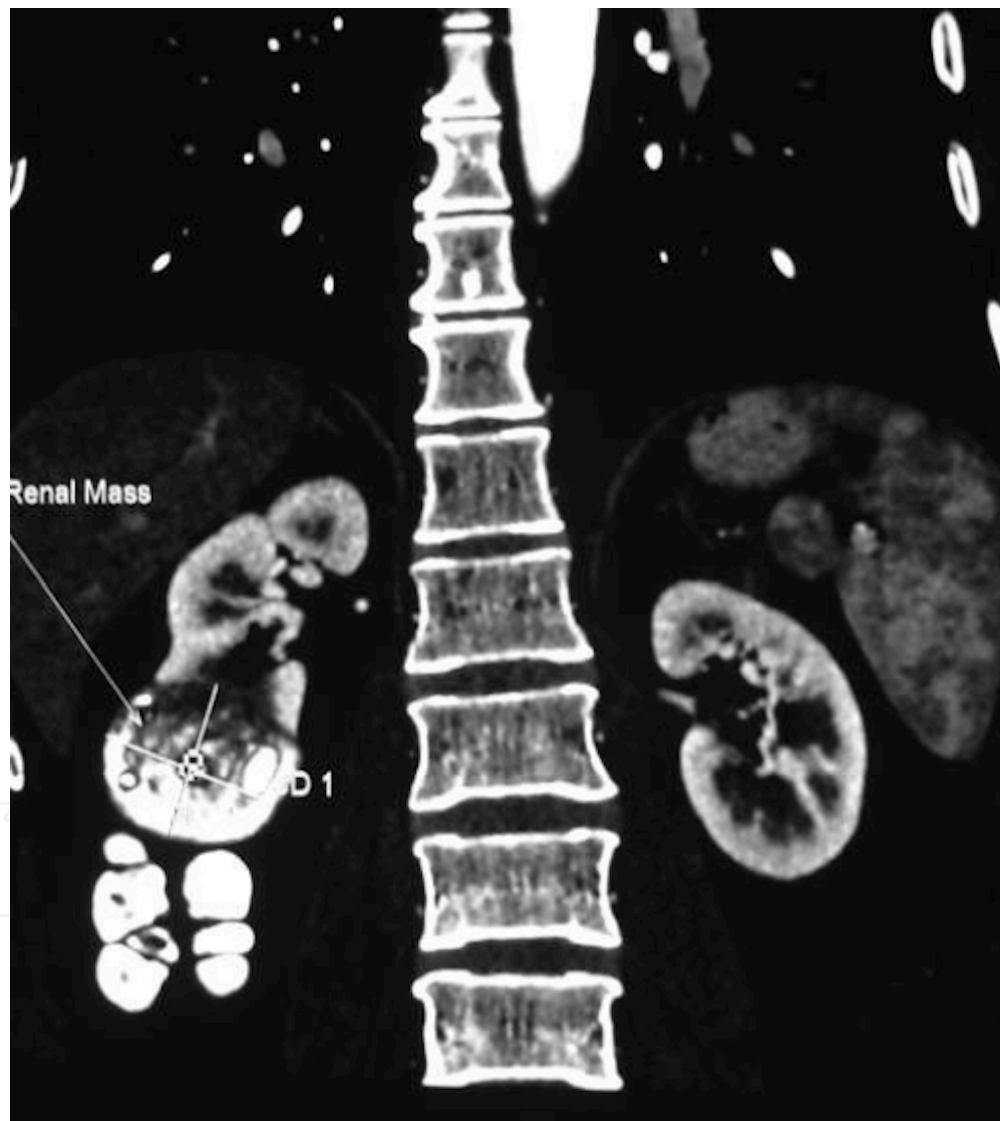
Imaging plays a central role in the diagnosis of echinococcosis. Various serological tests have evolved over time and contribute to diagnosis making, although they have low sensitivity [45]. Insensitive and nonspecific tests such as Casoni intradermal test, complement fixation test, indirect hemagglutination, and latex agglutination tests are now replaced by ELISA, immunoelectrophoresis, indirect immunofluorescence antibody test, and immunoblotting in routine laboratory testing [46, 47]. ELISA has positive titers in up to 80% of the cases [9]. Dipstick assays have been developed with nearly 100% sensitivity and approximately 91% specificity [48]. Newer immunodiagnostic tests are based on detection of echinococcal antigens in hydatid fluid fraction. These include *E. granulosus* antigen B (AgB), *E. granulosus* antigen 5 and EpC1. AgB8/2 antigen has provided the highest diagnostic sensitivity (84%–93.1%) and specificity (98%–99.5%) [49, 50]. Serology has a definite role in the follow up of cases, as the titer should fall after definitive treatment [51]. Eosinophilia occurs in 20%–50% of the cases [12].

Ultrasound is the key imaging tool to clinch the diagnosis. It demonstrates the floating membranes, daughter cysts, and hydatid sand apart from demonstrating the site, size, and number of cysts. The WHO/IWG-E classification for diagnosis and treatment is based on ultrasound imaging characteristics. It classifies the cyst into six subtypes (CL, CE1 to CE5) and three relevant groups: active (CE1 and 2), transitional (CE3), and inactive (CE4 and 5) [4]. “CL” is a univesicular, cystic lesion with uniform echoes, clear boundary, and thin visible wall. If it is a hydatid cyst, it is active. “CE1” is a univesicular anechoic cyst with presence of hydatid sand, double wall, and snowflake sign. The disease is active. “CE2” includes multi-vesicular, multi-septated cysts. Cyst septations produce “wheel-like” structures, and the presence of daughter cysts is indicated by “rosette-like” structure. “CE3a” is the detachment of laminated membrane from the cyst wall, visible as a “big snake sign” or as a “water-lily sign”. The disease status is transitional. “CE3b” shows an intracystic shadow of the daughter vesicles and solid septation, manifested as complex cyst shadow. The parasite is dying. “CE4” has heterogenous, hypoechoic, or hyperechoic contents in the cyst. “CE5” is intracystic solid degeneration and calcification of the cystic wall. The parasite is inactive. Transrectal ultrasound is helpful in evaluating pelvic cystic lesions.

On CT scan, unilocular or multilocular cystic lesions are identified with frequently calcified walls, debris, small daughter cysts, and increased tissue density of hydatid membrane that enhances on intravenous contrast administration [7]. CT scan provides information regarding the number of cysts, the organ of origin, residual parenchyma in the affected organ, and relationship of the cyst with the adjacent structures [Figure 1–4]. This preoperative assessment is essential for planning the approach and type of surgery. Retrograde pyelography may not demonstrate communication with the pelvicalyceal system because of high intracystic

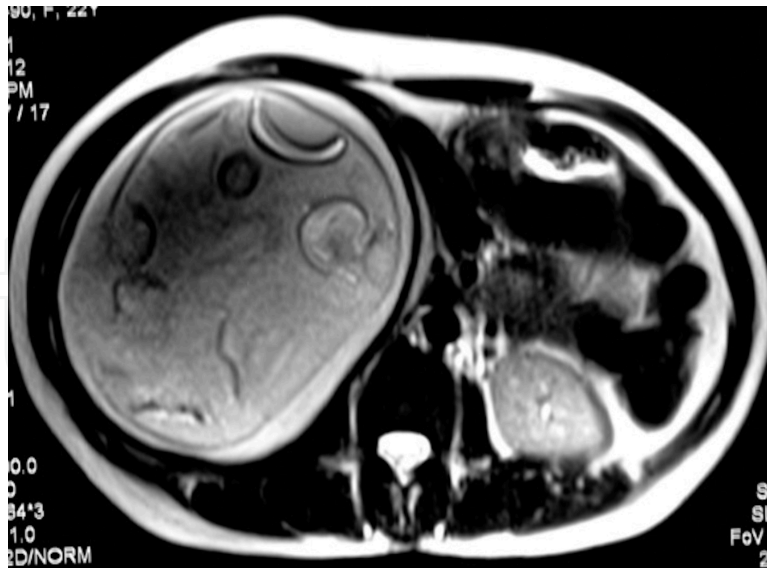
pressures [52]. Communication may be demonstrated soon after cyst decompression. CT-guided diagnostic needle aspiration is not indicated when echinococcal cyst is suspected due to risk of dissemination and anaphylactic reaction. Magnetic resonance imaging provides better tissue delineation especially in cases of pelvic hydatid cysts. In one study, the preoperative diagnostic accuracy for serological test was 73.3%, while it was 74% and 87.5% for ultrasound and CT scan respectively [4].

Hydatid cysts should be considered in the differential diagnosis of cystic masses of the genitourinary tract as they can radiologically and clinically mimic tumors, benign and malignant, and other cystic lesions of genitourinary tract.



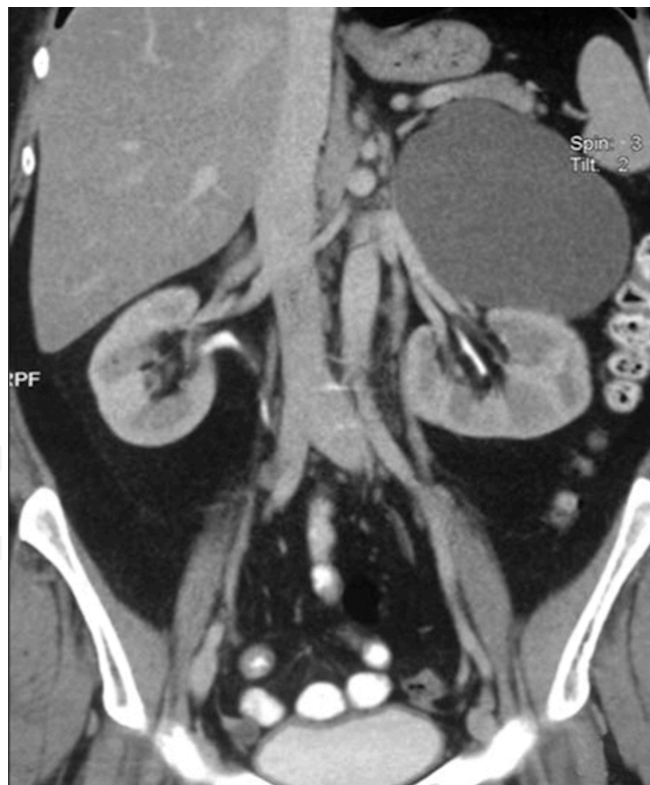Legend: Contrast-enhanced CT scan of the abdomen (coronal view) showing a multiloculated, exophytic, cystic lesion arising from lower pole of the right kidney with calcification of the cyst wall (Courtesy: Kumar et al. *J Endourol.* 2008;22:1709–1713.)

Figure 1. CT imaging of Renal Hydatid.



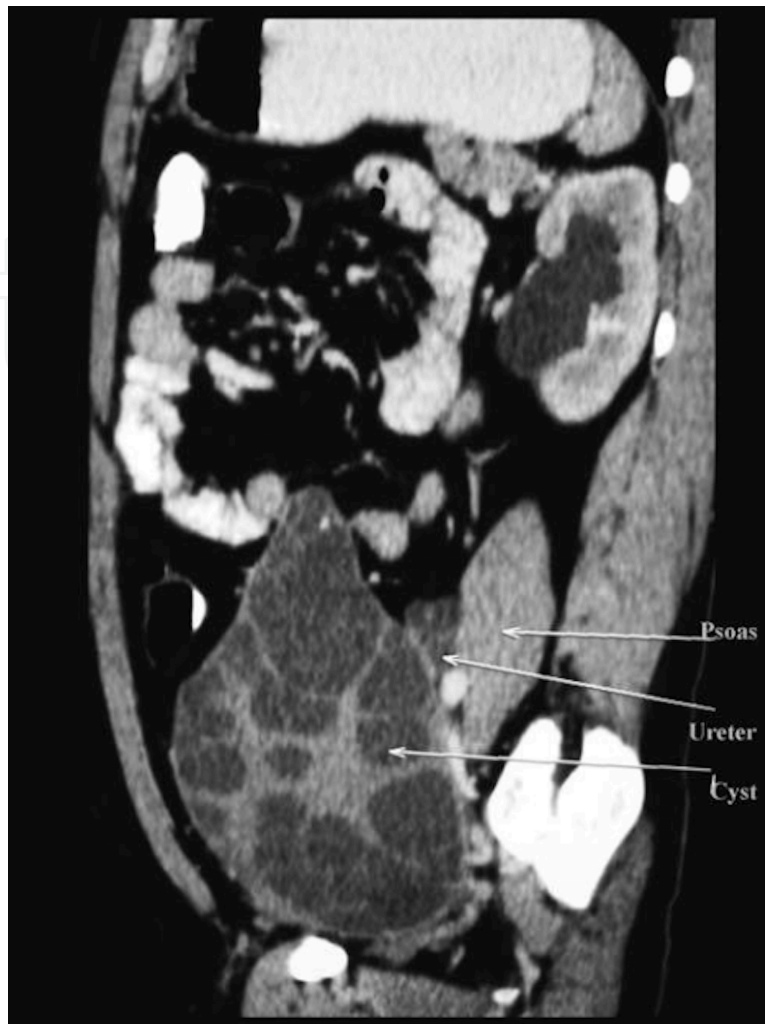Legend: Abdominal MRI revealing a multiloculated hydatid cyst of a kidney with a cyst-in-cyst appearance. (Courtesy: Kumar et al. *Asian J Endosc Surg.* 2013;6:342–345.)

Figure 2. MRI of renal hydatid cyst.



Legend: Contrast-enhanced computed tomography scan showing a cystic lesion involving the left adrenal gland without septations or daughter cyst. (Courtesy: Kumar et al. *Korean J Urol.* 2014;55:493–495.)

Figure 3. CT scan of adrenal hydatid cyst.



Legend: Contrast-enhanced CT of the abdomen (sagittal view) showing a retrovesical cyst with left hydroureteronephrosis. (Courtesy: Kumar et al. *J Endourol.* 2008;22:1709–1713.)

Figure 4. CT scan of retrovesicle hydatid cyst.

4. Management

Treatment depends on disease activity and symptom status. Actively growing or symptomatic cysts need to be treated. Treatment modalities include medical therapy, percutaneous intervention, and open and minimally invasive surgery. Surgical excision provides the best chance of cure. Medical therapy is used either as an adjunct to surgical excision or as a primary mode of treatment in poor surgical candidates, cases of disseminated hydatidosis, or cases of brain or bony hydatidosis [7]. Preoperative therapy with albendazole (10–15 mg/kg per day) with or without praziquantel (50 mg/kg) for 4 weeks before surgery may kill the scolices, decrease cyst material antigenicity, make the cyst inactive, reduce cyst wall tension thereby reducing risk of spillage [15]. In a study by Arif et al. on liver echinococcosis, patients who received preoperative Albendazole had a recurrence rate of 4.16%, while it was 18.75% in those who

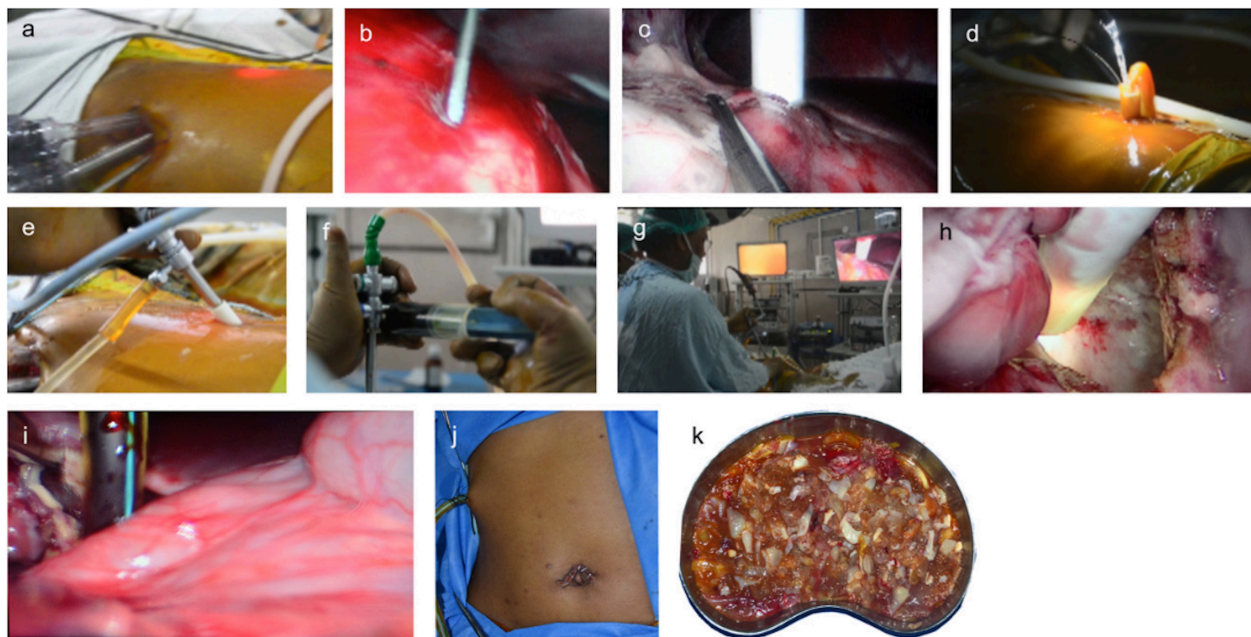
did not receive Albendazole [53]. One of the limitations of medical therapy is the serious drug-related adverse effect such as hepatotoxicity, leukopenia, allergic reactions, and alopecia [54] and the limited amount of literature available on its use in genito-urinary echinococcosis.

Percutaneous puncture, aspiration, instillation of scolicedal agent, and re-aspiration techniques (PAIR) under ultrasound guidance have been devised in an attempt to reduce the morbidity associated with open surgical procedures in cases of unilocular cysts not communicating with the pelvicalyceal system. However, it carries the risk of dissemination of daughter cysts and lethal anaphylaxis has been reported in 0.03%–0.04% of percutaneous procedures [55].

The surgical treatment planning for renal hydatid is based on residual renal function, hydatid cyst size, location, number, and degree of renal involvement. With the advent of minimally invasive surgery, the morbidity associated with open surgery has reduced. Smaller incisions result in reduced wound-related complications, early ambulation, and early return to work. Surgical treatment options for renal echinococcosis include cysto-pericystectomy, cyst de-roofing with endocyst evacuation, and partial or total nephrectomy. Laparoscopic management of renal hydatid cyst dates back to 1991 and includes laparoscopic cystopericystectomy, laparoscopic partial nephrectomy, laparoscopic aspiration, instillation of scolicedal agent, and suction [52]. Superficial hydatid cysts involving little renal parenchyma can be managed by pericystectomy while larger, deep seated cysts may require partial cystectomy or de-roofing with omentopexy, partial or total nephrectomy. In most cases, nephrectomy can be avoided and kidney can be preserved considering the benign nature of the disease and the fact that in hydatid cyst, the renal parenchyma is compressed and not invaded. Ex-vivo surgery with orthotopic replantation of the kidney for a centrally located hydatid cyst has been performed with good short-term outcome [56]. Partial nephrectomy may be necessary for thickened or calcified cysts with doubtful diagnosis [7]. Nephron-sparing surgeries are possible in 75% of the cases [57]. Nephrectomy may be needed in cases where the entire kidney is replaced by a hydatid cyst or in cases of poorly functioning kidney, cyst hemorrhage, cyst infection, or communicating cyst [7]. Techniques of controlled evacuation are used to prevent spillage and dissemination of daughter cysts. In controlled evacuation, one third of the cyst content is aspirated, followed by instillation of scolicedal agents such as 30% sodium chloride, 10% povidone iodine, 0.5% silver nitrate, or 95% ethanol [12, 15]. Moreover, during surgery, the cysts should be packed on all sides with gauze soaked in scolicedal solutions including 20% normal saline solution, 1% iodine, 10% cetrimide, 10% povidone-iodine, or 0.5% silver nitrate [58].

The laparoscopic approach for hydatid cyst management is safe and feasible with better postoperative recovery. The smaller incision, as compared to conventional open surgery leads to less postoperative pain, and wound-related complications. During surgery for hydatid cyst, the anesthetist should be ready with epinephrine injections, should severe anaphylactic reaction occur [58]. Both transperitoneal and retroperitoneal laparoscopic approaches have been described [59]. Transperitoneal approach provides a larger working space outside the Gerota fascia and prevents inadvertent cyst rupture [60]. Two of the main challenges in minimal invasive surgery for hydatid disease are the risk of intraperitoneal spillage and the difficult evacuation of particulate cyst contents including the daughter cyst and laminated membranes. However, even giant multilocular renal hydatid cysts have been successfully


treated by percutaneous nephroscopic aspiration, instillation, and re-aspiration through single-incision laparoscopic approach—the Santosh-PGI technique (Figure 5) [52]. In this technique following pneumoperitoneum, three conventional laparoscopic trocars with cannula (one 10 mm and two 5 mm) are inserted through a single periumbilical incision. After medial mobilization of the colon, the cyst is punctured with a 18-gauge 20 cm puncture needle introduced through the right lumbar region. 10% povidone-iodine solution is instilled for 10 minutes, followed by the passage of a 0.8128 mm Terumo guidewire through the puncture needle. The tract is dilated with Amplatz dilators to accommodate 30 French instruments. Two separate camera monitors are used: one for laparoscopy and the other for hydatid cystoscopy. A suction catheter is placed through the 5-Fr periumbilical port to help suck out small amount of fluid that may spill during the process of tract dilatation. Following dilatation of tract with Amplatz dilator, a 24-French caliber 25-degree nephroscope is introduced into the cyst and the contents are aspirated under vision followed by the removal of the laminated membrane with grasping forceps. This is an attractive technique because of its acceptable success rate and reduced morbidity. It highlights the feasibility of successful laparoscopic treatment even in cases of a giant hydatid cyst. Laparoscopic guidance for cysts puncture avoids inadvertent colonic injury. The use of conventional laparoscopic instruments through a single periumbilical incision not only reduces operative costs but also provides excellent cosmesis.



Legend: Surgical procedure. (a) Three conventional laparoscopic trocars, one 10 mm and two 5 mm, were inserted through the umbilical incision. (b) Laparoscopic guidance was used to puncture the cyst. (c) Tract dilatation with Amplatz dilators. (d,e) With the help of a nephroscope, all the cyst contents were aspirated until the clear cyst wall could be seen all around. (f) Injection of 10% povidone-iodine solution. (g) Cyst removal with grasping forceps through the nephroscope. (h) Deroofing the cyst. (i) Placement of the Portex drain into cyst cavity. (j) Closed port site. (k) Removed cyst contents. (Courtesy: Kumar et al. *Asian J Endosc Surg.* 2013;6:342–345.)

Figure 5. Percutaneous nephroscopic management of an isolated giant renal hydatid cyst guided by single-incision laparoscopy using conventional instruments: The Santosh-PGI technique.

The Palanivelu Hydatid System (PHS) helps in the controlled evacuation of the cyst contents, laparoscopically minimizing the fear of intraperitoneal spillage [61]. It consists of a 12 mm trocar and cannula assembly along with 5 mm and 8 mm reducers. The pyramidal tip of the trocar has fenestrations and the shaft is hollow to accommodate suction cannula. The 26 cm long cannula has 12 mm inner diameter with suction and irrigation channels [Figure 6]. This unique architecture of trocar and cannula allows for easy suction of scolices, as well as avoids spillage of contents. Following aspiration, the same cannula can be used for visualization of intracystic architecture and rule out its communication with the collecting system. Following the aspiration of the scolical agent after 10 minutes of contact time, the residual cyst can be marsupialized or excised depending on the location. The specimen is retrieved through a specimen retrieval bag.



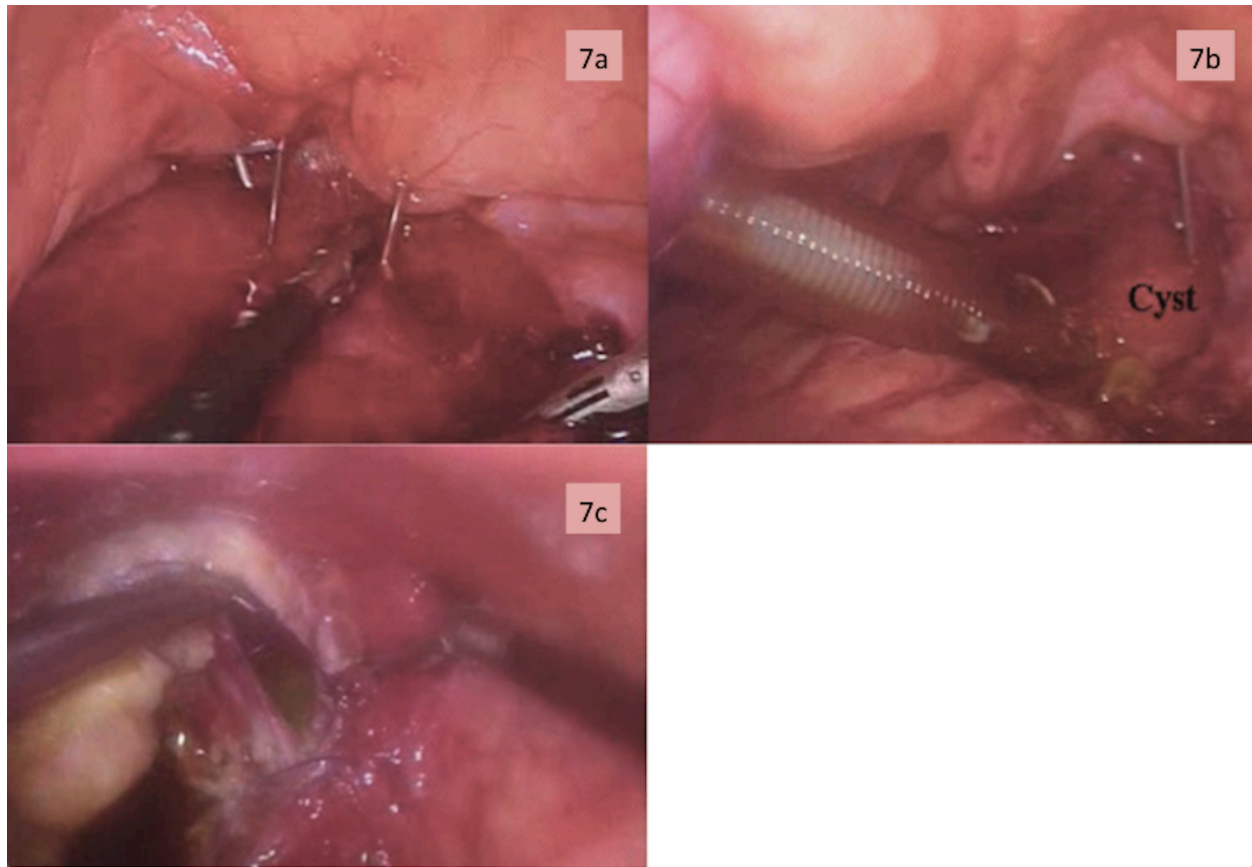
Legend: Palanivelu hydatid system showing the long trocar and cannula with two side channels for suction and irrigation.

Figure 6. The Palanivelu Hydatid System (PHS).

Retroperitoneoscopic approach further minimizes the risk of intraperitoneal spillage of cyst contents. With the increasing experience in retroperitoneoscopy, reports of retroperitoneoscopic hydatid cyst excision are emerging [62]. The technique involves standard three-port (5 mm, 10 mm, 10 mm) retroperitoneal access under the vision of a 30-degree telescope at 90-degree flank position, with the help of balloon dilatation. The cyst wall is packed with gauze soaked in scolical agent. In the technique described by Ozden and colleagues, a purse-string suture was placed on the cyst wall followed by cyst perforation with hook dissector. The fluid content was aspirated, followed by the instillation of scolical agent. Cystopericystectomy was performed and the intact cyst could be removed. The authors emphasize the technical feasibility of this approach, along with the advantage of limited risk of intraperitoneal spillage.

Surgical management of adrenal hydatid cyst involves partial or complete excision of the cyst by laparoscopic or open techniques. In a series of nine cases by Ackay and colleagues, adrenalectomy was performed in all cases with no recurrence at a median follow-up of 16 months (range: 6–64 months)[14]. Due to the limited amount of available data, it is difficult to say whether complete excision of adrenal is mandatory. Kumar and colleagues did transperitoneal laparoscopic aspiration with instillation of scolicedal agent with partial cystectomy for adrenal hydatid cyst. The area around the cyst was packed with Betadine-soaked gauze pieces. The cyst was aspirated during the procedure followed by the instillation of the scolicedal agent and maintained for 10 minutes. An appropriate plane between the cyst and adrenal gland could not be made. A 10 mm trocar was introduced inside the cyst and the cyst contents were sucked out, including the germinal layer. Partial excision of the cyst wall was done as it was adherent to renal vessels. Patient had no recurrence at sixth-month follow up. Total adrenalectomy may not be essential and may be required only when there is complete destruction of the gland [63]. Complete evacuation of the cyst contents, along with the prevention of intraperitoneal spillage of viable scolices, is the key principle in managing the adrenal hydatid cyst.

Retrovesicle hydatid cyst contains small bowel, sigmoid colon, rectum, ureter, urinary bladder, pelvic vessels, or internal genitalia of females as part of the pericyst. Although complete cyst excision has been described in few reports [64], it carries a high risk of inadvertent pelvic visceral injury. The narrow pelvic space along with dense adhesions to the surrounding structures may render difficulties in complete excision of pelvic hydatid cysts. Few case reports exist in literature regarding their management. In cases of pelvic or peri-vesical hydatid, where the cyst is large and adherent to adjacent vital organs, partial excision of hydatid cyst with adequate drainage is an acceptable alternative [7]. Laparoscopic cyst aspiration with instillation of scolicedal agent (LAIS) and suction has been successfully employed in the perivesical hydatid cyst (Figure 7) [7]. In this technique, pneumoperitoneum is created using Verres' needle in the epigastrium. Four ports are placed: a 12 mm camera port in the midline above the umbilicus; two 12 mm lateral working ports in the lower abdomen at lateral border of rectus; and an additional 5 mm port can be placed in the iliac fossa to help in retraction. Laparoscopy guided percutaneous puncture of the cyst with an 18 G needle is performed, followed by aspiration with instillation of scolicedal agent. The procedure is repeated to ensure the instillation of the scolicedal agent into the entire cyst. The ectocyst is opened and the lateral port is negotiated into the cyst for complete cyst evacuation using a wide-bore suction cannula followed by visual inspection of the cyst lumen to ensure the complete removal of scolices. Complete ectocyst excision is difficult with associated risk of inadvertent bladder-bowel injury. However, even in cases with partial or no excision of ectocyst, complete evacuation of daughter cysts, germinal layer, and lamellated membrane combined with medical therapy results in an acceptable short-term outcome. Even partial cystectomy can be difficult and may lead to inadvertent adjacent visceral injury [7]. However, on table recognition of such complication and primary repair reduces post-operative morbidity. With the advances in laparoscopic techniques, such visceral injuries can be managed laparoscopically.



Legend: (a) Laparoscopic-guided percutaneous cyst puncture, aspiration, and instillation of 10% povidone iodine solution. (b) Cyst contents and laminated membrane being sucked out through the port using a wide-bore suction cannula. (c) Excision of part of the ectocyst led to iatrogenic bladder injury, which was repaired by intra-corporeal suturing. (Courtesy: Kumar et al. *J Endourol.* 2008;22:1709–1713.)

Figure 7. LAIS for retrovesicle hydatid cyst.

The PHS system has also been successfully used for managing pelvic echinococcal cysts [65]. Ports include a 12 mm midline supra-umbilical port, two para-rectal lower abdominal ports (12 mm and 5 mm) and an accessory port in iliac fossa. After dissecting the ectocyst from adjacent viscera, Betadine-soaked gauzes are placed around the cyst. The puncture and aspiration technique is similar to the one described for renal echinococcosis. Complex retrovesicle echinococcal cysts may communicate with the bladder or rectum [36]. Their management is a challenge. Retrovesicle cysts communicating with the bladder have been managed with intravesicle instillation of scolicidal agents with good outcome [66]. Pelvic retroperitoneal cysts can also be evacuated by transvaginal route [67].

Nowadays even robot-assisted surgical excision of the pelvic hydatid cyst has been performed [68]. Patient position is same as for robotic radical prostatectomy. Superior magnification, 3D vision, and endowrist technology help in the accurate dissection with minimal collateral damage thereby, helping in complete cyst excision. Robot assisted laparoscopic surgery is a safe and feasible option in the management of pelvic hydatid cyst.

Prostatic hydatid cysts are rarely reported with only few case reports discussing their management. Sallami et al. described endoscopic management of prostatic hydatid cyst [69]. Surgery was performed under spinal anesthesia. Cystoscopy revealed a bulge in the posterior urethral wall. The posterior wall of the urethra was incised with a cold knife, taking care not to injure the bladder neck and verumontanum. Scolicidal agent was injected, followed by the aspiration of the cyst fluid. The cyst wall was opened, followed by the immediate suction of the cyst contents including the daughter cyst. The germinal layer was completely removed, followed by the re-instillation of the scolicidal agent. Post-procedure, a Foley catheter was placed for four days. Laparoscopic excision of the prostatic hydatid cyst is also safe and feasible [70]. Therapeutic principles are the same.

Preoperative diagnosis of testicular echinococcosis is difficult. In the cases reported, diagnosis was made based on histopathological examination of the orchidectomy specimen. The indications for orchidectomy were either suspicion of testicular malignancy or tuberculosis [39]. Ovarian echinococcal cysts have been rarely reported [22]. Although ovarian cystectomy shall be the ideal treatment, cyst marsupialization with evacuation of daughter cysts also has acceptable results [22].

5. Outcome

Majority of the literature available on genitourinary echinococcosis include case series and case reports. Many of the therapeutic principles are extrapolation of the experience with the hepatic hydatid cyst. Given the rarity of the disease, no randomized control trial comparing the treatment modalities for genitourinary hydatid exist. Moreover, long-term follow up in many cases is unavailable. Overall, the incidence of local and systemic recurrence is low. In a series of 30 cases of renal echinococcosis, only one patient had local recurrence, while extra-renal recurrence occurred in three more cases [4]. Risk factors for recurrence includes spillage of viable daughter cysts and scolices, incomplete removal of germinal layer, undetected cyst at other location, and return to endemic area.

6. Conclusion

Genitourinary echinococcosis is an uncommon disease. Preoperative diagnosis requires a high index of suspicion. It should be considered in differential diagnosis of cystic mass of genitourinary tract, especially in endemic regions. Computed tomography, ultrasonography, and antibody testing aid in diagnosing and classifying the stage of the cyst. Although a number of operative techniques have been described, complete removal of germinal layer with daughter cysts without spillage of viable cyst contents with perioperative medical therapy provide an optimum chance of cure with minimal morbidity. Considering the benign nature of the disease, organ preservation is feasible in majority of the cases. The conventional open surgical treatment has evolved into minimally invasive laparoscopic, endoscopic, and even robotic techniques with concomitant improvement in wound-related morbidity and cosmetic outcome.

Author details

Santosh Kumar* and Shivanshu Singh

*Address all correspondence to: santoshsp1967jaimatadi@yahoo.co.in ; santoshsp1967@yahoo.co.in

Advanced Urology Center, Department of Urology, Postgraduate Institute of Medical Education and Research, Chandigarh, India

References

- [1] Strohmaier WL, Bichler KH, Wilbert DM, Seitz HM. Alveolar echinococcosis with involvement of the ureter and testis. *J Urol*. 1990;144:733–734.
- [2] Kern P, Bardonnnet K, Renner E, Auer H, Pawlowski Z, Ammann RW, et al. European echinococcosis registry: Human alveolar echinococcosis, Europe, 1982-2000. *Emerg Infect Dis*. 2003;9:343–349.
- [3] Choi H, Park JY, Kim JH, Moon DG, Lee JG, Bae JH. Primary renal hydatid cyst: Mis-Interpretation as a renal malignancy. *Korean J Parasitol*. 2014;52:295–298.
- [4] Rexiati M, Mutalifu A, Azhati B, Wang W, Yang H, Sheyhedin I, et al. Diagnosis and surgical treatment of renal hydatid disease: A retrospective analysis of 30 cases. *PLoS ONE* 2014;9:e96602. DOI:10.1371/journal.pone.0096602.
- [5] Brunetti E, Garcia HH, Junghanss T. Cystic echinococcosis: Chronic, complex, and still neglected. *PLoS Negl Trop Dis*. 2011;5:e1146. DOI:10.1371/journal.pntd.0001146.
- [6] McManus DP, Zhang W, Li J, Bartley PB. Echinococcosis. *Lancet*. 2003;18:1295–1304.
- [7] Kumar S, Pandya S, Agarwal S, Lal A. Laparoscopic management of genitourinary hydatid cyst disease. *J Endourol*. 2008;22:1709–1713.
- [8] Zhang W, Li J, McManus DP. Concepts in immunology and diagnosis of hydatid disease. *Clin. Microbiol. Rev*. 2003;16:18. DOI:10.1128/CMR.16.1.18-36.2003.
- [9] Karabekios S, Gouliamos A, Kalovidouris A, Vlahos L, Papavasiliou C, Sakkas J. Features of computed tomography in hydatid cysts of the urinary tract. *Br J Urol*. 1989;64:575–578.
- [10] Shetty SD, Al-saigh A, Ibrahim AI, Patil KP, Bhattachan CL. Management of hydatid cysts of the urinary tract. *Br J Urol*. 1992;70:258–261.
- [11] Horchani A, Nouria Y, Kbaier I. Hydatid cyst of the kidney: A report of 147 controlled cases. *Eur Urol*. 2000;38:461–467.

- [12] Gogus O, Beduk Y, Topukcu Z. Renal hydatid disease. *Br J Urol* 1991;68:466.
- [13] Shukla S, Singh SK, Pujani M. Multiple disseminated abdominal hydatidosis presenting with gross hydatiduria: A rare case report. *Indian J Pathol Microbiol.* 2009;52:213–214.
- [14] Akcay MN, Akcay G, Balik AA, Boyuk A. Hydatid cysts of the adrenal gland: Review of nine patients. *World J Surg* 2004;28:97–99. DOI:10.4111/kju.2014.55.7.493.
- [15] Goel MC, Agarwal MR, Misra A. Percutaneous drainage of renal hydatid cyst: Early results and follow-up. *Br J Urol.* 1995;75:724–728.
- [16] Foster DG. Adrenal cysts: Review of literature and report of case. *Arch Surg.* 1966;92:131–143.
- [17] Yenyol CO, Minareci S, Ayder AR. Primary cyst hydatid of adrenal: A case report. *Int Urol Nephrol.* 2000;32:227–229.
- [18] Schoretsanitis G, de Bree E, Melissas J, Tsiftsis D. Primary hydatid cyst of the adrenal gland. *Scand J Urol Nephrol.* 1998;32:51–53.
- [19] Tampakoudis P, Assimakopoulos E, Zafarakas M, Tzevelekis P, Kostopoulou E, Bontis J. Pelvic echinococcus mimicking multicystic ovary. *Ultrasound Obstet Gynecol.* 2003;22:196–198.
- [20] Diaz-Recasens J, Garcia-Enguidanos A, Munoz I, Sainz de la Cuesta R. Ultrasonographic appearance of an echinococcus ovarian cyst. *Obstet Gynecol.* 1998;91:841–842.
- [21] Dede S, Dede H, Caliskan E, Demir B. Recurrent pelvic hydatid cyst obstructing labor, with a concomitant hepatic primary: A case report. *J Reprod Med.* 2002;47:164–166.
- [22] Cattorini L, Trastulli S, Milani D, Cirocchi R, Giovannelli G, Avenia N, et al. Ovarian hydatid cyst: A case report. *International Journal of Surgery Case Reports.* 2011;2:100–102. DOI:10.1016/j.ijscr.2010.12.005.
- [23] Bozkurt M, Bozkurt DK, CIL AS, Karaman M. Primary Ovarian and Pararectal Hydatid Cysts Mimicking Pelvic Endometriosis. *Acta Medica Iranica.* 2012;50:839–842.
- [24] Kaya A, Yildiz S, Ozaras R, Mert A. A primary giant hydatid cyst of ovary. *Iran J Radiol.* 2012;9:165–166. DOI:10.5812/iranjradi-ol.7955.
- [25] Rashid SQ. Primary and solitary uterine hydatid cyst: A most unusual site. *Journal of Medical Ultrasound.* 2011;19:57–60.
- [26] Thakare PY. Hydatid cysts in a pregnant uterus. *The Journal of Obstetrics and Gynecology of India.* 2014;64:215–217.
- [27] Bhattacharya A, Saha R, Mitra S, Nayak P. Primary hydatid cyst of broad ligament. *Tropical Parasitology.* 2013;3:155–157. DOI:10.4103/2229-5070.122148.

- [28] Bickers WM. Hydatid disease of the female pelvis. *Am J Obstet Gynecol.* 1970;107:477–483.
- [29] Deodhar SD, Patel VC, Kirloskar MS. Hydatid disease of urinary bladder (a case report). *J Postgrad Med.* 1986;32:46B–48B.
- [30] Angulo JC, Escribano J, Diego A, Sanchez-Chapado M. Isolated retrovesical and extra-renal retroperitoneal hydatidosis: Clinical study of 10 cases and literature review. *J Urol.* 1998;159:76–82.
- [31] Horchani A, Nouira Y, Chtourou M, Kacem M, Ben Safta Z. Retrovesical hydatid disease: A clinical study of 27 cases. *Eur Urol.* 2001;40:655–660.
- [32] Nasr R, Saad GA, Shahait M, Khater N. Retrovesical hydatid cyst presenting with urinary retention and left kidney atrophy. *Urol Ann.* 2014;6:68–70.
- [33] Kumar S, Sarkar D, Prasad S, Gupta V, Ghosala P, Kaman L, et al. Large pelvic masses of obscure origin: Urologist's perspective. *Urologia Internationalis.* 2012;88:215–224.
- [34] Srinivasan S. Retrovesical hydatid cyst presenting with urinary retention and left kidney atrophy. *Urol Ann.* 2014;6:70–71.
- [35] Parray FQ, Wani SN, Bazaz S, Khan SR, Malik NS. Primary pelvic hydatid cyst: A case report. *case reports in surgery.* Vol. 2011, Article ID 809387, 3 pages. 2011. DOI: 10.1155/2011/809387.
- [36] Kumar S, Naveen A, Mandal A, Singh SK. Case report unusual presentation of retrovesical hydatid cyst: Report of three cases. *African Journal of Urology.* 2007;14:155–157.
- [37] Nouira Y, Binous MY, Nouira K, Mekni A, Kallel Y, Fitouri Z, et al. Intraprostatic hydatid cyst: An unusual presentation. *Scientific World Journal.* 2006;6:2315–2318.
- [38] Bouchikhi AA, Lamrani YA, Tazi MF, Mellas S, Elammari J, Khallouk A, et al. Unilateral primitive hydatid cyst with surgical resection of the scrotum: A case report. *Journal of medical case reports.* 2013;7:109. DOI:10.1186/1752-1947-7-109
- [39] Singh B, Wani AA, Ganai AA, Singh M, Baba K. Hydatid cyst of testis: An unusual presentation of hydatid disease - Case report and review of literature. *Indian J Urol.* 2001;18:94–96.
- [40] Kumar PVN, Jahanshahi SH. Hydatid cyst of testis: A case report. *J Urol.* 1987;137:511–512.
- [41] Sağlam M, Taşar M, Bulakbaşı N, Tayfun C, Somuncu I. TRUS, CT and MRI findings of hydatid disease of seminal vesicles. *Eur Radiol.* 1998;8:933–935.

- [42] Ahmadnia H, Kalantari MR, Ghanbarizadeh SR. Why testes are resistant to hydatidosis: Is blood-testis-barrier responsible for this resistance? *Nigerian Journal of Parasitology*. 2008;29:84-87.
- [43] Khan RA, Wahab S, Chana RS, Fareed R. Isolated retroperitoneal hydatid cyst in a child: A rare cause of acute scrotal swelling? *J Pediatr Surg*. 2010;45:1717–1719. DOI: 10.1016/j.jpedsurg.2010.04.019
- [44] Mushtaque M, Mir MF, Nazir P, Khan PS. Primary isolated echinococcal cyst of the seminal vesicle: A rare case. *Urology Annals*. 2012;4:122–125. DOI: 10.4103/0974-7796.95571
- [45] Stojkovic M, Rosenberger K, Kauczor HU. Diagnosing and staging of cystic echinococcosis: How do CT and MRI perform in comparison to ultrasound? *PLoS Negl Trop Dis*. 2012;6:e1880.
- [46] Lightowers, MW, Gottstein B. *Echinococcosis/hydatidosis: Antigens, immunological, and molecular diagnosis*. Wallingford, Oxon, UK: CAB International. 1995.
- [47] Nasrieh MA, Abdel-Hafez SK. *Echinococcus granulosus* in Jordan: Assessment of various antigenic preparations for use in the serodiagnosis of surgically confirmed cases using enzyme immuno assays and the indirect haemagglutination test. *Diagn Microbiol Infect Dis*. 2004;48:117-123.
- [48] Al-Sherbiny MM, Farrag AA, Fayad MH, Makled MK, Tawfeek GM, Ali NM. Application and assessment of a dipstick assay in the diagnosis of hydatidosis and trichinosis. *Parasitol Res*. 2004;93:87–95.
- [49] Rott MB, Fernandez V, Farias S, Ceni J, Ferreira HB, Haag KL, et al. Comparative analysis of two different subunits of antigen B from *Echinococcus granulosus*: Gene sequences, expression in *Escherichia coli* and serological evaluation. *Acta Trop*. 2000;75:331–340.
- [50] Virginio VG, Hernandez A, Rott MB, Monteiro KM, Zandonai AF, Nieto A, et al. A set of recombinant antigens from *Echinococcus granulosus* with potential for use in the immunodiagnosis of human cystic hydatid disease. *Clin Exp Immunol*. 2003;132(2):309–315.
- [51] Feki W, Ghozzi S, Khiari R, Ghorbel J, Elarbi H, Khouni H, et al. Multiple unusual locations of hydatid cysts including bladder, psoas muscle, and liver. *Parasitology International*. 2008;57:83–86.
- [52] Kumar S, Choudhary GR, Pushkarna A, Najjapa B, Vatasla Ht. Percutaneous nephroscopic management of an isolated giant renal hydatid cyst guided by single-incision laparoscopy using conventional instruments: The Santosh-PGI technique. *Asian J Endosc Surg*. 2013;6:342–345. DOI:10.1111/ases.12050.

- [53] Arif SH, Shams Ul B, Wani NA, Zargar SA, Wani MA, Tabassum R, et al. Albendazole as an adjuvant to the standard surgical management of hydatid cyst liver. *Int J Surg.* 2008;6:448–451.
- [54] Von Sinner WN, Hellstorm M, Kavegi I, Norlen BJ. Hydatid disease of urinary tract. *J Urol.* 1993;149:577–580.
- [55] Neumayr A, Troia G, de Bernardis C, Tamarozzi F, Goblirsch S, Piccoli L, et al. Justified concern or exaggerated fear: The risk of anaphylaxis in percutaneous treatment of cystic echinococcosis—a systematic literature review. *PLoS Negl Trop Dis.* 2011;5:e1154.
- [56] Tscholl R, Ausfeld R. Renal replantation (orthotopic autotransplantation) for echinococcosis of the kidney. *J Urol.* 1985;133:456457.
- [57] Zmerli S, Ayed M, Horchani A, Chami I, El Ouakdi M, Ben Slama MR. Hydatid cyst of the kidney: Diagnosis and treatment. *World J Surg.* 2001;25:68–74.
- [58] Afsar H, Yagci F, Aybasti N, Meto S. Hydatid disease of the kidney. *Br J Urol.* 1994;73:17–22.
- [59] Aggarwal S, Bansal A. Laparoscopic Management of Renal Hydatid Cyst. *JSLs.* 2014;18:361–366. DOI:10.4293/108680813X13753907291396.
- [60] Shah KJ, Ganpule AP, Desai MR. Isolated renal hydatid cyst managed by laparoscopic transperitoneal nephrectomy. *Indian J Urol.* 2009;25:531–533.
- [61] Chipde SS, Yadav A, Ranjan P, Prakash A, Kapoor R. Total laparoscopic management of a large renal hydatid cyst by using hydatid trocar cannula system. *Journal of Surgical Technique and Case Report.* 2012;4:32–35. DOI:10.4103/2006-8808.100351
- [62] Ozden E, Bostanci Y, Mercimek MN, Yakupoglu YK, Yilmaz AF, Sarikaya S. Renal hydatid cyst treatment: Retroperitoneoscopic “closed cyst” pericystectomy. *International Journal of Urology.* 2011;18:237–239. DOI: 10.1111/j.1442-2042.2010.02703.x
- [63] Kumar S, Nanjappa B, Gowda KK. Laparoscopic management of a hydatid cyst of the adrenal gland. *Korean J Urol.* 2014;55:493–495.
- [64] Turan T, Tuncay L, Kayik S, Atahan O, Aybek Z. Retrovesical hydatid cyst. *J Urol.* 1998;159:2085–2086.
- [65] Subramaniam B, Abrol N, Kumar R. Laparoscopic Palanivelu-hydatid-system aided management of retrovesical hydatid cyst. *Indian Journal of Urology: IJU: Journal of the Urological Society of India.* 2013;29:59–60. DOI:10.4103/0970-1591.109987.
- [66] Vaidyanathan S, Rao MS, Sharma SK, Rajendran LJ, Subudhi CL, Rao KM, et al. Non-operative management of a pelvic hydatid cyst communicating with the bladder. *J Urol.* 1979;121:245–247.

- [67] Görgen H, Api M, Çetin A. Primary adnexial hydatid cyst mimicking ovarian tumor. *Journal of the Turkish German Gynecological Association*. 2009;10:232–234.
- [68] Dogra P, Javeli T, Saini A, Sharma S, Gupta N. Isolated retrovesical hydatid cyst [Internet]. 2010. Available from: <http://www.bjui.org/ContentFullItem.aspx?id=546>.
- [69] Sallami S, Nouria Y, Rhouma SB, Tanguour M, Cherif K, Rebai S, et al. Endoscopic treatment of a primary prostatic hydatid cyst: A mini-invasive therapeutic approach. *Urol J*. 2010;7:270-274.
- [70] El-Kappany HA, El-Nahas AR, El-Nahas HA. Laparoscopic excision of prostatic hydatid cyst: Case report and review of literature. *Journal of Endourology*. April 2005;19:3:290–294. DOI:10.1089/end.2005.19.290.

