

# We are IntechOpen, the world's leading publisher of Open Access books Built by scientists, for scientists

**4,800**

Open access books available

**122,000**

International authors and editors

**135M**

Downloads

Our authors are among the

**154**

Countries delivered to

**TOP 1%**

most cited scientists

**12.2%**

Contributors from top 500 universities



**WEB OF SCIENCE™**

Selection of our books indexed in the Book Citation Index  
in Web of Science™ Core Collection (BKCI)

Interested in publishing with us?  
Contact [book.department@intechopen.com](mailto:book.department@intechopen.com)

Numbers displayed above are based on latest data collected.

For more information visit [www.intechopen.com](http://www.intechopen.com)



---

# Focal High Intensity Focused Ultrasound for Prostate Cancer

---

Fouad Aoun, Marc Zanaty, Alexandre Peltier and  
Roland van Velthoven

Additional information is available at the end of the chapter

---

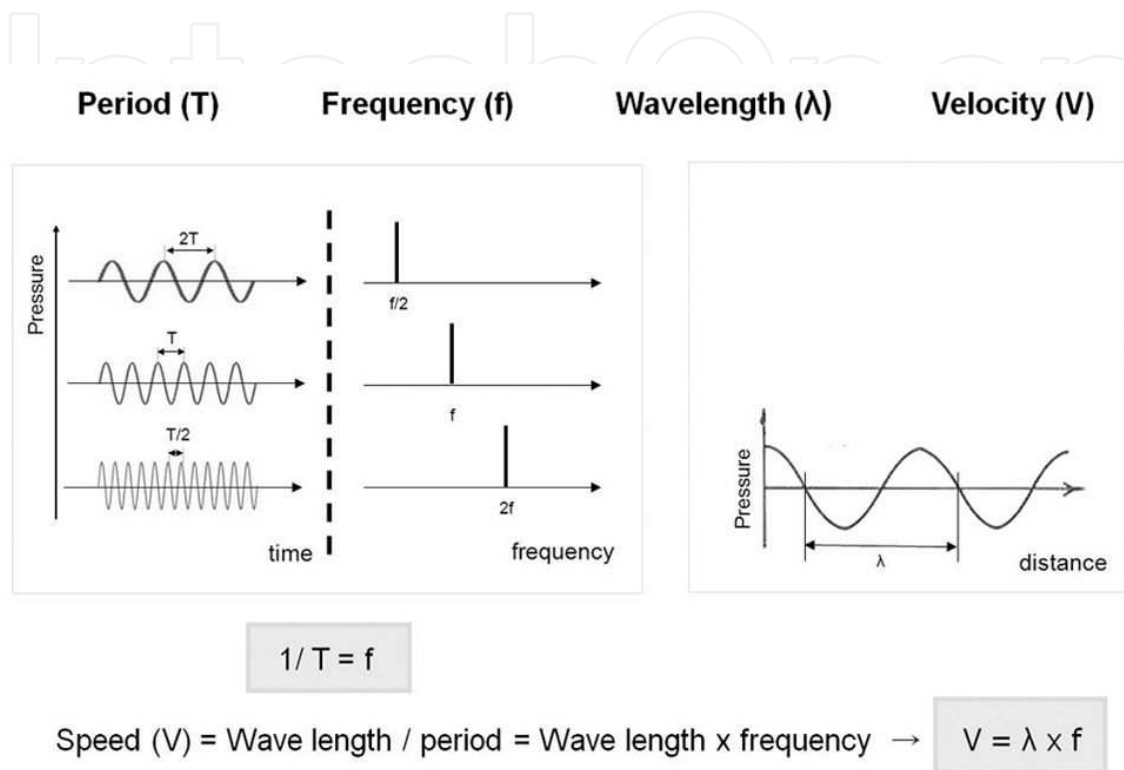
## 1. Introduction

Conventional treatment options for organ confined prostate cancer range from active surveillance to whole gland radical therapy. Active surveillance has the distinct advantage of avoiding over treatment and treatment related morbidity but carries the risk of silent progression of prostate cancer in up to 35 % of cases [1]. It may also induce no treatment related significant anxiety and uncertainty [2]. Radical therapy has the advantage of improving the overall and cancer specific survival in appropriately selected patients [3-4] but bears significant risk of treatment related functional complications that detrimentally affect quality of life [5-6]. Therefore, counseling patients for appropriate, individual treatment strategy remains challenging even for experienced physicians.

Consequently, focal therapy has emerged as an alternative option to standard therapies. The goal of this tissue preserving strategy as defined by the International Task Force on Prostate Cancer and the Focal Lesion Paradigm would be to 'selectively ablate(s) known disease and preserve(s) existing functions, with the overall objective of minimizing lifetime morbidity without compromising life expectancy [7]. A number of focal therapy energies and modalities have commonly been used [8]. Among these therapies, High Intensity Focused Ultrasound (HIFU) emerged as a valid mini invasive therapy for localised prostate cancer, using focused ultrasound to generate areas of intense heat to induce tissue necrosis. This energy delivery system originally used to treat the whole prostate is used nowadays to treat a part of the gland. Many case series have reported encouraging short term functional and oncological results of men with prostate cancer treated primarily in a focal manner [8-19]. Recently, we have published the first mid-term report (median follow up of 38 months) of focal HIFU for a clinically unilateral prostate cancer.

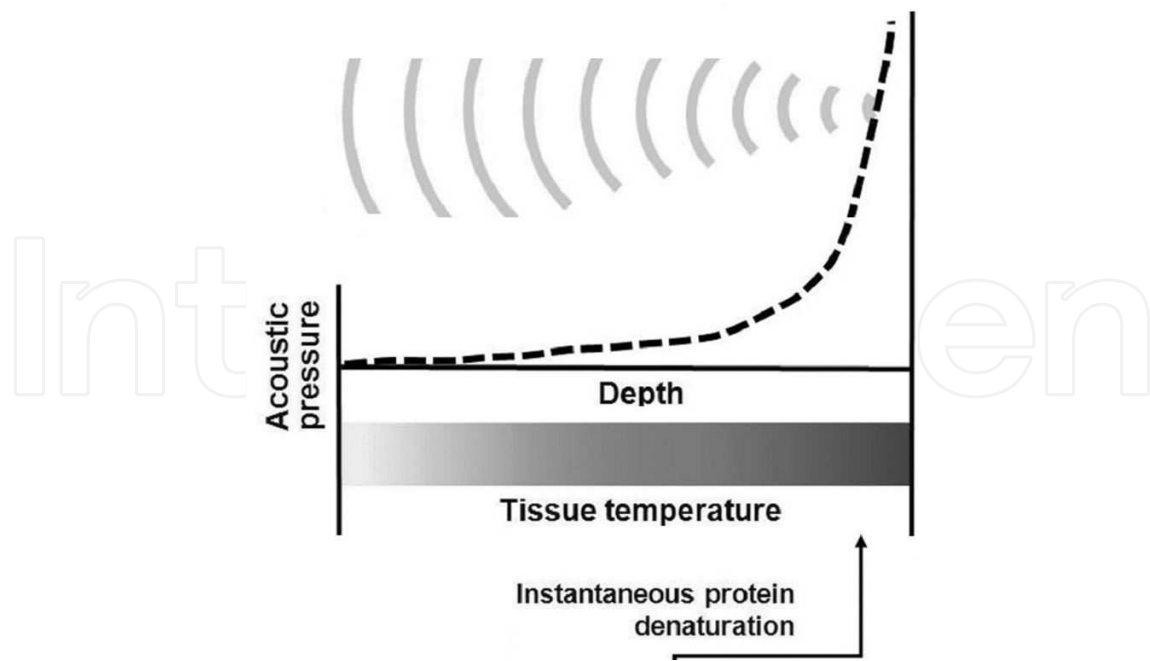
## 2. Basic physics of waves and ultrasound

To understand the basic principle of high intensity focused ultrasound as an ablative treatment modality for prostate cancer, the main properties of sound waves should be known and are summarized in figure 1 and 2.



**Figure 1.** Physical parameters of sound physics

Sound is defined as a mechanical disturbance from a state of equilibrium that propagates through an elastic material medium in the form of vibrating waves. These vibrating waves transport energy from its source to another area as long as a medium is present. The energy transported by sound is known as acoustic energy or sonic energy. Sonic intensity (SI), defined as a time-average rate of sonic energy-flow through a unit area (SI unit: W/cm<sup>2</sup>), is proportional to sonic pressure square and has a positive correlation with the power and energy of sound. This implies that the amount of energy accumulating at a target area is larger when the sonic pressure or intensity increases. The latter parameter varies with space and time, and it is usually expressed as peak or average intensity, and both quantities can refer to either a spatial or temporal dimension (e.g. ISP = spatial peak intensity, ISATA = spatial average, temporal average intensity). The frequency of a wave is derived from the amount of cycles per unit of time. Ultrasound (US) is a form of sound that has a frequency higher than the frequency detected by human ear (> 20.000 Hz vs. 20-20.000 Hz). HIFU therapy utilizes high intensity US waves that are propagated through human tissues. In contrast to other ablative therapies, HIFU therapy operates without the need of an electrode or antenna to deliver its waves. However, the main challenge of such a technique is focusing energy-accumulation at the target area to



**Figure 2.** HIFU uses high energy US waves generated from numerous sources and focuses them to a small spot. Acoustic pressure is rapidly elevated near focus where tissue temperatures are also raised to level that is sufficient for coagulation necrosis

induce significant biological reactions without causing harm to the intervening and surrounding tissues. Recently, a phased array US transducer technique was adopted for focal HIFU treatment. It sends temporally different sets of electronic signals to each specific transducer component, thus enabling beam-steering and focusing, which can move a focal spot in virtually any direction within physically allowed ranges. This system is not only more versatile than other systems but also highly efficient without any sonic attenuation [20].

### 3. Biological interactions of US

Since the mid 1950, US have been extensively used for diagnostic procedures without any detrimental effect on the human body [21]. However, it must be noted that US waves used for therapeutic purposes could be potentially dangerous. In fact, it carries energy that causes biological reactions in various ways. The most important are the thermal (hyperthermia) and non thermal (acoustic cavitation) effects [22-23]. The thermal effect is tissue heating and protein denaturation can occur at a temperature of  $56^{\circ}\text{C}$  [24-25]. Protein denaturation contributes to a subsequent coagulation necrosis (thermal ablation). The effect is a function of the wave amplitude and pulse frequency. Acoustic cavitation is defined by the creation and development of bubbles or cavities. The violent oscillation and collapse in US fields of these bubbles cause a significant degree of mechanical and thermal effects. Mechanical and cavitation tissue effects are caused by high amplitudes and ultra-short pulse wave, with amplitude reaching 100 Mpa and a pulse of 1-2 ms. Moderate pressure amplitude of 10 Mpa and continuous wave of 1 s are the cause of thermal effects. Short ultrasound pulses and low amplitude up to 1 Mpa

causes no significant heating, but cavitation caused by this type of waves are used in some circumstances like enhancing a drug delivery or the transient opening of the blood-brain barrier [22].

#### **4. Mechanisms of action of high intensity focused ultrasound**

The technique is based on the generation of focused ultrasound field. The focused ultrasound field is generated by a piezoelectric transducer with a center frequency of 1 to 7 MHz. The field is coupled into the body and aimed into a target region. Ultrasound waves are absorbed by tissues throughout their propagation and the acoustic energy will be converted to heat with a high energy density inside the focal zone [22]. The result is a temperature rise in the target zone within seconds to a level exceeding the threshold level of protein denaturation which is around 60 degrees. The result will be protein coagulation and coagulative necrosis [22-24]. In contrast there is a low acoustic energy density in the surrounding structures which keep them spared. This will create elliptical small volume lesions of 50-300 mm<sup>3</sup>. Larger volume can be ablated without gaps by combining single lesions.

Between sonication a pause is necessary to prevent boiling and bubbles formations which can reflect and distort the ultrasound field and the consequence is unpredictable lesion growth and lesion formation in unwanted areas. So to ablate a large solid tumor it can take several hours. Thus HIFU is a very time consuming procedure [22]. HIFU has the advantage over other thermal ablative techniques of being a mini-invasive and non-ionizing with no long-term cumulative effects which means that it could be safely repeated. Further more it is interesting non invasive surgical tool because it can cause cell death in a tissue that is distant from the source of US [23].

#### **5. Clinical devices in use**

There are two main types of transducers used for HIFU. In general HIFU needs a high power ultrasound transducer. Such kind of transducers is made of low loss piezoceramic materials or piezocomposites working in resonant mode. The two major types are the self-focusing spherical shaped piezoceramic transducers with fixed aperture and fixed focal length which is the simplest, and the phased array transducers made up of a large number of separate transducer elements. Thereby each element is driven by a separate electric radio frequency signal with an individual phase, frequency and amplitude. The advantages of phased arrays are the possibility for an adaptive selection of elements, the fast electronic beam steering and the beam forming capability. Such transducers are much more expensive and the number of elements in such transducers can reach thousands in some special cases [22].

On the other hands we can divide the transducers into extracorporeal used for the treatment of cutaneous and abdominal tumors, transrectal as those used for the prostate, and interstitial and endoscopic ones used for the treatment of biliary or esophageal lesions [24].

## 6. Guiding/monitoring of therapy

Therapy guidance is the key for a safe and effective HIFU. Guidance is accomplished mainly with two imaging methods which are US and MRI. Imaging techniques are used with HIFU therapy not only for therapeutic guidance but it allows also therapy planning and targeting, monitoring, controlling and assessing the treatment response and follow-up [22].

### 6.1. Ultrasound monitoring

This is the case of most today's HIFU treatment. In general the divergent field of the diagnostic transducer and the field of therapeutic source are superposed and arranged in parallel so that the diagnostic imager provides the beam view. This eases the positioning of the therapeutic source and the identification of organ at risk [22]. Real-time visualization of the targeted volume is feasible with decoupling of US image and focused US.

US are able to detect cloud of gas bubbles that are formed as results of cavitation and tissue heating. The detection of bubble could be an indication for the position of the thermal focus, but this cannot be used to assess and control lesion formation.

US are not able to perform temperature mapping. Some try to use some parameters such as speed of sound, or attenuation or reflection coefficient as indicators for temperature variations, but with modest success.

The major advantages of US are, first they share same physical mechanism so a good assessment of the beam pass is possible. Then it allows the use of conventional materials for the therapy unit so that the diagnostic US transducer can be easily integrated in the therapeutic source that allows for a small and flexible devices with lower prices [22].

### 6.2. MR-monitoring

The advantages of MRI over US are the capacity of giving a morphological image for planning, targeting and thermal monitoring. It can also assess the shape and size of the induced tissue lesion at the end of therapy. Contrast enhanced T1 imaging are employed. The induced lesions prove hypointense reflecting the loss of perfusion. Major disadvantage is the need for an MR compatible HIFU therapy unit and the cost of the MR scanner. Limitations are the confined space for patient access and the need of a complex and expensive technology [22].

### 6.3. MR thermometry

A different method exists to measure the temperature related changes with the MR. Mainly four methods have been described: T1, diffusion, proton density, and proton resonance frequency shift. The most frequently used method is the proton resonance frequency shift (PRFS). The proton resonance frequency shift can be measured directly or by phase mapping which consists of observing the phase shift induced by temperature change. Phase mapping is easier to do than direct assessment. Therefore phase mapping is the most common approach used for temperature mapping [22].



## 7. HIFU Therapy for prostate cancer: Its role in focal therapy

HIFU for the treatment of localized prostate cancer was developed in 1990. Nowadays there are two available devices for the treatment of prostate cancer: the Ablatherm™ (EDAP TMS S.A., Vaulx-en-Velin, France) and the Sonablate™ (Focus Surgery, Inc, Indianapolis, Indiana, USA) [26].

Both of them have a simultaneous imaging technique coupled to the treatment device. They differ by patient positioning and the degree of manual control of power. Currently, the technique is used among many cancer centers despite the fact that available guidelines do not recommend it for the treatment of localized prostate cancer. In 2010, the Cancer Care Ontario group excluded HIFU from its recommendations due to lack of randomized controlled clinical trials and short follow up [27]. The NICE guidelines in 2012 considered HIFU as an experimental technique with further studies needed in order to conclude [28]. In 2014, the FDA bans the use of HIFU for whole-gland primary treatment of clinically localized prostate cancer. At present, high quality evidence on efficacy and safety of HIFU is based on uncontrolled case series with a significant overlap of patients among series. There are no direct comparisons with active surveillance or whole gland radical therapies. Furthermore, the technique is not standardized and patient selection is not unanimous. The ideal candidate is defined as a patient aged > 70 years of age, with clinical stage T1-T2 N0M0, a Gleason score <7, a PSA level <15 ng/ml and a prostate volume of <40 ml, in particular if the patient is unsuitable for or refuse radical therapy [26]. A prostate volume of >40 ml and the presence of large calcifications are a contraindications for HIFU. In such cases where the volume exceed 40 ml a TURP or a cytoreductive androgen deprivation therapy or a 5 alpha reductase inhibitor before HIFU is recommended to reduce the volume of the prostate. The number of HIFU treatment per patient varies between one and five. The median follow up time is short with the longest series reporting data after a median follow up of 94 months [29].

HIFU could be used as a primary treatment or as a salvage therapy in recurrent prostate cancer after radiotherapy failure. The field could involve a whole gland ablation or a more focal therapy. For technical considerations, Hemiablation HIFU of an entire lobe delivered with intention to treat is currently used for focal therapy. The technique was demonstrated to be feasible and functional and disease control outcomes were encouraging at 3 years of follow up.

## 8. The principle rationale of tissue preservation is harm reduction and functional preservation

Adverse events affecting the urinary tract are reported in 2-58% of whole gland HIFU therapy in the literature. Rectal toxicities ranged from 0 to 15%. Erectile dysfunction is reported in 0 to 39% of cases [30]. Toxicity rates are believed to be lower after focal therapy. In our case series, 31 consecutive patients with unilateral organ confined prostate cancer were primarily treated by hemiablation HIFU. Early self-resolving LUTS were the most common complications and no rectal toxicities were reported. The strategy was well tolerated in the genitourinary functional domains: all patients were pad free continent despite a high number of apical lesions

(n=12) and only 25% of men in our cohort of relatively elderly patients (average age 71 years) who were potent preoperatively reported having ED post hemiablation. The procedure could possibly be delivered in an ambulatory care setting [19].

## 9. Monitoring of patients after focal HIFU

In the literature, there is no consensus on whether cancer control in focal therapy should be considered the absence of any cancer or the absence of clinically significant cancer and whether this should be limited to the treated or untreated area. In addition there is no standard follow up protocol for the assessment of clinical failure. In our opinion, histologic confirmation of complete ablation within the treated area appears to be essential in focal therapy. That's why any positive biopsy in the treated lobe independently of the percentage of core involvement should be considered a clinical failure. In contrast, contralateral positive biopsy should not be considered as a clinical failure but as a technical limitation. As a surrogate, although PSA testing is accepted as a valid outcome in standard therapy, there are no validated biochemical measures in tissue preservation. Furthermore, PSA values are difficult to interpret in the follow up because many factors influence post treatment values (the proportion of initial PSA that was due to tumor, amount of residual prostate tissue, progression of BPH, TURP...). Definitions that are currently used and validated for biochemical failure in whole gland radiation therapy (ASTRO, Phoenix, Stuttgart...) are used, without any evidence or validation, in whole gland HIFU and focal therapy [31]. Phoenix criteria should not be considered as response criteria to define failure but as a threshold to offer biopsy. We believe that a specific PSA based definition is unlikely to be derived and multiparametric MRI will play a major role in the future in the definition of failure if it is validated against histology outcomes.

## 10. Oncologic outcomes

Following whole gland ablation therapy, negative biopsy rates at 3 month of 51-96% and 64-87% with Ablatherm and Sonablate respectively were reported [32-36]. Overall survival rates and prostate cancer specific survival rates were 90% and 100% at 5 years and 83% and 98% at 8 years, respectively. The actuarial biochemical failure-free survival rates at 5 and 7 years were 77% and 69%, respectively. The actuarial disease-free survival rate at 5 and 7 years were 66% and 59%, respectively [32-36]. Biochemical success or failure rate was stratified against risk category according to the D'Amico classification in the majority of reports and was uniformly more favourable for the low and intermediate risk category compared to the high risk category. Some authors have argued that HIFU is a coagulative technology that unlike radiation therapy results in complete cell destruction independently of Gleason score. However, high grade tumours in prostate cancer are associated with increased neoangiogenesis responsible of a heat sink phenomenon that is tissue cooling by blood flow that causes thermal loss. The tissue under ablation in high grade tumour may be inadequately ablated and is a high risk site for persistent residual progressive disease and metastatic spread. Following



focal therapy, we demonstrated a biochemical recurrence free survival of 100%, 89%, 82.7% at 1, 2 and 3 years respectively, with an overall and cancer specific survival of 100% [19].

## 11. Limitations and Future perspectives

As any other interventional technique, there are some limitations for HIFU that must be mentioned. First, there are factors to take into account such as collateral damage to the tissues and the fact that the technique is operator dependent [37]. Second, the lack of comparative trials precludes any conclusion regarding the added value of HIFU treatment compared to active surveillance or radical therapies. Urological societies recommend using focal HIFU in controlled trials in order to provide the needed answers. In the future, the use of focal HIFU will not be limited to prostate cancer but will widespread to other applications. The two most interested research topics are focused ultrasound mediated targeted drug delivery and the transient and reversal opening of the blood-brain barrier

## Author details

Fouad Aoun\*, Marc Zanaty, Alexandre Peltier and Roland van Velthoven

\*Address all correspondence to: fouad.aoun@bordet.be

Department of Urology, Free University of Brussels (ULB), Brussels, Belgium

## References

- [1] Marberger M, Barentsz J, Emberton M, Hugosson J, Loeb S, Klotz L, Koch M, Shariat SF, Vickers A. Novel approaches to improve prostate cancer diagnosis and management in early-stage disease. *BJUI* 2012;109(2):1-7.
- [2] Kazer MW, Psutka SP, Latini DM, Bailey DE. Psychosocial aspects of active surveillance. *Curr Opin Urol.* 2013 May;23(3):273-7.
- [3] Wilt TJ, Brawer MK, Jones KM, et al. Radical prostatectomy versus observation for localized prostate cancer. *N Engl J Med.* 2012 Jul 19;367(3):203-13.
- [4] Boorjian SA, Eastham JA, Graefen M, et al. A critical analysis of the long-term impact of radical prostatectomy on cancer control and function outcomes. *Eur Urol* 2012;61(4):664-675.
- [5] Resnick MJ, Koyama T, Fan KH, et al. Long-term functional outcomes after treatment for localized prostate cancer. *N Engl J Med* 2013;368(5):436-445.

- [6] Turpen R, Rosser CJ. Focal therapy for prostate cancer: revolution or evolution? *BMC Urology* 2009;9:2.
- [7] Valerio M, Ahmed HU, Emberton M et al. The Role of Focal Therapy in the Management of Localised Prostate Cancer: A Systematic Review. *Eur Urol*. 2013 Jun 6. pii: S0302-2838(13)00557-5.
- [8] Onik G, Vaughan D, Lotenfoe R. The “male lumpectomy”: focal therapy for prostate cancer using cryoablation results in 48 patients with at least 2-year follow-up. *Urol Oncol*. 2008;26:500–505.
- [9] Lambert EH, Bolte K, Masson P. Focal cryosurgery: encouraging health outcomes for unifocal prostate cancer. *Urology*. 2007;69:1117–1120.
- [10] Muto S, Yoshii T, Saito K. Focal therapy with high-intensity-focused ultrasound in the treatment of localized prostate cancer. *Jpn J Clin Oncol*. 2008;38:192–199.
- [11] Ward JF, Jones JS. Focal cryotherapy for localized prostate cancer: a report from the national Cryo On-Line Database (COLD) Registry. *BJU Int*. 2011 published online Oct 28.
- [12] El Fegoun AB, Barret E, Prapotnich D. Focal therapy with high-intensity focused ultrasound for prostate cancer in the elderly. A feasibility study with 10 years follow-up. *Int Braz J Urol*. 2011;37:213–219.
- [13] Ahmed HU, Hindley RG, Dickinson L et al. Focal therapy for localised unifocal and multifocal prostate cancer: a prospective development study *Lancet Oncol* 2012; 13(6): 622–632.
- [14] Barret E, Ahallal Y, Sanchez-Salas R et al. Morbidity of focal therapy in the treatment of localized prostate cancer *Eur Urol*, 2013;63(4):618–622.
- [15] Ahmed HU, Freeman A, Kirkham A et al. Focal therapy for localized prostate cancer: a phase I/II trial. *J Urol*, 2011;185(4):1246–1254.
- [16] Bahn DK, Silverman P, Lee F, Badalament R, Bahn ED, Rewcastle JC. Focal prostate cryoablation: initial results show cancer control and potency preservation. *J Endourol*, 2006;20(9):688–692.
- [17] Ellis DS, Manny TB, Rewcastle JC. Cryoablation as primary treatment for localized prostate cancer followed by penile rehabilitation. *Urology* 2007, 69(2): 306–310
- [18] Bahn D, de Castro Abreu AL, Gill IS et al. Focal cryotherapy for clinically unilateral, low-intermediate risk prostate cancer in 73 men with a median follow-up of 3.7 years. *Eur Urol*, 62 (1) (2012), pp. 55–63.
- [19] van Velthoven R, Aoun F, Limani K, Narahari K, Lemort M and Peltier A Primary Zonal High Intensity Focused Ultrasound for Prostate Cancer: Results of a Prospective Phase IIa Feasibility Study *Prostate Cancer Volume* 2014, Article ID 756189, 6 pages <http://dx.doi.org/10.1155/2014/756189>

- [20] Hynynen K, McDannold N. MRI-guided focused ultrasound for local tissue ablation and other image-guided interventions. In: Wu J, Nyborg WL, eds. *Emerging therapeutic ultrasound*, 1<sup>st</sup> ed. Singapore: World Scientific Publishing, 2006:167-218
- [21] Dalecki D. Mechanical bioeffects of ultrasound. *Annu Rev Biomed Eng* 2004;6:229-248
- [22] Jenne, J.W., T. Preusser, and M. Gunther, High-intensity focused ultrasound: principles, therapy guidance, simulations and applications. *Z Med Phys*, 2012. 22(4): p. 311-22.
- [23] Cordeiro, E.R., et al., High-intensity focused ultrasound (HIFU) for definitive treatment of prostate cancer. *BJU Int*, 2012. 110(9): p. 1228-42.
- [24] ter Haar GR. Therapeutic application of ultrasound. *Prog Biophys Mol Biol* 2007;93:111-129.
- [25] ter Haar GR. Therapeutic and surgical applications. In: Hill CR, Bamber JC, ter Haar GR, eds. *Physical principles of medical ultrasound*, 2nd ed. West Sussex: John Wiley & Sons, 2004:407-456.
- [26] Rebillard, X., et al., High-intensity focused ultrasound in prostate cancer; a systematic literature review of the French Association of Urology. *BJU Int*, 2008. 101(10): p. 1205-13.
- [27] Lukka H, Waldron T, Chin J, Mayhew L, Warde P, Winkquist E, Rodrigues G, Shayan B High-intensity focused ultrasound for prostate cancer: a practice guideline. *Can Urol Assoc J*. 2010 Aug;4(4):232-6.
- [28] NICE guidelines 2012: Focal therapy using high-intensity focused ultrasound for localised prostate cancer. Issued in [guidance.nice.org.uk/ipg424](http://guidance.nice.org.uk/ipg424)
- [29] Limani K, Aoun F, Holz S, Paesmans M, Peltier A, van Velthoven R. Single High Intensity Focused Ultrasound Session as a Whole Gland Primary Treatment for Clinically Localized Prostate Cancer: 10-Year Outcomes. *Prostate Cancer* 2014, <http://dx.doi.org/10.1155/2014/186782>
- [30] Warmuth M, Johansson T, Mad P. Systematic review of the efficacy and safety of high-intensity focussed ultrasound for the primary and salvage treatment of prostate cancer. *Eur Urol*. 2010 Dec;58(6):803-15.
- [31] Roach M 3rd, Hanks G, Thames H Jr, et al. Defining biochemical failure following radiotherapy with or without hormonal therapy in men with clinically localized prostate cancer: recommendations of the RTOG-ASTRO Phoenix Consensus Conference. *Int J Radiat Oncol Biol Phys*. 2006; 65:965-974.
- [32] Blana A, Robertson CN, Brown SC, Chaussy C, Crouzet S, Gelet A, Conti GN, Ganzler R, Pasticier G, Thuroff S, Ward JF. Complete high-intensity focused ultrasound in

prostate cancer: outcome from the @-Registry. *Prostate Cancer Prostatic Dis.* 2012 Sep;15(3):256-9.

- [33] Pfeiffer D, Berger J, Gross AJ. Single application of high-intensity focused ultrasound as a first-line therapy for clinically localized prostate cancer: 5-year outcomes. *BJU Int.* 2012 Dec;110(11):1702-7
- [34] Thüroff S, Chaussy C. Evolution and outcomes of 3 MHz high intensity focused ultrasound therapy for localized prostate cancer during 15 years. *J Urol.* 2013 Aug; 190(2):702-10.
- [35] Pinthus JH, Farrokhyar F, Hassouna MM, Woods E, Whelan K, Shayegan B, Orovan WL. Single-session primary high-intensity focused ultrasonography treatment for localized prostate cancer: biochemical outcomes using third generation-based technology. *BJU Int.* 2012 Oct;110(8):1142-8.
- [36] Crouzet S, Rebillard X, Chevallier D, Rischmann P, Pasticier G, Garcia G, Rouviere O, Chapelon JY, Gelet A. Multicentric oncologic outcomes of high-intensity focused ultrasound for localized prostate cancer in 803 patients. *Eur Urol.* 2010 Oct;58(4):559-66.
- [37] Baumunk D, Andersen C, Heile U, et al, High-intensity focussed ultrasound in low-risk prostate cancer - oncological outcome and post interventional quality of life of an inexperienced therapy centre in comparison with an experienced therapy centre. *Aktuelle Urol.* 2013 Jul;44(4):285-92.

