

We are IntechOpen, the world's leading publisher of Open Access books Built by scientists, for scientists

4,800

Open access books available

122,000

International authors and editors

135M

Downloads

Our authors are among the

154

Countries delivered to

TOP 1%

most cited scientists

12.2%

Contributors from top 500 universities



WEB OF SCIENCE™

Selection of our books indexed in the Book Citation Index
in Web of Science™ Core Collection (BKCI)

Interested in publishing with us?
Contact book.department@intechopen.com

Numbers displayed above are based on latest data collected.
For more information visit www.intechopen.com



Radiotherapy and Chemotherapy Treatments in Head and Neck Cancer Patients — Protocol for Management Before, During and After RTP

Paula Bonar Alvarez, Mario Perez-Sayans García,
Maria Elena Padín Iruegas and Abel García-García

Additional information is available at the end of the chapter

1. Introduction

The term oral cancer is used as a synonym for squamous cell carcinoma, which constitutes 90% of malignant neoplasms. Surgery, radiotherapy and chemotherapy are the election treatments. The selection of an only treatment or combination depends principally on the location of the tumour, its size, histological subtype, stage and the patient's general state of health. Surgery and RTP tend to be used alone to treat cases of non-metastatic disease (stages I and II), whereas more advanced cancers (III and IV) are treated by surgery in combination with radiotherapy and/or chemotherapy. It is important to bear in mind that the surgeries these patients undergo are aggressive. They provoke aesthetic and functional alterations that affect the patient's quality of life.

Prior to undergoing radiotherapy treatment, it is important that patients with head and neck cancer undergo a dental evaluation. This is because surgery provokes big aesthetic and functional alterations. Therefore, patients who already show deficient oral health before treatment are likely to leave their oral hygiene, increasing the gravity of complications.

There are a number of complications that appear in the head and neck region, not only during treatment but also, after. These include mucositis, dental caries and xerostomia. In this paper, we will describe the adverse, acute and late complications, as well as the treatment guidelines. Furthermore, we will develop a patient management protocol for before, during and after radiotherapy.

2. Head and neck cancer

The term oral cancer is used as a synonym for oral squamous cell carcinoma (OSCC), which accounts for 90% of all head and neck cancers and 3-4% of malignancies [1, 2]. The incidence of head and neck cancer has increased significantly over the past 20 years. Over 575,000 new oral cancer cases are annually diagnosed in the world [3]. According to data published in 1998 by Spanish National Epidemiology Centre, in our country, the number of deaths by oral, pharyngeal and labial cancer amounted to 1,891 of men and 374 of women. In Spain, incidence accounts for 12 to 15 cases per 100,000 men/year and two to four cases per 100,000 women/year [4]. However, the figures are now matching up. This is because some women are adopting harmful habits, which were traditionally attributable to men. The disease mainly affects men over 40 years of age, with a peak of maximum incidence in their 60s [5, 6].

The etiology of cancer has multiple factors. The main risk factors are smoking and alcohol. Despite showing synergistic effects, these are independent risk factors, as shown in a study by Castellsagué et al. [6, 7]. In some cases of solar ultraviolet radiation in lip cancer, infections, diets low in fruit and vegetables, immunodepression, bad oral hygiene and the presence of genetic factors can have a relevant effect.

Patients diagnosed with this cancer are treated by surgery, radiotherapy (RTP), chemotherapy (QTP) or a combined treatment. The choice of a unique or combined treatment depends on the location of the tumour, its extension, histological subtype, tumour stage and the patient's general condition. Surgery and RTP are used in isolation to treat cases of non-metastatic disease (stages I and II). However, advanced stages (III and IV) require concomitant RTP and QTP. In the early stages, the treatment of choice is surgery. With this, the tumour is eliminated with safety margins. This is achieved with or without cervical emptying, depending on the location, size or suspicion of regional metastasis. Once the cervical emptying is completed and analysed, if the structures are affected, subsequent treatment with RTP is evaluated. Advanced stages can be treated with surgery followed by RTP but this combination only cures a minority of patients and fewer than 30% will be alive at five years. With these treatments, tumour control and survival rates are unsatisfactory. Only 30% of patients will be alive after three years, while 60-70% of patients will have a loco-regional recurrence and/or will develop distant metastasis, which, ultimately, is the main cause of death in these patients [8].

QTP, in addition to RTP and surgery, is associated with a better general survival rate in patients with oral or oropharyngeal cancer. Induction QTP can extend survival from 8% to 20% and concomitant adjuvant chemo-radiotherapy can prolong survival up to 16%.

QTP consists of the administration of cytotoxic drugs that are capable of destroying and inhibiting the growth and reproduction of malignant cells [9]. In head and neck cancers, the most extensively used drugs are bleomycin, cisplatin, methotrexate, 5-fluorouracil, vinblastine and cyclophosphamide [10]. QTP can be developed by administering one or more chemotherapeutic drugs. The use of isolated drugs (mono-chemotherapy) has proven useless in the induction of significant complete or partial responses. Thus, the current trend is polychemotherapy, which affects the cellular populations in different cell-cycle phases. This is achieved by using the synergistic action of the drugs, decreasing the development of resistance to them and promoting a higher response per administered dose [10]. The most used combinations

include cisplatin and 5-fluorouracil; cisplatin, 5-fluorouracil and taxol or cisplatin, bleomycin and methotrexate. Cytostatic drugs offer better results in tumours with a significant growth fraction and/or early distant or frequent dissemination such as lymphomas (90% growth fraction). This is not the case for squamous cell carcinoma, which is the most common head and neck malignancy (25% growth fraction). Therefore, QTP is usually associated with another therapeutic modality [11].

RTP can be applied locally (brachytherapy) or externally (teletherapy). The external radiotherapy is the classic way to administer radiotherapy with a remote radiation source of the organism. Sources of external irradiation are low voltage (X-ray), supervoltage (cobalt 60), megavoltage (linear accelerator) and electron beam (power source). Of these, the most widely used treatments for head and neck therapy are cobalt-60 and the linear particle accelerator [12]. External radiotherapy requires a division of the dose and a longer period to carry it out, consisting of a weekly dose of 10 Gy, 2 Gy daily for five days and two days of rest, usually spread out over a period of 5-7 weeks. Fractionated RTP allows a full high dose in the tumour, respecting the normal adjacent tissue and decreasing toxicity. It also conditions the response in healthy and tumour tissues by repairing injuries. This is because, compared to tumour tissue, normal tissue repairs damaged DNA better, especially at low doses. It also promotes the reoxygenation of tumour cells, increasing their radiosensitivity and the repopulation of the tissue between fractions. This is particularly the case during weekends when the area is not irradiated, thereby reducing the early effects [13]. The radiation dose depends on the location and type of tumour and whether the RTP is used alone or combined with other treatment modalities. When the RTP is exclusive, the dose is usually between 60 Gy and 80 Gy, whereas the dose administered post-surgically is 50-60 Gy [1].

On the other hand, brachytherapy is a method that uses ionizing radiation. It places radioactive material in the proximity of or within the tumour. There are different modalities of brachytherapy, of which interstitial RTP is the most frequently used for head and neck tumours. In this modality, Iridium 192 (Ir192) and Iodine 125 (I125) are the most frequent radioactive sources.

RTP and QTP are combined to improve therapeutic results, increasing loco-regional tumour control and distant metastasis [14].

There are different ways to classify the effects produced by RTP on head and neck regions, as are shown in Table 1,2, 3 [10, 15-17].

EFFECTS	ACUTE	LATE
	Mucositis	Necrosis of soft tissue
	Radiodermatitis	Trismus
	Opportunist infections	Osteoradionecrosis (ORN)
	Xerostomia	Post-radiation caries
	Alteration in taste	

Table 1. Acute and late effects of RTP.

CHRONOLOGY	IMMEDIATE	MEDIUM TERM	LONG TERM
	Mucositis	Post-radiation caries	Osteoradionecrosis
	Alteration in taste	Opportunist infections	Tooth disorder
	Xerostomia	Necrosis of soft tissue	
	Radiodermatitis	Trismus	

Table 2. Chronology of RTP: immediate, medium term and long term effects.

EVOLUTION	REVERSIBLE	IRREVERSIBLE
	Mucositis	Xerostomia
	Radiodermatitis	Alteration in taste
	Xerostomia	Post-radiation caries
	Alteration in taste	Osteoradionecrosis
	Opportunist infections	Tooth disorder
	Necrosis of soft tissue	
	Trismus	

Table 3. Evolution of RTP: reversible and irreversible effects.

2.1. Acute complications of radiotherapy

- a. Mucositis is the inflammation of the oral-orpharynx as a result of the cytotoxic effects of RTP. It is the most common complication that appears among patients who have been irradiated with neck and head cancer, with an incidence of 80 %. Mucositis is dose-dependent and therefore, it disappears with the end of the aggression [18]. The risk and its gravity depend on the characteristics of the treatment such as doses, size of the irradiated zone and its division.

The first sign is erythema, which appears when a dose of 10 Gy is accumulated (first week) and persists up to 15 days after the end of the RTP treatment. The point of maximum symptomatology is when there are accumulated doses of 60-70 Gy [19, 20]. Clinically, the mucosa is erythematous and edematous so it can become ulcerated and infected by fungi [19, 21]. The pain that accompanies mucositis can be so intense that it alters the patient's quality of life, limiting their basic oral functions such as speaking, swallowing saliva or eating [21].

Mucositis can be classified in four degrees, according to the intensity of the mucosa [16, 22]:

Grade 0: None (Figure 1).

Grade 1: Erythaema (Figure 2 and 3).

Grade 2: Erythaema, ulcers but capable of ingesting solids (Figure 4).

Grade 3: Ulcers, requiring liquid diet (Figure 5).

Grade 4: Oral feeding is impossible (Figure 6).

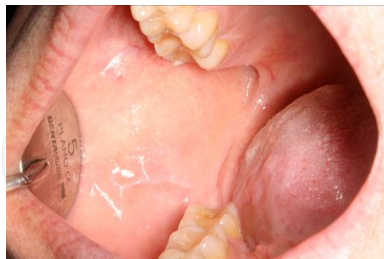

Figure 1. Grade 0.

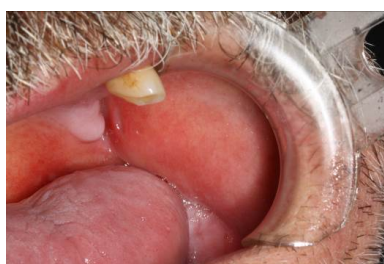

Figure 2. Grade 1.

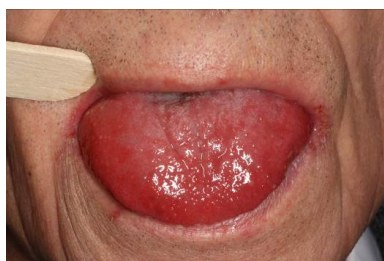

Figure 3. Grade 1.

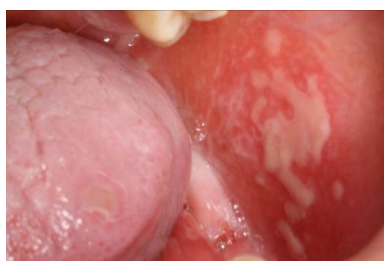

Figure 4. Grade 2.

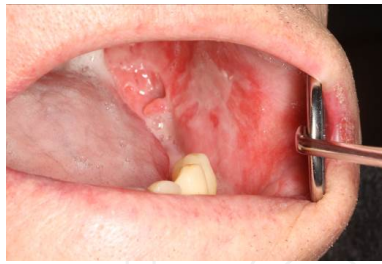


Figure 5. Grade 3.

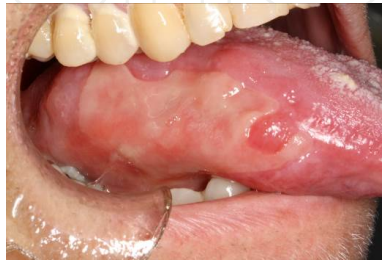

Figure 6. Grade 4.

- b. RTP facilitates the surge of opportunist infections, mainly Candida (Figure 7 and 8) as a result of the reduction of saliva, the use of dentures, deficient oral hygiene and the persistence of habits such as smoking or drinking [23]. These types of infections tend to disappear with topical anti-fungal drugs. However, irradiated patients frequently have to use more effective systemic drugs [24].

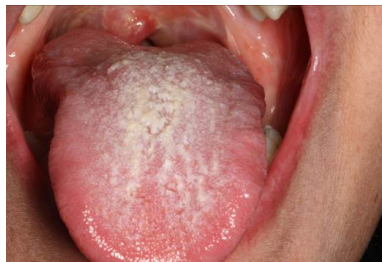

Figure 7. Candidiasis during RTP.

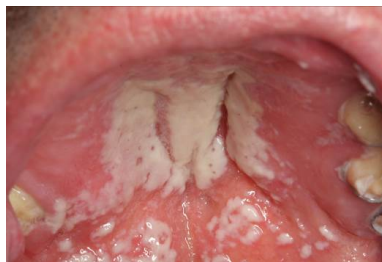

Figure 8. Candidiasis during RTP.

- c. Radiodermatitis is considered as skin and subcutaneous tissue toxicity. Depending on its severity, it is classified in three different levels. Transitory erythaema is produced by the congestion of dermal papillae within the first 24 hours. A dose of 3 Gy is enough to trigger it (Figure 9 and 10). A dose of 25 Gy will produce an acceleration of the skin flaking process, which is manifested as a significant decrease of thickness. This will then become dark, atrophic and flaky, which is called dry radiodermatitis (Figure 11). A 50-70 Gy dose will cause a delayed erythaema, followed by a superficial necrobiosis and the formation of skin scabs. If these lesions progress, bleeding vesicula easily appears, which is called wet radiodermatitis (Figure 12). These lesions are cured when the RTP treatment has ended, leaving scars on the skin. These can be white and esclerotic telangiectastic. Follicles are destroyed and, on occasions, pigmentations can appear [10].

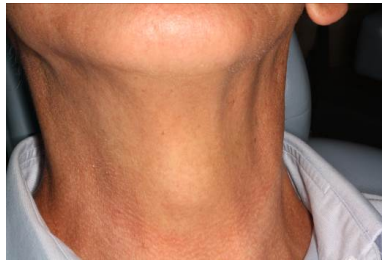

Figure 9. Radiodermatitis: Grade 0, 5 sessions of RTP.

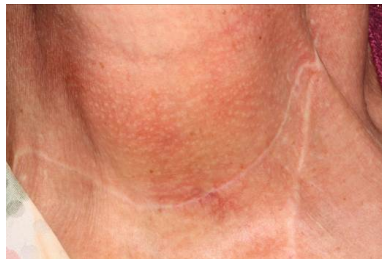

Figure 10. Radiodermatitis Grade I, 10 sessions of RTP.

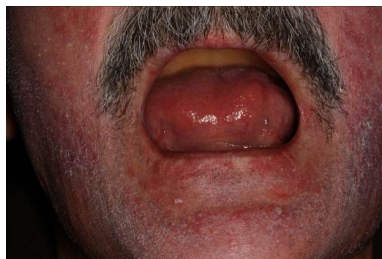

Figure 11. Radiodermatitis: Grade II, 17 sessions of RTP.

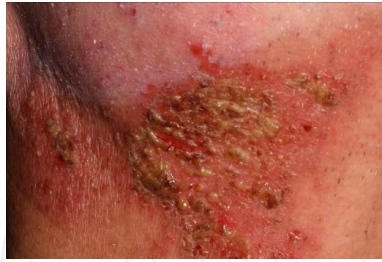

Figure 12. Radiodermatitis Grade III, 24 sessions of RTP.

- d. Most patients suffer xerostomia or salivary hypofunction due to RTP in head and neck cancers. This usually appears within the first weeks of radiation. In low doses (under 30 Gy), it is believed that the damage can be reversible. However, higher doses (over 60-70 Gy) result in an irreversible and permanent xerostomia. With the latter, there is a significant degeneration of the acini, which is reflected by concomitant inflammation and fibrosis of the interstitium (Figure 13).

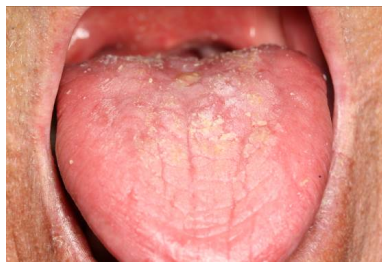

Figure 13. Rough tongue due to salivary hypofunction.

- e. Salivary hypofunction (a resting saliva flow of less than 0.2 ml per minute or a stimulated flow of less than 0.7 ml per minute) is caused by the damage of direct ionizing radiation of the salivary glands' cells [25]. This is the most persistent effect in patients submitted to RTP for head and neck tumours. It is characterized by changes in the amount and quality of saliva (more viscous and scarce). It produces oral discomfort and pain, a higher risk of dental caries, oral infection, difficulty of speech and disfagia. This has a damaging effect on the patient's quality of life [26-28]. The reduction of salivary flow can also increase the susceptibility of the dental caries and takes into account the integrity of the mucosa [29].
- f. The alteration in taste is a result of direct radiation of the taste buds and receptors of taste, as well as changes in the saliva [30-32]. It contributes to loss of appetite, which results in the patient's weight loss. It appears 15 days after the treatment starts from the 4 Gy and it reaches its maximum once the RTP is finished. In most cases, the sense of taste gradually returns to normal or almost normal levels one year after radiotherapy [33]. However, some

patients can experience a residual reduction of taste (hypogeusia), permanent damage to the sense (disgeusia) and the loss of taste (ageusia) [34, 35].

2.2. Late complications of radiotherapy

- a. There is a necrosis of soft tissue characterized by an ulcer located in the irradiated tissue, without the presence of residual malignancy (Figure 14 and 15). It is usually a painful condition and the tissues present a pale colour and lack of flexibility [36].

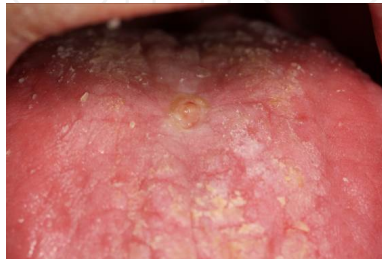

Figure 14. Necrosis of soft tissue two months after finishing RTP.

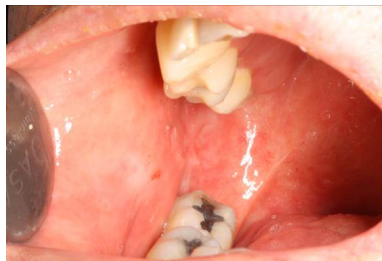

Figure 15. Necrosis of soft tissue two months after finishing RTP.

- b. Trismus is characterized by a reduction in the opening due to the contraction and even fibrosis of the masticating muscles and the ATM (Figure 16). It appears between three and six months after radiation [23]. It can result in eating and communication problems. It also impacts oral hygiene and the use of prosthesis, as well as the development of dental treatments.

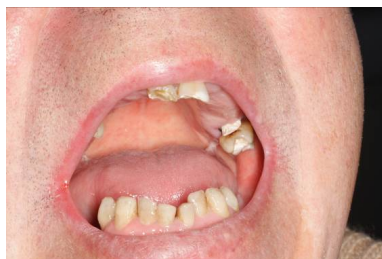

Figure 16. Still suffering from trismus one and a half years after finishing the RTP.

- c. Osteoradionecrosis could be the most severe RTP complication [38]. It is defined as an area of bone exposure in a previously irradiated area, of at least six weeks of evolution and in absence of tumour recurrence [37]. ORN is the result of reduced vascularity of periodontal bone, the periosteum. It causes hypovascular, hypocellular and hypoxic tissue, where the capacity of bone repair and regeneration is severely compromised [38-40]. It can be asymptomatic or it can produce pain, dysaesthesia or anesthesia, depending on its relation with the dental nerve. Patients report halitosis, trismus and dysgeusia. Patients find that ORN impacts food in the lesion and they have difficulties in chewing and swallowing, as well as exhibiting phonation [36]. In most cases, the condition is chronic, developing gradually and becoming wider and painful [38, 41].

There are risk factors that can bring about ORN. These can be related to the tumour, with the patient and with the treatment. With regard to factors that depend on the patient, we fundamentally focus on the realization of post radiotherapy extractions. In fact, the development of ORN with no previous surgery has proved to be extremely strange (incidence of 2.7% after five years). Some other determinant factors are poor oral hygienic, previous irradiations of the zone and the presence of periodontitis. Further factors include bad habits such as tobacco and alcohol. Depending on the treatment, the risk factors are the administrated dose, its division, the RTP type and the irradiated zone. Ultimately, the risk factors, depending on the tumour, include the anatomical localization, the proximity of other bone structures and the size of the tumour. These factors must be taken into account because they increase the risk of ORN and if we are aware of them, we can prevent it.

Most ORN cases take place in the jaw. Here, vascularization is deficient and there is high bone density (Figure 17, 18 and 19). Clinical manifestations of ORN may include pain, orofacial fistulas, exposure of the necrotic bone, pathological fractures and suppuration [42].

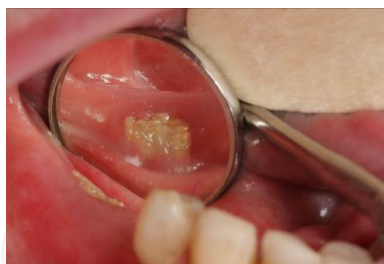

Figure 17. ORN in the jaw after extraction post-RTP.

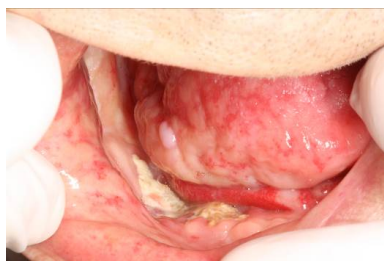

Figure 18. ORN in the jaw after extraction post-RTP.

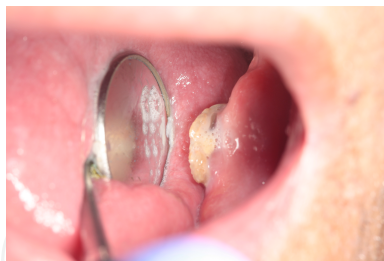

Figure 19. ORN after four months of finishing the RTP. Extraction had been carried out pre-RTP.

One third of ORN cases are spontaneous, although most cases occur due to teeth removal during radiotherapy or during an insufficient healing time after pre-RTP extractions. According to Starcke, Shannon, Murray and Makkonen, when the pre-RTP tooth removal is performed correctly and a certain period passes, a significant increase of osteoradionecrosis is not observed [43-45].

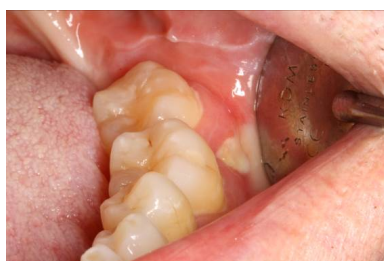

Figure 20. Spontaneous ORN in the jaw after RTP.

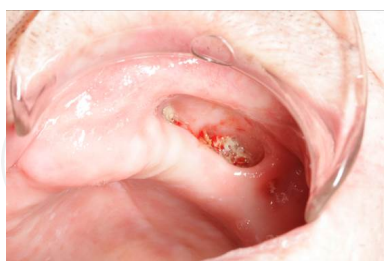

Figure 21. ORN after extraction post-RTP.

Incidence of ORN is two times higher in patients with teeth, although poor dental hygiene and continued drinking and smoking can also contribute to its quick appearance [46]. A higher incidence of osteoradionecrosis has been observed after receiving doses of over 65 Gy. This depends on the fractioning of radiation and the treatment with QTP or surgery in the irradiated area [47] (Figure 22 and 23 - case report of ORN that, after seven months of treatment, positively developed chlorhexidine.).

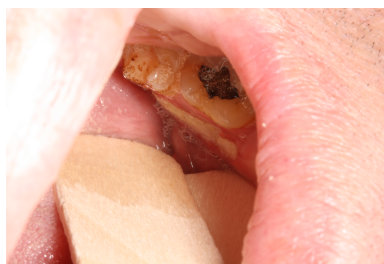

Figure 22. ORN two months after finishing the RTP, without previous extractions.

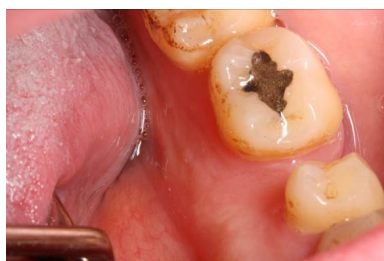

Figure 23. After seven months of good oral hygiene and rinses with chlorhexidine and chlorhexidine gel, it has progressed favourably.

- d.** Dental caries are very frequent in post-radiation starting three months after RTP has ended. There is a collapse and detachment of the enamel prisms that mainly affect the incisal edges, cuspids and cervical region of the teeth [10] (Figure 24). This is the result of a quantitative and qualitative alteration in the saliva, with a decrease of its stopping capacity. This favours the development of an acidogenic-cariogenic bacterial flora. A change towards a soft carbohydrate-rich diet, poor dental hygiene and the deterioration of motivation also influences this (Figure 25).

For irradiated patients, dietary changes - a softer or liquid diet with a higher concentration of carbohydrates - combined with a decrease in saliva, results in a change in the microbiota. This becomes increasingly cariogenic. This, in addition to poor dental hygiene, results in a demineralization of the enamel and the destruction of crowns and the cervical area. Here, the cement and dentin is exposed to the oral environment, producing increased dental sensitivity [48].

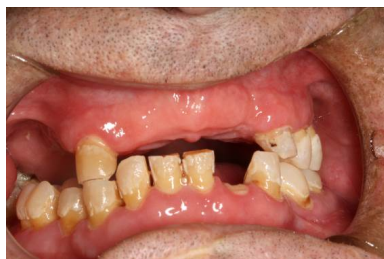

Figure 24. Dental wear during RTP.

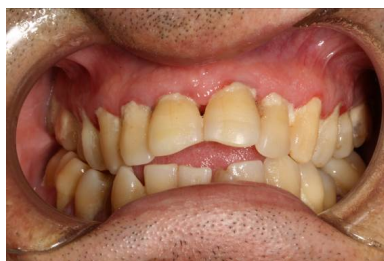

Figure 25. Accumulation of plaque due to poor hygiene during RTP.

3. Protocol for management before RTP

In literature of this subject area, there are articles published on the management of complications in patients with head and neck cancer. These mainly focus on mucositis, radiodermatitis and osteoradionecrosis. However, in order for this to be prevented, we must monitor the patient before, during and after radiotherapy. In this chapter, therefore, we will focus on the management of the radiated patient, mainly before radiotherapy. This is because there are few protocols and we believe that these are necessary in order to minimize the risks during treatment.

Figure 26 and 27: Orthopantomography of a patient before beginning the RTP and two years after finishing the RTP.

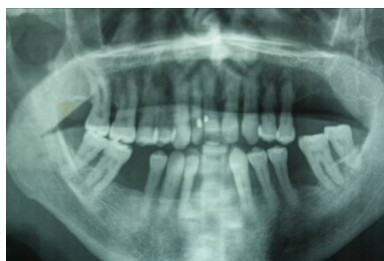

Figure 26. Before RTP.

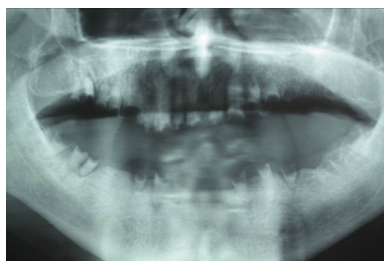


Figure 27. After RTP.

3.1. First visit

During the first visit, we collect the clinical history including the patients' personal data: age, gender, family medical history, personal medical history, current medical problems, medication, allergies and harmful habits. All patients are referred with an oncological report, including their medical history: tumour diagnosis, tumour stage and tumour treatment. A mouth X-ray is also included to evaluate the dental status. A bucodental exploration is developed to assess the oral situation of the patient and evaluate different therapeutic needs, covering the RTP protocol.

3.1.1. RTP protocol

1. All patients must bring orthopantomography and report your oncological data.
2. Medical history is covered.
3. On each visit, a radiographical series from the patient is necessary - extraoral (mouth closed, neck and maximum opening of the mouth) and intraoral (maxima intercuspidation, lateral intercuspidation, top and lower arcades, buccal mucosa and tongue), as is shown in Figures 28-38.
4. An exploration of the mucosa is developed (yugal mucosa, lips, tongue, gums, bottom of the vestibule, floor of the mouth, palate, etc.), in order to discard any pre-existing lesion.
5. A dental and periodontal exploration is developed with the assistance of a probe and mirror. The degree of dental hygiene is determined using the Silnesloe index [49].

Grade 0: Absence of dental plaque.

Grade 1: Plaque not visible but could be extracted from the gingival third of the tooth using the probe.

Grade 2: Moderate build-up of plaque in the gingival region that could easily be seen.

Grade 3: Abundance of plaque in the same region, possibly covering the neighbouring teeth.

6. The maximum interincisal distance is measured with callipers (a trismus is a buccal opening of less than 40 mm).
7. A culture is carried out. The sample is taken from the back of the tongue and the readings are at 24-48-72 hours. The sample is taken from the back of the tongue using a cotton swab, depositing it in an agar-sabourand plate and placing it in the furnace for 72 hours.
8. The status of the saliva function is assessed using a chart paper strip (1 cm thick by 17 cm length, with 1 cm not charted), introduced in a polyethylene bag. This is called a Global Saliva Test, in rest and stimulated [50]. The section of non-charted strip is extracted from the bag for testing. The end is then folded in a right angle and inserted in the oral cavity, below the tongue. When closing the lips, these will slightly touch the polyethylene bag. The saliva produced is accumulated in the lingual valleculae during the five minutes of the test's duration. During this time, the strip slowly soaks. Once this time has ended, it is

retrieved from the mouth and the wet charted strip is immediately read. Subsequently, the stimulation test is carried out by depositing some drops of citric acid at 4% in the oral cavity and repeating the same process.

Figures 28-39: Radiographical series from the patient going to treatment with RTP.

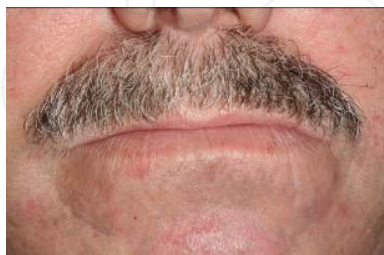

Figure 28. Mouth closed.

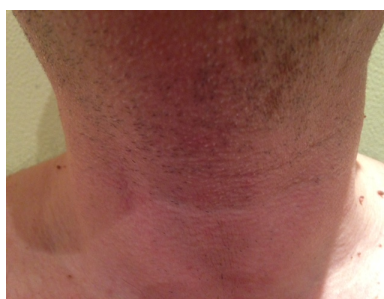

Figure 29. Neck.

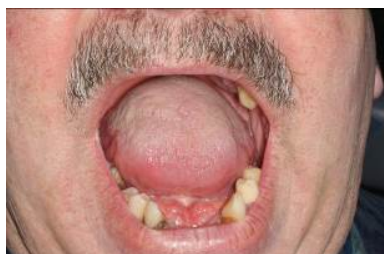

Figure 30. Maximum opening of the mouth.

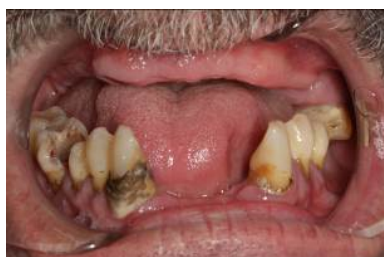

Figure 31. Maximum intercuspitation.

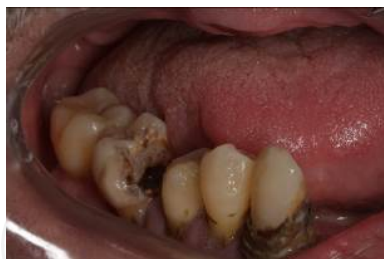

Figure 32. Right lateral intercuspitation.

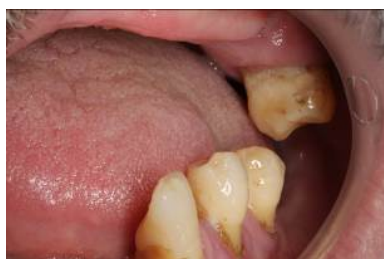

Figure 33. Left lateral intercuspitation.

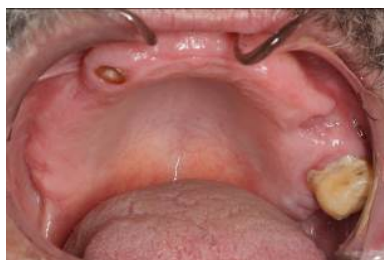

Figure 34. Top arcade.

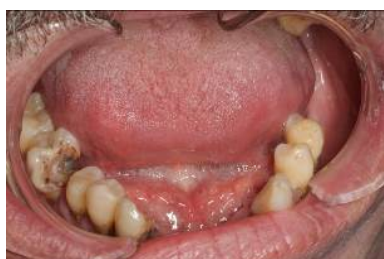

Figure 35. Lower arcade.

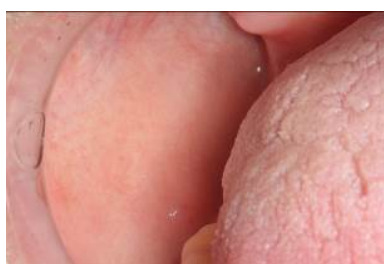

Figure 36. Right buccal mucosa.

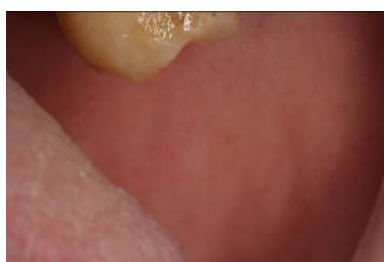

Figure 37. Left buccal mucosa.

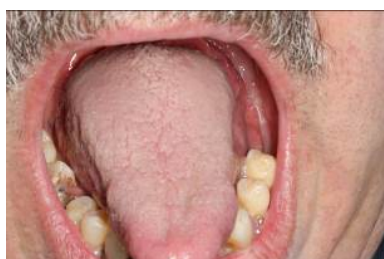

Figure 38. Tongue.

9. Once the odontogram is covered, with the assistance of an ortopantomography, the therapeutic needs will be defined:
 - Extraction (if this is necessary, all patients will sign an informed consent explaining all the possible complications).
 - Seals/endodontics.
 - Treatment for oral candidiasis (mycostatin - mouth wash three times a day for three minutes for four weeks).
 - Tartar removal, scaling and root planning.
 - Remove irritants that graze (traumatic prosthesis and sharp teeth).
 - Motivation in oral hygiene - strongly recommend a daily teeth brushing for at least three times a day with toothpaste with high fluoride content. Apart from Fluoridation

plan in patients with teeth - preparation of individual trays for the daily application of sodium fluoride gel at 1.24%, five minutes/day, indefinitely and mouth wash with chlorhexidine.

10. If extractions are recommended [51, 52], the prognosis of the tooth itself, the patient's motivation and their ability to follow oral hygiene instructions plays a role. All teeth with a questionable prognosis should be extracted before RTP:

- Caries (non-restorable).
- Active periodontal disease (symptomatic teeth).
- Moderate and severe periodontal disease (≥ 5 mm bags) especially with advanced bone loss, mobility and furcation involvement.
- Partial impaction or incomplete eruption, especially of third molars, which are not fully covered by the alveolar bone or in contact with the oral cavity.
- Extensive periapical lesions (if not chronic or well localized).
- Root fragments that are not completely covered by alveolar bone or show radiolucency.
- Teeth near the tumour or in the tumour.
- Lack of opposing teeth.
- Compromised hygiene.

When developing extractions, patients should be handled as follows [52-54].

- Antibiotic prophylaxis for patients who need it, as recommended by the ADA.
- Rinse with antiseptic mouthwash - chlorhexidine digluconate 0.12% for one minute.
- Anaesthetic technique:
- Anaesthesia with vasoconstrictor.
- Minimal trauma - regularization of the alveolar process by approximation of edges.
- Non-absorbable 4.0 silk suture.
- Antibiotics, Amoxicillin 750 mg 1/8 hours /7 days is prescribed.
- Post-operative treatment: analgesic-anti-inflammatory medication (ibuprofen 600 mg) and antiseptic mouthwash, chlorhexidine digluconate 0.12%.
- Minimum number of sessions, starting with mandibular extractions.

Most authors agree that the minimum delay time for RTP treatment is 15-20 days [39, 44, 52, 55]. While others indicate that, in the case of complex surgical procedures, patients must wait four to six weeks [10, 54].

Management before RTP

1. Report your oncological data.
2. Clinical history and bucodental exploration.
3. Orthopantomography.
4. Bucodental exploration.
5. The therapeutic needs will be defined: seals, endodontics and extractions.
6. Instructions and motivation in oral hygiene.
7. Global Saliva Test, in rest and stimulated.
8. Maximum interincisal distance.
9. Culture and identification of candidiasis.

4. Protocol for management during RTP

Patients who are to receive radiation therapy experience three main acute complications that cause functional disability and hinder the development of normal life. These are mucositis, radiodermatitis and xerostomia. Weekly monitoring is required, i.e., we must see the patient once a week during the eight weeks that the treatment usually lasts. The main symptoms appear after the fifth dose of radiation. Thus, on each visit, we usually develop the following measurements covered in the protocol.

4.1. RTP protocol

- a. Degree of mucositis.
- b. Degree of radiodermatitis.
- c. Degree of oral hygiene - Silnesloe index [49].
- d. Presence of ORN.
- e. Eliminate possible graze, if the patient has removable/complete prosthesis.
- f. Dental state and instructions in oral hygiene.
- g. Saliva amount by means of TSG I and TSG II [50].
- h. Culture at mid-treatment and at the end.
- i. Maximum interincisal distance at mid-treatment and at the end.
- j. Radiographical series from the patient is necessary - extraoral (mouth closed, neck and maximum opening of the mouth) and intraoral (maxima intercuspitation, lateral intercuspitation, top and lower arcades, buccal mucosa and tongue).
- k. Motivation in oral hygienic, strongly recommend a daily teeth brushing for at least three times a day with toothpaste with high fluoride content. Apart from Fluoridation plan in

patients with teeth - preparation of individual trays for the daily application of sodium fluoride gel at 1.24%, five minutes/day, indefinitely and mouth wash with chlorhexidine

During the radiotherapy treatment - and even 18 months later - no surgery technique should be used with these patients and if an endodontic treatment is necessary, dental apex cannot be surpassed. We advise exercises and jaw movements in order to prevent trismus and, in this way, the maximum opening can be kept.

We must insist on instructions on oral hygiene to prevent rampant caries. As these patients suffer from intense pain in the oral cavity, we can advise a soft brush so as not to irritate the mucosa, accompanied by a soft diet and anticariogenic.

Fundamentally, these patients report dryness of the mouth and less saliva. The quality of saliva changes - it feels thicker which causes rampant caries. That, added to the functional disability produced by mucositis, leads patients to abandon oral hygiene. As a result, their dental status worsens. Therefore, our treatment is based on prescribing oral rinses and insisting on the acquisition of oral hygiene habits. Basically, the purpose of it is to relieve symptoms using a formula. This includes using lidocaine hydrochloride 1% and chlorhexidine digluconate 0.12% before meals to help reduce swallowing pain [56-61].

Patients must drink at least half a litre of water a day to get a good hydration. There is a possibility of cryotherapy, above all in mucositis and occasioned by quimotherapics. Therefore, patients must thaw ice in their mouths every 30 minutes [62, 63].

Nowadays, there are saliva substitutes (sprays or gels that temporarily wet the oral mucosa - these are palliative) and stimulants (lemon drops, chewing gum with xylitol and sialogogues, among which the pilocarpine is the most important). Pilocarpine is an on-selective cholinergic agonist, which stimulates the salivary secretion. However, in our protocol, it is not recommended due to its various side effects [64, 65]. We recommend drinking water to hydrate, diet tips and good oral hygiene

As saliva decreases, the sense of taste disappears. Thus, a zinc element can be useful for the restoration of protein responsible for the regulation of pores in taste buds. It is also important to drink an abundance of liquids with meals and to slowly chew. This will liberate flavours and stimulate saliva [32, 66].

As for mucositis, large ulcerations appear in the mucosa of the oropharynx and oral cavity. Curing this disease usually takes three weeks. However, up to two months may pass before they start to subside [15, 56-58, 67]. In terms of management, we must differentiate pain control [68] and functional disability [60, 62, 69] by combining oral solutions (lidocaine hydrochloride 1% and chlorhexidine digluconate 0.12%) and a liquid or soft diet.

The election of treatment in the first phase of ulceration is to prevent infection. This can be achieved through good oral hygiene and antimicrobial agents, such as chlorhexidine mouthwash, povidone iodine and hyaluronic acid gels, which form a film that restructures the epithelium. With these measures, the bacteria colonization in injuries with ulcerous mucositis is prevented but its apparition is not [70].

As previously stated, these patients experience a lot of pain and so it is necessary to use anti-inflammatories. These include Benzydamine, which is used as a mouthwash and reduces concentrations of tumour necrosis factors. This is efficient in the reduction of intensity and the lasting of injuries in the mucosa [71].

There are cytoprotective agents that eliminate free radicals acting as antioxidants. In this group, we have amifostine, prostaglandins and sucralfate. The amifostine is a protector against the xerostomia during the radiotherapy treatment. It reduces its gravity and duration. However, it has multiple adverse effects and so its use is limited [72, 73]. Sucralfate adheres to the walls of the ulcer and constitutes a superficial barrier in the gastrointestinal tract. As a result, the oropharyngeal pain is reduced but mucositis is not prevented. Sucralfate has some antibacterial activity so it aids the healing of injuries and stimulates the synthesis of the prostaglandins [74-77].

It is difficult to specify which treatment should be elected as each patient responds differently to radiotherapy. Our experience is that chlorhexidine and hyaluronic acid [78] do not aid aggressive injuries. Thus, in different cases of mucositis III and IV, we recommend the use of, topical corticoids, mainly 0.5% Triamcinolone Acetonid, three times a day for three weeks. We also recommend oral rinses or creams, depending on whether the injuries are unique or multiple. The injuries develop favourably but as it is a corticoid, we have to suspend it gradually [79, 80]. Keefe et al. affirm that the high-level mucositis pain can be relieved with potent analgesic such as opiaceous [81].

Furthermore, we reviewed written studies on this subject and found that there are currently no published articles referring to the association between the administration of cortisone and the presence of recurrences in the head and neck. Moreover, if there are references in other locations, such as the prostate or the skin, it remains the treatment of choice [82-84].

Nowadays, there are new therapies (biological response modifiers) conducted in the investigation phase. These eliminate the mucositis, mainly reducing the minimum development of the mucositis and, specifically, various growth factors. They also contribute to the biological process of mucosity destruction [85]. In this group, we mention palifermine keratinocyte growth factor. In advanced degree cases, this sees reduced mucositis but has secondary effects and thus, its use is restricted [86-88].

Low-energy laser therapy is an effective method for the prevention and management of mucositis. It is used to accelerate the regeneration of tissues and stop swelling and pain [89-92].

It is also important to get a basic medium so that there is no mycosis. Thus, as a preventative measure, we recommend bicarbonate water rinses before meals (dilute a spoonful of bicarbonate in 200 ml of water). Additionally, in the case of candidiasis, the treatment of choice is Nystatin (topical antifungal). Here, we suggest rinsing three times a day, for three minutes over a period of four weeks. Optimal oral hygiene is crucial in order to reduce the risk of oral mucositis [89]. In cases that do not respond to the topical treatment or severe infections, we recommend systemic antifungal such as fluconazole, 150 mg. - daily doses for two weeks [93].

Little can be done to improve the toxicity of the skin, aside from moisturizing several times a day and not covering the area so it does not keep moisture. We also recommend leaving it to air dry.

Patients usually experience weight loss due to difficulties in swallowing caused by mucositis. Taste alterations causes a loss of appetite and dietary recommendations are necessary.

Management During RTP

1. Revisions, once a week, during treatment with radiotherapy valued:
 - a) Degree of mucositis.
 - b) Degree of radiodermatitis.
 - c) Degree of oral hygiene.
 - d) Presence of ORN.
 - e) Eliminate possible graze, if the patient has removable/complete prosthesis.
 - f) Dental state and instructions in oral hygiene.
 - g) Saliva amount by means of TSG I and TSG II.
 - h) Culture at mid-treatment and at the end.
 - i) Maximum interincisal distance at mid-treatment and at the end.
 2. Treatment of complications.
 3. Instructions of oral hygiene.
 4. Liquid or soft diet.
 5. Avoid extractions.
 6. Remove toxic habits.
 7. Remove any mechanical trauma to the oral mucosa.
 8. Exercise to reduce trismus.
-

5. Protocol for management After RTP

Patients are monitored one month after finishing RTP treatment, as well as at three months, six months, nine months, 12 months and 18 months. From then onwards, patients are reviewed semi-annually. A new OPG requested 12 months after ending RTP.

In each of the reviews, the oral condition of the patient is assessed to establish treatment needs, developing the following examinations that are covered in the protocol.

5.1. RTP protocol

1. Odontogram with the current situation after undergoing RTP, dental and periodontal status.
2. Rating of oral hygiene: the Silnesloe index [49]

Grade 0: Absence of dental plaque.

Grade 1: Plaque not visible but can be extracted from the gingival third of the tooth using the probe.

Grade 2: Moderate build-up of plaque in the gingival region that can easily be seen.

Grade 3: Abundance of plaque in the same region, possibly covering the neighbouring teeth.

3. Maximum interincisal distance is measured with a calliper (trismus is a mouth opening of <40mm). Different exercises, which should be carried out in order to increase the oral opening, are explained to the patient.
4. The state of the salivary function is quantitatively assessed by a Global Saliva Test (TSG), both at rest (TSG I) and stimulated (TSG II), following the technique described by López-Jornet et al. [50].
5. A culture of the lingual dorsum is developed for isolation and identification of the candida species. The clinical form of candidiasis (subclinical, erythaematous, pseudomembranous) is assessed.
6. Mucositis and residual radiodermatitis are evaluated.
7. Avoid complete or removable prosthesis until six months post RTP. Weekly monitoring is essential to prevent damages in the mucosa and always add soft filler.
8. An exhaustive inspection of the oral cavity to early diagnose the recurrences.
9. Radiographical series from the patient is necessary - extraoral (mouth closed, neck and maximum opening of the mouth) and intraoral (maxima intercuspitation, lateral intercuspitation, top and lower arcades, buccal mucosa and tongue).
10. Motivation in oral hygienic - strongly recommend a daily teeth brushing for at least three times a day with toothpaste with high fluoride content. Apart from Fluoridation plan in patients with teeth - preparation of individual trays for the daily application of sodium fluoride gel at 1.24%, five minutes/day, indefinitely and wash mouth with clorhexidine.

Patient attending the annual review after finishing the RTP. We see good oral and dental hygiene and healthy appearance of mucous.

Follows the same pattern (mouth closed, neck, maximum opening of the mouth, maximum intercuspitation, right and left lateral intercuspitation, top and lower arcade, right and left buccal mucosa and tongue).

Patient who comes to review after 14 months of finishing RTP. He has lost four lower incisors and the root-canal therapy we sent to keep them up to remove them.

The first Figure 39 shows the patient's condition before the RTP. Subsequent figures show the patient's current state (mouth closed, neck, maximum opening of the mouth, maximum intercuspitation, right and left lateral intercuspitation, top and lower arcade, right and left buccal mucosa and tongue).

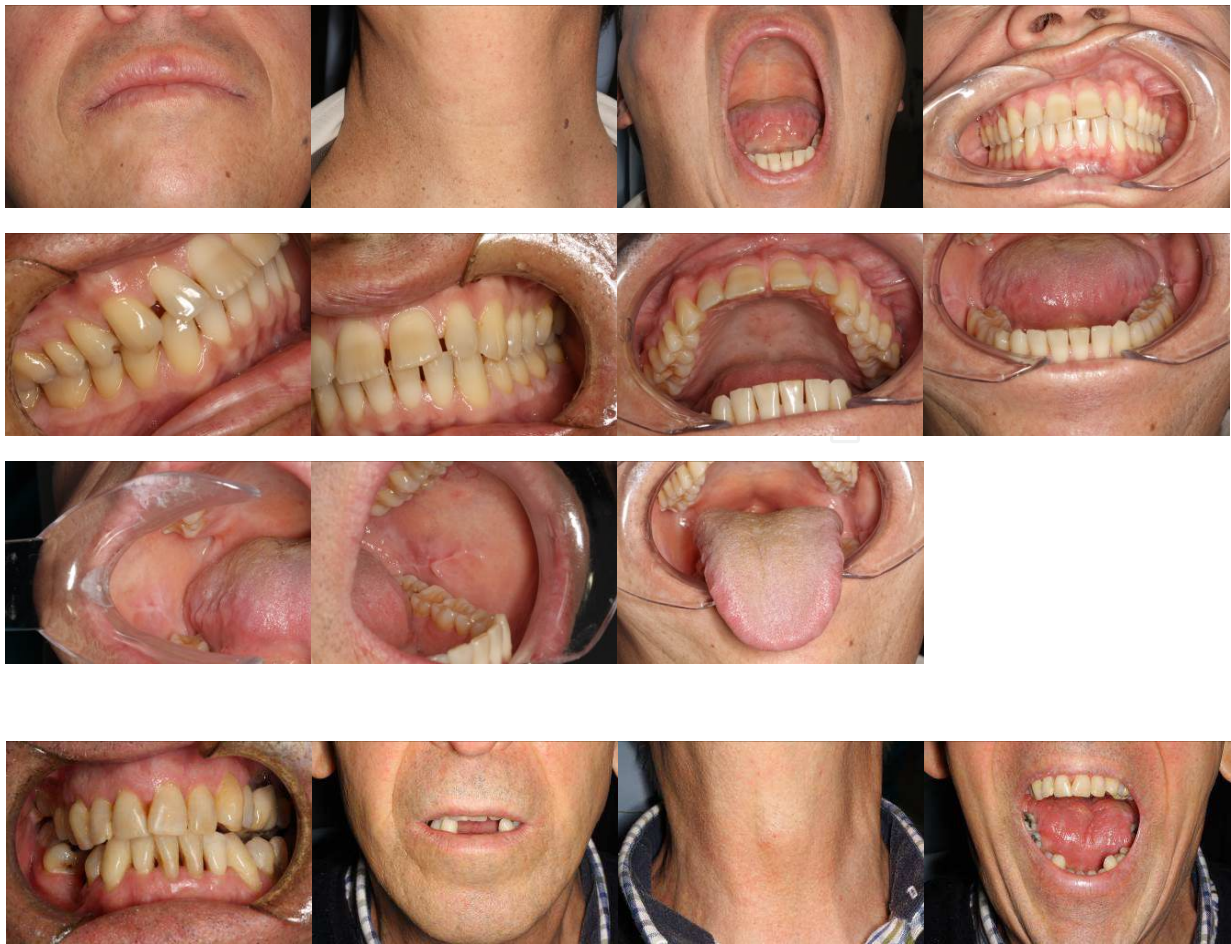
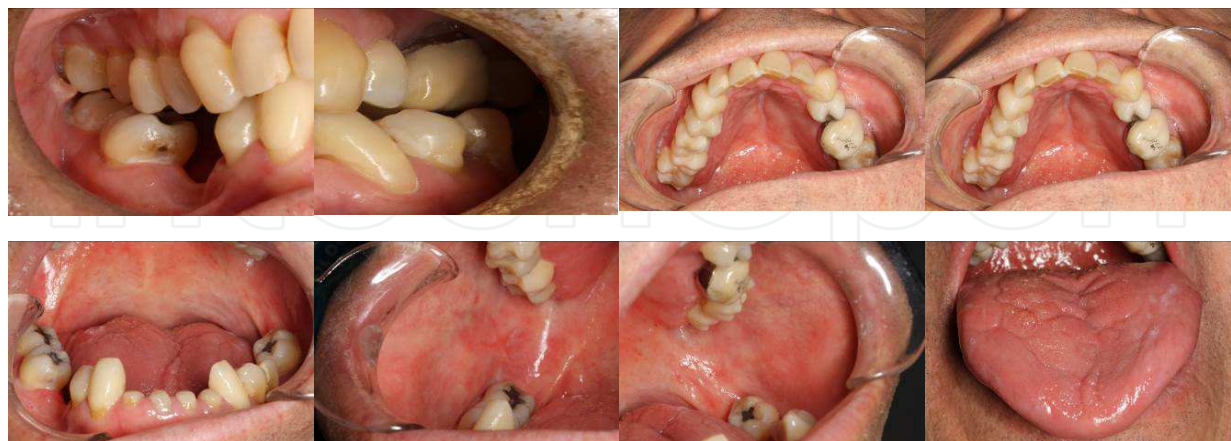
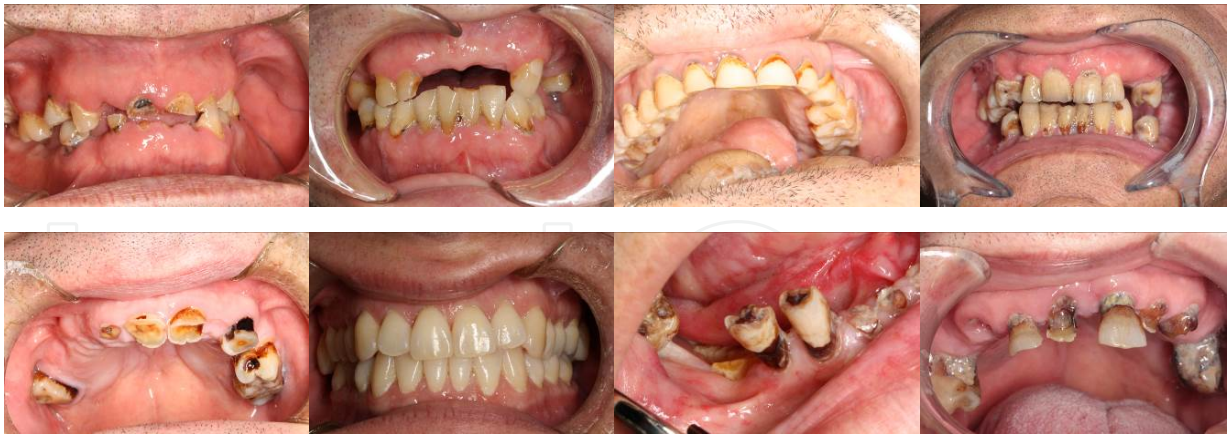Figure 39. Before RTP



The figures below show the oral health status of different patients after one year of finishing the RTP. Here, you can see the various statuses of rampant caries and poor oral hygiene, except in a case where there is excellent oral hygiene



5.2. Assessment of osteoradionecrosis

1. It is classified according to the grade of bone affection [94, 95]. The time of apparition after RTP and the association to exodoncias are valued either pre or post RTP.

Stage I: Osteoradionecrosis superficial - soft-tissue ulceration is minimal and only the exposed cortical bone is necrotic.

Stage II: Osteoradionecrosis localized - the exposed cortical bone and underlying medullary bone are necrotic.

IIA: Soft-tissue ulceration is minimal.

IIB: Soft-tissue necrosis (including orocutaneous fistulation).

Stage III: Osteoradionecrosis diffuse - bone necrosis full thickness of a segment (ability to pathological fracture).

IIIA: Soft-tissue ulceration is minimal.

IIIB: Soft-tissue necrosis (including orocutaneous fistulation).

2. Diagnosis

It is based on the clinical findings and medical history of the patient with the confirmation of a radiology study and biopsy - exposed area of bone necrosis due to tissue-irradiation, minimum cure of three to six months, without evidence of local healing and neoplastic absence enfermedad [38, 41, 96].

The symptoms can manifest months or years after the radiation of the patient. The injuries appear as ulcerations, with the exposure of rough and necrotic bone. In some cases, the injuries are discovered during a visual inspection of the cavity or due to the incommodity in a determined part of the mouth.

3. Treatment

In the first stage, a conservative treatment must be carried out. First, all irritants of the mouth are eliminated such as tobacco, alcohol and removable/complete prosthesis. Then, good oral

hygiene and oral rinse with chlorixidine 0,12 is carried out three times a day and a gel of clorhexidine is applied on the injuries three or four times a day.

In stage II, there is symptomatology and so the previous actions must be completed with an antibiotic treatment. In these cases, we can do a curettage of the exposed part until vital and vascular zone [97].

In stage III, pain can be intense and fistulization, suppuration and fractures can occur. Here, more radical surgery is needed to eliminate the osteolytic zone remaining vascularized [98].

5.3. Extraction post-RTP

The criteria established by Sulaiman et al. and Jansma et al. should be followed. After radiation therapy, it is necessary to delay any surgery for 18 months in order to reduce risks. The recommendations below should be followed [52, 53]:

- Rinse with antiseptic mouthwash - chlorhexidine digluconate 0.12%, one minute.
- Anaesthetic technique:
 - -Anaesthesia without vasoconstrictor - truncal block, infiltrative anaesthesia, never intraligamental anaesthesia.
- Minimal trauma, alveolectomy, regularization of the alveolar process with no rotary instruments.
- Primary sealing with mucoperiosteal flaps.
- Non-absorbable 4.0 silk suture.
- Always prophylactic antibiotic (Amoxicillin 750mg 1/8 hours/10 days, if allergic to penicillin, a combination of spiramycin and metronidazole (Rhodogil®) is prescribed - two every eight hours, for 10 days).
- Post-operative treatment: analgesic-anti-inflammatory medication (Ibuprofen 600mg) and antiseptic mouthwash chlorhexidine digluconate 0.12%, plus antibiotics.
- Space the extractions in time.

Management After RTP

1. Patients are monitored one month after finishing RTP treatment, as well as at three months, six months, nine months, 12 months and 18 months. From then onwards, patients are reviewed semi-annually. A new OPG is requested 12 months after the end of the RTP.
 - a) Residual mucositis and radiodermatitis.
 - b) Grade of oral hygiene - oral hygiene motivation.
 - c) Presence of ORN.
 - d) Oral dental status.
 - e) Global Saliva Test (TSG), both at rest (TSG I) and stimulated (TSG II).

Management After RTP

f) Culture.

g) Maximum interincisal distance.

2. Avoid extractions at least 18 months after finishing the RTP.

3. Avoid performing or complete/removable prosthesis for three to six months post-RTP.

4. Stimulate oral aperture through exercises.

9. Treatment of Complications.

10. Diagnosis of recurrences.

6. Conclusions

Prior to initiating RTP treatment, all patients should be protocolled to ensure that they present optimal oral conditions. In this way, local and systemic complications can be minimized during and after treatment and measures that can be adopted to reduce adverse effects can be established. We consider it vital to quantify resting and stimulated saliva production prior to the commencement of RTP, as any previously existing xerostomia must be treated to prevent complications during RTP. The utility of an oral assessment should be explained and the importance of maintaining good oral health should be stressed.

Author details

Paula Bonar Alvarez¹, Mario Perez-Sayans García^{1,2*}, Maria Elena Padín Iruegas³ and Abel García-García⁴

*Address all correspondence to: perezsayans@gmail.com

1 Oral Medicine, Oral Surgery and Implantology Unit. Faculty of Medicine and Dentistry. Santiago de Compostela, Spain

2 Instituto de Investigación Sanitaria de Santiago (IDIS), Santiago de Compostela, Spain

3 Human Anatomy and Embryology area. Faculty of Physiotherapy. Department of functional biology and health sciences, Pontevedra, Spain

4 Oral Medicine, Oral Surgery and Implantology Unit. Department of Maxillofacial Surgery, Complejo Hospitalario Universitario, Spain

References

- [1] Barnes L, Eveson J, Reichart P, Sidransky D. *World Health Organization Classification of Tumours: Pathology and Genetics of Head and Neck Tumours*. 2005.
- [2] Bagan J, Sarrion G, Jimenez Y. 'Oral cancer: Clinical Features'. *Oral Oncol* 2010;46(6): 414-417.
- [3] Black R, Bray F, Ferlay J, Parkin D. 'Cancer Incidence and Mortality in the European Union: Cancer Registry Data and Estimates of National Incidence for 1990'. *Eur J Cancer* 1997;33(7):1075-1107.
- [4] Moore SR, Johnson N, Pierce AM, Wilson DF. 'The Epidemiology of Mouth Cancer: A Review of Global Incidence'. *Oral Dis* 2000;6(2):65-74.
- [5] Ord RA, Blanchaert RH. *Oral Cancer: The Dentist's Role in Diagnosis, Management, Rehabilitation, and Prevention*. Quintessence Pub.; 2000.
- [6] Little JW. *Tratamiento Odontológico del Paciente Bajo Tratamiento Médico*. : Elsevier España; 1998.
- [7] Castellsagué X, Quintana MJ, Martínez MC, Nieto A, Sanchez MJ, Juan A, et al. 'The Role of Type of Tobacco and Type of Alcoholic Beverage in Oral Carcinogenesis'. *International Journal of Cancer* 2004;108(5):741-749.
- [8] Marcial VA, Pajak TF. 'Radiation Therapy Alone or in Combination with Surgery in Head and Neck Cancer'. *Cancer* 1985;55(S9):2259-2265.
- [9] Caballero M, Grau JJ, Casellas S, Bernal-Sprekelsen M, Blanch JL. 'The Role of Chemotherapy in Advanced Oral Cavity Cancer'. *Acta Otorrinolaringologica (English Edition)* 2009;60(4):260-267.
- [10] (10) Ceballos A, Bullón P, Gándara J, Chimenos E, Blanco A, Martínez-Sahuquillo A, et al. *Medicina Bucal Práctica*. Danú, SL 2000.
- [11] Pignon J, Bourhis J, Domenge C, Designe L. 'Chemotherapy Added to Locoregional Treatment for Head and Neck Squamous-Cell Carcinoma: Three Meta-Analyses of Updated Individual Data'. *The Lancet* 2000;355(9208):949-955.
- [12] Laramore GE. 'Role of Particle Radiotherapy in the Management of Head and Neck Cancer'. *Curr Opin Oncol* 2009;21(3):224-231.
- [13] Steel GG. *Basic Clinical Radiobiology*.
- [14] Cox JD, Stetz J, Pajak TF. 'Toxicity Criteria of The Radiation Therapy Oncology Group (RTOG) and the European Organization for Research and Treatment of Cancer (EORTC)'. *International Journal of Radiation Oncology* Biology* Physics* 1995;31(5): 1341-1346.

- [15] Sciubba JJ, Goldenberg D. 'Oral Complications of Radiotherapy'. *The Lancet Oncology* 2006;7(2):175-183.
- [16] Scully C, Sonis S, Diz P. 'Oral Mucositis'. *Oral Dis* 2006;12(3):229-241.
- [17] World Health Organization. *WHO Handbook For Reporting Results of Cancer Treatment*. 1979.
- [18] Raber-Durlacher JE, Elad S, Barasch A. 'Oral Mucositis'. *Oral Oncol* 2010;46(6):452-456.
- [19] Ray-Chaudhuri A, Shah K, Porter R. 'The Oral Management of Patients Who Have Received Radiotherapy to the Head and Neck Region'. *Br Dent J* 2013;214(8):387-393.
- [20] Scully C, Epstein JB. 'Oral Health Care for the Cancer Patient'. *European Journal of Cancer. Part B: Oral Oncology* 1996;32(5):281-292.
- [21] Epstein JB, Schubert M. 'Oropharyngeal Mucositis in Cancer Therapy'. *Oncology* 2003;17(12):1767-1776.
- [22] Seto BG, Kim M, Wolinsky L, Mito RS, Champlin R. 'Oral Mucositis in Patients Undergoing Bone Marrow Transplantation'. *Oral Surgery, Oral Medicine, Oral Pathology* 1985;60(5):493-497.
- [23] Singh N, Scully C, Joyston-Bechal S. 'Oral Complications of Cancer Therapies: Prevention and Management'. *Clin Oncol* 1996;8(1):15-24.
- [24] Meurman JH, Grönroos L. 'Oral and Dental Health Care of Oral Cancer Patients: Hyposalivation, Caries and Infections'. *Oral Oncol* 2010;46(6):464-467.
- [25] Dirix P, Nuyts S, Vander Poorten V, Delaere P, Van Den Bogaert W. 'The Influence of Xerostomia After Radiotherapy on Quality of Life'. *Supportive Care In Cancer* 2008;16(2):171-179.
- [26] Cooper JS, Fu K, Marks J, Silverman S. 'Late Effects of Radiation Therapy in the Head and Neck Region'. *International Journal of Radiation Oncology* Biology* Physics* 1995;31(5):1141-1164.
- [27] Schweiger JW. 'Oral Complications Following Radiation Therapy: A Five-Year Retrospective Report'. *J Prosthet Dent* 1987;58(1):78-82.
- [28] Mandel ID. 'The Role of Saliva in Maintaining Oral Homeostasis'. *J Am Dent Assoc* 1989 Aug;119(2):298-304.
- [29] Chambers MS, Toth BB, Martin JW, Fleming TJ, Lemon JC. 'Oral and Dental Management of the Cancer Patient: Prevention and Treatment of Complications'. *Supportive Care in Cancer* 1995;3(3):168-175.
- [30] Mossman K. 'Gustatory Tissue Injury in Man: Radiation Dose Response Relationships and Mechanisms of Taste Loss'. *The British Journal of Cancer. Supplement* 1986;7:9.

- [31] Spielman A. 'Chemosensory Function and Dysfunction'. *Critical Reviews in Oral Biology & Medicine* 1998;9(3):267-291.
- [32] Cowart B. 'Taste Dysfunction: A Practical Guide for Oral Medicine'. *Oral Dis* 2011;17(1):2-6.
- [33] Tomita Y, Osaki T. 'Gustatory Impairment and Salivary Gland Pathophysiology in Relation to Oral Cancer Treatment'. *Int J Oral Maxillofac Surg* 1990;19(5):299-304.
- [34] Andrews N, Griffiths C. 'Dental Complications of Head and Neck Radiotherapy: Part 1'. *Aust Dent J* 2001;46(2):88-94.
- [35] Conger AD. 'Loss and Recovery of Taste Acuity in Patients Irradiated to the Oral Cavity'. *Radiat Res* 1973;53(2):338-347.
- [36] Jham BC, Freire, Addah Regina Da Silva. 'Oral Complications of Radiotherapy in the Head and Neck'. *Revista Brasileira de Otorrinolaringologia* 2006;72(5):704-708.
- [37] Balogh JM, Sutherland SE. 'Osteoradionecrosis of the Mandible: A Review'. *J Otolaryngol* 1989 Aug;18(5):245-250.
- [38] Marx RE. 'Osteoradionecrosis: A New Concept of its Pathophysiology'. *Journal Of Oral And Maxillofacial Surgery* 1983;41(5):283-288.
- [39] Beumer J, Harrison R, Sanders B, Kurrasch M. 'Preradiation Dental Extractions and the Incidence of Bone Necrosis'. *Head Neck Surg* 1983;5(6):514-521.
- [40] Epstein JB, Rea G, Wong FL, Spinelli J, Stevenson-Moore P. 'Osteonecrosis: Study of the Relationship of Dental Extractions in Patients Receiving Radiotherapy'. *Head Neck Surg* 1987;10(1):48-54.
- [41] Mcleod NM, Bater MC, Brennan PA. 'Management of Patients at Risk of Osteoradionecrosis: Results of Survey of Dentists and Oral & Maxillofacial Surgery Units in the United Kingdom, and Suggestions for Best Practice'. *British Journal Of Oral And Maxillofacial Surgery* 2010;48(4):301-304.
- [42] Brown D, Evans A, Sándor G. *Hyperbaric Oxygen Therapy in the Management of Osteoradionecrosis of the Mandible*. 2004.
- [43] Starcke E, Shannon I. 'How Critical is the Interval Between Extractions and Irradiation in Patients With Head and Neck Malignancy?' *Oral Surgery, Oral Medicine, Oral Pathology* 1977;43(3):333-337.
- [44] Murray CG, Herson J, Daly TE, Zimmerman S. 'Radiation Necrosis of the Mandible: A 10 Year Study. Part II. Dental Factors; Onset, Duration and Management of Necrosis'. *International Journal Of Radiation Oncology* Biology* Physics* 1980;6(5):549-553.
- [45] Makkonen T, Kiminki A, Makkonen T, Nordman E. 'Dental Extractions in Relation to Radiation Therapy of 224 Patients'. *Int J Oral Maxillofac Surg* 1987;16(1):56-64.

- [46] Curi MM, Lauria L. 'Osteoradionecrosis of the Jaws: A Retrospective Study of the Background Factors and Treatment in 104 Cases'. *Journal Of Oral And Maxillofacial Surgery* 1997;55(6):540-544.
- [47] Granström G. 'Radiotherapy, Osseointegration and Hyperbaric Oxygen Therapy'. *Periodontol* 2000 2003;33(1):145-162.
- [48] Kielbassa AM, Hinkelbein W, Hellwig E, Meyer-Lückel H. 'Radiation-Related Damage to Dentition'. *The Lancet Oncology* 2006;7(4):326-335.
- [49] Silness J, Løe H. 'Periodontal Disease in Pregnancy II. Correlation Between Oral Hygiene and Periodontal Condition'. *Acta Odontologica* 1964;22(1):121-135.
- [50] López-Jornet P, Camacho-Alonso F, Bermejo-Fenoll A. 'A Simple Test for Salivary Gland Hypofunction Using Oral Schirmer's Test'. *Journal Of Oral Pathology & Medicine* 2006;35(4):244-248.
- [51] Epstein J, Stevenson-Moore P. 'Periodontal Disease and Periodontal Management in Patients with Cancer'. *Oral Oncol* 2001;37(8):613-619.
- [52] Jansma J, Vissink A, Spijkervet FK, Roodenburg JL, Panders AK, Vermey A, et al. 'Protocol for the Prevention and Treatment of Oral Sequelae Resulting from Head and Neck Radiation Therapy'. *Cancer* 1992;70(8):2171-2180.
- [53] Sulaiman F, Huryn JM, Zlotolow IM. 'Dental Extractions in the Irradiated Head and Neck Patient: A Retrospective Analysis of Memorial Sloan-Kettering Cancer Center Protocols, Criteria, and End Results'. *Journal Of Oral And Maxillofacial Surgery* 2003;61(10):1123-1131.
- [54] Silvestre-Donat F, Plaza A, Serrano M. Revisión. 'Prevención y Tratamiento de las Complicaciones Derivadas de la Radioterapia en Pacientes Con Tumores de Cabeza y Cuello'. *Medicina Oral* 1998;3(3):136-147.
- [55] Bruins HH, Koole R, Jolly DE. 'Pretherapy Dental Decisions in Patients With Head and Neck Cancer: A Proposed Model for Dental Decision Support'. *Oral Surgery, Oral Medicine, Oral Pathology, Oral Radiology, And Endodontology* 1998;86(3):256-267.
- [56] Cawley MM, Benson LM. 'Current Trends in Managing Oral Mucositis'. *Clin J Oncol Nurs* 2005;9(5):584-592.
- [57] Biswal BM. 'Current Trends in the Management of Oral Mucositis Related to Cancer Treatment'. *Malays J Med Sci* 2008 Jul;15(3):4-13.
- [58] Trucci VM, Veeck EB, Morosolli AR. 'Current Strategies for the Management of Oral Mucositis Induced by Radiotherapy or Chemotherapy'. *Revista Odonto Ciência (Journal Of Dental Science)* 2009;24(3):309-314.
- [59] *Strategies for Managing Radiation-Induced Mucositis in Head and Neck Cancer. Seminars in Radiation Oncology*: Elsevier; 2009.

- [60] Blanco Carrión A. 'Nueva Fórmula Magistral en Forma de Colutorio Para Lesiones Dolorosas de la Mucosa Oral'. *REVISTA EUROPEA DE ODONTOESTOMATOLOGIA* 1996;8:169-172.
- [61] Stone R, Fliedner MC, Smiet A. 'Management of Oral Mucositis in Patients With Cancer'. *European Journal of Oncology Nursing* 2005;9:S24-S32.
- [62] Lalla RV, Sonis ST, Peterson DE. 'Management of Oral Mucositis in Patients Who Have Cancer'. *Dent Clin North Am* 2008;52(1):61-77.
- [63] Wong HM. 'Oral Complications and Management Strategies for Patients Undergoing Cancer Therapy'. *The Scientific World Journal* 2014;2014.
- [64] Zimmerman RP, Mark RJ, Tran LM, Juillard GF. 'Concomitant Pilocarpine During Head and Neck Irradiation is Associated With Decreased Posttreatment Xerostomia'. *International Journal Of Radiation Oncology* Biology* Physics* 1997;37(3):571-575.
- [65] Niedermeier W, Matthaeus C, Meyer C, Staar S, Müller R, Schulze H. 'Radiation-Induced Hyposalivation and its Treatment With Oral Pilocarpine'. *Oral Surgery, Oral Medicine, Oral Pathology, Oral Radiology, and Endodontology* 1998;86(5):541-549.
- [66] Joshi VK. 'Dental Treatment Planning and Management for the Mouth Cancer Patient'. *Oral Oncol* 2010;46(6):475-479.
- [67] Sonis ST. 'Oral Mucositis in Cancer Therapy'. *J Support Oncol* 2004;2(6 Suppl 3):3-8.
- [68] Cheng KK. 'Oral Mucositis, Dysfunction, and Distress in Patients Undergoing Cancer Therapy'. *J Clin Nurs* 2007;16(11):2114-2121.
- [69] Trucci VM, Veeck EB, Morosolli AR. 'Current Strategies for the Management of Oral Mucositis Induced by Radiotherapy or Chemotherapy'. *Revista Odonto Ciência (Journal Of Dental Science)* 2009;24(3):309-314.
- [70] Keefe DM, Schubert MM, Elting LS, Sonis ST, Epstein JB, Raber-Durlacher JE, et al. 'Updated Clinical Practice Guidelines for the Prevention and Treatment of Mucositis'. *Cancer* 2007;109(5):820-831.
- [71] Epstein JB, Silverman S, Paggiarino DA, Crockett S, Schubert MM, Senzer NN, et al. 'Benzylamine Hcl for Prophylaxis of Radiation-Induced Oral Mucositis'. *Cancer* 2001;92(4):875-885.
- [72] Rades D, Fehlauer F, Bajrovic A, Mahlmann B, Richter E, Alberti W. 'Serious Adverse Effects of Amifostine During Radiotherapy in Head and Neck Cancer Patients'. *Radiation Therapy and Oncology* 2004;70(3):261-264.
- [73] Wasserman TH, Brizel DM, Henke M, Monnier A, Eschwege F, Sauer R, et al. 'Influence of Intravenous Amifostine on Xerostomia, Tumor Control, and Survival After Radiotherapy for Head-and-Neck Cancer: 2-Year Follow-Up of a Prospective, Randomized, Phase III Trial'. *International Journal of Radiation Oncology* Biology* Physics* 2005;63(4):985-990.

- [74] Epstein JB, Wong FL. 'The Efficacy of Sucralfate Suspension in the Prevention of Oral Mucositis Due to Radiation Therapy'. *International Journal of Radiation Oncology* Biology* Physics* 1994;28(3):693-698.
- [75] Brown DT, Miller CH, Maupin DE. 'The Effect of Sucralfate on the Growth of Cariogenic Streptococci'. *J Prosthet Dent* 1991;66(2):256-260.
- [76] Etiz D, Erkal H, Serin M, Küçük B, Heparı A, Elhan A, et al. 'Clinical and Histopathological Evaluation of Sucralfate in Prevention of Oral Mucositis Induced by Radiation Therapy in Patients With Head and Neck Malignancies'. *Oral Oncol* 2000;36(1):116-120.
- [77] 'Sucralfate Stimulation of Gastric PGE2 Synthesis-Possible Mechanism to Explain its Effective Cytoprotective Properties'. *Gastroenterology: WB SAUNDERS CO INDEPENDENCE SQUARE WEST CURTIS CENTER, STE 300, PHILADELPHIA, PA 19106-3399*; 1984.
- [78] Barber C, Powell R, Ellis A, Hewett J. 'Comparing Pain Control and Ability to Eat and Drink With Standard Therapy Vs Gelclair: A Preliminary, Double Centre, Randomised Controlled Trial on Patients With Radiotherapy-Induced Oral Mucositis'. *Supportive Care in Cancer* 2007;15(4):427-440.
- [79] Llamas Martínez S, Esparza Gómez G, Moreno López L, Cerero Lapiedra R. 'Corticoides: Su Uso en Patología de la Mucosa Oral'. *Medicina Oral* 2003;8(4):248-259.
- [80] González-Moles M. 'The Use of Topical Corticoids in Oral Pathology'. *Med Oral Patol Oral Cir Bucal* 2010;15:E827-E831.
- [81] Keefe DM, Schubert MM, Elting LS, Sonis ST, Epstein JB, Raber-Durlacher JE, et al. 'Updated Clinical Practice Guidelines for the Prevention and Treatment of Mucositis'. *Cancer* 2007;109(5):820-831.
- [82] Dietrich K, Schned A, Fortuny J, Heaney J, Marsit C, Kelsey K, et al. 'Glucocorticoid Therapy and Risk of Bladder Cancer'. *Br J Cancer* 2009;101(8):1316-1320.
- [83] Severi G, Baglietto L, Muller DC, English DR, Jenkins MA, Abramson MJ, et al. 'Asthma, Asthma Medications, and Prostate Cancer Risk'. *Cancer Epidemiol Biomarkers Prev* 2010 Sep;19(9):2318-2324.
- [84] Jensen AØ, Thomsen HF, Engebjerg M, Olesen AB, Friis S, Karagas M, et al. 'Use of Oral Glucocorticoids and Risk of Skin Cancer and Non-Hodgkin's Lymphoma: A Population-Based Case-Control Study'. *Br J Cancer* 2008;100(1):200-205.
- [85] Von Bültzingslöwen I, Brennan MT, Spijkervet FK, Logan R, Stringer A, Raber-Durlacher JE, et al. 'Growth Factors and Cytokines in the Prevention and Treatment of Oral and Gastrointestinal Mucositis'. *Supportive Care in Cancer* 2006;14(6):519-527.

- [86] Spielberger R, Stiff P, Bensinger W, Gentile T, Weisdorf D, Kewalramani T, et al. 'Palifermin for Oral Mucositis After Intensive Therapy for Hematologic Cancers'. *N Engl J Med* 2004;351(25):2590-2598.
- [87] Schmidt E, Thoennissen NH, Rudat A, Bieker R, Schliemann C, Mesters RM, et al. 'Use of Palifermin for the Prevention of High-Dose Methotrexate-Induced Oral Mucositis'. *Ann Oncol* 2008 Sep;19(9):1644-1649.
- [88] Vadhan-Raj S, Trent J, Patel S, Zhou X, Johnson MM, Araujo D, et al. 'Single-Dose Palifermin Prevents Severe Oral Mucositis During Multicycle Chemotherapy in Patients With Cancer: A Randomized Trial'. *Ann Intern Med* 2010;153(6):358-367.
- [89] Lalla RV, Latortue MC, Hong CH, Ariyawardana A, D'Amato-Palumbo S, Fischer DJ, et al. 'A Systematic Review of Oral Fungal Infections in Patients Receiving Cancer Therapy'. *Supportive Care in Cancer* 2010;18(8):985-992.
- [90] Silva GBL, Mendonça EF, Bariani C, Antunes HS, Silva MAG. 'The Prevention of Induced Oral Mucositis With Low-Level Laser Therapy in Bone Marrow Transplantation Patients: A Randomized Clinical Trial'. *Photomedicine and Laser Surgery* 2011;29(1):27-31.
- [91] Migliorati C, Hewson I, Lalla RV, Antunes HS, Estilo CL, Hodgson B, et al. 'Systematic Review of Laser and Other Light Therapy for the Management of Oral Mucositis in Cancer Patients'. *Supportive Care in Cancer* 2013;21(1):333-341.
- [92] Posten W, Wrone DA, Dover JS, Arndt KA, Silapunt S, Alam M. 'Low-Level Laser Therapy for Wound Healing: Mechanism and Efficacy'. *Dermatologic Surgery* 2005;31(3):334-340.
- [93] Pappas PG, Kauffman CA, Andes D, Benjamin DK, Jr, Calandra TF, Edwards JE, Jr, et al. 'Clinical Practice Guidelines for the Management of Candidiasis: 2009 Update by the Infectious Diseases Society of America'. *Clin Infect Dis* 2009 Mar 1;48(5):503-535.
- [94] Schwartz HC, Kagan AR. 'Osteoradionecrosis of the Mandible: Scientific Basis for Clinical Staging'. *American Journal Of Clinical Oncology* 2002;25(2):168-171.
- [95] Epstein JB, Wong FL, Stevenson-Moore P. 'Osteoradionecrosis: Clinical Experience and a Proposal for Classification'. *Journal of Oral and Maxillofacial Surgery* 1987;45(2):104-110.
- [96] Peterson DE, Doerr W, Hovan A, Pinto A, Saunders D, Elting LS, et al. 'Osteoradionecrosis in Cancer Patients: The Evidence Base for Treatment-Dependent Frequency, Current Management Strategies, and Future Studies'. *Supportive Care in Cancer* 2010;18(8):1089-1098.
- [97] Madrid C, Abarca M, Bouferrache K. 'Osteoradionecrosis: An Update'. *Oral Oncol* 2010;46(6):471-474.

- [98] Pitak-Arnop P, Sader R, Dhanuthai K, Masaratana P, Bertolus C, Chaine A, et al. 'Management of Osteoradionecrosis of the Jaws: An Analysis of Evidence'. *European Journal of Surgical Oncology (EJSO)* 2008;34(10):1123-1134.

IntechOpen

IntechOpen

