

We are IntechOpen, the world's leading publisher of Open Access books Built by scientists, for scientists

4,800

Open access books available

122,000

International authors and editors

135M

Downloads

Our authors are among the

154

Countries delivered to

TOP 1%

most cited scientists

12.2%

Contributors from top 500 universities

**WEB OF SCIENCE™**Selection of our books indexed in the Book Citation Index
in Web of Science™ Core Collection (BKCI)

Interested in publishing with us?
Contact book.department@intechopen.com

Numbers displayed above are based on latest data collected.

For more information visit www.intechopen.com

Considerations for the Spread of Odontogenic Infections – Diagnosis and Treatment

Flaviana Soares Rocha, Jonas Dantas Batista,
Cláudia Jordão Silva, Roberto Bernardino Júnior and
Luis Henrique Araújo Raposo

Additional information is available at the end of the chapter

<http://dx.doi.org/10.5772/59161>

1. Introduction

The goal of this chapter is to present the basis for correct diagnosis and management of severe odontogenic infections. The knowledge of the anatomy of fascial spaces is essential for the correct diagnosis and treatment of head and neck infections, because both facial and cervical fasciae work as an effective barrier against the spread of infections in this region[1, 2]. Once these infections occur, they are often difficult to assess accurately by clinical examinations and conventional radiographic techniques, and the outcome may be serious and potentially life-threatening[3]

The fasciae of the neck are glossy and divided into two separated layers: the superficial fascia and the deep fascia. The superficial fascia is actually a component of the fatty subcutaneous tissue while the deep cervical fascia is divided into three layers: the superficial layer, the visceral or middle layer, and the pre vertebral or deep layer. The deep cervical fascia plays an important role in determining the location and course of spread of infections within the soft tissues of the neck. The infections that commonly affect head and cervical areas are frequently from odontogenic origin and to a lesser frequency, proceeding from foreign bodies or trauma to this region[4]. An impacted mandibular third molar is one of the most frequent causes of odontogenic infection[5-7]. Moreover, an semi-impacted third molar results in odontogenic infection more commonly than fully erupted or completely impacted molars [7].

Odontogenic infections occasionally spread beyond the barriers of the fascial spaces, which are formed, as seen, by the deep cervical fascia of the suprahyoid regions of the neck[2]. Among various spaces, the submandibular space is one of the first to be involved in odontogenic

infections, similar to the masticatory space[2]. As infection may spread along deep cervical facial planes and neck cavities, widespread cellulitis, necrosis, abscess formation, and sepsis may occur in these cases[4]. Therefore, it is important to understand the anatomy, rate of progression and potential for airway compromise of an infection[7]. Spontaneous dissemination of an odontogenic infection is however, very rare in immunocompetent patients[8, 9]. In patients with anatomical abnormalities, systemic diseases or immunosuppression, bacteremia caused by dental procedures may lead to generalized or metastatic systemic infection complications leading to hospital care[10, 11]. In particular, patients with poorly controlled diabetes mellitus are more susceptible to bacterial infections[12-14]. However, death from odontogenic infection is quite rare [9, 15, 16].

Despite being rare, facial and neck fasciae spaces involved by infections from odontogenic origin may lead to a very morbid condition. The diagnosis delay and late or wrong therapeutic approaches to deep infections in these areas are the main causes of high mortality rate in this life-threatening situation.[4] Dentistry has made great progress in prevention and early intervention of odontogenic infection. The introduction of antibiotics reduced significantly the mortality and morbidity of these infections, however, even in this contemporary postantibiotic era, serious infections such as a descending necrotizing mediastinitis still have a high mortality rate with a fulminating course, leading frequently to death.[17-20]

2. Facial and cervical space anatomy

The knowledge of the relevant facial and cervical anatomy of the face is essential for today's clinical practice, allowing precise and successful diagnosis. Figure 1 describes the principal anatomic structures and spaces of the face.

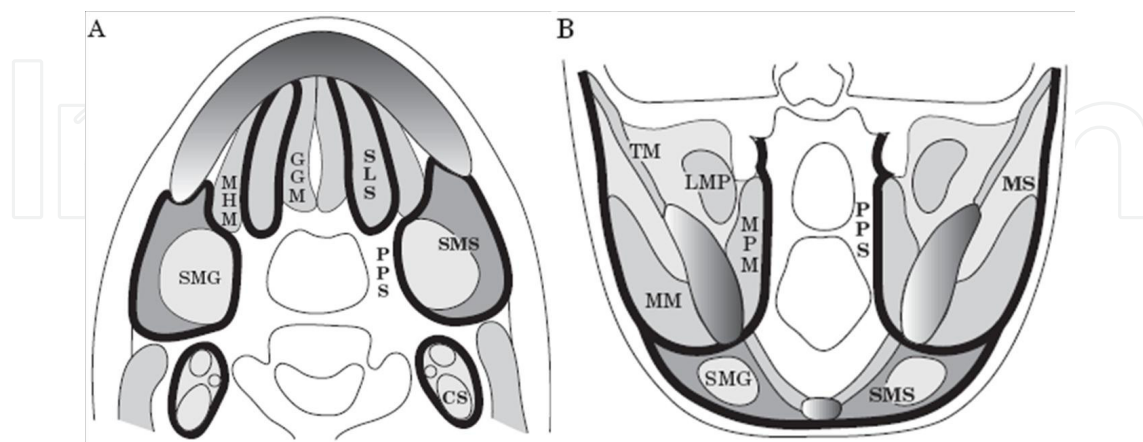


Figure 1. Anatomy of the fascial spaces in axial (A) and coronal (B) images. SMS: submandibular space; SLS: sublingual space; PPS: parapharyngeal space; CS: carotid space; MS: masticatory space. SMG: submandibular gland; GGM: genioglossus muscle; MHM: mylohyoid muscle; MM: masseter muscle; MPM: medial pterygoid muscle; LPM: lateral pterygoid muscle; TM: temporal muscle.

The superficial fascia a component of the fatty subcutaneous tissue and the deep cervical fascia is an important anatomic structure, determining the location and course of spread within the soft tissues of the neck.

2.1. Deep cervical fascia

The deep cervical fascia is divided into three layers: the superficial layer, the visceral or middle layer, and the pre-vertebral or deep layer.

The superficial layer of the deep cervical fascia encircles the neck, enveloping the sternocleidomastoid and trapezius muscles and the muscles of mastication, along with the submandibular and parotid salivary glands. It extends from the nuchal line of the skull, mastoid processes, and mandible inferiorly to the scapula, clavicle, and lower cervical vertebrae.

The middle layer of the deep cervical fascia encloses the anterior viscera of the neck (thyroid gland, larynx, trachea, and pharynx) and the strap muscles. It attaches to the skull base and extends into the mediastinum.

The deep layer of the deep cervical fascia is divided into the pre-vertebral and alar divisions. The pre-vertebral division tightly encloses the spine and paraspinal muscles. Ventrally, it lies immediately anterior to the vertebral bodies, forming the anterior wall of the pre-vertebral space. It extends from the base of the skull to the coccyx.

The alar division of the deep layer of the deep cervical fascia lies between the pre-vertebral division and the middle layer of the deep cervical fascia. It extends from the skull base to the mediastinum. The carotid sheath is made of contributions from all three layers of the deep cervical fascia and envelops the carotid artery, jugular vein, and vagus nerve.[21, 22]

2.2. Fascial spaces

The parapharyngeal space fascia is in an area of fatty areolar tissue with complex fascial margins that lies in a central location in the deep face. It extends from the skull base to the hyoid bone, containing only fat tissue, branches of the trigeminal nerve, and the pterygoid venous plexus. Posterior to the parapharyngeal space is the carotid space. All three layers of deep cervical fascia contribute to the carotid sheath that circumscribe this space.

The carotid space extends from the skull base to the aortic arch. Its suprahyoid contents include the internal carotid artery, jugular vein, cranial nerves IX–XII, and deep cervical lymph node chain.

The retropharyngeal space is a posterior midline space that has the middle layer of deep cervical fascia as its anterior margin and the deep layer of deep cervical fascia as its posterior and lateral margins. It extends from the skull base to the level of the T3 vertebral body.[21, 23]

The danger space lies posterior to the retropharyngeal space and is separated from the retropharyngeal space by the alar fascia. The posterior margin of the danger space is the pre-vertebral division of the deep layer of the deep cervical fascia. The importance of the danger space, and the reason for its name, is that it extends from the skull base to the level of the

diaphragm, providing a pathway into the posterior mediastinum and pleural spaces. Infections of danger space most commonly occurs when an abscess in the retropharyngeal space ruptures through the alar fascia.[21, 23³¹]

3. Teeth involved in fascial infections

Invasive dental manipulation is known to cause bacteremia and generally considered high-risk procedures for the spread of infection in susceptible patients.[31-48] Sato et al., has shown that the main origin of maxillofacial infections were odontogenic (79.31%), followed by trauma (10.7%), immunosuppression (1.6%), pathologies (1.6%), and other causes (8%).[49] Seppänen et al., also reiterated that the most common dental procedures that precede odontogenic infection complications are: tooth extraction (60%), endodontic treatment (20%), dental implant surgery (8%), restorative treatment (8%) and dental plaque and calculus removal (4%).[50-52]

Lower third molars are more frequently involved in odontogenic infections when compared with other teeth. Flynn et al., presented in their prospective study with 37 consecutive hospitalized patients, a 68% prevalence rate of this group of teeth in association with odontogenic infections, followed by other lower posterior teeth (premolars, first and second molars), without anterior teeth involvement.[13] Third molar removal is one of the most regular dentoalveolar surgical procedures.[10, 26, 52-65] With an 80% prevalence of retained third molars in the adult population,[23] appropriate treatment, and especially prophylactic third molar removal remains a key focus of interest in healthcare with both medical and economic dimensions. It is generally accepted that substantial risks may arise both from third molar removal,[6, 29, 37, 60, 66, 67] as well as from a “wait and see” policy.[4, 11, 14, 25, 33, 44, 65]

4. Microbiological involvement

The severe infections of odontogenic origin frequently involve a complex polymicrobial mix of aerobes, facultative aerobes and strict anaerobes working together. Some species like *Peptostreptococcus*, *Staphylococcus*, *Lactobacillus*, *Prevotella*, *Treponema*, *Fusobacterium*, *Veillonella*, *Actinomyces*, *Bacteroides* ssp. and oral *Streptococcus* sp. are frequently associated with infections of odontogenic origin.[13, 36, 43, 46, 48, 56] Sakamoto et al., reported 17 different species collected from a single surgical site.[48] Flynn et al., isolated 90 different strains of microorganisms in 37 patients, and of these, 17 were penicillin-resistant.[13] Other species can be easily found at the infection sites, but generally, they reflect the indigenous microflora of the oral cavity. Routine culture and sensitivity testing for minor oral infections does not appear to be justified, however, when an infection involves anatomic spaces of moderate or greater severity, or when there is significant medical/immune compromise, the tests become important to the outcome.

5. Pathway of facial and cervical infections of odontogenic origins

5.1. Fascial infections derived from mandibular odontogenic origins

Infections originating in the facial planes of the head and neck spread downward along the cervical fascia, facilitated by gravity, breathing, and negative intrathoracic pressure. Knowledge of the facial spaces and fascial planes is essential for understanding the propagation, pathways, symptoms, and complications of cervical infections.[4, 47] Although the pattern of spread varies among patients, a relatively constant trend in the distribution of infection into the spaces seem to be evident. Some studies clearly demonstrated that the masticatory space is the most prevalent site for odontogenic infection spread. Taken together with the finding that the masticatory space encompasses the posterior mandibular body, ramus, and a part of the alveolar bones of the maxilla, this suggests that the masticatory space may be the initial site of spread of odontogenic infection. This contention was further supported by the finding that mandibular infection more frequently involved the masseter and medial pterygoid muscles (located in the lower compartment of the masticatory space where the mandible is included) than the temporalis and lateral pterygoid muscles (located in the upper compartment of the space where part of the maxilla is included).[3]

The spaces adjacent to the masticatory space are the parotid space posteriorly, the parapharyngeal space medially, and the submandibular and sublingual spaces inferiorly (Figure 1).[48] The parapharyngeal space occupies the central position among the masticatory, parotid, and carotid vascular spaces. Therefore, infections in the parapharyngeal space may originate from any adjacent space. A fascia extends from the posterior superior margin of the medial pterygoid muscle to the base of the skull to separate the masticatory space from the parapharyngeal space.[49] In this way, it is possible to believe that infection spreading from the masticatory space into the parapharyngeal space may pass via the medial pterygoid muscle. Yonetsu et al., found that 100% of patients with parapharyngeal space involvement also had the medial pterygoid muscle affected, and 79% of patients with infection in the medial pterygoid muscle area had concomitant involvement of the parapharyngeal space. However, in none of their cases spread from the submandibular into the pharyngeal spaces.[3]

The parotid space abuts the posterior masticatory space and is enveloped by a layer of the deep cervical fascia.[50] Yonetsu et al., demonstrated that odontogenic infection may extend into the parotid space, via the masticatory space.[3] The retropharyngeal space connects the skull base to the upper mediastinum and contains loose fatty tissue in its infrahyoid portion. Thus, the retropharyngeal space is considered to be important due to its proximity to the airway and because infections in this space may cause mediastinitis, bronchial erosion, and septicemia.[3, 50] The vertebral and vascular spaces are thought to be rarely involved by head and neck infection.[51]

The infection spread occurs when accumulated pus perforates bone at the weakest and thinnest part. In the mandible, the lingual aspect of the molar region represents the easiest way.[4, 52] If odontogenic infection perforates this portion of bone, it will spread into the sublingual or

submandibular space. As these spaces are partially separated by a thin sheet of mylohyoid muscle, infection in either space easily spreads into the other. It is generally believed that the midline enables free communication from either the sublingual or submandibular space.[3, 50]

Delineating the maxillary spread pattern is quite difficult, because limited data is available regarding its infections.[3] Nevertheless, it is plausible to consider that the observed difference in the spread profile between maxillary and mandibular infections may be due to differences in the distance between the original focal area in jaw bones and each of the spaces. For instance, maxillary infection was associated with temporalis muscle involvement more often than mandibular infection. Maxillary infection also spreads first to the masticatory space, but the temporalis and lateral pterygoid muscles are predominant targets for the infection. Involvement of the sublingual and submandibular spaces is rare. Otherwise, odontogenic infection arising in the mandible spreads first to the masticatory space. The masseter and medial pterygoid muscles in the masticatory space are most frequently involved. Thereafter, the infection spreads medially into the parapharyngeal space and posteriorly into the parotid space. Involvement of the sublingual and submandibular spaces seems to occur directly from the primary site of mandibular infection.[3]

There are complex pathways which allow infection to spread along the facial and neck structures. Thus, it is important for dental practitioners to know more about the possibility of a dental intervention to be a cause of severe infections.

The sequence of odontogenic infection spread that most commonly occurs is:

1. The masticatory space is the primary site of spread from mandibular infection.
2. The parotid and pharyngeal spaces are the secondary sites of spread from the masticatory space.
3. Mandibular infection spreads directly to the sublingual and submandibular spaces, and
4. Maxillary infection spreads to the deep facial and neck spaces in a different way from that of mandibular infection (Figure 2).

5.2. Fascial infections derived from maxillary odontogenic origins

The pattern of maxillary infection spread differs from that of the mandible. Generally, the main maxillary spaces involved were found to be the buccal maxillary (19.05%) and canine (15.24%). [49] According to Yonetsu et al., the temporalis muscle was involved in 100% of the patients with maxillary infection. The involvement of the temporalis muscle in mandibular infections occurred only in 26% of the patients. The downward spread into the sublingual and submandibular spaces from maxillary infections did not occur. The lateral pterygoid and masseter muscles were frequently involved (86%) as in the cases of mandibular infection. Other spaces were also involved, but less frequently. The buccal space was involved in 57% of the patients with maxillary infection[66] (Figure 2).

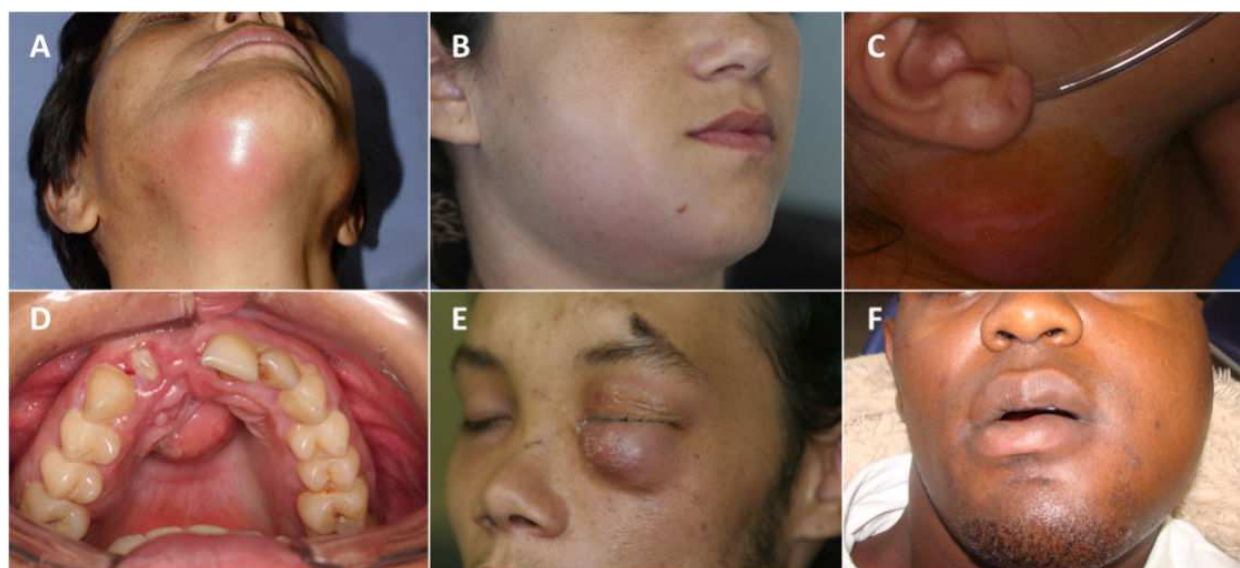

Figure 2. Different locations of odontogenic infections. (A) Submandibular and sublingual region. (B) Submandibular region. (C) Cervical region. (D) Palate. (E) Orbital region. (F) Submandibular and buccal region.

6. Causes of infections

6.1. Pericoronitis

Pericoronitis is an infection of the gingiva of a partially erupted tooth. The most frequent form of pericoronitis is caused by the partially erupted lower third molar, mainly due to the favorable niche that is created once the mucous cap covering the molar becomes retentive and deep enough to trap food particles and reduce the oxygen potential. These factors create the perfect microenvironment for the onset and subsequent development of a recurrent infectious, inflammatory condition caused by polymicrobial microorganisms, especially strict anaerobes. [19] Third molar pericoronitis may appear in either of its two acute variations, namely serous and suppurative, as well as in its chronic form; when either of the two acute forms previously mentioned stays untreated.

6.2. Periapical lesions/Intra-oral abscess

The most significant clinical condition of all bacterial infections of periapical origin is the so-called acute apical periodontitis.[16] It is usually the result of purulent pulpitis that spreads into the periapical space, therefore, it appears in the course of pulpal disease. In acute apical periodontitis there is an accumulation of pus inside the apical space of the tooth involved. This condition is commonly underestimated by dental practitioners in terms of its morbidity and mortality.[46] (Figure 3)

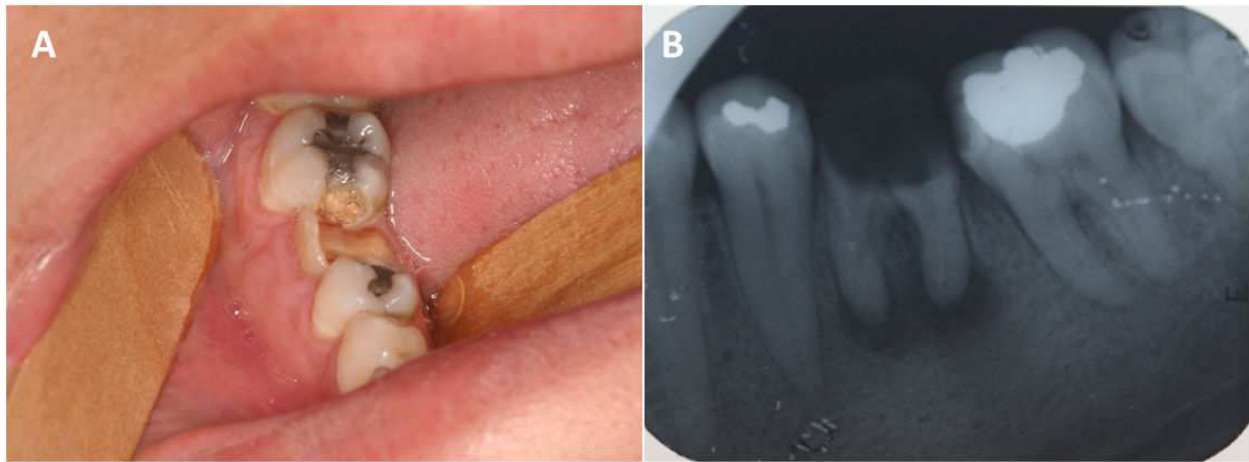


Figure 3. Clinical (A) and radiographic(B) aspects of a periapical lesion.

6.3. Infection of sublingual, submental and submandibular spaces (Ludwig's Angina)

Ludwig's angina is a rapidly spreading cellulitis that may produce upper airway obstruction, often leading to death. The most common source of Ludwig's angina is an odontogenic infection, from one or more grossly decayed, infected teeth, and is usually as a result of a native oral mixed aerobic-anaerobic flora. The patient with Ludwig's angina presents severe and obvious extra oral swellings including bilateral submandibular, submental, and sublingual spaces. Elevation and displacement of the tongue, trismus, drooling of saliva, airway obstruction, sore throat, dysphagia and/or dyspnea are commonly present. With extensive use of drainage and antibiotics, most facial infections have satisfactory outcome before they have a chance to progress to Ludwig's angina.[1] (Figure 4)

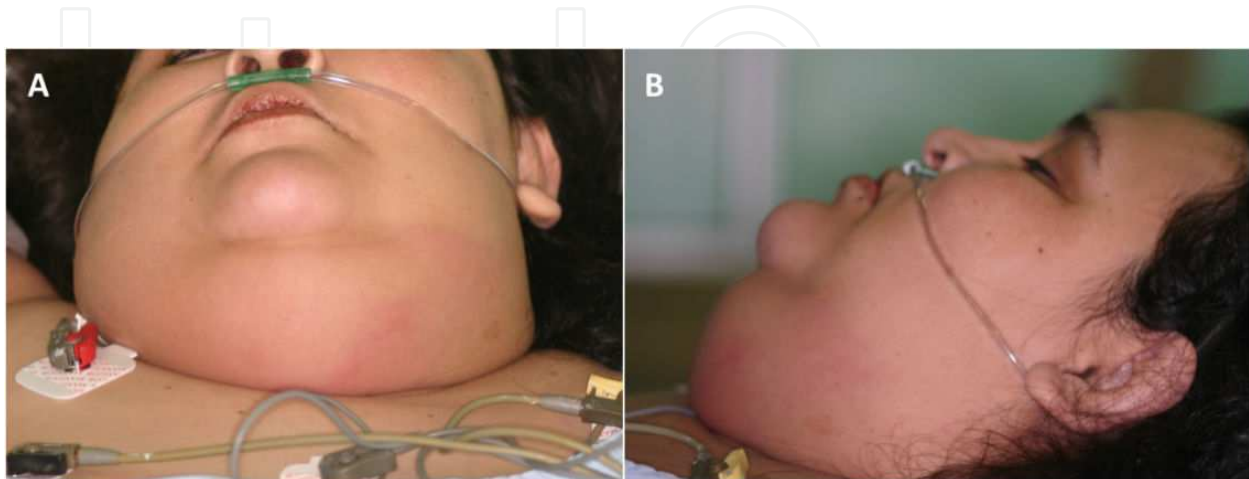


Figure 4. Clinical presentation of Ludwig's angina.

6.4. Cervical cellulitis

Cervical cellulitis is most commonly from odontogenic origin and despite modern antibiotic therapy, cases with an initial delay in diagnosis and treatment may still result in this life-threatening situation.[17, 58-60] Odontogenic infections are usually locally confined, self-limiting processes. However, under certain circumstances, like anatomical variations or suppression of the immune system of some patients, these infections may pass through the bony, muscular, and mucosal barriers and spread into contiguous and distant spaces, resulting in severe fulminating infections in the body cavities.[60]

When cervical cellulitis involves the parapharyngeal, retropharyngeal, and viscerovascular spaces, the purulent process has easy access to the mediastinum, pericardium, and thorax, thereby increasing mortality rates.[13, 17, 58-60] Because of the fulminant nature of descending cervical cellulitis with mediastinal complications, prompt recognition followed by broad-spectrum antibiotic therapy, immediate surgical intervention, and intensive medical support are required.[13, 61]

The second and third mandibular molars are the teeth most frequently implicated in the cause of odontogenic deep neck infections.[17, 58, 60, 61] Because their roots lie below the mylohyoid muscle, medial perforation of a periapical abscess has immediate access to the submandibular space. Then, a collection of pus in the neck spreads along the cervical fascial planes, resulting in complications.[13]

6.5. Descending Necrotizing Mediastinitis (DNM)

Acute purulent mediastinitis occasionally develops as a complication of odontogenic infection, in which case it is denominated descending necrotizing mediastinitis.[17] This is a serious infection involving the connective tissue that fills the interpleural spaces and surrounds the median thoracic organs. It is one of the most dreaded and the most lethal form of mediastinitis, which occurs as a complication of oropharyngeal abscesses or as a complication of cervical trauma, with severe cervical infection spreading along the fascial planes into the mediastinum. As infection spreads along deep cervical fascial planes into the mediastinum, widespread cellulitis, necrosis, abscess formation, and sepsis may concomitantly occur. The delay of diagnosis and late or incomplete drainage of the mediastinum are the main causes for high mortality rates associated with this condition.[4]

Even with the use of computed tomography scanning or magnetic resonance examination, aggressive drainage, and modern antibiotic treatment, the mortality rate of descending necrotizing mediastinitis remains high. Surgical management, particularly the optimal form of mediastinal drainage, remains controversial with support ranging from cervical drainage alone to cervical drainage and routine thoracotomy.

6.6. Necrotizing fasciitis

Abscesses of the peritonsillar region are among the most common deep abscesses of the head and neck. Although rare, complications resulting from this disease may be life threatening.

One of the most dangerous complications is necrotizing fasciitis, which is a rare soft tissue infection characterized by progressive destruction of fascia and adipose tissue that may not involve the skin.[62, 63] Necrotizing fasciitis is characterized by its fulminating, devastating, and rapid-progressing course.[64] Diabetes mellitus, burns and malnutrition are common predisposing factors. Initially, cervical necrotizing fasciitis is predominantly characterized by a “simple” infection in the upper aerodigestive tract like pharyngitis or even tonsillitis. Typically, the general condition gets worse within a very short period of time with cardiovascular decompensation due to a toxic shock-like condition. Cervical necrotizing fasciitis initially involves the superficial muscular system and superficial fascial planes of the head and neck or it may result from a deep soft tissue infection, such as odontogenic infections or even pharyngitis, which spreads along the deep fascial planes.

If the disease is not recognized in time the infection can rapidly involve the great vessels or mediastinum, producing systemic toxicity and sepsis.[65, 66] The basis of successful treatment comprises aggressive surgical debridement and drainage of the involved necrotic fascia and tissue along with intensive broad-spectrum intravenous antibiotic coverage.[63]

7. Signs and symptoms

The current signs and symptoms presented by patients with severe infections from odontogenic origin are crucial factors for the patient’s life maintenance. Sato et al., has shown in their eight-year retrospective study that cases of odontogenic infections call for immediate therapeutics, either clinical or surgical, with precise daily or long-term monitoring of patients until complete resolution of the clinical infection status is reached. The most frequent signs and symptoms found in these patients were trismus (43.33%), fever (28.10%), dysphagia (25.24%), pain (24.76%), and swelling (20%), all of which are classic signs of a dire clinical situation.²⁶

8. Imaging

Imaging plays an essential role in the diagnosis and management of head and neck infections since, by clinical examination alone. It is often difficult to determine if a swollen neck is due to cellulitis or an abscess; the location, extent or source of the infection, and whether the process is self-limited or if it is potentially life-threatening is also clinically unclear.[21]

Radiographs of the cervical segment and the chest may be useful in the demonstration of subcutaneous emphysema in the form of vertical, linear, clear bands of gas extending from the cervical spaces into the mediastinum. The lateral radiograph of the neck can reveal a prevertebral soft tissue opacity pushing the trachea anteriorly. Chest radiograph can demonstrate a widened mediastinum and pleural effusion. However, the modest diagnostic sensibility of cervical and chest plain film should call immediately for computed tomography scanning or a magnetic resonance of the cervicothoracic areas.[2, 17, 67, 68]

Any patient with neck swelling and/or pain from dental infection should have a computed tomography exam of the neck and chest to evaluate the spread of infection. Computed tomography examination and neck evaluation include: diffuse thickening of the cutis and subcutis and reticular enhancement of the subcutaneous fat of the face and neck; thickening and/or enhancement of cervical fasciae; asymmetric thickening or enhancement of cervical muscles, reactive lymphadenopathy; septic vascular thrombosis and fluid collections with or without gas. Mediastinal computed tomography findings include: streaky enhancement of mediastinal fat, fluid collections with or without gas, pericardial effusion and pleural effusion.[21]

9. Treatment

Treatment of odontogenic infections includes diagnosis and management of the causative factor, drainage when necessary (Figures 5-6) and, usually, prescription of appropriate antibiotics. It is imperative that the source of infection be addressed immediately. In addition, the patient's medical status must be optimized. The patient's fluid and nutrition status should also be addressed, as many patients with odontogenic infections have decreased oral intake due to pain and difficulty in chewing or swallowing. The clinician must be aware of the most likely causative organisms and prescribe the narrowest spectrum of antibiotics that will cover all possible offending organisms.

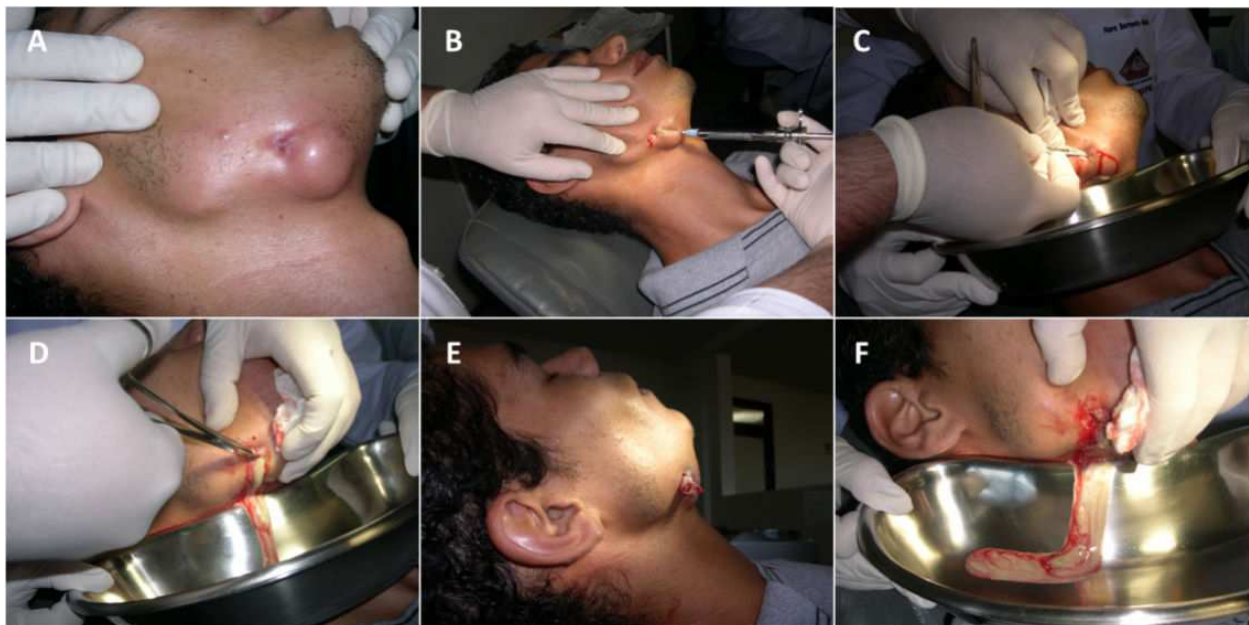


Figure 5. Sequence of drainage of odontogenic infection – case 1. Note that the most dependent part (under the swelling) must be incised not the thin most swollen part (to prevent scarring).

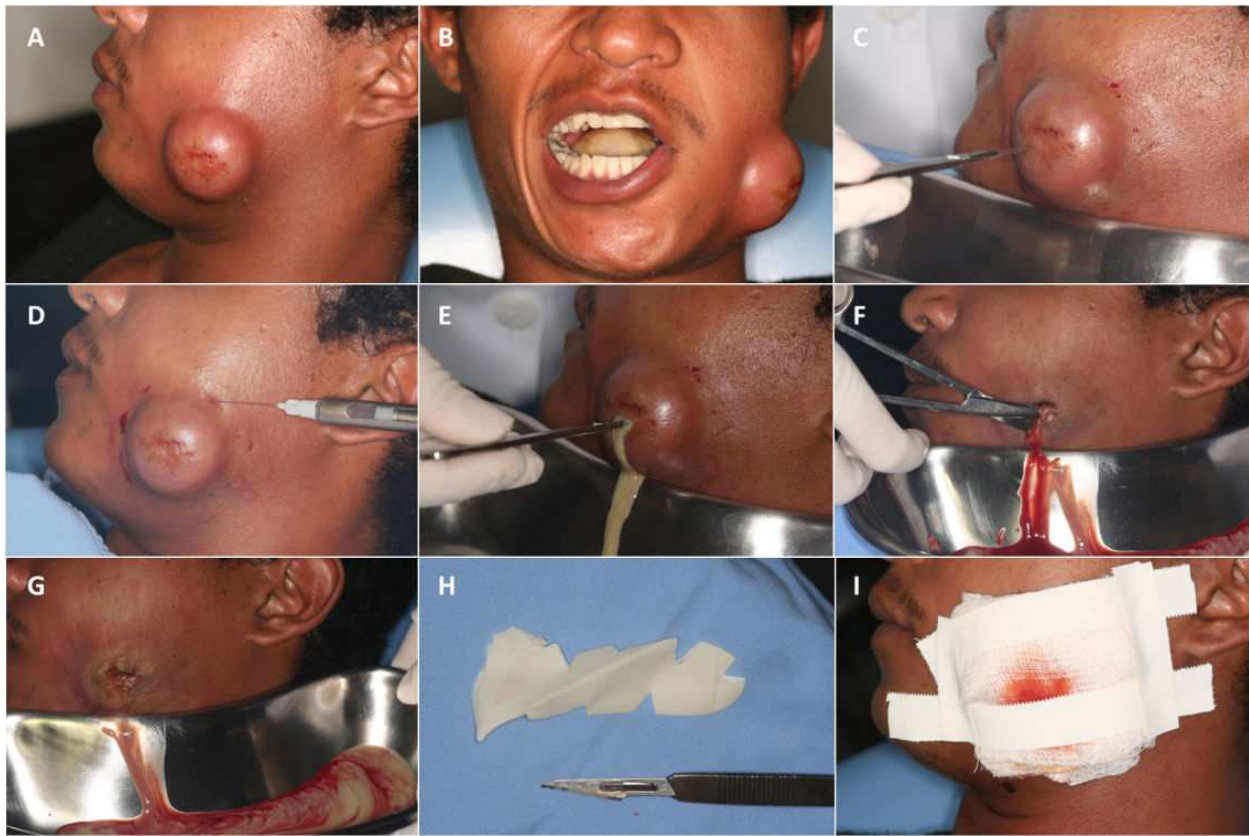

Figure 6. Figure 6: Sequence of drainage of odontogenic infection – case 2.

10. Conclusions

A simple tooth infection, especially in diabetics, immunocompromised, or debilitated patients should not be underestimated in its ability to cause severe infections. Furthermore, even non-invasive dental manipulations may also precipitate systemic spread. Facial and cervical infections are potentially lethal complications. However, with good knowledge of the anatomic pathways of the infection, early diagnosis, attention to airway maintenance, aggressive intravenous antibiotic therapy, surgical intervention and careful postoperative management, the infectious process should have a satisfactory outcome. The practitioner must be alert to the particularities of infections from odontogenic origin, as well as to the facial and cervical spaces anatomy, because these structures are crucial for the patient's life and play important roles during the execution of treatment procedures.

Acknowledgements

The authors would like to thank Analice Giovani Pereira for the support during the writing of the chapter and selection of clinical cases.

Author details

Flaviana Soares Rocha¹, Jonas Dantas Batista^{1*}, Cláudia Jordão Silva¹,
Roberto Bernardino Júnior² and Luis Henrique Araújo Raposo³

*Address all correspondence to: jonasdantasbat@gmail.com

1 Department of Oral and Maxillofacial Surgery and Implantology – School of Dentistry - Federal University of Uberlândia – UFU, Brazil

2 Department of Human Anatomy - Biomedical Science Institute - Federal University of Uberlândia – UFU, Brazil

3 Department of Occlusion, Fixed Prosthesis, and Dental Materials – School of Dentistry - Federal University of Uberlândia – UFU., Brazil

References

- [1] Abramowicz S, Abramowicz JS, Dolwick MF. Severe life threatening maxillofacial infection in pregnancy presented as Ludwig's angina. *Infect Dis ObstetGynecol* 2006: 2006: 51931.
- [2] Ariji Y, Gotoh M, Kimura Y, Naitoh M, Kurita K, Natsume N, *et al.* Odontogenic infection pathway to the submandibular space: imaging assessment. *Int J Oral MaxillofacSurg* 2002: 31: 165-169.
- [3] Yonetsu K, Izumi M, Nakamura T. Deep facial infections of odontogenic origin: CT assessment of pathways of space involvement. *AJNR Am J Neuroradiol* 1998: 19: 123-128.
- [4] Mihos P, Potaris K, Gakidis I, Papadakis D, Rallis G. Management of descending necrotizing mediastinitis. *J Oral MaxillofacSurg* 2004: 62: 966-972.
- [5] Haug RH, Hoffman MJ, Indresano AT. An epidemiologic and anatomic survey of odontogenic infections. *J Oral MaxillofacSurg* 1991: 49: 976-980.
- [6] Indresano AT, Haug RH, Hoffman MJ. The third molar as a cause of deep space infections. *J Oral MaxillofacSurg* 1992: 50: 33-35; discussion 35-36.
- [7] Ohshima A, Ariji Y, Goto M, Izumi M, Naitoh M, Kurita K, *et al.* Anatomical considerations for the spread of odontogenic infection originating from the pericoronitis of impacted mandibular third molar: computed tomographic analyses. *Oral Surg Oral Med Oral Pathol Oral RadiolEndod* 2004: 98: 589-597.
- [8] Gosney MA, Preston AJ, Corkhill J, Millns B, Martin MV. Pseudomonasaeruginosa-septicaemiafroman oral source. *Br Dent J* 1999: 187: 639-640.

- [9] Seppanen L, Lauhio A, Lindqvist C, Suuronen R, Rautemaa R. Analysis of systemic and local odontogenic infection complications requiring hospital care. *J Infect* 2008; 57: 116-122.
- [10] Bergmann OJ. Oral infections and septicemia in immunocompromised patients with hematologic malignancies. *J ClinMicrobiol* 1988; 26: 2105-2109.
- [11] Wilson W, Taubert KA, Gewitz M, Lockhart PB, Baddour LM, Levison M, *et al.* Prevention of infective endocarditis: guidelines from the American Heart Association: a guideline from the American Heart Association Rheumatic Fever, Endocarditis and Kawasaki Disease Committee, Council on Cardiovascular Disease in the Young, and the Council on Clinical Cardiology, Council on Cardiovascular Surgery and Anesthesia, and the Quality of Care and Outcomes Research Interdisciplinary Working Group. *J Am Dent Assoc* 2007; 138: 739-745, 747-760.
- [12] Harrison GA, Schultz TA, Schaberg SJ. Deep neck infection complicated by diabetes mellitus: Report of a case. *Oral Surg Oral Med Oral Pathol* 1983; 55: 133-137.
- [13] Sugata T, Fujita Y, Myoken Y, Fujioka Y. Cervical cellulitis with mediastinitis from an odontogenic infection complicated by diabetes mellitus: report of a case. *J Oral MaxillofacSurg* 1997; 55: 864-869.
- [14] Ueta E, Osaki T, Yoneda K, Yamamoto T. Prevalence of diabetes mellitus in odontogenic infections and oral candidiasis: an analysis of neutrophil suppression. *J Oral Pathol Med* 1993; 22: 168-174.
- [15] Carter L, Lowis E. Death from overwhelming odontogenic sepsis: a case report. *Br Dent J* 2007; 203: 241-242.
- [16] Green AW, Flower EA, New NE. Mortality associated with odontogenic infection! *Br Dent J* 2001; 190: 529-530.
- [17] Estrera AS, Landay MJ, Grisham JM, Sinn DP, Platt MR. Descending necrotizing mediastinitis. *SurgGynecolObstet* 1983; 157: 545-552.
- [18] Mathieu D, Neviere R, Teillon C, Chagnon JL, Lebleu N, Wattel F. Cervical necrotizing fasciitis: clinical manifestations and management. *Clin Infect Dis* 1995; 21: 51-56.
- [19] Sakamoto H, Aoki T, Kise Y, Watanabe D, Sasaki J. Descending necrotizing mediastinitis due to odontogenic infections. *Oral Surg Oral Med Oral Pathol Oral RadiolEndod* 2000; 89: 412-419.
- [20] Wheatley MJ, Stirling MC, Kirsh MM, Gago O, Orringer MB. Descending necrotizing mediastinitis: transcervical drainage is not enough. *Ann ThoracSurg* 1990; 49: 780-784.
- [21] Pinto A, Scaglione M, Scuderi MG, Tortora G, Daniele S, Romano L. Infections of the neck leading to descending necrotizing mediastinitis: Role of multi-detector row computed tomography. *Eur J Radiol* 2008; 65: 389-394.

- [22] Smith JK, Armao DM, Specter BB, Castillo M. Danger space infection: infection of the neck leading to descending necrotizing mediastinitis. *EmergRadiol* 1999; 6: 129-132.
- [23] Harnsberger HR, Osborn AG. Differential diagnosis of head and neck lesions based on their space of origin. 1. The suprahyoid part of the neck. *AJR Am J Roentgenol* 1991; 157: 147-154.
- [24] Lockhart PB, Brennan MT, Kent ML, Norton HJ, Weinrib DA. Impact of amoxicillin prophylaxis on the incidence, nature, and duration of bacteremia in children after intubation and dental procedures. *Circulation* 2004; 109: 2878-2884.
- [25] Rajasuo A, Nyfors S, Kanervo A, Jousimies-Somer H, Lindqvist C, Suuronen R. Bacteremia after plate removal and tooth extraction. *Int J Oral MaxillofacSurg* 2004; 33: 356-360.
- [26] Sato FR, Hajala FA, Freire Filho FW, Moreira RW, de Moraes M. Eight-year retrospective study of odontogenic origin infections in a postgraduation program on oral and maxillofacial surgery. *J Oral MaxillofacSurg* 2009; 67: 1092-1097.
- [27] Flynn TR, Shanti RM, Levi MH, Adamo AK, Kraut RA, Trieger N. Severe odontogenic infections, part 1: prospective report. *J Oral MaxillofacSurg* 2006; 64: 1093-1103.
- [28] Eklund SA, Pittman JL. Third-molar removal patterns in an insured population. *J Am Dent Assoc* 2001; 132: 469-475.
- [29] Kunkel M, Morbach T, Kleis W, Wagner W. Third molar complications requiring hospitalization. *Oral Surg Oral Med Oral Pathol Oral RadiolEndod* 2006; 102: 300-306.
- [30] Worrall SF, Riden K, Haskell R, Corrigan AM. UK National Third Molar project: the initial report. *Br J Oral MaxillofacSurg* 1998; 36: 14-18.
- [31] Hugoson A, Kugelberg CF. The prevalence of third molars in a Swedish population. An epidemiological study. *Community Dent Health* 1988; 5: 121-138.
- [32] Bui CH, Seldin EB, Dodson TB. Types, frequencies, and risk factors for complications after third molar extraction. *J Oral MaxillofacSurg* 2003; 61: 1379-1389.
- [33] Libersa P, Roze D, Cachart T, Libersa JC. Immediate and late mandibular fractures after third molar removal. *J Oral MaxillofacSurg* 2002; 60: 163-165; discussion 165-166.
- [34] Moghadam HG, Caminiti MF. Life-threatening hemorrhage after extraction of third molars: case report and management protocol. *J Can Dent Assoc* 2002; 68: 670-674.
- [35] Valmaseda-Castellon E, Berini-Aytes L, Gay-Escoda C. Inferior alveolar nerve damage after lower third molar surgical extraction: a prospective study of 1117 surgical extractions. *Oral Surg Oral Med Oral Pathol Oral RadiolEndod* 2001; 92: 377-383.

- [36] Yoshii T, Hamamoto Y, Muraoka S, Kohjitani A, Teranobu O, Furudo S, *et al.* Incidence of deep fascial space infection after surgical removal of the mandibular third molars. *J Infect Chemother* 2001; 7: 55-57.
- [37] Blakey GH, Marciani RD, Haug RH, Phillips C, Offenbacher S, Pabla T, *et al.* Periodontal pathology associated with asymptomatic third molars. *J Oral Maxillofac Surg* 2002; 60: 1227- 1233.
- [38] Eliasson S, Heimdahl A, Nordenram A. Pathological changes related to long-term impaction of third molars. A radiographic study. *Int J Oral Maxillofac Surg* 1989; 18: 210-212.
- [39] Fuselier JC, Ellis EE, 3rd, Dodson TB. Do mandibular third molars alter the risk of angle fracture? *J Oral Maxillofac Surg* 2002; 60: 514-518.
- [40] Knutsson K, Brehmer B, Lysell L, Rohlin M. Pathoses associated with mandibular third molars subjected to removal. *Oral Surg Oral Med Oral Pathol Oral Radiol Endod* 1996; 82: 10- 17.
- [41] Manganaro AM, Cross SE, Startzell JM. Carcinoma arising in a dentigerous cyst with neckmetastasis. *Head Neck* 1997; 19: 436-439.
- [42] Punwutikorn J, Waikakul A, Ochareon P. Symptoms of unerupted mandibular third molars. *Oral Surg Oral Med Oral Pathol Oral Radiol Endod* 1999; 87: 305-310.
- [43] Yamaoka M, Furusawa K, Ikeda M, Hasegawa T. Root resorption of mandibular second molar teeth associated with the presence of the third molars. *Aust Dent J* 1999; 44: 112-116.
- [44] Leone SA, Edenfield MJ, Cohen ME. Correlation of acute pericoronitis and the position of the mandibular third molar. *Oral Surg Oral Med Oral Pathol* 1986; 62: 245-250.
- [45] Venta I, Turtola L, Murtomaa H, Ylipaavalniemi P. Third molars as an acute problem in Finnish university students. *Oral Surg Oral Med Oral Pathol* 1993; 76: 135-140.
- [46] Robertson D, Smith AJ. The microbiology of the acute dental abscess. *J Med Microbiol* 2009; 58: 155-162.
- [47] Zachariades N, Mezitis M, Stavrinidis P, Konsolaki-Agouridaki E. Mediastinitis, thoracic empyema, and pericarditis as complications of a dental abscess: report of a case. *J Oral Maxillofac Surg* 1988; 46: 493-495.
- [48] Braun IF, Hoffman JC, Jr. Computed tomography of the buccomasseteric region: 1. Anatomy. *AJNR Am J Neuroradiol* 1984; 5: 605-610.
- [49] Curtin HD. Separation of the masticator space from the parapharyngeal space. *Radiology* 1987; 163: 195-204.

- [50] Paparella MM, Shumrick KA. *Otolaryngology: Head and Neck*. Philadelphia: WB Saunders, 1993: 2545-2563.
- [51] Nyberg DA, Jeffrey RB, Brant-Zawadzki M, Federle M, Dillon W. Computed tomography of cervical infections. *J Comput Assist Tomogr* 1985; 9: 288-296.
- [52] Lindner HH. The anatomy of the fasciae of the face and neck with particular reference to the spread and treatment of intraoral infections (Ludwig's) that have progressed into adjacent fascial spaces. *Ann Surg* 1986; 204: 705-714.
- [53] Gutierrez-Perez JL. Third molar infections. *Med Oral Patol Oral Cir Bucal* 2004; 9 Suppl: 122-125; 120-122.
- [54] Dogan N, Orhan K, Gunaydin Y, Koymen R, Okcu K, Uocok O. Unerupted mandibular third molars: symptoms, associated pathologies, and indications for removal in a Turkish population. *Quintessence Int* 2007; 38: e497-505.
- [55] Peltroche-Llacsahuanga H, Reichhart E, Schmitt W, Lutticken R, Haase G. Investigation of infectious organisms causing pericoronitis of the mandibular third molar. *J Oral MaxillofacSurg* 2000; 58: 611-616.
- [56] Gonzalez-Moles MA, Gonzalez NM. Bacterial infections of pulp and periodontal origin. *Med Oral Patol Oral Cir Bucal* 2004; 9 Suppl: 34-36; 32-34.
- [57] Marple BF. Ludwig angina: a review of current airway management. *Arch Otolaryngol Head Neck Surg* 1999; 125: 596-599.
- [58] Rubin MM, Cozzi GM. Fatal necrotizing mediastinitis as a complication of an odontogenic infection. *J Oral MaxillofacSurg* 1987; 45: 529-533.
- [59] Garatea-Crelgo J, Gay-Escoda C. Mediastinitis from odontogenic infection. Report of three cases and review of the literature. *Int J Oral MaxillofacSurg* 1991; 20: 65-68.
- [60] Zeitoun IM, Dhanarajani PJ. Cervical cellulitis and mediastinitis caused by odontogenic infections: report of two cases and review of literature. *J Oral MaxillofacSurg* 1995; 53: 203- 208.
- [61] Maisel RH, Karlen R. Cervical necrotizing fasciitis. *Laryngoscope* 1994; 104: 795-798.
- [62] Sellers BJ, Woods ML, Morris SE, Saffle JR. Necrotizing group A streptococcal infections associated with streptococcal toxic shock syndrome. *Am J Surg* 1996; 172: 523-527; discussion 527-528.
- [63] Skitarelic N, Mladina R, Morovic M, Skitarelic N. Cervical necrotizing fasciitis: sources and outcomes. *Infection* 2003; 31: 39-44.
- [64] Tung-Yiu W, Jehn-Shyun H, Ching-Hung C, Hung-An C. Cervical necrotizing fasciitis of odontogenic origin: a report of 11 cases. *J Oral MaxillofacSurg* 2000; 58: 1347-1352; discussion 1353.

- [65] Lalwani AK, Kaplan MJ. Mediastinal and thoracic complications of necrotizing fasciitis of the head and neck. *Head Neck* 1991; 13: 531-539.
- [66] Shindo ML, Nalbone VP, Dougherty WR. Necrotizing fasciitis of the face. *Laryngoscope* 1997; 107: 1071-1079.
- [67] Novellas S, Kechabtia K, Chevallier P, Sedat J, Bruneton JN. Descending necrotizing mediastinitis: a rare pathology to keep in mind. *Clin Imaging* 2005; 29: 138-140.
- [68] Schuknecht B, Stergiou G, Graetz K. Masticator space abscess derived from odontogenic infection: imaging manifestation and pathways of extension depicted by CT and MR in 30 patients. *EurRadiol* 2008; 18: 1972-1979.
- [69] Tsunoda R, Suda S, Fukaya T, Saito K. Descending necrotizing mediastinitis caused by an odontogenic infection: a case report. *J Oral MaxillofacSurg* 2000; 58: 240-242.