

We are IntechOpen, the world's leading publisher of Open Access books Built by scientists, for scientists

4,800

Open access books available

122,000

International authors and editors

135M

Downloads

Our authors are among the

154

Countries delivered to

TOP 1%

most cited scientists

12.2%

Contributors from top 500 universities



WEB OF SCIENCE™

Selection of our books indexed in the Book Citation Index
in Web of Science™ Core Collection (BKCI)

Interested in publishing with us?
Contact book.department@intechopen.com

Numbers displayed above are based on latest data collected.
For more information visit www.intechopen.com



Multidisciplinary Management of Benign Jaw Tumors in Children

Mehmet Cemal Akay, Mert Zeytinoğlu,
Birant Şimşek and Işıl Aras

Additional information is available at the end of the chapter

<http://dx.doi.org/10.5772/59341>

1. Introduction

A tumor is defined, in brief, as abnormal growth of tissue; tumoral formations are classified under two main headings, benign and malignant. The oro-facial region including the jaw bones, maxilla and mandible, is a site for a multitude of neoplastic conditions. Odontogenic tumors (OTs) constitute a wide range and diverse kind of lesions derived from tooth forming apparatus and its remnants. OTs originate from epithelium or ectomesenchyme or from both, showing varying degrees of inductive interaction between these embryonic components of the developing tooth germ. [1]. The majority of these tumors occur intraosseously within the maxillofacial skeleton, while extraosseous odontogenic tumors occur nearly always in the tooth-bearing mucosa. Due to their specific structure and location they have been identified and classified by pathologists into a separate group, differing in histogenesis, biology, clinical findings and radiological signs from other tumors developing in the oral cavity and facial bones (Figure 1).

The aim of the chapter is to review multidisciplinary treatment approaches to pediatric patients with benign jaw tumors from a radiological and clinical point of view and assess advantages and disadvantages of the current treatment techniques, possible complications and their prevention in the light of the recent literature.

1.1. Etiology of odontogenic tumors

According to current literatures, it is known that the potential sources for development of an odontogenic tumor are varied, and these include:

1. **The pre-functional dental lamina** (odontogenic epithelium with ability to produce a tooth), which is more abundant distal to the lower third molars.
2. **The post-functional dental lamina**, a concept that covers those epithelial remnants such as Serre's epithelial rests, located within the fibrous gingival tissue; the epithelial cell rests of Malassez in the periodontal ligament and the reduced enamel organ epithelium, which covers the enamel surface until tooth eruption.
3. **The basal cell layer of the gingival epithelium**, which originally gave rise to the dental lamina.
4. **The dental papilla**, origin of the dental pulp, which has the potential to be induced to produce odontoblasts and synthesize dentin and/or dentinoid material.
5. **The dental follicle.**
6. **The periodontal ligament**, which has the potential to induce the production of fibrous and cemento-osseous mineralized material [2].

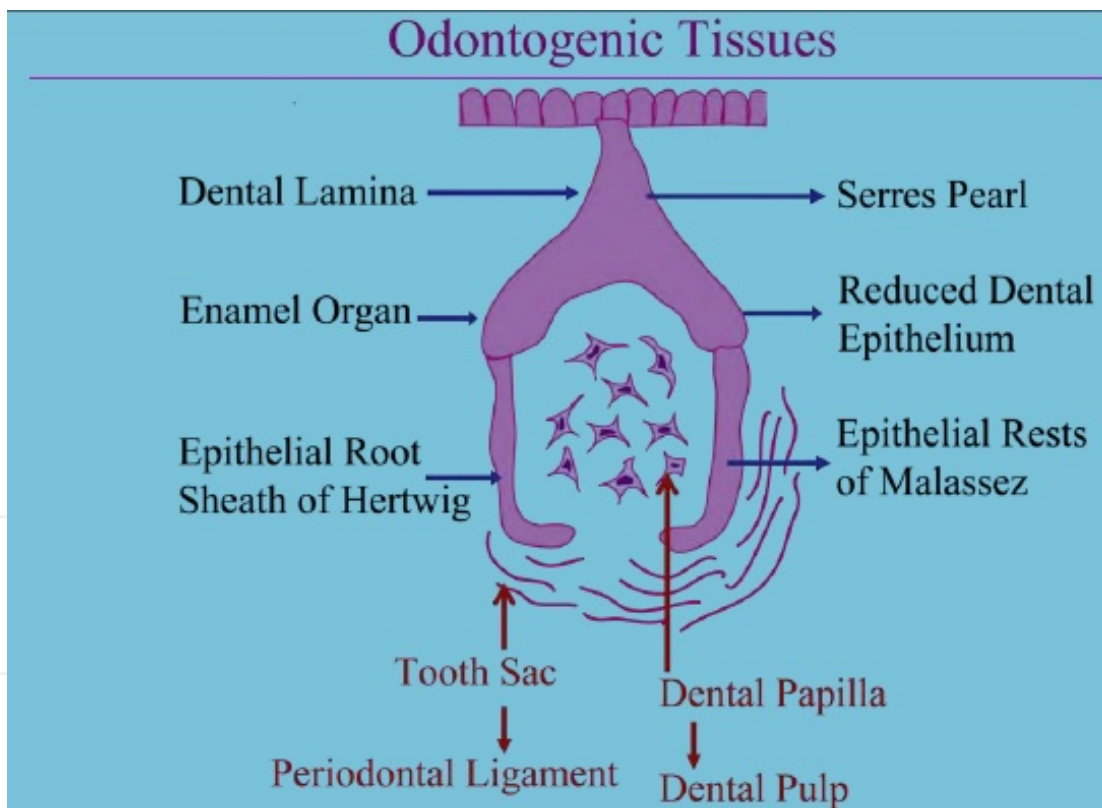


Figure 1. Odontogenic tumors arising from odontogenic tissues

From a biological point of view, some of these lesions represent hamartomas with varying degrees of differentiation, while the rest are benign or malignant neoplasms with variable aggressiveness and potential to develop metastases. These tumors constitute a heterogeneous group of diseases with diverse clinical and histopathological features [3]. The relative fre-

quency of OTs obtained from studies from different parts of the world, have varied widely. Some authors have reported that OTs are rare with a relative frequency of 1%, while others have reported OTs constitute up to 32% of jaw lesions [4-6]. These disparities have been suggested to be due to the differences in terminology and classification and also, possibly due to racial and or genetic differences in the occurrence of the various types of OTs. OTs comprise a large heterogeneous group of lesions originating from the epithelium and/or odontogenic ectomesenchyme and remnants. OTs include entities of a hamartomatous nature, such as odontoma, benign neoplasms, some of which are aggressive as is the case of ameloblastoma and myxoma and malignant neoplasms capable of metastasis [2, 7].

Primary jaw tumors are broadly classified into odontogenic and nonodontogenic groups. The World Health Organization (WHO) classified this group of lesions in 1971 and 1992. In 2005, the WHO published the latest updated edition of the classification of OTs. There were 6 major changes in this schema from the previous versions namely:

1. parakeratinized variant of odontogenic keratocyst is now classified as a benign tumor and termed KCOT
2. adenomatoid odontogenic tumor (AOT) originates from the odontogenic epithelium with mature fibrous stroma and without ectomesenchyme
3. calcifying odontogenic cyst (COC) is divided into 2 benign and 1 malignant groups
4. clear cell odontogenic tumor is a malignant lesion and termed clear cell odontogenic carcinoma (CCOC)
5. odontogenic carcinosarcoma is not included due to the lack of evidence for the existence of this type and
6. some changes were made regarding terminology and subtypings [5-7].

The latest WHO classification has been used as a global standard for the last 10 years but our knowledge of odontogenic tumors continues to evolve.

The latest WHO classification of odontogenic tumors

1. Malignant odontogenic tumors

Odontogenic carcinomas

Metastasizing (malignant) ameloblastoma

Ameloblastic carcinoma - primary type

Ameloblastic carcinoma - secondary type (dedifferentiated), intraosseous

Ameloblastic carcinoma - secondary type (dedifferentiated), peripheral

Primary intraosseous squamous cell carcinoma solid type

Primary intraosseous squamous cell carcinoma derived from keratocystic odontogenic tumor

Primary intraosseous squamous cell carcinoma derived from odontogenic cysts

Clear cell odontogenic carcinoma

Ghost cell odontogenic carcinoma

Odontogenic sarcomas

Ameloblastoma fibrosarcoma

Ameloblastic fibro-dentino- and fibro-odontosarcoma

2. Benign odontogenic tumors

Odontogenic epithelium with mature, fibrous stroma without odontogenic ectomesenchyme

Ameloblastoma, solid/multicystic type

Ameloblastoma, extraosseous/peripheral type

Ameloblastoma, desmoplastic type

Ameloblastoma, unicystic type

Squamous odontogenic tumor

Calcifying epithelial odontogenic tumor

Adenomatoid odontogenic tumor and Keratocystic odontogenic tumor

Odontogenic epithelium with odontogenic ectomesenchyme, with or without hard tissue formation

Ameloblastic fibroma

Ameloblastic fibro-dentinoma

Ameloblastic fibro-odontoma

Odontoma

- Odontoma, complex type

- Odontoma, compound type

Odontoameloblastoma

Calcifying cystic odontogenic tumor

Dentinogenic ghost cell tumor

Mesenchyme and/or odontogenic ectomesenchyme with or without odontogenic epithelium

Odontogenic fibroma

Odontogenic myxoma and myxofibroma

Cementoblastoma

Bone-related (Fibro-osseous) lesions

Ossifying fibroma

Fibrous dysplasia

Osseous dysplasia

Periapical Osseous Dysplasia

Focal Osseous Dysplasia

Florid Osseous Dysplasia

Central giant cell granuloma

Cherubism

Aneurysmal bone cyst

Solitary (Simple) bone cyst

Other tumors

Melanotic neuroectodermal tumor of infancy

Classification of the Latest Benign Fibro-Osseous Lesions of the Craniofacial Complex: [8]

1. Bone dysplasias

a. Fibrous dysplasia

- i. Monostotic
- ii. Polyostotic
- iii. Polyostotic with endocrinopathy (McCune-Albright)
- iv. Osteofibrous dysplasia

b. Osteitis deformans

c. Pagetoid heritable bone dysplasias of childhood

d. Segmental odontomaxillary dysplasia

2. Cemento-osseous dysplasia

a. Focal cemento-osseous dysplasia

b. Florid cemento-osseous dysplasia

3. Inflammatory/reactive processes

a. Focal sclerosing osteomyelitis

b. Diffuse sclerosing osteomyelitis

c. Proliferative periostitis

4. Metabolic Disease: hyperparathyroidism

5. Neoplastic lesions (Ossifying fibromas)

a. Ossifying fibroma

b. Hyperparathyroidism jaw lesion syndrome

c. Juvenile ossifying fibroma

- i. Trabecular type
- ii. Psammomatoid type

d. Gigantiform cementomas

In pace with new findings of new genetic and molecular changes, classification of odontogenic tumors will necessitate further modification and subsequent changes in the classification system. Hence a new and revised version of the classification will always be dynamic. Characteristics and epidemiology of jaw tumors have been described mostly in adults. Compared with their adult counterparts, jaw tumors in childhood show considerable differences. Tumors of the head and neck represent only 2% to 5% of all pediatric tumors. OTs in children constitute approximately 3% of all tumor like growths in the oral cavity, jaws and salivary glands in all age groups [9]. In general, OTs in the pediatric population are rare and considerably more so than in the adult population. There are differences in the spectrum of diseases seen in this group and in adults. When the diseases are similar, there are sometimes differences in their clinical behavior. There are additional management concerns when working with children. Treatment burden is given relatively greater consideration in children since they are growing and developing and treatment may exert untoward influences therein. It is important for the clinicians involved in the diagnosis and treatment of pediatric head and neck tumors to understand certain patterns that follow the development of these lesions, so that misdiagnosis and delays in treatment can be avoided. Because of their relative rarity, this broad spectrum of lesions require careful attention and close collaboration between pediatricians, medical oncologists, radiotherapists, pathologists and surgeons working in the head and neck area. Pathology is uncommon among the pediatric age group, its incidence and prevalence has been increasing in recent years, and it remains a significant cause of morbidity and mortality in this population. Recently, Jones and Franklin performed a retrospective investigation of oral and maxillofacial pathologies within a 30-year period. Those authors verified that biopsies in patients aged between 10 and 16 years represented 8.2% of all cases reported.[10]

Classification of pediatric jaw tumors

The various classifications systems proposed by authors are enumerated as below:

1. Jaw Tumors in Children (11)

1. Classification of non-odontogenic jaw tumors in children

I. Benign mesenchymal tumors

- a) Giant cell lesions
- b) Fibro-osseous lesions
- c) Myxoma

II. Hematopoietic and reticuloendothelial tumors

- a) Langerhans cell histiocytosis
- b) Burkitt's lymphoma
- c) Lymphoma

III. Neurogenic tumors

- a) Neurofibroma
- b) Neurilemmoma
- c) Neuroma
- d) Ganglioneuroma
- e) Neuroblastoma

f) Melanotic neuroectodermal tumor

IV. Vascular lesions

- a) Vascular malformation (capillary, lymphatic, venous, arterial, combined)
- b) Hemangioma
- c) Aneurysmal bone cyst

V. Malignant mesenchymal tumors

- a) Osteogenic sarcoma
- b) Chondrosarcoma
- c) Fibrosarcoma
- d) Ewing's sarcoma

VI. Malignant epithelial tumors

- a) Squamous cell carcinoma
- b) Mucoepidermoid carcinoma
- c) Adenoid cystic carcinoma
- d) Adenocarcinoma

2. Classification of odontogenic jaw tumors in children

I. Epithelial tumors

- a) Ameloblastoma (Peripheral, Unicystic, Solid, Multicystic)
- b) Adenomatoid odontogenic tumor
- c) Calcifying epithelial odontogenic tumor

II. Mesodermal tumors

- a) Cementoma
- b) Periapical cemental dysplasia
- c) Cementifying fibroma
- d) Cementoblastoma
- e) Odontogenic fibroma

III. Mixed tumors

- a) Ameloblastic fibroma
- b) Odontoma

3. Classification of Small Round Cell Tumors in children

1. Soft tissue Rhabdomyosarcoma

Soft tissue (extraosseous) Ewing's sarcoma

Hemangiopericytoma

2. Osseous Ewing's sarcoma

Small cell osteosarcoma

Mesenchymal chondrosarcoma

Hemangiopericytoma of bone

3. Neural

Neuroblastoma

Peripheral neuroectodermal tumors

- Askin's tumor
- Neuroepithelioma

Pheochromocytoma

4. International classification of childhood cancer (12)

Malignant Bone tumors

- a) Osteosarcomas
- b) Chondrosarcomas
- c) Ewing tumor and related sarcomas of bone
- d) Other specified malignant bone tumors
- e) Unspecified malignant bone tumors

Soft tissue and other extraosseous sarcomas

- a) Rhabdomyosarcomas
- b) Fibrosarcomas, peripheral nerve sheath tumors and other fibrous neoplasms
- c) Kaposi's sarcoma
- d) Other specified soft tissue sarcomas
- e) Unspecified soft tissue sarcomas

2. Clinical sign and symptoms of pediatric jaw tumors

Pediatric patients encompass a very interesting study group, as several long term physiological changes take place in the maxillofacial area. During the mixed dentition period, children can refer with a complaint of swelling in the maxillofacial area, which may or may not be associated with pain. These mostly include both hard and soft tissue pathologies. When involving bone, only odontogenic cysts or odontogenic tumors as a category have been considered. Intraosseous pediatric jaw lesions can present in diverse clinical patterns and their diagnoses can vary from odontogenic to non-odontogenic pathogeneses, which can rarely include connective tissue pathology. The great majority of pediatric jaw tumors are non-odontogenic [13,14].

OTs can be observed casually or after the appearance of nonspecific symptoms. Because of their slow-growth tendency, usually they do not cause pain. The odontogenic tumors grow in the jaw, through the haversian system, without metastases but with a high probability of relapse. In the majority of cases, tumors of the head and neck in children are first seen by general practitioners or pediatricians with subsequent delays in investigations and diagnosis. Some of these tumors may disappear spontaneously without any treatment. During the mixed dentition period, children can report with complaint of swelling in the maxillofacial area, which may or may not be associated with pain. A history of trauma also needs to be elicited, because they are prone to falling down during playing, which can affect the jaws. Because of the complex anatomy and development of the head and neck, neoplasms during infancy and childhood arising at this site represent the most difficult challenges in clinical practice. [15]

3. Diagnosis of pediatric jaw tumors

The odontogenic cysts and tumors are a diverse group of lesions that represent deviation from normal odontogenesis. The physical signs and symptoms of odontogenic cysts and tumors

will depend to a certain extent on the dimensions of the lesion. A small lesion is unlikely to be diagnosed on a routine examination of the mouth because signs will not be demonstrable. Such lesions are only likely to be detected at an early stage as the result of routine radiographic examination. Exceptions are some early lesions that may present in conjunction with a devitalized tooth, which is detectable on clinical examination. Some cystic lesions may become secondarily infected, leading to their diagnosis. Clinical absence of one or more teeth without the history of extraction may also be a clinical indicator of an undiagnosed odontogenic cyst or tumor because many of these lesions are associated with impacted or congenitally missing teeth. As the lesion grows, other indirect changes may occur. An enlarging lesion between two teeth can cause the crowns to converge and the roots to diverge. Growth that is nearly undetectable visually may lead to difficulty with denture retention. As the lesion enlarges even further, expansion of the bone may be seen directly. This is usually toward the buccal surface of the alveolar bone because this is the thinnest area and expansion occurs here most easily. Clinically evident expansion is often a late finding, especially in lesions developing within the ramus or angle of the mandible or within the maxillary sinus. Lesions in these areas may become extremely large before expansion is observed clinically. Masses in the neck confront the pediatrician with greater opportunities for evaluation before a decision regarding biopsy or excision is reached. Signs of systemic involvement must also be determined.

3.1. Radiographic and imaging studies

- The primary goals of radiographic assessment are to more precisely define the primary lesion and to detect metastatic disease for clinical staging
- Chest radiographs are useful screens for mediastinal lymphadenopathy
- Ultrasound is able to differentiate a solid from a cystic mass, and give general relationships of the mass to adjacent structures
- Axial and coronal computerized tomography (CT) allows documentation of bone erosion and invasion of adjacent structures
- Magnetic resonance imaging (MRI) offers improved tissue contrast and definition
- Angiography delineates the blood supply to a lesion, and offers the ability to embolize specific factors to decrease blood loss associated with excision of vascular lesions
- Bone scans and liver spleen scans offer modalities to detect systemic disease. [9, 16]

A tissue diagnosis becomes necessary in order to diagnose and initiate proper therapy.

3.2. Biopsy

- Biopsy of OTs allows histologic evaluation of the mass
- Excisional biopsy is often therapeutic as well as diagnostic
- Incisional biopsy is required in cases where the lesion is large, or the lesion is relatively inaccessible

- Fine needle aspiration for cytologic study is useful in salivary gland and thyroid gland lesions. However, its generalized use for all pediatric head and neck masses is limited due to the rarity of squamous or glandular neoplasms developing in children
- Large bore needle biopsy has no established role in the evaluation of head and neck malignancies in children and has been reported to cause seeding along the needle tract in children. [9, 16]

OTs have a specific histological structure reflecting various stages of odontogenesis and are located mainly in the jaws, rarely in other parts of the skeletal system. Due to their specific structure and location they have been identified and classified by pathologists into a separate group of neoplasms differing from other lesions developing in the oral cavity and facial bones [17]. Odontogenic tissue is programmed to produce dentin and enamel due to active interactions between odontogenic mesenchyme and epithelium. Tooth formation is achieved via odontogenic mesenchyme and epithelium stage- and spatial-specific differentiation from early tooth development to late maturation [18]. Therefore, when odontogenic tissue becomes undifferentiated and undergoes tumoral changes, it has the potential to produce abnormal calcifications with enameloid, dentinoid, and cementum-like material histologic features. For this reason, these odontogenic calcifications are important odontogenic tumor characteristics and occasionally are accompanied by odontogenic epithelium ghost cell change and amorphous odontogenic mesenchyme hyalinization [19].

Aspiration cytology, a well established diagnostic tool in adult oncology, is recently gaining acceptance in pediatric population, as clinicians add this technique to their diagnostic armamentarium. Fine-needle aspiration cytology is a useful and reliable tool in the diagnosis of head and neck OTs with no contraindications and minimal complications even in children [20].

More than 95% of all OT reported in large series are benign and around 75% are represented by odontomas, ameloblastomas and myxomas (which could be considered as “relatively frequent OT”). Due to the inclusion of the odontogenic keratocyst as a tumor, these figures will be modified significantly, as this lesion is more frequently diagnosed than the other three entities. Some studies have shown epidemiological data that demonstrate that there is a second group of OT, which, although rare in terms of general pathology, are of “intermediate frequency” with respect to other OT, which have to be considered in the differential diagnosis of tumors of the oral and maxillofacial regions; therefore they have to be included within the contents of pathology of the graduate and post-graduate courses of oral and general pathology. The lack of specific markers to confirm the odontogenic origin of all the lesions included in the current WHO classification makes diagnoses mainly on anatomic considerations, or on the histomorphological similarities among some tumors with the above mentioned odontogenic structures. However, as most OT contain variable amounts of epithelium, and the fact that such tissue may express several of the more than 20 cytokeratin markers (intermediate filaments of the epithelial cells) known to date, there are some studies that have demonstrated that cytokeratins 14 and 19 are the more frequently expressed by OT, and that these are also expressed in the different epithelial structures of the developing tooth [21, 22], leading to promote their use as a diagnostic tool to support the odontogenic nature of these entities. Additionally, the expression of amelogenin, a representative protein of the enamel matrix,

which is produced by secretory ameloblasts and that seem to actively participate in the process of production and mineralization of enamel, has been consistently demonstrated within the enamel matrix and the cytoplasm of the cells of the reduced enamel epithelium, stratum intermedium and stellate reticulum of the enamel organ, as well as in some epithelial OT, particularly at the basal endings of the cuboidal or columnar cells of ameloblastomas and in cells of calcifying epithelial odontogenic tumor, malignant ameloblastoma and ameloblastic carcinoma [22]. Therefore, the use of these markers is a valuable tool to discard other types of epithelial lesions that may develop within the oral and maxillofacial regions. More recently, calretinin, a 29-kDa calcium-binding protein has been shown to be expressed in both unicystic and solid ameloblastomas but not in other types of odontogenic cysts, and this finding led some authors to propose it may be considered a specific immunohistochemical marker for neoplastic ameloblastic epithelium [23] and an important diagnostic aid in the differential diagnosis of cystic odontogenic lesions, particularly the keratocystic odontogenic tumor [24]. In the same way, the expression of cytodifferentiation of neoplastic epithelium via epithelial-mesenchymal interactions and mineralization markers, such as bone morphogenetic protein (BMP) is of great value to study those lesions that are characterized by the production of hard dental tissues [25, 26].

4. Treatment of pediatric jaw tumors

The majority of tumors of the mouth and jaw in children are benign. Tanaka et al. reported that only 3% of their cases were malignant in nature. In another study, benign tumors composed 93% of the cases (13, 14, 27).

Treatment consists of a range of surgical methods, from surgical curettage to hemimandibulectomy and reconstruction with bone graft. Generally, surgical excision, curettage, cryosurgery or en bloc resection are adequate for treatment of these tumors. However, some patients need multiple treatment because of its specific criterias such as the clinical behavior and extent of the lesion. Odontogenic lesions encompasses a wide spectrum of lesions and their variants, which either can be a cyst or a tumor. Odontogenic cysts are derived from the epithelium associated with the development of the dental apparatus while a tumor forms through some aberration from the normal pattern of odontogenesis. But the fact, that these lesions can mimic each other can complicate the diagnosis. The Adenomatoid Odontogenic Tumor is a benign, nonaggressive odontogenic tumor which has been known by a number of descriptive names since it was first reported. In almost all instances, the lesion may be removed by surgical enucleation. Unicystic Ameloblastoma is another tumor of the odontogenic series which has been described as benign but locally invasive. The Dentigerous Cyst, a cyst of odontogenic origin, has the potential of transforming into an Ameloblastoma. The Odontogenic Keratocyst, is characterized by aggressive behavior has debatable treatment options. All OTs can have a similar clinical and radiographic features which can mislead the dentist and a biopsy is needed to make a final diagnosis. Of all odontogenic tumors, ameloblastomas are the most controversial in terms of treatment. Treatments range from surgical curettage to bloc excision or resection [28]. Surgical excision in the infant or child is sometimes met with resistance by both parents

and physicians, yet with many tumors surgery is clearly the best treatment. A wide resection for some tumors may pose psychological and cosmetic difficulties that parents can learn to accept if these difficulties are discussed in an open and helpful manner. When parents accept their children disabilities, the children in turn, can adjust very well functionally and psychologically following operations [29]. Cryosurgery is relatively new to the management of head and neck tumors in children. Local freezing has the ability to destroy tumor cells. A wide variety of probe tips are available to treat lesions of the skin, nose, mouth, nasopharynx, oropharynx, hypopharynx and larynx. Unlike surgical excision or radiation therapy, cryosurgery has the capability of destroying the tumor and only minimally affecting the surrounding normal tissue; also unlike radiation therapy, cryosurgery can be repeatedly administered to a specific area should the tumor persist or recur. The role of cryosurgery is still being assessed, but the potential is both great and exciting [29]. In planning treatment for pediatric tumors, authors stress the importance of the growth development of the jaw, and of esthetics and functional concerns in later periods of life [30].

5. Benign odontogenic tumors

5.1. Odontogenic epithelium with mature, fibrous stroma without odontogenic ectomesenchyme

5.1.1. Ameloblastomas have been classified as follows (WHO 2005 classification)

- Ameloblastoma, solid/multicystic type
- Ameloblastoma, extraosseous/peripheral type
- Ameloblastoma, desmoplastic type
- Ameloblastoma, unicystic type

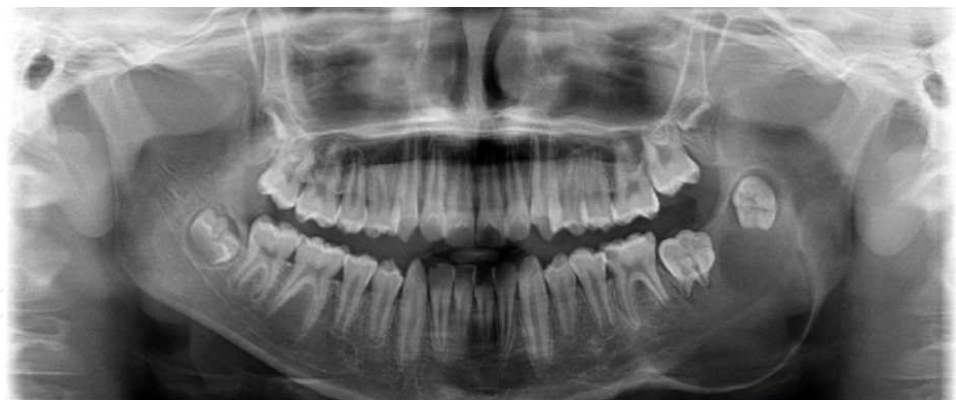Ameloblastoma is a tumor of the odontogenic epithelium, first described by Cusick in 1827. Ameloblastoma is perhaps the most perplexing of all odontogenic neoplasms due to its unexplainable clinical and histopathological behavior [31] It accounts for less than 1% of all odontogenic cysts and tumors. Although all ameloblastomas have the same cell of origin, there are several biologically distinct forms. The differences are especially important in pediatric cases. Central ameloblastomas occur as unicystic, multicystic or solid lesions. Ameloblastoma is non-encapsulated and infiltrates surrounding bone marrow. Even though they are locally infiltrative, they can rarely metastasize. They may occur in any part of both jaws but most are in the middle and posterior regions of the mandible. Ameloblastomas are always purely radiolucent and may be unilocular but frequently become multilocular as they increase in size. If not found and treated early, they will expand the jaws. Despite being categorized as benign tumors, ameloblastomas have a high rate of recurrence, and there is a risk of malignant transformation when treated inadequately. Clinically, ameloblastoma frequently manifests as a painless swelling, which can be accompanied by facial deformity, malocclusion, and loss of dentition, ulceration and periodontal disease. Sometimes pain occurs with varying intensities,

but often quite low. It is not known whether the cause of the pain is pressure from the tumor on peripheral nerves or secondary infection [32].

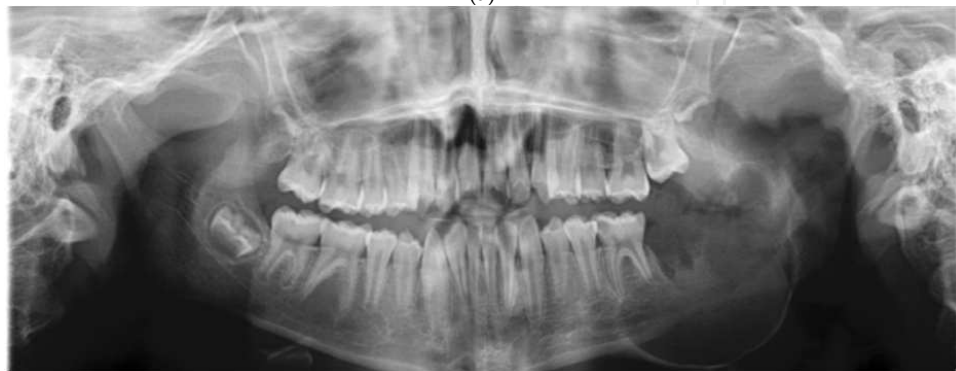The unicystic ameloblastoma resembles a dentigerous or primordial cyst clinically and radiographically and often occurs in teenage patients. Multicystic or solid ameloblastomas occur most commonly in patients 30 to 50 years of age and are extremely rare in childhood. Choung and Kaban in review of pediatric jaw tumors found only one case in 10 years. In the pediatric population, ameloblastoma must be considered in the differential diagnosis of radiolucent lesions of the jaws. In the vast majority of pediatric cases, however, these turn out to be either odontogenic or non-odontogenic cysts or non-odontogenic primary jaw tumors. The two ameloblastic lesions that are found in childhood are the ameloblastic fibroma and the unicystic ameloblastoma. The ameloblastic fibroma appears as an asymptomatic radiolucent lesion, often associated with an impacted tooth and indistinguishable from an odontogenic cyst. The patients are usually under 12 years of age. The unicystic ameloblastoma occurs in teenagers, most commonly in the mandible. The patient exhibits a painless facial swelling or radiolucency, usually associated with an impacted third molar. The lesion is most commonly unilocular and may produce cortical expansion or perforation. Roots of adjacent teeth may be displaced or resorbed. Aspiration reveals clear serous fluid from a cystic mass [33].

There has been some debate regarding the most appropriate method for surgical removal of ameloblastomas. These range from conservative to radical modes of treatment. The conservative modalities include curettage, enucleation and cryosurgery; while the radical modalities are marginal, segmental and composite resections. The recommended treatment for ameloblastoma in children should be radical resection, 0.5 to 1 cm past what appears to be normal bone [34]. Treatment of both unicystic ameloblastomas and ameloblastic fibromas consists of enucleation [33]. Simple curettage is usually met with recurrence. It has been reported that pediatric ameloblastomas are generally unicystic and do not extend beyond the cystic wall of the tumor cell. [30] This type of tumor has a much better prognosis (Figure 2).

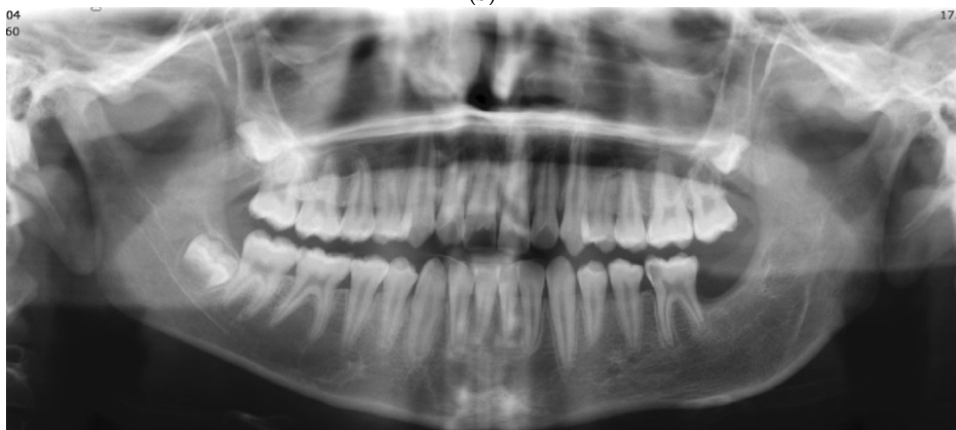Early diagnosis is the most important component of therapy for this odontogenic tumor, which does not have specific radiographic features in the early stages. In particular, unilocular ameloblastoma may be difficult to diagnosis for the surgeon. Surgical enucleation with bony curettage and intra-operative cryostat examination of the lesion allows preservative treatment and reduction of the risk of relapse [35]. The loss of permanent teeth, removed during the surgical treatment, will require orthodontic-prosthetic rehabilitation when the patient reaches adult age. Peripheral ameloblastoma occurs in soft tissue outside and overlying the alveolar bone. This neoplasm arises from the basal layer of the surface epithelium or remnants of the dental lamina. It occurs most frequently in the fourth to sixth decade and has a slight male predilection. The mandible is affected twice as frequently as the maxilla. Seldom does this neoplasm exhibit any radiographic findings. Superficial erosion in the alveolar region is occasionally observed. The microscopic pattern of peripheral ameloblastoma is similar to that of central ameloblastoma; however, it lacks the invasiveness of its central counterpart. Most peripheral ameloblastomas are acanthomatous. This lesion can be confused with peripheral odontogenic fibroma because features of both lesions may be present. However, in the hands of an experienced oral pathologist the



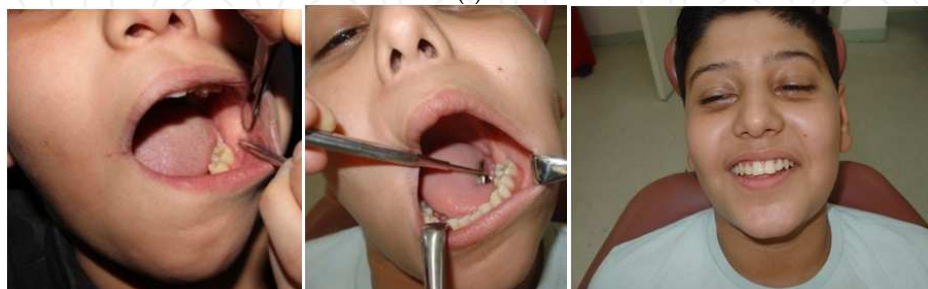(a)



(b)



(c)



(d)

Figure 2. (a): Ameloblastoma: Orthopantomograph of a 12-year-old boy who had a painless bony- hard swelling of the left mandible associated with cortical expansion. (b): Radiological appearance after surgical treatment. (c): Radiological appearance taken 24 months post-operatively. (d): Presurgery photographs showing the left mandible associated with cortical expansion and postoperative clinical control at 12 and 24 months

diagnosis is generally not difficult. Because this lesion is relatively innocuous, noninvasive, and displays little tendency for recurrence, it is treated by local excision. Despite its behavior, 1-year follow-up examinations are recommended [36, 37].

5.1.2. Squamous odontogenic tumor

The squamous odontogenic tumor (SOT) is a rare and benign neoplasm frequently located within the jaws. In 1975, Pullon et al. identified this entity and reported it for the first time in a series of 6 cases. This benign tumor has a slow and gradual growth that might invade the trabecular bone, destroying the cortical bone and infiltrating adjacent structures. Its aetiology remains unknown although it could be originated from the epithelial remnants of the Malassez. It usually appears over the lateral radicular surface of an erupted tooth and diminishes the height of alveolar bone causing tooth mobility. There is a similar entity that is characterized by squamous odontogenic tumor like proliferations (SOTLP) with a very similar histological pattern than the SOT. This lesion commonly is located in the wall of an odontogenic cyst and has a non-neoplastic character like in the SOT, representing probably, an hamartomatous lesion. [38]

5.1.3. Calcifying epithelial odontogenic tumor

The calcifying epithelial odontogenic tumor (CEOT) is a rare tumor. It was first described as a separate pathologic entity by a Dutch pathologist Jens Jorgen Pindborg in 1955. The term "Pindborg's tumor" was first used by Shafer and colleagues in 1963. CEOT is a rare benign odontogenic epithelial neoplasm representing about 0.4-3% of all odontogenic tumors. This tumor more frequently affects adults in the age range of 20-60 years, with a peak incidence in the 5th decade of life with equal sex predisposition. CEOT is a rarely seen odontogenic tumor in pediatric patients. It is a benign, but locally aggressive tumor; of all the odontogenic tumors, CEOT accounts for 1% of the cases. Approximately 200 cases have been reported to date. Although the tumor is clearly of odontogenic origin, its histogenesis is still uncertain. It usually involves the premolar-molar area of the mandible with about 50% cases associated with unerupted or embedded teeth. Etiology of this lesion is not clear. In the 113 cases reviewed by Franklin and Pindborg, patients ranged from 8 to 92 years with a mean age of 40 years. Radiographically, this tumor is often mistaken for a dentigerous cyst or ameloblastoma [39]. The diagnosis of CEOT is based on histological examination, revealing polyhedral neoplastic cells which have abundant eosinophilic, finely granular cytoplasm with nuclear pleomorphism and prominent nucleoli. Most of the cells are arranged in broad ramifying and anastomosing sheet-like masses with little intervening stroma. An extracellular eosinophilic homogenous material staining like amyloid is characteristic of this tumor with concentric calcified deposits, resembling psammoma bodies called "Liesegang rings. A painless, slow-growing swelling is the most common presenting sign. The differential diagnosis includes adenomatoid odontogenic tumor, calcifying odontogenic cyst, dentigerous cyst, ameloblastic fibro-odontoma and odontoma. It is an infiltrative neoplasm and causes destruction with local expansion. Definitive resection of the entire mass with tumor-free surgical margins (en bloc resection) is the preferred

treatment as tumor will recur if not completely removed. Long-term follow ups are recommended (Figure 3). Local recurrence rates of 10-15% have been reported [40]

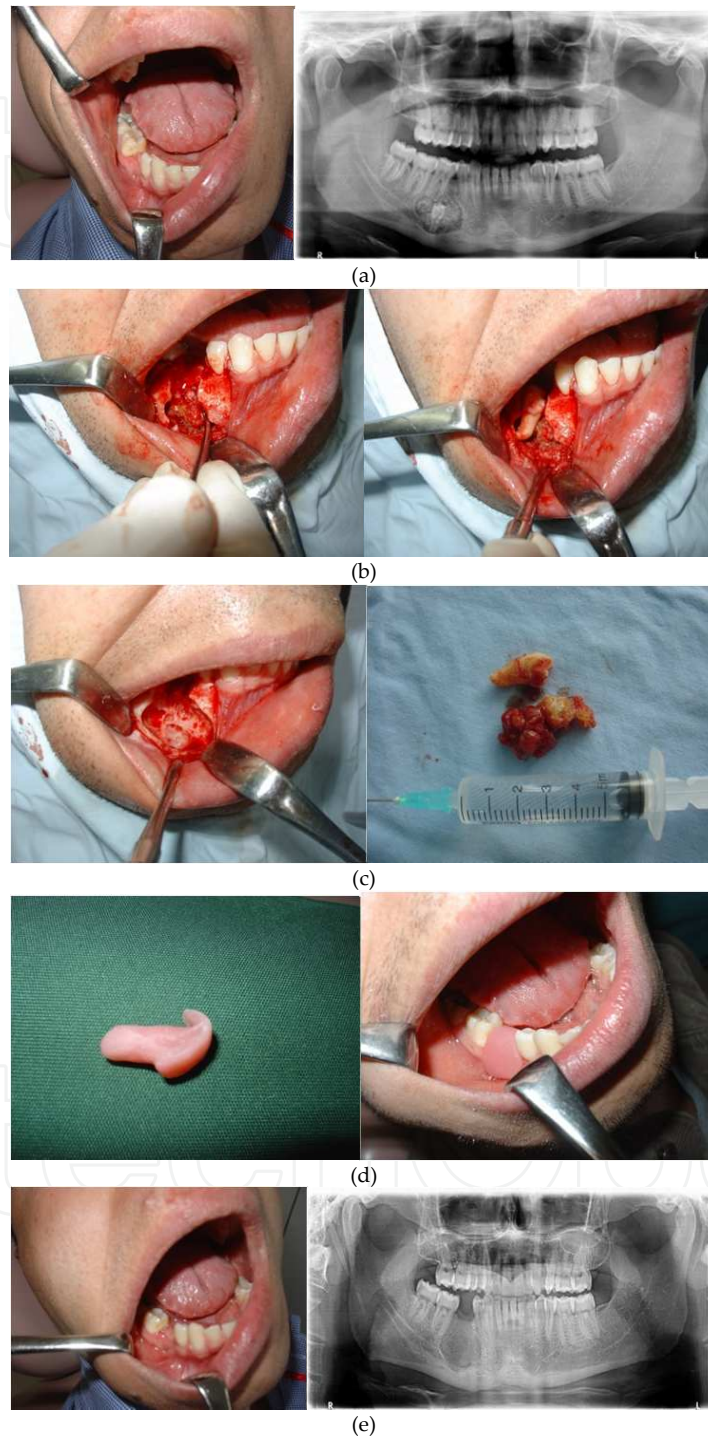


Figure 3. (a): Pindborg (CEOT) tumor associated with impacted premolar. Preoperative clinical (left) and radiological appearance of CEOT (right). (b): Clinical appearance of CEOT and impacted premolar tooth. (c): Postoperative operation site and macroscopic appearance of the mass. (d): Application of surgical obturator. (e): Postoperative clinical (left) and radiological control (right) at 12 months.

5.1.4. *Adenomatoid Odontogenic Tumor (AOT)*

This is a tumor mostly of teenagers. It occurs in the middle and anterior portions of the jaws in contrast to ameloblastoma which is found mostly in the posterior segment. Two-thirds occur in the maxilla and it is more common in females. The tumor may be partially cystic, and in some cases solid lesion may be present as masses in the wall of a large cyst. It is believed that lesion is not a neoplasm" Philipson et al. subdivided this condition into three groups referred to as follicular, extrafollicular, and peripheral. These variants have common histologic characteristics that indicate a common origin as derived from the complex system of dental lamina or its remnant [41]. The follicular and extrafollicular variants account for 96% of all AOT and of these 71% are follicular variants. The peripheral variant is the rarest with only 18 cases reported so far [42]. The follicular variant is predominantly associated with the crown and often part of the root of an impacted (unerupted) tooth (Figure 4). The most frequently associated tooth is the maxillary canine rarely the permanent molars. Based on the clinical and radiographic examination the follicular variant is often initially mistaken as dentigerous cyst. This tumor is encapsulated and is treated by curettage with a recurrence rate approaching zero. The radiographic appearance is a unilocular radiolucency, often around the crown of an unerupted tooth in which case they resemble a dentigerous cyst. A homogeneous, eosinophilic and amorphous material may occasionally be found in AOT [43]. If they are present in sufficient size and number, they may show on the radiograph as a "snow-flake" pattern

5.1.5. *Keratocystic odontogenic tumor*

The Keratocystic Odontogenic Tumor (KCOT) has been defined by the World Health Organization In 2005, as a benign intraosseous neoplasm of odontogenic origin with characteristic lining of parakeratinized squamous epithelium. It represents approximately 10 percent of all jaw cysts and may occur in a wide age range of patients. About 70 percent or more cases involve the mandible, especially in the molar, angle and ramus regions. The clinical features associated with the keratocystic odontogenic tumor show it to be a unilocular or multilocular radiolucency. It is generally believed that these lesions originate from remnants of the dental lamina in the same way as the primordial cyst. However, a tooth is generally not missing and, therefore, they are believed to originate from additional remnants of the lamina not involved in tooth formation. Alternatively, in some cases they may arise from the oral mucosa, particularly in the retromolar region, because daughter cysts are found between the oral mucosa and the cyst in the retromolar region [44].

Symptoms such as pain, swelling and drainage may be present, especially with larger lesions. However, at least half of all lesions are discovered as incidental radiographic findings. Due to the propensity of KCOTs to grow within the medullary bone, they have the potential to become extremely large without causing any clinical signs or symptoms. Radiographically, the KCOT presents as a well defined radiolucency with thin corticated margins. These tumors are normally diagnosed histologically from a sample of the lining. With simple enucleation, it seems that the recurrence rate may be from 25% to 60%. Approximately 20-40 percent of these tumors are associated with an unerupted tooth and can be identical in appearance to a dentigerous cyst (Figure 5). Root resorption is relatively uncommon. The classic treatment of

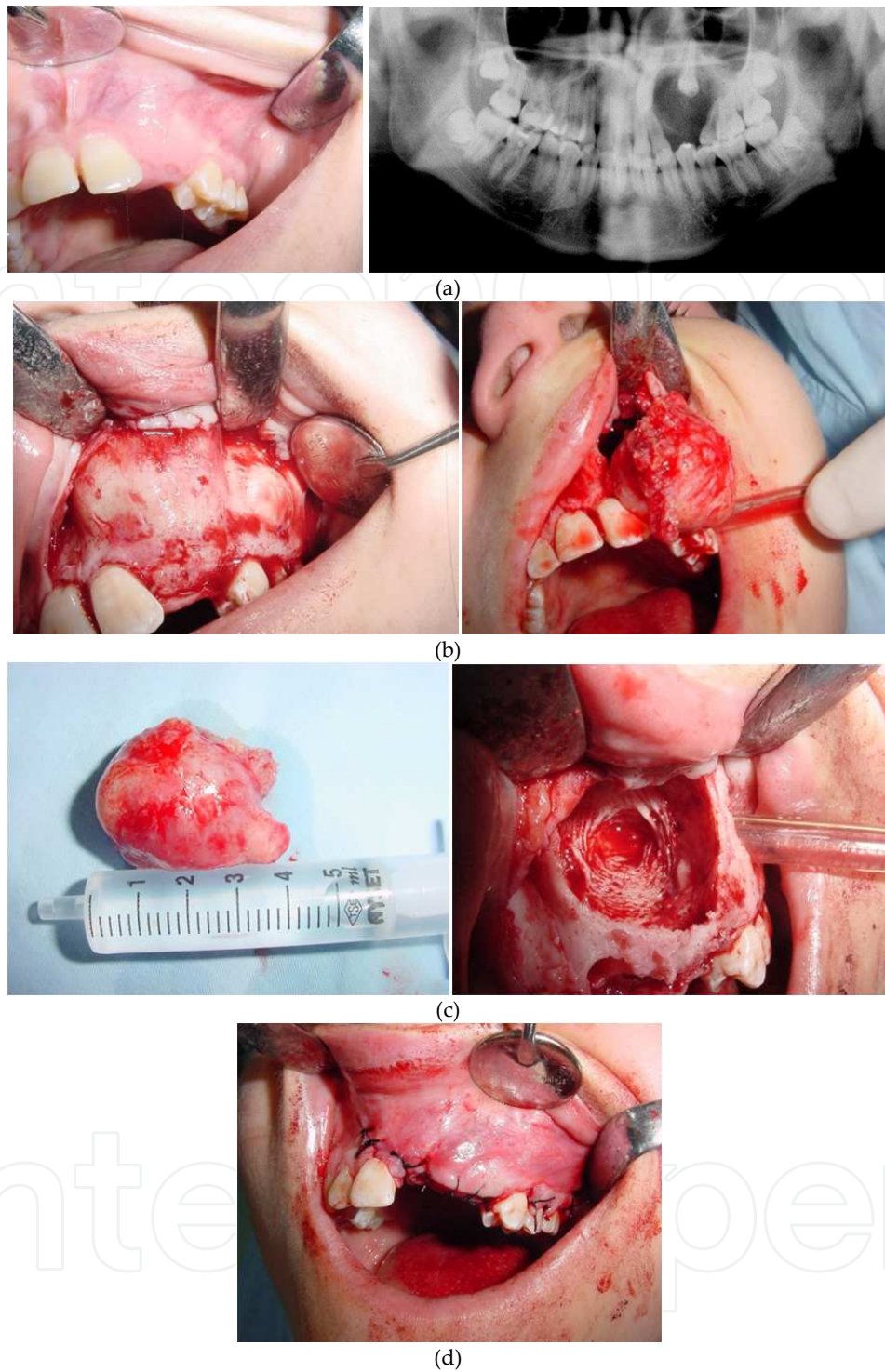


Figure 4. AOT associated with canine tooth. Oral photograph showing an anterior maxillary swelling in a 16-year-old girl. Preoperative radiological appearance of AOT. (b): Oral photograph showing large buccal anterior expansion. Clinical appearance of the mass being removed. (c): Clinical appearance of the encapsulated mass and the operation site after enucleation. (d): Postoperative appearance of the operation site

this lesion is surgical marsupialization, enucleation and curettage being performed through an intraoral approach. KCOTs have a high recurrence rate and develop more aggressively than

any other jaw cyst. Based on the high rate of recurrence, most authors advocate radical enucleation for small unilocular keratocysts and suggest resection and bone grafting for very large lesions. But there is a general agreement that complete removal of large multilocular KCOTs of the mandible ramus may be difficult because of the possibility that remnants of cystic tissue or that satellite microcysts may be left behind. Most authors have shown the successful treatment of large KCOTs using the technique of decompression and irrigation. The benefits of this protocol over more conventional approaches (enucleation, en bloc resection) lie in the minimal surgical morbidity. In addition, the associated structures such as the inferior alveolar nerve and developing teeth are less vulnerable to damage. Morgan et al. reported that treatment with Carnoy's solution did not show a significant association with recurrence. Most reports point out that recurrence will appear within the 5 to 7 years [45, 45].

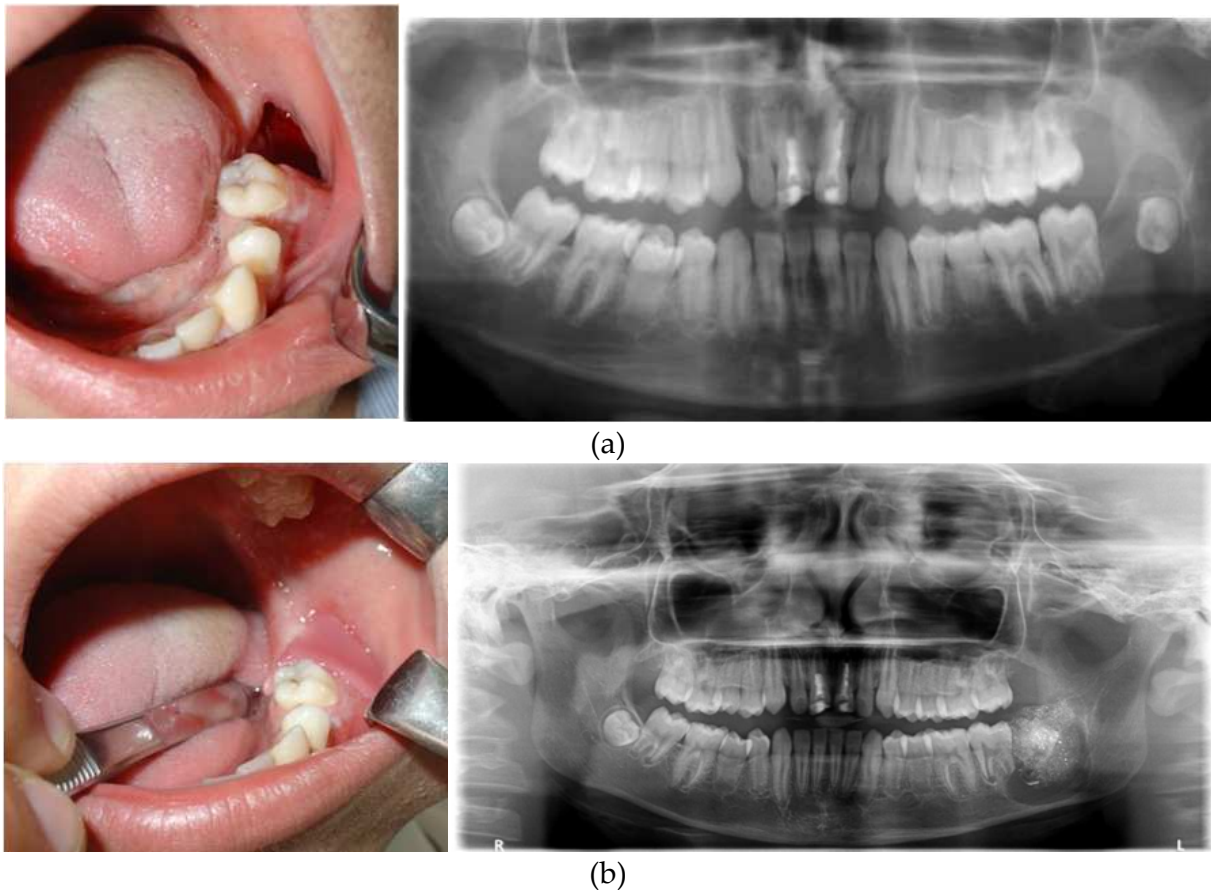


Figure 5. (a): KCOT. Frontal photograph and radiograph showing a 14-year-old boy presenting a posterior mandibular radiolucency associated with impacted left third molar. (b): Oral and radiographic appearance of the operated area with gauze tamponade after cystostomy and application of the surgical obturator.

5.2. Odontogenic epithelium with odontogenic ectomesenchyme, with or without hard tissue formation

5.2.1. *Ameloblastic fibroma*

This tumor, at least conceptually, is a compound odontoma and which includes the ameloblastic fibrodentinoma, ameloblastic odontoma and complex odontoma [46]. All show evidence of inductive interaction between odontogenic epithelial and ectomesenchymal components, but only the ameloblastic fibroma lacks hard tissue formation. The ameloblastic fibroma presents as a jaw swelling and multilocular radiolucency in the lower premolar or molar region or, less commonly, in the maxilla. This is a tumor of childhood, the typical patient is about 12–14 years old, seldom is it seen beyond age 20 yrs. The posterior segment of the mandible is the most common location. Local swelling or failure of teeth to erupt on time or in proper alignment may call attention to the tumor. Ameloblastic fibromas are purely radiolucent. Small lesions may be unilocular but larger lesions are ordinarily multilocular. Both odontogenic epithelium and odontogenic ectomesenchyme contribute to this tumor (an odontogenic mixed tumor not to be confused with the mixed tumor of the salivary gland). The epithelium grows in small islands and cords. This tumor is clearly benign and is ordinarily treated by vigorous curettage. The recurrence rate is placed at about 15%. Even though this tumor is comprised of both odontogenic epithelium and odontogenic ectomesenchyme, it does not secrete either enamel matrix or dentin. Its microscopic structure like its radiographic appearance, is reminiscent of that of the ameloblastoma, but with two major differences: the connective tissue component resembles dental papilla; and the stellate reticulum zone of the epithelium is poorly developed. The ameloblastic fibroma poses two further problems: for the histopathologist, it must be distinguished from a developing complex odontoma; and for the surgeon, the requirement for complete excision must be weighed against the need to preserve the developing jaw bones and dentition [40].

5.2.2. *Ameloblastic fibrodentinoma and Ameloblastic fibro-odontoma*

Ameloblastic fibrodentinoma (AFD) and ameloblastic fibroodontoma represent, at least for didactic purposes, intermediate stages between the ameloblastic fibroma and the complex odontoma. They also represent the interface between hamartomas and neoplasms, and occur in late adolescence or in early adulthood. A classic site for the formation of an ameloblastic fibrodentinoma is within, or adjacent to, the follicle of an unerupted tooth, typically a lower third molar, in its path of eruption. Most often it presents as a symptomless radio-opacity and may not be the cause of the failure of the underlying tooth to erupt (Figure 6). The ameloblastic fibro-odontoma is a more variable entity and, as already noted, may be hard to distinguish, clinically, radiographically and histopathologically, from a developing complex odontoma or ameloblastic fibroma. The majority of ameloblastic fibro-odontomas are small, mixed radio-opaque/radiolucent lesions that occur across a similar age-range to the ameloblastic fibrodentinoma, and most are small and unilocular with limited growth potential after completion of tooth formation. They show features that suggest the formation of tooth-like structures, complete with tubular dentine and varying degrees of enamel matrix calcification. That this is

not a developing odontoma is suggested by its perceived continued growth potential (hence the belief that at least some are true neoplasms) and its presentation at an age when odontomes have normally “matured” and become quiescent, as well as incorporating an extensive soft tissue (radiolucent) component that somewhat resembles ameloblastic fibroma [40, 46]. A regular follow-up protocol should be established to rule out any evidence of recurrence and malignant transformation. A detailed study is required in order to understand the relationship of AFD and related lesions, their biological behavior and management strategies [47].

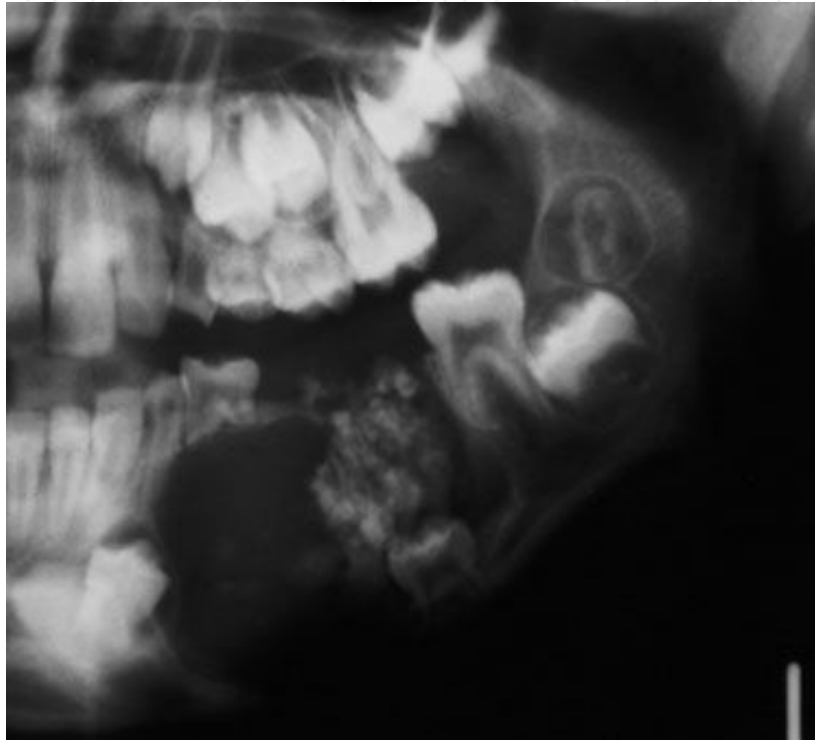


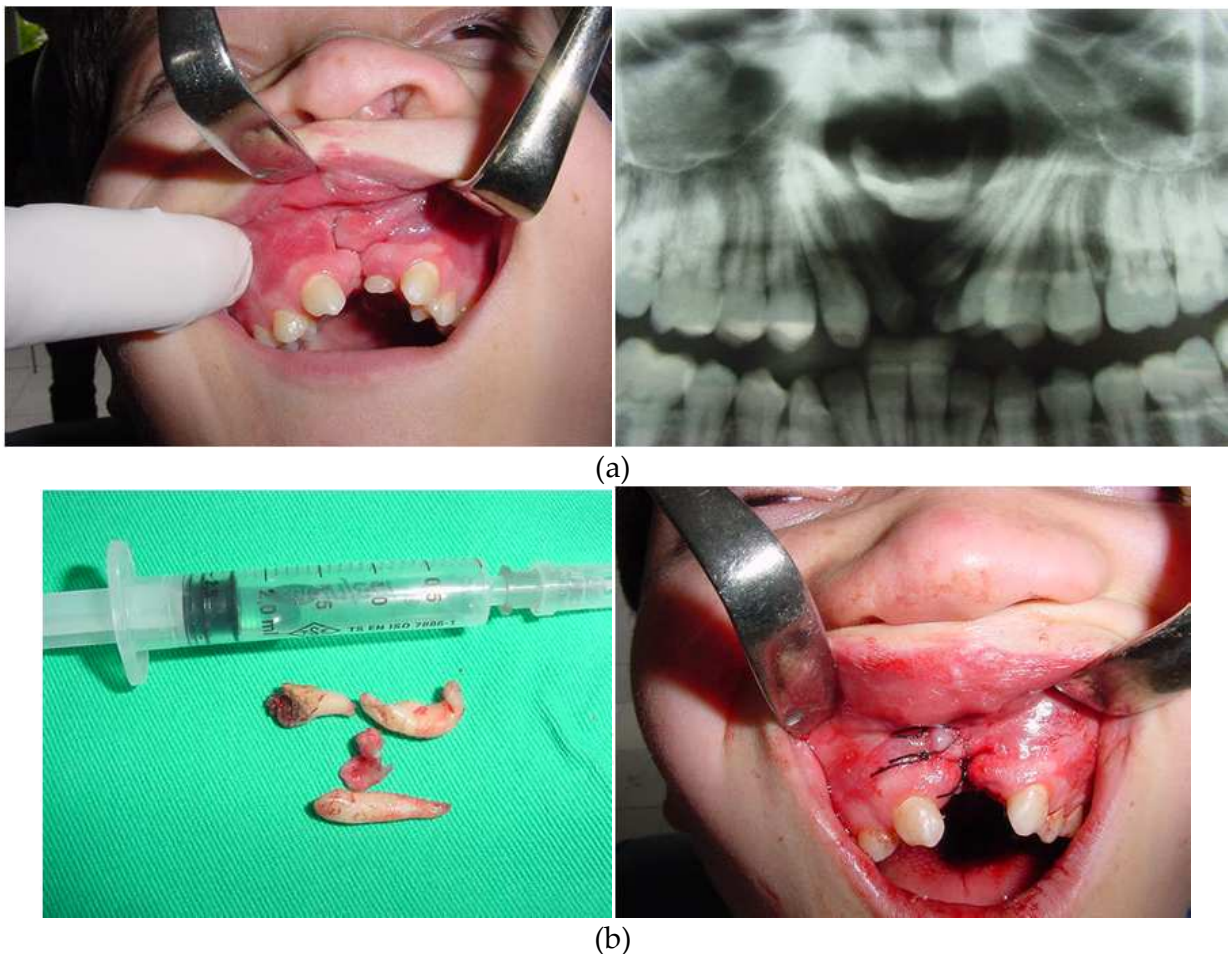
Figure 6. Ameloblastic fibro-odontoma. This combines the radio-opaque component that resembles a complex odontoma with radiolucent soft tissue that histologically combines the features of ameloblastic fibroma with the early stages of tooth germ development.

5.2.3. *Odontoma*

- **Odontoma, complex type**
- **Odontoma, compound type**

Odontomas are hamartomas of aberrant tooth formation, which occur due to budding of extra-odontogenic epithelial cells or detachment of odontogenic cells from the dental lamina [48]. These odontogenic cells may in turn differentiate and deposit enamel, dentine, cementum or pulp in the form of multiple teeth like structures (compound odontoma), amorphous calcified masses (complex odontoma) or a combination of both (composite odontoma and compound-complex odontoma). Trauma to the tooth bud during its early developmental stages has been proposed as a possible predisposing factor for the origin of odontoma. [49,50].

As a result, these tumors are mostly radiodense. In the compound odontoma, multiple small and malformed tooth-like structures are formed creating a “bag of marbles” radiographic appearance. In the complex odontoma, there is little or no tendency to form tooth-like structures. The dentin and enamel are entwined in a mass that bears no resemblance to teeth. Both types of odontoma are found in the early years, usually in the teens or early twenties. Compound odontoma is more common in the anterior jaw segment whereas the complex type is found more commonly in the posterior jaws (Figure 7). Many are associated with an unerupted tooth. Odontomas behave more like developmental abnormalities (hamartomas) than true neoplasms. Although they may reach a large size, they do eventually cease growing in contrast to true neoplasms which show continuous growth. Treatment is elective surgery. They have a limited growth potential and cause no pain or cosmetic deformity [46].



NOTE: We have skipped odontoameloblastoma, calcifying cystic odontogenic tumor, dentinogenic ghost cell tumor, malignant ameloblastoma, ameloblastic carcinoma, clear cell odontogenic carcinoma because they are exceedingly rare.

Figure 7. a): Compound odontoma associated with two mesiodens. Photograph and radiograph showing a 11-year-old boy presenting an anterior maxillary radiolucency with impacted supernumerary teeth and radio-opaque mass. (b): Macroscopic appearance of the supernumerary teeth and postoperative operation site

5.3. Mesenchyme and/or odontogenic ectomesenchyme with or without odontogenic epithelium

5.3.1. Odontogenic fibroma

Central odontogenic fibromas are encountered as unilocular radiolucencies that turn out to be solid, rather than cystic, following enucleation. They are rare, far rarer for example than ameloblastomas, and arise usually anterior to the molars, more commonly in the maxilla and mainly in women, as a small, well-circumscribed radiolucency that may cause resorption and/or displacement of adjacent vital teeth (Figure 8). A wide age-range is noted among the relatively few reported cases, and a scalloped radiographic margin may denote a more aggressive behavior pattern. Following enucleation, most odontogenic fibromas do not recur, although there have been occasional reports of some following a more aggressive course; however, there seems to be little correlation with the histological pattern [40, 46]

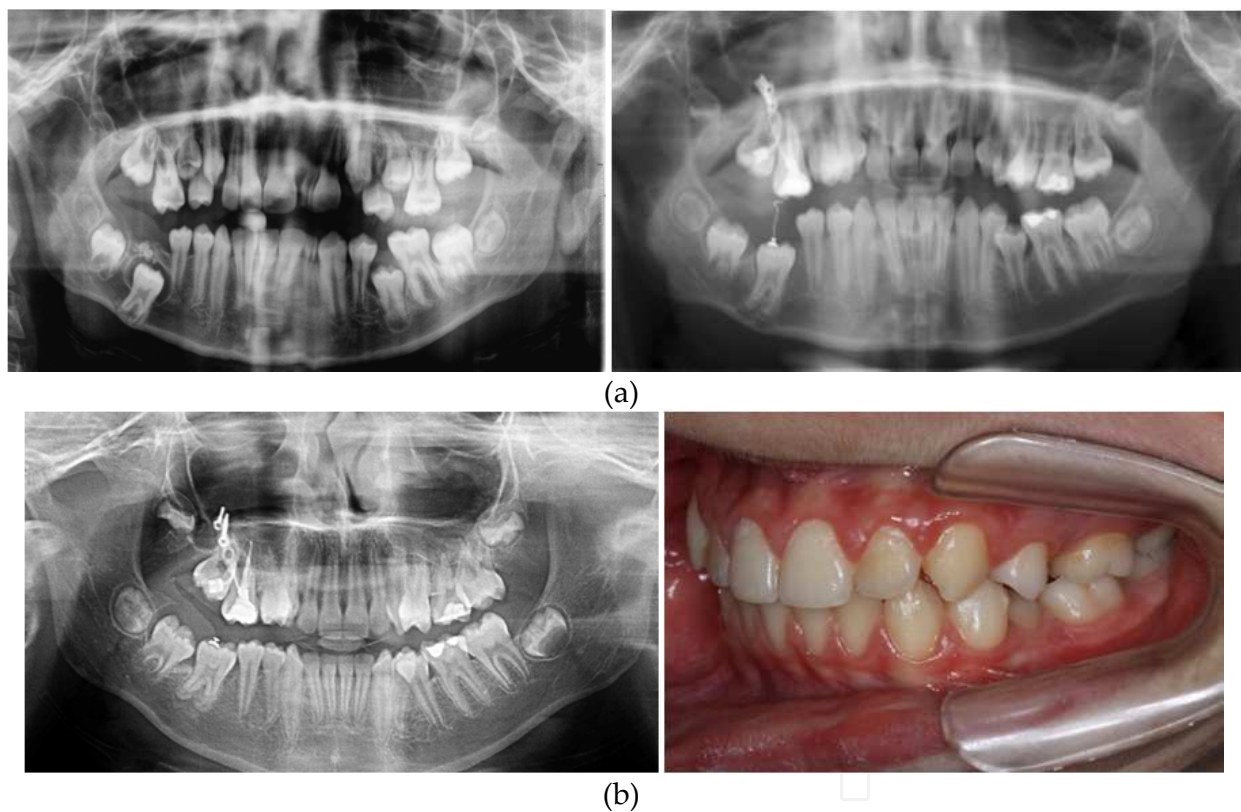


Figure 8. (a): Odontogenic fibroma. Radiograph showing a 12-year-old boy presenting with a posterior mandibular mass associated with an impacted left first molar tooth. (b): Orthodontic extrusion of the impacted first molar using the zygomatic bone anchor and clinical appearance after the right first molar extrusion

5.3.2. Odontogenic myxoma/myxofibroma

Despite the name similarity, the odontogenic myxoma is quite a different entity from the odontogenic fibroma in almost all respects. Odontogenic myxoma (OM) of the jaws, first

described by Thoma and Goldman in 1947, is believed to arise from odontogenic ectomesenchyme [51, 52]. It is a rare benign tumor characterized grossly by mucoid or gelatinous grayish-white tissue that replaces the cancellous bone and expands the cortex. OMs are locally invasive, non-metastasizing neoplasms of the jaws, almost exclusively seen in tooth-bearing areas. It accounts for 0.2-17.7% of odontogenic tumors. It predominantly involves the mandible and maxillary tumors are known to be more aggressive than tumors involving the mandible [53]. Most frequently, OMs occur in the 2nd and 3rd decades of life. Cortical expansion and perforation are common findings; however, maxillary myxomas often extend into the sinus [54]. Radiographically, the tumor presents as a unilocular or multilocular radiolucent lesion with fine, bony trabeculae within its interior structure expressing a honeycombed, soap bubble, or tennis racket appearance [55]. A histologic characteristic of this tumor resembles the mesenchymal portion of a tooth in development. The lesion is not encapsulated being characterized by the proliferation of a few rounded cells, fusiforms and star cells, being included in abundant myxomatous stroma with a few collagen fibers [56]. They are uncommon. Extragnathic skeletal lesions are a rarity. Since it does not produce a calcified matrix material, it is purely radiolucent. If allowed to reach a large size, it takes a big operation to remove it [40].

5.3.3. Cementoblastoma

Cementoblastoma in the current World Health Organization classification of odontogenic tumors, is in the category of tumors of mesenchyme and/or odontogenic ectomesenchyme with or without odontogenic epithelium [57]. The lesion was first recognized by Noeberg in 1930 [58]. The lesion is considered as the only true neoplasm of cementum origin. It generally occurs in young persons, comprises <1-6.2% of all odontogenic tumors and is characterized as being attached to the roots, most frequently associated with first permanent molars [59]. The differential diagnosis for a periapical radiopacity include cementoma, osteoblastoma, periapical cemental dysplasia, condensing osteitis and hypercementosis. The majority of these tumors are radiopaque, but a radiolucent tumor may occur in rare instances. Histologically, it presents as a well-circumscribed tumor composed of cementum like tissue surrounded by a fibrous capsule. Surgical enucleation of the cementoblastoma with the associated tooth is usually curative, although recurrences have been reported following incomplete excision. The recurrence rate is 21.7-37.1% [60, 61].

5.4. Bone-related (Fibro-osseous) lesions

5.4.1. Juvenile ossifying fibroma

Benign fibro-osseous lesions of the head and neck region are uncommon and constitute a wide range of tumors sharing some histopathological features. This group includes developmental, reactive or dysplastic lesions as well as neoplasm such as fibrous dysplasia (FD), ossifying fibroma (OF), and cemento-osseous dysplasia (COD) [62]. Ossifying fibromas are rare benign, neoplasms arising from undifferentiated cells of the periodontal ligament tissues (63). These have been described as demarcated or rarely encapsulated

neoplasms consisting of fibrous tissue containing varying amounts of mineralized material resembling bone and/or cementum which is one of its principal characteristics [64]. In 1872, Menzel first described ossifying fibroma, but in 1972, Montgomery assigned terminology to it. It accounts for 3.1% of all oral tumors and for 9.6% of all gingival lesions. There are two types of ossifying fibroma, central and peripheral. The central type arises from the endosteum or periodontal ligament adjacent to the root apex and expands from the medullary cavity of the bone. The peripheral type occurs solely on the soft tissue overlying the alveolar process. Trauma or local irritants are known to precipitate the development of this lesion [65]. It is common in young adults (especially, 2nd and 3rd decades) with a female predominance and is generally asymptomatic until the growth produces a noticeable swelling most often found in interdental gingiva, located anterior to molars and in the maxilla [66]. The suggested etiology although unknown has been associated with inflammatory hyperplasia of the periodontal ligament [67]. When ossifying fibroma is diagnosed in young people the term "juvenile" is used. The accurate nature and classification of JOF has undergone considerable debate among pathologists, resulting in a confusing evolution of competing nomenclatures [68]. According to the WHO classification of odontogenic tumors 2005, JOF is further subdivided into two distinct clinic-pathological variants i.e., juvenile psammomatoid ossifying fibroma (JPOF) and juvenile trabecular ossifying fibroma (JTOF) [69]. Juvenile psammomatoid ossifying fibroma (JPOF) is a rare fibro-osseous neoplasm that arises within the craniofacial bones in individuals under 15 years of age, and these lesions are usually benign and tend to grow slowly. JPOF is a rare fibro-osseous neoplasm. Probability of malignancy makes this lesion worrisome. The lesion is nonencapsulated but well demarcated from surrounding bone. JPOF mainly involves the bones of the orbit and paranasal sinuses, whereas the trabecular type commonly involves the jaws. JPOFs are rare, benign, potentially aggressive fibro-osseous tumors of the craniofacial bones characterized by the presence of numerous calcified spherules within an actively proliferating connective tissue stroma. They are mainly seen in the sino-naso-orbital region of young individuals. Males and females are equally affected. The maxilla and the mandible are the dominant sites of incidence. Occurrence in the maxilla is slightly more frequent than in the mandible (Figure 9). The incidence of JPOF is still unknown because of relatively few cases reported till date. The pathogenesis of JPOF jaw lesions are related to the maldevelopment of basal generative mechanism that is essential for root formation. The developing tooth can either be displaced, missing or remain unerupted. It tends to occur at younger age group and is locally aggressive and these characteristics make them different from conventional ossifying fibroma and other fibro-osseous lesions. Moreover, this lesion may clinically manifest with rapid painless expansion of the affected bone as an aggressive lesion mimicking malignancy such as osteosarcoma. JPOF can be easily excluded from malignant bone tumors on the routine histological examination. Additionally, it may be difficult to distinguish JPOF from other fibro-osseous lesions because of the overlapping features. It is important to accurately recognize JPOF for reaching the diagnosis and treatment planning. Because of this lesion's aggressive nature and high recurrence rate, early detection and complete surgical excision are essential [40, 46].

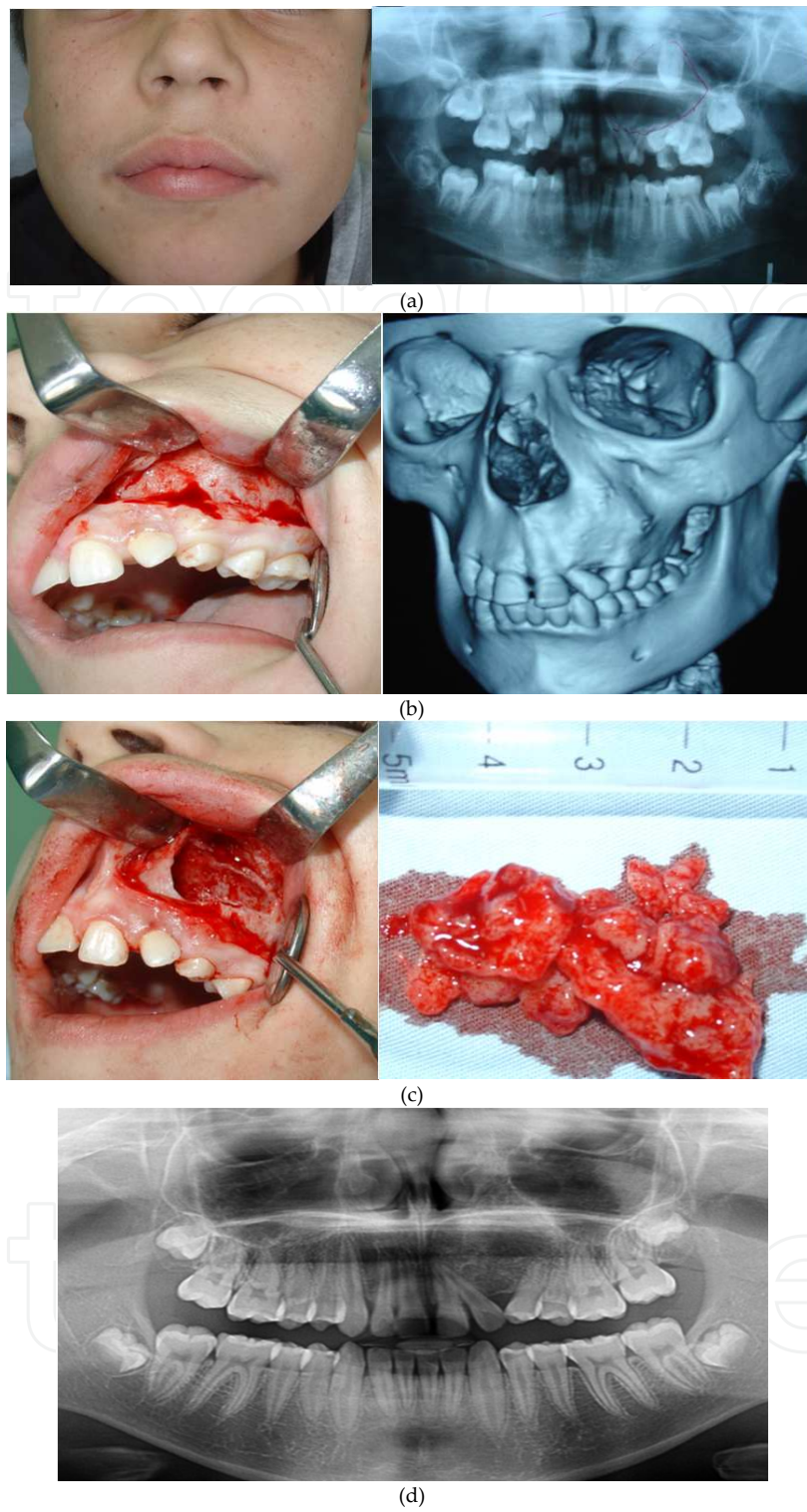


Figure 9. (a): JPOF. Photograph showing a 14-year-old boy presenting an anterior maxillary expansion associated with impacted left canine tooth ; Preoperative facial view showing asymmetry of face (left); Preoperative radiograph showing large radiolucency, well-defined sclerotic border around the upper left impacted canine tooth (right). (b): Clinical and radiographical appearance of buccal cortical expansion. (c): Clinical appearance after enucleation and the mass. (d): Postoperative panoramic radiograph showing normal bone pattern

5.4.2. Central giant cell granuloma

There are a number of lesions that occur in the jaws that contain giant cells within them. They include cherubism, giant cell granuloma of the jaws, giant cell tumor, aneurysmal bone cyst, traumatic bone cyst and brown tumor of hyperparathyroidism. Their relationship to each other, however, is ill defined. The histological similarities with the finding of multinucleated giant cells of osteoclastic origin and the lesions themselves greatly differ in their genetic origin, etiopathogenesis and clinical behaviour. Central giant cell granuloma (CGCG) is fairly common in the jaws and it is a nonneoplastic bone disease, probably reactive to some unknown stimulus. CGCG constitutes approximately 7% of the benign jaw tumors. Usually, it occurs in patients 30 years of age or younger with painless swelling and an asymmetry in facial appearance. The clinical behavior of CGCG ranges from a slowly growing asymptomatic lesion to an aggressive lesion manifesting with pain, local bone destruction, root resorption, or displacement of teeth. The highest rate of occurrence is the mandible, and most mandibular lesions occur anterior to the first molars.

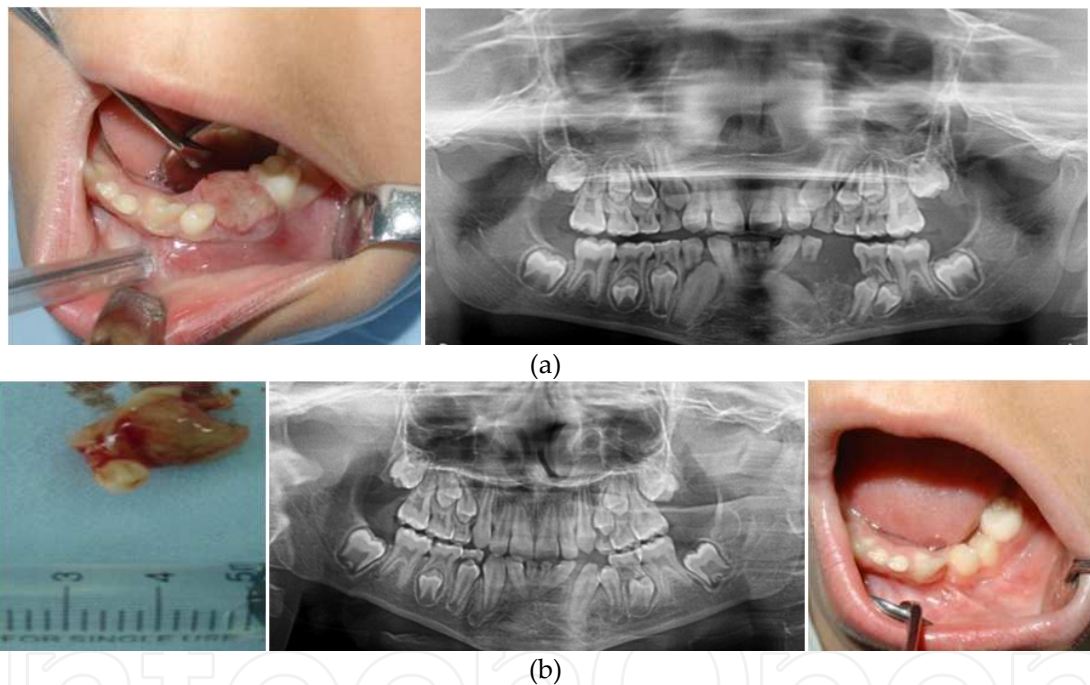


Figure 10. (a). CGCG: Photograph showing a 13-year-old boy presenting a posterior mandibular lesion at premolar region (a): Preoperative facial view showing ulcerative mass (left): Preoperative radiograph showing the lesion. (b): Excised pathologic mass associated with tooth ; Postoperative panoramic radiograph showing normal bone pattern. Clinical view taken 13 months post-operatively

Its etiology is still unknown and its biological behavior is poorly understood. This lesion occurs almost exclusively within the jaw bones. It usually presents as a painless swelling of the jawbone. Radiographically, CGCG presents as radiolucent defect, which may be unilocular or multilocular. The defect usually is well-circumscribed and, in some cases, displacement of teeth can be found (Figure 10). Conventional treatment for the CGCG has been local curettage and this has been associated with a high success rate and low recurrence rate. The conservative surgical treatment of CGCG usually involves curettage alone or along with peripheral

ostectomy with no evidence of disease in a 2 year follow up period. The margins of the CGCG may also be thermally sterilized with a laser or a cryoprobe. Radical surgical techniques of resection without continuity defect, peripheral ostectomy and en-bloc resection have sometimes been justified for aggressive CGCG. Pediatric patients necessitate conservative management to prevent long term developmental defects. Steroids and calcitonin have been advocated recently for inhibition of osteoclastic activity. Equal parts of triamcinolone acetone (10mg/ml) and 0.5% bupivacaine injected into the lesion for a period of 11 weeks has been shown to be effective in a child patient. Relative contraindications do exist in certain medical conditions, such as diabetes mellitus, peptic ulcer and generalized immunocompromised states. Calcitonin nasal spray 200 U/spray once or twice daily was reported to be safe and effective for the treatment of CGCG [40,46].

6. Conclusion

Literature reveals very few reported studies involving pediatric pathologies and there are different treatment modalities for pediatric jaw tumors in the recent literatures. Many surgeons find it difficult to decide which technique offers better results, and are also uncertain about the factors which might influence their techniques of choice. The rapid growth and development process in childhood and adolescence affects the growth potential of tumors and tumor like lesions and occasionally results in considerable morbidity. There are many rare odontogenic tumors that may involve the head and neck in the pediatric population. Each of them deserves careful attention by a multidisciplinary tumor board that includes pediatric oncologists, radiation oncologists, dentists, and surgeons. Clinicians need to keep abreast of the various intraosseous lesions with their presenting signs and symptoms, so that the patient can be treated without any delay and avoiding unnecessary administration of antibiotics. Subsequent to an unresponsive antibiotic therapy radiographs are taken to reveal a radiolucent or radiodense lesion in the jaws. As a consequence the contribution of pathological examination remains imperative in odontogenic cyst or tumor diagnosis. It is very important to consider surgical and permanent dental concerns during jaw tumor treatment planning. Facial growth and aesthetic results should be considered in the surgical planning.

Author details

Mehmet Cemal Akay^{1*}, Mert Zeytinoglu¹, Birant Şimşek¹ and Işıl Aras²

*Address all correspondence to: cemalakay@yahoo.com

1 Ege University, Faculty of Dentistry, Department of Oral and Maxillofacial Surgery, Bornova, Izmir, Turkey

2 Ege University, Faculty of Dentistry, Department of Orthodontics, Izmir, Turkey

References

- [1] Pindborg, JJ. & Kramer, IRH. (1971) Histological typing of odontogenic tumours, jaw cysts, and allied lesions (International Histological Classification of Tumours No. 5). Geneva World Health Organization
- [2] Taylor, AM. (2008) New findings and controversies in odontogenic tumors. *Med Oral Patol Oral Cir Bucal*. Sep1; 13(9): E555-8.
- [3] Slootweg, PJ., Van den Bos, T.& Straks, W. (1985) Glycosaminoglycans in myxoma of the jaw: a biochemical study. *J Oral Pathol*. Apr;14(4):299-306.
- [4] Ulmansky, M., Lustmann, J.& Balkin, N. (1999) Tumors and tumor-like lesions of the oral cavity and related structures in Israeli children, *Int J Oral Maxillofac Surg*. Aug; 28(4):291-4.
- [5] Barnes, L., Eveson, JW., Reichart, P.& Sidransky, D. (2005) (editors). World Health Organisation classification of tumours. Pathology and genetics of head and neck tumours. Lyon: IARC Press, p. 283-328.
- [6] Philipsen, HP. & Reichart, PA. (2006) Classification of odontogenic tumours. A historical review, *Oct;35(9):525-9*.
- [7] Tawfik, MA. & Zyada, MM. (2010) Odontogenic tumors in Dakahia, Egypt: analysis of 82 cases. *Oral Surg Oral Med Oral Pathol Oral Radiol Endod* 109: e67–e73.
- [8] Eversole, R., Su, L.& ElMofty,S. (2008) Benign fibro-osseous lesions of the craniofacial complex. A review. *Head Neck Pathol*. Sep;2(3):177-202.
- [9] Cunningham, MJ., Myers,EN.& Bluestone, CD. (1987) Malignant tumors of the head and neck in children: a twenty-year review. *Int J Pediatr Otorhinolaryngol*. Oct;13(3): 279-92.
- [10] Jones, AV.& Franklin, CD. (2006) An analysis of oral and maxillofacial pathology found in children over 30-year period. *International Journal of Paediatr Dent*. 16:19-30.
- [11] Choung, R.& Kaban, LB. (1985) Diagnosis and treatment of jaw tumours in children. *J Oral Maxillofac Surg*. 43: 323-332.
- [12] Steliarova-Foucher, E., Stiller, C., Lacour, B.& Kaatsch, P. (2005) International Classification of Childhood Cancer, third edition. *Apr 1;103(7):1457-67*.
- [13] Tanaka, N., Murata, A., Yamaguchi, A.& Kohama, G. (1999) Clinical features and management of oral and maxillofacial tumors in children. *Oral Surg Oral Med Oral Pathol*. Jul;88(1):11-5.

- [14] Tanrikulu, R., Erol, B.& Haspolat, K. (2004) Tumors of the maxillofacial region in children: retrospective analysis and long-term follow-up outcomes of 90 patients. *Turk J Pediatr.* Jan-Mar;46(1):60-6.
- [15] Rapidis, AD., Economidis, J., Goumas, PD., Langdon, JD., Skordalakis, A., Tzortzotou, F., Anagnostopoulos, D.& Matsaniotis, N. (1988) Tumours of the head and neck in children. A clinico-pathological analysis of 1,007 cases. *J Craniomaxillofac Surg.* Aug;16(6):279-86.
- [16] Willging JP. (2000) Head and Neck Masses in Children. American Academy of Otolaryngology Annual Meeting, Washington, D.C. September.
- [17] Mullapudi, SV., Putcha, UK.& Boindala S. (2011) Odontogenic tumors and giant cell lesions of jaws--a nine year study. *World Journal of Surgical Oncology.* Jul 5;9:68.
- [18] Slavkin, HC., Cummings, E., Bringas, P. & Honig, LS. (1982) Epithelial-derived basal lamina regulation of mesenchymal cell differentiation. *Prog Clin Biol Res.* 1982;85 pp: 249-59.
- [19] Badger, KV.& Gardner, DG. (1997) The relationship of adamantinomatous cranio-pharyngioma to ghost cell ameloblastoma of the jaws: a histopathologic and immunohistochemical study. *J Oral Pathol Med.* Sep;26(8):349-55.
- [20] Alam, K., Khan, R., Jain, A., Maheshwari, V., Agrawal, S., Chana, RS.& Harris, SH. (2009) The value of fine-needle aspiration cytology in the evaluation of pediatric head and neck tumors. *International Journal of Pediatric Otorhinolaryngology* Jul; 73(7):923-7.
- [21] Crivelini, MM., de Araújo, VC., de Sousa, SO. & de Araújo, NS. (2003) Cytokeratins in epithelia of odontogenic neoplasms. *Oral Dis.* Jan;9(1):1-6.
- [22] Kumamoto, H., Kimi, K. & Ooya, K. (2001) Detection of cell cycle-related factors in ameloblastomas. *J Oral Pathol Med.* May;30(5):309-15.
- [23] Coleman, H., Altini, M., Ali, H., Doglioni, C., Favia, G.& Maiorano, E. (2001) Use of calretinin in the differential diagnosis of unicystic ameloblastomas. *Histopathology.* Apr;38(4):312-7.
- [24] DeVilliers, P., Liu, H., Suggs, C., Simmons, D., Daly, B., Zhang, S., Raubenheimer, E., Larsson, A. & Wright T. (2008) Calretinin expression in the differential diagnosis of human ameloblastoma and keratocystic odontogenic tumor. *Am J Surg Pathol.* Feb; 32(2):256-60.
- [25] Gao, YH., Yang, LJ.& Yamaguchi, A. (1997) Immunohistochemical demonstration of bone morphogenetic protein in odontogenic tumors. *J Oral Pathol Med.* Jul;26(6) : 273-7.

- [26] Kumamoto, H. & Ooya K. (2006) Expression of bone morphogenetic proteins and their associated molecules in ameloblastomas and adenomatoid odontogenic tumors. *Oral Dis.* Mar;12(2):163-70.
- [27] Sato, M., Tanaka, N., Sato, T. & Amagasa, T. (1997) Oral and maxillofacial tumours in children: a review. *Br J Oral Maxillofac Surg.* 63:92-5.
- [28] Regezi, J.& Sciubba, J. (1993) Odontogenic tumors. In: Regezi J, Sciubba J editor. *Oral Pathology.* ed 2. Philadelphia, PA: Saunders; p. 362–397.
- [29] Jaffe, BF. (1973) Pediatric head and neck tumors: a study of 178 cases. *Laryngoscope* Oct;83(10):1644-51.
- [30] Feinberg, SE.& Steinberg, B. (1996) Surgical management of ameloblastoma. *Oral Surg Oral Med Oral Pathol Oral Radiol Endod.* 81:383-8.
- [31] Ramesh, V., Singh, S., Bailwad, SA., Kiran, K., Agarwal, RK. & Singh A. (2014) The Complexity of Stromal Changes in Desmoplastic Ameloblastoma. *Ann Med Health Sci Res.* Mar-Apr; 4(Suppl 1): S14–S17.
- [32] Peter, AR.& Philipsen, HA. (2000) *Odontogenic tumors and allied lesions*, London: Quintessence, pp.43–58.
- [33] Troulis, MJ., Williams, WB.& Kaban, LB. (2004) Staged protocol for resection, skeletal reconstruction, and oral rehabilitation of children with jaw tumors. *J Oral Maxillofac Surg.* Mar;62(3):335-43.
- [34] Vohra, FA., Hussain, M., Mudassir, MF. & Mudassir, MS. (2009) Ameloblastomas and their management: A review *Journal of Surgery Pakistan* 14(3):136–52.
- [35] Asamo, EA., Ayanlere, AO., Olaitan, AA.& Adekeye, EO. (1990) Paediatric tumours of the jaws in northern Nigeria. *Clinical presentation and treatment.* Apr;18(3):130-5.
- [36] Simpson, HE. (1974) Basal-cell carcinoma and peripheral ameloblastoma. *Aug;38(2):* 233-40.
- [37] Gold, L. (1991) Biologic behavior of ameloblastoma. *Oral Maxillofac Surg Clin N Am.* 3:21–71.
- [38] Sala-Pérez, S., Marco-Molina, V.& Gay-Escoda, C. (2013) Squamous odontogenic tumor-like proliferation in a radicular cyst: A case report. *J Clin Exp Dent.* Dec 5(5): e298-301.
- [39] Lee, SK.& Kim YS.(2014) Current Concepts and Occurrence of Epithelial Odontogenic Tumors: II. Calcifying Epithelial Odontogenic Tumor Versus Ghost Cell Odontogenic Tumors Derived from Calcifying Odontogenic Cyst. *The Korean Journal of Pathology* 48: 175-187.
- [40] Morgan, PR. (2011) Odontogenic tumors: a review. *Periodontology* 2000, Oct;57(1): 160-76.

- [41] Philipsen, HP.& Reichart, PA. (1991) Adenomatoid odontogenic tumour: facts and figures. *Oral Oncology*, 35(2),pp.125–131.
- [42] Philipsen, HP., Reichart, PA., Zhang, KH., Nikai, H.& Yu, QX. (1991) Adenomatoid odontogenic tumor: Biologic profile based on 499 cases. *Journal of Oral Pathology and Medicine*, 20(4),pp.149–158.
- [43] Acharya, S. Goyal, A., Rattan, V., Vaiphei, K.& Bhatia, SK.(2014) Dentigerous Cyst or Adenomatoid Odontogenic Tumor: Clinical Radiological and Histopathological Dilemma. *Case Reports in Medicine*, Article ID 514720, 5 pages.
- [44] Arcuri, F., Grivetto, F., Poglio, G., Bruccoli, M.&Benech, A. (2011) Simultaneous palatal pleomorphic adenoma and mandibular keratocystic odontogenic tumor in a pediatric patient. *J Craniofac Surg*. Nov;22(6):2347-50.
- [45] Hyun, HK., Hong, SD.& Kim, JW. (2009) Recurrent keratocystic odontogenic tumor in the mandible: a case report and literature review. *Oral Surg Oral Med Oral Pathol Oral Radiol Endod*. Aug;108(2):e7-10.
- [46] Pogrel, MA. (2013) *Clinical Pathology: Odontogenic and Nonodontogenic Tumors of the Jaws*. Chapter 23, pp 490-534.
- [47] Sankireddy, S., Kaushik, A., Krishna, BA., Reddy, AL., Vinod, VC.& Sridevi, V. (2013) Ameloblastic fibrodentinoma involving anterior maxilla: a rare case report. *J Indian Soc Pedod Prev Dent*. Oct-Dec;31(4):275-8.
- [48] Wood, NK., Goaz, PW.& Lenher, JF. (2006) Mixed radiolucent-radiopaque lesions associated with teeth. In: Wood NK, Goaz PW (eds), *Differential diagnosis of oral and maxillofacial lesions*, 5th edition, Mosby Co., St. Louis, 423–426.
- [49] Glasstone, S.(1952) The development of halved tooth germs; a study in experimental embryology, *J Anat*, 86(1):12–15.
- [50] Levy, BA. (1968) Effects of experimental trauma on developing first molar teeth in rats, *J Dent Res*, 47(2):323–327.
- [51] Neville, BW., Damm, DD., Allen, CM.& Bouquet, JE., (2010) editors. *Odontogenic cysts and tumors*. In: *Oral and Maxillofacial Pathology*. 3 rd ed. Philadelphia: WB Saunders; p. 678-740.
- [52] Noffke, CE., Raubenheimer, EJ., Chabikuli, NJ.& Bouckaert, MM. (2007) Odontogenic myxoma: Review of the literature and report of 30 cases from South Africa. *Oral Surg Oral Med Oral Pathol Oral Radiol Endod* 104:101-9.
- [53] Jaswal, A., Jana, AK., Biswas, M., Sikder, B.& Nandi, TK.(2008) Recurrent odontogenic myxoma of maxilla: A diagnostic and operative dilemma. *Indian J Otolaryngol Head Neck Surg* 60:41-4.
- [54] Singaraju, S., Wanjari, SP.& Parwani, RN.(2010) Odontogenic myxoma of the Maxilla: A report of a rare case and review of the literature. *J Oral Maxillofac Pathol*.4:19-23.

- [55] Sivakumar, G., Kavitha, B., Saraswathi, TR.& Sivapathasundharam, B. (2008) Odontogenic myxoma of maxilla. *Indian J Dent Res* ; 19:62-5.
- [56] Aquilino, RA., Tuji, FM., Eid, NL., Molina, OF., Joo, HY.& Neto, FH. (2006) Odontogenic myxoma in the maxilla: A case report and characteristics on CT and MR. *Oral Oncol Extra* 42:133-6.
- [57] Huber, AR.& Folk, GS. (2009) Cementoblastoma. *Head Neck Pathol.* 3:133-5.
- [58] Pynn, BR., Sands, TD.& Bradley, G. (2001) Benign cementoblastoma: A case report. *J Can Dent Assoc* 67:260-2.
- [59] Sumer, M., Gunduz, K., Sumer, AP.& Gunhan O. (2006) Benign cementoblastoma: A case report. *Med Oral Patol Oral Cir Bucal.* 11:E483-5.
- [60] Brannon, RB.& Fowler, CB. (2001) Benign fibro-osseous lesions: A review of current concepts. *Adv Anat Pathol.* 8:126-43.
- [61] Sharma, N. (2014) Benign cementoblastoma: A rare case report with review of literature. *Contemporary Clinical Dentistry* Jan-Mar 5(1)pp:92-4.
- [62] Sarode, SC., Sarode, GS., Waknis, P., Patil, A.& Jashika M. (2011) Juvenile psammomatoid ossifying fibroma: A review. *Oral Oncol.* 47:1110-6.
- [63] Godhi,, S., Goyal, S., Giraddi, G.& Goyal, S. (2008) Cementifying fibroma of the mandible: A case report. *J Oral Health Comm Dent.* 2:42-5.
- [64] Keleş, B., Duran, M., Uyar, Y., Azimov, A., Demirkan, A., Esen, HH. (2010) Juvenile ossifying fibroma of the mandible: A case report. *J Oral Maxillofac Res.* 1:e5.
- [65] Yadav, A.& Mishra, MB. (2011) Peripheral cemento- ossifying fibroma of mandible: A case report. *Indian J Stomatol.* 2:193-6.
- [66] Shetty, DC., Urs, AB., Ahuja, P., Sahu, A., Manchanda, A.& Sirohi, Y. (2011) Mineralized components and their interpretation in the histogenesis of peripheral ossifying fibroma. *Indian J Dent Res.* 22:56-61.
- [67] Kenney, JN., Kaugars, GE., Abbey, LM. (1989) Comparison between the peripheral ossifying fibroma and peripheral odontogenic fibroma. *J Oral Maxillofac Surg.* 47:378-82.
- [68] Brannon, RB., Fowler, CB., Carpenter, WM.& Corio, RL. (2002) Cementoblastoma: An innocuous neoplasm? A clinicopathologic study of 44 cases and review of the literature with special emphasis on recurrence. *Oral Surg Oral Med Oral Pathol Oral Radiol Endod* 93:311-20.
- [69] Kramer, IRH., Pindborg, JJ.& Shear, M. (1992) *Histological typing of odontogenic tumours.* 2nd ed. Berlin: Springer-Verlag.

