

We are IntechOpen, the world's leading publisher of Open Access books Built by scientists, for scientists

4,800

Open access books available

122,000

International authors and editors

135M

Downloads

Our authors are among the

154

Countries delivered to

TOP 1%

most cited scientists

12.2%

Contributors from top 500 universities



WEB OF SCIENCE™

Selection of our books indexed in the Book Citation Index
in Web of Science™ Core Collection (BKCI)

Interested in publishing with us?
Contact book.department@intechopen.com

Numbers displayed above are based on latest data collected.

For more information visit www.intechopen.com



Crestal Anesthesia for Dentoalveolar Surgery

Koroush Taheri Talesh, Shiva Solahaye Kahnamouii,
Mohammad Hosein Kalantar, Motamedi,
Shahram Mehrzad and Javad Yazdani

Additional information is available at the end of the chapter

<http://dx.doi.org/10.5772/59162>

1. Introduction

Predictable anesthesia is an essential requirement for both the patient and the dentist. The patient's opinion about the dental treatment is closely related to the local anesthesia (LA) experience and the proper use of LA techniques and pain management which are indispensable for successful dental treatment. In modern dentistry, creating favorable local anesthesia is an important factor in patient satisfaction and relaxation, the general view of the most successful dentist is one who can do without pain and anxiety for patients. Local anesthesia is a technique that is indispensable for dental professionals. Preventing pain during dental treatment is the ultimate goal of all dentists who are working in their profession. Sometimes problems can prevent them from achieving this goal. These problems include: lack of anesthesia in patients with possible aberrations, inner fears, infections etc. There are many causes for the occurrence of these problems, including: biological diversity in response to medications, anatomical differences between patients and considerable fear and anxiety associated with the injection of local anesthesia. Although this problem may arise in any part of the oral cavity, it most often occurs in the mandibular second molars. In the absence of complete anesthesia, performing dental treatment cannot be done and a significant number of cases of medical emergencies have arisen during dental treatment without LA. Although pain control is accomplished successfully in most cases, some anesthesia techniques like mandibular block are accompanied by drawbacks including difficulty in achieving anesthesia because of anatomic variations, deep and invasive needle penetration, paresthesia, trismus, paralysis, transportation of oral microbial flora to anatomic spaces, delayed onset of anesthesia, hematoma formation, high incidence of positive aspiration, undesired soft and/or hard tissue anesthesia with possible patient-induced injury, and difficulty in hemostasis in those with bleeding disorders. [1]

The inferior alveolar nerve block (IANB) is the most commonly used injection technique for achieving local anesthesia for mandibular restorative and surgical procedures. However, the IANB does not always result in successful pulpal anesthesia. Failure rates of 7 to 75% have been reported in experimental studies.

Supplementary anesthetic injection methods have evolved to circumvent the above disadvantages. These include intrapulpal, intraosseous, intraseptal and intraligamentary injections. Giffin introduced crestal anesthesia (CA) as a new variation of intraosseous anesthesia, which he claimed was tested for different dental procedures ranging from simple restorations to extractions. The technique relies on alveolar crestal perforations formed by canals of Zuckerkandl and Hirschfeld, which provide gingiva with innervation and circulation. Since then some have commented on the technique and approved it. However, to the best of our knowledge, no systematically designed case-controlled study has been done to evaluate its benefits and disadvantages. This chapter assesses our experience with this technique in the mandible.

Mandible anatomy the mandible, the largest and strongest bone of the face, encases the lower teeth. It consists of a curved, horizontal portion, the body, and two perpendicular portions, the rami, which unite with the ends of the body nearly at right angles.

2. Mandibular canal

In human anatomy, the mandibular canal is a canal within the mandible that contains the inferior alveolar nerve, inferior alveolar artery, and inferior alveolar vein. It runs obliquely downwards and forwards in the ramus, and then horizontally forward in the body, under the alveoli and communicates with them by small openings. On arriving at the premolar teeth, it exits via the mental foramen; a small branch known as the mandibular incisive nerve continues to the incisor teeth (Figure 1).

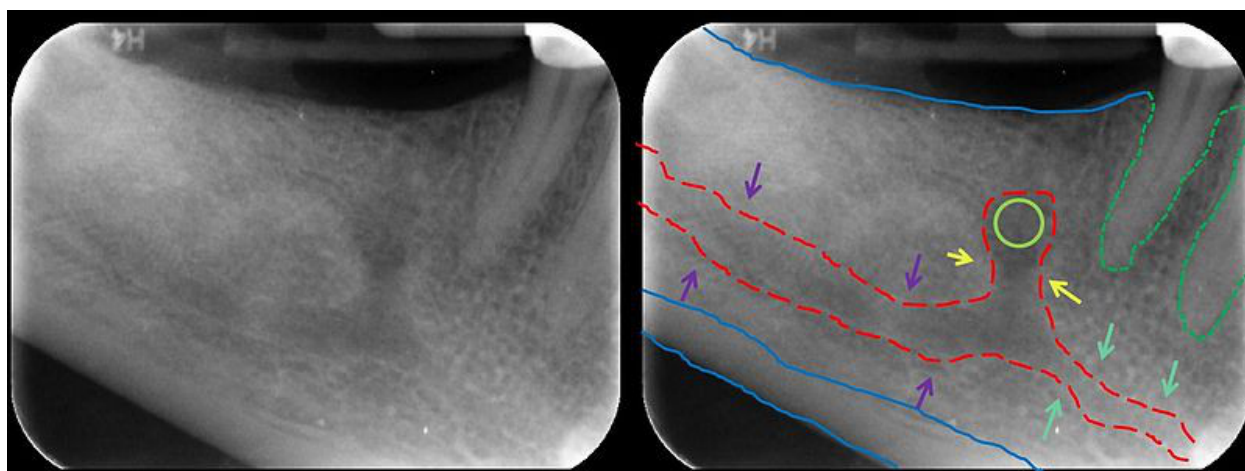


Figure 1. On arriving at the premolar teeth, the IAN exits via the mental foramen; a small branch known as the incisive nerve continues to the incisor teeth through the bone.

The lamina dura is the part of the alveolar bone that lines the socket; it is a thin layer of dense cortical bone called the lamina dura made of immature bone that lies adjacent to the periodontal ligament; lamina dura surrounds the tooth socket and provides the attachment surface which Sharpey's fibers of the periodontal ligament perforate. On an x-ray the lamina dura appears as a radiopaque line surrounding the tooth root. An intact lamina dura is seen as a sign of healthy periodontium. The lamina dura, along with the periodontal ligament, plays an important role in bone remodeling and thus in orthodontic tooth movement. The bone that underlies the lamina dura is cancellous bone. Under the lamina dura is the less dense cancellous bone. Trabeculi are tiny spicules of bone crisscrossing the cancellous bone that make it look spongy. These trabeculi separate the cancellous bone into tiny compartments which contain the blood producing marrow.

The alveolar process is the thickened ridge of bone that contains the tooth sockets in the maxilla and the mandible. It is also referred to as the alveolar bone. The mineral content of the alveolar bone is mostly hydroxyapatite, which is also found in enamel as the main inorganic substance. The buccinator muscle attaches to the alveolar processes of both the maxilla and mandible.

The periodontal ligament (PDL) is a group of specialized connective tissue fibers that essentially attach a tooth to the alveolar bone within which it sits.[1] These fibers help the tooth withstand the substantial natural compressive forces which occur during chewing. It consists of cells, and extracellular compartments of fibers. The cells are fibroblast, epithelial, undifferentiated mesenchymal, bone and cementum cells. The extracellular compartment consists of collagen fiber bundles embedded in ground substance. The PDL substance has been estimated to be 70% water and is thought to have a significant effect on the tooth's ability to withstand stress loads. The PDL is a part of the periodontium that provides for the attachment of teeth to the surrounding alveolar bone by way of the cementum. The PDL appears as the dark space (0.4 to 1.5 mm on radiographs), or radiolucent area between the radiopaque lamina dura of the alveolar bone proper and the radiopaque cementum.

In modern dentistry, providing an efficient and localized anesthesia is a must. The reality is that without anesthesia, one cannot perform safe treatment. In some occasions the anesthetizing techniques are accompanied by some drawbacks especially in mandibular block anesthesia such as: difficulty in achieving anesthesia (due to anatomic variations); deep and invasive needle penetration, paresthesia, trismus, paralysis, transportation of oral microbial flora to anatomic spaces, delayed onset of anesthesia, hematoma formation, high incidence of positive aspiration, undesired soft and/or hard tissue anesthesia with possible patient induced injury and difficulty in hemostasis in patients with bleeding disorders.(3-20)

Supplementary anesthetic injection methods have evolved to circumvent the abovementioned disadvantages. These include intrapulpal, intraosseous, intraseptal and intraligamentary injections. Giffin introduced a new variation of intraosseous anesthesia -Crestal Anesthesia (CA) - which he claimed was tested on more than 6000 teeth for different dental procedures ranging from simple restorations to extractions. The technique relies on alveolar crestal perforations formed by foramina of Zuckerkandl and Hirschfield (17), which provide gingiva with innervation and circulation (Figure 2).

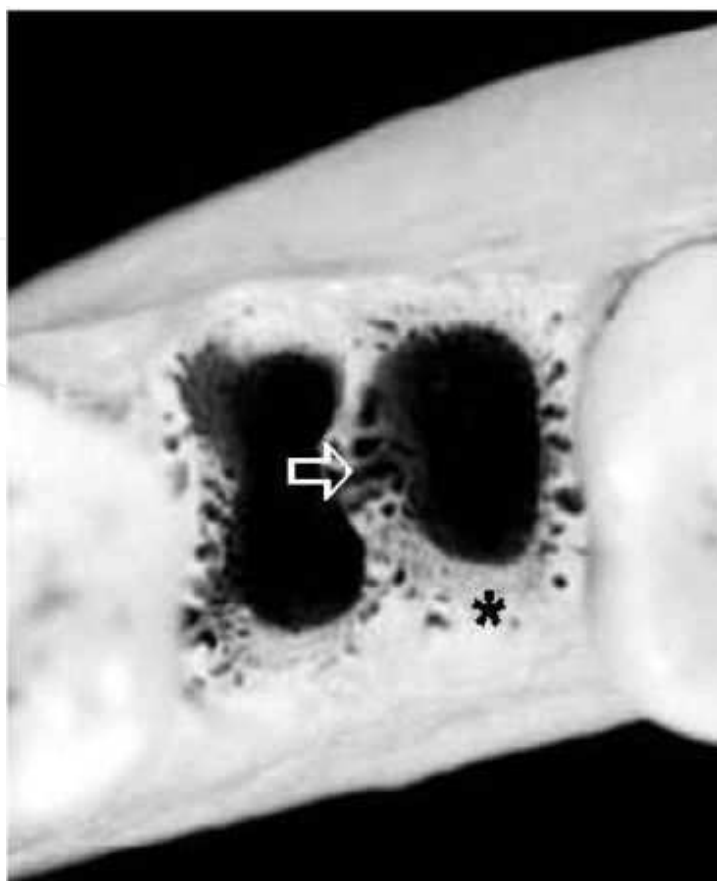


Figure 2. Alveoli of mandibular teeth. Note that the foramina of the nutrient canals are greater both in number and size in the interdental bone (arrow) comparing to marginal bone (*)

Since, then some have commented on the technique and approved it. (9) We also assessed this technique on 69 systemically and mentally healthy individuals between 18 and 47 years randomly selected from patients referring to the department of oral and maxillofacial surgery in Tabriz during 2003-2005. We did a split-mouth case-control clinical trial.

Crestal anesthesia technique: A regular dental anesthetic syringe and a standard short 27 gauge needle are used. Then an interdental gingival papilla is selected adjacent to the tooth or area to be anesthetized. A topical anesthetic agent (in this study benzocaine) is applied with a cotton-tipped applicator and the syringe is positioned so that as the papilla is penetrated, needle bevel and orifice are positioned subperiosteally adjacent to bone and crestal nutrient canals (Figure 3).

Then, using significant pressure the anesthetic agent is injected. This procedure should last at least 20 sec. usually 1/8 of a standard anesthetic cartridge suffices per papilla. One or both of the papilla (in case of inadequate numbness) can be used for the procedure. In this study, we used both papillae to get adequate anesthesia required for extraction. A classic direct Inferior Alveolar Nerve Block (IANB) plus long buccal nerve block was performed on the contralateral side for purpose of comparison. All of the extractions were completed in less than 10 minutes.

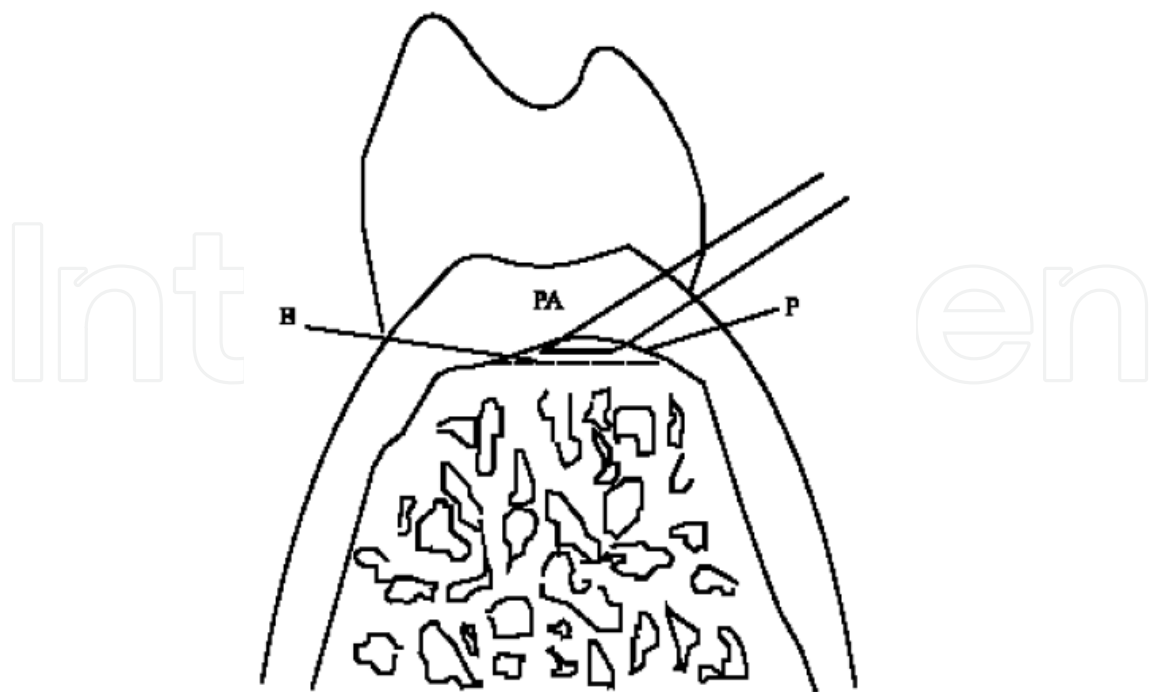


Figure 3. CA technique. Note the pooling of the injectate in subperiosteal area (P). B = alveolar bone, PA = interdental papilla

All had 2 bilateral posterior teeth (premolars, first and second molars) to be extracted. All patients were asked to rate the injection pain based on a scale of 0-5, where 0 represented no pain, 1 mild pain, 2 moderate pain, 3 moderate to severe pain, 4 severe and 5 intolerable pain. The contralateral canine was used as the unanesthetized control to ensure that the pulp tester was operating properly and that the subject was responding appropriately during the experiment. At the beginning of each appointment and before any anesthetic, the experimental tooth and the control canine were tested 3 times using a pulp tester (Gentle-Pulse, Parkell, Farmingdale, NY, USA) to record baseline vitality. The criterion for pulpal anesthesia was an absence of response by the patient to the maximum output (10). To record the changes (increase) of blood pressure an automatic digital blood pressure monitor (Omron HEM-711AC, Omron Healthcare Inc, Bonnockbum, Il, USA) was used. The blood pressure was recorded 5 sec prior to the penetration of syringe's needle to record the baseline blood pressure. Then we recorded the pressure immediately after the injection was initiated terminated and immediately before its termination. Again an average of 2 recordings was used to compare the difference of blood pressure in the 2 techniques. In order to compare, the administered volume of the anesthetic solution, anesthetic cartridges were stamped with milliliter marks and the used volume was recorded. CT scan of the lower jaw after the CA injection (using the mentioned combination of anesthetic solution and radiopaque agent previously tested on rabbits) to show the solution's penetration; the diffusion of the anesthetic solution can be seen in Figure 4 a-e; note the opaque area in the injection site that is a result of the instant diffusion of the injected contrast medium (anesthetic agent + opaque media).

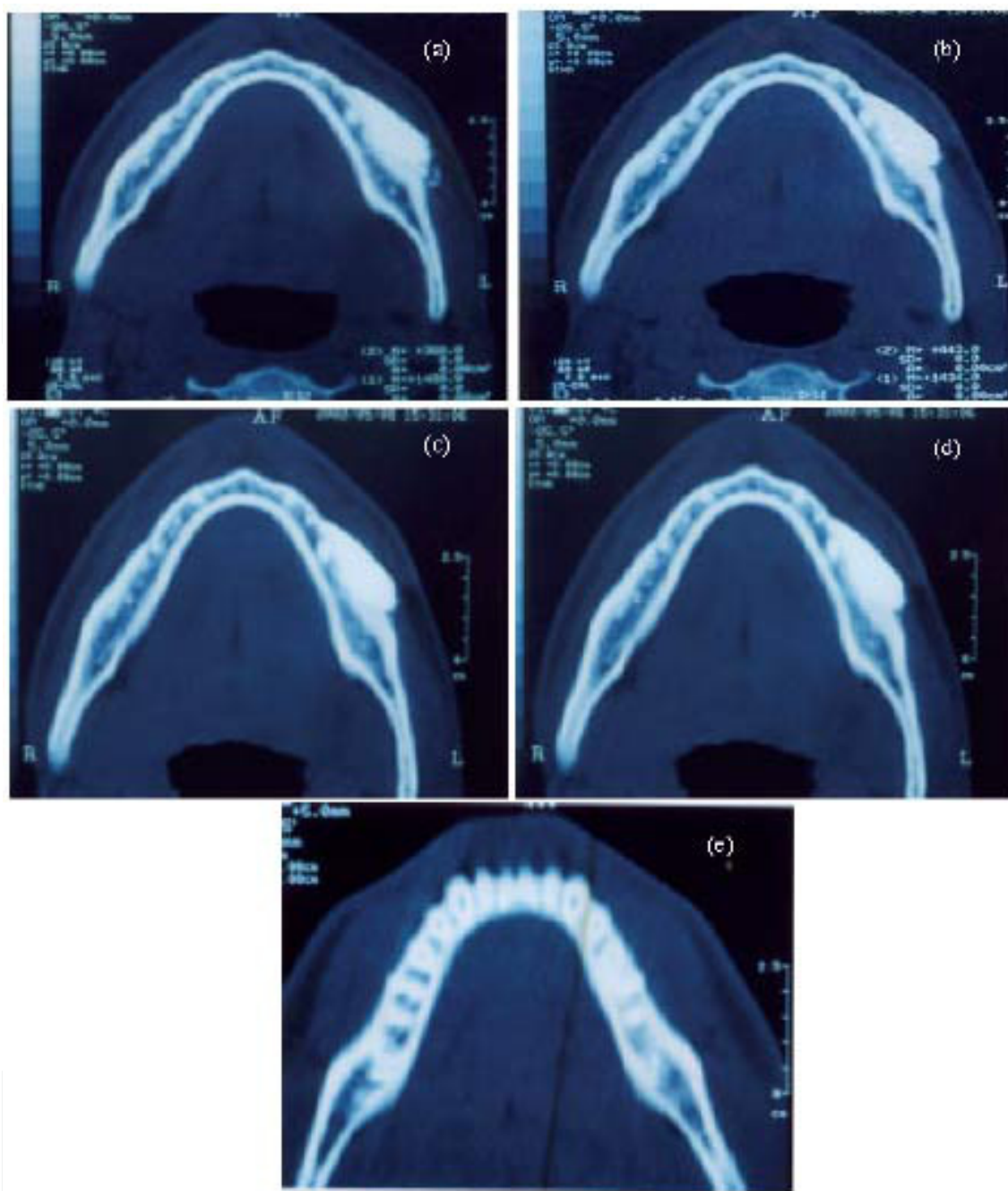


Figure 4. a-e: Penetration of radiopaque contrast media in cancellous bone shows penetration after crestal injection on axial CT scan.

Our study showed there was a statistically significant difference ($p < 0.001$) in the onset of anesthesia between CA (7.00 ± 0.71 sec) and IANB (3.30 ± 0.67 min). A statistically significant difference was also present ($p < 0.05$) between the duration of anesthesia in CA and IANB which lasted 23.10 ± 2.13 min and 32.10 ± 2.02 min respectively. Thus, the anesthesia was virtually instantaneous for CA and more lasting in IANB. The anesthetic success rates are presented in Table 1.

Tooth	CA	IANB
1st premolar	94 (15)	81 (13)
2nd premolar	95 (21)	81 (18)
1st molar	100 (12)	83 (10)
2nd molar	100 (8)	87 (7)
3rd molar	100 (11)	91 (10)

Table 1. Percentage (No.) of successful anesthesia gained by Crestal Anesthesia (CA) and Inferior Alveolar Nerve Block (IANB) techniques

There were no significant differences in heart rate increase between CA (0.58 ± 0.32 beat min⁻¹) and IANB (0.97 ± 0.00 beat min⁻¹) ($p > 0.05$). Blood pressure increased 0.00 ± 0.07 mmHg in CA and 0.97 ± 0.00 mmHg in IANB. There was no statistically no difference between them ($p > 0.05$). Only about a 5th of an anesthetic cartridge (0.40 ± 0.07 mL) was used in CA. On the other hand, IANB needed about five times more anesthetic solution (1.99 ± 0.06 mL) for initiating the anesthesia. Most of the pain ratings were in the moderate to severe and severe categories for IANB (3.44 ± 0.22) and only in the moderate to severe category for CA (1.45 ± 0.18) and there was a statistically significant difference between them ($p < 0.001$).

The majority of patients receiving CA appreciated not having discomfort and incapacitation often experienced with IANB anesthesia.

One patient with IANB anesthesia developed dry socket she was not a smoker and no other reasonable rationale was found for this occurrence. By the end of three month follow up we found no problems that could be attributed to CA.

3. Conclusion

Although, the CA method or other similar methods of injection such as the intraseptal method (utilizing the alveolar bone nutritional canals) are traditionally considered as supplementary injections, they are successfully used by numerous clinicians as a primary route of anesthetic administration and high success rates of anesthesia and satisfaction both by patients and dentists have been obtained.

The benefits of conventional Intraosseous Injections (IOI) are clearly known. With the advances in this area and introduction of new instruments and techniques patients and dentists benefit from profound anesthesia without unnecessary lip and tongue anesthesia. Unfortunately above facts have not made IOI as popular as the infiltration and block techniques.

Unsuccessful injections in the premolar region may be due to dense cortical bone of mental foramen that acts like a dam and reduces the diffusion rate of anesthetic solution. Also reduced diameter and fewer nutrient canals compared to posterior region may play a role. Reported primary intraligamentary anesthesia success rates of 74-92% were <99% observed in CA. (10)

It seems that the high success rate of CA is due to fast (or even immediate) diffusion of anesthetic agent through the very porous region of the tooth socket.

Longer duration of anesthesia in IANB compared to CA was an expected finding. CA produced duration of anesthesia similar to those of reported intraligamentary injection (2).

Another advantage of CA is its 0% of positive aspiration. The above facts might explain the reason for the statistically lesser readings of blood pressure and the heart (pulse) rate. As with intraosseous types of injections, the CA allows bilateral treatment of mandibular areas without complete mandibular numbness or lack of tongue control.

CA injections penetrate the uncomplicated tissue structures aseptically that probably account for mild post injection discomfort (gingival soreness). The presence of anatomical anomalies such as tori at the proposed site of injection would preclude the dentist from using the CA effectively.

Crestal anesthesia is an efficient, fast, and reliable technique in posterior mandibular dental restorative procedures and may be considered as a reliable and safe primary injection method in posterior mandibular teeth for exodontias or restorative dental procedures.

Author details

Koroush Taheri Talesh¹, Shiva Solahaye Kahnamouii^{1*}, Mohammad Hosein Kalantar, Motamedi², Shahram Mehrzad³ and Javad Yazdani¹

*Address all correspondence to: shiva.kahnamouii@gmail.com

1 Tabriz University of Medical Sciences, Tabriz, Iran

2 Trauma Research Center, Baqiyatallah University of Medical Sciences and Azad University of Medical Sciences, Tehran, Iran

3 Private Practice, Country

References

- [1] Certosimo, A.J. and R.D. Archer, 1996. A clinical evaluation of electrical pulp tester as an indicator of local anesthesia. *Oper. Dent*, 21 (1): 25-30.
- [2] Dower, J.S. Jr. and Z.M. Barniv, 2004. Periodontal ligament injection: Review and recommended technique. *Gen. Dent*, 52 (6): 537-542.
- [3] J. Weaver, 1987. An evaluation of electric pulp tester as a measure of analgesia in human vital teeth. *J. Endod.*, 13: 233-238.

- [4] Fish, L., D. McIntire and L. Johnson, 1989. Temporary paralysis of cranial nerves III, IV and VI after a Gow-Gates injection. *JADA.*, 119: 127-30.
- [5] Giffin, K.M., 1994. Providing intraosseous anesthesia with minimal invasion. *JADA*, 125: 1119-11121.
- [6] Goebel, W., 1983. Multiple techniques of mandibular analgesia. *Gen. Dent*, 31: 216-220.
- [7] Gow-Gates, G., 1973. Mandibular conduction anesthesia: A new technique using extraoral landmarks. *Oral. Surg. Oral. Med. Oral. Pathol.*, 36: 321-328.
- [8] Kafalias, M., G. Gow-Gates and G. Saliba, 1987. The Gow-Gates technique for mandibular block anesthesia: A discussion and a mathematical analysis. *Anesth. Prog.*, 34: 142-149.
- [9] Kama, J.C., 1994. Intraosseous pressure anesthesia. *JADA*, 125 (11): 1420-1421.
- [10] Kaufman, E., L. LeResche, E. Sommers, S. Dworkin and E. Truelove, 1984. Intraligamentary anesthesia: A double-blind comparative study. *JADA*, 108: 175-178.
- [11] Khedari, A., 1982. Alternative to mandibular block injections through intraligamentary anesthesia. *Quintessence Int.*, 2: 231-237.
- [12] Kleber, C.H., 2003. Intraosseous anesthesia: Implications, instrumentation and techniques. *JADA*, 134 (4): 487-491.
- [13] Malamed, S., 1981. The Gow-Gates mandibular block. *Oral. Surg. Oral. Med. Oral. Pathol.*, 51: 463-467.
- [14] Malamed, S., 1982. The Periodontal Ligament (PDL) injection: An alternative to inferior alveolar nerve block. *Oral. Surg. Oral. Med. Oral. Pathol.*, 53: 117-1721.
- [15] Malamed, S., 2005. *Hand Book of Local Anesthesia*. 5th Edn. Mosby, St. Louis.
- [16] Reams, G. and J. Tinkle, 1989. Supplemental anesthetic techniques. *J. Ore. Dent. Assoc.*, 58: 34-39.
- [17] Schroeder, H. and R. Page, 1990. The normal periodontium. In: Shluger, S., R. Youdelis, R. Page, R. Johnson (Eds.). *Periodontal diseases*. Philadelphia: Lea and Febiger, pp: 31-77.
- [18] Walton, R., B. Abbott, 1981. Periodontal ligament injection: A Clinical Evaluation. *JADA*, 103: 571-575.
- [19] Watson, J. and G. Gow-Gates, 1992. Incidence of positive aspiration in Gow-Gates mandibular block. *Anesth. Pain Control Dent*, 1: 73-76.
- [20] Watson, J., 1973. Some anatomic aspects of Gow-Gates technique for mandibular anesthesia. *Oral. Surg. Oral Med. Oral. Pathol*, 36: 328-330.

