

We are IntechOpen, the world's leading publisher of Open Access books Built by scientists, for scientists

4,800

Open access books available

122,000

International authors and editors

135M

Downloads

Our authors are among the

154

Countries delivered to

TOP 1%

most cited scientists

12.2%

Contributors from top 500 universities



WEB OF SCIENCE™

Selection of our books indexed in the Book Citation Index
in Web of Science™ Core Collection (BKCI)

Interested in publishing with us?
Contact book.department@intechopen.com

Numbers displayed above are based on latest data collected.

For more information visit www.intechopen.com



Structural and Functional features of Major Synovial Joints and Their Relevance to Osteoarthritis

Xiaoming Zhang, Brian Egan and Jinxi Wang

Additional information is available at the end of the chapter

<http://dx.doi.org/10.5772/59978>

1. Introduction

Osteoarthritis (OA) is considered to be an organ disease that may affect all of the articular and peri-articular tissues such as articular cartilage, synovium, ligament, capsule, subchondral bone, and peri-articular muscles [1-3]. Understanding the structural and functional features of the joint is of great significance for the diagnosis and treatment of OA. Although OA can occur in any synovial joint in the body, it mainly attacks the joints responsible for weight/load bearing such as the knee, hip, hand, and ankle joints. In this chapter, we will focus only on the structural and functional features of the major synovial joints and their relevance to osteoarthritis.

2. Shoulder (glenohumeral) joint

The glenohumeral joint is a ball-and-socket joint formed by the shallow glenoid cavity of the scapula and the head of the humerus. The joint cavity is slightly deepened by a ring-shaped fibrocartilage structure called the “glenoidal labrum”, which attaches to the edge of the glenoid cavity. Because of its structure, the joint has a wide range of movement in all directions. However, its wide range of mobility is accompanied by instability. Only about 1/3 of the humeral head surface area attaches to the glenoid cavity. The humeral head is held onto the glenoid cavity by the rotator cuff muscles, namely, the supraspinatus, infraspinatus, teres minor, and subscapularis. These four muscles are located superior, posterior, and anterior on three sides around the joint cavity.

The fibrous joint capsule originates from the margin of the glenoid cavity and attaches to the anatomical neck of the humerus. The arrangement of the joint capsule is remarkably loose,

particularly inferiorly when the arm is fully adducted (in anatomical position), allowing great separation between the bones of the joint and freedom of motion [4]. There are two apertures: one opens toward the intertubercular groove (sulcus) of the humerus to allow the long head of the biceps tendon to travel into the joint cavity, the other opens to the subscapularis bursa located anterior and inferior to the coracoid process of the scapula. The synovial membrane is lined up the inner surface of the joint capsule. In addition, it forms a tubular sheath wrapping the long head of the biceps tendon and extends into the intertubercular groove.

There are two intrinsic ligaments that are part of the joint capsule, the glenohumeral ligament that strengthens the anterior portion of the capsule and the coracohumeral ligament that is located superiorly. In addition, the transverse humeral ligament holds the long head of the biceps brachii muscle tendon inside the intertubercular groove, and the coraco-acromial ligament stabilizes the glenohumeral joint from above.

The supraspinatus muscle tendon travels laterally in between the acromion of the scapula and the superior aspect of the joint capsule and attaches to the greater tubercle of the humerus. A synovial bursa called the “subacromial/subdeltoid bursa” is located in between the acromion and the muscle tendon to prevent friction of the latter against the bone. A second bursa associated with the glenohumeral joint is located anterior-inferiorly to the coracoid process at the neck of the scapula. It protects the tendon of the subscapularis muscle from friction against the neck of scapula. This bursa communicates with the joint cavity.

The movement of the glenohumeral joint is in three axes plus circumduction. The extensive range of movement of the joint is due to its structural feature, a large humeral head articulating with a small glenoid cavity and a loose joint capsule. Many muscles move the glenohumeral joint including the thoracoappendicular muscles (muscles that originate from the thoracic wall and attach to the humerus) and scapulohumeral muscles (muscles that originate from the scapula and attach to the humerus).

The glenohumeral joint is supplied by the anterior and posterior circumflex humeral arteries and the suprascapular artery. The joint is innervated by the axillary and lateral pectoral nerves[5].

Commonly seen injuries to the glenohumeral joint and its associated bursae are the following:

- a. Subacromial/subdeltoid bursitis due to wear-and-tear.
- b. Supraspinatus tendonitis, usually as a further development of subacromial bursitis.
- c. Bicipital tendonitis, an inflammatory process of the long head of the biceps tendon inside the intertubercular groove. This process can be accompanied by tendon rupture, and/or transverse humeral ligament tear.
- d. Subscapular bursa inflammation (bursitis).
- e. Dislocation of the glenohumeral joint, which often happens with the humeral head dislocating inferiorly. If the dislocated humeral head is positioned anterior to the long head of the triceps brachii muscle tendon, it is called an “anterior dislocation”. Risk factors for shoulder injury include athletic participation, male gender, and young or old age [6,7].

Young, active individuals can experience dislocation or partial-dislocation of the shoulder during exercise, practice, or competitive events. In prospective cohort studies of young military populations, 3% to 6% sustained shoulder dislocations or partial-dislocations were observed [8,9].

- f. Fracture at the surgical neck of the humerus. This fracture often causes axillary nerve injury.
- g. Joint instability. Shoulder instability is a significant problem due to the structural features of the shoulder joint. Studies of young and adult patients revealed the chance of recurrent shoulder instability after standard non-operative treatment at 55% to 67%, with the young male population presenting recurring injuries at an 87% rate during a five year follow-up[8,10]. Randomized clinical trials demonstrated that surgical stabilization of the shoulder is more effective to prevent the recurrence of injury than immobilization and rehabilitation alone [11-13]. Identifying specific structural risks associated with shoulder instability is another way to combat recurrent shoulder dislocations.

OA in the glenohumeral joint. Primary OA in the glenohumeral joint is relatively uncommon, and occurs more often in women and patients over the age of 60 [14,15]. In younger patients, it is usually caused by injuries to the joint that occurred several years earlier such as joint dislocation, fracture, rotator cuff tear, and glenoid labrum injury.

3. Elbow joint

The elbow joint is a complex structure involving three bones, the humerus, ulna, and radius, articulating together. There are three joints wrapped within one joint capsule: the humeroulnar joint, the humeroradial joint, and the proximal radioulnar joint.

The humeroulnar joint is formed between the trochlear of the humerus and the trochlear notch of the ulna. It is a typical hinge joint capable of flexion and extension. The humeroradial joint is formed between the capitulum of the humerus and the head of the radius. The capitulum is a ball shaped structure that allows the head of the radius, which is a disc-shaped structure articulating with the capitulum on its flat surface, to move in two directions: flexion and extension, plus axial rotation against the capitulum. The proximal radioulnar joint is formed between the head of the radius (round surface) and the radial notch of the ulna. The radial structure rotates against the ulnar structure when the forearm carries out pronation and supination actions.

The fibrous joint capsule surrounds the elbow joint on four sides with the anterior and posterior sides weaker than those on the medial and lateral sides. Therefore, elbow joint dislocation often happens anteriorly or posteriorly. Synovial membrane lines the inner surface of the fibrous joint capsule.

The fibrous joint capsule thickens on the medial and lateral sides to become medial (ulnar) or lateral (radial) collateral ligaments. The ulnar collateral ligament is a triangular shaped

ligament containing three components: the anterior cord-like band (strongest), the posterior fan-like band, and the oblique band. The radial collateral ligament is fan-shaped and connects the lateral epicondyle of the humerus with the annular ligament of the radial head. The annular ligament is a ring-shaped ligament that surrounds the circumference of the disc-shaped radial head and fixes it to the radial notch of the ulna.

The movement of the elbow joint includes flexion/extension and pronation/supination. There are more than a dozen muscles across the elbow joint that participate in moving the joint. Blood is supplied to the elbow joint by anastomosing branches from the humeral artery, radial artery, and ulna artery. Musculocutaneous, radial, and ulnar nerves innervate this joint.

OA in the elbow joint: The elbow is one of the least affected joints by osteoarthritis because of its well matched joint surfaces and strong stabilizing ligaments. As a result, the elbow joint can tolerate large forces across it without becoming unstable. Development of osteoarthritis in elbow joint is usually due to previous injuries to the joint.

4. Wrist (radiocarpal) joint

The wrist joint is a condyloid joint. The proximal joint surface is the distal end of the radius and the articular disc. The distal joint surface is formed by three of the proximal row of carpal bones (scaphoid, lunate, and triquetrum). The ulna and pisiform are not involved in wrist joint formation. The articular disc is a triangular-shaped fibrocartilage structure that connects the styloid process of the ulna to the distal end of the radius. The distal end of the ulna is located proximal to the articular disc and thus does not contact the carpal bones.

The fibrous joint capsule is strengthened by several ligaments which are all part of the fibrous joint capsule. Anteriorly, there is the palmar radiocarpal ligament. Posteriorly, there is the dorsal radiocarpal ligament. On the medial side, there is the ulnar collateral ligament which attaches to the ulnar styloid process. On the lateral side, there is the radial collateral ligament which attaches to the radial styloid process. The synovial membrane lines the internal surface of the fibrous joint capsule and forms numerous synovial folds.

The movement of the wrist joint involves flexion/extension, abduction/adduction, and circumduction. Many muscles from the forearm to the hand move this joint. The wrist joint is supplied by the palmar and dorsal carpal arches which are branches of the radial and ulnar arteries. The innervation of this joint is by median, radial, and ulnar nerves.

OA in the wrist joint: There are different causes, both idiopathic and traumatic, of wrist osteoarthritis. Traumatic causes of wrist OA include injuries to ligament, articular cartilage, and bone. Although injuries to many wrist ligaments can lead to progressive wrist arthrosis, a chronic scapholunate ligament tear in particular is known to produce intercarpal instability, altered wrist kinematics and joint loading, and degeneration of the radiocarpal joint. Fracture and subsequent nonunion of the scaphoid also leads to a series of predictable degenerative changes. Wrist OA can also occur secondary to an intra-articular

fracture of the distal radius or ulna or from an extra-articular fracture resulting in malunion and abnormal joint loading [16].

5. Hand joints

There are several groups of joints in the hand. From proximal to distal, the groups are:

- a. Intercarpal joints: These are the joints between the carpal bones within each row and between the proximal and distal rows. They are plane types joints with little movement, and most of them share a common joint cavity.
- b. Carpometacarpal and intermetacarpal joints: These are the joints between the distal row of the carpal bones and the metacarpal bones and also between each metacarpal bone. They are grouped together because they share a common joint cavity. They are all plane types joints except for the carpometacarpal joint of the thumb (1st digit), which is a saddle type joint.
- c. Metacarpophalangeal joints: These are joints between the metacarpal bones and the proximal phalanges. They are condyloid joints allowing bi-directional movements (flexion/extension and adduction/abduction).
- d. Interphalangeal joints: These are the joints between each phalange. They are hinge types joints.

OA in hand: Hand OA is a prevalent disorder. It is not one single disease, but a heterogeneous group of disorders. It may appear as osteophyte or joint space narrowing, interphalangeal nodal, or thumb base erosion [17-19].

6. Hip joint

The hip joint is a ball-and-socket joint formed by the head of the femur (ball) and the acetabulum of the pelvis (socket). It is a very stable joint that bears all the weight of the upper body yet maintains a wide range of movement.

The head of the femur is covered by articular cartilage except for the center where a depression called the "fovea" allows for the attachment of the ligament to the femoral head.

The acetabulum is formed by the fusion of three pelvic bones: pubis, ischium, and ilium. It is a hemispherical hollow socket facing anteriolaterally. The edge of the acetabulum is called the "acetabular rim", which is covered by semilunar-shaped articular cartilage called the "lunate surface of the acetabulum". It is an incomplete circle with the inferior part missing. The missing inferior segment is called the "acetabular notch". This notch is bridged by the "transverse acetabular ligament", which is part of a fibrocartilaginous ring that attaches to the margin of the acetabulum. This lip-shaped ring structure is called the "acetabular labrum". It increases

the articular surface of the acetabulum by 10%. The central region of the acetabulum is not covered by any articular cartilage; rather, it is filled with a fat pad. This region is called the “acetabular fossa”, which has a thin wall from the ischium and communicates with the acetabular notch (Figure 1).

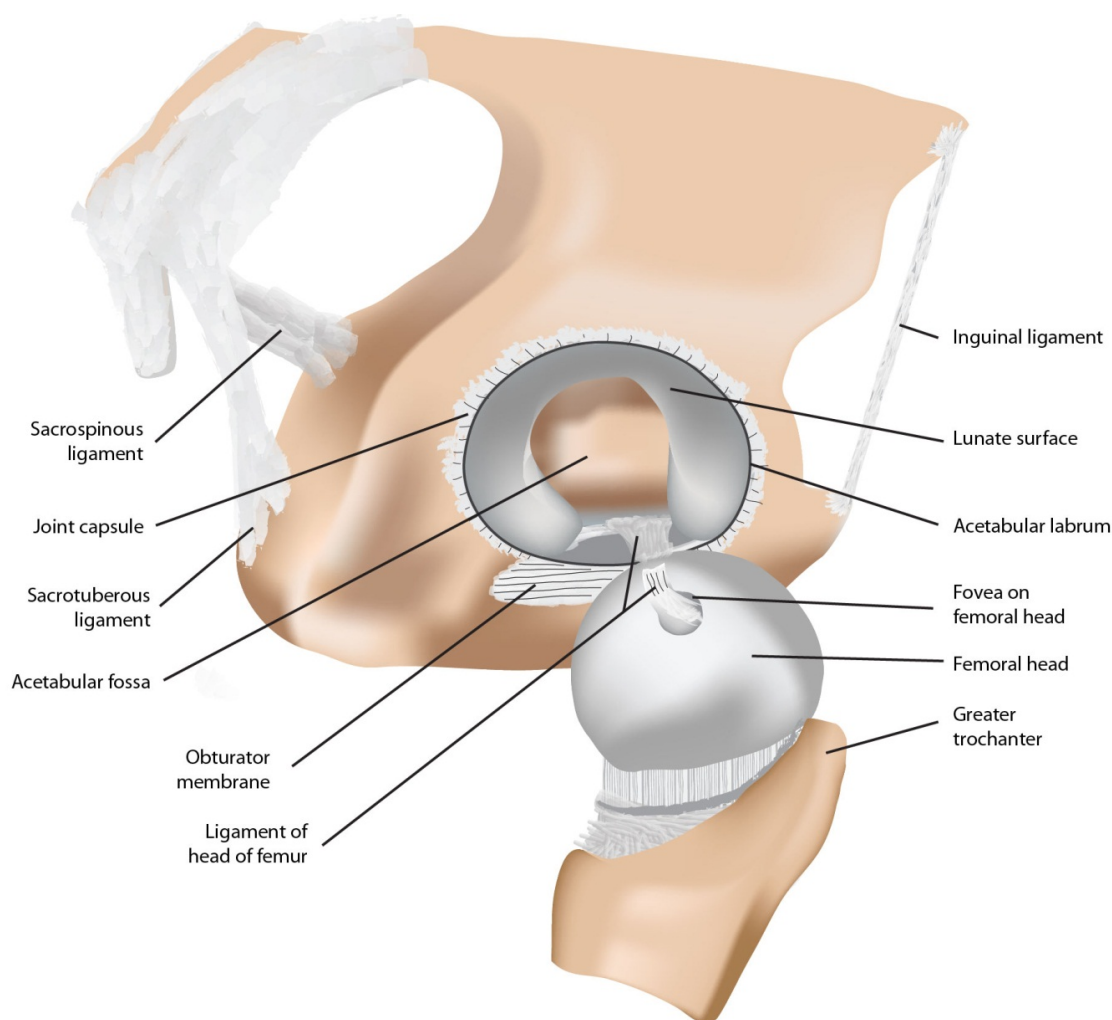


Figure 1. An illustration showing the lateral view of the hip joint. The ligament of the head of the femur has been transected and the femoral head has been dislocated to show the internal structure of the acetabulum.

More than half of the femoral head fits into the acetabulum making the joint the most stable for weight bearing.

The capsule of the hip joint is strong in its fibrous layer. It attaches just outside the acetabular rim proximally and the femoral neck, intertrochanteric line, and greater trochanter distally. Most of the fibers of this joint capsule run in a spiral direction between its two ends. This is particularly true when the hip joint is extended at a standing position (anatomical position). At this position, the joint capsule is tightened, pushing the head of the femur against the acetabulum firmly. When the hip joint is flexed, such as when one is in a sitting position, the spiral joint capsule fibers are “unwound” becoming straight. The straightened joint capsule

fibers are longer than their spiral state making the joint capsule loosen for more mobility. The synovial membrane lines up the inner surface of the fibrous joint capsule and forms synovial folds at the femoral neck.

There are three intrinsic joint ligaments that are part of the joint capsule.

- a. Iliofemoral ligament: A Y-shaped ligament located anterior-superiorly to the joint. It attaches to the anterior inferior iliac spine and the acetabular rim proximally and the intertrochanteric line distally. It is the strongest ligament of the body preventing overextension of the hip joint.
- b. Pubofemoral ligament: A ligament located anterior-inferiorly bridging the pubic bone and the iliofemoral ligament. It works together with the latter to prevent overextension of the hip joint. It also protects the joint from over-abduction.
- c. Ischiofemoral ligament: A ligament located posteriorly between the ischium and the femoral neck/greater trochanter.

The ligament of the head of the femur is actually a synovial fold located inside the joint cavity. It attaches to the fovea of the head of the femur at one end and the transverse acetabular ligament at the other. There is a small artery running inside this ligament. It is a weak ligament of little importance for the stability of the joint.

The movement of the hip joint is extensive in all three axes (flexion/extension, abduction/adduction, and medial/lateral rotation) plus circumduction. Its movement is also affected by the positions of the knee and the vertebral column. Muscles in the gluteal region, lumbar region, anterior thigh, medial thigh, and posterior thigh are involved when moving the hip joint. Some muscles move the joint in more than one direction.

The major blood supply to the hip joint is the retinacular arteries arising from the medial and lateral circumflex femoral arteries. Both are branches of the profunda femoris artery or the femoral artery. The medial and lateral circumflex arteries travel along the intertrochanteric ridge and the intertrochanteric line of the femur and anastomose with each other. The retinacular arteries branch off from the circumflex arteries and travel along the neck of the femur to reach the femoral head and the hip joint. When fracture happens to the neck of the femur, retinacular arteries are injured resulting in reduced blood supply to the femoral head and the hip joint.

“Hilton’s Law” states that the nerve that innervates the muscles moving the joint also innervates the joint. The following nerves innervate the muscles that move the hip joint: femoral nerve, obturator nerve, and superior and inferior gluteal nerves.

OA in the hip joint: In addition to idiopathic OA, acetabular fracture is a known cause of post-traumatic OA of the hip joint [20]. Acetabular dysplasia is predictive of hip OA and subsequent hip arthroplasty [21]. An increased prevalence of radiographic hip OA and osteophytosis is observed in high bone mass (HBM) cases compared with controls [22]. In addition, the development of knee OA is related to variations in hip and pelvic anatomy [23].

7. Knee joint

The knee joint is formed by three bones: femur, tibia, and patella. It is basically a hinge joint for flexion and extension with additional motions such as gliding (between the femur and patella), rolling (between the femur and tibia), and rotation (between the femur and tibia). There are three articulations in this joint: medial femorotibial (between the medial condyles of the femur and the tibia), lateral femorotibial (between the lateral condyles of the femur and the tibia), and femoropatellar (between the femur and the patella). The articulating surfaces of the femur are ball-shaped, whereas the articulating surfaces of the tibia are flat. When they articulate with each other, it is like two balls placed on a warped table top, making the articulation very unstable. Ligaments, menisci, and muscles strengthen the knee joint (Figure 2).

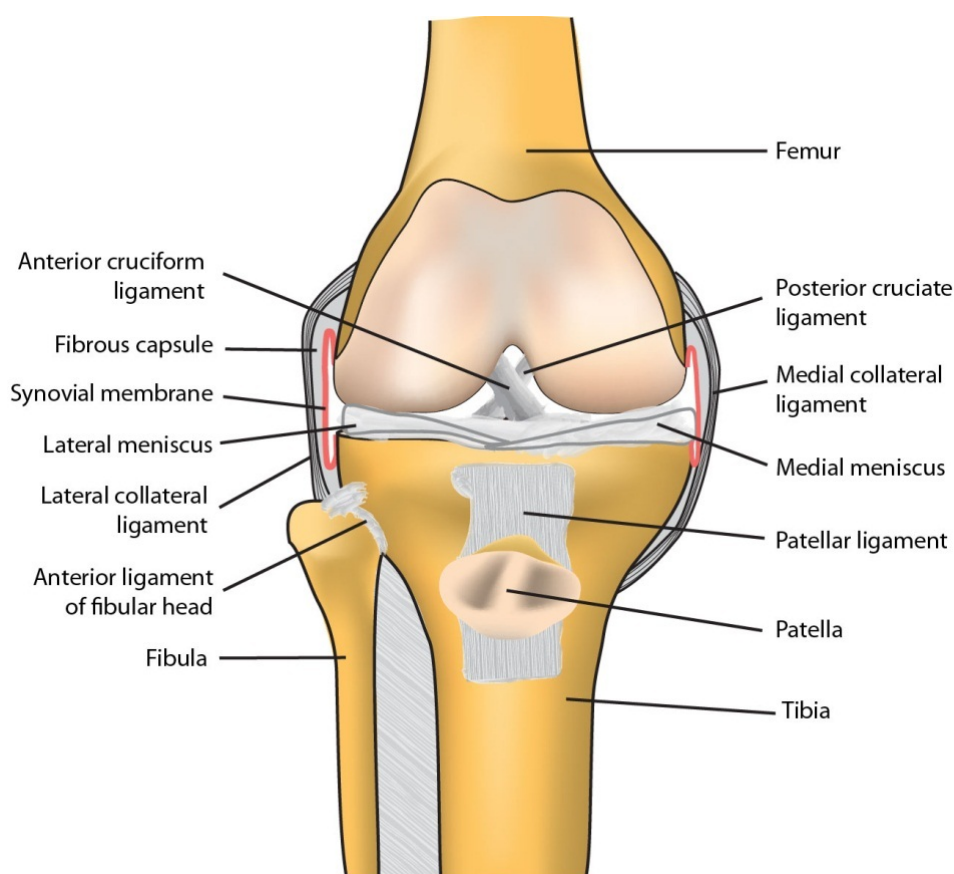


Figure 2. An illustration showing the anterior view of the knee joint with major intra-articular and peri-articular tissues. The patellar ligament has been reflected downward with the attached patella.

The fibrous capsule of the knee joint thickens in some areas to become the intrinsic joint ligaments. Anteriorly, the fibrous capsule merges with the quadriceps tendon, the patella, and the patellar ligament so that these structures become part of the anterior fibrous joint capsule. Posteriorly, the fibrous joint capsule has an opening at the medial condyle of the tibia. This opening allows the tendon of the popliteus muscle to exit the joint capsule and attach to the tibia.

The synovial membrane lines the inside surface of the fibrous joint capsule. In the center of the joint where the intercondylar fossa houses the anterior and posterior cruciate ligaments, the synovial membrane leaves the posterior fibrous capsule and reflects anteriorly into the intercondyle fossa area forming the “infrapatella synovial fold”. This synovial fold excludes the cruciate ligaments and the infrapatella fat pad from the joint cavity and almost sub-divides the knee joint cavity into medial and lateral halves. This unique anatomical feature allows surgeons to approach the cruciate ligaments through the posterior fibrous capsule without entering the joint cavity. However, the synovial membrane does not cover the following joint structures: articular cartilages on femur and tibia, the posterior surface of the patella, and the menisci.

There are about 12 bursae around the knee joint; some of them communicate with the joint cavity.

Anteriorly, there are 5 bursae. The suprapatellar bursa is a large, deep bursa located above the patella and under the quadriceps tendon. It communicates with the joint cavity. The synovial membrane of the knee joint becomes the lining of this bursa. There are 2 prepatella bursae: the subtendinous prepatellar bursa is located between the patellar tendon and the patella and the subcutaneous prepatellar bursa is located between the skin and the patellar tendon. There are also 2 infrapatellar bursae: the deep infrapatellar bursa is located between the patellar tendon and the tibia and the subcutaneous infrapatellar bursa is located between the skin and the patellar tendon.

Posteriorly, there are several bursae associated with the muscle attachments around the knee joint such as the gastrocnemius bursae, the semimembranosus bursa, and the popliteus bursa. These bursae are less clinically significant than those located in the anterior aspect of the knee.

The knee joint is strengthened by two groups of ligaments, external ligaments and internal ligaments. There are five external knee joint ligaments, and most of them are part of the fibrous joint capsule (intrinsic ligaments).

The patellar ligament is the distal portion of the quadriceps tendon when it wraps the patella and goes on to insert into the tibial tuberosity. On each side of the patellar ligament extending from the aponeurosis of the vastus medialis and vastus lateralis, are the medial and lateral “patellar retinacula”, which help to maintain the position of the patella.

There are two collateral ligaments on each side of the knee joint. The medial (tibial) collateral ligament (MCL or TCL) is a flat, broad band of the fibrous joint capsule. Its fibers continue into the medial meniscus connecting the two. When the MCL is injured, the medial meniscus is mostly involved. The lateral (fibular) collateral ligament (LCL or FCL) is a cord-like strong extracapsular ligament. It attaches to the fibular head splitting the tendon of the biceps femoris muscle. It is separated from the joint capsule by the tendon of the popliteus muscle, and therefore is not connected to the lateral meniscus.

The oblique and arcuate popliteal ligaments are located posteriorly to the knee joint and strengthen the joint capsule posteriorly.

The internal or intra-articular ligaments include the cruciate ligaments and the meniscal ligaments. The cruciate ligaments are located inside the fibrous joint capsule in the intercondylar fossa but outside the synovial membrane, and therefore outside the joint cavity. They cross each other and play the most important role in maintaining the contact between the femur and the tibia when the knee is flexed. Whatever position the knee joint is at, one of the cruciate ligaments is maintained in tension.

The anterior cruciate ligament (ACL) arises from the anterior intercondylar area of the tibia posterior to the attachment of the medial meniscus, travels posterior-laterally, and attaches to the medial surface of the lateral condyle of the femur. When the ACL travels across the posterior cruciate ligament (PCL), it is on the lateral side of the PCL. The ACL prevents the posterior movement of the femur from the tibial plateau when the knee is extended. When the knee joint is flexed, the ACL prevents the anterior movement of the tibia from the femur [24,25].

The posterior cruciate ligament (PCL) arises from the posterior intercondylar area of the tibia, travels anteriorly on the medial side of the ACL, and attaches to the lateral surface of the medial condyle of the femur. It is stronger than the ACL. When the knee joint is extended, the PCL prevents the anterior movement of the femur from the tibial plateau. When the knee is flexed, the PCL prevents the posterior movement of the tibia from the femur.

Because of the anatomical relationship between the two cruciate ligaments, the medial rotation of the tibia is limited to about 10° when the knee is flexed. This is because the ACL is pushed against the PCL and the latter blocks the ACL from moving medially during the rotation. Under the same situation but reversing direction, the lateral rotation of the tibia is about 60° because the two cruciate ligaments are moving away from each other.

The menisci are crescent-shaped fibrocartilage structures located on the articular surface of the tibia. They are thicker at the external margins and thin in the central edges, thereby deepening the surface of the tibial articular surface. They attach to the intercondylar area of the tibia with their ends and to the fibrous joint capsule on each side. Other than these attachments, the menisci are free of attachment to other joint structures. Therefore, they are mobile along with the knee joint movement. The medial meniscus is C-shaped, attaches to the medial collateral ligament and is less mobile. The lateral meniscus is almost O-shaped and is more movable.

The movement of the knee joint is essentially flexion and extension. During these actions, the patella glides against the femur and the femur rolls against the tibial plateau. When the knee joint is in the fully extended position with the foot on the ground, the femur may rotate 5° medially along its longitudinal axis on the tibial plateau. This is the locking of the knee. When the knee is "locked", the knee joint is stable for weight bearing and the thigh and leg muscles can briefly relax. To "unlock" the knee, the popliteus muscle rotates the femur laterally about 5° [26-28].

When the knee joint is extended, the contacting area between the femur and the tibia moves anteriorly; when the knee is flexed, this contacting area moves posteriorly. As a result, the menisci, particularly the lateral meniscus, moves anteriorly during extension, and posteriorly during flexion.

The blood supply to the knee joint is from the genicular arteries branched from the popliteal artery. Extensive anastomoses form around the knee joint. The nerve innervation of the knee joint follows Hilton's law by femoral, obturator, and sciatic nerves.

The knee joint is the most vulnerable joint for injury. Structures that are most frequently injured are the ACL, MCL, and the medial meniscus. Because of its weight bearing feature, the knee joint is also the most affected joint for OA [29-31].

8. Ankle joint

The ankle joint is a hinge joint involving three bones: distal tibia, distal fibula, and superior surface of talus. The distal end of the tibia forms an L-shaped joint surface with its horizontal aspect articulating with the talus from above and its vertical aspect articulating with the talus on the medial side. The distal end of the fibula forms the lateral malleolus. The fibula articulates with the talus on the lateral side and forms the lateral malleolus. The distal tibia and distal fibula are connected together by ligaments forming an open rectangular recess like a mortise facing inferiorly. The superior surface of the talus sits inside the mortise like a trochlea to form the ankle joint with three articular surfaces, superior and medially by tibia and laterally by fibula.

The superior articular surface of the talus is not rectangular in shape, but rather trapezoidal with a wider anterior measure and a narrower posterior measure. When the ankle joint is dorsiflexed, the wider anterior portion of the talus sits in the mortise formed by the tibia and fibula. In this situation, there is little room for the talus to move inside the joint cavity. Therefore, the ankle joint is most stable when the foot is dorsiflexed. On the contrary, when the ankle joint is plantarflexed, the narrower posterior portion of the talus sits inside the mortise and there is more room laterally for the talus to move. In this situation, the ankle joint is unstable and is vulnerable to injuries.

The joint capsule of the ankle joint is loose anteriorly and posteriorly but strengthened on each side by collateral ligaments. Synovial membrane lines the internal surface of the fibrous capsule.

The ligaments of the ankle joint can be grouped into those that stabilize the tibia and the fibula and those that are located on each side of the joint.

There is an interosseous ligament located deep between the tibia and the fibula. In addition, there are the anterior superior tibiofibular ligament, anterior inferior tibiofibular ligament in the front, and posterior tibiofibular ligament at the back. All of these ligaments strengthen the bond between tibia and fibula and stabilize the ankle joint.

On the lateral side of the ankle, the fibrous joint capsule is reinforced by the lateral ligaments of the ankle. They are intrinsic joint ligaments (being part of the fibrous joint capsule) and are actually three separate structures (Figure 3A).

- a. Anterior talofibular ligament – from the lateral malleolus to talus.

- b. Posterior talofibular ligament – from the lateral malleolus to talus at the back.
- c. Calcaneofibular ligament – from lateral malleolus to the lateral surface of the calcaneus.

The medial ligament of the ankle is also referred to as the deltoid ligament of the ankle. It is a fan-shaped ligament that originates from the medial malleolus and attaches to several bones distally. From anterior to posterior in sequence, the portions of the medial ligament of the ankle are the anterior tibiotalar part, the tibionavicular part, the tibiocalcaneal part, and the posterior tibiotalar part (Figure 3C).

The major movements of the ankle joint are dorsiflexion and plantarflexion. The ankle joint can slightly abduct and adduct. When the foot is in plantarflexion in combination with adduction, the movement is inversion (Figure 3B). When the foot is in dorsiflexion in combination with abduction, the ankle joint is carrying out eversion (Figure 3D).

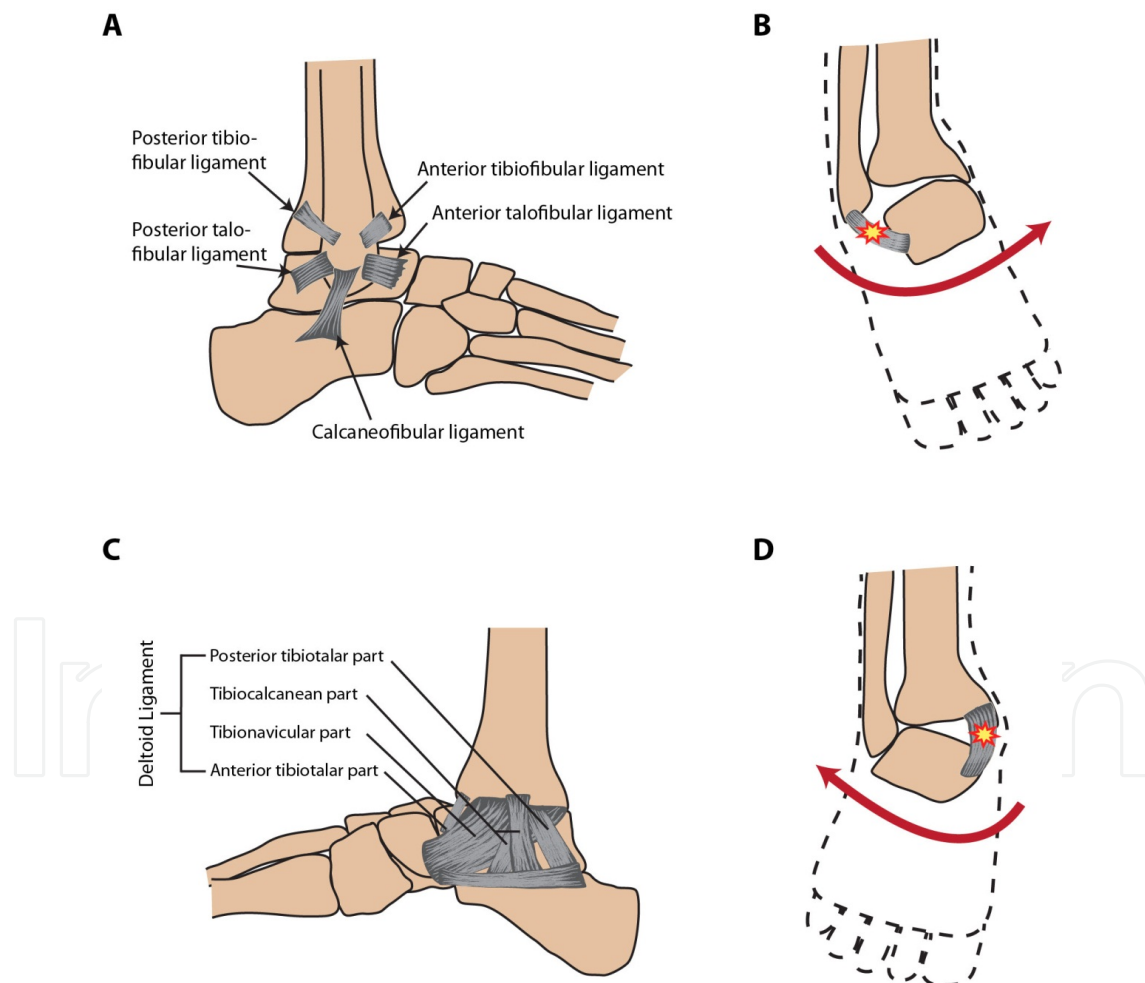


Figure 3. (A) A representation of major lateral ligaments of the ankle and the tibiofibular ligaments. (B) A typical inversion injury of the ankle that leads to damage of the lateral ankle ligaments. (C) The deltoid ligament which is the primary medial ankle ligament complex. (D) A typical eversion injury of the ankle that results in damage to the medial ligaments of the ankle.

The blood supply to the ankle joint is via the anterior tibial artery, the posterior tibial artery, and the fibular artery which is a branch of the posterior tibial artery. The nerve innervation is by the tibial nerve and the deep fibular nerve.

Ankle joint injury: The ankle is a second joint that demonstrates a high susceptibility to injury. A severe injury of major ligaments of the ankle may cause instability of the joint.

Like knee injuries, ankle injuries often occur during participation in sports or exercise; consequently, populations of athletes are often used in incidence studies. For example, ankle injuries are estimated to account for 14% of all athletic injuries, with sprains to ankle ligaments accounting for over 75% of ankle injuries [32-34]. The anterior talofibular ligament is the most commonly injured ankle ligament, involved in an estimated 85% of sprains sustained during United States high school sports [35]. A major problem accompanying ankle injury is the high rate of recurrence associated with chronic ankle instability. Approximately 15% of all ankle sprains occur in ankles with previous ligament injury[35]. Current models of chronic ankle instability (CAI) identify sufferers as experiencing—individually or in combination—mechanical instability, perceived instability, and recurrent sprains. Further characterizing patients with CAI by specific impairment, activity limitations, and participation restrictions, could help in the design of targeted treatments and injury reduction programs[36].

Ankle joint osteoarthritis: Idiopathic OA is common in the hand, foot, knee, spine, and hip joints, but rarely occurs in the ankle joint mainly due to its stable anatomical structure. However, the risk of post-traumatic OA in the ankle appears to be at least as great as the risk in the other joints. Differences among joints in congruity, articular cartilage thickness, force transmission across the joint surfaces, joint stability, and the presence of menisci could make some joints more vulnerable to OA. For example, the knee has thick menisci but the ankle does not. In addition, the ankle joint has a smaller bearing surface and is more constrained. The distal tibial articular surface has much thinner cartilage than the proximal tibial articular surface. Mechanical loading on the articular surface of the distal tibia after chondral damage causes higher subchondral bone strains than the loading on the proximal tibial articular surface. These differences may make the distal tibial articular surface more vulnerable to degradation of cartilage and development of OA [37-42].

9. Conclusion

This chapter summarizes the structural and functional features of major synovial joints of the human body and their relevance to joint injury and the development of OA. Although OA can affect any synovial joint, the prevalence of OA in specific joints is closely related to their structural and functional features. Idiopathic OA rarely occurs in the ankle, wrist, elbow, and shoulder, but it is common in the hand, foot, knee, spine, and hip joints. The risk of post-traumatic OA in the ankle, wrist, elbow, and shoulder appears to be as great as the risk in the hand, foot, knee, and hip. Differences among joints in articular surface congruity, articular cartilage thickness, mechanical force transmission, ligament structure-related joint stability, and the presence of menisci could make some joints more vulnerable to the development of

OA. A better understanding of the structural and functional features of major synovial joints of the human body may help us develop more effective strategies for the prevention and treatment of OA.

Acknowledgements

This work was supported in part by the U.S. National Institutes of Health (NIH)/NIAMS grant R01 AR059088, the U.S. Department of Defense medical research grant W81XWH-12-1-0304, and the Harrington Distinguished Professorship Endowment. The authors thank Mr. Zhaoyang Liu for editorial assistance.

Author details

Xiaoming Zhang¹, Brian Egan² and Jinxi Wang^{2*}

*Address all correspondence to: jwang@kumc.edu

1 Department of Anatomy and Cell Biology, University of Kansas School of Medicine, Kansas City, USA

2 Department of Orthopedic Surgery, University of Kansas School of Medicine, Kansas City, USA

References

- [1] Brandt KD, Dieppe P, Radin E. Etiopathogenesis of osteoarthritis. *Med Clin North Am.* 2009;93(1):1-24, xv.
- [2] Brandt KD, Radin EL, Dieppe PA, van de Putte L. Yet more evidence that osteoarthritis is not a cartilage disease. *Ann Rheum Dis.* 2006;65(10):1261-1264.
- [3] Loeser RF, Goldring SR, Scanzello CR, Goldring MB. Osteoarthritis: a disease of the joint as an organ. *Arthritis Rheum.* 2012;64(6):1697-1707.
- [4] Gray H. *Gray's Anatomy*. Edinburgh: C. Livingstone; 1989.
- [5] Moore KL, Dalley AF, Agur AMR. Upper Limb. In: Moore KL, Dalley AF, Agur AMR (eds.) *Clinically Oriented Anatomy* 7th ed. 2014; Wolters Kluwer|Lippincott Williams & Wilkins, Philadelphia, pp793-819.
- [6] Zacchilli MA, Owens BD. Epidemiology of shoulder dislocations presenting to emergency departments in the United States. *J Bone Joint Surg Am.* 2010;92(3):542-549.

- [7] Owens BD, Agel J, Mountcastle SB, Cameron KL, Nelson BJ. Incidence of glenohumeral instability in collegiate athletics. *Am J Sports Med.* 2009;37(9):1750-1754.
- [8] Owens BD, Duffey ML, Nelson BJ, DeBerardino TM, Taylor DC, Mountcastle SB. The incidence and characteristics of shoulder instability at the United States Military Academy. *Am J Sports Med.* 2007;35(7):1168-1173.
- [9] Owens BD, Campbell SE, Cameron KL. Risk factors for posterior shoulder instability in young athletes. *Am J Sports Med.* 2013;41(11):2645-2649.
- [10] Robinson CM, Howes J, Murdoch H, Will E, Graham C. Functional outcome and risk of recurrent instability after primary traumatic anterior shoulder dislocation in young patients. *J Bone Joint Surg Am.* 2006;88(11):2326-2336.
- [11] Kirkley A, Griffin S, Richards C, Miniaci A, Mohtadi N. Prospective randomized clinical trial comparing the effectiveness of immediate arthroscopic stabilization versus immobilization and rehabilitation in first traumatic anterior dislocations of the shoulder. *Arthroscopy.* 1999;15(5):507-514.
- [12] Kirkley A, Werstine R, Ratjek A, Griffin S. Prospective randomized clinical trial comparing the effectiveness of immediate arthroscopic stabilization versus immobilization and rehabilitation in first traumatic anterior dislocations of the shoulder: long-term evaluation. *Arthroscopy.* 2005;21(1):55-63.
- [13] Jakobsen BW, Johannsen HV, Suder P, Sojbjerg JO. Primary repair versus conservative treatment of first-time traumatic anterior dislocation of the shoulder: a randomized study with 10-year follow-up. *Arthroscopy.* 2007;23(2):118-123.
- [14] Nakagawa Y, Hyakuna K, Otani S, Hashitani M, Nakamura T. Epidemiologic study of glenohumeral osteoarthritis with plain radiography. *J Shoulder Elbow Surg.* 1999;8(6):580-584.
- [15] Raymond AC, McCann PA, Sarangi PP. Magnetic resonance scanning vs axillary radiography in the assessment of glenoid version for osteoarthritis. *J Shoulder Elbow Surg.* 2013;22(8):1078-1083.
- [16] Weiss KE, Rodner CM. Osteoarthritis of the wrist. *J Hand Surg Am.* 2007;32(5):725-746.
- [17] Kloppenburg M, Kwok WY. Hand osteoarthritis--a heterogeneous disorder. *Nat Rev Rheumatol.* 2012;8(1):22-31.
- [18] Kwok WY, Kloppenburg M, Marshall M, Nicholls E, Rosendaal FR, Peat G. The prevalence of erosive osteoarthritis in carpometacarpal joints and its clinical burden in symptomatic community-dwelling adults. *Osteoarthritis Cartilage.* 2014;22(6):756-763.
- [19] Kwok WY, Kloppenburg M, Marshall M, Nicholls E, Rosendaal FR, van der Windt DA, Peat G. Comparison of clinical burden between patients with erosive hand os-

- teoarthritis and inflammatory arthritis in symptomatic community-dwelling adults: the Keele clinical assessment studies. *Rheumatology (Oxford)*. 2013;52(12):2260-2267.
- [20] Lawyer TJ, Jankowski J, Russell GV, Stronach BM. Prevalence of post-traumatic osteoarthritis in morbidly obese patients after acetabular fracture fixation. *J Long Term Eff Med Implants*. 2014;24(2-3):225-231.
- [21] Thomas GE, Palmer AJ, Batra RN, Kiran A, Hart D, Spector T, Javaid MK, Judge A, Murray DW, Carr AJ, Arden NK, Glyn-Jones S. Subclinical deformities of the hip are significant predictors of radiographic osteoarthritis and joint replacement in women. A 20 year longitudinal cohort study. *Osteoarthritis Cartilage*. 2014;22(10):1504-1510.
- [22] Hardcastle SA, Dieppe P, Gregson CL, Hunter D, Thomas GE, Arden NK, Spector TD, Hart DJ, Laugharne MJ, Clague GA, Edwards MH, Dennison EM, Cooper C, Williams M, Davey Smith G, Tobias JH. Prevalence of radiographic hip osteoarthritis is increased in high bone mass. *Osteoarthritis Cartilage*. 2014;22(8):1120-1128.
- [23] Weidow J, Mars I, Karrholm J. Medial and lateral osteoarthritis of the knee is related to variations of hip and pelvic anatomy. *Osteoarthritis Cartilage*. 2005;13(6):471-477.
- [24] Takeda K, Hasegawa T, Kiriya Y, Matsumoto H, Otani T, Toyama Y, Nagura T. Kinematic motion of the anterior cruciate ligament deficient knee during functionally high and low demanding tasks. *J Biomech*. 2014;47(10):2526-2530.
- [25] Oberlander KD, Bruggemann GP, Hoher J, Karamanidis K. Knee mechanics during landing in anterior cruciate ligament patients: A longitudinal study from pre- to 12 months post-reconstruction. *Clin Biomech (Bristol, Avon)*. 2014;29(5):512-517.
- [26] Liu H, Wu W, Yao W, Spang JT, Creighton RA, Garrett WE, Yu B. Effects of knee extension constraint training on knee flexion angle and peak impact ground-reaction force. *Am J Sports Med*. 2014;42(4):979-986.
- [27] Markolf KL, Jackson SR, Foster B, McAllister DR. ACL forces and knee kinematics produced by axial tibial compression during a passive flexion-extension cycle. *J Orthop Res*. 2014;32(1):89-95.
- [28] McClelland JA, Feller JA, Menz HB, Webster KE. Patterns in the knee flexion-extension moment profile during stair ascent and descent in patients with total knee arthroplasty. *J Biomech*. 2014;47(8):1816-1821.
- [29] Hayashi D, Felson DT, Niu J, Hunter DJ, Roemer FW, Aliabadi P, Guermazi A. Pre-radiographic osteoarthritic changes are highly prevalent in the medial patella and medial posterior femur in older persons: Framingham OA study. *Osteoarthritis Cartilage*. 2014;22(1):76-83.
- [30] Valdes AM, Suokas AK, Doherty SA, Jenkins W, Doherty M. History of knee surgery is associated with higher prevalence of neuropathic pain-like symptoms in patients with severe osteoarthritis of the knee. *Semin Arthritis Rheum*. 2014;43(5):588-592.

- [31] van der Esch M, Knol DL, Schaffers IC, Reiding DJ, van Schaardenburg D, Knoop J, Roorda LD, Lems WF, Dekker J. Osteoarthritis of the knee: multicompartmental or compartmental disease? *Rheumatology (Oxford)*. 2014;53(3):540-546.
- [32] Fong DT, Hong Y, Chan LK, Yung PS, Chan KM. A systematic review on ankle injury and ankle sprain in sports. *Sports Med*. 2007;37(1):73-94.
- [33] Nelson AJ, Collins CL, Yard EE, Fields SK, Comstock RD. Ankle injuries among United States high school sports athletes, 2005-2006. *J Athl Train*. 2007;42(3):381-387.
- [34] Fong DT, Man CY, Yung PS, Cheung SY, Chan KM. Sport-related ankle injuries attending an accident and emergency department. *Injury*. 2008;39(10):1222-1227.
- [35] Swenson DM, Collins CL, Fields SK, Comstock RD. Epidemiology of U.S. high school sports-related ligamentous ankle injuries, 2005/06-2010/11. *Clin J Sport Med*. 2013;23(3):190-196.
- [36] Hiller CE, Kilbreath SL, Refshauge KM. Chronic ankle instability: evolution of the model. *J Athl Train*. 2011;46(2):133-141.
- [37] Buckwalter JA, Martin JA. Osteoarthritis. *Adv Drug Deliv Rev*. 2006;58(2):150-167.
- [38] Coester LM, Saltzman CL, Leupold J, Pontarelli W. Long-term results following ankle arthrodesis for post-traumatic arthritis. *J Bone Joint Surg Am*. 2001;83-a(2):219-228.
- [39] Lubbeke A, Salvo D, Stern R, Hoffmeyer P, Holzer N, Assal M. Risk factors for post-traumatic osteoarthritis of the ankle: an eighteen year follow-up study. *Int Orthop*. 2012;36(7):1403-1410.
- [40] McKinley TO, Bay BK. Trabecular bone strain changes associated with cartilage defects in the proximal and distal tibia. *J Orthop Res*. 2001;19(5):906-913.
- [41] Stufkens SA, Knupp M, Horisberger M, Lampert C, Hintermann B. Cartilage lesions and the development of osteoarthritis after internal fixation of ankle fractures: a prospective study. *J Bone Joint Surg Am*. 2010;92(2):279-286.
- [42] Tochigi Y, Buckwalter JA, Martin JA, Hillis SL, Zhang P, Vaseenon T, Lehman AD, Brown TD. Distribution and progression of chondrocyte damage in a whole-organ model of human ankle intra-articular fracture. *J Bone Joint Surg Am*. 2011;93(6):533-539.

