

We are IntechOpen, the world's leading publisher of Open Access books Built by scientists, for scientists

4,800

Open access books available

122,000

International authors and editors

135M

Downloads

Our authors are among the

154

Countries delivered to

TOP 1%

most cited scientists

12.2%

Contributors from top 500 universities

**WEB OF SCIENCE™**Selection of our books indexed in the Book Citation Index
in Web of Science™ Core Collection (BKCI)

Interested in publishing with us?
Contact book.department@intechopen.com

Numbers displayed above are based on latest data collected.

For more information visit www.intechopen.com

Classifications and Definitions of Normal Joints

Xiaoming Zhang, Darryl Blalock and Jinxi Wang

Additional information is available at the end of the chapter

<http://dx.doi.org/10.5772/59977>

1. Introduction

The anatomical definition of a joint (articulation) is the location where two or more bones, or any rigid parts of the skeleton, connect with each other. It forms a mechanical support to the skeleton and allows a variety of movements in different ranges between the rigid skeletal elements. Some joints, such as the sutures between cranial bones, allow very little or no movement. Other joints, such as the shoulder and hip joints, allow free movement in a large range [1].

2. Joint classification

Joints differ from each other by their tissue formation, function, structure, and movement.

2.1. Types of joints by tissue formation

When the articulating bones are connected, the connection may mainly involve three types of tissues – fibers, cartilages, or synovial membrane. Therefore, joints are generally classified according to these three tissues.

The fibrous joints are united by dense connective fibers such as the sutures between cranial bones, the interosseous membrane in the forearm, and the socket articulation between the root of the tooth and the alveolar processes of the maxilla and the mandible. The interosseous membrane allows movement between the two articulating bones. This type of fibrous joint is classified as “syndesmoses” (discussed below). The root of the tooth and its alveolar process associate in a manner similar to how a cone-shaped peg fits into a socket. There is very little room to move in this type of joint, which is defined as “gomphosis”.

The cartilaginous joints have cartilage in between articulating bones to form a cartilaginous plate or disc. An example of a primary cartilaginous joint is the epiphyseal plate of a long bone, which disappears after puberty. An example of a secondary cartilaginous joint is the intervertebral disc between each vertebra.

The synovial joint is also called the “diarthrodial joint” and is formed by three basic components – the joint cavity, the joint (articular) cartilage which covers the surfaces of articulating bones, and the joint capsule which is composed of a synovial membrane layer lining up the joint cavity and a fibrous layer outside the synovial membrane. In addition, a synovial joint may have ligaments that form a portion of the fibrous joint capsule or ligaments that exist inside the joint capsule (Figure 1). Cartilaginous discs, such as the menisci in the knee joint, may also be found inside the joint cavity.

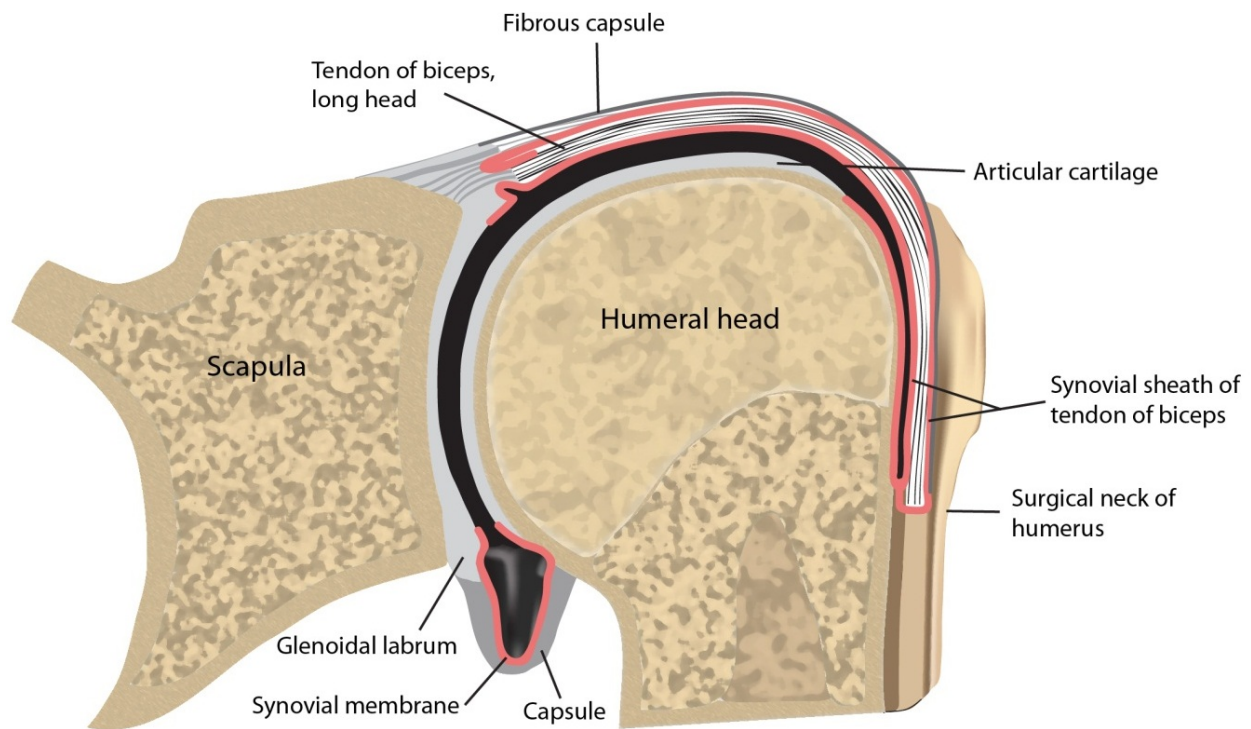


Figure 1. An illustration of the shoulder joint shows that the synovial membrane (red) lines the inner surface of the fibrous capsule. The joint/synovial cavity is marked in black. The tendon of the long head of the biceps passes through the joint and is enclosed in a tubular sheath of synovial membrane, which is continued around the tendon into the intertubercular sulcus as far as the surgical neck of the humerus.

2.2. Types of joints by tissue formation and mobility

Synarthroses joint: A fibrous type of joint that allows very little or no movement under normal conditions. If a joint is formed with an intervening tissue (fibrous connective tissue, cartilage, or bone) in between the two joint forming elements, it is a “synarthroses” joint. This type of

joint usually has limited mobility. The above mentioned suture joints between cranial bones and the gomphosis are synarthroses joints.

Diarthroses joint: If a joint has a space in between the two joint forming elements, it is a “diarthroses” joint. Synovial joints are diarthroses joints and their mobility varies in a large range.

Synostoses joint: This term is used to define when two bones fuse with each other under either normal or abnormal conditions. Normally, cranial bones fuse together when a child reaches adulthood, or when the diaphysis and epiphysis fuses in puberty. Abnormal fusion of bones may occur too early in development such as the early fusion of cranial bones (craniostenosis) or when bones are abnormally joined together such as the synostosis of the cervical vertebrae.

Syndesmoses joint: It refers to fibrous joints containing either an interosseous membrane or a ligament that allows movement. The distal tibiofibular joint is a typical syndesmosis joint.

Synchondroses joint: A cartilaginous joint containing a hyaline cartilage in between the two joined bones. The primary cartilaginous joint with an epiphyseal plate between the epiphysis and the diaphysis of a long bone is a typical synchondrosis joint. The joint between the first rib and the sternum (not including any other ribs) is also a synchondroses joint. However, the intervertebral discs are not considered synchondroses joints because they are composed of fibrous cartilage. They, along with the joint between the pubic bones, are instead referred to as “symphysis” joints.

2.3. Types of joints categorized by structure and movement.

Joints develop into different physical forms. As a result, the structural formation of a joint determines its movement. There are six types of joints in this category and they are all synovial joints (Figure 2).

Pivot type: A round bony process fits into a bony groove permitting rotation. For example, the atlanto-axial joint (between C1 and the Dens of C2 vertebrae).

Ball and socket type: A ball shaped bony head fits into a concavity allowing movement in several axes. The glenohumeral (shoulder) and hip joints are ball and socket type joints.

Plane type: The joint surfaces of both bones are flat against each other. Gliding action in one direction (uniaxial) can happen in this type of joint, for example, the acromioclavicular joint.

Hinge type: A joint forms like a door hinge allowing only one direction (uniaxial) movement, for example, the elbow joint.

Saddle type: The opposing articular surfaces are both saddle shaped. As a result, this type of joint can move in two directions (biaxial), for example, the carpometacarpal joint of the thumb.

Condyloid type: A rounded bony prominence of one bone articulates with a shallow indentation of another bone. This type joint allows two direction (biaxial) movement as well as circumduction, for example, the metacarpophalangeal joints.

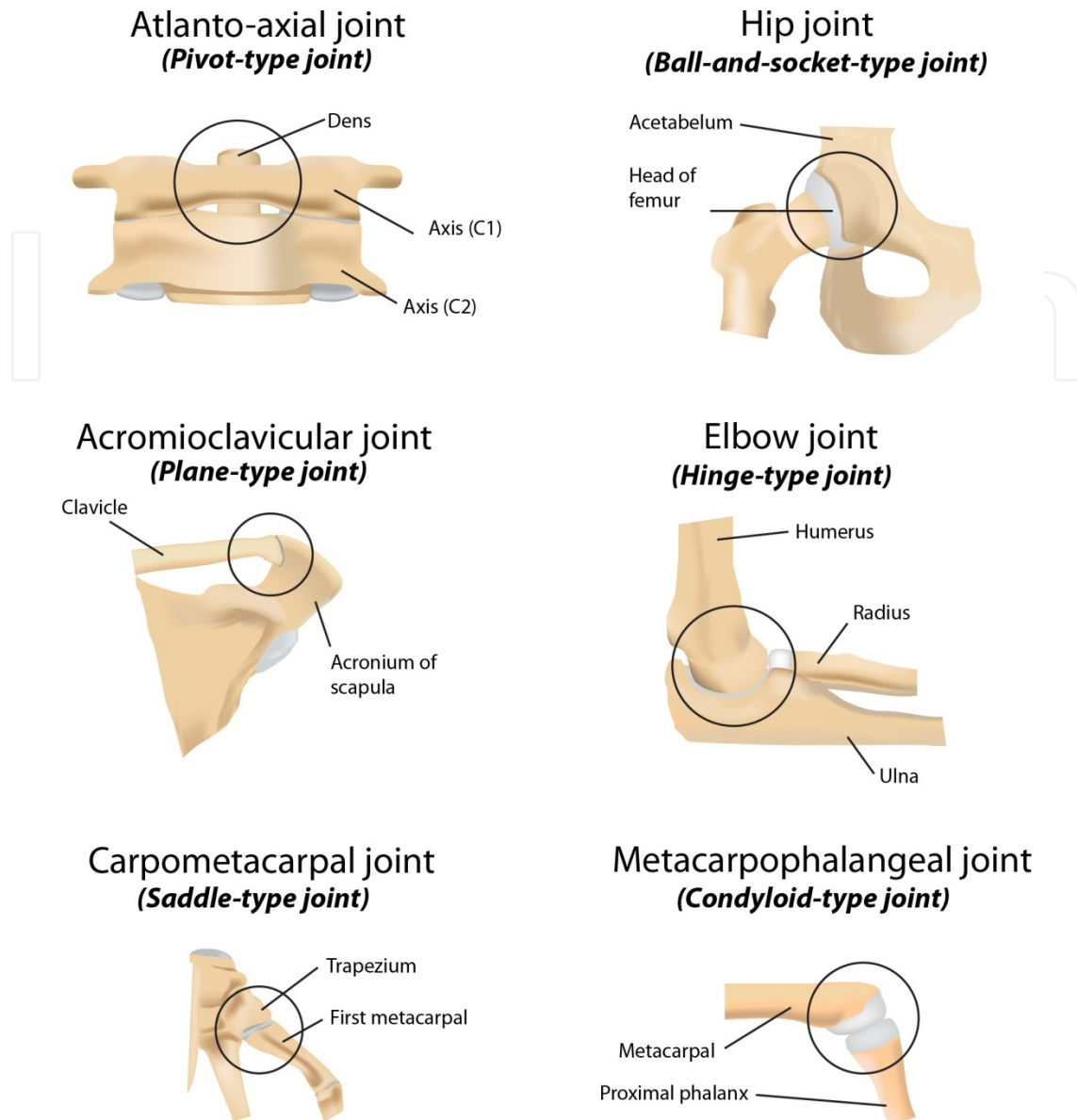


Figure 2. Diagrammatic illustrations show the structural features of six different types of human joints.

3. Cartilage associated with joints

Cartilage is a semi-rigid type of connective tissue composed of cells called chondrocytes and a large amount (>95%) of specialized extracellular matrix. Chondrocytes are scattered among the matrix and located in spaces called “lacunae”.

A primary cartilaginous joint (synchondroses) such as the epiphyseal plate contains hyaline cartilage. The secondary cartilaginous joints (symphyses) such as the intervertebral discs contain fibrous cartilage. In synovial joints, a layer of hyaline cartilage “caps” the articulating surfaces of each joint-forming bone. This particular cartilage is called “articular cartilage”. Articular cartilage provides smooth, low-friction, gliding surfaces for free movement. It also absorbs mechanical impacts placed on the articulating bones [1].

Cartilage is usually covered on its external surface by a thin layer of connective tissue named “perichondrium”. However, perichondrium does not cover articular cartilage, the epiphyseal plate, and cartilage immediately under the skin such as the cartilage at the ear and nose.

Based on the characteristics of its matrix, cartilage is classified as the following and each type has its own different appearance and mechanical property [2].

3.1. Hyaline cartilage

Hyaline cartilage is named such because of the glassy (transparent) appearance of its matrix in living state. The matrix contains predominantly water (60-80%), with type II collagen fibers (~15%), chondroitin sulfate proteoglycan aggregates (~9%), and adhesive non-collagen glycoproteins (~5%) [2]. The highly hydrated matrix is due to the high content of proteoglycans, which allows water molecules to bind and stay. The hydrated matrix permits diffusion of small metabolites and nutrients as well as providing resilience to mechanical pressures during weight bearing. The matrix is made by the chondrocytes, which continuously remodel the matrix throughout life in response to mechanical, chemical, and biological signals. However, as the body ages, this remodeling process slows down or stops, resulting in degradation that surpasses synthesis. This is particularly the case in articular cartilage located in synovial joints.

3.2. Fibrocartilage

Fibrocartilage is a combination of hyaline cartilage and dense regular connective tissue [2]. The chondrocytes in fibrous cartilage appear similar to those in the hyaline cartilage. These cells make various amounts of type I and type II collagen fibers resulting in different proportions of type I and type II collagen in fibrocartilages at different regions of the body. Fibrocartilage can be found in intervertebral discs, pubic symphysis, articular discs inside several joint cavities, and the menisci in the knee joint. There is no perichondrium surrounding the fibrocartilages in these regions. Fibrocartilage functions much like a shock absorber for joints.

3.3. Elastic cartilage

Elastic cartilage is characterized by hyaline cartilage containing elastic fibers with the presence of elastin in its matrix. This type of cartilage is found mainly in the external ear, the wall of external acoustic meatus, the auditory (Eustachian) tube, and the epiglottis of the larynx [2].

4. Definition, structure, and function of joint tissues

4.1. Articular cartilage

Articular cartilage is a highly specialized viscoelastic hyaline cartilage that is found overlying the bone ends in synovial joints and forming the joint surface [3,4]. Articular cartilage has all the characteristics of hyaline cartilage with some additional features of its own.

Human articular cartilage is normally 2-4 mm thick and does not have a perichondrium on either the surface side that faces the joint cavity or the deep side that connects to the bone [3]. It has a limited intrinsic capacity to heal and repair, and is closely related to joint health.

From the joint surface to subchondral bone, a cross section of articular cartilage can be divided into four zones under the microscope (Figure 3).

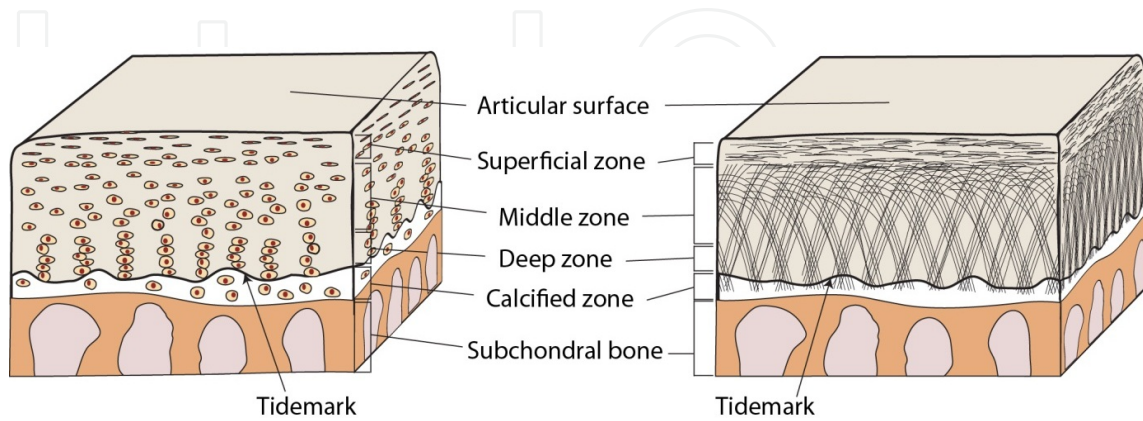


Figure 3. Illustrations showing the zonal features of human articular cartilage and subchondral bone. **Left panel** (chondrocyte organization): The superficial zone chondrocytes are small and flattened, which are orientated parallel to the joint surface. The middle zone chondrocytes are rounded and oriented randomly. The deep zone chondrocytes are grouped in columns or clusters. **Right panel:** Collagen orientation in articular cartilage. In the superficial (tangential) zone, small and medium-sized collagen fibrils aggregate into bundles that are aligned parallel to the joint surface. In the middle and deep zones, collagen fibrils aggregate into larger bundles and are aligned more perpendicular to the joint surface.

The superficial (tangential) zone contains numerous elongated and flattened chondrocytes. These cells are surrounded by dense type II collagen fibril fascicles arranged parallel to the surface [2]. This zone occupies 10-20% of the articular cartilage's thickness and is in contact with synovial fluid. It bears shear, tensile, and compressive forces imposed on the articular surface [3].

The intermediate (middle or transitional) zone is deep to the superficial zone and contains randomly distributed round chondrocytes. Collagen fibers are generally organized in an oblique orientation to the surface. It occupies 40-60% of the thickness of articular cartilage and mainly resists compressive forces.

The deep (radial) zone has round chondrocytes arranged in short columns perpendicular to the joint surface. Collagen fibers located between cell columns are thick and are generally perpendicular to the joint surface. The proteoglycan content is the highest among all the zones while water concentration is low. It occupies about 30% of the thickness of articular cartilage and provides additional resistance to compressive forces [5,6].

The calcified zone contains a small amount of chondrocytes and a large amount of calcified matrix. A smooth and heavily calcified line called the "tidemark" separates this zone from the deep zone. The primary role of the calcified zone is to firmly secure articular cartilage to subchondral bone. This highly organized structure is responsible for the unique mechanical properties of articular cartilage.

In addition to the histologically defined zones, the matrix distribution of articular cartilage is distinguished in three regions [3].

The pericellular matrix is a thin layer adjacent to the cell membrane completely surrounding the chondrocyte. It contains mainly proteoglycans, glycoproteins, and other noncollagenous proteins. This matrix region may function to initiate signal transduction within cartilage.

The territorial matrix is thicker and surrounds the pericellular matrix. It is composed mostly of fine collagen fibrils that form a network around the cells. This region may protect the cartilage cells against mechanical stresses when there are substantial forces loaded.

The interterritorial region is the largest and refers to the collagen fibrils arranged parallel to the surface in the superficial zone, obliquely in the middle zone, and perpendicular in the deep zone. It contributes the most to the biomechanical properties of articular cartilage. The extracellular matrix accounts for approximately 95% of the dry weight of articular cartilage [4]. The primary macromolecule found in articular cartilage is type II collagen, which represents 90-95% of the total collagen content. The remaining are collagen types I, IV, V, VI, IX, and XI. The second largest group of macromolecules is proteoglycans which consist of a protein core with covalently linked glycosaminoglycan chains (GAGs). The main proteoglycans found in articular cartilage include aggrecan, decorin, biglycan and fibromodulin with aggrecan being the most abundant. Negatively charged carboxyl and sulfate groups found on these GAGs, namely keratan sulfate and chondroitin sulfate, have a high affinity for water [2,3].

The renewal process of mature articular cartilage is very slow due to the stable type II collagen structure and the long half-life of GAGs. The matrix degrading enzyme metalloproteinase activity is also low [2,3].

4.2. Synovial membrane (synovium)

Synovial membrane is the inner layer of the joint capsule facing the joint cavity and synovial fluid. The synovium lines the joint cavity producing synovial fluid that lubricates the joint surfaces and provides nutrition to the articular cartilage [7]. The synovial membrane is composed of two layers; the surface layer consisting of one or two layers of synovial cells and the underlying connective tissue layer.

There are two types of synovial cells. Type A synovial cells are macrophage-like cells whereas type B cells are fibroblast-like. These cells secrete hyaluronic acid and glycoprotein molecules, which are part of the synovial fluid lubricating the joint surfaces. There is no basal lamina separating the synovial cells from the underlying connective tissue. This connective tissue contains a rich network of fenestrated capillaries, which allow plasma to flow out of blood circulation and enter the joint cavity. The filtered plasma content combines with hyaluronic acid, glycoproteins, and leukocytes becoming the synovial fluid [8,9]. Normal synovial fluid appears clear to pale yellow in color, transparent, and contains less than 200 white blood cells/ μ l [10].

4.3. Joint capsule

The joint capsule is essential to the proper function of synovial joints. It forms the seal that contains synovial fluid within the joint, imparts passive stability by limiting joint movement, and provides active stability via its proprioceptive nerve endings [11]. It is composed of collagen fibers that are firmly adhered to bone through a fibrocartilaginous attachment. Localized thickenings of the capsule form capsular ligaments that provide strong points of fixation to bone. Tendons commonly attach to the joint capsule and occasionally replace it as is the case with the quadriceps and patellar tendons in the anterior knee. Blood vessels and nerves pass through the joint capsule supplying both the capsule and the underlying synovium. Nerve endings in the joint capsule are thought to be proprioceptive and play an important role in the active protection of the capsule and associated ligaments by reflex control of the appropriate musculature [11].

4.4. Tendon

Tendon is a tough band of fibrous connective tissue that usually connects muscle to bone. Tendons are mainly composed of type I collagen fibers arranged in fascicles and bands. Proteoglycans are primarily responsible for holding the collagen fibrils together. Specialized fibroblast cells called "tenocytes" exist in tendons and are responsible for collagen synthesis in tendon. Tendon is surrounded by a loose connective tissue layer called "peritendineum", which blends with the periosteum when the tendon attaches to the bone [12-14].

At the site of tendon insertion, parallel collagen fibers penetrate through the periosteum and insert into the mineralized fibrocartilage zone of the bone. Elastic fibers function to prevent overstretching and cartilage cells function to resist transverse shortening at the tendon insertion site [15].

Tendons contain some, but not many blood vessels. Enhanced physical activity can increase blood flow in the tendon. In regions where the tendons wrap around bony pulleys, blood supply is largely reduced. Tendons also have nerve supply in various degrees [12].

4.5. Ligament

Ligaments can be defined as dense bands of collagenous fibers that span a joint and are anchored to bone at either end [16]. Like tendon, ligament is made of dense connective tissue consisting mainly of type I collagen. Some ligaments are located outside the joint cavity; others are inside the joint cavity. Some ligaments are discrete structures that stand alone such as the cruciate ligaments in the knee; some are regional thickenings of the joint capsule as a part of the fibrous layer of the joint capsule. The primary function of ligaments is to provide passive stability to a joint through a normal range of motion under an applied load. Bundles of collagen fibrils form the majority of the ligament substance [17]. These fibrils are typically aligned in the direction of tension applied to the ligament during normal joint motion.

The ligament-bone interface is a complex structure that has been described as two distinct insertion types: direct and indirect. Direct insertion involves passage of a ligament directly

into cortical bone. The superficial ligament collagen fibers merge with the fibrous layer of the periosteum while the majority of the insertion consists of deeper fibers directly penetrating the cortex [17]. These deep fibers pass through ligament substance, fibrocartilage, mineralized fibrocartilage and finally into bone. This direct insertion typically occurs at a right angle to the bone. In contrast, indirect insertions typically occur more obliquely. This type of insertion is less common and usually involves a wide surface area of insertion along the bone surface as opposed to directly into the cortex [17]. These insertions are believed to allow gradual transmission of force between ligament and bone.

4.6. Subchondral bone

The bony component lying under (deep to) the calcified zone of the articular cartilage is called subchondral bone, which can be separated into two distinct anatomic entities: subchondral bone plate and subchondral trabecular bone.

The subchondral bone plate is the thin cortical lamella, lying parallel to and immediately under the calcified cartilage. This cortical endplate is a penetrable structure and is invaded by channels that provide a direct link between articular cartilage and subchondral trabecular bone. A number of arterial and venous vessels, as well as nerves penetrate through the channels and send tiny branches into calcified cartilage, communicating between the calcified cartilage and the trabeculae bone [18-20].

Compared to the subchondral bone plate, the subchondral trabecular bone is more porous and metabolically active, containing blood vessels, sensory nerves, and bone marrow. It exerts important shock-absorbing and supportive functions in normal joints and may also be important for cartilage nutrient supply and metabolism [18,19].

Subchondral bone changes are important features of osteoarthritis (OA), suggesting that subchondral bone plays a vital role in the pathogenesis of OA [21-23]. Bone marrow edema-like lesions (BMELs), which are strongly associated with pain among patients with OA, are frequently identified by magnetic resonance imaging (MRI) in patients with progressive OA. BMELs are also observed in the healthy, asymptomatic population and predict an increased risk of OA [24,25].

5. Conclusion

This chapter describes the classification of different types of joints based on their structural and functional features. The anatomical and functional features of six different types of human joints are demonstrated. Definitions and structures of specific joint tissues associated with the function of joints such as the joint cartilage, synovial membrane, joint capsule, tendon, ligament, ligament-bone interface, and subchondral bone are described in great detail. The clinical relevance of specific joint structures to joint injury, joint instability, and the development of OA is discussed at both macro- and micro-anatomical levels.

Acknowledgements

This work was supported in part by the U.S. National Institutes of Health (NIH)/NIAMS grant R01 AR059088, the U.S. Department of Defense medical research grant W81XWH-12-1-0304, and the Harrington Distinguished Professorship Endowment. The authors thank Mr. Brian Egan and Mr. Zhaoyang Liu for their graphic and editorial assistance.

Author details

Xiaoming Zhang¹, Darryl Blalock² and Jinxi Wang²

*Address all correspondence to: jwang@kumc.edu

1 Department of Anatomy and Cell Biology, University of Kansas School of Medicine, Kansas City, USA

2 Department of Orthopedic Surgery, University of Kansas School of Medicine, Kansas City, USA

References

- [1] Moore KL, Dalley AF, Agur AMR.. Introduction to Clinically Oriented Anatomy. In: Moore KL, Dalley AF, Agur AMR (eds.), *Clinically Oriented Anatomy*, 7th ed. 2014; Wolters Kluwer | Lippincott Williams & Wilkins, Philadelphia, p25-29.
- [2] Ross MH, Pawlina W. Cartilage. In: Ross MH and Pawlina W. (eds.) *Histology: A text and Atlas* 6th ed. 2011; Wolters Kluwer | Lippincott Williams & Wilkins, Philadelphia, pp198-217.
- [3] Sophia Fox AJ, Bedi A, Rodeo SA. The basic science of articular cartilage: structure, composition, and function. *Sports Health*. 2009;1(6):461-468.
- [4] Alford JW, Cole BJ. Cartilage restoration, part 1: basic science, historical perspective, patient evaluation, and treatment options. *Am J Sports Med*. 2005;33(2):295-306.
- [5] Curtin WA, Reville WJ. Ultrastructural observations on fibril profiles in normal and degenerative human articular cartilage. *Clin Orthop Relat Res*. 1995(313):224-230.
- [6] Minns RJ, Steven FS. The collagen fibril organization in human articular cartilage. *J Anat*. 1977;123(Pt 2):437-457.
- [7] Firestein GS, Kelley WN. *Kelley's textbook of rheumatology*. 9th ed. Philadelphia, PA: Elsevier/Saunders; 2013.

- [8] Edwards JC. The nature and origins of synovium: experimental approaches to the study of synoviocyte differentiation. *J Anat.* 1994;184 (Pt 3):493-501.
- [9] Vandenabeele F, De Bari C, Moreels M, Lambrichts I, Dell'Accio F, Lippens PL, Luyten FP. Morphological and immunocytochemical characterization of cultured fibroblast-like cells derived from adult human synovial membrane. *Arch Histol Cytol.* 2003;66(2):145-153.
- [10] Thompson JC. Basic Science. In: Thompson JC (eds.) *Netter's Concise Orthopaedic Anatomy* 2nd ed. 2010; Saunders/Elsevier, Philadelphia, p20.
- [11] Ralphs JR, Benjamin M. The joint capsule: structure, composition, ageing and disease. *J Anat.* 1994;184 (Pt 3):503-509.
- [12] Benjamin M, Kaiser E, Milz S. Structure-function relationships in tendons: a review. *J Anat.* 2008;212(3):211-228.
- [13] Connizzo BK, Yannascoli SM, Soslowsky LJ. Structure-function relationships of post-natal tendon development: a parallel to healing. *Matrix Biol.* 2013;32(2):106-116.
- [14] Thorpe CT, Birch HL, Clegg PD, Screen HR. The role of the non-collagenous matrix in tendon function. *Int J Exp Pathol.* 2013;94(4):248-259.
- [15] Schuenke M, Schulte E, Schumacher U. The Muscles. In: Schuenke M, Schulte E, Schumacher U. (eds.) *Thieme Atlas of Anatomy, general anatomy and musculoskeletal system.* 2006; Thieme, Stuttgart, p42.
- [16] Frank CB. Ligament structure, physiology and function. *J Musculoskelet Neuronal Interact.* 2004;4(2):199-201.
- [17] DeLee J, Drez D, Miller MD. *DeLee & Drez's orthopaedic sports medicine : principles and practice.* 3rd ed. Philadelphia: Saunders/Elsevier; 2010.
- [18] Li G, Yin J, Gao J, Cheng TS, Pavlos NJ, Zhang C, Zheng MH. Subchondral bone in osteoarthritis: insight into risk factors and microstructural changes. *Arthritis Res Ther.* 2013;15(6):223.
- [19] Madry H, van Dijk CN, Mueller-Gerbl M. The basic science of the subchondral bone. *Knee Surg Sports Traumatol Arthrosc.* 2010;18(4):419-433.
- [20] Milz S, Putz R. Quantitative morphology of the subchondral plate of the tibial plateau. *J Anat.* 1994;185 (Pt 1):103-110.
- [21] Baker-LePain JC, Lane NE. Role of bone architecture and anatomy in osteoarthritis. *Bone.* 2012;51(2):197-203.
- [22] Burr DB, Gallant MA. Bone remodelling in osteoarthritis. *Nat Rev Rheumatol.* 2012;8(11):665-673.
- [23] Weinans H, Siebelt M, Agricola R, Botter SM, Piscaer TM, Waarsing JH. Pathophysiology of peri-articular bone changes in osteoarthritis. *Bone.* 2012;51(2):190-196.

- [24] Link TM, Steinbach LS, Ghosh S, Ries M, Lu Y, Lane N, Majumdar S. Osteoarthritis: MR imaging findings in different stages of disease and correlation with clinical findings. *Radiology*. 2003;226(2):373-381.
- [25] Wluka AE, Hanna F, Davies-Tuck M, Wang Y, Bell RJ, Davis SR, Adams J, Cicuttini FM. Bone marrow lesions predict increase in knee cartilage defects and loss of cartilage volume in middle-aged women without knee pain over 2 years. *Ann Rheum Dis*. 2009;68(6):850-855.

IntechOpen

IntechOpen