

We are IntechOpen, the world's leading publisher of Open Access books Built by scientists, for scientists

4,800

Open access books available

122,000

International authors and editors

135M

Downloads

Our authors are among the

154

Countries delivered to

TOP 1%

most cited scientists

12.2%

Contributors from top 500 universities



WEB OF SCIENCE™

Selection of our books indexed in the Book Citation Index
in Web of Science™ Core Collection (BKCI)

Interested in publishing with us?
Contact book.department@intechopen.com

Numbers displayed above are based on latest data collected.
For more information visit www.intechopen.com



Role of Implants in Maxillofacial Prosthodontic Rehabilitation

Derek D'Souza

Additional information is available at the end of the chapter

<http://dx.doi.org/10.5772/59578>

1. Introduction

Maxillofacial prostheses play a vital role in comprehensive rehabilitation by restoring physical and psychological well-being in patients with missing or disfigured anatomical structures due to congenital abnormalities, trauma, or disease [1]. It is possible to restore esthetics, function and re-establish the self confidence of the patient by providing a well designed prosthesis such as a prosthetic ear, eye, nose, cranial plate or a combination of these.

The last few decades have witnessed a significant increase in extensive malignancies of the head and neck region [2]. This has resulted in increasing number of patients with extensive post-surgical defects. Many of them need to be suitably rehabilitated to minimize long-term physical, functional and psychological consequences and ensure early return to normal life. In addition, these patients could be more willing to accept large surgical resections, if counseled about prosthetic reconstruction, prior to definitive surgery. It is crucial that all such patients receive a pre-operative referral to a maxillofacial prosthodontist prior to surgery [3].

When these patients report to the maxillofacial prosthetic clinic they report with complex defects and their general health status is also compromised. Achieving adequate retention of the prosthesis, especially when the defect is extensive, is a big challenge and requires a multi-disciplinary approach. With the advent of predictable osseointegration, a new era dawned in the field of prosthodontic rehabilitation of the head and neck region. Cases that were earlier condemned as "hopeless" were suddenly given a new range of options and the chance to be comprehensively restored to form and function. This chapter discusses the role of implants in comprehensive maxillofacial rehabilitation.

2. Retention of maxillofacial prostheses

Historically the means of achieving retention of facial prostheses has been primarily by use of medical adhesives or by means of anatomical or mechanical retention using various devices such as spectacles, springs, studs, clips or magnets [3]. An ideal adhesive should be one that provides firm functional retention under flexure or extension during speech, facial expressions, and moisture or perspiration contact, however such an adhesive is not yet available. Facial prostheses may additionally be retained by judicious use of anatomic tissue undercuts, thereby minimizing the displacement potential caused by other external forces. There is a potential for tissue irritation with use of this technique and due care and regular follow up is a must. Special care is warranted where tissues have been previously irradiated.

2.1. Cellular level changes of osseointegration

It is necessary to have a clear concept about the science of implantation and the healing of bone following a successful implant placement. Osseous healing along an implant follows a similar process to fracture healing but is subjective to the nature of the surface of the implant [4]. As soon as blood comes into contact with the surface of the implant, proteins adsorb to it, platelets get activated and bind to the adsorbed protein which results in the formation of a clot. This coagulum at the implant surface supports the deposition of proteins, releases inflammatory mediators and initiates new tissue formation. The release of numerous signaling molecules influence the migration of monocytes, neutrophils (both involved in inflammation), and mesenchymal cells (cells that can differentiate into osteoblasts) towards the implant surface [4]. Following the aggregation of neutrophils and macrophages from nearby capillary beds to the implant site there is further release of inflammatory mediators which are necessary for the initiation of osteogenesis. Components of tissue growth factor β (TGF- β) super-family are also expressed within 24 hours of implantation, including bone morphogenetic proteins (BMPs) and growth & differentiation factors (GDFs). These signaling molecules result in the collection, migration, and differentiation of mesenchymal cells, which take part in the formation of woven bone. Woven bone subsequently undergoes a sequence of remodeling, resulting in the formation of mature bone which is the desired end result [5].

2.2. Implant surface modifications

Various surface modifications are being commercially marketed since the days of the first Brånemark implants [6]. Grit-blasting and acid etching still remain the most commonly employed surface modification techniques in use today. Sand blasting increases the surface area of the implant as compared to machined surfaces. The resultant increase in surface area has been shown to improve cell attachment and proliferation which results in increased implant stability [7–10]. Electrochemical anodization is another chemical surface modification method that has been employed. This process increases surface micro-texture and also modifies the chemistry of the implant coating resulting in a titanium oxide layer that is several orders of magnitude thicker than a passivated surface [11, 12]. The addition of a ceramic coating to the roughened surface is another method of improving osseointegration. Here a plasma

sprayed hydroxyapatite (HA) coating is used to create an irregular surface for osseointegration. The process involves blasting the implant surface with HA particles at a high temperature. The result is a coating that develops cracks as it rapidly cools. These coatings show enhanced bone-to-implant contact initially, *in vivo*, however the mechanical properties of the bone-coating interface has exhibited non-uniform degradation in the long term [13-16].

In other alternatives, crystalline deposition of nano-sized calcium phosphate and addition of a fluoride treatment to roughened titanium surfaces have also been tried with varying success [17-19]. While several advances in surface modification have been made in order to improve implant osseointegration, no treatment addresses the issue of reducing infection. While some manufacturers claim to be bacteria-proof due to their tight interlocking, the implant itself does not prevent bacterial attachment which can lead to formation of biofilms and subsequent implant failure [20, 21].

2.3. Craniofacial implants

In order to obtain predictable craniofacial osseointegration, different protocols had to be developed. It was necessary to have certain modifications as compared to the oral implants. These implants were made from titanium alloys and were generally shorter i.e. 3 – 5 mm long, threaded and with the same machined surface as the oral implants. It was further found important to attach a flange in the coronal part of the fixture [Figure 1]. The reason for this was the idea that even if the implant was subjected to a longitudinally directed trauma, the flange would prevent it from being pushed into the deeper structures. This has also proved to be a safe and secure measure, as several trauma cases have occurred, but only a minority have caused fractures of the skull bone, and none have caused severe damage [22].




Figure 1. Design of craniofacial implants

The first abutment that was originally used was also of an intraoral type, but with time, extra-oral abutments of different types were developed. These include abutments for the bone-anchored hearing aid (BAHA) and abutments for bone-anchored epistheses (BAE). The length of the fixtures to be used is determined by the thickness of the cranial bones. In a normal adult

the temporal bone has a thickness of approximately 4 mm. This is also the length of the most commonly available implants. It may be possible to install longer fixtures in the frontal bone, zygoma and maxilla. The skin over the abutments has to be reduced to a minimum. This is to prevent constant discomfort or trauma experienced by the patient when the prosthesis will move. Patients who have split skin grafts around the implant abutment show the least skin penetration problems [22, 23].

In pediatric cases the skull bone is much thinner, sometimes barely 1–3 mm thick. In these cases a different approach is necessitated. A simple technique is by the utilization of a semi-permeable membrane at the first stage surgery [24]. By utilizing this technique, 1–2 mm bone can be gained during a 6-month healing period, thus making it possible to install a 4-mm long fixture also in children. The semi-permeable membrane is then removed at the second stage surgery.

Osseointegration in irradiated bone was early believed to be contraindicated. Patients who are recovering from various forms of cancer need comprehensive rehabilitation and can benefit a lot from the use of osseointegrated implants. Clinically though there were higher failure rates along with certain other problems such as dehiscence of the soft tissue as well as osteoradionecrosis [25]. Taking into consideration that the irradiated bone will take longer to heal it is advisable to first delay the placement of the implant and also to allow 4 to 8 months for osseointegration. Another approach is to expose the patients to adjunctive hyperbaric oxygen therapy (HBO). HBO has been shown to accelerate healing and also prevent osteoradionecrosis [26, 27]. In 2013, de Oliveira, Abrahão and Dib [28] however found that there is no difference in implant success between irradiated and normal bone. Keeping all things constant and knowing the risk factors involved it seems to be better to ensure all precautions are maintained in case selection, implant placement and also to ensure that the patient receives HBO therapy to reduce failures in patients who have received some form of radiotherapy and/or chemotherapy.

2.4. Factors of importance for predictable osseointegration

There are six factors of importance that must be carefully monitored to ensure predictable osseointegration [29–31].

Material of the fixture-Titanium alloys are the most commonly used as these are known to integrate in the bone without causing adverse effects. It can remain incorporated into the bone for many decades, and be used as anchorage for different prostheses.

Macrostructure of the implant-A screw-shaped implant ensures better primary stability as compared to a conical shaped implant. This may be due to micro-movements of the conical shape and reduced osseointegration.

Microstructure of the implant-Original Brånemark implants had a smooth surface as they were manufactured by machining. Clinically however it has been observed that very smooth surfaces have lesser degree of osseointegration, along with minor amount of resorption. On the other hand a highly roughened surface shows rapid integration; but later secondary

inflammation and secondary resorption is noticed that can endanger the long-term survival of the implant.

Osseous bed into which the implant is placed-Geriatric patients with bone that is osteoporotic will show lesser degree of osseointegration. Similar is the case of patients who have had radiotherapy or who have sustained severe burns that alter the osseous quality and reduce its capacity for osseointegration.

Surgical technique – The surgical intervention should be carefully monitored with slow speed, high torque and copious irrigation with cold water. The temperature should never be allowed to rise as the osteoblasts are extremely heat labile and get damaged easily. The implant itself should never be touched by gloves or gauze. It is vital that the surgical bed be free from fibers, powder and any other foreign matter that might hinder osseointegration.

Loading the implant – The implant should be loaded along its long axis as far as feasible. Lateral, torsional or cantilever forces are least tolerated and should be minimized by efficient planning and design.

2.5. Retention of maxillofacial prostheses and craniofacial implants

With the increased use of osseointegrated implants, dependence on adhesive and anatomic methods of retention has diminished. Magnets or clips can be used to effectively retain the prostheses [Figure 2] and will also minimize force transfer to the implant and supporting bone. The resultant decrease in dependence on chemical (adhesives) and anatomic (tissue undercuts) retention is beneficial to both the patient and the prosthodontist [31 – 35].

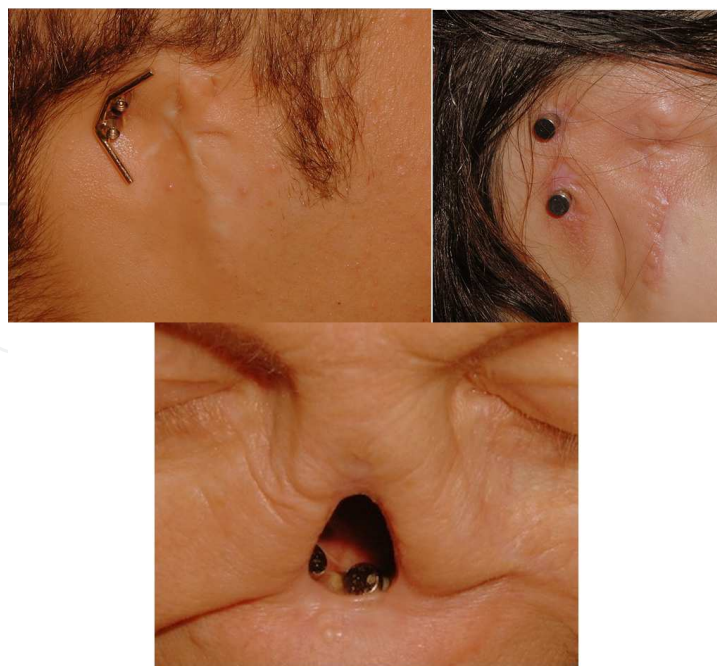

Figure 2. Different retention options for attachment of craniofacial prostheses

Craniofacial implants require adequate osseous thickness of the bone on the temporal and mastoid regions, for example in the rehabilitation of a case of congenital microtia. Thus, implant placement may not be as ideal in normal situations or with acquired defects from accidents. Other designs may also be provided if the distance between the two implants is too close or too far apart. Other crucial factors in rehabilitating this type of defect are marginal fit, good retention, and acceptable esthetics. Various studies have shown that retention using craniofacial implants has improved the satisfaction of patients with craniofacial prostheses. However, the actual level of satisfaction depends, to a large extent, on the location or type of defect, sex, and age of the patient [36 – 38].

3. Orbital prosthesis

In order to address the area of rehabilitation of the orbit it is vital to understand the different types of surgical techniques used in ophthalmic surgeries. Evisceration, enucleation, and exenteration are the three main surgical techniques by which all or parts of the orbital contents are removed [39]. Evisceration is the removal of the contents of the globe while leaving the sclera and extra-ocular muscles intact. Enucleation is the removal of the eye from the orbit while preserving all other orbital structures. Exenteration is the most radical of the three procedures and involves removal of the eye, adnexa, and part of the bony orbit.

Evisceration is usually indicated in cases of endophthalmitis unresponsive to antibiotics and for improvement of esthetics in an eye that is damaged and has lost its vision. Enucleation is indicated for the above two conditions as well as for painful eyes with no useful vision, malignant intraocular tumors, in ocular trauma to avoid sympathetic ophthalmia in the second eye, in phthisis with degeneration, and in congenital anophthalmia or severe microphthalmia to enhance development of the bony orbit. Exenteration is indicated mainly for large orbital tumors or orbital extension of intraocular tumors [39].

The first two namely evisceration and enucleation can be easily rehabilitated with excellent cosmetic results using custom made ocular prostheses [1, 3]. These are fabricated after custom made impressions using silicone impression materials and can be retained fairly well if the eyelids and ocular muscles are intact [Figure 3 – 5]. If required then additional soft tissue components may be fabricated using silicone elastomers which can be shaded and colour matched to the skin of the subject. They may be retained with suitable eye-frames or by use of local undercuts and adhesives [1, 3].

Exenteration surgical procedures are far more extensive and need expert and multi-specialty approach for rehabilitation. Post operatively when the patient reports for rehabilitation it may be necessary to advise the patient to undergo an additional surgical procedure to deepen the existing socket or for thinning of the skin flaps used for the initial wound closure. This will ensure better cosmetic outcome as there will be adequate space to accommodate the retentive framework, ocular component as well as the bulk of silicone elastomer. These large prostheses do not function well with adhesives or eye glasses alone [Figure 6 – 8]. Application of implants in these large orbital defects reduces the need for adhesives and enables easy insertion and

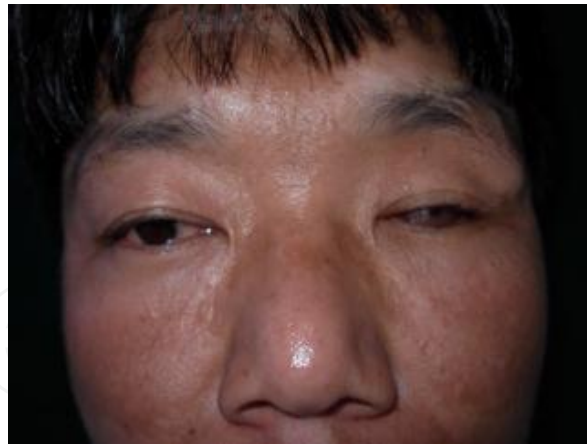

Figure 3. Ocular Defect Left eye

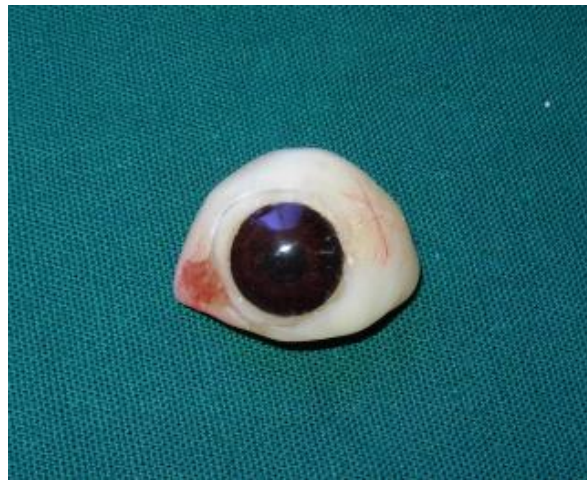

Figure 4. Custom-made ocular prosthesis

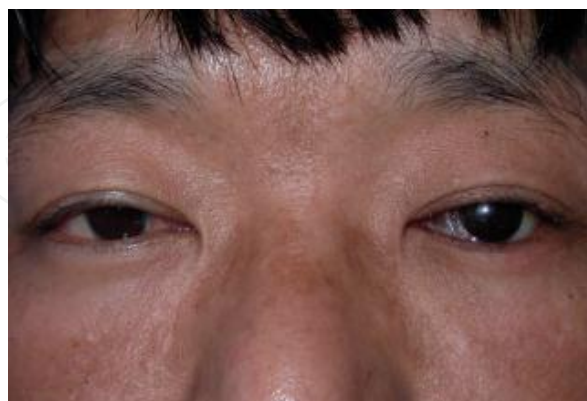

Figure 5. Customised orbital prosthesis *in situ*

removal of the prosthesis. Patients can easily remove the prosthesis when not in use and also replace it quickly and effortlessly [39 – 41].

The ideal locations where craniofacial implants may be placed are the supero-lateral rim and the infero-lateral rim. The implants are placed in such a manner that they project into the defect space. The advantage of this is that the boundaries of the prosthesis can conceal the retentive mechanism effectively. It is advisable to place at least three implants both in the upper and the lower orbital rims. This ensures adequate retention even if one or more implants fail. In case the patient has received irradiation as part of the onco-therapeutic process they need to be advised hyperbaric oxygen therapy as described earlier [25 – 27]. The bony architecture in this region is mostly cortical and therefore shorter implants may be used. It is advisable to wait for 6-8 months for complete osseointegration before the implants are uncovered. The eye prostheses gain maximum retention by use of Neodymium magnets housed in a carrier superstructure within the orbit. Due to the natural shape of the orbit being oval, the abutments, once placed on the implants, will converge toward the center of the orbit. It is therefore important to allow for adequate space of at least 1cm apart between the implants during the surgical phase so that the abutments do not contact thereby interfering with the superstructure.

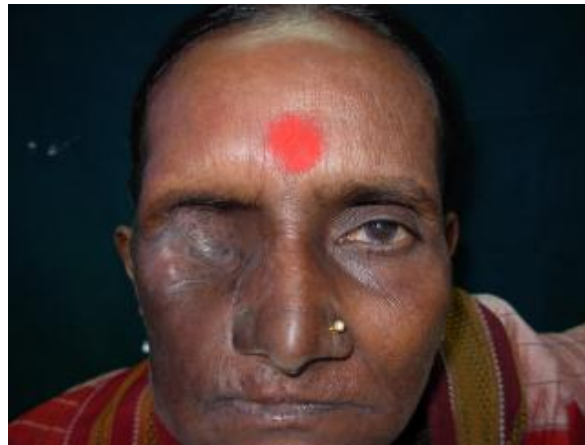

Figure 6. Post-exenteration orbital defect



Figure 7. Custom-made orbital prosthesis



Figure 8. Orbital prosthesis retained with spectacles

After the abutments are attached the fabrication of the prosthesis may be carried out by the maxillofacial prosthodontic team. The margins of the prosthesis may be thinned to ensure better esthetic outcome. Simple frames may also be used so that the borders are concealed [Figure 8]. Patients need to be kept on regular follow-up protocol for any changes in the implants, skin or colour changes in the prosthesis itself [39, 41].

4. Nasal prosthesis

The nose and its adjacent structures play a vital role in facial esthetics. Unlike other facial structures it cannot be easily hidden or camouflaged and hence any person with a congenital or acquired defect looks for early rehabilitation. Small defects are best reconstructed by the plastic surgeon but when both bone and soft tissue have been lost as a result of malignancy related surgeries or due to severe mid-face trauma, then other alternatives are required [1, 42]. Retention using less invasive methods such as the use of tissue or bony undercuts or mechanical with spectacles has been tried with limited success. Even though it may be a challenge, the use of osseointegrated fixtures will ensure excellent retention and esthetic outcome. Ideally three implants need to be placed for adequate retention. It is recommended that a triangular placement around the residual nasal aperture be used. Two implants should be placed at the area of alar base in a vertical line drawn downward from the medial canthus of each eye. One additional implant is placed at the nasal bridge in the midline inferior to the

frontal sinus to complete an isosceles triangle [Figure 9]. The implants at the alar base should project out at 90° to surface. The implant at the midline of the nasal bridge should project downward 30° or at the same angle as the nasal bones project from frontal bone [43].

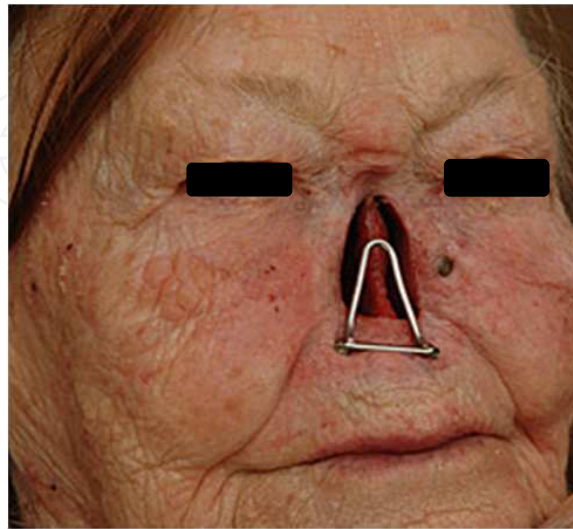


Figure 9. Nasal defect with bar attachment on three implants



Figure 10. Nasal prosthesis in situ

The prosthetic superstructure is fabricated in silicone and retained with the help of clips or magnets [Figure 10] within the prosthesis that engage a metal bar connecting the implants [1, 3]. The connector framework ensures even force distribution over all the three fixtures. In certain cases where there is complete or partial loss of the maxilla and associated midfacial

structures, the nasal component may be magnetically connected to the intraoral obturator [Figure 11] thus providing mutual retention to each other [44 – 46]. The use of spectacles once again distracts the observer's vision from the borders between the skin and the prosthesis and ensures better esthetic outcome [1, 3].

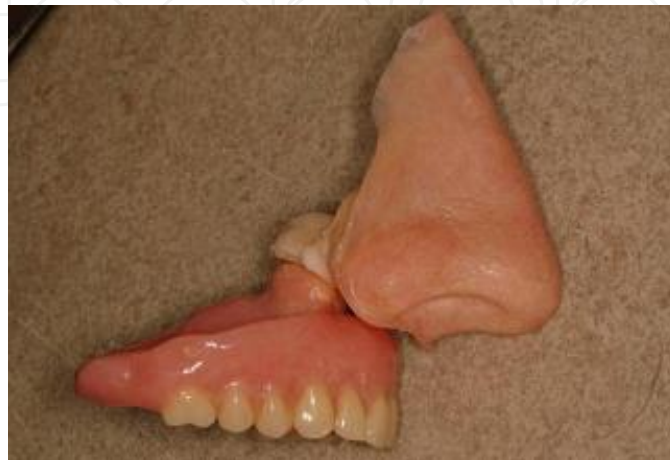

Figure 11. Nasal and maxillary obturator prosthesis connected with magnets

5. Auricular defects

The auricle may be congenitally malformed as in microtia or may be disfigured as a result of trauma following road traffic accidents, burns, acid attacks, or animal or human bites. Surgically they may be removed due to local malignancies. Plastic surgeons may attempt an autogenous reconstruction of the external ear but it is extremely challenging and technically demanding. In contrast an esthetically pleasing and excellent shade matched auricular prosthesis may be fabricated from acrylic polymers or from silicone elastomers [Figure 12 – 15]. The main problem with these prostheses has been their retention. Traditionally tissue undercuts, mechanical retention with springs, clips, hairpieces and adhesives have been used to hold them in place [3]. These have serious limitations as retention is not very strong and can be dislodged by daily activities of life [47 – 50].

Once again osseointegrated implants have proven to be a boon and are presently the method of choice. In these cases two or three implants placed external to the external auditory meatus in the temporo-mastoid region are sufficient [Figure 16]. Implants placed to retain a prosthetic ear are limited in length by the thickness of the mastoid and temporal bones as well as the mastoid air cells. Positioning of implants in the temporal bone is critical to the overall esthetic result and so the use of a surgical guide is mandatory. In cases of microtia or where there are

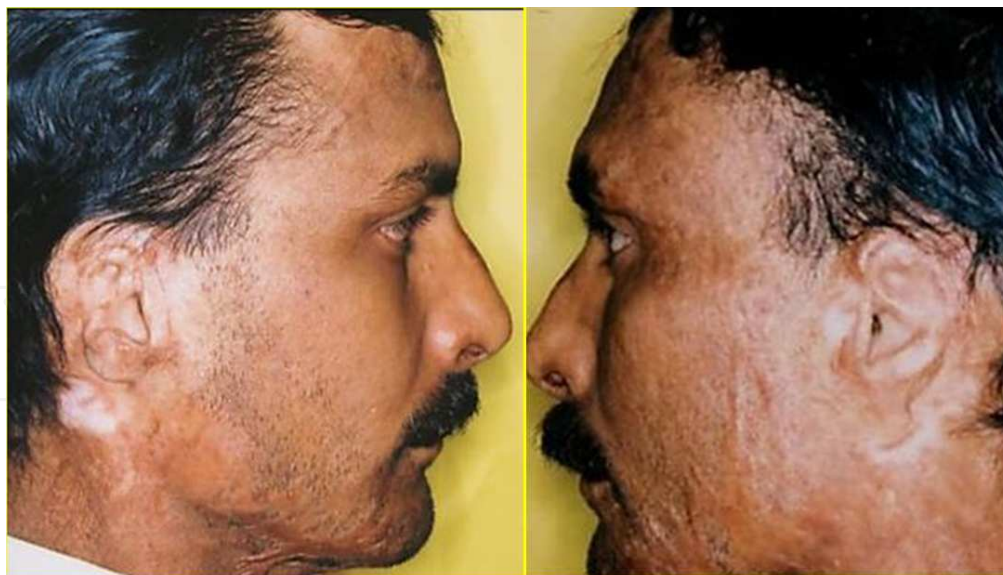

Figure 12. Bilateral auricular defect following severe burns

a malformed tissue tags it may be beneficial to have them surgically removed prior to the start of the rehabilitation process [48, 51].

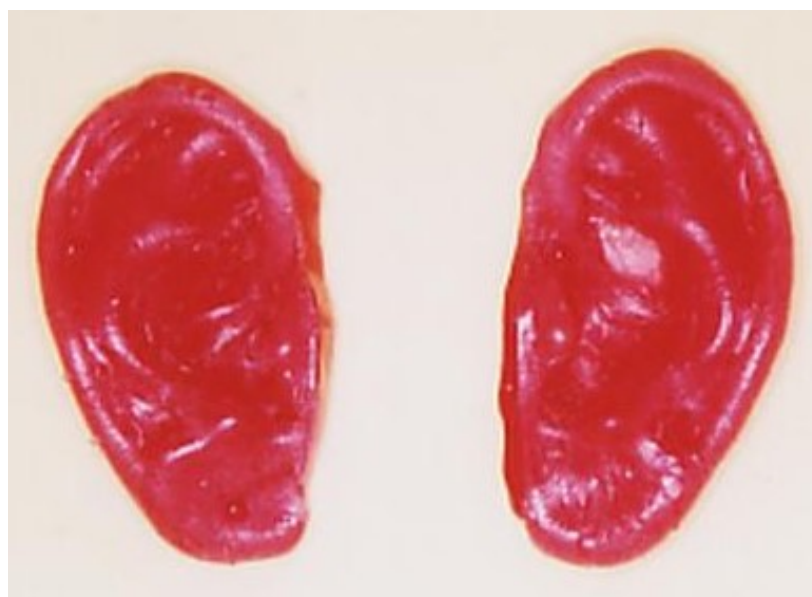

Figure 13. Wax patterns of ear prosthesis

The maxillofacial prosthodontist should fabricate a diagnostic wax-up of the proposed prosthesis replicating the anatomic features of contra-lateral ear and properly positioned to provide facial symmetry [51]. Using the wax pattern a surgical guide is then replicated with acrylic resin or vinyl acetate. The guide should indicate the most optimal location for implant placement. The implants are usually related to the anti helix of the external ear. In this position

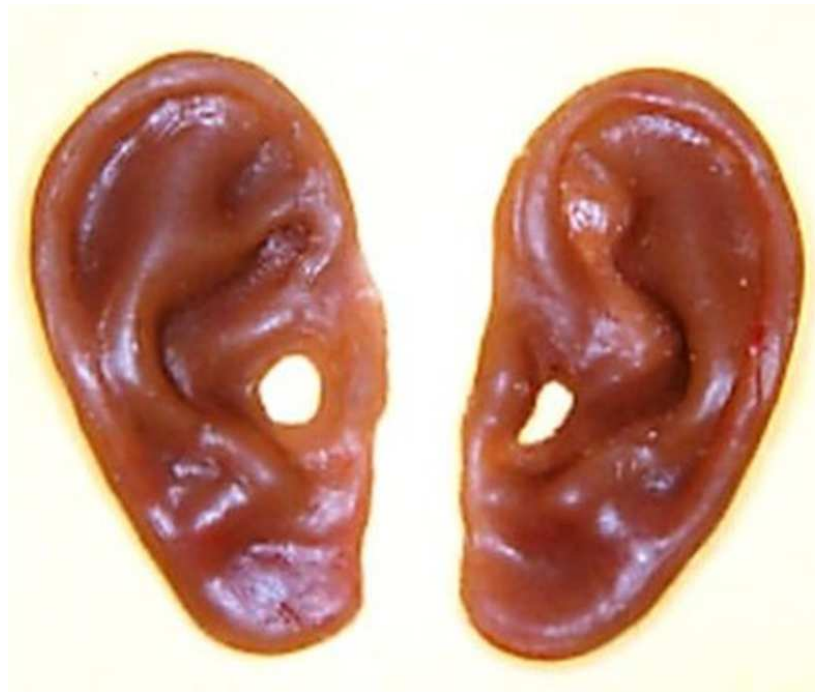

Figure 14. Finished and polished silicone ear prostheses

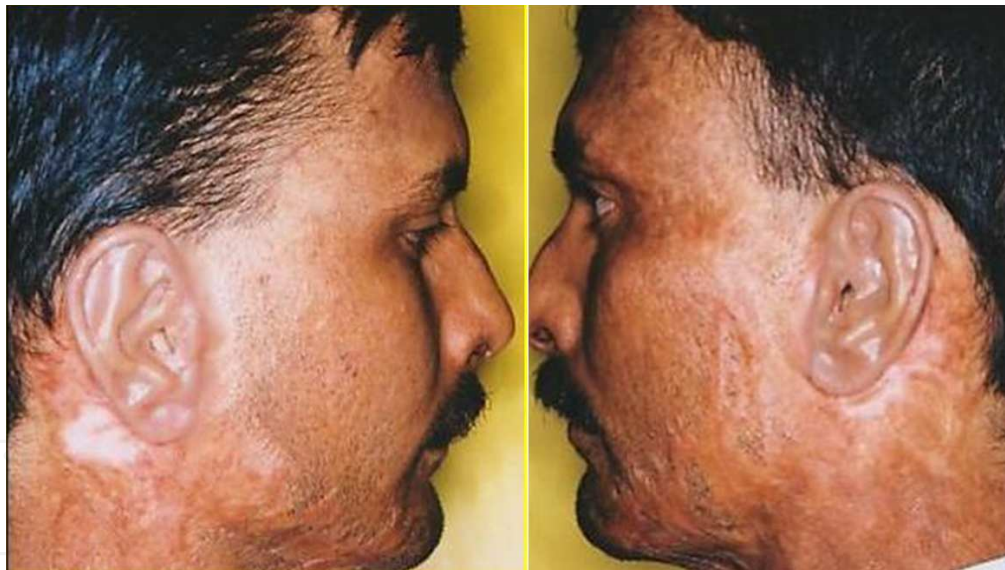

Figure 15. Bilateral auricular prosthesis (mechanically retained)

the exposed implants and the retention system have the best opportunity to be hidden from view. Two retention systems using either metal bars of 2 mm diameter soldered to metallic cylinders or retention clips may be used separately or in combination [Figure 17, 18]. The fabrication steps of the silicone prosthesis follow the routine steps as for other external prostheses. The advantage of having long hair to hide the margins is an added advantage. Cleanliness and proper maintenance is a must and should be ensured at follow-up [51 – 54].

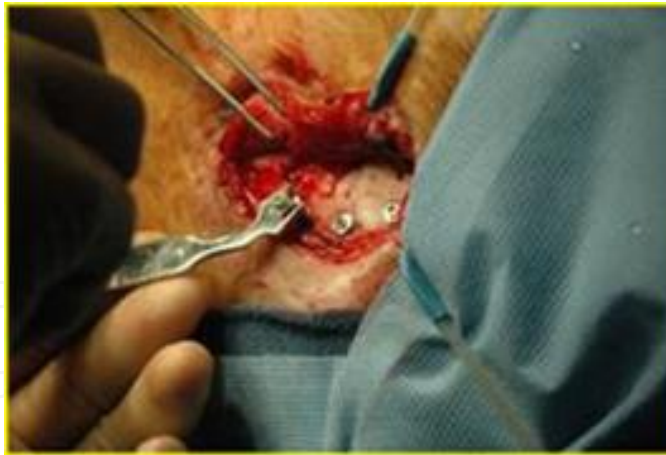

Figure 16. Craniofacial implants placed for ear prosthesis

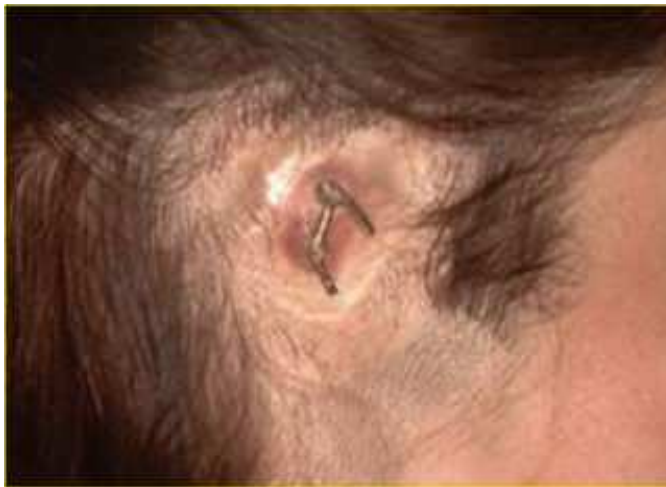

Figure 17. Bar retainer connected to the abutments

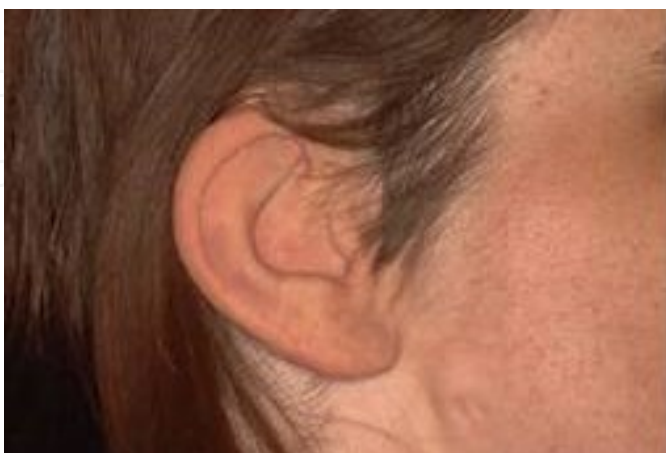

Figure 18. Implant retained ear prosthesis in situ

6. Management of the dentate maxillectomy patient

The dental health status of the patient is the first consideration when planning for prosthetic implantation. Preservation of all possible teeth and vigorous dental hygiene are important in the preoperative period to reduce problems in the postoperative period, when cleaning will be difficult if not impossible. The decision to remove maxillary teeth may come into question if the patient may receive pre and post-operative radiation. It is felt by most prosthodontists that the potential risk of osteoradionecrosis resulting from dental treatment in the maxilla is minimal. Each tooth that can be saved has tremendous potential value as an abutment for the obturator prosthesis. Therefore, all teeth should be retained except those that are grossly carious and cannot be restored by any means [55]. In addition to assessment and preservation of teeth, it is important to obtain maxillary and mandibular casts in the pre-operative period. Two maxillary casts should be obtained; one to be used as a permanent record, and the other for reproduction of the anticipated surgical defect to be used as a guide for fabrication of the prosthesis. One copy of the pre-operative cast should be kept at all times and further duplication done if so required.

Various designs of intra-oral prostheses are possible keeping in mind the principles as applicable for removable cast framework partial dentures. Where required other forms of additional retention are possible using the myriad commercially available intra-coronal or extra-coronal precision attachments. These should suffice to provide a prosthesis that is functionally stable and acceptable to the patient [55 – 58].

6.1. Obturators

Various types and designs of obturators may be planned. Based on the time of placement they can be classified as: surgical, interim and definitive. Surgical obturators are those that are placed immediately after surgery. Although there has been some disagreement about the value of surgical obturators, they do offer distinct advantages for the surgeon and the patient.

Design of the surgical obturator is a challenge, and involves communication between the surgeon and the prosthodontist. The preoperative plan should be discussed, and actual anticipated defects should be clearly marked on the preoperative cast. Areas that will definitively be resected should be outlined, as well as areas that may be involved. The type of retention method that the surgeon prefers should be communicated prior to surgery [56, 59]. Retention holes in the acrylic plate should be created on the defect side so that the edges can be sutured immediately after surgery to the cheek to support the surgical pack *in situ* [Figure 19, 20].

Interim obturators are those prostheses which are placed immediately after removal of the surgical packing and should be used until tissue contracture is minimal [Figure 21 – 24]. Time between removal of the pack and obturator placement should be minimal, as tissue contraction and edema will quickly alter the shape of the defect, making it difficult to insert an obturator. For this reason, it is important to have a post-surgical obturator made prior to removal of packing. It is also important that the prosthodontist be present with the surgeon when packing

is removed so the prosthesis can be inserted immediately after inspection of the surgical site by the surgeon [59].

The definitive obturator is designed when the surgical defect has stabilized, approximately 3 to 12 months after definitive surgery [Figure 25]. The bulb portion that extends into the defect area must be kept hollow in order to lessen the weight of the prosthesis [Figure 26]. The design of the prosthesis should allow maximal distribution of forces to all available teeth, remaining hard palate, walls of the defect, and areas of remaining alveolus. In addition, occlusion must be restored to the best extent possible so that the prosthesis can be functional and not just cosmetic. Regular follow-up is mandatory and modifications should be carried out as required. The prosthodontist must be careful to note signs that the obturator is no longer functioning, such as fluid reflux into the nasal cavity, change in voice quality or TMJ problems [56, 59].

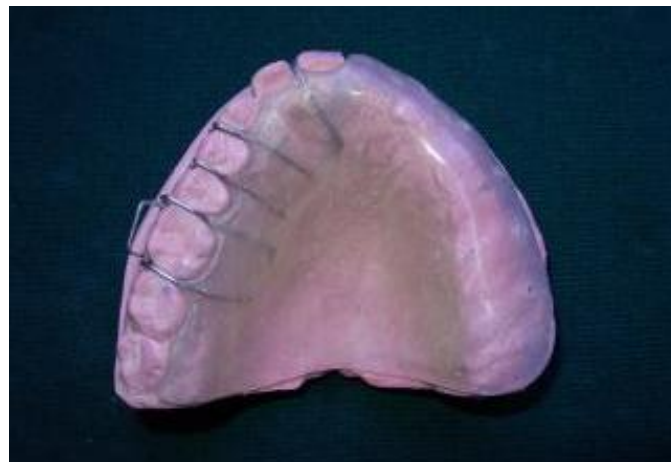

Figure 19. Surgical obturator with retentive holes on surgical side (left)

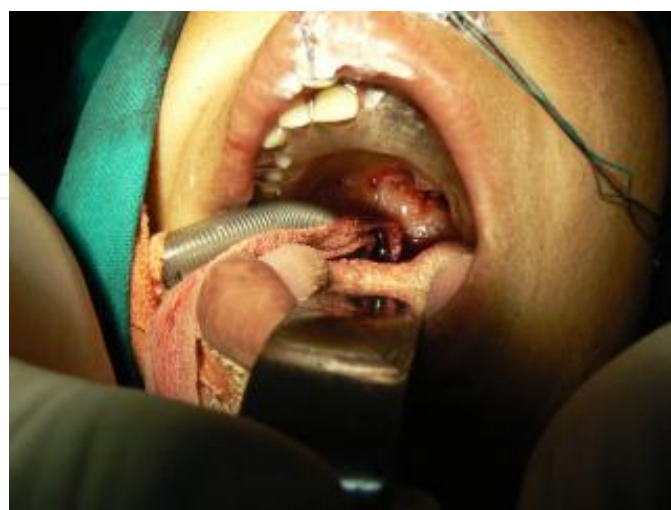

Figure 20. Surgical obturator fixed in situ immediately following surgery

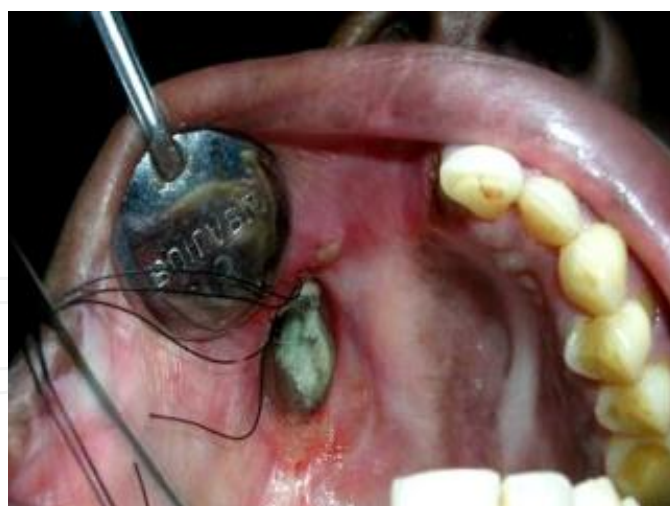

Figure 21. Healed maxillary defect (mirror image)



Figure 22. Impression made in irreversible hydrocolloid

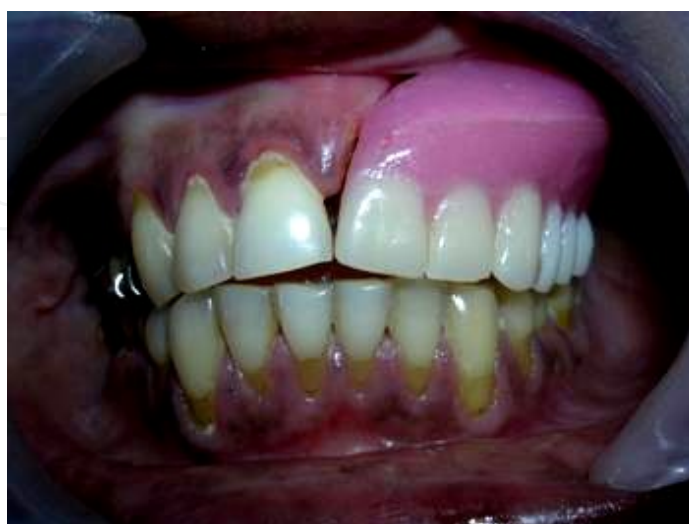

Figure 23. Try-in of maxillary obturator prosthesis

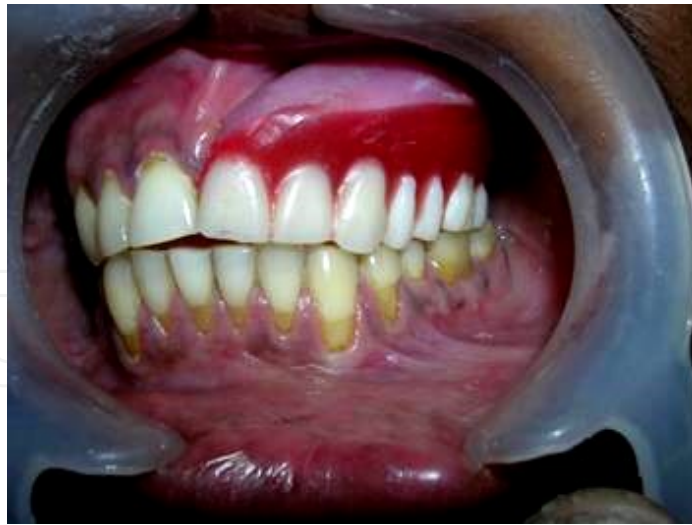

Figure 24. Interim obturator prosthesis in situ

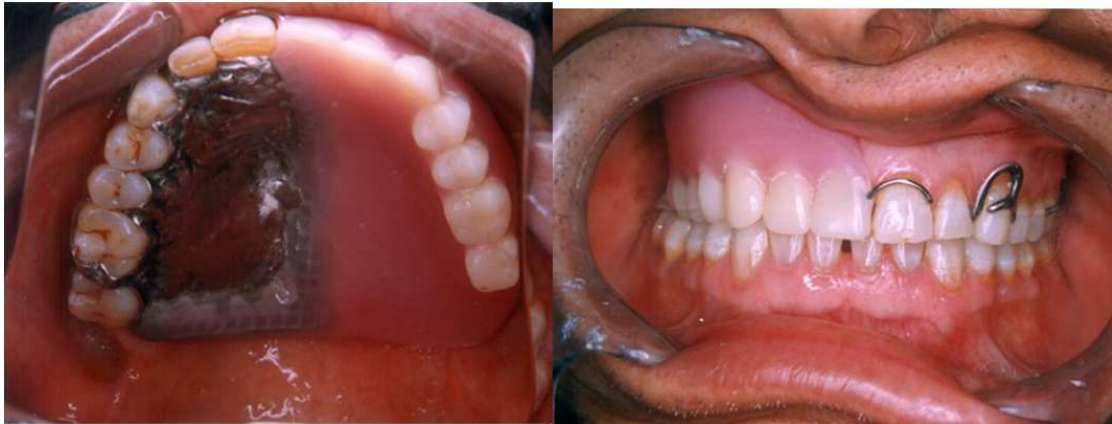

Figure 25. Definitive obturator prosthesis in situ

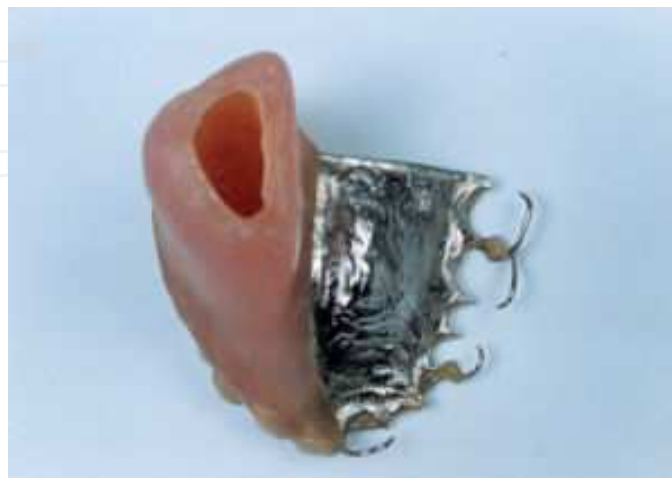

Figure 26. Definitive obturator prosthesis showing hollow bulb

6.2. Management of the edentulous maxillectomy patient

Edentulous maxillectomy patients are always a challenge for the maxillofacial team due to the complexity of postoperative rehabilitation. Retention of the obturator is a problem since there is a lack of support of adjacent teeth for stabilization. In addition, the reduced volume of residual ridge of the edentulous patient demands that stress be distributed to all available portions of the palate.

Some of the important guidelines to be informed to the maxillofacial surgeon or oncosurgeon at the time of resection are as follows:-[59-62].

Maintain as much hard palate as possible. Since the edentulous patient must rely on remnants of the hard palate for primary retention, support and stability, the prosthodontist should advise the surgeon to resect only that portion of the hard palate that is mandatory to allow for clean margins [Figure 27]. It is vital to ensure that the ipsilateral palate is preserved which will allow a tripod effect. If the anterior alveolus can be maintained, the patient will have better facial esthetics and less contracture postoperatively.

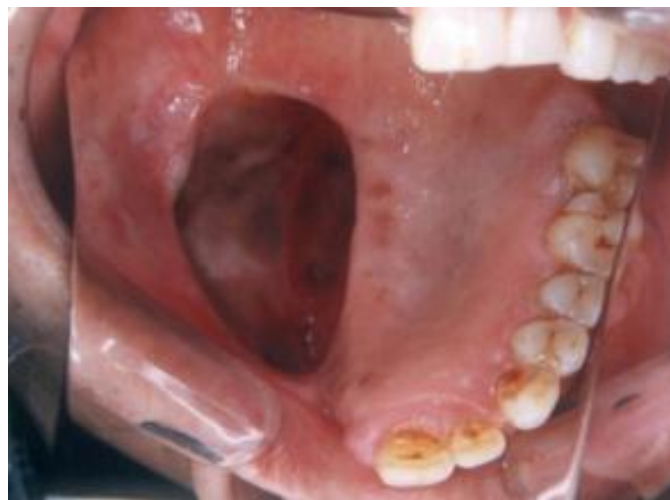

Figure 27. Maximum retention of hard palate (mirror image)

Skin graft the cheek flap The edentulous patient requires maximal distribution of forces, and the mucosa on the cheek will be an area of contact with the obturator. The thick squamous epithelium of a split-thickness skin graft will resist the wear and tear applied by the obturator as compared to the friable oral tissues.

Remove the inferior turbinate. By removing the inferior turbinate, the prosthesis can be contoured to fit into the nasal cavity. This vertical height will resist the rotational forces applied during mastication. In addition, by adding an extension into the nasal cavity, a larger surface of bone may be utilized to balance the stresses generated during mastication.

Skin graft the maxillary sinus walls This is necessary as the movements of the obturator bulb will transmit greater force to the sinus walls in the edentulous patient. These walls can be prepared during surgery to allow the bony undercuts to serve for retention or for vertical support to

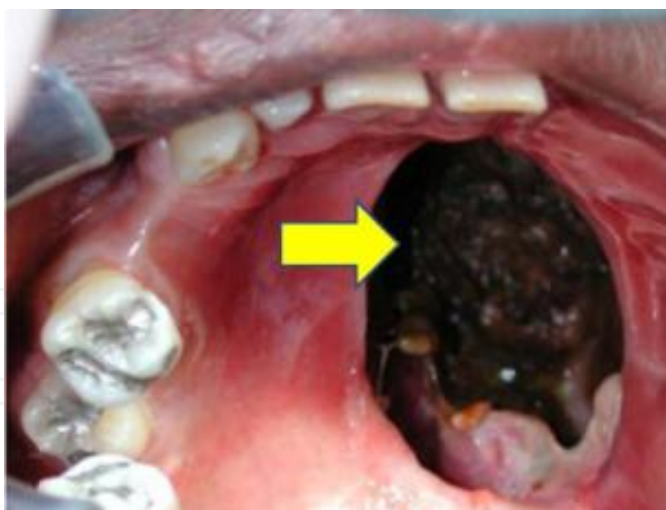

Figure 28. Skin graft on lateral wall of maxillary post-surgical defect

keep the prosthesis from rotating into the defect during mastication. The sinus walls are covered with respiratory mucosa, which must be denuded and covered with a split-thickness skin graft. Grafting the sinus walls stops formation of polypoid tissue and mucus generation within the sinus and allows the walls to become load-bearing areas [Figure 28].

With the increased use of osseointegrated implants, dependence on mechanical and anatomic methods of retention has diminished. Osseointegrated implants provide excellent retention to the definitive obturator. Retentive magnets and various designs of clips are available to minimize force transfer to the implant and supporting bone [3, 63, 64].

For a long time it was considered taboo to place implants in irradiated bone. However numerous studies have shown that use of hyperbaric oxygen chambers can be of immense value in such patients and allow for successful osseointegration as discussed earlier [25 – 27].

6.3. Zygomatic implants

Remote bone anchorage using zygoma implants for extensive maxillofacial defects is another option. Effective axial loading of the zygoma implant is accomplished by cross-arch stabilization with a rigid splint framework using at least 4 implants with adequate anterior – posterior spread [Figure 29]. When patients present with maxillary defects that do not have ideal residual anatomy, it may be possible to place zygoma implants in areas that will enhance the desired splinting effect of the bar assembly. The most significant and immediate benefit of this approach is the ability to extend the prosthesis anchorage points into defect areas, thus minimizing the cantilever forces on teeth and implants in residual ridge tissue. Maxillectomy and severely resorbed maxilla are challenging to restore with provision of removable prostheses. Dental implants are essential to restore aesthetics and function and subsequently quality of life in such group of patients. Zygomatic implants reduce the complications associated with bone grafting procedures and simplify the rehabilitation of atrophic maxilla and maxillectomy [65, 66].

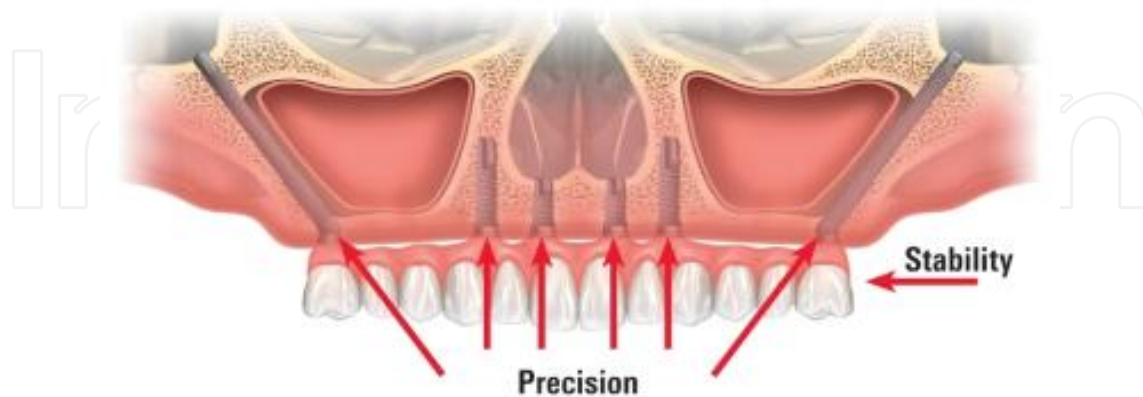


Figure 29. Diagrammatic representation of zygomatic implants

Studies using three-dimensional finite element analysis were carried out to study the impact of different levels of zygomatic bone support (10, 15, and 20 mm) on the biomechanics of zygomatic implants. Results indicated maximum stresses within the fixture were increased by three times, when bone support decreased from 20 to 10 mm, and concentrated at fixture/bone interface. However, stresses within the abutment screw and abutment itself were not significantly different regardless of the bone support level. Supporting bone of 10 mm showed double the stress as compared to levels of 15 and 20 mm. The deflection of the fixtures was decreased by two to three times as the level of bone support increased to 15 mm and 20 mm respectively. Therefore, it is important that the zygomatic bone support should not be kept at less than 15 mm. This will reduce the amount of deflection of the fixture and ensure long-term success of the implants [67, 68].

Placement of zygomatic implants lateral to the maxillary sinus, according to the extra-sinus protocol, is one of the treatment options in the rehabilitation of severely atrophic maxilla or following maxillectomy surgery in the head and neck cancer patients. Studies on a full-arch fixed-prosthesis supported by four zygomatic implants in the atrophic maxilla under occlusal loading have shown that maximum von Mises stresses were significantly higher under lateral loading compared with vertical loading within the prosthesis and its supporting implants. Peak stresses were found to be concentrated at the interface between the prosthesis and the fixtures when subjected to vertical load and also at the internal line angles of the prosthesis when subjected to lateral load. The zygomatic bone exhibited much lower stress levels as compared to the alveolar bone especially under lateral load. The zygomatic bone overall showed less values of stress than the alveolar bone and the prosthesis-implant complex under both types of loading [67]. Further research and long-term studies need to be carried out on these types of implants so that the rehabilitation of the atrophied or missing maxilla can be successfully carried out.

7. Microimplants and maxillofacial rehabilitation

Patients with craniofacial birth defects present with extreme skeletal deformities and often require a multi-pronged approach for achieving acceptable esthetic results. Vachiramam et al. [69], have described a series of cases in which orthodontic microimplants were used to better the surgical outcome of such patients. Use of these microimplants for support helped in distraction osteogenesis procedures involving the mandible, maxilla, or midface. The microimplants were additionally used to stabilize the dentition for orthodontic tooth movement or for resisting change from long-term use of inter-arch elastics. They concluded that microimplants appear to have good potential in the approach to treat patients with craniofacial anomalies. They can also be useful to present an alternative treatment plan in patients who refuse orthognathic surgery. Microimplants may be of great utility for the rehabilitation of craniofacial patients with congenitally missing permanent teeth; malformed teeth or patients with ectodermal dysplasia with reduced dentition that makes reciprocal orthodontic anchorage difficult [69].

8. Future trends in maxillofacial rehabilitation

The use of Computed Tomography (CT) and Magnetic Resonance Imaging (MRI) in conjunction with Rapid Prototyping (RP) have revolutionized the methods of old-fashioned impressions using various types of dental materials and sculpting of the prosthesis by hand in wax or clay [Figure 30, 31]. Recently advances in 3D optical imaging using 3D whole field profilometer based on the projection of incoherent light and 3D laser eye-safe scanners have been utilized [70, 71]. The advantages of such a system are that they are non-invasive, have a higher speed of data acquisition, and the scanners are more rugged and portable than the CT or MRI scanners [70].

Once the data has been acquired the virtual 3D models are obtained and the final prosthesis can be designed virtually. Two models one with the defect and another with the built up prosthesis are generated using epoxy photo-polymerising resins in a 3D printer [Figure 32, 33]. The final prosthesis is then fabricated from silicone rubber using these moulds [70 – 72].

In order to minimize the harmful effects of the metallic implants and their by-products, several newer materials are being tried. New alloys like tantalum, niobium, zirconium, and magnesium are receiving attention given their satisfying mechanical and biological properties. Non-oxide ceramics like silicon nitride and silicon carbide are being currently developed as a promising implant material possessing a combination of properties such as good wear and corrosion resistance, increased ductility, good fracture and creep resistance, and relatively high hardness in comparison to alumina. Polymer/magnesium composites are being developed to improve mechanical properties as well as retain polymer's property of degradation [73].

Nanotechnology and tissue engineering along with the concepts of stem cell technology are poised to dramatically define the next quantum leap in the field of maxillofacial reconstruction.

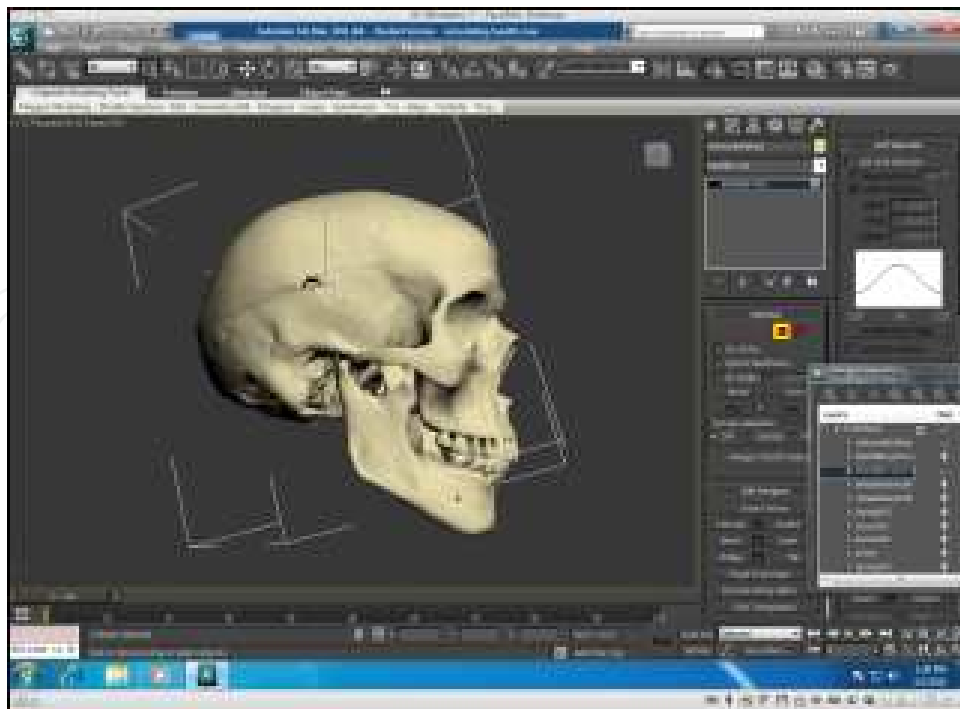


Figure 30. 3D virtual reconstruction and planning

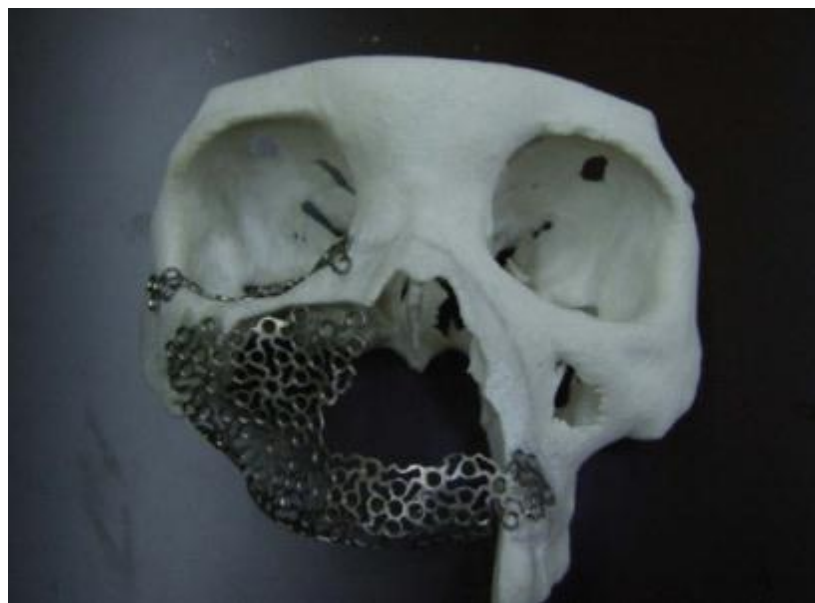


Figure 31. Rapid prototype modelling of maxillofacial prosthesis

Whether it is regeneration of new osseous tissue *in vivo* for placement of implants or even the regeneration of a complete ear or nose literally 'grown' from the stem cells of the person or a suitable donor-the possibilities are endless [74, 75]. It seems to be just a matter of time before the dream of autologous reconstruction of defective or missing anatomical structures soon becomes a reality.




Figure 32. 3D printer

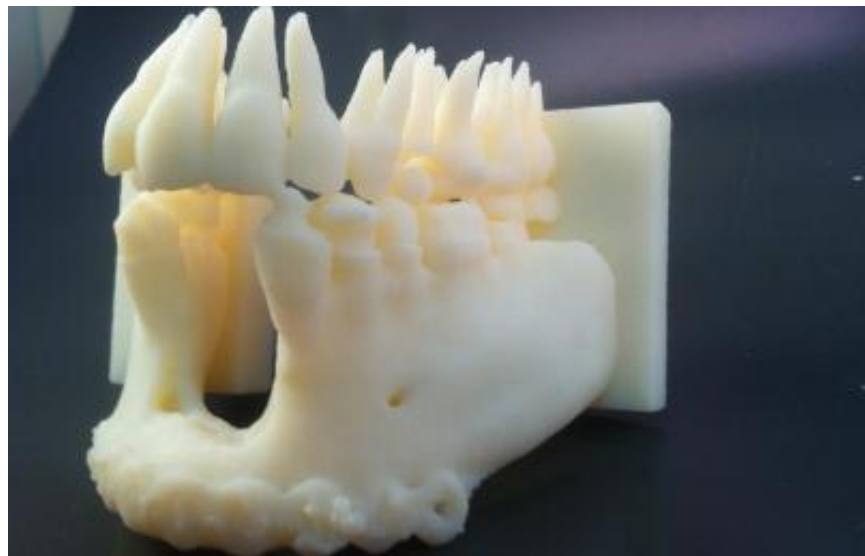


Figure 33. 3D printed model of mandibular defect

9. Conclusion

The discovery of osseointegration has been arguably one of the most beneficial medical breakthroughs especially in the head and neck region. The number of successful implants being placed is increasing rapidly as better implants, more efficient investigative techniques and superior armamentarium is readily available. These implants have also revolutionized the scope and the efficacy of rehabilitation of the entire craniofacial region [76].

Despite the rise in cancers of the head and neck region there is also a deeper understanding of the changes at cellular level and better treatment options and targeted medication. It is hoped that with each passing day there will be continued dedicated research to fight and eradicate all these killer diseases. Until then the science of craniofacial implantology will ensure that the

patients receive the most comprehensive rehabilitation that can be offered and ensure that their early return to form and function.

In future it is hoped that technological advances in allied fields such as radio-diagnosis and imaging, CAD-CAM manufacturing, tissue engineering, laser scanning, 3D-printing, development of newer nano-based materials and robotic placement of implants will work in tandem to ensure that larger numbers of patients can be treated early, economically and effectively [77-79]. Then alone will the dream of health for all be truly a reality.

Acknowledgements

I gratefully acknowledge all my respected teachers, enthusiastic students and tolerant patients who have taught me that I know so little and shown me that there is so much more learn.

Author details

Derek D'Souza*

Address all correspondence to: dsjdsouza@gmail.com

Consultant Prosthodontist, Pune, India

References

- [1] Brecht LE. Craniofacial and maxillofacial prosthetics. In: Thorne CH et al. (eds.) Grabb and Smith's Plastic Surgery. 6th edn. Philadelphia: Lippincott Williams & Wilkins; 2007: 350 –7.
- [2] Semple C, Parahoo K, Norman A, McCaughan E, Humphris G, Mills M. Psychosocial interventions for patients with head and neck cancer. Cochrane Database of Systematic Reviews 2013, 7: CD009441.
- [3] Mantri S and Khan Z. Prosthodontic Rehabilitation of Acquired Maxillofacial Defects. In: Agulnik M (ed.) Head and Neck Cancer Rijeka: InTech; 2012: 315 – 36.
- [4] Villar CC, Huynh-Ba G, Mills MP, Cochran DL. Wound healing around dental implants. Endodontic Topics 2011; 25: 44–62.
- [5] Kuzyk PR, Schemitsch EH. The basic science of peri-implant bone healing. Indian J Orthop 2011; 45:108-15.

- [6] Coelho PG, Granjeiro JM, Romanos GE, Suzuki M, Silva NR, Cardaropoli G, et al. Basic research methods and current trends of dental implant surfaces. *J Biomed Mater Res B Appl Biomater* 2009; 88:579-96.
- [7] Actis L, Gaviria L Ong JL. Antimicrobial surfaces for craniofacial implants: state of the art. *J Korean Assoc Oral Maxillofac Surg.* 2013; 39(2): 43–54.
- [8] Ramaswamy Y, Wu C, Zreiqat H. Orthopedic coating materials: considerations and applications. *Expert Rev Med Devices* 2009; 6:423-30.
- [9] Özcan M, Hämmerle C. Titanium as a reconstruction and implant material in dentistry: Advantages and Pitfalls. *Materials* 2012; 5:1528-45.
- [10] Stanford CM. Surface modifications of dental implants. *Aust Dent J* 2008; 53(Suppl 1): S26–S33
- [11] Lin YH, Peng PW, Ou KL. The effect of titanium with electrochemical anodization on the response of the adherent osteoblast-like cell. *Implant Dent* 2012; 21(4): 344-9.
- [12] Kim MH, Lee SY, Kim MJ, Kim SK, Heo SJ, Koak JY. Effect of biomimetic deposition on anodized titanium surfaces. *J Dental Res* 2011; 90(6):711-16.
- [13] Hanawa T. Degradation of dental implants. In: Eliaz N (ed) *Degradation of Implant Materials*. Springer: New York; 2012: 57-78.
- [14] Iezzi G, Malchiodi L, Quaranta A, Ghensi P, Piattelli A. Peri-implant bone response around a human hydroxyapatite-coated implant retrieved after a 10-year loading period: A case report. *Int J Oral Maxillofac Implants* 2012; 28(4): 190-4.
- [15] Baker MI, Eberhardt AW, Martin DM, McGwin G, Lemons JE. Bone properties surrounding hydroxyapatite-coated custom osseous integrated dental implants. *J Biomed. Mater. Res* 2010; 95B: 218–24.
- [16] van Oirschot BAJA, Bronkhorst EM, van den Beucken JJJP, Meijer GJ, Jansen JA, Junker R. Long-term survival of calcium phosphate-coated dental implants: a meta-analytical approach to the clinical literature. *Clin. Oral Impl. Res.* 24, 2013, 355–62.
- [17] Jimbo R, Coelho PG, Vandeweghe S, Schwartz-Filho HO, Hayashi M, Ono D, Wennerberg, A. Histological and three-dimensional evaluation of osseointegration to nanostructured calcium phosphate-coated implants. *Acta Biomaterialia* 2011; 7(12): 4229-34.
- [18] Goené RJ, Testori T, Trisi P. Influence of a nanometer-scale surface enhancement on *de novo* bone formation on titanium implants: a histomorphometric study in human maxillae. *Int J Periodontics Restorative Dent* 2007; 27: 211-9.
- [19] Hong YS, Kim MJ, Han JS, Yeo IS. Effects of hydrophilicity and fluoride surface modifications to titanium dental implants on early osseointegration: An in vivo study. *Implant Dent* 2014; 23(5): 529-33.

- [20] Monjo M, Petzold C, Ramis JM, Lyngstadaas SP, Ellingsen JE. In vitro osteogenic properties of two dental implant surfaces. *Int J Biomater* 2012; 181024: 1-14.
- [21] Abraham CM. A brief historical perspective on dental implants, their surface coatings and treatments. *Open Dent J* 2014; 8: 50-5.
- [22] Granström, G. Craniofacial osseointegration. In: *Oral Diseases* 2007; 13: 261–9.
- [23] Rocke DJ, Tucci DL, Marcus J, McClennen J, Kaylie D. Osseointegrated implants for auricular defects: Operative techniques and complication management. *Otol Neurotol* 2014; 35(9): 1609-14.
- [24] Kelly JA. Craniofacial and Maxillofacial Implants. In: Devlin H, Nishimura I (eds.) *Oral and Cranial Implants* Springer-Verlag; 2013: 28 – 37.
- [25] Chrcanovic BR, Albrektsson T, Wennerberg A. Dental implants in irradiated versus non-irradiated patients: A meta-analysis. *Head Neck* 2014; doi: 10.1002/hed.23875.
- [26] Anderson L, Meraw S, Al-Hezaimi K, Wang HL. The influence of radiation therapy on dental implantology. *Implant Dent* 2013; 22(1): 31–8.
- [27] Javed F, Al-Hezaimi K, Al-Rasheed A, Almas K, Romanos, GE. Implant survival rate after oral cancer therapy: A review. *Oral Oncol* 2010; 46(12): 854-9.
- [28] de Oliveira JAP, Abrahão M, Dib LL Extraoral implants in irradiated patients *Braz J Otorhinolaryngol* 2013; 79(2):185-9.
- [29] Wennerberg A, Albrektsson T. On implant surfaces: a review of current knowledge and opinions. *Int J Oral Maxillofac Implants* 2010; 25 (1): 63-74.
- [30] Ramazanoglu M, Oshida Y. Osseointegration and bioscience of implant surfaces-Current concepts at bone-implant interface In: *Implant Dentistry-A Rapidly Evolving Practice*, Turkyilmaz I (ed) Rijeka; InTech; 2011; 57 – 82.
- [31] Thimmappa B, Girod SC. Principles of implant-based reconstruction and rehabilitation of craniofacial defects. *Craniofacial Trauma Reconstr.* 2010; 3(1): 33–40.
- [32] Goiato, MC, dos Santos DM, de Carvalho DSF, Pellizzer EP, Santiago Jr JF, Moreno A. Craniofacial implants success in facial rehabilitation. *J Craniofac Surg* 2011; 22(1): 241-2.
- [33] Pekkan G, Tuna SH, Oghan F. Extraoral prostheses using extraoral implants. *Int J Oral Maxillofac Surg* 2011; 40(4): 378-83.
- [34] Nemli SK, Aydin C, Yilmaz H, Bal BT, Arici YK, Quality of life of patients with implant-retained maxillofacial prostheses: A prospective and retrospective study. *J Prosthet Dent* 2013;109(1): 44–52.
- [35] Ariani N, Visser A, van Oort RP, Kusdhany L, Rahardjo TB, Krom BP et al. Current state of craniofacial prosthetic rehabilitation. *Int J Prosthodont* 2012; 26(1): 57-67.

- [36] Curi MM, Oliveira MF, Molina G, Cardoso CL, De Groot OL, Branemark PI, de Cás-sia BRK. Extraoral implants in the rehabilitation of craniofacial defects: implant and prosthesis survival rates and peri-implant soft tissue evaluation. *J Oral Maxillofac Surg* 2012; 70(7): 1551-7.
- [37] Cohen M. Craniofacial surgery: the first 25 years. Where do we come from? Who are we? Where are we going? *J Craniofac Surg* 2014; 25(1): 14-6.
- [38] Smolarz-Wojnowska A, Raithel F, Gellrich NC, Klein C. Quality of implant anchored craniofacial and intraoral prostheses: Patients evaluation. *J Craniofac Surg* 2014; 25(2): 202-7.
- [39] Alford M. Eucleation, evisceration, and exenteration techniques In: Duane's Clinical Ophthalmology [CD ROM] Lippincott Williams & Wilkins. 2006; (5) Chapter 82.
- [40] Ozcelik TB, Yilmaz B Two-piece impression procedure for implant-retained orbital prostheses. *Int J Oral Maxillofac Implants*. 2012; 27(5): 93-5.
- [41] Karakoca-Nemli, S, Aydin, C, Yilmaz H and Bal BT. A method for fabricating an im-plant-retained orbital prosthesis using the existing prosthesis. *J Prosthodont* 2011; 20: 583-6.
- [42] Ethunandan M, Downie I, Flood T. Implant-retained nasal prosthesis for reconstruc-tion of large rhinectomy defects: the Salisbury experience. *Int J Oral Maxillofac Surg*. 2010; 39 (4): 343-9.
- [43] Bedrossian E, Brånemark PI. Systematic treatment planning protocol for patients with maxillofacial defects: avoiding living a life of seclusion and depression. *Atlas Oral Maxillofac Surg Clin North Am* 2012; 20(1): 135-58.
- [44] Banerjee S, Kumar S, Bera A, Gupta T, Banerjee A. Magnet retained intraoral-extra oral combination prosthesis: a case report. *J Adv Prosthodont* 2012; 4(4): 235-8.
- [45] Goyal S, Goyal MK, Kallingan P. Magnetically retained extra oral prosthesis and maxillary interim obturator. *Eur J Prosthodont* 2014; 2: 37-40.
- [46] Dholam KP, Shetty KG, Bhirangi PP. Restoration of nasal defect with implant-re-tained nose prosthesis. *J Indian Prosthodont Soc*; 2007; 7 (4): 196-9
- [47] Lovely M, Dathan PC, Gopal D, George BT, Nair KC. Implant retained auricular prosthesis with a modified Hader bar: A case report *J Indian Prosthodont Soc* 2014; 14(2): 187-190.
- [48] Aydin C, Karakoca S, Yilmaz H, Yilmaz C. Implant retained auricular prosthesis: An assessment of implant success and prosthetic complications. *Int J Prosthodont* 2008; 21: 241-4.
- [49] Guo G, Schwedtner O, Klein M. A retrospective study of implant-retained auricular prosthesis. *Int J Oral Maxillofac Implants* 2008; 23: 539-43.

- [50] Nanda A, Jain V, Kumar R, Kabra K. Implant-supported auricular prosthesis. *Indian J Dent Res* 2011; 22:152-6.
- [51] Wright RF, Zemnick C, Wazen JJ, Asher E. Osseointegrated implants and auricular defects: a case series study. *J Prosthodont* 2008; 17(6): 468-75
- [52] Federspil, PA. Auricular Prostheses In: Staudenmaier R (ed) *Aesthetics and functionality in ear reconstruction*. Basel, Karger; 2010; 68: 65-80.
- [53] Dilber E, Koc O, Ozturk AN, and Karamese M Craniofacial implant-retained auricular prosthesis: A case report. *J Oral Implant* 2013; 39 (4): 479-82.
- [54] Kievit, H, Verhage-Damen GW, Ingels KJ, Mylanus EA, Hol MK. Long-term quality of life assessment in patients with auricular prostheses. *J Craniofac Surg* 2013; 24(2): 392-7.
- [55] Kim DR, Lim YJ, Kim MJ, Kwon HB. The importance of remaining teeth reconstruction in the definite obturator for a hemimaxillectomy patient. *J Craniofac Surg* 2011; 22(6): 2359-61.
- [56] Lethaus B, Lie N, de Beer F, Kessler P, de Baat C, Verdonck HW. Surgical and prosthetic reconsiderations in patients with maxillectomy. *J Oral Rehab* 2010; 37(2): 138-42.
- [57] Shirota T, Shimodaira O, Matsui Y, Hatori M, Shintani S. Zygoma implant-supported prosthetic rehabilitation of a patient with a maxillary defect. *Int J Oral Maxillofac Surg* 2011; 40(1): 113-7.
- [58] Murat S, Gurbuz A, Isayev A, Dokmez B, Cetin U. Enhanced retention of a maxillofacial prosthetic obturator using precision attachments: Two case reports. *Eur J Dent* 2012; 6(2): 212-7.
- [59] Jacob RF. Clinical management of the edentulous maxillectomy patient In: Taylor TD (ed) *Clinical Maxillofacial Prosthetics* Quintessence 2000: 85 – 102.
- [60] Kumar P, Alvi HA, Rao J, Singh BP, Jurel SK, Kumar L, Aggarwal H. Assessment of the quality of life in maxillectomy patients: A longitudinal study *J Adv Prosthodont* 2013; 5: 29-35
- [61] Pace-Balzan A, Shaw RJ, Butterworth C. Oral rehabilitation following treatment for oral cancer. *Periodontol* 2000. 2011; 57: 102–17.
- [62] Sharma AB, Buemer J III. Reconstruction of maxillary defects: the case for prosthetic rehabilitation. *J Oral Maxillofac Surg* 2005; 63: 1770-3.
- [63] Parr GA, Tharp GE, Rahn AO. Prosthodontic principles in the framework design of maxillary obturator prosthesis. *J Prosthet Dent* 2005; 93: 405-11.

- [64] Padmanabhan TV, Kumar VA, Mohamed KK, Unnikrishnan N. Prosthetic rehabilitation of a maxillectomy with a two-piece hollow bulb obturator. A clinical report. *J Prosthodont* 2011; 20: 397–401.
- [65] Sharma A, Rahul GR. Zygomatic implants/fixture: a systematic review. *J Oral Implantol* 2013; 39(2): 215-24.
- [66] Gonçalves, LM, Gonçalves TMSV, Rodrigues AHC, Lanza MD, Nascimento PRG, Girundi FMS. Intra-and extra-oral prostheses retained by zygoma implants following resection of the upper lip and nose. *J Prosthodont* 2014; doi: 10.1111/jopr.12178.
- [67] Romeed SA, Malik R, Dunne SM. Zygomatic implants: the impact of zygoma bone support on biomechanics. *J Oral Implantol*. 2014; 40(3): 231-7.
- [68] Pasquale P, Ferrari F, Trevisiol L, Francesco NP. Zygoma implant-supported prosthetic rehabilitation of a patient after subtotal bilateral maxillectomy. *J Craniofac Surg* 2013; 24(2): 159-62.
- [69] Vachiramon A, Urata M, Kyung HM, Yamashita DD, Yen SLK, Cleft Palate Craniofac J; 2009, 46 (2):136-46.
- [70] Cavagnini G, Sansoni G, Vertuan A, Docchio F. 3D optical body scanning: application to forensic medicine and to maxillofacial reconstruction. In: International Conference on 3D Body Scanning Technologies 2010: 167-78.
- [71] Qiu J, Gu X, Xiong Y, Zhang F. Nasal prosthesis rehabilitation using CAD-CAM technology after total rhinectomy: A pilot study. In: Supportive Care in Cancer 2011; 19 (7): 1055-9.
- [72] Subburaj K, Nair C, Rajesh C, Meshram SM, Ravi B. Rapid development of auricular prosthesis using CAD and rapid prototyping technologies. *Int. J. Oral Maxillofac Surg* 2007; 36: 938–43.
- [73] Jakobsen C, Sørensen JA, Kassem M, and Thygesen TH. Mesenchymal stem cells in oral reconstructive surgery: A systematic review of the literature. *J Oral Rehabil* 2013; 40: 693–706.
- [74] Mantripragada VP, Lecka-Czernik B, Ebraheim NA, Jayasuriya AC. An overview of recent advances in designing orthopedic and craniofacial implants. *J Biomed Mater Res* 2013; 101A: 3349–64.
- [75] Nayyer L, Patel KH, Esmaeili A, Rippel RA, Birchall M, O'toole G, Butler PE, Seifalian AM. Tissue engineering: revolution and challenge in auricular cartilage reconstruction. *Plast Reconstr Surg*. 2012; 129(5):1123-37.
- [76] Roumanas ED, Freymiller EG, Chang TL, Aghaloo T, Buemer J III. Implant retained prosthesis for facial defects: An up to 14-year follow-up report on the survival rates of implants at UCLA. *Int J Prosthodont* 2002; 15: 325-32.

- [77] Olszewski, R. Surgical engineering in cranio-maxillofacial surgery: a literature review. *J Healthc Eng* 2012; 3(1): 53-86
- [78] Watson D, Reuther MS. Advancing the art of rhinoplasty with tissue engineering. In Shiffman MA, Giuseppe AD (Eds) *Advanced Aesthetic Rhinoplasty*. Springer Berlin Heidelberg 2013; 1107-18.
- [79] Davis BK, Emert R. The role of technology in the maxillofacial prosthetic setting. In: *Printed Biomaterials Biological and Medical Physics, Biomedical Engineering* 2010; 111-20.

IntechOpen

