

We are IntechOpen, the world's leading publisher of Open Access books Built by scientists, for scientists

4,800

Open access books available

122,000

International authors and editors

135M

Downloads

Our authors are among the

154

Countries delivered to

TOP 1%

most cited scientists

12.2%

Contributors from top 500 universities



WEB OF SCIENCE™

Selection of our books indexed in the Book Citation Index
in Web of Science™ Core Collection (BKCI)

Interested in publishing with us?
Contact book.department@intechopen.com

Numbers displayed above are based on latest data collected.

For more information visit www.intechopen.com



Vascular Calcification in Patients with End-Stage Renal Disease

Kosaku Nitta

Additional information is available at the end of the chapter

<http://dx.doi.org/10.5772/59403>

1. Introduction

Chronic kidney disease (CKD)-mineral and bone disorder (CKD-MBD) becomes an important issue in CKD management [1]. CKD patients show a bone and mineral disorder as follows: (i) laboratory abnormal metabolisms of calcium, phosphate, and vitamin D; (ii) evidence of calcified tissue disturbance; (iii) and arterial calcification. Arterial calcification is known to be related to numerous worse symptomatic outcomes, such as ischemic cardiovascular attacks and death [2]. The pathogenesis of vascular calcification in CKD is complex, and instead of occurring by a simple process of calcium and phosphate precipitation, it is produced by an active process in which vascular smooth muscle cells (VSMCs) undergo apoptosis and vesicle formation and are transformed into osteoblast-like cells that induce matrix formation and attract local factors that are involved in the mineralization process [3] (Fig. 1).

The pathogenesis of the multifactorial interactions between aging and progression of vascular calcification remains uncertain. However, there is no doubt that end-stage renal disease (ESRD) patients are at high risk of and have a common finding of vascular calcification due to multiple confounders that promote the differentiation of VSMCs to osteoblast-like cells, which are able to enhance the tissue calcium deposition process [4]. Vascular calcification has recently reported to be associated with many traditional risk factors, aging, high blood pressure, diabetes, and hyperlipidemia, and with nontraditional risk factors, including elevated serum phosphate level, hyperparathyroidism, and high-dose prescription of calcium [5]. Vascular calcification causes a decrease in vascular elasticity, an increase in pulse wave velocity [6], an induction of cardiomyopathy [7], a decrease in coronary artery flow, and an ischemic change (Fig. 2).

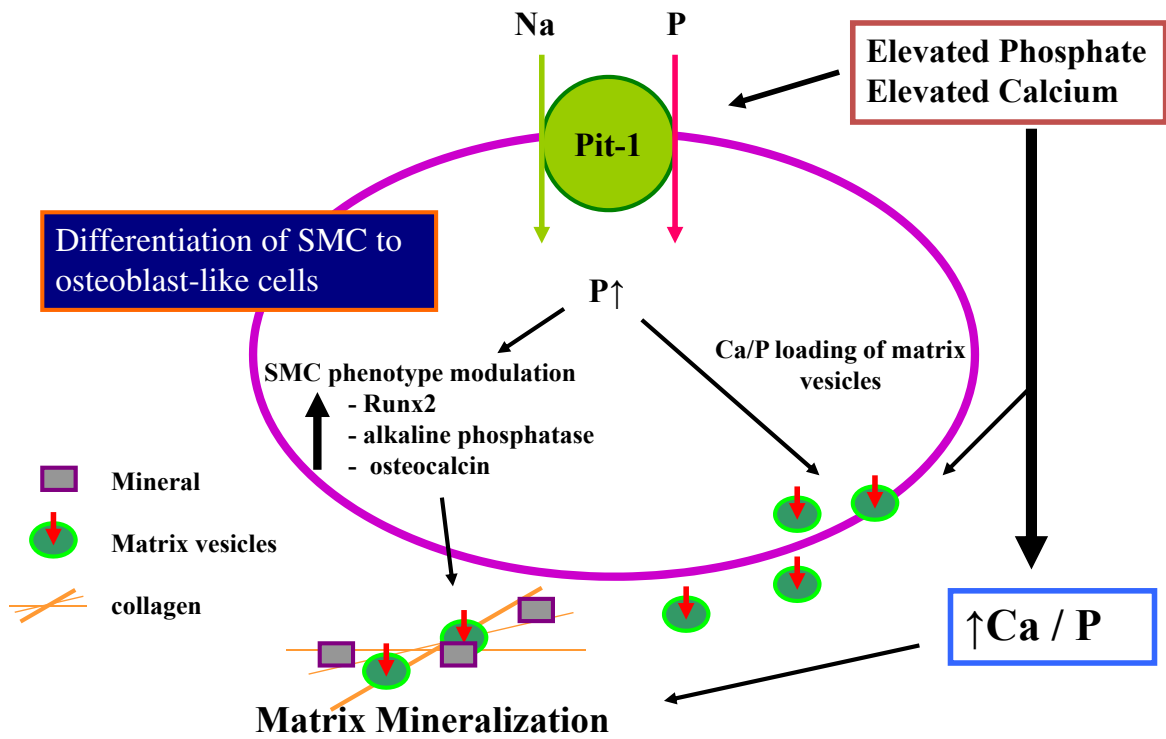


Figure 1. Relationship between calcium and phosphorus and vascular calcification.

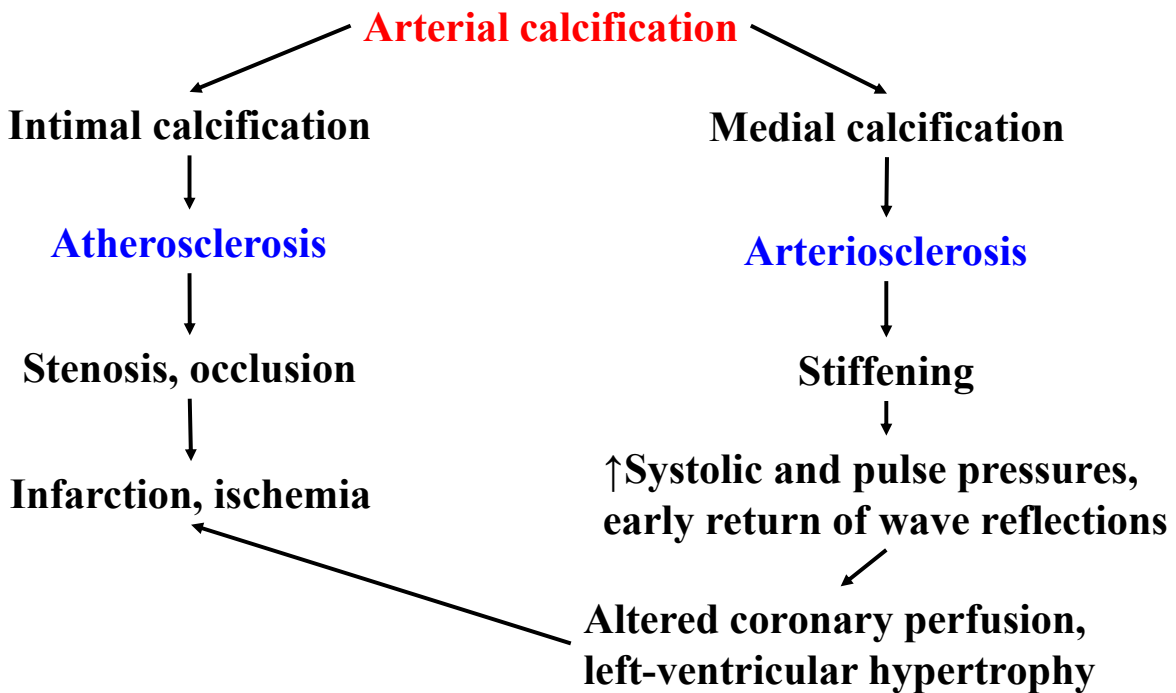


Figure 2. Schematic representation of the clinical effects of arterial intimal and medial calcification.

Recent therapeutic regimens that are performed to suppress vascular calcification are concentrated on the control of metabolic markers of skeletal disorder, including phosphate, and

vitamin D. The antiosteoporosis drugs such as bisphosphonates [8] have shown therapeutic possibility, but more additional clinical trials are needed. The ADVANCE study has recently shown that cinacalcet and low-dose vitamin D reduce vascular and cardiac valve calcification in hemodialysis (HD) patients with secondary hyperparathyroidism (SHPT) [9]. This review article describes recent progress in terms of the pathogenic mechanisms and methods of assessing and managing vascular calcification in ESRD patients.

2. Pathophysiology and bone-associated proteins

The pathophysiology of vascular disorder in HD patients is recently recognized as different from the pathophysiology of atherosclerotic alterations in healthy subjects [10]. Vascular calcification progresses in association with aging, and deposition of calcium in the media is > 30-times more in the thoracic aorta at 90 years old than those at 20 years old [11]. Age-associated medial calcinosis in arteries is also related to hypertension, diabetes, and hyperlipidemia [12], and it is specific for arteries and does not affect other soft tissues in normal subjects. Vascular calcification was previously considered as a passive finding, but it has recently been recognized as an active process [13–15].

Two patterns of vascular calcification have been reported. One appears in the intimal layer and the other occurs in the medial layer of the vessel wall which is known as in Monckeberg's calcification [16], and both types are related to increased mortality of HD patients [17]. Intimal calcification is found to be related to chronic inflammatory changes and the occurrence of plaques and occlusive lesions. This intimal type of calcification is a predictor of the advanced atherosclerosis and is found to be seen in the aorta and coronary arteries. Medial calcification is identified with diffuse calcium deposition and can occur independent of atherosclerosis, and it is frequently shown in conduit arteries, including the femoral and tibial arteries [13, 16].

There are well-known changes in the arterial wall, such as intimal thickening, calcification of elastic lamellae, an increased extracellular matrix, and deposition of collagen and a relatively small elastic fiber content, and these findings are associated with arterial remodeling in CKD patients [17]. Numerous bone-related proteins, including osteopontin, osteocalcin, and osteoprotegerin (OPG), and bone morphogenetic proteins (BMPs) are associated with the vascular remodeling, and they are found to be appeared in the calcified lesions and are known to be related to vascular calcification [18]. VSMCs are the main component of the arterial media, and they can transform to osteoblast-like cells in association with up-regulation of transcription factors, such as Runt-related transcription factor 2 (Runx2) and Msh homeobox 2 (Msx2), which are important factors for normal bone formation [19]. This phenotypic differentiation may be related to the deposition of calcium in the layer of VSMCs that is similar to bone development, indicating that this type of vascular calcification is ectopic ossification. In addition, uremic condition has been found to induce transformation of VSMCs into osteoblast-like cells and suppresses the transformation of macrophages into osteoclasts [20]. The arteries of HD patients demonstrate up-regulation of alkaline phosphatase activity and enhanced expression of Runx2, which is predictor of osteogenic differentiation of VSMCs [21].

3. Dysregulation of calcium and phosphate metabolism

Traditional risk factors, such as aging, hypertension, diabetes, and hyperlipidemia, and various nontraditional factors, including low serum calcium levels, high serum phosphate levels, high-dose prescription of CaCO_3 , chronic inflammation, and malnutrition, have been observed in ESRD patients [22]. Patients with advanced CKD demonstrate hyperphosphatemia followed by reduced renal phosphate excretion. Vascular calcification is obviously related to impaired serum calcium and phosphate concentrations [16, 21, 23]. Elevated serum phosphate concentration is found to be recognized as an arterial injury factor [24], and when phosphate control had been poorest, vascular calcification had rapidly progressed in CKD patients [25].

There are two different mechanisms of vascular calcification that are proposed to verify the relationship between abnormal calcium and phosphate metabolism and vascular calcification. Previous studies have shown that calcium is a key element in the initiation of vascular calcification by promoting calcium deposition in VSMCs under normal phosphate metabolism [26], and when the phosphate levels are increased, this calcium deposition has been enhanced additionally [27]. Hyperphosphatemia may directly cause vascular injury, and it indirectly promotes osteoblastic differentiation via a type III sodium-dependent phosphate cotransporter (PiT-1). A previous report [28] demonstrated that an increased intracellular phosphate concentration may directly enhance VSMCs to differentiate to calcifying cells by activating genes. In addition, El-Abbadi et al. [29] has shown an experimental model of CKD-related vascular calcification in which severe arterial calcification progresses only after the mice are treated with a high-phosphate diet, indicating that hyperphosphatemia is a powerful stimulator of arterial calcification. These results suggest that high-dose phosphate and calcium prescription is the most important risk factor in vascular calcification.

It is recognized that secondary hyperparathyroidism (SHPT) is common in ESRD patients and appears even in the early stage of CKD. Mineral metabolism disorders, such as hyperphosphatemia, is associated with the progression of CKD stage, leading to the occurrence of SHPT, which is detected by elevated serum parathyroid hormone (PTH) concentrations and parathyroid gland hyperplasia [30]. Increased PTH concentration is critical for the proliferation and activation of osteoclasts and important for the enhanced bone resorption in these patients. A remarkable reduction in serum 1,25-dihydroxyvitamin D [$1,25(\text{OH})_2\text{D}$] concentration is detected in the early stage of CKD [31], and the decrease in $1,25(\text{OH})_2\text{D}$ level is associated with renal and nonrenal mediators, such as decreased sun light exposure, reduced synthesis of the $25(\text{OH})\text{D}$ precursor, and decreased dietary injection [32]. Reduced vitamin D production occurs in parallel with CKD progression and stimulates parathyroid gland enlargement, followed by SHPT [30].

Decreased $25(\text{OH})\text{D}$ concentrations influenced survival independently of vascular calcinosis and increased arterial stiffness, indicating that $25(\text{OH})\text{D}$ may affect mortality of CKD patients through additional mechanisms that require to be expected [33]. Active vitamin D promotes intestinal uptake of calcium and phosphate and stimulates osteoblastic transformation of VSMCs. Furthermore, $1,25(\text{OH})_2\text{D}$ has been known to play a role as a negative modulator of

the renin–angiotensin axis, which acts an important key element in the cardiovascular system by controlling extracellular volume and electrolyte metabolism [34]. Even though high-dose of 1,25(OH)₂D promotes arterial calcinosis [35], normal doses have been reported to inhibit arterial calcinosis in experimental models of CKD [36].

4. Fibroblast growth factor 23 and vascular calcification

Fibroblast growth factor 23 (FGF-23) is a new regulator produced by osteoblasts, which is associated with the regulation of phosphate and vitamin D metabolism [37]. FGF-23 has been shown to reduce the synthesis and promote the degradation of 1,25(OH)₂D. Actually, recombinant FGF-23 suppresses renal 25-hydroxyvitamin D-1 α -hydroxylase mRNA within 1 h in mice [38]. The enhanced degradation of 1,25(OH)₂D by 24-hydroxylase may be related to this phenomenon. In addition, a phosphaturic effect of FGF-23 contributes to decreased phosphate uptake in the kidney. FGF-23 has been shown to down-regulate types IIa and IIc sodium-phosphate cotransporters on the apical area of proximal epithelial cells [38, 39].

Klotho has been reported as a 130-kDa β -glucuronidase that catalyzes the hydrolysis of steroid β -glucuronides [40]. The Klotho gene is mainly expressed in the kidneys, and its mutation induces many aging-associated diseases [41]. Since the phenotype of FGF-23-knockout (KO) mice is similar to those of Klotho-KO mice [42, 43], a common signaling pathway has been proposed, FGF-23 receptors (FGF-Rs). FGF-23 acts via FGF receptors (FGF-Rs) in a Klotho-dependent manner since a Klotho/FGF-R complex binds to FGF-23 with higher affinity than FGF-R or Klotho only [44]. FGF-23 has lower affinity for its receptors, and the combination with circulating Klotho is important to enhance the binding of FGF-23 to FGF-Rs [45]. Taken together, the activation of FGFRs needs not only circulating FGF-23 as a ligand but also Klotho as a specific activator whose affinity attributes the selectivity on target organs.

Klotho is mainly present in the kidneys, whereas FGF-23 secretes from bone cells, and this bone–kidney interaction is essential for physiological and pathological mechanism. According to recent information, it is likely that this axis exerts a fundamental regulation of calcium metabolism with Klotho and to show a more specific effect on phosphate homeostasis via the presence of FGF-23. Both Klotho and FGF-23 affect synthesis of active vitamin D and PTH, indicating that FGF-23 may control PTH secretion in the parathyroid glands. In support of this mechanism, results obtained *in vitro* suggest that FGF-23 suppresses PTH mRNA transcription and protein secretion in a dose-dependent manner [46]. On the other hand, PTH promotes FGF-23 production by osteoblasts because increased FGF-23 concentrations in animals with primary HPT occur, which is decreased by parathyroidectomy [47].

5. Inhibitors of vascular calcification

Fetuin-A is originally synthesized in the liver, and circulating fetuin-A concentrations fall during the inflammatory process [48]. Fetuin-A is an extracellular calcium-regulatory factor

that functions as a new inhibitor of calcium-phosphate deposition [49], suppresses calcinosis by binding hydroxyapatite [50], and protects VSMCs from the harmful effects of calcium overload and subsequent calcification [51]. Fetuin-A suppresses VSMC apoptosis through death-signaling pathways: (i) it is internalized by VSMCs, concentrated in intracellular vesicles, and secreted via vesicle release from apoptotic and living VSMCs; (ii) fetuin-A in vesicles suppresses their ability to nucleate calcium phosphate; and (iii) fetuin-A increases phagocytosis of vesicles by VSMCs. These results confirm finding that the internalization of fetuin-A into VSMCs is a key finding in the inhibition of vesicle-mediated VSMC calcification [51]. In *in vitro* experiments, fetuin-A has been reported to antagonize the action of TGF- β 1 (transforming growth factor- β 1) and inhibit osteogenesis and calcium-containing matrix deposition in dexamethasone-treated rat bone marrow cells [49]. Moreover, fetuin-A-KO mice show severe ectopic calcinosis in the myocardium, kidney, lung, tongue, and skin [49]. A recent study [49] demonstrated that ESRD patients who had lower serum fetuin-A concentrations showed a lower survival rate from cardiovascular diseases, indicating that fetuin-A is related to the mechanism of the accelerated extraskeletal calcinosis.

Matrix Gla protein (MGP) is a matrix protein that was firstly discovered from bone [52], and it is an important modulator of vascular calcification. To exert its biological activity, MGP requires to be activated through interaction with vitamin K [53]. The calcification of cartilage and blood vessels has been found to be inhibited by MGP [54]. MGP affects on vascular calcification directly by reducing calcium crystal formation and indirectly by modulating transcription factors that suppress VSMC transformation to the osteoblast-like cells [55]. Moreover, MGP is an important factor capable of transformation of VSMCs [58]. A decrease in glomerular filtration rate has been shown to result in a reduction in uncarboxylated MGP level which is related to vascular calcification [56].

The receptor activator of nuclear factor κ -light-chain-enhancer of activated B-cells (RANK), and RANK ligand (RANKL), and osteoprotegerin (OPG) might be associated with the mechanism of vascular calcification. RANKL functions are inhibited by OPG that acts as a decoy receptor to inhibit RANKL/RANK relationships [57]. This system may be related to the imbalance of bone-vascular calcification interactions and could be a predictor of the grade of vascular calcification. A recent study [58] demonstrated that coronary arterial calcification (CAC) is significantly associated with plasma OPG values in CKD patients. The serum OPG levels >757.7 pg/ml in CKD patients were indicator of CAC. These results are compatible with those reported in our previous study [59]. The relationship between serum OPG concentrations and CAC is unclear. The functional role of circulating OPG has been found to be modulated by several factors, including the relevant association of different tissue sources and the contribution of various comorbidities. OPG has been reported to have protective effect against vascular calcium deposition in experimental models [60]. Interestingly, higher OPG concentrations have been shown in patients with vascular injury, indicating that an elevated OPG concentration may be attribute to a compensatory self-defense mechanism that stimulates vascular calcification [61].

6. Evaluation of vascular calcification

Several types of noninvasive methods are useful for screening of the detection of vascular calcification: plain X-rays for visible calcification of the aorta and peripheral arteries; two-dimensional ultrasound for detecting calcification of the carotid arteries and femoral arteries; and echocardiography for the evaluation of valvular calcification; and computer tomography (CT) is considered to be the gold standard for quantification of coronary artery and aorta calcification.

Electron-beam CT (EBCT) and multislice CT (MSCT) are relatively sensitive methods for quantitative assessment of vascular calcification, such as CAC, which utilize an electrocardiographic trigger capable of the evaluation of the heart in diastolic phase, thereby prohibiting moving artifacts [62]. These methods can be usually used to assess the presence of vascular calcifications, the evaluation of longitudinal vascular calcification, and the effect of various treatments on vascular calcification [63]. EBCT is not available in every hospital, although most hospitals have MSCT equipment and, with software applications to enable gated imaging, the new MSCT can evaluate vascular calcification. However, there have been conflicting reports concerning the relationship between the grade of CAC estimated by EBCT and the prevalence of cardiovascular events in ESRD patients [64, 65]. The conflicting results could be confirmed by the evidence that the arterial calcification score evaluated by MSCT is a combination of both medial and intimal calcification, and the finding that is a limitation of the CT-based assessment. MSCT can be used to evaluate aortic calcification [66, 67]. Conventional CT could be used to estimate noncoronary vascular calcification, such as aortic calcification. The area of the aortic circumference that is calcified can be estimated as an aortic calcification index (ACI). It is likely that conventional CT is relatively inexpensive and applicable for screening of vascular calcification. A previous study [72] utilized the conventional CT to estimate aortic calcification in diabetic HD patients. The ACI could not be applicable to evaluate the medial/intimal calcification.

Plain lateral-abdominal X-ray is an inexpensive method for detecting the presence of vascular calcification in CKD patients, but it is semiquantitative, and longitudinal alterations of vascular calcification may not be confirmed. Lateral abdominal X-ray could be utilized as an alternative to CT [69]. The presence of vascular calcification observed on plain X-rays may give some information concerning the pattern of the arterial wall calcification. Kauppila et al. [70] showed the application of lateral lumbar X-rays to confirm the pattern of aortic calcification, in the area responsible to the part of the first to the fourth lumbar vertebrae. This semiquantitative method is a more applicable and less expensive technique for showing arterial calcification and could be utilized for cardiovascular risk management.

We have shown a simple method to study the grade of aortic arch calcification (AoAC) using plain chest X-ray in HD patients [71]. AoAC score (AoACS) was evaluated as a percentage of the proportion of calcified aortic arch, and the mean AoACS was $5.0\% \pm 4.5\%$ ranging from 0% to 15%. Older age and longer dialysis duration were significant factors in the patients with AoAC. The grade of AoAC was significantly associated with the AoAC volume measured by MSCT. We suggest that screening HD patients for AoAC is a cost-effective method to find

patients at the highest risk of cardiovascular diseases and of identifying therapy by inhibiting vascular calcification.

7. Applicable therapy of vascular calcification

Hyperphosphatemia is associated with SHPT and contributes to cardiovascular and all-cause mortality. The phosphate binders are recently utilized to treat hyperphosphatemia, including sevelamer, lanthanum, and the calcium-based phosphate binders (CBPBs) such as CaCO_3 . Sevelamer is a calcium-free phosphate binder that does not increase serum calcium concentrations, enables better serum phosphate management than CBPBs, reduces the extent of aortic calcification in ESRD patients, and improves serum lipid profile because it decreases low-density lipoprotein cholesterol (LDL-C) and induces the increase in high-density lipoprotein cholesterol (HDL-C) [72]. In a clinical study consisting of 200 HD patients, Chertow et al. [73] showed that sevelamer had significantly reduced the extent of coronary and aortic calcification compared with CBPBs after 1 year of therapy. These results were reevaluated by other investigators [74], who demonstrated that sevelamer significantly reduced the progression of vascular calcification when compared with CaCO_3 . One of the possible mechanism is a strong phosphate-binding ability of sevelamer in the intestine, without calcium overload. In the Renagel in New Dialysis study including HD patients with pretreatment CAC scores of 30 or higher, no significant difference was detected in the rate of CAC progression up to 18 months of follow-up between the sevelamer group and CBPB group [75]. *In vitro* experimental studies have demonstrated that acetylated LDL-C induces calcium deposition, whereas HDL-C reduces it in cultured VSMCs [76]. In *in vivo* human studies, sevelamer has been shown to decrease LDL-C and to increase HDL-C concentrations. This improved lipid profile may be associated with the lowering grade of vascular calcification found after sevelamer therapy. These findings were confirmed with the evidence that intensive LDL-C-lowering therapy with atorvastatin in the Calcium Acetate Renagel Evaluation-2 study demonstrated similar effects on the extent of CAC in HD patients treated with sevelamer and those treated with calcium acetate [77].

The calcium-sensing receptor (CaR) is a G protein-coupled receptor that binds calcium ions and makes it possible to respond to changes in the extracellular calcium ion levels [78]. CaR expression in the arterial wall has been found to be profoundly decreased in HD patients compared with normal subjects [79]. These results are compatible with those reported by Alam et al. [80], who showed lower expression CaR in the calcified human arteries compared with those without calcification. These findings indicate that CaR expression was closely associated with vascular calcification in the vessel wall. Ivanovski et al. [81] showed finding of direct suppression of phosphate-stimulated calcium deposition in cultured human VSMC *in vitro* by a calcimimetic R-568, through local CaR activation. Lopez et al. [82] examined the effect of the R-568 alone and in combination with calcitriol on the induction of vascular calcification in a uremic rat model with SHPT. The results of the experiment indicated that the R-568 decreased serum PTH concentrations

without induction of vascular calcification, suppressed calcitriol-stimulated calcium deposition on vasculature, and reduced mortality rate related to supplementation of calcitriol. They concluded that R-568 suppresses increased serum PTH concentrations in uremic rats and inhibits calcitriol-stimulated calcium deposition in arterial tissues.

Bisphosphonates might play a possible role in the treatment of vascular calcification because these agents have been found to eliminate vascular calcification in experimental animal models. Tamura et al. [83] previously reported that etidronate suppressed calcitriol-stimulated aortic calcium deposition in uremic rats. They showed that 2 mg/kg of etidronate was not effective but that 5–10 mg/kg of etidronate inhibited calcium deposition in the aorta. In another experimental study using cultured bovine VSMCs, pamidronate reduced arterial calcium deposition [84]. In clinical studies, etidronate has been found to suppress and even reverse the CAC progression in some of HD patients [8, 85], but the mechanism is unclear. Bisphosphonates suppress bone resorption, with decreased efflux of calcium and phosphate, limiting their deposition in the vascular tissues, or may affect the function of the sodium/phosphate cotransporter in VSMCs [86].

There are a few prospective randomized trials available in the literature with therapeutic interventions aimed at controlling vascular calcification and improving survival in patients with advanced CKD. Since there is an association between CKD-MBD, vascular calcification and mortality, mineral balance abnormalities became an obvious target for therapeutic interventions. Unfortunately, no additional data have been published to change the perspective in the KDIGO guidelines [69]. The EVOLVE trial in 3883 HD patients was conducted to test the hypothesis that treatment with cinacalcet would reduce the risks of death and nonfatal cardiovascular events [87]. However, no benefit was demonstrated from using the calcimimetic agent.

8. Conclusion

Vascular calcification is highly prevalent in ESRD and independently predictive of future cardiovascular events and mortality. Calcification occurs in both the intimal and medial layers of vasculature, but medial calcification is the major form in ESRD patients. Medial calcification increases arterial stiffness and pulse pressure, induces left ventricular hypertrophy, reduces perfusion of the coronary arteries, and ultimately promotes increased cardiovascular mortality. Vascular calcification results not from a passive deposition of calcium and phosphate but rather is an active cell-mediated process involving vascular smooth muscle cell apoptosis and vesicle release; muscle cell differentiation forms a contractile to osteoblast-like phenotype. Cutting-edge scientific research on the mechanisms underlying vascular calcification is increasingly being undertaken, and further insight into the mechanisms may lead to the development of several types of therapeutic agents that will improve the cardiovascular outcome in ESRD patients.

Author details

Kosaku Nitta

Address all correspondence to: knitta@kc.twmu.ac.jp

Department of Medicine, Kidney Center, Tokyo Women's Medical University, Tokyo, Japan

References

- [1] Moe SM, Drueke T, Lameire N, Eknoyan G. Chronic kidney disease-mineral-bone disorder: a new paradigm. *Adv Chronic Kidney Dis* 2007; 14: 3–12.
- [2] Goldsmith D, Covic A, Sambrook P, Ackrill P. Vascular calcification in long-term haemodialysis patients in a single unit: a retrospective analysis. *Nephron* 1997; 77: 37–43.
- [3] Moe SM, Chen NX. Mechanisms of vascular calcification in chronic kidney disease. *J Am Soc Nephrol* 2008; 19: 213–6.
- [4] Shroff RC, Shanahan CM. The vascular biology of calcification. *Semin Dial* 2007; 20: 103–9.
- [5] Chertow GM, Raggi P, Chasan-Taber S, et al. Determinants of progressive vascular calcification in haemodialysis patients. *Nephrol Dial Transplant* 2004; 19: 1489–96.
- [6] Raggi P, Bellasi A, Ferramosca E, Islam T, Muntner P, Block GA. Association of pulse wave velocity with vascular and valvular calcification in hemodialysis patients. *Kidney Int* 2007; 71: 802–7.
- [7] Nitta K, Akiba T, Uchida K, et al. Left ventricular hypertrophy is associated with arterial stiffness and vascular calcification in hemodialysis patients. *Hypertens Res* 2004; 27: 47–52.
- [8] Nitta K, Akiba T, Suzuki K, et al. Effects of cyclic intermittent etidronate therapy on coronary artery calcification in patients receiving long-term hemodialysis. *Am J Kidney Dis* 2004; 44: 680–8.
- [9] Raggi P, Chertow GM, Torres PU, et al. The ADVANCE study: a randomized study to evaluate the effects of cinacalcet plus low-dose vitamin D on vascular calcification in patients on hemodialysis. *Nephrol Dial Transplant* 2010; 26: 1327–39.
- [10] Kalantar-Zadeh K, Block G, Humphreys MH, Kopple JD. (2003) Reverse epidemiology of cardiovascular risk factors in maintenance dialysis patients. *Kidney Int* 2003; 63: 793–808.

- [11] Elliott RJ, McGrath LT. Calcification of the human thoracic aorta during age. *Calcif Tissue Int* 1994; 54: 268–73.
- [12] Atkinson J. Age-related medial elastocalcinosis in arteries: mechanisms, animal models, and physiological consequences. *J Appl Physiol* 2008; 105: 1643–51.
- [13] Shanahan C, Cary N, Salisbury J, Proudfoot D, Weissberg P, Edmonds M. (1999) Medial localization of mineralization-regulating proteins in association with Monckeberg's sclerosis: evidence for smooth muscle cell-mediated vascular calcification. *Circulation* 1999; 100: 2168–76.
- [14] Shioi A, Taniwaki H, Jono S, Okuno, Y., Koyama, H., Mori, K. and Nishizawa, Y. Monckeberg's medial sclerosis and inorganic phosphate in uremia. *Am J Kidney Dis* 2001; 38: S47–9.
- [15] Wexler L, Brundage B, Crouse J, Detrano R, et al. Coronary artery calcification: pathophysiology, epidemiology, imaging methods, and clinical implications. A statement for health professionals from the American Heart Association. *Circulation* 1996; 94:1175–92.
- [16] London G, Marchais S, Guerin A, Metivier F, Adda H. Arterial structure and function in end-stage renal disease. *Nephrol Dial Transplant* 2002; 17: 1713–24.
- [17] Dhore CR, Cleutjens JP, Lutgens E, et al. Differential expression of bone matrix regulatory proteins in human atherosclerotic plaques. *Arterioscler Thromb Vasc Biol* 2001; 21: 1998–2003.
- [18] Chillon JM, Mozar A, Six I, et al. Pathophysiological mechanisms and consequences of cardiovascular calcifications: role of uremic toxicity. *Ann Pharm Fr* 2009; 67: 234–40.
- [19] Shroff RC, McNair R, Figg N, et al. Dialysis accelerates medial vascular calcification in part by triggering smooth muscle cell apoptosis. *Circulation* 2008; 118: 1748–57.
- [20] Chen NX, Duan D, O'Neill KD, et al. The mechanisms of uremic serum-induced expression of bone matrix proteins in bovine vascular smooth muscle cells. *Kidney Int* 2006; 70: 1046–53.
- [21] Speer MY, Yang HY, Brabb T, et al. Smooth muscle cells give rise to osteochondrogenic precursors and chondrocytes in calcifying arteries. *Circ Res* 2009; 104: 733–41.
- [22] Cannata-Andia JB, Rodriguez-Garcia M, Carrillo-Lopez N, Naves-Diaz M, Diaz-Lopez B. Vascular calcifications: pathogenesis, management, and impact on clinical outcomes. *J Am Soc Nephrol* 2006; 17 (12 Suppl 3): S267–73.
- [23] Raggi P, Boulay A, Chasan-Taber S, et al. Cardiac calcification in adult hemodialysis patients. A link between end-stage renal disease and cardiovascular disease? *J Am Coll Cardiol* 2002; 39: 695–701.

- [24] Kanbay M, Goldsmith D, Akcay A, Covic A. Phosphate: the silent stealthy cardiorenal culprit in all stages of chronic kidney disease: a systematic review. *Blood Purif* 2009; 27: 220–30.
- [25] Kestenbaum B, Sampson JN, Rudser KD, et al. Patterson, D. J., Seliger, S. L., Young, B., Sherrard, D. J. and Andress, D. L. (2005) Serum phosphate levels and mortality risk among people with chronic kidney disease. *J Am Soc Nephrol* 2005; 16: 520–8.
- [26] Yang H, Curinga G, Giachelli, C. Elevated extracellular calcium levels induce smooth muscle cell matrix mineralization in vitro. *Kidney Int* 2004; 66: 2293–9.
- [27] Reynolds JL, Joannides AJ, Skepper JN, et al. Human vascular smooth muscle cells undergo vesicle-mediated calcification in response to changes in extracellular calcium and phosphate concentrations: a potential mechanism for accelerated vascular calcification in ESRD. *J Am Soc Nephrol* 2004; 15: 2857–67.
- [28] Jono S, McKee M, Murray C, et al. Phosphate regulation of vascular smooth muscle cell calcification. *Circ Res* 2000; 87: E10–17.
- [29] El-Abbadi MM, Pai AS, Leaf EM, et al. Phosphate feeding induces arterial medial calcification in uremic mice: role of serum phosphorus, fibroblast growth factor-23, and osteopontin. *Kidney Int* 2009; 75: 1297–307.
- [30] Eknoyan G, Levin A, Levin NW. Bone metabolism and disease in chronic kidney disease. *Am J Kidney Dis* 2003; 42: S1–201.
- [31] Levin A, Bakris G, Molitch M, et al. Prevalence of abnormal serum vitamin D, PTH, calcium, and phosphorus in patients with chronic kidney disease: results of the study to evaluate early kidney disease. *Kidney Int* 2007; 71: 31–8.
- [32] Holick M. Vitamin D deficiency. *N Engl J Med* 2007; 357: 266–81.
- [33] Barreto DV, Barreto FC, Liabeuf S, et al. Vitamin D affects survival independently of vascular calcification in chronic kidney disease. *Clin J Am Soc Nephrol* 2009; 4: 1128–35.
- [34] Li Y, Kong J, Wei M, Chen Z, Liu S, Cao L. 1,25-Dihydroxyvitamin D₃ is a negative endocrine regulator of the renin–angiotensin system. *J Clin Invest* 2002; 110: 229–38.
- [35] Henley C, Colloton M, Cattley RC, et al. 1,25-Dihydroxyvitamin D₃ but not cinacalcet HCl (Sensipar/Mimpara) treatment mediates aortic calcification in a rat model of secondary hyperparathyroidism. *Nephrol Dial Transplant* 2005; 20: 1370–7.
- [36] Mathew S, Lund R, Chaudhary L, Geurs T, Hruska K. Vitamin D receptor activators can protect against vascular calcification. *J Am Soc Nephrol* 2008; 19: 1509–19.
- [37] Shimada T, Kakitani M, Yamazaki Y, et al. Targeted ablation of Fgf23 demonstrates an essential physiological role of FGF23 in phosphate and vitamin D metabolism. *J Clin Invest* 2004; 113: 561–8.

- [38] Shimada T, Hasegawa H, Yamazaki Y, et al. FGF23 is a potent regulator of the vitamin D metabolism and phosphate homeostasis. *J Bone Miner Res* 2004; 19: 429–35.
- [39] Segawa H, Kawakami E, Kaneko I, et al. Effect of hydrolysis-resistant FGF23-R179Q on dietary phosphate regulation of the renal type II Na/Pi transporter. *Pflugers Arch* 2003; 446: 585–92.
- [40] Kuro-o M, Matsumura Y, Aizawa H, et al. Mutation of the mouse *Klotho* gene leads to a syndrome resembling ageing. *Nature* 1997; 390: 45–51.
- [41] Tsujikawa H, Kurotaki Y, Fujimori T, et al. *Klotho*, a gene related to a syndrome resembling human premature ageing, functions in a negative regulatory circuit of vitamin D endocrine system. *Mol Endocrinol* 2003; 17: 2393–403.
- [42] Razzaque MS, Sitara D, Taguchi T, et al. Premature aging-like phenotype in fibroblast growth factor 23 null mice is a vitamin D-mediated process. *FASEB J* 2006; 20: 720–2.
- [43] Nakatani T, Sarraj B, Ohnishi M, et al. In vivo genetic evidence for *Klotho*-dependent, fibroblast growth factor 23 (*Fgf23*)-mediated regulation of systemic phosphate homeostasis. *FASEB J* 2009; 23: 433–41.
- [44] Kurosu H, Ogawa Y, Miyoshi M, et al. Regulation of fibroblast growth factor-23 signaling by *Klotho*. *J Biol Chem* 2006; 281: 6120–3.
- [45] Mohammadi M, Olsen SK, Ibrahim OA. Structural basis for fibroblast growth factor receptor activation. *Cytokine Growth Factor Rev* 2005; 16: 107–37.
- [46] Krajisnik T, Björklund P, Marsell R, et al. Fibroblast growth factor-23 regulates parathyroid hormone and 1-hydroxylase expression in cultured bovine parathyroid cells. *J Endocrinol* 2007; 195: 125–31.
- [47] Kawata T, Imanishi Y, Kobayashi K, et al. Parathyroid hormone regulates fibroblast growth factor-23 in a mouse model of primary hyperparathyroidism. *J Am Soc Nephrol* 2007; 18: 2683–8.
- [48] Ketteler M, Vermeer C, Wanner C, Westenfeld R, Jahn-Dechent W, Floege J. Novel insights into uremic vascular calcification: role of matrix Gla protein and α -2-Heremans Schmid glycoprotein/fetuin. *Blood Purif* 2002; 20: 473–6.
- [49] Ketteler M, Wanner C, Metzger T, et al. Deficiencies of calcium-regulatory proteins in dialysis patients: a novel concept of cardiovascular calcification in uremia. *Kidney Int* 2003; Suppl 84: S84–7.
- [50] Schafer C, Heiss A, Schwarz A, et al. The serum protein α 2-Heremans-Schmid glycoprotein/fetuin-A is a systemically acting inhibitor of ectopic calcification. *J Clin Invest* 2003; 112: 357–66.
- [51] Reynolds JL. Multifunctional roles for serum protein fetuin-A in inhibition of human vascular smooth muscle cell calcification. *J Am Soc Nephrol* 2005; 16: 2920–30.

- [52] Price P, Williamson M. Primary structure of bovine matrix Gla protein, a new vitamin K-dependent bone protein. *J Biol Chem* 1985; 260: 14971–5.
- [53] Cancela L, Hsieh CL, Francke U, Price PA, (1990) Molecular structure, chromosome assignment, and promoter organization of the human matrix Gla protein gene. *J Biol Chem* 1990; 265: 15040–8.
- [54] Luo G, Ducy P, McKee M, et al. Spontaneous calcification of arteries and cartilage in mice lacking matrix GLA protein. *Nature* 1997; 386: 78–81.
- [55] Bostrom K, Tsao D, Shen S, Wang Y, Demer L. Matrix GLA protein modulates differentiation induced by bone morphogenetic protein-2 in C3H10T1/2 cells. *J Biol Chem* 2001; 276: 14044–52.
- [56] Parker B, Ix J, Cranenburg E, Vermeer C, Whooley M, Schurgers L. (2009) Association of kidney function and uncarboxylated matrix Gla protein: data from the Heart and Soul Study. *Nephrol Dial Transplant* 2009; 24: 2095–101.
- [57] Collin-osdoby P. Regulation of vascular calcification by osteoclast regulatory factors RANKL and osteoprotegerin. *Circ Res* 2004; 95: 1046–57.
- [58] Morena M, Dupuy AM, Jaussent I, et al. A cut-off value of plasma osteoprotegerin level may predict the presence of coronary artery calcifications in chronic kidney disease patients. *Nephrol Dial Transplant* 2009; 24: 3389–97.
- [59] Nitta K, Akiba T, Uchida K, et al. Serum osteoprotegerin levels and the extent of vascular calcification in haemodialysis patients. *Nephrol Dial Transplant* 2004; 19: 1886–9.
- [60] Bennet BJ, Scatena M, Kirk EA, et al. Osteoprotegerin inactivation accelerates advanced atherosclerotic lesion progression and calcification in older ApoE^{-/-} mice. *Arterioscler Thromb Vasc Biol* 2006; 26: 2117–24.
- [61] Schoppet M, Sattler AM, Schaefer JR, Herzum M, Maisch B, Hofbauer LC. (2003) Increased osteoprotegerin serum levels in men with coronary artery disease. *J Clin Endocrinol Metab* 2003; 88: 1024–8.
- [62] Salazar H, Raggi P. Usefulness of electron-beam computed tomography. *Am J Cardiol* 2002; 89: 17B-22B.
- [63] Chertow GM, Raggi P, Chasan-Taber S, Bommer J, Holzer H, Burke SK. (2004) Determinants of progressive vascular calcification in haemodialysis patients. *Nephrol Dial Transplant* 2004; 19: 1489–96.
- [64] Sharples E, Pereira D, Summers S, et al. Coronary artery calcification measured with electron-beam computerized tomography correlates poorly with coronary artery angiography in dialysis patients. *Am J Kidney Dis* 2004; 43: 313–9.
- [65] Haydar A, Hujairi N, Covic A, Pereira D, Rubens M, Goldsmith D. Coronary artery calcification is related to coronary atherosclerosis in chronic renal disease patients: a

- study comparing EBCT-generated coronary artery calcium scores and coronary angiography. *Nephrol Dial Transplant* 2004; 19: 2307–12.
- [66] Moe SN, O'Neill KD, Fineberg N, Persohn S, Ahmed S, Garrett P, Meyer CA. Assessment of vascular calcification in ESRD patients using spiral CT. *Nephrol Dial Transplant* 2003; 18: 1152–1158
- [67] Nitta K, Akiba T, Suzuki K, et al. Assessment of coronary artery calcification in hemodialysis patients using multi-detector spiral CT scan. *Hypertens Res* 2004; 27: 527–33.
- [68] Taniwaki H, Ishimura E, Tabata T, et al. Aortic calcification in haemodialysis patients with diabetes mellitus. *Nephrol Dial Transplant* 2005; 20: 2472–8.
- [69] Kidney Disease: Improving Global Outcomes (KDIGO) CKD-MBD Work Group. KDIGO clinical practice guideline for the diagnosis, evaluation, prevention, and treatment of chronic kidney disease-mineral and bone disorder (CKD-MBD). *Kidney Int* 2009; Suppl 113: S1–S130.
- [70] Kauppila LI, Polak JF, Cupples LA, Hannan MT, Kiel DP, Wilson PW. New indices to classify location, severity and progression of calcific lesions in the abdominal aorta: a 25-years follow-up study. *Atherosclerosis* 1997; 132: 245–50.
- [71] Ogawa T, Ishida H, Matsuda N, et al. Simple evaluation of aortic arch calcification by chest radiography in hemodialysis patients. *Hemodial Int* 2009; 13: 301–6.
- [72] Chertow GM, Burke SK, Dillon MA, Slatopolsky E. Long-term effects of sevelamer hydrochloride on the calcium \times phosphate product and lipid profile of hemodialysis patients. *Nephrol Dial Transplant* 1999; 14: 2907–14.
- [73] Chertow GM, Burke SK, Raggi P. Sevelamer attenuates the progression of coronary and aortic calcification in hemodialysis patients. *Kidney Int* 2002; 62: 245–52.
- [74] Cozzolino M, Staniforth ME, Liapis H, et al. Sevelamer hydrochloride attenuates kidney and cardiovascular calcifications in long-term experimental uremia. *Kidney Int* 2003; 64: 1653–61.
- [75] Block GA, Spiegel DM, Ehrlich J, et al. Effects of sevelamer and calcium on coronary artery calcification in patients new to hemodialysis. *Kidney Int* 2005; 68: 1815–24.
- [76] Proudfoot D, Davies JD, Skepper JN, Weissberg PL, Shanahan CM. Acetylated low-density lipoprotein stimulates human vascular smooth muscle cell calcification by promoting osteoblastic differentiation and inhibiting phagocytosis. *Circulation* 2002; 106: 3044–50.
- [77] Qunibi W, Moustafa M, Muenz LR, et al. A 1-year randomized trial of calcium acetate versus sevelamer on progression of coronary artery calcification in hemodialysis patients with comparable lipid control: the Calcium Acetate Renegel Evaluation-2 (CARE-2) study. *Am J Kidney Dis* 2008; 51: 952–65.

- [78] Brown EM, MacLeod RJ. Extracellular calcium sensing receptors as integrators of multiple metabolic signals. *Cell Calcium* 2004; 35: 209–16.
- [79] Molostvov G, James S, Fletcher S, et al. Extracellular calcium-sensing receptor is functionally expressed in human artery. *Am J Physiol Renal Physiol* 2007; 293: F946–55.
- [80] Alam MU, Kirton JP, Wilkinson FL, et al. Calcification is associated with loss of functional calcium-sensing receptor in vascular smooth muscle cells. *Cardiovasc Res* 2009; 81: 260–8.
- [81] Ivanovski O, Nikolov IG, Joki N, et al. The calcimimetic R-568 retards uremia-enhanced vascular calcification and atherosclerosis in apolipoprotein E deficient (apoE(-/-)) mice. *Atherosclerosis* 2009; 205:55–62.
- [82] Lopez I, Aguilera-Tejero E, Mendoza FJ, et al. Calcimimetics R-568 decreases extraosseous calcifications in uremic rats treated with calcitriol. *J Am Soc Nephrol* 2006; 17: 795–804.
- [83] Tamura K, Suzuki Y, Matsushita M, Fujii, H., Miyaura, C., Aizawa, S. and Kogo, H. (2007) Prevention of aortic calcification by etidronate in the renal failure rat model. *Eur J Pharmacol* 2007; 558: 159–66.
- [84] Saito E, Wachi H, Sato F, Sugitani H, Seyama Y. Treatment with vitamin k2 combined with bisphosphonates synergistically inhibits calcification in cultured smooth muscle cells. *J Atheroscler Thromb* 2007; 14: 317–24.
- [85] Hashiba H, Aizawa S, Tamura K, Kogo H. Inhibition of the progression of aortic calcification by etidronate treatment in hemodialysis patients: long-term effects. *Ther Apher Dial* 2006; 10: 59–64.
- [86] Persy V, De Broe M, Ketteler M. Bisphosphonates prevent experimental vascular calcification: Treat the bone to cure the vessels? *Kidney Int* 2006; 70: 1537–8.
- [87] Chertow GM, Block GA, Correa-Rotter R, et al. Effect of cinacalcet on cardiovascular disease in patients undergoing dialysis. *N Engl J Med* 2012; 367: 2482–94.