

We are IntechOpen, the world's leading publisher of Open Access books Built by scientists, for scientists

4,800

Open access books available

122,000

International authors and editors

135M

Downloads

Our authors are among the

154

Countries delivered to

TOP 1%

most cited scientists

12.2%

Contributors from top 500 universities



WEB OF SCIENCE™

Selection of our books indexed in the Book Citation Index
in Web of Science™ Core Collection (BKCI)

Interested in publishing with us?
Contact book.department@intechopen.com

Numbers displayed above are based on latest data collected.
For more information visit www.intechopen.com



Dental Implants

Dongliang Zhang and Lei Zheng

Additional information is available at the end of the chapter

<http://dx.doi.org/10.5772/59258>

1. Introduction

This chapter reviews the present and probable future need and demand for dental implants. A dental implant is defined as an artificial tooth root replacement and is used to support restorations that resemble a natural tooth or group of natural teeth.

2. The goal of modern dentistry

The goal of modern dentistry is to return patients to oral health in a predictable fashion. The partial and complete edentulous patient may be unable to recover normal function, esthetics, comfort, or speech with a traditional removable prosthesis. The patient's function when wearing a denture may be reduced to one sixth of that level formerly experienced with natural dentition; however, an implant prosthesis may return the function to near-normal limits. The esthetics of the edentulous patient are affected as a result of muscle and bone atrophy. Continued bone resorption leads to irreversible facial changes. An implant prosthesis allows normal muscle function, and the implant stimulates the bone and maintains its dimension in a manner similar to healthy natural teeth. As a result, the facial features are not compromised by lack of support as often required for removable prostheses. In addition, implant-supported restorations are positioned in relation to esthetics, function, and speech, not in neutral zones of soft tissue support. The soft tissues of the edentulous patients are tender from the effects of thinning mucosa, decreased salivary flow, and unstable or unretentive prostheses. The implant-retained restoration does not require soft tissue support and improves oral comfort. Speech is often compromised with soft tissue-borne prostheses because the tongue and perioral musculature may be compromised to limit the movement of the mandibular prosthesis. The implant prosthesis is stable and retentive without the efforts of the musculature. Implant prostheses often offer a more predictable treatment course than traditional restorations. Thus

the profession and the public are becoming increasingly aware of this dental discipline. Manufacturers' sales have increased from a few million dollars to more than several hundred million dollars. Almost every professional journal now publishes refereed reports on dental implants. All U.S. dental schools now teach implant dentistry to all interfacing specialties. Implant dentistry to all interfacing specialties. Implant dentistry has finally been accepted by organized dentistry. The current trend to expand the use of implant dentistry will continue until every restorative practice uses this modality for abutment support of both fixed and removable prostheses on a regular basis as the primary option for all tooth replacement.

3. Options for replacement of lost teeth

Implants can be necessary when natural teeth are lost. When tooth loss occurs, masticatory function is diminished; when the underlying bone of the jaws is not under normal function it can slowly lose its mass and density, which can lead to fractures of the mandible and reduction of the vertical dimension of the middle face. Frequently, the physical appearance of the person is noticeably affected.

When a tooth is lost, the individual and dentist face two choices. The first choice is: should I replace the missing tooth? The second is: what is the best way to replace it? Although these decisions may seem sequential, they are interrelated in important ways. The technical options available can influence the decision to replace a tooth, and modern science has produced more and better options for tooth replacement in many circumstances. The age and general health of the patient are critical. The condition of the remaining dentition, its configuration in the mouth, and its periodontal support are very important aspects of the decision to replace. Finally, the relative cost of options can play a role, but should not be dispositive for a treatment plan. In making these decisions, the dentist and patient must evaluate all of these factors to reach the best treatment for a particular patient.

A number of restorative options for the treatment of missing teeth are recognized as accepted dental therapy, depending on particular circumstances the patient presents. These include:

1. Tissue-supported removable partial dentures (Figure 1)
2. Tooth-supported bridges
3. Implant-supported teeth (Figure 2)

Likewise, there are two basic options for replacing teeth in a completely edentulous arch:

1. Tissue-supported removable complete dentures
2. Implant-supported over-dentures

All these therapies have their indications for use.

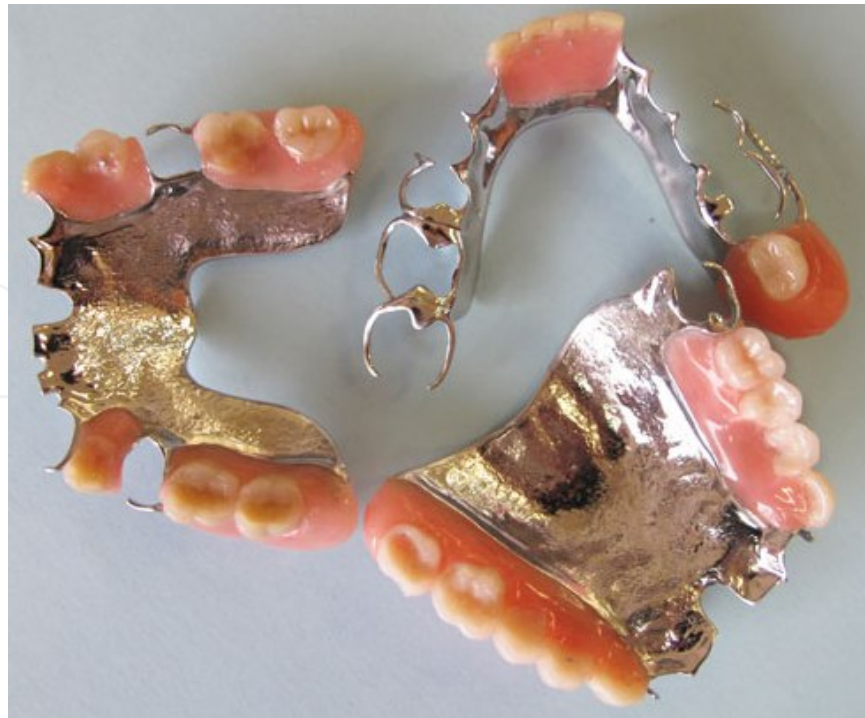

Figure 1. A typical collection of prosthetic devices, including flippers, removable partial dentures.

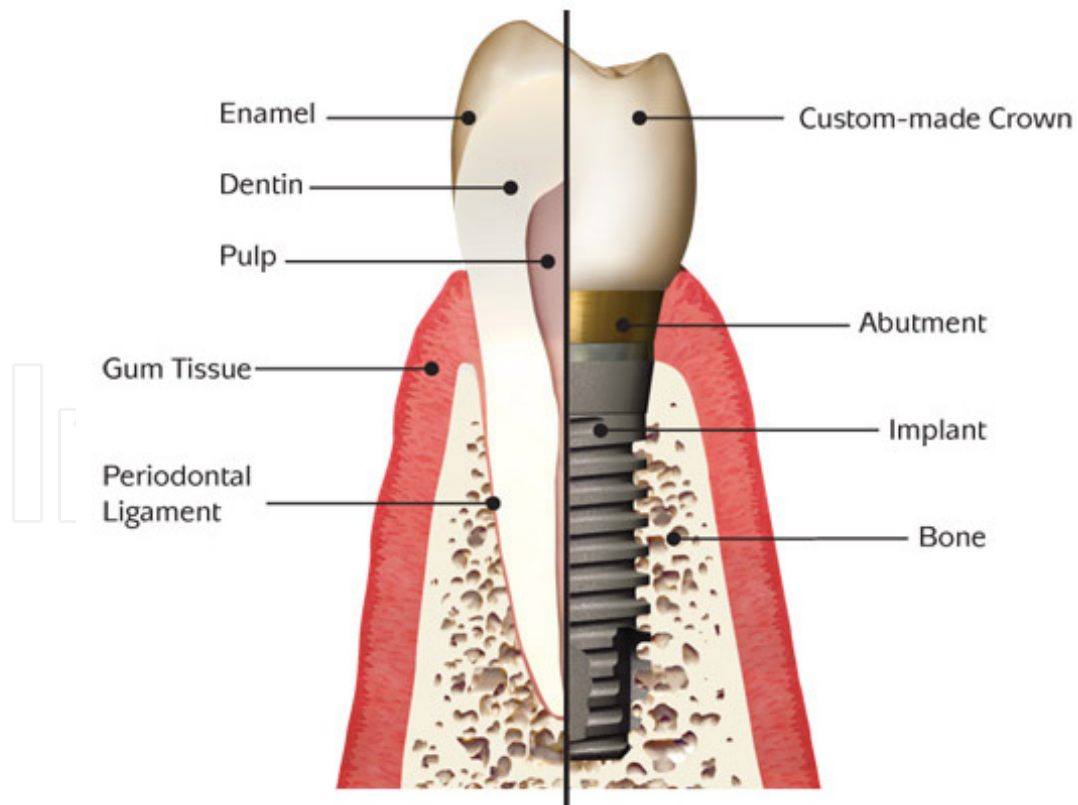


Figure 2. Comparison of natural tooth and crown with implant and crown.

4. Bone-supported prostheses

4.1. Dental implants

The implant is placed where the root of the missing tooth used to be. The replacement root is then used to attach a replacement tooth. Like the other options, dental implants are used to replace missing teeth and restore masticatory function to an individual's dentition.

The major types of dental implants are osseointegrated and fibrointegrated implants. Earlier implants, such as the subperiosteal implant and the blade implant, were usually fibrointegrated. The most widely accepted and successful implant today is the osseointegrated implant. Examples of endosseous implants (implants embedded into bone) date back over 1350 years. While excavating Mayan burial sites in Honduras in 1931, archaeologists found a fragment of mandible with an endosseous implant of Mayan origin, dating from about 600 AD.

Widespread use of osseointegrated dental implants is more recent. Modern dental implantology developed out of the landmark studies of bone healing and regeneration conducted in the 1950s and 1960s by Swedish orthopedic surgeon P.I. Brånemark. This therapy is based on the discovery that titanium can be successfully fused with bone when osteoblasts grow on and into the rough surface of the implanted titanium. This forms a structural and functional connection between the living bone and the implant. A variation on the implant procedure is the implant-supported bridge, or implant-supported denture.

Today's dental implants are strong, durable, and natural in appearance. They offer a long-term solution to tooth loss. Dental implants are among the most successful procedures in dentistry. Studies have shown a 5-year success rate of 95% for lower jaw implants and 90% for upper jaw implants. The success rate for upper jaw implants is slightly lower because the upper jaw (especially the posterior section) is less dense than the lower jaw, making successful implantation and osseointegration potentially more difficult to achieve. Lower posterior implantation has the highest success rate of all dental implants.

Dental implants are less dependent than tooth- or tissue-supported prostheses on the configuration of the remaining natural teeth in the arch. They can be used to support prostheses for a completely edentulous arch, for an arch that does not have posterior tooth support, and for almost any configuration of partial edentulism with tooth support on both sides of the edentulous space.

Additionally, dental implants may be used in conjunction with other restorative procedures for maximum effectiveness. For example, a single implant can serve to support a crown replacing a single missing tooth. Implants also can be used to support a dental bridge for the replacement of multiple missing teeth, and can be used with dentures to increase stability and reduce gum tissue irritation. Another strategy for implant placement within narrow spaces is the incorporation of the mini-implant. Mini-implants may be used for small teeth and incisors.

Modern dental implants are virtually indistinguishable from natural teeth. They are typically placed in a single sitting require a period of osseointegration. This integration with the bone

of the jaws takes anywhere from 3 to 6 months to anchor and heal. After that period of time a dentist places a permanent restoration for the missing crown of the tooth on the implant.

Although they demonstrate a very high success rate, dental implants may fail for a number of reasons, often related to a failure in the osseointegration process. For example, if the implant is placed in a poor position, osseointegration may not take place. Dental implants may break or become infected (like natural teeth) and crowns may become loose. Dental implants are not susceptible to caries attack, but poor oral hygiene can lead to the development of peri-implantitis around dental implants. This disease is tantamount to the development of periodontitis (severe gum disease) around a natural tooth.

Dental implant reconstruction may be indicated for tooth replacement any time after bone growth is complete. Certain medical conditions, such as active diabetes, cancer, or periodontal disease, may require additional treatment before the implant procedure can be performed. In some cases in which extensive bone loss has occurred in a jaw due to periodontal disease, implants may not be advised. Under proper circumstances, bone grafting may be used to augment the existing bone in a jaw prior to or in conjunction with placement.

5. Improvements in dental implant technology

New dental technology, materials, and designs have improved the dental implant procedure. Patients no longer have to wait to replace their missing teeth; the dental implant, abutment, and crown can be placed in just one visit. With immediate dental implants, the patient doesn't need to live with a space between teeth or wear a temporary crown while waiting for the dental implant to heal. With single-visit dental implants becoming more successful, more patients are inquiring about this procedure.

Using an ICAT cone beam CT scanner, a dentist can preplan dental implant surgery through 3-D imaging, creating a virtual mock-up of the mouth, which may eliminate an incision through the gums to find the bone. This, in turn, means less pain and healing time for the patient. During the planning stages, the prosthetic tooth can be fabricated by a dental laboratory and can be ready at the time of surgery. This procedure bypasses the osseointegration period, in which the implant fuses to the bone. Although the implant still needs to heal, it can do so with the dental crown attached.

Mini-implants are a relatively recent implant technology. They are used primarily for dentures; a series of mini-implants are placed through the mucosa into the bone of the jaw. Posts are used to anchor the appliance into place. Mini-implants mean less pain and healing time, and normally cost less than traditional dental implants. These cutting-edge dental implants also eliminate the wait on the healing process for the final step. Patients can start wearing their replacement teeth right away.

Traditional dental implants meant that a new dental appliance was necessary, but some patients may be able to use existing dentures with mini-implants. Existing dentures can be

fitted to attach to the posts implanted during surgery, enabling patients to return home with their repurposed dentures immediately after their surgery. Mini-implants are being used, in some indicated cases, to anchor dental crowns and dental bridges as well.

For the next 20 years the current elderly and baby-boom generations will be dominant factors in the demand for adult dental services. The former and a large portion of the latter did not experience the full benefits of modern preventive dentistry. They lost more teeth as children and young adults than the birth cohorts that follow them. Also, their dentitions suffered from greater caries attack, but they received substantial restorative care. Some of these restorations are likely to fail with time and a portion of those will require extraction, either due to the sequelae of previous restorative treatment or due to the advance of periodontal disease. Both generations have retained most of their natural teeth and are likely to want to replace those teeth they have already lost or will lose. Individuals aged 50 years and older today are likely to experience a substantial need for tooth replacement, and many of them will act on that need by choosing to have dental implants.

Over a longer time horizon, when today's young adults and children reach the age at which previous generations required substantial prosthetic replacement, their tooth loss is likely to be much less than those previous generations. That is good news. They will retain teeth, many of them sound. Hopefully, these groups will enjoy natural dentition throughout their life and will navigate old age with functioning, healthy, natural teeth.

6. Generic prosthetic component terminology

A generic language for endosteal implants was developed by Misch and Misch in 1992. The order in which it is presented follows the chronology of insertion to restoration. In formulating the terminology, five commonly used implant systems in the United States were referenced. Fifteen years later, the dramatic evolution of the U.S. implant market has resulted in changes in nearly all the implant lines and component designs. In 2000 the U.S. market alone had to choose from more than 1300 different implant designs and 1500 abutments in various materials, shapes, sizes, diameters, lengths, surfaces, and connections. More than ever, a common language is needed. In pharmacology the variety of pharmaceutical components makes it impossible to list them all by proprietary names, but a list by category of drugs is useful. Likewise, implant components still can be classified into broad application categories, and the practitioner should be able to recognize a certain component category and know its indications and limitations.

This book incorporates a generic terminology, first introduced by Misch and Misch for endosteal implants, that blends a continuity and familiarity of many implant systems with established definitions from the terms of the Illustrated Dictionary of Dentistry and the glossaries from Terms of The Academy of Prosthodontics, American Implantologists.

7. Generic implant body terminology

Root form implants are a category of endosteal implants designed to use a vertical column of bone, similar to the root of a natural tooth. Although many names have been applied, the 1988 National Institutes of Health consensus statement on dental implants and the American Academy of Implant Dentistry recognized the term root form. The exponential growth of implant use over the last 20 years has been paralleled by an explosion of the implant manufacturing field. There are currently more than 90 implant body designs available, offering countless combinations of design features: screws, baskets, plateaus, ball, cylinders, diameters, lengths, prosthetic connections, and surface conditions.

The most common root form design combines a separate implant body and prosthodontic abutment to permit only the implant body placement during bone healing. A second procedure is required to attach the implant abutment. The design and surgical philosophy is to achieve clinical rigid fixation that corresponds to a microscopic direct bone-to-implant interface without intervening fibrous tissue occurring over any significant portion of the implant body before the prosthetic phase of the procedure. Over the years, three different surgical approaches have been used for the two-piece implant systems: one stage, two stage, and immediate restoration. The two-stage surgical process places the implant body below the soft tissue, until the initial bone healing has occurred. During a second-stage surgery, the soft tissues are reflected to attach a permucosal element or abutment. During a one-stage surgical approach, the implant body and the permucosal abutment above the soft tissue are both placed until initial bone maturation has occurred. The abutment of the implant then replaces the permucosal element without the need for a secondary soft tissue surgery.

The immediate restoration approach places the implant body and the prosthetic abutment at the initial surgery. A restoration is then attached to the abutment (out of occlusal contacts in partially edentulous patients) at the appointment.

An implant body especially designed for one surgical method may also be selected. For example, a permucosal element may already be attached to the implant body by the manufacturer to facilitate a one-stage surgical approach. An implant body also may have a prosthetic abutment, which may be part of the inserted and restored at the initial surgery. This was the original concept first introduced by Strock in the 1930s.

There are three primary types of root form body endosteal implant based on design, cylinder, screw, or combination.

Cylinder (press-fit) root form implants depend on a coating or surface condition to provide microscopic retention to the bone. Most often the surface is either coated with a rough material (e.g., hydroxyapatite, titanium plasma spray) or a macro retentive design (e.g., sintered balls). Cylinder implants are usually pushed or tapped into a prepared bone site. They can be a parallel wall cylinder or a tapered implant design. Screw root forms are threaded into a slightly smaller prepared bone site and have the macroscopic retentive elements of a thread for initial bone fixation. They may be machined, textured, or coated. There are three basic screw-thread geometries: V-thread, buttress (or reverse buttress) thread, and power (square)

thread designs. Threaded implants are primarily available in a parallel cylinder or tapered cylinder design. Micro or macro thread features, variable thread pitch, depth, and angle, as well as self-tapping features, can be combined to create a myriad of implant designs. Combination root forms have macroscopic features from both the cylinder and screw root forms. The combination root form design also may benefit from microscopic retention to bone through varied surface treatments (machined, textured, and the addition of coatings).

Root forms also have been described by their means of insertion, healing, surgical requirements, surface characteristics, and interface.

8. Implant body regions

The implant body may be divided into a crest module (cervical geometry), a body, and an apex. Each section of an implant has features that are of benefit in the surgical or prosthetic application of the implant.

8.1. Implant body

An implant body is primarily designed for either surgical ease or prosthetic loading to the implant bone interface. Year ago, the implant body was the primary design feature. A round implant permits round surgical drills to prepare the bone. A smooth-walled cylinder implant allows the implant to be pressed or tapped into position, similar to a nail into a piece of wood. A tapered cylinder fits into the top of the osteotomy for further ease of placement.

A cylinder implant design system offers the advantage of ease of placement, even in difficult access locations. The cover screw of the implant also may be attached to the implant before implant placement. For example, in the very soft D4 bone the posterior regions of the maxilla, the surgeon must rotate a threaded implant design into place. Very soft bone may strip during threaded implant insertion. This may result in lack of initial fixation, and the implant will not be rigid. A tapered cylinder implant may be pressed by hand into soft bone and can be initially fixated more easily. The speed of implant rotation during insertion and the amount of apical force in implant insertion soft bone are less relevant for a press-fit cylinder. The cylinder system also presents some benefits for the single-tooth implant application, especially if adjacent to teeth with tall clinical crowns. Thread extenders are needed for the screw implant in these situations, as well as additional tools to insert the cover screw of the implant. In dense bone, cylinder systems also are easier and faster to place because bone tapping is not required.

Most cylinder implants are essentially smooth-sided and bullet-shaped implants that require a bioactive or increased surface area coating for retention in the bone. When these materials are placed on an implant, the surface area of bone contact increases more than 30%. The greater the functional surface area of the bone implant contact, the better the support system for the prosthesis.

A solid screw implant body design is the most commonly reported in the literature. A solid screw body is defined as an implant of a circular cross section without penetrating any vents

or holes. A number of manufactures provide this design (e.g., Nobel Biocare, Biomet, Zimmer, ITI, BioHorizons, LifeCroe, Bio-Lok). The thread may be V-shaped, buttress, reverse buttress, or square (power thread) in design. The V-shaped threaded screw has the longest history of clinical use. The most common outer thread diameter is 3.75mm, with 0.38-mm thread depth, and a 0.6-mm thread pitch (distance). The carious body lengths usually range from 7 to 16 mm, although lengths from 5 mm to 45 mm are available. Similar body designs are offered in a variety of diameters (narrow, standard, wide) to respond to the mechanical, esthetic, and anatomical requirements in different areas of the mouth.

A solid screw implant body permits the osteotomy and placement of the implant in dense cortical bone as well as in fine trabecular bone. The surgery may be easily modified to accommodate both extremes in bone density, The solid screw permits the implant removal at the time of surgery if placement is not ideal. It also permits implant removal at the Stage II surgery if angulation or crestal bony contours are not deemed adequate for long-term prosthesis success. The solid screw implant body may be machined or roughened to increase marginally the functional surface area or to take advantage of biochemical properties related to the surface coating (e, g., bone bonding or bone growth factors).

A threaded implant body is primarily designed to increase the bone-implant surface area and to decrease the stresses at the interface during occlusal loading. The functional surface area of a threaded implant is greater than a cylinder implant by a minimum of 30% and may exceed 500% depending on the thread geometry. This increase in functional implant surface area decreases the stress imposed on the implant-bone interface and is directly related to the thread geometry.

8.2. Crest module

The crest module of an implant body is that portion designed to retain the prosthetic component in a one-piece or two-piece implant system. It also represents the transition zone from the implant body design to the transosteal region of the implant at the crest of the ridge. The abutment connection area usually has a platform on which the abutment is seated; the platform offers physical resistance to axial occlusal loads. An antirotation feature also is included on the platform (external hex) or extends within the implant body (internal hex, octagon, Mores taper or cone screw, internal grooves or cam tube, and pin slots). The implant body has a design to transfer stress/strain to the bone during occlusal loads (e, g., threads or large spheres), whereas the crest module often is designed to reduce bacterial invasion. (e. g., smoother to impair plaque retention if crestal bone loss occurs). Its smoother dimension varies greatly from one system to another (0.5 to 0.5 mm). When the crest module is smooth, polished metal, it is often called a cervical collar.

A high-precision fit of the external or internal anti-rotational component (flat to flat dimension) is para-mount to the stability of the implant body/abutment connection. The prosthetic connection to the crest module is received by slip-fit or friction-fit with a butt or bevel joint. All prosthetic connections aim at providing a precise mating of the two components with minimal tolerance.

Another antirotational feature of an implant body may be flat sides or grooves along the body or apical region of the implant body. When bone grows against the flat or groove regions, the bone is placed in compression with rotational loads. The apical end of each implant should be flat rather than pointed. This allows for the entire length of the implant to incorporate design features that maximize desired strain profiles. Additionally, if an opposing cortical plate is perforated, a sharp, V-shaped apex may irritate or inflame the soft tissues if any movement occurs (e. g., the inferior border of the mandible).

9. Implant surgery

At the of insertion of a two-stage implant body (stage I surgery), a frost-stage cover screw is placed into the top of the implant to prevent bone, soft tissue, or debris from invading the abutment connection area during healing.

After a prescribed healing period sufficient to allow a supporting bone interface to develop, a second-stage procedure may be performed to expose the two-stage implant or to attach a transepithelial portion. This transepithelial portions is termed a permucosal extension because it extends the implant above the soft tissue and results in the development of a permucosal seal around the implant. This implant component has also been called a healing abutment because stage II uncover surgery often uses this device for initial soft tissue healing.

In the case of a one-stage procedure, the surgeon may have placed the permucosal extension at the time of implant insertion or may have selected an implant body design with a cervical collar of sufficient height to be supragingival. In the case of immediate load, the permucosal healing abutment may not be used at all if a temporary prosthesis is delivered on the day of surgery or may be used until the suture removal appointment and the temporary teeth delivery. The permucosal extension is available in multiple heights to accommodate soft tissue variations. It also can be straight, flared, or anatomical to assist in the initial contour of the soft tissue healing.

9.1. Prosthetic attachments

The abutment is the portion of the implant that supports or retains a prosthesis or implant superstructure. A superstructure is defined as a metal framework that attaches to the implant abutment(s) and provides either retention for a removable prosthesis (e, g., a cast bar retaining an overdenture with attachments) or the framework for a fixed prosthesis. Three main categories of implant abutments are described, according to the method by which the prosthesis or superstructure is retained to the abutment; (1) an abutment for screw retention uses a screw to retain the prosthesis or superstructure, (2) an abutment for cement retention uses dental cement to retain the prosthesis or superstructure, and (3) an abutment for attachment uses an attachment device to retain a removable prosthesis(such as an O-ring attachment).The abutment for cement/screw/attachment may be screwed or cemented into the implant body, but this aspect is not delineated within the generic terminology

Each of three abutment types may be further classified as straight or angled abutments, describing the axial relationship between the implant body and the abutment. An abutment for screw retention uses a hygiene cover screw placed over the abutment to prevent debris and calculus from invading the internally threaded portion of the abutment retention during prosthesis fabrication between prosthetic appointments.

The lack of abutment design of a decade ago has been replaced by a variety of options. The expansion of implant dentistry, its applications for esthetic dentistry, and the creativity of manufacturers in this very competitive market is responsible today. In the abutment for cement category, the doctor may choose from one-and two-piece abutments; UCLA type (plastic castable, machined/plastic castable, gold sleeve castable); two-piece esthetic; two-piece anatomical; two-piece shoulder; preangled (several angulations); or ceramic, Zirconia, or computer-assisted custom design. The abutment for screw category also has been enlarged with one-and two-piece overdenture abutments of different contours and heights.

Many manufacturers classify the prosthesis as fixed whenever cement retains the prostheses, fixed/removable when screws retain a fixed prosthesis, and removable when the restoration is removed by the patient. This description implies that only screw-retained description, because a fixed, cemented prosthesis also may be removed by the dentist (especially when a temporary cement is used). The generic language in this chapter separates prostheses into either fixed or removable in a method similar to traditional prosthetics.

9.2. Prosthesis fabrication

An impression is necessary to transfer the position and design of the implant or abutment to a master cast for prosthesis fabrication. A transfer coping is used in traditional prosthetics to position a die in an impression. Most implant manufacturers use the terms transfer and coping to describe the component used for the final impression. Therefore a transfer coping is used to position an analog in an impression and is defined by the portion of the implant it transfers to the master cast, either the implant body transfer or the abutment transfer coping.

Two basic implant restorative techniques are used to make a master impression, and each uses a different design transfer coping, based on the transfer technique performed. An indirect transfer coping uses an impression material requiring elastic properties. The indirect transfer coping is screw into the abutment or implant body and remains in place when a traditional "closed tray" impression is set and removed from the mouth. The indirect transfer coping is usually slightly tapered to allow ease in removal of the impression and often has flat sides or smooth undercuts to facilitate reorientation in the impression after it is removed.

A direct transfer, often square, and a long central screw to secure it to the abutment or implant body and may be used a pick-up implant coping. An "open tray" impression tray is used to permit direct access to the long central screw securing the indirect transfer coping. After the impression material is set, the direct transfer coping screw is unthreaded to allow removal of the impression from the mouth, direct transfer copings take advantage of impression materials having rigid properties and eliminate the error of permanent deformation because they remain within the impression until the master model is poured and separated.

9.3. Laboratory fabrication

An analog is defined as something that is analogous or similar to something else. An implant analog is used in the fabrication of the master cast to replicate the retentive portion of the implant body or abutment (implant body analog, implant abutment analog). After the master impression is obtained, the corresponding analog (e, g., implant body, abutment for screw) is attached to the transfer coping and the assembly is poured in stone to fabricate the master cast.

A prosthetic coping is a thin covering, usually designed to fit the implant abutment for screw retention. It serves as the connection between the abutment and the prosthesis or superstructure. A prefabricated coping usually is a metal component machined precisely to fit the abutment. A castable coping usually is a plastic pattern cast in the same metal as the superstructure or prosthesis. A screw-retained prosthesis or superstructure is secured to the implant body or abutment with a prosthetic screw.

10. Prosthetic options in implant dentistry

Implant dentistry is similar to all aspects of medicine in that treatment begins with a diagnosis of the patient's condition. Many treatment options stem from the diagnostic information. Traditional dentistry provides limited treatment options for the edentulous patient. Because the dentist cannot add abutments, the restoration design is directly related to the existing oral condition. On the other hand, implant dentistry can provide. On the other hand, implant dentistry can provide a range of additional abutment locations. Bone augmentation may further modify the existing edentulous condition in both the partial and total edentulous arch and therefore also affects the final prosthetic design. As a result, a number of treatment options are available to most partially and completely, the implant treatment plan of choice at a particular moment is patient and problem based. Not all patients should be treated with the same restoration type or design.

Almost all man-made creations, whether art, building, or prostheses, require the end result to be visualized and precisely planned for optimal results. Blueprints indicate the finest details for buildings. The end result should be clearly identified before the project begins, yet implant dentist often forget this simple but fundamental axiom. Historically in implant dentistry, bone available for implant insertion dictated the number and locations of dental implants. The prosthesis then was often determined after the position and number of implants were selected.

The goals of implant dentistry are to replace a patient's missing teeth to normal contour, comfort, function, esthetics, speech, and health, regardless of the previous atrophy, disease, or injury of the stomatognathic system. It is the final restoration, not the implant, that accomplish these goals. In other words, patients are missing teeth, not implants. To satisfy predictably a patient's needs and desires, the prosthesis should first be designed. In the stress treatment theorem, the final restoration is first planned, similar to the architect designing a building before making the foundation foundation. Only after this is accomplished can the abutments necessary to support the specific predetermined restoration be designed.

11. Completely edentulous prosthesis design

The completely edentulous patient is too often treated as though cost were the primary factor in establishing a treatment plan. However, the doctor and staff should specifically ask about the patient's desires. Some patients have a strong psychologic need to have a fixed prosthesis as similar to natural teeth as possible. On the other hand, some patients do not express serious concerns whether the restoration is fixed or removable as long as prosthetic problems are addressed. To assess the ideal final prosthetic design, the existing anatomy is evaluated after restoration is desired.

An axiom of implant treatment is not provide the most predictable, most cost-effective treatment that will satisfy the patient's anatomical needs and personal desires. In the completely edentulous patient, a removable implant. Supported prosthesis offers several advantages over a fixed-implant restoration.(Box 1).

BOX 1. Advantages of Removable Implant-supported Protheses in the Completely Edentulous Patient

*facial esthetics can be enhanced with labial flanges and denture teeth compared with customized metal or porcelain teeth. The labial contours of the removable restoration can replace lost bone width and height and support the labial soft tissues without hygienic compromise.

*The prosthesis can be removed at night to manage nocturnal parafunction.

*Fewer implants may be required.

*Less bone augmentation may be necessary before implant insertion.

*Shorter treatment if no bone augmentation is required.

*The treatment may be expensive for the patient.

*Long-term treatment of complications is facilitated.

*Daily home care is easier.

However, some completely edentulous patients require a fixed restoration because of desire or because their oral condition makes the fabrication of teeth difficult if a superstructure and removable prosthesis are planned. For example, when the patient has abundant bone and implants have already been placed, the lack of crown height space may not permit a removable prosthesis.

Too often, treatment plans for completely edentulous patients consist of a maxillary denture and a mandibular overdenture with two implants. However, in the long term, this treatment option may prove a disservice to the patient. The maxillary arch will continue to lose bone,

and the bone loss may even be accelerated in the premaxilla. Once this dimension is lost, the patient will have much more difficulty with retention and stability of the restoration. In addition, the lack of posterior implant support in the mandible will allow posterior bone loss to continue. Paresthesia, facial changes, and reduced posterior occlusion on the maxillary prosthesis are to be expected. The doctor should diagnose the amount of bone loss and its consequences on facial esthetics, function, and the psychological and overall health. Patients should be made aware of future compromises in bone loss and its associated problems with minimal treatment options, which do not address the continued loss of bone in regions where implants are not inserted.

It is even more important to visualize the final restoration at the onset with a fixed-implant restoration. After this first important step, the individual areas of ideal or key abutment support are determined to assess whether it is possible to place the implants to support the intended prosthesis. The patient's force and bone density in the region of implant support are evaluated. The additional implants to support the expected forces on the prosthesis designed may then be determined with implant size and design selected to match force and area conditions. Only then is the available bone evaluated to assess whether it is possible to place the implants to support the intended prosthesis. In inadequate natural or implant abutment situations, the existing oral conditions or the needs and desires of the patient must be altered. In other words, either the mouth must be modified by augmentation to place implants in the correct anatomical positions, or the mind of the patient must be modified to accept a different prosthesis type and its limitations. A fixed-implant restoration may be indicated for either the partially or the completely edentulous patient. The psychological advantage of fixed teeth is a major benefit, and edentulous patients often feel the implant teeth are better than their own. The improvement over their removable restoration is significant.

BOX 2. Advantages of fixed Restorations in the Partially Edentulous patient

1. psychological (feels, more like natural teeth)
 2. Less food entrapment
 3. Less maintenance (no attachments to change or adjust)
 4. Longevity (lasts the life of the implants)
 5. Similar overhead cost as completely implant-supported overdentures
-

The completely implant-supported overdenture requires the same number of implants as a fixed-implant restoration. Thus the cost of implant surgery may be similar for fixed or removable restorations. Fixed prostheses often last longer than overdentures, because attachments do not require replacement and acrylic denture teeth wear faster than porcelain to metal. The chance of food entrapment under a removable overdenture is often greater than

for a fixed restoration, as soft tissue extensions and support are often required in the latter. The laboratory fees for a fixed prosthesis may be similar to a bar, coping attachments, and over denture. Because the denture or partial denture fees are much less than fixed prostheses, many clinicians charge the patient a much lower fee for removable over dentures on implants. Yet chair time and laboratory fees are often similar for fixed or removable restorations that are completely implant supported. One should consider increasing the patient fees for over dentures to a level more in line with fixed restorations.

| Type | Definition |
|------|--|
| FP-1 | Fixed prosthesis; replaces only the crown; looks like a natural tooth |
| FP-2 | Fixed prosthesis; replaces the crown and a portion of the root; crown contour appears normal in the occlusal half but is elongated or hypercontoured in the gingival half |
| FP-3 | Fixed prosthesis; replaces missing crowns and gingival color and poration of the edentulous site; prosthesis most often uses denture teeth and acrylic gingival, but may be porcelain to metal |
| RP-4 | Removable prosthesis ; overdenture supported completely by implant |
| RP-5 | Removable prosthesis; overdenture supported by both soft tissue and implant |

Table 1. Prosthodontic classification

12. Partially edentulous prosthesis design

A common axiom in traditional prosthodontics for partial edentulism is to provide a fixed partial denture whenever applicable. The fewer natural teeth missing the better the indication for a fixed partial denture. This axiom also applies to implant prostheses in the partially edentulous patient. Ideally, the fixed partial denture is completely implant supported rather than joining implants in the treatment plan. Although this may be a cost disadvantage, it is outweighed by significant intraoral health benefits. The added implants in the edentulous site result in fewer pontics, more retentive units in the restoration, and less stress to the supporting bone. As a result complications are minimized and implant and prosthesis longevity are increased (BOX 2)

13. Prosthetic options

In 1989, Misch proposed five prosthetic options for implant dentistry (Table 1). The first three options are fixed prostheses (FPs). These three options may replace partial (one tooth or

several) or total dentitions and may be cemented or screw retained. They are used to communicate the appearance of the final prosthesis to all the implant team members. These options depend on the aspects of the prosthesis in the esthetic zone. Common to all fixed options is the inability of the patient to remove the prosthesis. Two types of final implant restorations are removable prostheses (RPS); they depend on the amount of implant support, not the appearance of the prosthesis.

13.1. Fixed prostheses

13.1.1. FP-1

An FP-1 is a fixed restoration and appears to the patient to replace only the anatomical crowns of the missing natural teeth. To fabricate this restoration type, there must be minimal loss of hard and soft tissues. The volume and position of the residual bone must permit ideal placement of the implant in a location similar to the root of a natural tooth. The final restoration appears very similar in size and contour to most traditional fixed prostheses used to restore or replace natural crowns of teeth.

The FP-1 prosthesis is most often desired in the maxillary anterior region, especially in the esthetic zone during smiling or speaking. The final FP-1 restoration appears to the patient to be similar to a crown on a natural tooth. However, the implant abutment can rarely be treated as a natural tooth prepared for a full crown. The cervical diameter of a maxillary central incisor is approximately 6.5 mm with an oval to triangular cross section. However, the implant abutment is usually 4 mm in diameter and round in cross section. In addition, the placement of the implant rarely corresponds exactly to the crown-root position of the original tooth. The thin labial bone lying over the facial aspect of a maxillary anterior root remodels after tooth loss and the crest width shifts to the palate, decreasing 40% within the first 2 years. The occlusal table is also usually modified in unesthetic regions to conform to the implant size and position and to direct vertical forces to the implant body. For example, posterior mandibular implant-supported prostheses have narrower occlusal tables at the expense of the buccal contour, because the implant is smaller in diameter and placed in the central fossa region of the tooth.

Because the width or height of the crestal bone is frequently lacking after the loss of multiple adjacent natural teeth, bone augmentation is often required before implant placement to achieve natural-looking crowns in the cervical region. There are no interdental papillae in edentulous ridges; therefore soft tissue augmentation also is often required to improve the interproximal gingival contour. Ignoring this step causes open “black” triangular spaces (where papillae usually be present) when the patient smiles. FP-1 prostheses are especially difficult to achieve when more than two adjacent teeth are missing. The bone loss and lack of interdental soft tissue complete the final esthetic result, especially in the cervical region of the crowns.

The restorative material of choice for an FP-1 prosthesis is porcelain to noble to noble-metal alloy. A noble-metal substructure can easily be separated and soldered in case of a nonpassive fit at the metal try-in, and noble metals in contact with implants corrode less than nonprecious alloys. Any history of exudate around a subgingival base-metal margin will dramatically

increase the corrosion effect between the implant and the base metal. A single tooth FP-1 crown may use aluminum oxide cores and porcelain crowns, or ceramic abutments and porcelain crowns. However, the risk of fracture may increase with the latter scenario, as implant forces are greater on implants than natural teeth.

13.1.2. FP-2

An FP-2 fixed prosthesis appears to restore the anatomical crown and a portion of the root of the natural tooth. The volume and topography of the available bone is more apical compared with the ideal bone position of a natural root (1 to 2 mm below the cement-enamel junction) and dictate a more apical implant placement compared with the FP-1 prosthesis. As a result, the incisal edge is in the correct position, but the gingival third of the crown is overextended, usually apical and lingual to the position of the original tooth. These restorations are similar to teeth exhibiting periodontal bone loss and gingival recession.

The patient and the clinician should be aware from the onset of treatment that the final prosthetic teeth will appear longer than healthy natural teeth (without bone loss). The esthetic zone of a patient is established during smiling in the maxillary arch and during speech of sibilant sounds for the mandibular arch. If the high lip during smiling or the low lip line longer are usually of no esthetic consequence, provided that the patient has been informed before treatment.

As the patient becomes older, the maxillary esthetic zone is altered. Only 10% of younger patients do not show any soft tissue during smiling, whereas 30% of 60 year old and 50% of 80year olds do not display gingival regions during smiling. The low lip position during speech is not affected as much as the mandibular soft tissue during speech.

A multiple-unit Fp-2 restoration does not require as specific an implant position because the cervical contour is not displayed during function. The implant position may be chosen in relation to bone width, angulation, or hygienic considerations rather than purely esthetic demands (as compared with the FP-1 prosthesis). On occasion, the implant may even be placed in an embrasure between two teeth. This often occurs for mandibular anterior teeth for full-arch fixed restorations. If this occurs, the most esthetic area usually requires the incisal two thirds of the two crowns to be ideal in width, as though the implant were not present. Only the cervical region is compromised. Although the implant is not positioned in the correct facial-lingual position, it should be placed in the correct facial-lingual position to ensure that contour, hygiene, and direction of forces are not compromised.

The material of choice for an FP-2 prosthesis is precious metal to porcelain. The amount and contour of the metal work is different than for a FP-1 restoration and is more relevant in an FP-2 prosthesis, because the amount of additional volume of tooth replacement increases the risk of unsupported porcelain in the final prosthesis, then the metal work in undercontoured.

13.1.3. FP-3

The FP-3 fixed restoration appears to replace the natural teeth crowns and has pink-colored restorative materials to replace a portion of the soft tissue. As with the FP-2 prosthesis, the

original available bone height has decreased by natural resorption or osteoplasty at the time of implant placement. To place the incisal edge of the teeth in proper position for esthetics, function, lip support, and speech, the excessive vertical dimension to be restored requires teeth that are unnatural in length. However, unlike the FP-2 prosthesis, the patient may have a normal to high maxillary lip line during smiling or a low mandibular lip line during speech. The ideal high smile line displays the interdental papilla of the maxillary anterior teeth but not the soft tissue above the midcervical regions. Approximately 7% of males and 14% of females have a high smile or “gummy” smile and display more than 2 mm of gingival above the free gingival margin of the teeth.

The patient may also have greater esthetic demands even when the teeth are out of the esthetic smile and speech zones. Patients complain that the display of longer teeth appears unnatural even though they must lift or move their lips in unnatural positions to see the covered regions of the teeth. As a result of the restored gingival color of the Fp-3, the teeth have a more natural appearance in size and shape and the pink restorative material mimics the interdental papillae and cervical emergence region. The addition of gingival-tone acrylic or porcelain for a more natural fixed prosthesis appearance is often indicated with multiple implant abutments because bone loss is common with these conditions.

There are basically two approaches of denture teeth and acrylic and metal substructure or a porcelain metal restoration. The primary factor that determines the restoration material is the amount of crown height space. An excessive crown height space means a traditional porcelain-metal restoration will have a large amount of metal in the substructure, so the porcelain thickness will not be greater than 2-mm thick. Otherwise there is an increase in porcelain fracture. Precious metals are indicated for implant restorations to decrease the risk of corrosion and improve the accuracy of the casting, as nonprecious metals shrink more during the casting process. However, the large amount of metal in the substructure acts as a heat sink and complicates the application of porcelain during the fabrication of the prosthesis. In addition, as the metal cools after casting, the thinner regions of metal cool first and create porosities in the structure. This may lead to fracture of the framework after loading. Furthermore when the casting is reinserted into the oven to bake the porcelain, the heat is maintained within the casting at different rates, thus the porcelain cool-down rate is variable, which increases the risk of porcelain fracture. In addition, the amount of precious metal in the casting adds to the weight and cost of the restoration. An FP-3 porcelain-to-metal restoration is more difficult to fabricate for the laboratory technician than an FP-2 prosthesis. The pink porcelain is harder to make appear as soft tissue and usually requires more baking cycles. This increases the risk of porosity or porcelain fracture.

An alternative to the traditional porcelain-metal fixed prosthesis is a hybrid restoration (see Table 2). This restoration design uses a smaller metal framework, with denture teeth and acrylic to join these elements together. This restoration is less expensive to fabricate and is highly esthetic because of the premade denture teeth and acrylic pink soft tissue replacements. In addition, the intermediary acrylic between the denture teeth and framework may reduce the impact force of dynamic occlusal loads. The hybrid prosthesis is easier to repair in porcelain fracture, as the denture tooth may be traditional porcelain-metal restoration. However, the

fatigue of acrylic is greater than the traditional prosthesis; therefore repair of the restoration is more commonly needed.

The crown height space determination for a hybrid versus the traditional porcelain-metal restoration is 15 mm from the bone to the occlusal plane. When less than this dimension is available, a porcelain-to-metal is suggested. When a greater crown height space is present a hybrid restoration is often fabricated.

| Consideration | Porcelain-metal | Hybrid |
|-----------------------------|-----------------|-----------------|
| Occlusal Vertical Dimension | ≤15 mm | ≥15 mm |
| Technique | Same | Same |
| Retention | Cement or screw | Cement or Screw |
| Precision of fit | Same | Same |
| Esthetics | Same | Same |
| Soft tissue | Difficult | Easier |
| Teeth | Difficult | Easier (resin) |
| Time/Appointments | Same | Less |
| Weight | More | Less |
| Cost | More | Less |
| Impact forces | More | Less |
| Volume (bulk) | Same | Same |
| Lone term | Same | Same |
| Occlusion | Same | Same |
| Speech | Same | Same |
| Hygiene | Same | Same |
| Complications | Same | Same |
| Aging of materials | Less | More |

Table 2. Comparison of Porcelain-to-Metal versus Hybrid Prostheses (FP-3)

Implants placed too facial, lingual, or in embrasures are easier to restore when vertical bone has been lost and an FP-2 or FP-3 prosthesis is fabricated, because even extremely high smile lip lines do not expose the implant abutments. The greater crown heights allow the correction of incisal edge positions. However, the FP-2 or FP-3 restoration has greater crown height compared with the FP-1 fixed types of prostheses; therefore a greater moment of force is placed on the implant cervical regions, especially during lateral forces (e.g., mandibular excursions or with cantilevered restorations). As a result, should be considered with these restorations.

An FP-2 or FP-3 prosthesis rarely has the patient's interdental papillae or ideal soft tissue contours around the emergence of the crown, because these restorations are used when there is more crown height space and the lip does not expose the soft tissue regions of the patient. In the maxillary arch, wide open embrasures between the implants may cause food impaction

or speech problems. These complications may be solved by using a removable soft tissue replacement device or making overcontoured cervical restorations. The maxillary FP-2 or FP-3 prosthesis is often extended or juxtaposed to the maxillary soft tissue so that speech is not impaired. Hygiene is more difficult to control, although access next to each implant abutment is provided.

The mandibular restoration may be left above the tissue, similar to a sanitary pontic. This facilitates oral hygiene in the mandible, especially when the implant permucosal site is level with the floor of the mouth and the depth of the vestibule. However, if the space below the restoration is too great, the lower lip may lack support in the labiomental region.

13.2. Removable prostheses

There are two kinds of removable prostheses, based upon support of the restoration (see Table 1). Patients are able to remove the restoration, but not the implant. Supported superstructure attached to the abutments. The difference in the two categories of removable restorations is not in appearance (as it is in the fixed categories). Instead, the two removable categories are determined by the amount of implant support. The most common removable implant prostheses are over dentures for completely edentulous patients, Traditional removable partial dentures with clasps on implant abutment crowns have not been reported in the literature with any frequency. No long-term or short-term studies are currently available. On the other hand, complete removable overdentures have often been reported with predictability. As a result, the removable prosthetic options are primarily overdentures for the completely edentulous.

13.2.1. RP-4

RP-4 is a removable prosthesis completely supported by the implant, teeth, or both. The restoration is rigid when inserted: overdenture attachments usually connect the removable prosthesis to a low-profile tissue bar or superstructure that splints the implant abutments. Usually five or six implants in the mandible and six to eight implants in the maxilla are required to fabricate completely with favorable dental criteria.

The implant placement criteria for an RP-4 prosthesis is different than for a fixed prosthesis. Denture teeth more acrylic are required for the removable restoration. In addition, a superstructure and overdenture attachments must be added to the implant abutments. This requires a more lingual and apical implant placement in comparison with the implant position for a fixed prosthesis. The implants in an RP-4 prosthesis (and an FP-2 or FP-3 restoration) should be placed in the mesiodistal position for the best biomechanical and hygienic situation. On occasion, the position of an attachment on the superstructure or prosthesis may also affect the amount of spacing between the implants. For example, a Hader clip requires the implant spacing to be greater than 6 mm from edge to edge, and as a consequence reduces the number of implants that may be placed between the mental foramina. The RP-4 prosthesis may have the same appearance as an FP-1, FP-2, or FP-3 restoration. A porcelain-to-metal prosthesis with attachments in selected abutment crowns can be fabricated for patients with the cosmetic desire

of a fixed prosthesis,. The overdenture attachments permit improved oral hygiene or allow the patient to sleep without the excess of nocturnal bruxism on the prosthesis.

13.2.2. RP-5

RP-5 is a removable prosthesis combining implant and soft tissue support. The amount of implant support is variable. The completely edentulous mandibular overdenture may have: (1) two anterior mandibular independent of each other; (2) splinted implants in the canine region to enhance retention; (3) three splinted implants in the premolar and central incisor areas to provide lateral stability; or (4) implants splined with a cantilevered bar to reduce soft tissue abrasions and to limit the amount of soft tissue coverage needed for prosthesis support. The primary advantage of an RP-5 restoration is the reduced cost. The prosthesis is very similar to traditional overdentures supported by natural teeth.

A preimplant treatment denture may be fabricated to ensure the patient's satisfaction. This technique is especially indicated for patients with demanding needs and desires regarding the final esthetic result. The implant dentist can also use the treatment denture as a guide for implant placement. The patient can wear the prosthesis during the healing stage. After the implants are uncovered, the superstructure is fabricated within the guidelines of the existing treatment restoration. Once this is achieved, the preimplant treatment prosthesis may be converted to the RP-4 or RP-5 restoration.

The clinician and the patient should realize that the bone will continue to resorb in the soft tissue-bone regions of the prosthesis of the prosthesis. Relines and occlusal adjustments every few years are common maintenance requirements of an RP-5 restoration. Bone resorption with RP-5restorations may occur two to three times faster than the resorption found with full dentures. This can be a factor when considering this type of treatment in young patients, despite the lesser cost and low failure rate.

Author details

Dongliang Zhang^{1*} and Lei Zheng^{2,3}

*Address all correspondence to: zhangdongliang@hotmail.com

1 Beijing Stomatology Hospital affiliated to Capital University of Medical science, Beijing City, P.R. China

2 Clinical director, Xinya dental, Changchun City, P.R. China

3 The department oral maxillofacial surgery, Jilin University, Chaoyang District, Changchun City, P.R. China

References

- [1] Mish CE: Dental education: meeting the demands of implant dentistry, *J Am Dent Assoc* 121:334-338, 1990.
- [2] Davarpanah M, Martinez H, Kebir M, Tecucianu JF, Lazzara RC, et al: *Clinical manual of implant dentistry*, London, 2003, Quintessence.
- [3] Branemark PI, Hansson BO, Adell R, et al: Osseointegrated implants in the treatment of the deentulous jaw. Experience from a 10-year period, *Scand J Plast Reconstr Surg* 16(Suppl):1-132, 1977
- [4] Misch EC, Misch CM: Generic terminology for endosseous implant prosthodontics, *J Prosthet Dent* 68:809-812, 1992.
- [5] Strock AE: Experimental work on dental implantation in the alveolus, *Am J Orthod Oral Surg* 25:5, 1939.
- [6] The glossary of prosthodontics terms, *J Prosthet Dent* 94: 10-92, 2005.
- [7] Misch CE: Consideration of biomechanical stress in treatment with dental implants, *Dent Today* 25:80,82,84,85; quiz 85, 2006.
- [8] Jacobs R, Schotte A, van Steenberghe D et al: Posterior jaw bone resorption in osseointegrated implant overdentures, *Clin Oral Implants Res* 2:63-70, 1992.
- [9] Goodacre CJ, Bernal G, Rungcharassaeng K et al: Clinical complications with implants and implant prosthodontics, *J Prosthet Dent* 90:121-132, 2003.
- [10] Misch CE: Posterior single tooth replacement. In Misch CE, editor: *Dental implant prosthetics*, St Louis, 2005, Mosby.

IntechOpen