

# We are IntechOpen, the world's leading publisher of Open Access books Built by scientists, for scientists

4,800

Open access books available

122,000

International authors and editors

135M

Downloads

Our authors are among the

154

Countries delivered to

TOP 1%

most cited scientists

12.2%

Contributors from top 500 universities



WEB OF SCIENCE™

Selection of our books indexed in the Book Citation Index  
in Web of Science™ Core Collection (BKCI)

Interested in publishing with us?  
Contact [book.department@intechopen.com](mailto:book.department@intechopen.com)

Numbers displayed above are based on latest data collected.  
For more information visit [www.intechopen.com](http://www.intechopen.com)



---

# Advances in Radiographic Techniques Used in Dentistry

---

Zühre Zafersoy Akarlan and Ilkay Peker

Additional information is available at the end of the chapter

<http://dx.doi.org/10.5772/59129>

---

## 1. Introduction

Conventional radiographic techniques have been used in dental radiography since the discovery of the x-rays. With the revolution in electronic systems, equipment's have been produced to achieve a radiographic image in a digital format. Digital images are in numeric format and differ from conventional radiographs in terms of pixels, and the different shades of gray given to these pixels [1].

A digital image is produced by analog-to-digital conversion (ADC). First, the small ranges of voltage values in the signal are grouped together as a single value. Second, every sampled signal is assigned a value and stored in the computer. Last, the computer organizes the pixels in their proper locations and displays a shade of gray corresponding the number assigned and the image becomes visible on the computer screen [1].

Two dimensional and three dimensional digital imaging modalities have been developed for dentomaxillofacial diagnosis, treatment planning and several clinical applications. These modalities consist of digital intraoral imaging, digital panoramic and cephalometric imaging and cone-beam computed tomography.

The knowledge of advances regarding radiographic techniques and proper use of them gives the opportunity to the practitioner for improvement in diagnostic tasks and treatment planning. Therefore, the aim of this chapter is to focus on the requirements, applications, advantages and disadvantages and artifacts of the currently available digital imaging techniques according to the literature.

## 2. Two dimensional digital imaging in dentistry

Two dimensional imaging is an adjunct of clinical examination in dentistry. It has an important role in the diagnosis of dental pathologies and treatment planning.

---

Two dimensional imaging could be broadly categorized as intraoral and extraoral imaging. Intraoral imaging includes periapical, bitewing and occlusal projections, while extraoral imaging includes panoramic and cephalometric projections. These both were acquired with conventional radiography; which is a technique using films, cassettes and wet film processing for long time, but nowadays with the introduction of digital systems they could be achieved with digital imaging.

Two dimensional digital imaging systems have been considerably improved since their initial introduction. This improvement in type, size, shape, radiation effective dose, and resolution of the sensors made them to be adopted in routine use in dental clinics [2,3]. The diagnostic performance of two dimensional digital imaging systems was found to be comparable with conventional radiography. Studies reported the usefulness of digital imaging in caries diagnosis [4-6], periodontal bone defects [7-9], endodontic applications and diagnosis of periapical lesions [10,11], root fractures [12] and root resorption [13,14].

### 2.1. Digital intraoral imaging

Digital intraoral imaging could be achieved by periapical, bitewing and occlusal projections. Periapical images show the crown and root of the investigated tooth/teeth and some of the surrounding structures. It is useful in dentistry as it shows the entire image of tooth/teeth, periapical region and some of the surrounding structures. Bitewing images show only the crown of the tooth/teeth and part of the root(s), but allow the visualization of both the maxillary and mandibular teeth crowns and alveolar crest in one image. Occlusal images show the palate and the floor of the oral cavity and a larger area of teeth and surrounding structures compared to periapical and bitewing projections. Assessment of bucco-lingual direction of interested regions is also possible with the cross-sectional occlusal technique. It is useful for the examination of the palate and floor of mouth and for the anterior teeth when patients are unable to open their mouth wide enough for the placement of receptors in periapical projections. Although two dimensional intraoral digital imaging is useful and has several advantages, the superimposition of unwanted structures is the main problem in capable of decision-making for correct diagnosis and treatment planning [15].

Intraoral digital imaging could be achieved with indirect, semi-direct and direct digital intraoral techniques. The dentists should have knowledge about the requirements, advantages and disadvantages of these systems in detail to maximize benefits and safe use of the systems.

**Indirect Digital Intraoral Imaging:** In this method, conventional radiographs (analog images) are transferred to digital medium with the aid of a flatbed scanner with a transparency adapter, a slide scanner and a digital camera. It is a simple way to obtain a digital image and it is less expensive compared to semi-direct and direct digital systems. This technique was used more commonly at the beginning of digital image acquisition. With the improvement and wide-spread of other digital techniques, it has lost its popularity nowadays [16].

**Semi-Direct Digital Intraoral Imaging:** Semi-direct digital intraoral imaging is possible with a system using photo-stimulable phosphor coated plates (PSP) (Figure 1). These plates are placed in the mouth of the patient and exposed to x-rays. After the exposure, they are scanned

with a special laser scanner system and the latent image becomes visible on the computer monitor [17]. The latent image is erased by exposing the plates with bright light prior to a new x-ray exposure after the plates are scanned [18,19].

The plates should not be exposed to light because this will release some of the energy captured by the plate before it is scanned and degrade the quality of the radiographic image. Hence, the plates exposed to x-ray should be kept in subdued light environment prior to scanning. [18]

Different types of scanners are present. Some of the scanners scan only one plate in each step, and other are capable of scanning more than one at each scan. [19] Scanning time also differ among modalities from 4 seconds to several minutes and according to the spatial and contrast resolution of the image.

Similar to films used in conventional radiography there are different sizes of plates, including child size, adult size, adult bitewing size and occlusal size and they can be used with the film holders used in conventional radiography [20].

Semi-direct digital imaging is a more comfortable technique for patients' compared to direct digital intraoral imaging as the plates' are flexible to some extent and the size, shape and thickness are similar to films used in conventional radiography [21].

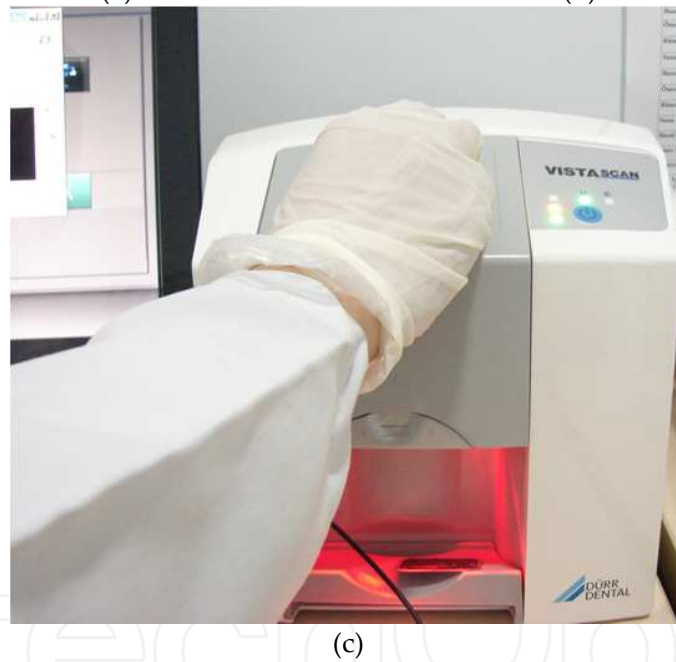

**Direct Digital Intraoral Imaging:** Direct digital intraoral images could be achieved with solid-state sensors. There are two types of solid state-sensors; charged-coupled device (CCD) and complementary metal oxide semiconductor (CMOS).

**CCD sensors:** A solid state silicon chip is used to record the image in this technology. Silicon crystals convert absorbed radiation to light and the electrons constitutes the latent image according to the light intensity. This signal is sent to the computer with a cable connecting the sensor and the computer, and the image becomes visible on the screen (Figure 2) [1,19].

**CMOS sensors:** This technology was adapted to intraoral digital imaging after the CCD sensors were invented. These sensors have a similar working principle with CCD, only the chip design differ in terms of integration of the control circuitry directly into the sensor [16]. CMOS sensors are less expensive than CCD's [1]. Initial CMOS systems had a cable connected to the sensor and computer, but nowadays cable-free type is also produced. In cable-free type, the radiographic data stored in the chip are transferred to the computer in radio-waves with the aid of a stationary radio-wave receiver connected to the computer. The manufactures instruction recommends the distance between the sensor and this receiver should not be more than 180cm, but in a study it was reported that this distance could be more than this, but should not exceed 350cm [22].

## 2.2. Digital extraoral imaging

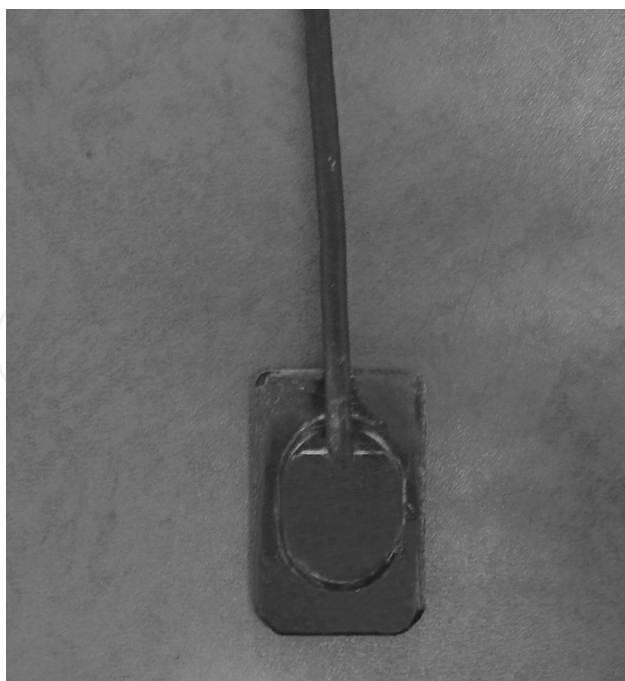
The revolution in digital extraoral radiography includes digital panoramic imaging and digital cephalometric imaging. Digital extraoral and panoramic systems have not been widely adopted since their first introduction in the dental market (Figure 3). This was due to their very high costs. Sometime after their invention, relatively cost effective systems with improved computer settings (computer speed, data storage capacities) have been manufactured and they



**Figure 1.** PSP plates (a,b) and plate scanning system (c)

have been started to be adopted in dental practice [23]. The image quality of direct digital panoramic images has been reported to be equal to conventional panoramic radiographs [24].

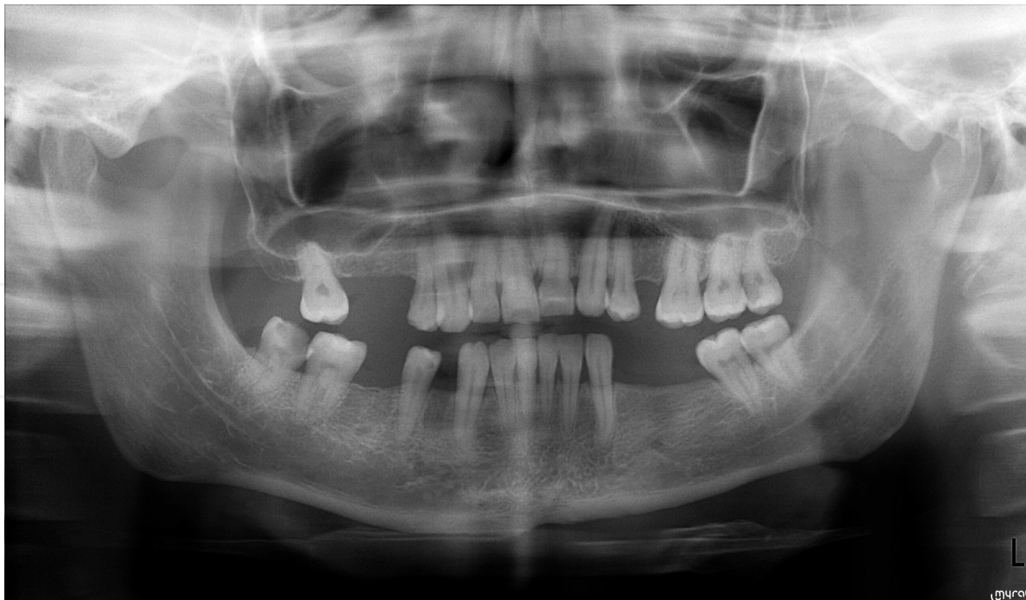Panoramic radiography has been one of the most common imaging method among dentists. This technique provides facial structures that includes both maxillary and mandibular teeth and their supporting structures to be imaged on a single film with a single exposure. It is simple and could be applied in cases when mouth opening is not enough to place an intraoral receptor, and an extreme gag reflex (Figure 4) [25].



**Figure 2.** Cabled CCD sensor

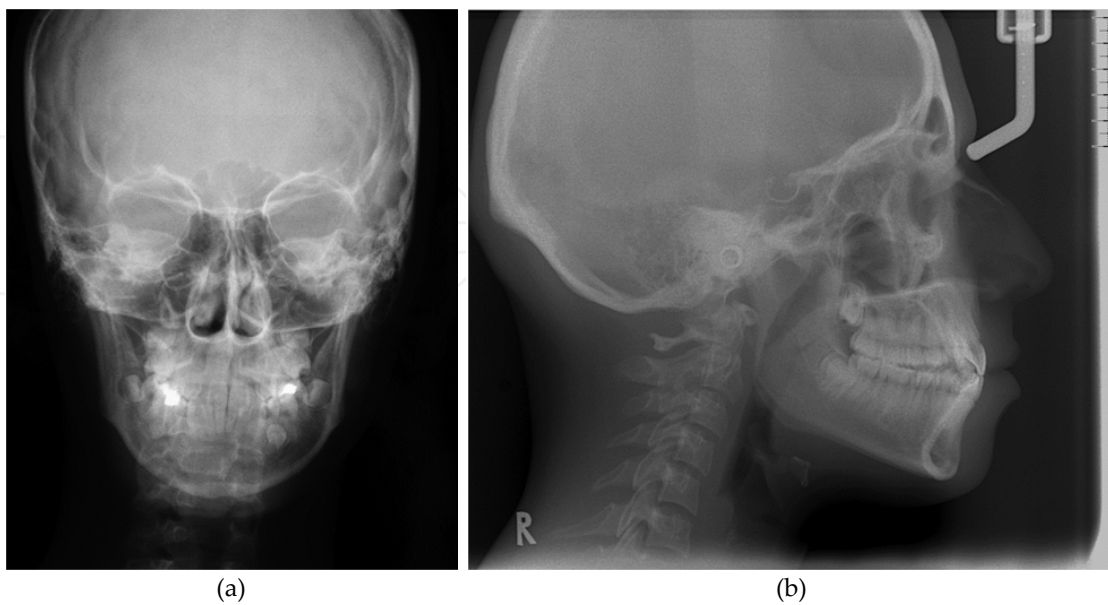


**Figure 3.** A digital panoramic unit



**Figure 4.** An example of digital panoramic image

Similar to panoramic imaging the same revolution took place in cephalometric radiography. Cephalometric radiography is a technique providing the image of the head in lateral and posterioranterior view (Figure 5). It is frequently used by orthodontists as a treatment planning tool. Some manufacturers made special digital units with a cephalometric attachment to allow exposure of standardized skull views. Digital cephalometric images make it possible to perform cephalometric analysis and superimposition on chair side computer, enhancement of the images for further aid in diagnosis, ease of storage and data transmission [26].



**Figure 5.** Digital posterioranterior (a) and lateral cephalometric image (b)

CCD sensor and PSP plate technology have been used in panoramic and cephalometric devices to capture the image. Compared with digital intraoral sensors, CCD's used in extraoral imaging contains more quantity of pixels to make the image wide and long compared with intraoral imaging. In panoramic units, the CCD is placed opposite to the x-ray source and the long axis of the array is oriented to the x-ray beam. The mechanics used for digital panoramic machine is similar to conventional technique however, it differs for cephalometric imaging. A CCD receptor in a size which could completely take the image of the skull simultaneously is very expensive; therefore to reduce the cost a different mechanic was constructed. In this system, a linear CCD array and a slit shaped x-ray beam with a scanning motion is present and this provides scanning of the skull in short time. The disadvantage of this mechanic is the increased possibility of patient movement artifacts during scanning [1].

### **2.3. Advantages and disadvantages of two dimensional digital imaging in comparison with conventional radiography**

Digital intraoral and extraoral systems have some advantages and disadvantages compared with conventional radiographic techniques. Recently, with the routine use of these systems some aspects which were stated to be advantages initially have been started to be questioned also.

**Image enhancement:** Image enhancement is the improvement of the original image to make the image visually more appealing. This could be both applied to digital intraoral and extraoral images. Image enhancement could be made by adjusting the contrast and brightness, applying various filters to reduce unsharpness and noise and zooming the image [27].

Radiographic contrast describes the range of densities on a radiograph. It is defined as the differences in densities between light and dark regions [15]. First generation digital sensors performed suboptimal images in terms of contrast and spatial resolution. This has been improved with the new detector technology [2]. The resultant image of an underexposed or overexposed digital detector could be corrected in terms of density and contrast. This especially helps to prevent the retakes due to improper contrast and density [28]. It was reported that contrast enhancement was useful for the detection of low contrast objects both in solid-state and PSP systems [29] and contrast and brightness-enhanced digital images enabled better signal detection and showed a comparable performance with film for detection of artificially induced recurrent caries [30].

There are various filters in each system which could be applied to the digital images for image enhancement. In general, there are filters which sharpen, smooth and emboss the image [31] Filters that smooth the image remove high frequency noise. Filters that sharpen the images either remove low frequency noise or enhance boundaries between regions with different intensities. (edge enhancement) [1]. Filters that emboss the image make it appear as an image with depth. This is named as "3D" in some software's as the resultant image resembles a three dimensional image. It was reported that filtration of a digital panoramic image with the emboss filter may have a value in detecting approximal caries especially in the mandibular molar region [31] and the sharpen filter may be useful for detecting subtle approximal caries [32].



However, controversial results were reported also. Digitally enhanced images with sharpness, zoom and pseudocolour were found not to be effective for the detection of occlusal caries [33].

Image processing is task dependent. Filters should be applied in special cases and they should be used properly and carefully by the clinicians. An edge enhancement filter could be useful for marginal bone height measurements around implants [29] while, it may not improve the level of accuracy for cephalometric points detection [34].

A study demonstrated digital image magnification at X3, X6 and X12 had a significant influence on observer performance in the detection of approximal caries but magnification over these values reduced the diagnostic accuracy [35]. In another study, it was reported that three digital magnifications; 1 : 1, 2 : 1, and 1 : 2 did not affect the detection of root fractures [36].

*The operator should be very careful during image enhancement, because inaccurate application of these functions may lead to inaccurate diagnosis of pathology! [1]*

**Image analysis:** Image analysis functions help to obtain diagnostically relevant information from the image. Linear, curved and angle measurements, area calculation, densitometric analysis, complex tools and procedures are present in this extent. Simple linear, curved and angle measurements, area calculation and densitometric analysis functions are generally present in the software of digital imaging devices, but complex tools and procedures require special software [1].

Measurements can be performed with a special digital ruler and are expressed as pixels and in millimeters or inches in digital images. The operator could measure something with the aid of the electronic ruler by drawing lines or curves with the cursor. If the measurement is going to be expressed as pixels the detector should be exposed with an object with known dimensions for the conversion of the pixels into real length [19]. It was reported that radiographic measurements of bone height around implants in images obtained from a PSP system was accurate and precise as much as conventional radiographs [29].

Computer aided cephalometric analysis is faster in data acquisition and analysis than conventional radiographic techniques. Special programs have been developed to perform computer aided cephalometric analysis directly on the screen displayed images. This could reduce the potential errors occurring from digitizing of the radiographs and the need of hardcopies. [37, 38] The reliability of landmark identification and linear and angular measurements in conventional and digital lateral cephalometry was found to be comparable with each other, but all landmarks were not accurately identified in both techniques [39]. A software developed for quantitative analysis of cervical vertebrae maturation was found to be useful [40].

**Decrease in radiographic working time:** CCD and CMOS sensors provide an important decrease in radiographic working time, especially for radiographic evaluation during endodontic treatment or surgical procedures. Reduction in radiographic working time differs among sensors and plates. Images with sensors are obtained simultaneously after the exposure on the screen, but the PSP plates require an additional scanning procedure after exposure and this increases working time. Working time differ between cable-free and cabled sensors. Cable-free sensors require less time compared with cabled sensors [20,22,41].

**Ease in archiving and electronically transmission of the images:** Images can be easily archived in digital medium and can be electronically transferred to other clinics or for consultation without any impairment in the image quality by web or CD, flash disk etc. in a very short time and little effort. In addition, other operators have the chance to enhance the image when required [1, 26].

**Elimination of film processing step and hazardous wastes:** One of the important advantages of digital systems is the elimination of a dark room, film processing equipment's and hazardous wastes such as processing chemicals, lead foil present in the film package and rare earth products in extraoral film cassettes [1,26,27].

In direct digital panoramic and cephalometric imaging the step of inserting and removing a film in cassette in a dark room is eliminated. Besides, the elimination of film processing step puts away the artifacts due to improper processing which could be a reason for retakes of radiographs both in digital intraoral and extraoral radiology [1].

**Radiation dose:** It was suggested that direct digital intraoral systems [1,26,42,43,44] and direct digital cephalometric systems require less radiation dose to obtain an image compared with conventional film in the first presentation of the systems [45,46].

The radiation dose required for CCD and CMOS sensors for a single exposure is lower compared to that of films. PSP plates require less radiation exposure than conventional film while, they require higher radiation dose compared with CCD and CMOS sensors [1].

The active imaging area of CCD and CMOS sensors are smaller than films thus, they do not show the same number of teeth or area [20]. According to a study additional retakes of images due to placement errors compared with films were higher in these sensors as they have a smaller active imaging area [47]. Therefore the number of images required for the radiographic examination of the same region increases. Due to these factors the effect in radiation dose decrease in sensor systems may be speculated [20].

The dynamic range of the sensors is lower from the PSP plates. This means that, the quality of the image decrease in systems using sensors when overexposed, however, the quality remains unchanged even at overexposure of the PSP plates. This could be an advantage for decreasing the retakes, but a disadvantage which may result in unnecessary high patient radiation dose [48].

### **Disadvantages**

**Cost:** The cost of shifting from film based systems to digital intraoral and extraoral systems is very expensive [1,26]. This leads to a decrease in the popularity of these systems especially in countries having low income rates.

**Lack in cross infection control:** Compared with films, the sensors and plates used in digital imaging are not disposable and could not be sterilized thus; special attention is required for infection control. The sensors and plates could be covered with a special film protecting cover, traditional plastic sheaths or latex finger cots. The traditional plastic sheath covering the sensor during exposure was found to leak in some cases [49] and although latex finger cot stretched

over the sensor resulted in less contamination it did not fully eliminate the risk [50]. Therefore, authors suggested the use of both a plastic sheath and a latex finger cot especially during invasive procedures [20,49,50].

Wiping the plates covered with a special plastic cover with soap or alcohol before placing in the scanner was reported as a useful method in disinfection control [21,51].

**Structures of sensors and plates:** CCD and CMOS sensors are thicker and stiff than conventional films and the patients feel more uncomfortable during the radiographic process compared with film. Besides, the cable attached to the sensor makes sensor placement in the oral cavity difficult [1,22,52].

PSP plates are similar to films in terms of dimension and thickness. Reports indicated that PSP plates were more tolerable by both adult [21] and pediatric patients than sensors [53]. Although PSP plates are similar to films some kinds of plastic envelopes used for covering the plates have sharp edges, and their corners could not be bent. This leads to difficulty during placement of the plates in the oral cavity and the patients may feel uncomfortable [20].

Physical damage could occur if the patient bites the cable of the CCD and CMOS sensors and PSP plates. In addition PSP plates are prone to damage if they are dropped to floor, bended, and scratched. Mechanical wear and trauma influences the life span of the plates and sensors. This affects the cost-effectiveness of these systems compared with conventional radiography [20].

It is not possible to distinguish images from plates that have been exposed backward in most PSP systems [1,26]. One manufacturer has developed a PSP system with a metal disk present on the hard cover which protects the plates. In the case of opposite insertion of the plate, this object becomes visible on the radiographic image.

**Ability of manipulation of the images for fraudulent purposes:** Digital technology also brings the capability of manipulation of the original image. This is an important issue for legal purposes. Manufacturers are developing systems which keep the original of the image obtained subsequently after x-ray exposure. With this security key if anyone alters the contrast, density and other characteristics of the image, it is possible to acquire the original data. Thus if one could show the source of the original data these images are considered to be reliable [19,54].

#### 2.4. Artifacts in two dimensional digital imaging

The term artifact describes any distortion or error in the image that is unrelated to the subject being studied [55]. Image artifacts decrease the rate of accurate diagnosis and treatment planning. Additionally, radiographic retakes cause unnecessary radiation dose exposure to patients, clinicians, radiology staff and the environment, as well as the loss of time and money [56]. These are going to be presented as artifacts in intraoral digital imaging and digital panoramic imaging in this section.

### 2.4.1. Artifacts in digital intraoral imaging

Although image artifacts in film-based radiography are well-known, digital radiography, like any emerging technology, produces new and different challenges. Thus, knowing the reasons of image artifacts is very important for the clinicians [57]. The artifacts of digital imaging can be categorized in three parts: **I) Operator artifacts during exposed image receptors** **II) Image processing artifacts:** and **III) Defective sensor artifacts**

#### **I) Operator artifacts during exposed image receptors**

**Cone-cut image:** It is resulted from improper alignment of the position-indicating device; partial image occurs.

**Distorted images:** These artifacts occur because bending of phosphor plates during intraoral placement [1].

**Double images:** It appears due to incomplete erasure of previous image in PSP plates.

**Underexposed images:** This could be related with i) placement of the opposite side of the PSP plate facing the x-ray tube, ii) noisy images and iii) overlapped sensor plate images.

Opposite side of the sensor plate wrongly placed facing the x ray tube: This is a significant problem for most phosphor plate systems due to backward placement of the phosphor plate in the mouth cannot be distinguished from correct placement. The images have little x-ray attenuation from the polyester base when exposed backward [1]. On the other hand, very few manufacturers had placed a metal disc back of the sensor plates to distinguish by the clinician.

The sensor plate wrongly placed in protector envelope.

Noisy images: It appears as a result of excessive exposure to ambient light between image acquisition and scanning [1].

Overlapped sensor plate images: It appears when plates are overlapped before scanning.

**II) Image processing artifacts:** This type of artifacts can be corrected thorough rescanning by another scanner without the need to retakes [57].

**a. Incorrect usage of image processing tools:** This type of artifact occurs form incorrect use of filters [1].

**b. The artifacts resulting from image scanning resolution:** Scanning under the 300 dpi causes lack of detail [1].

**c. Undefined image artifacts [57].**

The image of a horizontal white line after scanning

Brightness of images although scanning with optimal conditions and procedures

Half images after scanning

Reduction of the image size

Overlapped images after scanning of two different intraoral sensor plates in two different slots.

### III) Defective sensor artifacts [1].

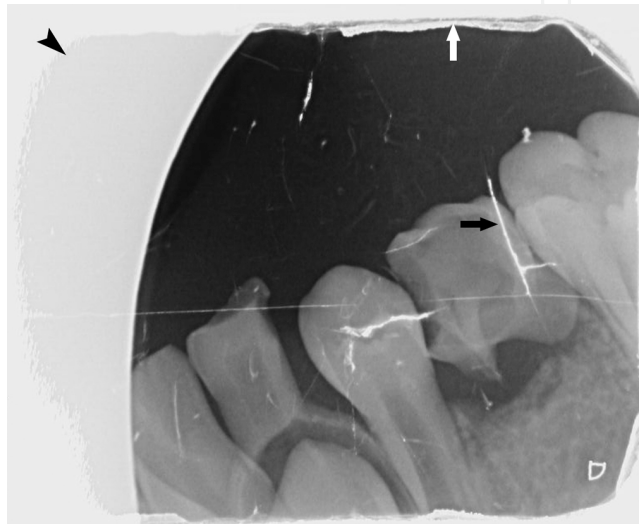
The image artifact resulting from scratching or biting mark.

The image artifact resulting from partial peeling of the coating of the intraoral sensor plate.

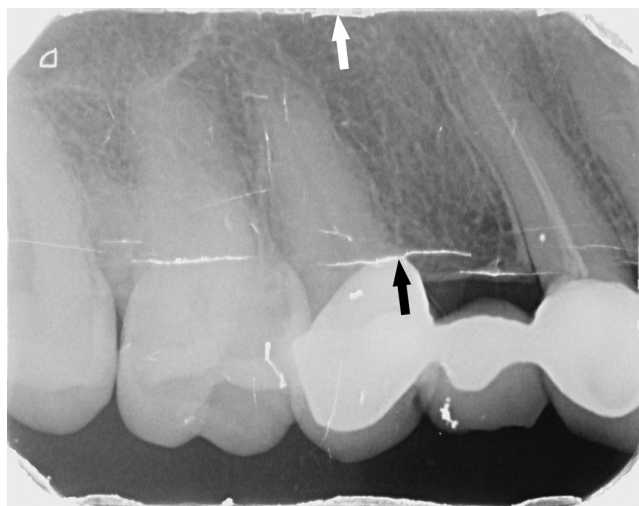The image artifact resulting from surface contamination by glove powder smudging.

Geometric image artifacts resulting from mishandling of CCD sensors.

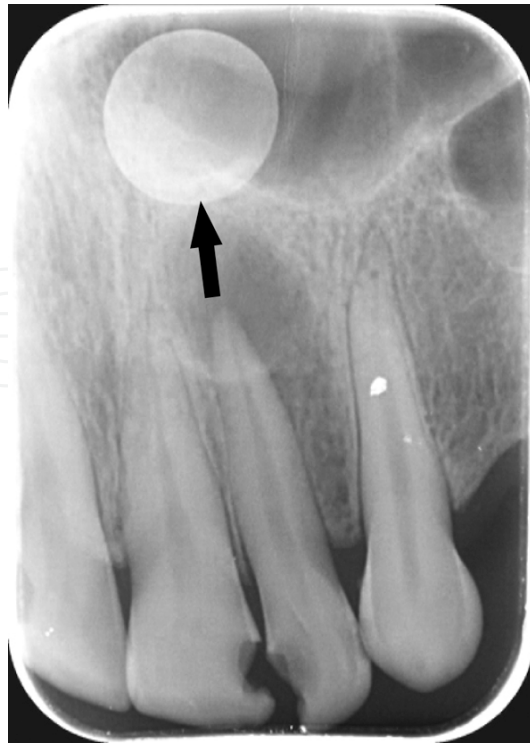Examples of intraoral image artifacts are presented in Figure 6-13.



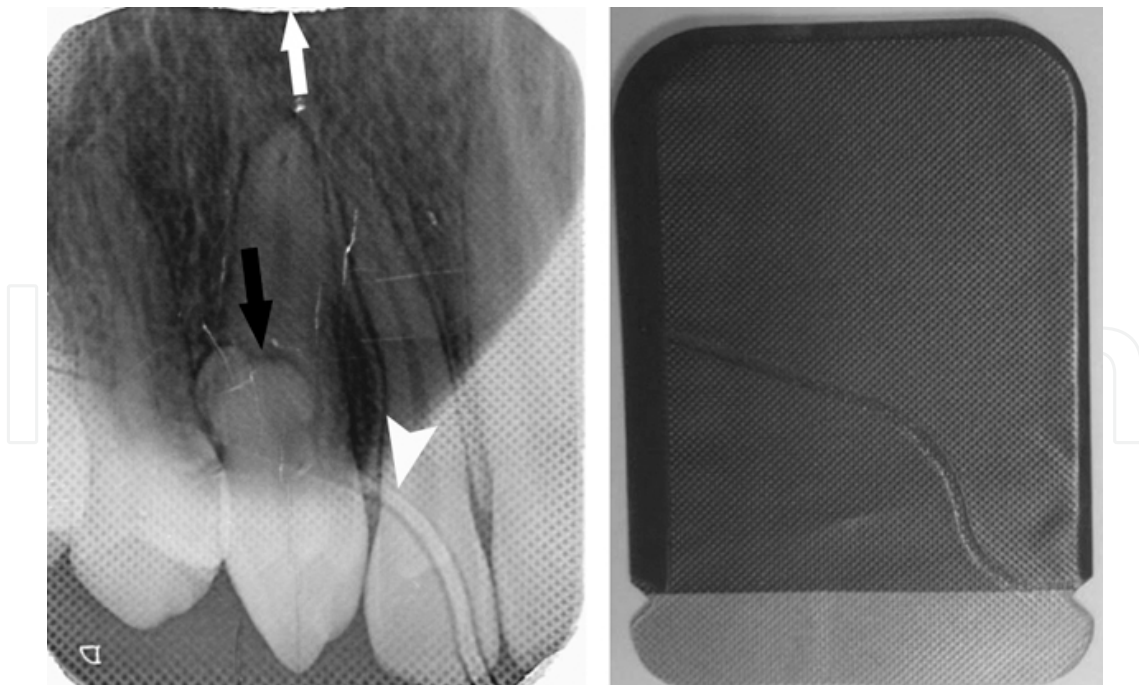
**Figure 6.** Cone-cut image (black arrowhead), the image artifact resulting from excessive bending of the plate within the mouth (black arrow) and image artifact resulting from partial peeling of the coating of the plate (white arrow).



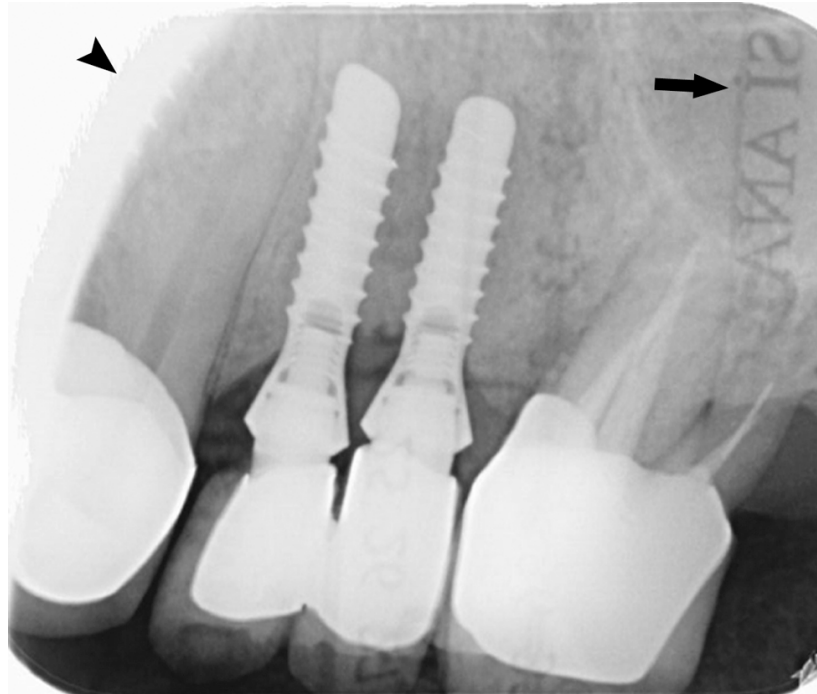
**Figure 7.** The image artifact resulting from excessive bending of the plate within the mouth (black arrow) and image artifact resulting from partial peeling of the coating of the plate (white arrow).



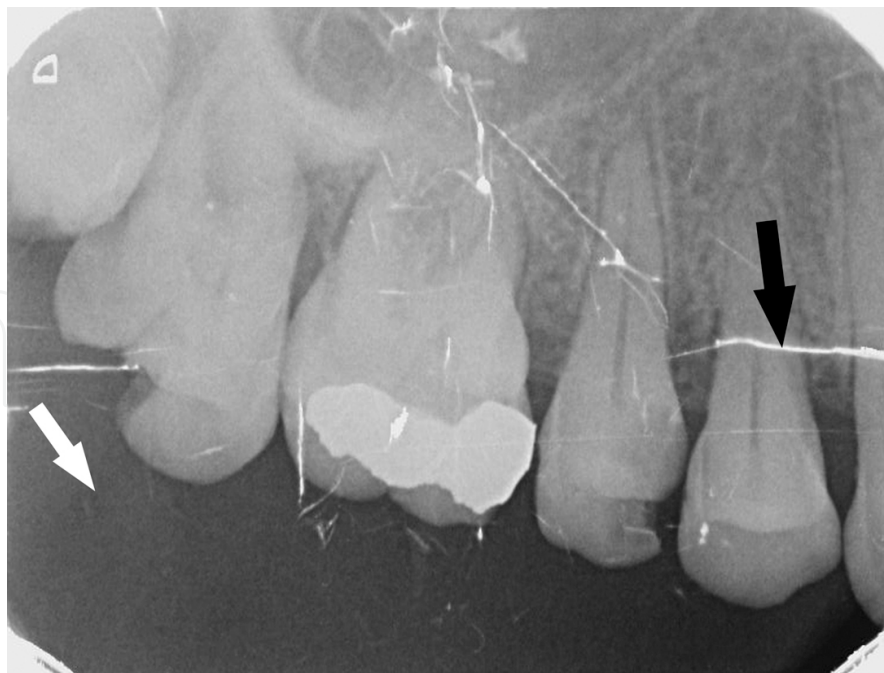**Figure 8.** The image of metal disc resulting from opposite insertion of the plate facing the x ray tube (black arrow).



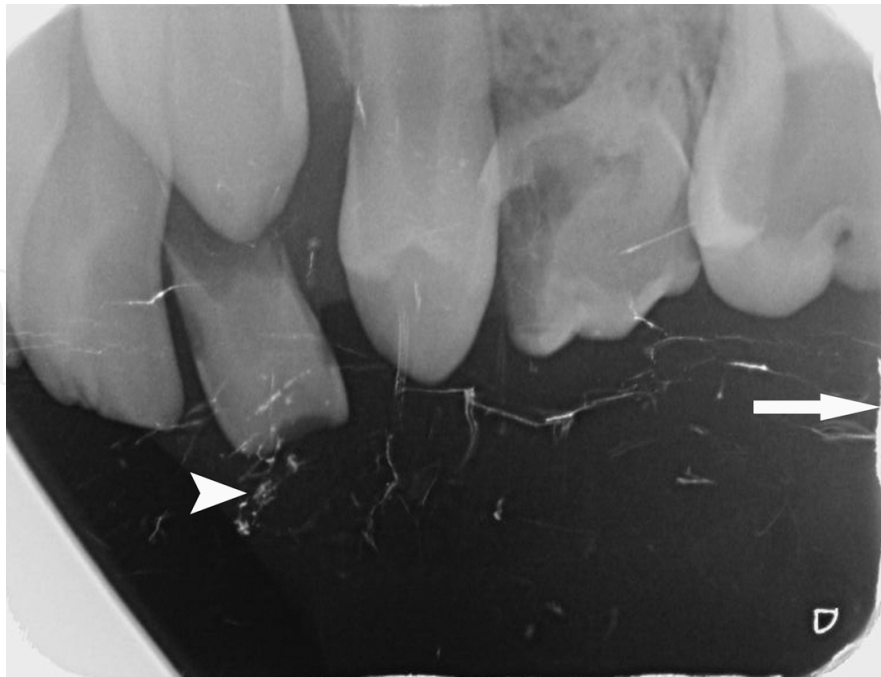**Figure 9.** The image artifact resulting from opposite insertion of the plate in protector envelope (white arrowhead) and partial peeling of the coating of the plate (white arrow). Also overlapped sensor plate image is seen. Note the odontoma in the canine region (black arrow).



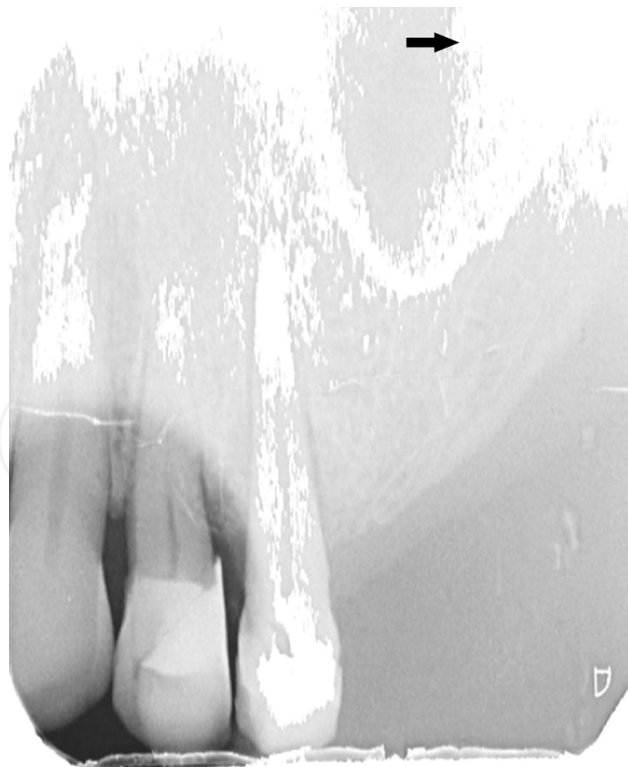**Figure 10.** The image artifact resulting from cone-cut (black arrowhead) and image of letters due to contact of plate and letters before scanning (black arrow).



**Figure 11.** The bright image artifact resulting from non-uniform image density (white arrow), the image artifact resulting from excessive bending of the plate within the mouth (black arrow).



**Figure 12.** The image artifact resulting from scratching or biting mark the image artifact resulting from excessive bending of the plate within the mouth (white arrowhead) and generalized brightness of the image



**Figure 13.** The image artifact resulting from surface contamination by glove powder smudging (black arrow) and image artifact resulting from partial peeling of the coating of the plate (white arrow).



### 2.4.2. Artifacts in digital panoramic imaging

Artifacts in digital panoramic imaging are similar to the errors occurring in conventional panoramic radiography. One of the advantages of digital panoramic imaging is that errors associated with film radiographs; such as static electricity and image processing are not present as in this technique.

Artifacts could occur due to I)technical errors, II)improper patient positioning and III)during x-ray exposure in digital panoramic imaging [58-60].

#### i. Artifacts due to technical errors

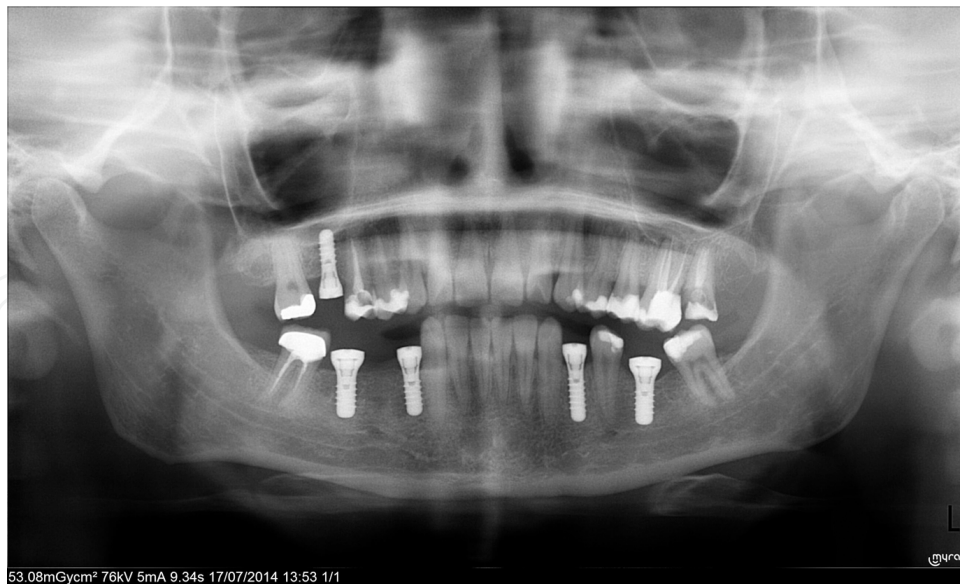1. Radiopaque artifacts (earrings, necklace, prosthesis, lead apron, spectacles, apron/thyroid shield etc.)

#### ii. Artifacts due to improper patient positioning

1. Occlusal plane rotated downwards, the condyles approaching the upper edge of the image or are cut-off by its upper edge due to chin tipped too low.
2. Occlusal plane rotated upwards, the condyles approach the lateral edges of the image or are projected off its edges symmetrically and bilaterally due to chin raised too high.
3. Overlapped or unclear appearance of the anterior teeth because of patient not biting on the bite-block
4. Narrowed or blurring anterior teeth, superimposition of the spine on the condyles or rami caused due to patients biting the bite-block too far forward.
5. Widening of anterior teeth due to the patient biting the bite-block too far back.
6. Asymmetrical placement of teeth, the condyle is enlarged and is above the contra lateral condyle, which is smaller and lower in the image due to the rotation of the head in sagittal plane.
7. Radiolucency above the maxillary teeth roots due to the patient not raising the tongue against the palate.
8. The patient's neck is stretched forward on a slant, vertebral column causing extreme lightness in the anterior region as a result of the superimposed shadow of the spine.
9. Superimposition of the hyoid bone with the body of the mandible according to the patient's Frankfurt plane not being parallel to the floor

#### iii. Artifacts occurring during x-ray interpretation

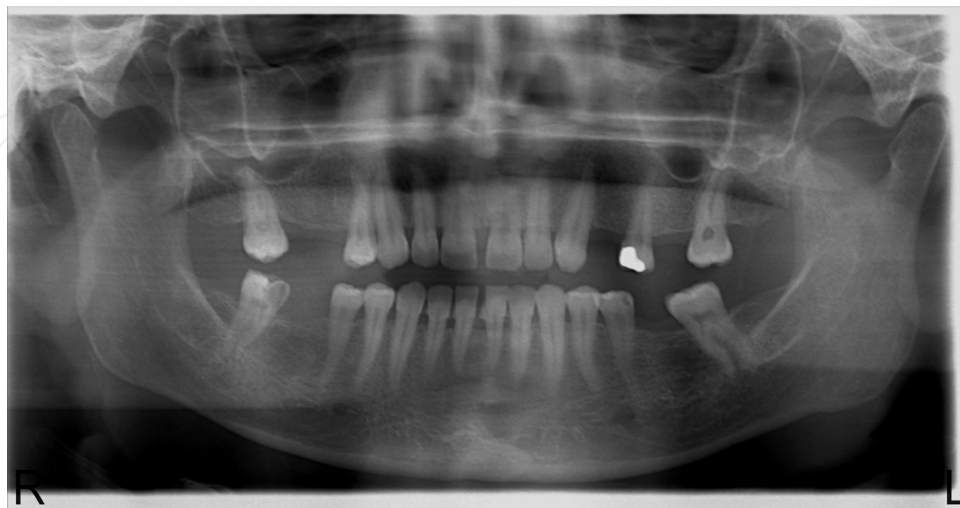1. Missing or doubled objects or abrupt shifting of image vertically due to the horizontal or vertical movement of the patient during exposure.



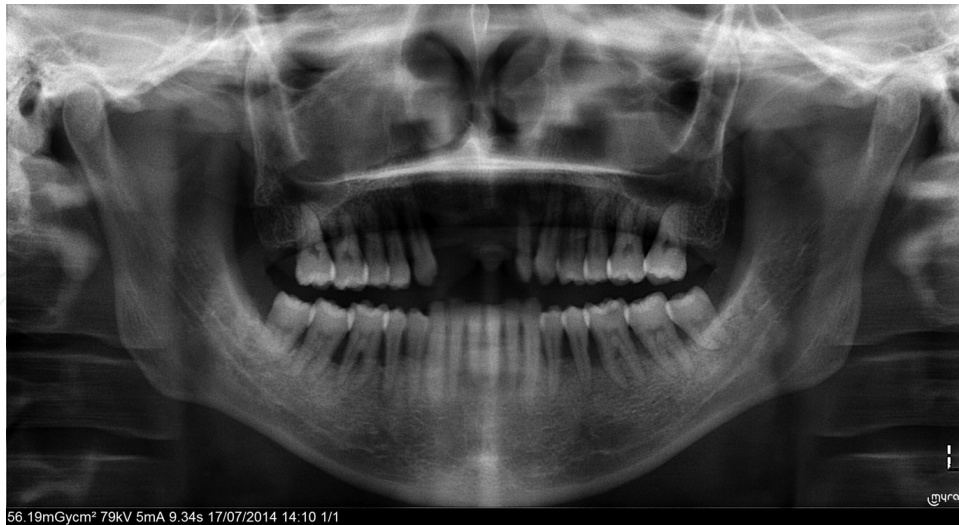**Figure 14.** Digital panoramic image demonstrating occlusal plane rotated downwards, the condyles approach the upper edge of the image superimposition of the hyoid bone with the body of the mandible according to the patient's Frankfurt plane not being parallel to the floor.

It was reported that artifacts of digital panoramic images differed between patients with mixed dentition and permanent dentition and more artifacts were seen in permanent dentition. Positioning the patient too forward was seen more common in the mixed dentition. Slumped position and improper chin position were more commonly seen in the permanent dentition. Blurred or shortened upper incisors were more prevalent in the mixed dentition [61]. Training of dental personnel and a discussion of technical measures to be taken if errors occur are essential to maximize the quality of panoramic radiographs [59].

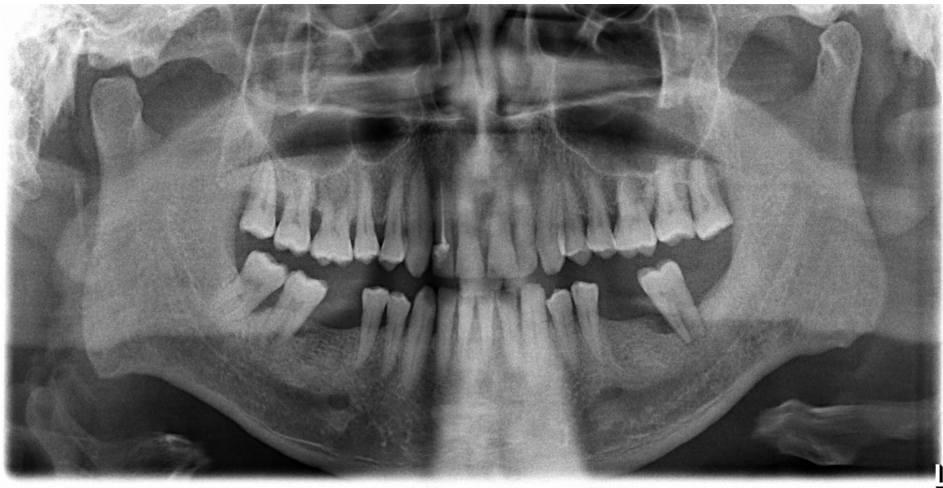Examples of digital panoramic image artifacts are presented in Figure 14-17.



**Figure 15.** Digital panoramic image demonstrating radiolucency above the maxillary teeth roots due to the patient not raising the tongue against the palate.



**Figure 16.** Digital panoramic image demonstrating narrowed anterior teeth, superimposition of the spine on the condyles or rami caused due to patients biting the bite-block too far forward and radiolucency above the maxillary teeth.



**Figure 17.** Digital panoramic image demonstrating vertebral column causing extreme lightness in the anterior region as a result of the superimposed shadow of the spine and noisy image.

### 3. Three dimensional digital imaging in dentistry

Three dimensional imaging gives the opportunity to the practitioner to examine the dento-maxillofacial region without superimposition and distortion of the image. Three dimensional imaging was acquired with conventional tomography [62] and tuned aperture computed tomography techniques in the past years [63] but, with the introduction of cone-beam computed tomography (CBCT) it left its place to this new imaging modality. Details about CBCT technique and its clinical applications are going to be discussed in this section.

### 3.1. Cone-beam computed tomography

CBCT is a relatively new digital imaging technology. Although, it has been given several names including dental volumetric tomography (DVT), cone beam volumetric tomography (CBVT), dental computed tomography (DCT) and cone beam imaging (CBI), the most preferred name is cone-beam computed tomography (CBCT) [55].

This technique was initially developed for angiography in 1982 and was applied to dental imaging some after. It has the advance of three dimensional imaging of the area of interest without superimposition of other structures. Multiplanar and 3D images could be achieved with this technique with lower radiation dose and higher spatial resolution relative to computed tomography (CT) providing better visualization of structures with mineralized tissue. Although CBCT images have high spatial resolution, the data from which images are created contains considerable noise caused by scattered radiation. Thus, soft tissue contrast in CBCT images is inferior to that in CT images [64]. Another problem which can affect the image quality and diagnostic accuracy of the images is the scatter and beam hardening caused by high density neighboring structures, such as enamel, metal posts and restorations [65].

The CBCT system works with a flat panel detector and special scanner using collimated x-ray source that produces a cone-or pyramid-shaped beam of x-radiation making a single full or partial circular rotation around the head of the patient. A sequence of discrete planar projection images using a digital detector is produced after exposure. Subsequently, these two-dimensional images are reconstructed into a three-dimensional volume [55,66].

Examples of multiplanar and three dimensional CBCT images are presented in Figure 19-22.

Patient positioning differs among CBCT devices (Figure 18). An image could be achieved with the patient seated, standing or supine position. CBCT is not a complex device to use and three dimensional image reconstruction can be made easily with appropriate software [55,67].

Compared with two dimensional imaging, the effective radiation dose can be higher in CBCT depending on the machine, field of view, and the resolution of the image [3,68]. The effective doses for various devices range from 52 to 1025 microsieverts [55]. This is an important issue because all imaging modalities using x-rays for the acquisition of radiographic images rely on a basic principle; '*As Low As Reasonably Possible (ALARA)*'. This principle maintains the protection of patients and staff during the acquisition of images. Therefore, the selection criteria of the CBCT examination should weigh potential patient benefits against the risks associated with the level of radiation dose. This could be achieved by appropriate clinical usage and optimizing technical factors such as; using the smallest field of view necessary for diagnostic purposes, and using appropriate personal and patient protective shielding [66,69].

Although dental exposure only contributes a few percent to the populations' total medical exposure, it is curial to adopt certain measures to avoid unnecessary repeated examinations, especially with the advent of CBCT in dentistry [70].

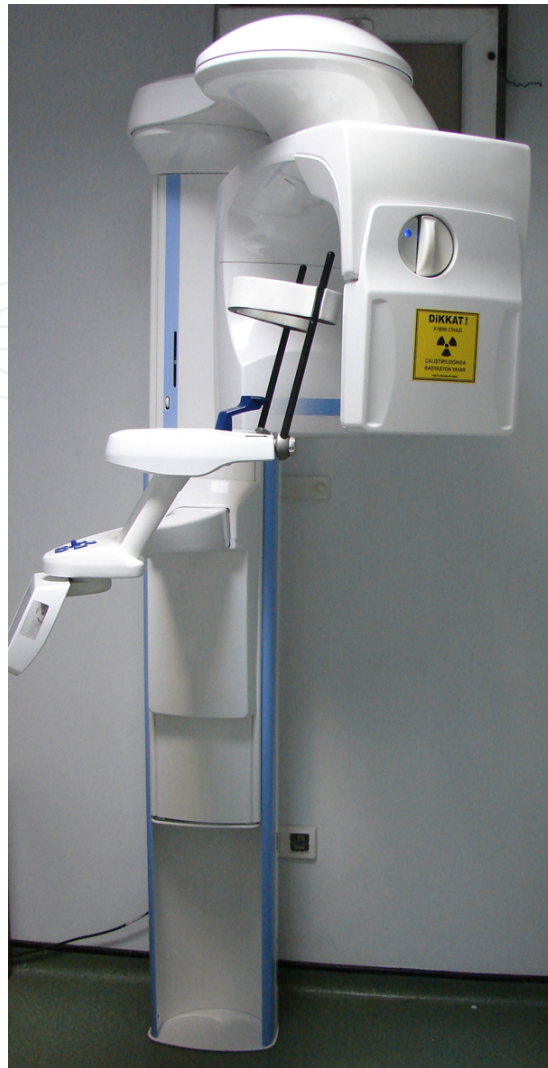

Figure 18. A CBCT unit

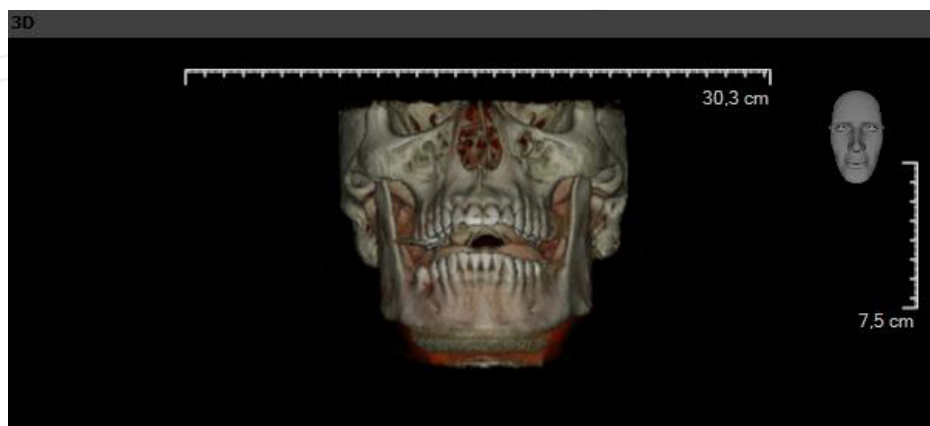


Figure 19. An example of a three dimensional CBCT image

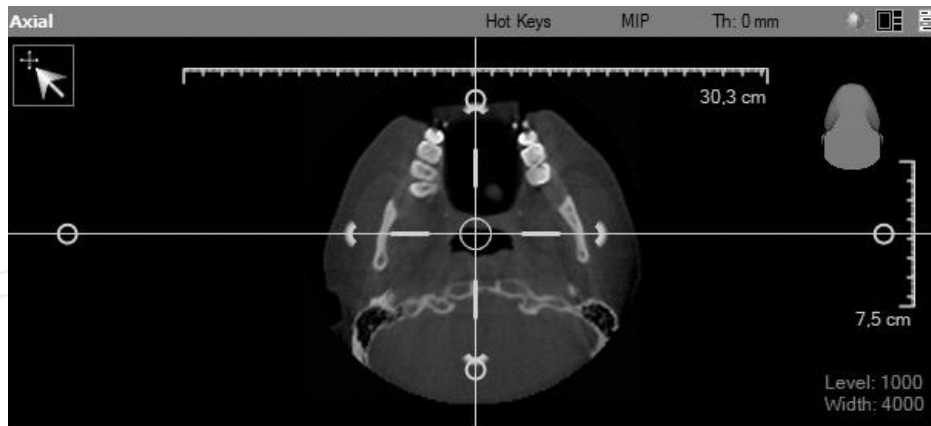


Figure 20. An example of an axial slice of CBCT image

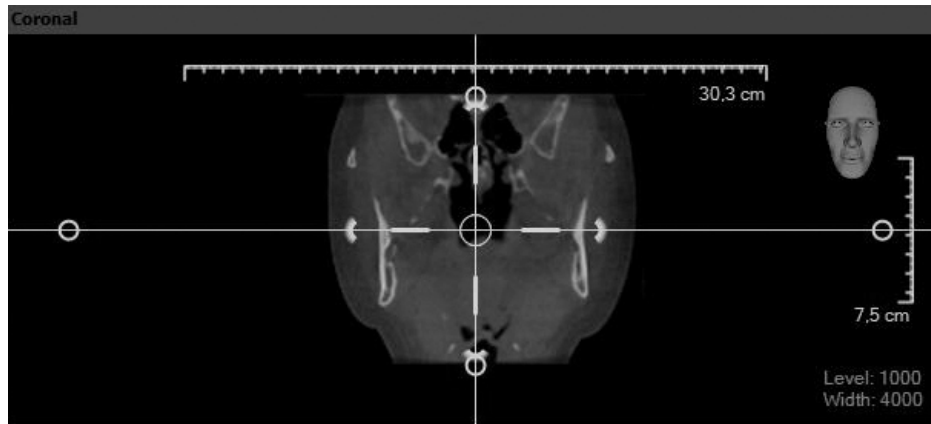


Figure 21. An example of a coronal slice of CBCT image

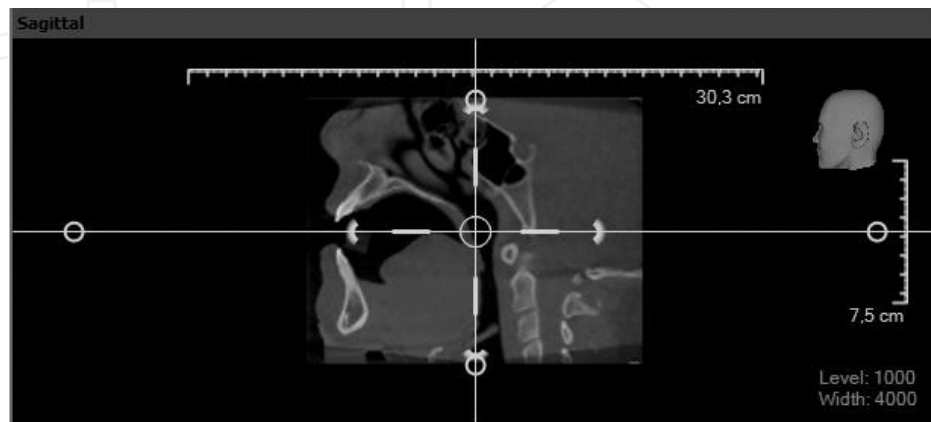


Figure 22. An example of a sagittal slice of CBCT image

### 3.2. Applications of CBCT in Dentistry

CBCT is used in all areas of dentistry including oral and maxillofacial surgery, orthodontics, pediatric dentistry, periodontology and endodontics. It has been recommended that the use of CBCT could benefit the diagnosis and treatment outcomes for specific cases [55,71].

#### 3.2.1. Oral and maxillofacial surgery

Radiographic methods for the assessment of bone quantity and quality are traditionally used in preoperative planning of dental implant placement. The American Academy of Oral and Maxillofacial Radiology (AAOMR) recommended the evaluation of a potential implant site should include cross-sectional imaging, orthogonal to the site of interest [72]. CBCT is one of the techniques which could be used for cross sectional imaging orthogonal to the site of interest. It is a popular method of planning dental implant placement [73]. It provides the visualization of the alveolar bone height, width and buccolingual dimensions and spatial localization of the neighboring anatomic structures, such as inferior alveolar canal, incisive canal and maxillary sinus. Accurate measurements could be performed directly, as the images are free from distortion however; errors in patient positioning can lead to alterations in these distances. It was concluded that improper patient positioning led to imprecise measurements of bone height and width, which may cause damage to anatomical structures [74].

In addition to implant site assessment, CBCT is used in the pre-surgical evaluation of impacted teeth, supernumerary teeth, and relationship of the inferior alveolar canal to the roots of mandibular third molars, lesions localized on the jaws, osteomyelitis, and osteonecrosis etc. This will benefit to the maxillofacial surgeon to visualize the accurate location of the pathology and its relationship with adjacent structures and important anatomical landmarks [55,75].

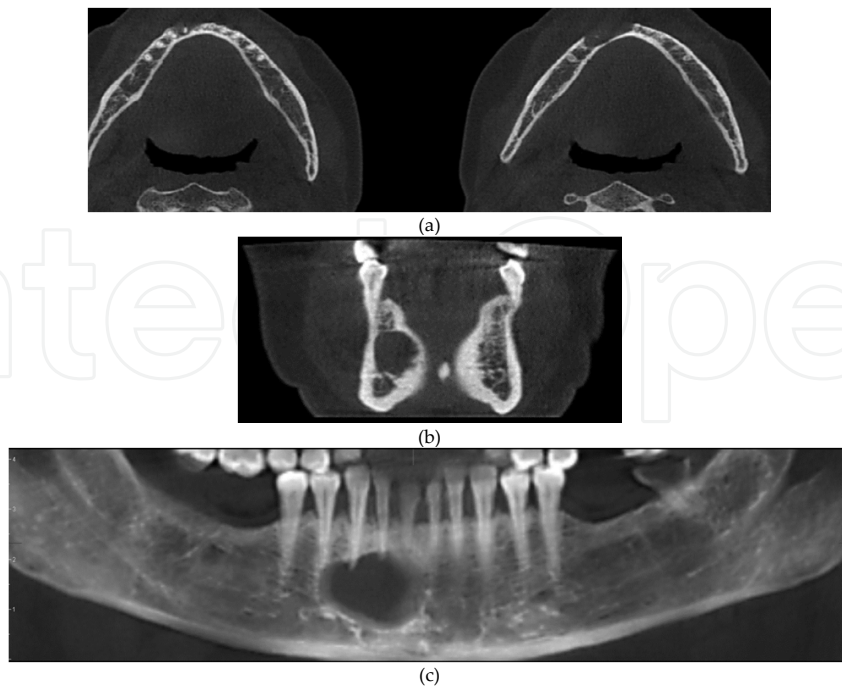
Maxillofacial fractures could be also diagnosed with CBCT, but the limits and thus an indication for medical computed tomography exist where there is extensive fractures with suspicion of craniocerebral trauma [76].

Degenerative pathologies or abnormalities in the bony structures of temporomandibular joint, such as cortical erosion, condylar sclerosis and/or articular eminence, articular surface flattening, presence of osteophytes and ankylosis can also be visualized with CBCT [55].

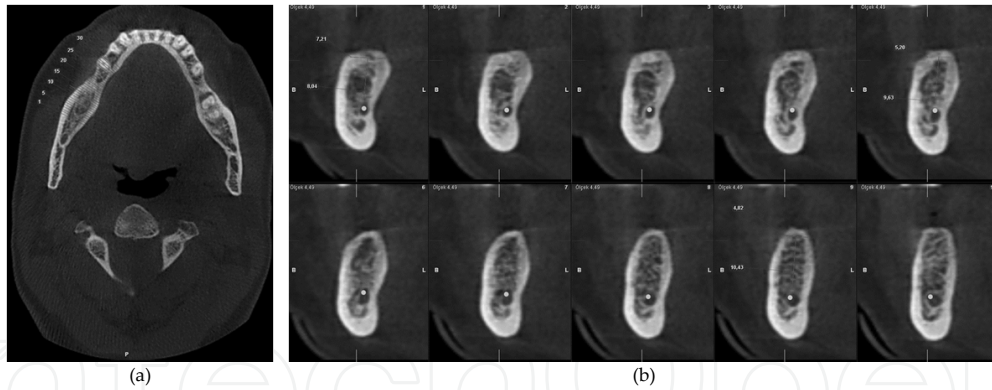
Examples of CBCT images acquired for a radiolucent lesion (Figure 23), preoperative implant planning (Figure 24), TMJ (Figure 25) and a fracture in the mandible (Figure 26).

#### 3.2.2. Orthodontics and pediatric dentistry

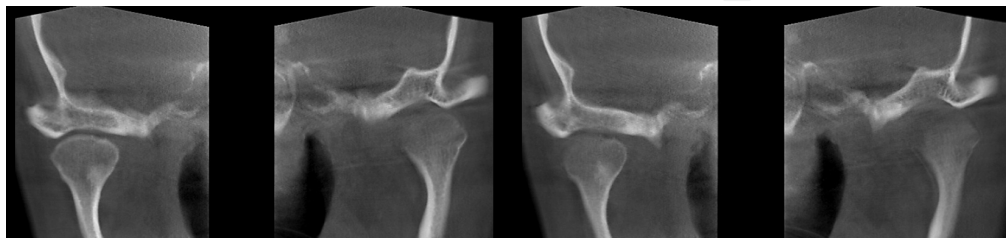
Radiographic assessment has always been an important aspect in orthodontics for diagnosis and treatment planning. Two dimensional radiographic techniques have been used for a long time but it has some well documented limitations such as magnification, geometric distortion, superimposition of structures, projective displacements (which may elongate or foreshorten an object's dimensions), rotational errors and linear projective transformation [77,78]. However, CBCT allows for evaluation and analysis of the area of interest without any distortion, magnification and superimposition of other structures.



**Figure 23.** The axial (a), coronal (b) and panoramic (c) CBCT images of a radiolucent lesion seen in the anterior region of the mandible.

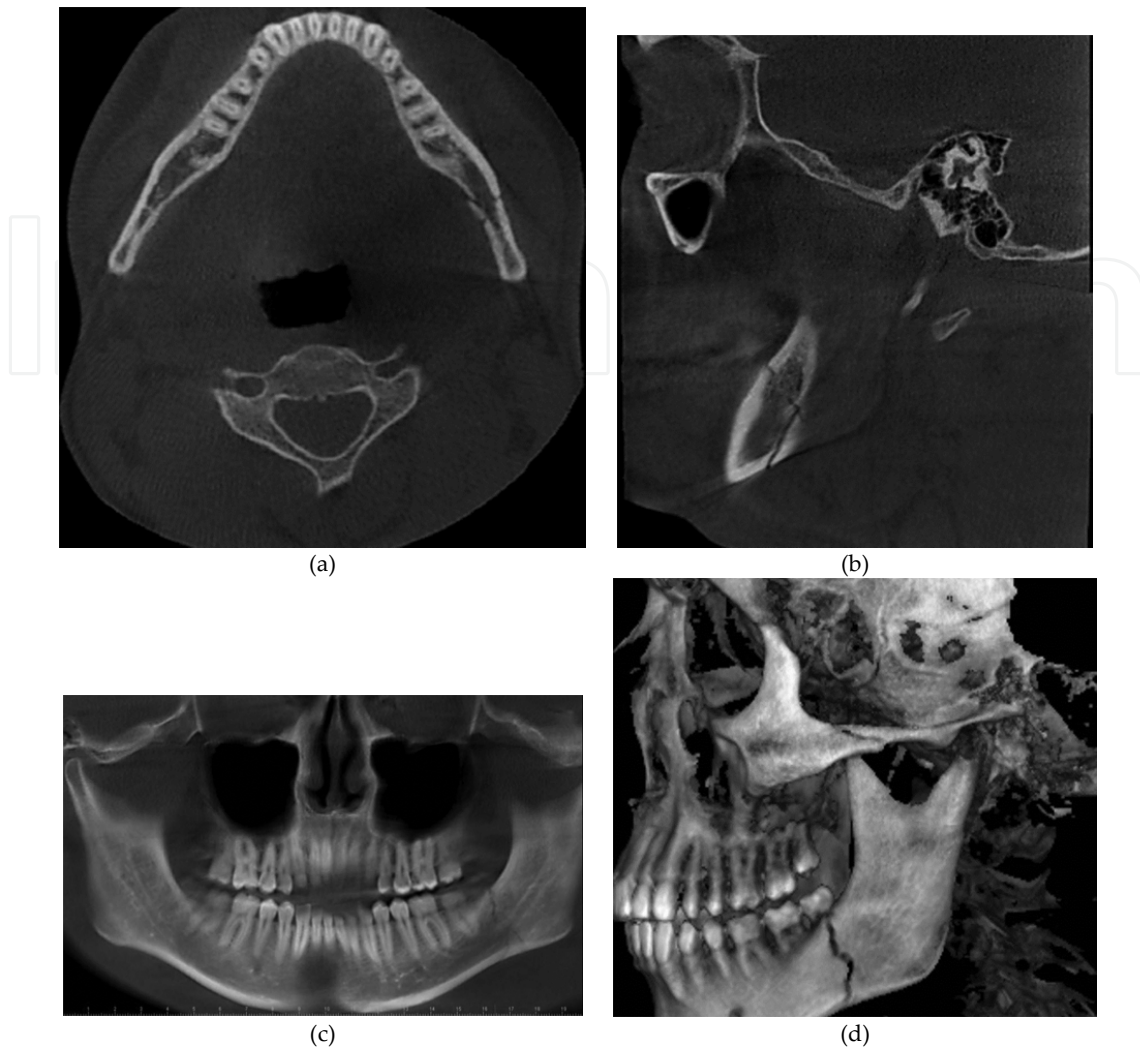


**Figure 24.** The axial (a) and cross sectional (b) images of a CBCT scan for preoperative implant planning.



**Figure 25.** The coronal CBCT images of the TMJ.





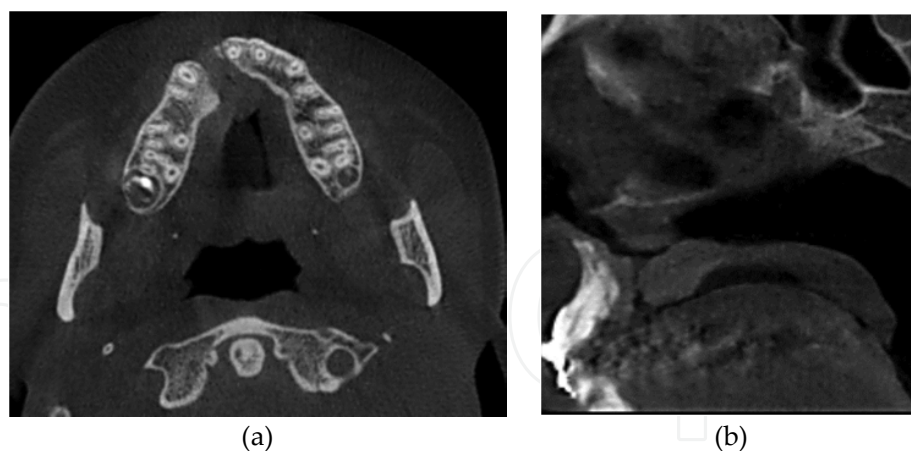
**Figure 26.** The axial (a), sagittal (b), panoramic (c) and 3D CBCT image (d) of a fracture in the left third molar region in mandible.

It has been suggested that information obtained from a CBCT scan has the potential to improve orthodontic diagnosis and treatment planning in airway analysis before and after orthognathic surgical planning, [79] cleft lip palate [80,81] root position and structure [82] and mini screw placement [83,84].

A study evaluated the impact of CBCT on orthodontic diagnosis and treatment planning and reported the most frequently diagnosis and treatment plan changes occurred in cases of unerupted teeth, severe root resorption, or severe skeletal discrepancies. Contrary, they found no benefit for abnormalities of the temporomandibular joint, airway, or crowding [85].

During the past decade, CBCT imaging has been a popular method in orthodontics, but the disability of showing 'minor external root resorption or not providing treatment at a microscopic level' still are disadvantages [86].

An example of CBCT image acquired for cleft palate is presented in Figure 27.



**Figure 27.** The axial (a) and sagittal (b) CBCT images of a cleft palate.

The use of CBCT in pediatric dentistry has been mentioned in the dental literature. A research from Korea demonstrated the most prevalent usage of CBCT among children and adolescents were for diagnosis and monitoring of the growth of cysts and other tumors, following by localization of impacted teeth, and supernumerary teeth [87].

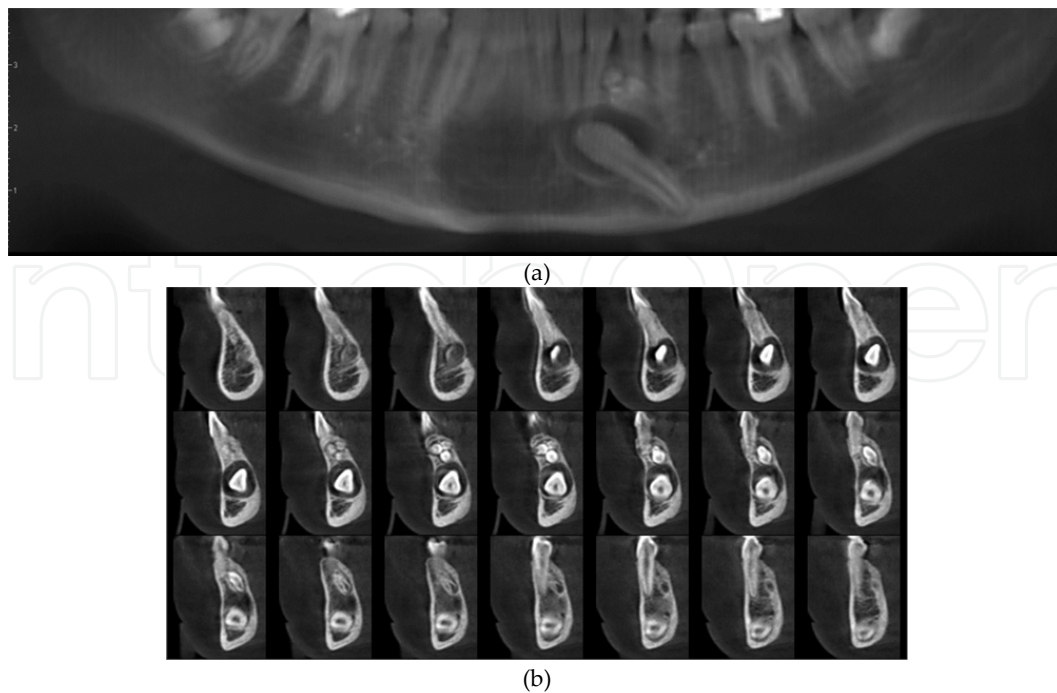
Children are more suspicious to dental trauma on anterior teeth than adults. Thus, teeth fracture is a common sequel. From a database search it was concluded that CBCT was useful in cases in which conventional radiographic techniques yield inconclusive results or showed a fracture in the middle third of a root. CBCT may rule out or confirm an oblique course of fracture involving the cervical third in the labiolingual dimension. Although there are considerable advantages of CBCT in the diagnosis of fractures, more experimental and clinical studies are warranted to determine the exact impact on outcomes [88].

CBCT generates a higher effective radiation dose to the tissues than conventional radiographic techniques. The effective radiation dose should not be underestimated, especially in children, who are much more susceptible to stochastic biological effects [89].

Similar CBCT exposure settings are predicted to result in higher equivalent doses to the head and neck organs in children than in adults. Some CBCT scanners present in the dental market provide a pediatric option to the user. A study evaluated the equivalent radiation doses of two CBCT machines; one with a pediatric preset option and the other with an adult setting. They demonstrated significantly higher equivalent radiation dose when the child phantom was scanned with adult settings. When the pediatric preset was used for the scans, there was a decrease in the ratio of equivalent dose to the child mandible and thyroid. Thus, the practitioner must put pressure on the machine settings during scanning pediatric patients. If not, this will result in excessive radiation to children [90].

*A CBCT scan must be only used in cases when the radiographic data is going to change the treatment modality and treatment outcome in orthodontics and pediatric dentistry!*

An example of CBCT image acquired from a child having an impacted permanent canine and an odontoma is presented in Figure 28.



**Figure 28.** The panoramic (a) and cross sectional (b) CBCT image of a child having an impacted permanent canine and an odontoma.

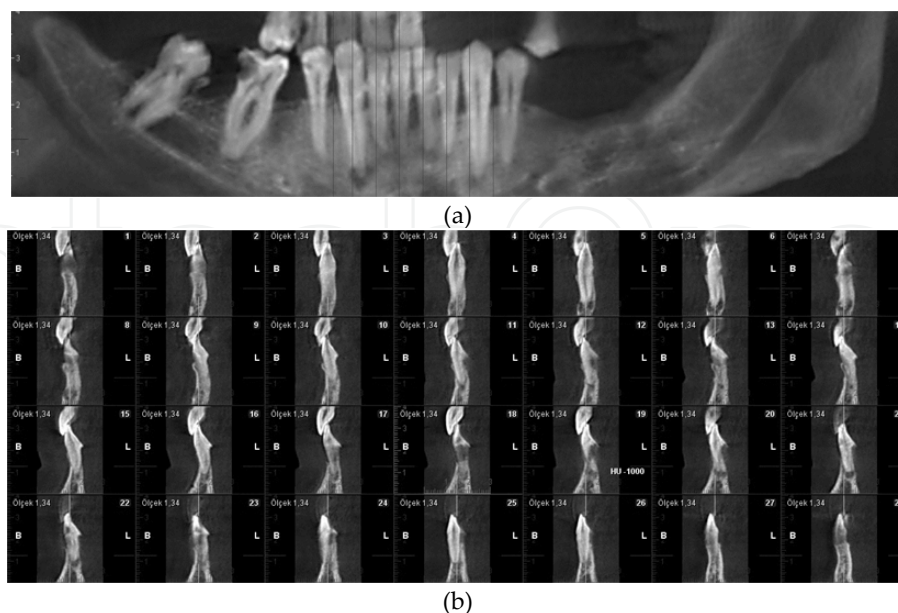
### 3.2.3. Periodontology

Diagnosis of periodontal pathologies; such as, gingival hyperplasia, gingival recession and bleeding, depends on clinical signs and symptoms. However, radiographic imaging is essential in the diagnosis of pathologies related with alveolar bone. Two dimensional imaging techniques are routinely used for the assessment of alveolar bone defects in periodontology, but diagnosis of bone craters and alveolar bone support is limited by projection geometry and superimpositions of adjacent anatomical structures. CBCT has the capability of imaging these areas without the limitations of two dimensional imaging techniques [91,92].

Studies have evaluated the role of CBCT in periodontal diagnosis. In vitro studies reported the usefulness of CBCT in the imaging of periodontal defects [93-95]. A study explored the diagnostic values of digital intraoral radiography and CBCT in the determination of periodontal bone loss, infrabony craters and furcation involvements. The authors reported that the detection of crater and furcation involvements failed in 29% and 44% for the CCD, respectively. On the other hand all defects were visualized with CBCT. Besides, the panoramic reconstruction and cross sectional images of CBCT allowed comparable measurements of periodontal bone levels and defects as with intraoral radiography [96]. In a clinical study it was reported that CBCT may provide detailed radiographic information in furcation involvements present in patients with chronic periodontitis and so may have an effect on treatment planning decisions [97].

*Although CBCT provide benefits in periodontal diagnosis, it should be used only in cases having the necessity of three dimensional imaging! [91]*

An example of CBCT image acquired for periodontal pathology is presented in Figure 29.



**Figure 29.** The panoramic (a) and cross sectional (b) CBCT image showing periodontal alveolar bone loss. Note the apical lesion and also external root resorption in the incisor.

### 3.2.4. Endodontics

Radiographic imaging has an important role in the diagnosis of periapical lesions and treatment procedure. Radiographic data not only helps the diagnosis of the pathology but also gives us the possibility to assess the anatomy of the tooth, such as the root number and curvature, pulp horns, coronal and radicular pulp tissue, root apex, lamina dura and periradicular alveolar bone. Until recently, the assessment of these structures relied on two dimensional radiographs. However, such images have inherent limitations in endodontics [98,99].

Endodontic applications of CBCT include the diagnosis of periapical lesions due to pulpal inflammation, identification and localization of internal and external resorption, detection of vertical root fractures, visualization of accessory canals, elucidation of causes of non-healing endodontically treated teeth, [99] and pre-surgical assessment of apical lesions for the planning of endodontic surgery [100,101].

A study evaluated the sensitivity and specificity of CBCT and digital periapical radiography in the detection of mesial root perforations of mandibular molars and demonstrated that CBCT could be used for detection of perforation *before* obturating root canals. Contrary, periapical radiography (with three different horizontal angulations) would be trustworthy in filled root canals [102].

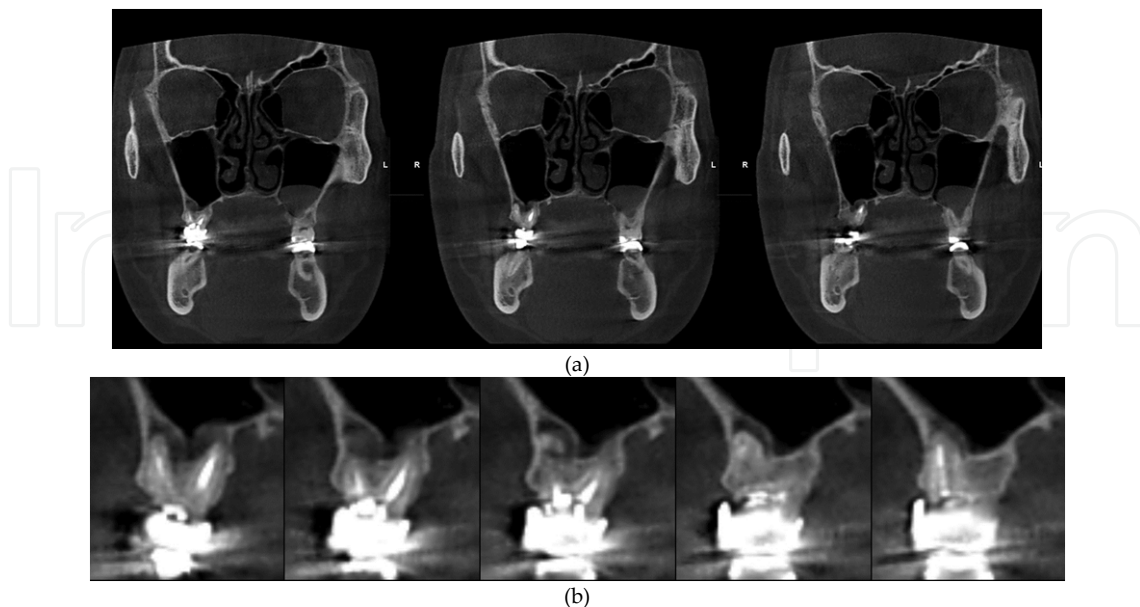
A study compared the accuracy of CBCT scans and periapical radiographs in diagnosis of vertical root fractures and the influence of root canal filling on this issue. The results showed that the specificity of CBCT was reduced by the presence of root canal filling but its overall accuracy was not influenced. Both the sensitivity and overall accuracy of periapical radio-

graphs were reduced by the presence of root canal filling but still CBCT showed a higher accuracy than periapical radiographs for detecting vertical root fracture [103].

CBCT is also useful for the diagnosis of the origin of pain in the maxillary posterior region. Maxillary premolar and molar teeth show a close relationship with sinus maxillaries. This may cause the periradicular infection to spread and erode the cortical border of sinus maxillaries and cause an infection in the sinus. Similarly, an infection occurring in the periradicular region of teeth having root apices localized directly in the sinus lead to sinus infection also. In such cases the patient has both a tooth infection and sinus maxillaries infection and a correct diagnosis is essential for successful treatment. One other situation is that in some cases sinus infection leads to the posterior teeth give false positive signs and symptoms of periapical infection. It was reported that compared with periapical radiographs CBCT revealed a higher number of correct diagnosis of periapical pathology. This technique also allowed appreciate evaluation of expansion of the lesions into the maxillary sinuses, thickening of the sinus mucosa, missed canals and apicomarginal communications [104].

CBCT has become an important imaging modality for diagnosis and treatment planning in endodontics. However, the higher effective dose of ionizing radiation compared to two dimensional imaging modalities limits the routine usage of this technique. Concerning the utility of CBCT in treatment planning decisions, the gain of radiographic information with this technique has to be evaluated carefully on an individual basis. Moreover, radioopaque materials such as root canal filling and posts often create artifacts, which may compromise diagnosis [105].

An example of CBCT image acquired for periapical pathology is presented in Figure 30.



**Figure 30.** The coronal (a) and cross sectional (b) CBCT images of a periapical lesion present in the maxillary first molar.

## 4. Conclusion

Tremendous advances have been made for improvements of digital imaging systems since their initial introduction on the market and it seems that their adaptation will be increasing in the future. Dentists should have knowledge of the working principles, requirements, clinical benefits and hazardous effects of these systems for proper usage.

## Author details

Zühre Zafersoy Akarslan and Ilkay Peker

\*Address all correspondence to: dtzuhre@yahoo.com

Gazi University Faculty of Dentistry, Department of Dentomaxillofacial Radiology Ankara, Turkey

## References

- [1] Ludlow JB, Mol A. Digital Imaging In: White SC, Pharoah MJ. 6<sup>th</sup> ed Oral Radiology. Principles and Interpretation. St. Louis Mosby/Elsevier; 2009. p78-99.
- [2] Farman AG, Farman TT. A Comparison of 18 Different X-Ray Detectors Currently Used in Dentistry. Oral Surgery Oral Medicine Oral Pathology Oral Radiology Endodontics 2005;99(4):485-489.
- [3] Eshraghi T, McAllister N, McAllister B. Clinical Applications of Digital 2-D and 3-D Radiography for the Periodontist. Journal of Evidence Based Dental Practice 2012;12(3):36-45.
- [4] Erten H, Akarslan ZZ, Topuz Ö. The Efficiency of Three Different Films and Radiosialography in Detecting Approximal Carious Lesion. Quintessence International 2005;36 (1):65-70.
- [5] Castro VM, Katz JO, Hardman PK, Glaros AG, Spencer P. In Vitro Comparison of Conventional Film and Direct Digital Imaging in the Detection of Approximal Caries. Dentomaxillofacial Radiology 2007;36(3):138-42.
- [6] Bottenberg P, Jacquet W, Stachniss V, Wellnitz J, Schulte AG. Detection of Cavitated or Non-Cavitated Approximal Enamel Caries Lesions Using CMOS and CCD Digital X-Ray Sensors and Conventional D and F-Speed Films at Different Exposure Conditions. American Journal of Dentistry 2011;24(2):74-78.
- [7] Jorgenson T, Masood F, Beckerley JM, Burgin C, Parker DE. Comparison of Two Imaging Modalities: F-Speed Film and Digital Images for Detection of Osseous De-

- fects in Patients with Interdental Vertical Bone Defects. *Dentomaxillofacial Radiology* 2007;36(8):500-505.
- [8] de Molon RS, Morais-Camillo JA, Sakakura CE, Ferreira MG, Loffredo LC, Scaf G. Measurements of Simulated Periodontal Bone Defects in Inverted Digital Image and Film-Based Radiograph: An In Vitro Study. *Imaging Sciences in Dentistry* 2012;42(4):243-247.
- [9] Vandenberghe B, Corpas L, Bosmans H, Yang J, Jacobs R. A Comprehensive in Vitro Study of Image Accuracy and Quality for Periodontal Diagnosis. Part 1: The Influence of X-Ray Generator on Periodontal Measurements Using Conventional and Digital Receptors. *Clinical Oral Investigation* 2011;15(4):537-549.
- [10] Paurazas SB, Geist JR, Pink FE, Hoen MM, Steiman HR. Comparison of Diagnostic Accuracy of Digital Imaging by Using CCD and CMOS-APS Sensors With E-Speed Film in The Detection of Periapical Bony Lesions. *Oral Surgery Oral Medicine Oral Pathology Oral Radiology Endodontics* 2000;89(3):356-362.
- [11] Wallace JA, Nair MK, Colaco MF, Kapa SF. A Comparative Evaluation of the Diagnostic Efficacy of Film and Digital Sensors for Detection of Simulated Periapical Lesions. *Oral Surgery Oral Medicine Oral Pathology Oral Radiology Endodontics* 2001;92(1):93-97.
- [12] Shintaku WH, Venturin JS, Noujeim M, Dove SB. Comparison between Intraoral Indirect and Conventional Film-Based Imaging for the Detection of Dental Root Fractures: An Ex Vivo Study. *Dental Traumatology* 2013;29(6):445-449.
- [13] Kamburoğlu K, Tsesis I, Kfir A, Kaffe I. Diagnosis of Artificially Induced External Root Resorption Using Conventional Intraoral Film Radiography, CCD, and PSP: An Ex Vivo Study. *Oral Surgery Oral Medicine Oral Pathology Oral Radiology Endodontics* 2008;106(6):885-891.
- [14] Kamburoğlu K, Barenboim SF, Kaffe I. Comparison of Conventional Film with Different Digital and Digitally Filtered Images in the Detection of Simulated Internal Resorption Cavities--An Ex Vivo Study in Human Cadaver Jaws. *Oral Surgery Oral Medicine Oral Pathology Oral Radiology Endodontics* 2008;105(6):790-797.
- [15] White SC, Pharoah MJ. *Oral Radiology. Principles and Interpretation*. 6<sup>th</sup> Ed St. Louis Mosby/Elsevier; 2009.
- [16] Wakoh M, Kuroyanagi K. Digital Imaging Modalities for Dental Practice. *The Bulletin of Tokyo Dental College* 2001;42(1):1-14.
- [17] Pai SS, Zimmerman JL. Digital Radiographic Imaging in Dental Practice. *Dentistry Today* 2002;21(6):56-61.
- [18] Molteni R. Effect of Visible Light on Photo-Stimulated-Phosphor Imaging Plates. *International Congress Series* 1256 (2003) 1199– 1205.

- [19] Van Der Stelt PF. Filmless Imaging: The Uses of Digital Radiography in Dental Practice. *Journal of American Dental Association* 2005;136(10):1379-1387.
- [20] Wenzel A, Møystad A. Work Flow with Digital Intraoral Radiography: A Systematic Review. *Acta Odontologica Scandinavica* 2010;68(2):106-114.
- [21] Wenzel A, Frandsen E, Hintze H. Patient Discomfort and Cross-Infection Control in Bitewing Examination with a Storage Phosphor Plate and a CCD-Based Sensor. *Journal of Dentistry* 1999;27(3):243-246.
- [22] Tsuchida R, Araki K, Endo A, Funahashi I, Okano T. Physical Properties and Ease of Operation of a Wireless Intraoral X-Ray Sensor. *Oral Surgery Oral Medicine Oral Pathology Oral Radiology Endodontics*. 2005;100(5):603-608.
- [23] Farman AG, Farman TT. Extraoral and Panoramic Systems. *Dental Clinics of North America* 2000;44(2):257-272.
- [24] Molander B, Gröndahl HG, Ekestubbe A. Quality of Film-Based and Digital Panoramic Radiography. *Dentomaxillofacial Radiology* 2004;33(1):32-36.
- [25] Alan G L. Panoramic Imaging. In: White SC, Pharoah MJ. *Oral Radiology. Principles and Interpretation*. 6<sup>th</sup> Ed St. Louis Mosby/Elsevier; 2009.
- [26] Brennan J. An Introduction to Digital Radiography in Dentistry. *Journal of Orthodontics* 2002;29(1):66-69.
- [27] Wenzel A. Computer-Aided Image Manipulation of Intraoral Radiographs to Enhance Diagnosis in Dental Practice: A Review. *International Dental Journal* 1993;43(2):99-108.
- [28] Van Der Stelt PF. Better Imaging: The Advantages of Digital Radiography. *Journal of American Dental Association* 2008;139 Suppl:7S-13S.
- [29] Borg E. Some Characteristics of Solid-State and Photo-Stimulable Phosphor Detectors for Intra-Oral Radiography. *Swedish Dental Journal Suppl*. 1999;139:i-viii, 1-67.
- [30] Nair MK, Ludlow JB, May KN, Nair UP, Johnson MP, Close JM. Diagnostic Accuracy of Intraoral Film and Direct Digital Images for Detection of Simulated Recurrent Decay. *Operative Dentistry* 2001;26(3):223-230.
- [31] Akarslan ZZ, Akdevelioğlu M, Güngör K, Erten H. A Comparison of the Diagnostic Accuracy of Bitewing, Periapical, Unfiltered and Filtered Digital Panoramic Images for Approximal Caries Detection in Posterior Teeth. *Dentomaxillofacial Radiology* 2008;37(8):458-463.
- [32] Belém MD, Ambrosano GM, Tabchoury CP, Ferreira-Santos RI, Haiter-Neto F. Performance of Digital Radiography with Enhancement Filters for the Diagnosis of Proximal Caries. *Brazilian Oral Research* 2013;27(3):245-251.



- [33] Kositbowornchai S, Basiw M, Promwang Y, Moragorn H, Sooksuntisakoonchai N. Accuracy of Diagnosing Occlusal Caries Using Enhanced Digital Images. *Dentomaxillofacial Radiology* 2004;33(4):236-240.
- [34] Leonardi RM, Giordano D, Maiorana F, Greco M. Accuracy Of Cephalometric Landmarks on Monitor-Displayed Radiographs with and without Image Emboss Enhancement. *European Journal Of Orthodontics* 2010;32(3):242-247.
- [35] Møystad A, Svanaes DB, Larheim TA, Grøndahl HG. Effect of Image Magnification of Digitized Bitewing Radiographs on Approximal Caries Detection: An In Vitro Study. *Dentomaxillofacial Radiology* 1995;24(4):255-259.
- [36] Kositbowornchai S, Sikram S, Nuansakul R, Thinkhamrop B. Root Fracture Detection on Digital Images: Effect of the Zoom Function. *Dental Traumatology* 2003 19(3):154-159.
- [37] Gotfredsen E, Kragsskov J, Wenzel A. Development of a System for Craniofacial Analysis from Monitor-Displayed Digital Images. *Dentomaxillofacial Radiology* 1999;28(2):123-126.
- [38] Chen YJ, Chen SK, Chang HF, Chen KC. Comparison of Landmark Identification in Traditional Versus Computer-Aided Digital Cephalometry. *Angle Orthodontics* 2000;70(5):387-392.
- [39] Akhare PJ, Dagab AM, Alle RS, Shenoyd U, Garla V. Comparison of Landmark Identification and Linear and Angular Measurements in Conventional and Digital Cephalometry. *International Journal of Computerized Dentistry* 2013;16(3):241-254.
- [40] Santiago RC, Cunha AR, Júnior GC, Fernandes N, Campos MJ, Costa LF, Vitral RW, Bolognese AM. New Software for Cervical Vertebral Geometry Assessment and its Relationship to Skeletal Maturation--A Pilot Study. *Dentomaxillofacial Radiology* 2014;43(2):20130238.
- [41] Wenzel A, Kirkevang LL. Students' Attitudes to Digital Radiography and Measurement Accuracy of Two Digital Systems in Connection with Root Canal Treatment. *European Journal of Dental Education* 2004;8:167-171.
- [42] Horner K, Shearer AC, Walker A, Wilson NH. Radiovisiography: An Initial Evaluation. *British Dental Journal* 1990;168(6):244-248.
- [43] Walker A, Horner K, Czajka J, Shearer AC, Wilson NH. Quantitative Assessment of a New Dental Imaging System. *British Journal of Radiology* 1991;64(762):529-536.
- [44] Soh G, Loh FC, Chong YH. Radiation Dosage of a Dental Imaging System. *Quintessence International* 1993;24(3):189-191.
- [45] Näslund EB, Møystad A, Larheim TA, Øgaard B, Kruger M. Cephalometric Analysis with Digital Storage Phosphor Images: Extreme Low-Exposure Images with and

- without Postprocessing Noise Reduction. *American Journal of Orthodontics and Dentofacial Orthopedics* 2003;124(2):190-197.
- [46] Näslund EB, Kruger M, Petersson A, Hansen K. Analysis of Low-Dose Digital Lateral Cephalometric Radiographs. *Dentomaxillofacial Radiology* 1998;27(3):136-139.
- [47] Hellén-Halme K, Johansson PM, Håkansson J, Petersson A. Image Quality of Digital and Film Radiographs in Applications Sent to the Dental Insurance Office in Sweden for Treatment Approval. *Swedish Dental Journal* 2004;28(2):77-84.
- [48] Berkhout WE, Beuger DA, Sanderink GC, Van Der Stelt PF. The Dynamic Range of Digital Radiographic Systems: Dose Reduction or Risk of Overexposure? *Dentomaxillofacial Radiology* 2004;33(1):1-5.
- [49] Hokett SD, Honey JR, Ruiz F, Baisden MK, Hoen MM. Assessing the Effectiveness of Direct Digital Radiography Barrier Sheaths and Finger Cots. *Journal of American Dental Association* 2000;131:463-467.
- [50] Hubar JS, Gardiner DM. Infection Control Procedures in Conjunction with Computerized Dental Radiography. *International Journal of Computerized Dentistry* 2000;3(4):259-267.
- [51] Negron W, Mauriello SM, Peterson CA, Arnold R. Cross-Contamination of the PSP Sensor in a Preclinical Setting. *Journal Of Dental Hygiene* 2005;79(3):1-10.
- [52] Al-Rawi W, Teich S. Evaluation of Physical Properties of Different Digital Intraoral Sensors. *Compendium of Continuing Education in Dentistry* 2013;34(8):E76-83.
- [53] Russo JM, Russo JA, Guelmann M. Digital Radiography: A Survey of Pediatric Dentists. *Journal of Dentistry for Children (Chic)*. 2006;73(3):132-135.
- [54] Berg EC. Legal Ramifications of Digital Imaging in Law Enforcement. *Forensic Science Communications* 2000;2(4).
- [55] Scarfe WC, Farman AG. Cone Beam Computed Tomography. In: White SC, Pharoah MJ. *Oral Radiology. Principles and Interpretation*. 6<sup>th</sup> Ed St. Louis Mosby Elsevier; 2009. P.225-243
- [56] Peker I, Alkurt MT. Evaluation of Radiographic Errors Made by Undergraduate Dental Students in Periapical Radiography. *The New York State Dental Journal* 2009;75(5):45-48.
- [57] Chiu HL, Lin SH, Chen CH, Wang WC, Chen JY, Chen YK, Lin LM. Analysis of Photostimulable Phosphor Plate Image Artifacts in an Oral and Maxillofacial Radiology Department. *Oral Surgery Oral Medicine Oral Pathology Oral Radiology Endodontics* 2008;106(5):749-756.
- [58] Brezden NA, Brooks SL. Evaluation of Panoramic Dental Radiographs Taken in Private Practice. *Oral Surgery Oral Medicine Oral Pathology* 1987;63(5):617-621.

- [59] Akarslan ZZ, Erten H, Güngör K, Celik I. Common Errors on Panoramic Radiographs Taken in a Dental School. *Journal of Contemporary Dental Practice* 2003;4(2): 24-34.
- [60] Rondon RH, Pereira YC, Do Nascimento GC. Common Positioning Errors in Panoramic Radiography: A Review. *Imaging Science in Dentistry* 2014;44(1):1-6.
- [61] Peretz B, Gotler M, Kaffe I. Common Errors in Digital Panoramic Radiographs of Patients with Mixed Dentition and Patients with Permanent Dentition. *International Journal of Dentistry* 2012;2012:584138. Doi: 10.1155/2012/584138.
- [62] Frederiksen NL. Advanced Imaging. In: *Oral Radiology Principles and Interpretation*, 6<sup>th</sup> Ed, St. Louis, Mosby/Elsevier 2009,P. 207-224.
- [63] Yamamoto K, Hayakawa Y, Kousuge Y, Wakoh M, Sekiguchi H, Yakushiji M, Farman AG. Diagnostic Value of Tuned-Aperture Computed Tomography versus Conventional Dentoalveolar Imaging in Assessment of Impacted Teeth. *Oral Surgery Oral Medicine Oral Pathology Oral Radiology Endodontics* 2003;95(1):109-118.
- [64] Tyndall DA, Price JB, Tetradis S, Ganz SD, Hildebolt C, Scarfe WC; American Academy of Oral and Maxillofacial Radiology. Position Statement of the American Academy of Oral and Maxillofacial Radiology on Selection Criteria for the use of Radiology in Dental Implantology with Emphasis on Cone Beam Computed Tomography. *Oral Surgery Oral Medicine Oral Pathology Oral Radiology* 2012;113(6): 817-826.
- [65] Soğur E, Baksi BG, Gröndahl HG. Imaging of Root Canal Fillings: A Comparison of Subjective image Quality Between Limited Cone-Beam CT, Storage Phosphor and Film Radiography. *International Endodontic Journal* 2007;40(3):179-185.
- [66] American Dental Association Council On Scientific Affairs. The Use of Cone-Beam Computed Tomography in Dentistry. An Advisory Statement from the American Dental Association Council on Scientific Affairs. *Journal of American Dental Association* 2012;143(8):899-902.
- [67] Hatcher DC, Dial C, Mayorga C. Cone Beam CT for Presurgical Assessment of Implant Sites. *Journal of the California Dental Association* 2003;31(11):825-833.
- [68] Scarfe WC, Levin MD, Gane D, Farman AG. Use of Cone Beam Computed Tomography in Endodontics. *International Journal of Dentistry* 2009;2009:634567. Doi: 10.1155/2009/634567.
- [69] Dawood A, Patel S, Brown J. Cone Beam CT in Dental Practice. *British Dental Journal* 2009;207(1):23-28.
- [70] Farman AG. ALARA Still Applies. *Oral Surgery Oral Medicine Oral Pathology Oral Radiology Endodontics* 2005;100(4):395-397.

- [71] Alamri HM, Sadrameli M, Alshalhoob MA, Sadrameli M, Alshehri MA. Applications of CBCT in Dental Practice: A Review of the Literature. *General Dentistry* 2012;60(5): 390-400.
- [72] Tyndall DA, Brooks SL. Selection Criteria for Dental Implant Site Imaging: A Position Paper of the American Academy of Oral and Maxillofacial Radiology. *Oral Surgery Oral Medicine Oral Pathology Oral Radiology Endodontics* 2000;89(5):630-637.
- [73] Horner K. Cone-Beam Computed Tomography: Time for an Evidence-Based Approach. *Primary Dental Journal* 2013;2(1):22-31.
- [74] Visconti MA, Verner FS, Assis NM, Devito KL. Influence of Maxillomandibular Positioning in Cone Beam Computed Tomography for Implant Planning. *International Journal of Oral And Maxillofacial Surgery* 2013;42(7):880-886.
- [75] Stoetzer M, Nickel F, Rana M, Lemound J, Wenzel D, Von See C, Gellrich NC. Advances in Assessing the Volume of Odontogenic Cysts and Tumors in the Mandible: A Retrospective Clinical Trial. *Head And Face Medicine* 2013; 20;9:14.
- [76] Kaeppler G. Applications of Cone Beam Computed Tomography in Dental and Oral Medicine. *International Journal of Computerized Dentistry* 2010;13(3):203-219.
- [77] Tsao DH, Kazanoglu A, Mccasland JP. Measurability of Radiographic Images. *American Journal of Orthodontics* 1983; 84(3): 212–216.
- [78] Adams GL, Gansky SA, Miller AJ, Harrell WE Jr, Hatcher DC. Comparison between Traditional 2-Dimensional Cephalometry and a 3-Dimensional Approach on Human Dry Skulls. *American Journal of Orthodontics and Dentofacial Orthopedics* 2004;126(4):397-409.
- [79] Burkhard JP, Dietrich AD, Jacobsen C, Roos M, Lübbers HT, Obwegeser JA. Cephalometric and Three Dimensional Assessment of the Posterior Airway Space and Imaging Software Reliability Analysis before and after Orthognathic Surgery. *Journal of Craniomaxillofacial Surgery*. 2014; Pii: S1010-5182(14)00128-0. Doi: 10.1016/J.Jcms.2014.04.005. Article in Press
- [80] Cheung T, Oberoi S. Three Dimensional Assessment of the Pharyngeal Airway in Individuals with Non-Syndromic Cleft Lip and Palate. 2012;7(8):E43405. Doi: 10.1371/Journal.Pone.0043405
- [81] Garib DG, Yatabe MS, Ozawa TO, Da Silva Filho OG. Alveolar Bone Morphology in Patients with Bilateral Complete Cleft Lip and Palate in the Mixed Dentition: Cone Beam Computed Tomography Evaluation. *The Cleft Palate Craniofacial Journal* 2012;49(2):208-214.
- [82] Baysal A, Ucar FI, Buyuk SK, Ozer T, Uysal T. Alveolar Bone Thickness and Lower Incisor Position in Skeletal Class I and Class II Malocclusions Assessed with Cone-Beam Computed Tomography. *Korean Journal of Orthodontics* 2013;43(3):134-140.

- [83] Morea C, Hayek JE, Oleskovicz C, Dominguez GC, Chilvarquer I. Precise Insertion of Orthodontic Miniscrews with a Stereolithographic Surgical Guide Based on Cone Beam Computed Tomography Data: A Pilot Study. *International Journal of Oral and Maxillofacial Implants* 2011;26(4):860-865.
- [84] Chang HP, Tseng YC. Miniscrew Implant Applications in Contemporary Orthodontics. *The Kaohsiung Journal of Medical Sciences* 2014;30(3):111-115.
- [85] Hodges RJ, Atchison KA, White SC. Impact of Cone-Beam Computed Tomography on Orthodontic Diagnosis and Treatment Planning. *American Journal of Orthodontics and Dentofacial Orthopedics* 2013;143(5):665-674.
- [86] Noar JH, Pabari S. Cone Beam Computed Tomography--Current Understanding and Evidence for its Orthodontic Applications? *Journal of Orthodontics* 2013;40(1):5-13.
- [87] Shim YS, Kim AH, Choi JE, An SY. Use of Three-Dimensional Computed Tomography Images in Dental Care of Children and Adolescents in Korea. *Technology Health Care* 2014; 4. Epub Ahead of Print
- [88] May JJ, Cohenca N, Peters OA. Contemporary Management of Horizontal Root Fractures to the Permanent Dentition: Diagnosis--Radiologic Assessment to Include Cone-Beam Computed Tomography. *Pediatric Dentistry* 2013;35(2):120-124.
- [89] Aps JK. Cone Beam Computed Tomography in Paediatric Dentistry: Overview of Recent Literature. *European Archives of Paediatric Dentistry* 2013;14(3):131-140.
- [90] Al Najjar A, Colosi D, Dauer LT, Prins R, Patchell G, Branets I, Goren AD, Faber RD. Comparison of Adult and Child Radiation Equivalent Doses from 2 Dental Cone-Beam Computed Tomography Units. *American Journal of Orthodontics and Dentofacial Orthopedics* 2013;143(6):784-792.
- [91] Acar B, Kamburoğlu K. Use of Cone Beam Computed Tomography in Periodontology. *World Journal of Radiology* 2014; 28;6(5):139-147.
- [92] Corbet, EF Ho DK, Lai SM. Radiographs in Periodontal Disease Diagnosis and Management. *Australian Dental Journal* 2009;54(1): S27-S43.
- [93] Mengel R, Candir M, Shiratori K, Flores-De-Jacoby L. Digital Volume Tomography in the Diagnosis of Periodontal Defects: An In Vitro Study on Native Pig and Human Mandibles. *Journal of Periodontology* 2005;76(5):665-673.
- [94] Misch KA, Yi ES, Sarment DP. Accuracy of Cone Beam Computed Tomography for Periodontal Defect Measurements. *Journal of Periodontology* 2006;77(7):1261-1266.
- [95] Mol A, Balasundaram A. In Vitro Cone Beam Computed Tomography Imaging of Periodontal Bone. *Dentomaxillofacial Radiology* 2008;37(6):319-324.
- [96] Vandenberghe B, Jacobs R, Yang J. Detection of Periodontal Bone Loss Using Digital Intraoral and Cone Beam Computed Tomography Images: An In Vitro Assessment of Bony and/or Infrabony Defects. *Dentomaxillofacial Radiology* 2008;37(5):252-260.

- [97] Walter C, Kaner D, Berndt DC, Weiger R, Zitzmann NU. Three-Dimensional Imaging as a Pre-Operative Tool in Decision Making for Furcation Surgery. *Journal of Clinical Periodontology* 2009;36(3):250–257.
- [98] Patel S. New Dimensions in Endodontic Imaging: Part 2. Cone Beam Computed Tomography. *International Endodontic Journal* 2009;42(6): 463–475.
- [99] Tyndall DA, Kohltfarber H. Application of Cone Beam Volumetric Tomography in Endodontics. *Australian Dental Journal* 2012;57(L):72-81.
- [100] Rigolone M, Pasqualini D, Bianchi L, Berutti E, Bianchi SD. Vestibular Surgical Access to the Palatine Root of the Superior First Molar: "Low-Dose Cone-Beam" CT Analysis of the Pathway and its Anatomic Variations. *Journal of Endodontics* 2003;29(11):773-775.
- [101] Tsurumachi T, Honda K. A New Cone Beam Computerized Tomography System for use in Endodontic Surgery. *International Endodontics Journal* 2007;40(3):224-232.
- [102] Haghanifar S, Moudi E, Mesgarani A, Bijani A, Abbaszadeh N. A Comparative Study of Cone-Beam Computed Tomography and Digital Periapical Radiography in Detecting Mandibular Molars Root Perforations. *Imaging Science in Dentistry* 2014;44(2): 115-119.
- [103] Hassan B, Metska ME, Ozok AR, Van Der Stelt P, Wesselink PR. Detection of Vertical Root Fractures in Endodontically Treated Teeth by a Cone Beam Computed Tomography Scan. *Journal of Endodontics* 2009;35(5):719-722.
- [104] Low KM, Dula K, Burgin W, Von Arx T. Comparison of Periapical Radiography and Limited Cone-Beam Tomography in Posterior Maxillary Teeth Referred for Apical Surgery. *Journal of Endodontics* 2008;34(5):557–562.
- [105] Jeger FB, Lussi A, Bornstein MM, Jacobs R, Janner SF. [Cone Beam Computed Tomography in Endodontics: A Review for Daily Clinical Practice][Article in German] *Schweiz Monatsschr Zahnmed* 2013;123(7-8):661-668.

IntechOpen

