

# We are IntechOpen, the world's leading publisher of Open Access books Built by scientists, for scientists

**4,800**

Open access books available

**122,000**

International authors and editors

**135M**

Downloads

Our authors are among the

**154**

Countries delivered to

**TOP 1%**

most cited scientists

**12.2%**

Contributors from top 500 universities



**WEB OF SCIENCE™**

Selection of our books indexed in the Book Citation Index  
in Web of Science™ Core Collection (BKCI)

Interested in publishing with us?  
Contact [book.department@intechopen.com](mailto:book.department@intechopen.com)

Numbers displayed above are based on latest data collected.

For more information visit [www.intechopen.com](http://www.intechopen.com)



---

# Non-Invasive Imaging Modalities for Clinical Investigation in Regenerative Medicine

---

Deana G. Haralampieva, Simon M. Ametamey,  
Tullio Sulser and Daniel Eberli

Additional information is available at the end of the chapter

<http://dx.doi.org/10.5772/59356>

---

## 1. Introduction

Recent developments in the field of regenerative medicine highlighted the emerging need for cellular therapies. This novel approach is at the doorstep to its clinical application. Nevertheless, there is still a lack of consistent and unbiased data on the survival, distribution and safety of implanted cells. The tight collaboration between pharmacology, chemistry, biology and physics expanded the collection of methods for *in vivo* imaging and allowed for real time assessment of functional read-outs, localization and viability of the implants. The successful implementation of stem cell visualization will provide for improvements in many healthcare fields. Of key importance is the identification of the most valuable method for non-invasive monitoring of cells and affected tissue. In this chapter we will assess the advantages and drawbacks of different imaging techniques, focusing specifically on cell therapy and methods utilized for tissue engineering and regenerative medicine.

Organ transplantation still remains the gold standard for the treatment of terminally damaged organs. This method brings along a collection of drawbacks like the shortage of available donor organs and the high morbidity of immunosuppressive therapy. Regenerative medicine offers an alternative for the replacement of organs and tissues overcoming pitfalls and proposing a therapy with patient's own cells. The discovery of the self-renewal and differentiation capacities of stem cells accelerated the development of regenerative medicine and inspired researchers and clinicians to search for novel treatment options for the improvement of the quality of life of patients [1]. The tremendous success in medical sciences and biotechnology allowed the development of many ideas, some of which are now being approved by clinical trials. Nearly 26'000 studies utilizing cell therapy are currently ongoing [2] trying to establish the safety and effectiveness of this new method for applications in neurology, cardiology or

oncology. Autologous stem cell therapy is a novel promising approach with increasing impact on regenerative medicine. Preliminary data of many preclinical studies on different human disorders showed a beneficial effect of this treatment [3]. The usage of the patient's own cells to rebuild tissues and regain functionality after trauma is currently investigated, as it may have a profound influence on many human diseases once its application is approved. Several hurdles are yet to be overcome before the safety of this method is guaranteed. One possibility to avoid the post mortem read-out of a study or the invasiveness of a biopsy is the use of *in vivo* imaging. Succeeding in this would also significantly reduce the number of animal experiments to be performed. The emerging need for "real time" visualization of cells and tissue gives rise to many questions in the field of regenerative medicine. Many different cellular therapies are on the door step into clinics and a method for non-invasive tracking of transplanted cells and defining their fate, functionality and differentiation is of great importance. Of high interest is also the visualization of their effect on the damaged tissue or organ.

In the past two decades many researchers concentrated on developing new modalities for better visualization on the cellular and molecular level. As none of the available imaging systems fulfils all needs, many efforts have been put into expanding the potential of the available methods by testing the application of a variety of vectors, genes, proteins and cells for precise read-outs. The visualization techniques relevant to clinical cell tracking include positron emission tomography (PET), single-photon emission computed tomography (SPECT) and magnetic resonance imaging (MRI) [4]. Hybridizations of computed tomography (CT) and MRI with PET and SPECT allow simultaneous acquisition of anatomical information and reveal new state-of-the-art modalities for successful molecular imaging (SPECT/CT, PET/CT, PET/MRI) [5]. Generally, the utilization of radioactive tracers provides high sensitivity and requires short image acquisition time. Nevertheless, the production of the radioactive isotopes is very expensive and its application comes along with radiation exposure for the patient. Therefore, MRI seems to be an attractive alternative devoid of harmful radiation. This modality has spectacular image resolution and anatomical read-out capabilities [6]. However, it is more time-consuming and lacks the high sensitivity of PET and SPECT [7] (see Table 1). There are also a few optical imaging modalities using bioluminescence (BLI) or fluorescence (FI), which have been widely utilized in small animal models [8]. These are cost-saving methods (using fluorescent proteins or luciferase activity) which allow for very rapid result obtainment. Nevertheless, their spatial resolution is low and decreases with depth, which is the main reason why they are not applicable for life cell imaging in humans.

Many cells are potentially accessible by imaging and developments in this field already support the diagnosis and therapy of several human diseases. However, a feasible technique for non-invasive monitoring of the tissue engineering process is still missing. A variety of cells was shown to be applicable for tissue and organ restoration, but yet little is known about the safety, viability, functionality and migration of these cells *in vivo* and their direct or indirect involvement in the healing process. Despite the abundance of new techniques for non-invasive visualization of cells, their translation into the clinic is challenging. Hence, here we will discuss the advantages and drawbacks of different imaging modalities applicable for humans and their implementation in the diagnostics and monitoring of the treatment of various diseases

located in the hot spot of current clinical trials. Moreover, we will consider potential strategies for expansion of the available techniques, in particular for successful tissue engineering and regenerative medicine.

Imaging Modality	Spatial Resolution	Temporal Resolution	Sensitivity	Safety	Clinically Applied	Cost
CT	50-200 $\mu\text{m}$ (preclinical) 0.5-1 mm (clinical)	minutes	not defined	Ionizing radiation	Yes	\$\$
MRI	25-100 $\mu\text{m}$ (preclinical) ~1 mm (clinical)	minutes-hours	$10^{-3} - 10^{-5}\text{M}$ poor	No ionizing radiation	Yes	\$\$\$
PET	1-2 mm (preclinical) 5-7mm (clinical)	seconds-minutes	$10^{-11} - 10^{-12}\text{M}$ excellent	Ionizing radiation	Yes	\$\$\$
SPECT	1-2 mm (preclinical) 8-10 mm (clinical)	minutes	$10^{-10} - 10^{-11}\text{M}$ excellent	Ionizing radiation	Yes	\$\$

**Table 1.** Characterizations of clinical imaging modalities (adapted from [9]).


## 2. MR imaging

### 2.1. MRI basics

The phenomenon of Magnetic Resonance Imaging (MRI) was discovered observing the reaction of certain nuclei, mostly  $^1\text{H}$  in the body, when placed in a strong magnetic field ( $B_0$ ) [10]. Within a magnetic field, the sum of spins is a net magnetization aligned with the applied field. The macroscopic magnetization is an effect of a slight excess of spins in “low energy” state, in parallel to the  $B_0$  direction. The precession frequency of each atom with magnetic moment is directly proportional to the strength of the magnetic field. After applying a radiofrequency (RF) pulse which matches the precession frequency, some of the “excess” atoms absorb energy and flip, thereby changing the direction of the net magnetization vector. The flip angle depends on the intensity, waveform and duration of the RF pulse [11]. These atoms then re-emit the energy during transition to their original orientation (relaxation) (Figure 1).

As already shown, MRI is based on a unique combination of radio waves and strong magnetic fields, which allows the generation of cross-sectional images of the body in any plane. Depending on the relaxation time after the RF pulse, one can distinguish between T1-and T2-weighted images.

MRI is an imaging modality, which uses non-ionizing electromagnetic radiation and is thus not harmful for patients. This is one of the strongest advantages of this technology over the other methods described in this chapter.



**Figure 1.** MRI scanner uses radiowaves and strong magnetic fields to obtain anatomical and functional body images. 1) Atoms spin in random directions. 2) Applying a magnetic field makes atoms line up either in the direction of  $B_0$ , or in the opposite direction. The distribution is not exactly equal, as more atoms prefer to turn in “low energy” state, thereby creating a net magnetization parallel to  $B_0$ . 3) Introducing a RF pulse makes half of the “excess” atoms change the direction of their magnetization moment-to the “high energy” state. 4) Turning the RF off makes these atoms turn back to their “low energy” position (relaxation), thereby emitting energy.

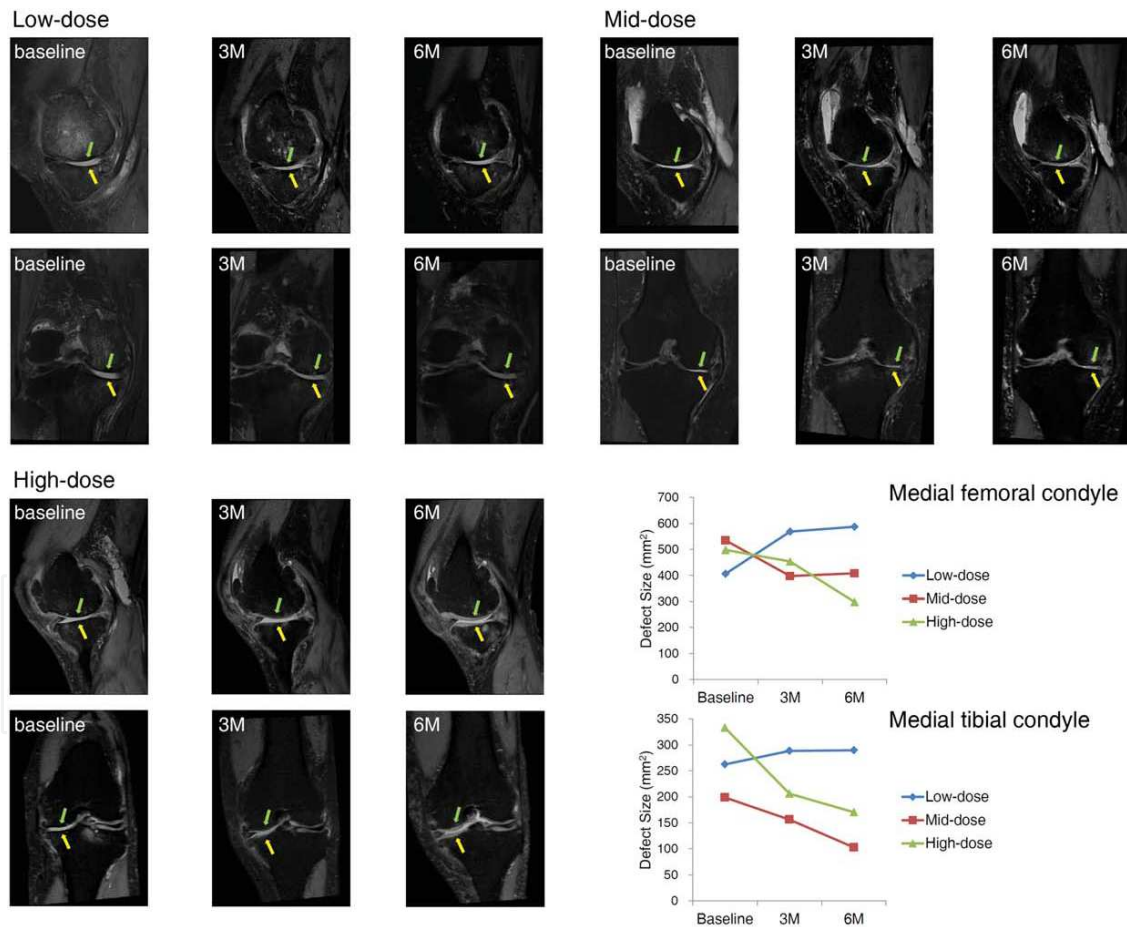
## 2.2. MRI applications

One of the biggest advantages of MRI is its high soft tissue contrast. This allows for very precise images and simultaneous detection of functional, molecular and anatomical data. The tight collaboration of science and medicine led to the clinical implementation of the MRI modality for various diseases. Nevertheless, most of its potential remains at the pre-clinical state, as the application safety of many methods is still under investigation. Cerebral perfusion imaging, MR angiography flow imaging, cardiac MRI, functional MRI and MR spectroscopy are just a few of the MRI sub-groups. However, up-to-date, MR is clinically mainly used for the imaging of soft tissues.

A clinical trial study with patients suffering from acute myocardial infarction showed successful implementation of MRI. Intracoronary infusions of bone marrow-derived stem cells at different time points helped with cardio regeneration, which could be visualized by this technique [12]. Another study is on its doorstep to clinics, gathering breast cancer patients for breast restoration. The aim is to use MRI of autologous adipose-derived stem cells to visualize the engraftment into the host tissue. The outcome of this study may have a great impact on the utilization of MRI for cell tracking as a novel tool for breast tissue regeneration [13]. A further example for the implementation of MRI for cell therapy studies was the evaluation in a multiple sclerosis clinical trial. In this case, adult bone marrow derived stromal cells were intravenously administered to the patients and MRI scans were performed to follow the occurring changes. The main objective was to evaluate the effect of mesenchymal stem cell transplantation on the number of Gadolinium (Gd)-positive lesions [14]. Another way of addressing the safety and efficacy of using autologous mesenchymal stem cells as a possible therapy for multiple sclerosis is being proposed by a group, using MR imaging for the assessment of the therapeutic effect of the cell treatment [15]. All in all, MRI seems to be a promising tool for monitoring therapy and diagnostic outcomes. Nevertheless, most of the clinical studies using stem cell therapy in combination with MRI are focused on the visuali-

zation of the regenerating soft tissue, rather than on the transplanted stem cells, their localization, viability and safety.

Further efforts have been put into the development of strategies for bone and cartilage regeneration. Recent studies are concentrating on developing a MRI-based method for visualization of knee osteoarthritis by assessing the number and location of lesions, cartilage thickness, and subchondral bone alteration at different time points [16]. Others went further by using autologous adipose tissue derived mesenchymal stem cells (AD MSCs) as the most hopeful candidate progenitor cell source for cartilage tissue engineering in patients with degenerative arthritis. Promising results showed improved knee functions and reduced pain without any adverse events. The cartilage regeneration process was captured by MRI at different time points, showing decreased size of cartilage defect, while the volume of cartilage increased over time in the high-dose patients (Figure 2) [17]. This depicts an excellent example of the gradual morphologic regeneration process, visualized by means of MRI.



**Figure 2.** MRI evaluation of articular cartilage regeneration in the medial and femoral condyles after intra-articular injection of autologous AD MSCs. Sagittal and coronal MRIs before, 3, and 6 months after AD MSCs injection depicted the beneficial effect of the high-dose stem cell therapy upon cartilage regeneration by visualizing increase in thickness, and significantly decreased defect size. (Reprinted from [17], Copyright (2014), with permission from “John Wiley and sons” and Kang Sup Yoon, M.D., Ph.D.)

Besides its tremendous spatial resolution for visualization of soft tissues, MRI has proven successful in the imaging of the spinal cord and column. There are several clinical studies concentrating on the regeneration of this region using mesenchymal stem cell (MSC) transplants after injury. One group is trying to evaluate the change of MSC-treated spinal cord injury using MRI. Scans will be performed at 3 and 6 months after transplantation in order to track the effects of the possible cell treatment and the different ways of application (intravenous, intrathecal, into the spinal cord) [18]. The outcome of this trial will allow suggesting the most beneficial cell delivery method for further studies. Another project was concentrating on the visualization of spinal cord lesions inducing limb paralysis. The proposed treatment strategy included injections of bone marrow derived stem cells. Again, the preferred non-invasive imaging method for localization of the injuries was MRI [19]. It seems that MRI is a suitable imaging tool to assess spinal cord lesions and their repair by stem cells. One group addressed the safety and efficacy of autologous MSC injections in patients with chronic spinal cord injury. The outcome of this study revealed changes in MRI such as decreased cavity size and the appearance of fiber-like low signal intensity streaks [20]. An increasing amount of research is concentrating on the transplantation of stem cells as a therapeutic tool, but still, most of the data derives from pre-clinical models. Nevertheless, promising studies in humans reveal new possible solutions for many disorders.

The implementation of contrast agents for enhancement of MRI offers higher contrast and resolution. Gadolinium (Gd) and superparamagnetic iron-oxide (SPIO) are most commonly used for direct stem cell labeling in clinical and preclinical trials, with SPIO particles offering the highest sensitivity amongst all MR contrast agents. Despite initial reports that SPIO labeling of stem cells is safe and does not affect cell biology, recent studies indicate certain metabolic and functional changes. Therefore, some essential issues need to be considered before accepting such agents for clinical trials. A recent study [21] used Gd-or SPIO-labeled mesenchymal stem cells, transduced with a luciferase vector to monitor their viability via BLI. The outcome showed a distinction between viable and non-viable Gd cells, correlating with the luciferase signal. However, dead SPIO-cells indicated a persistent signal void *in vivo*, with simultaneous decrease of luciferase activity. This demonstrates that the absence or presence of a contrast agent signal alone does not prove for cell viability. Often, dead cells are being phagocytized by macrophages and the labeling persists in the new "host cells". Although Gd-labeling of stem cells seems feasible [22], its main disadvantages are the large amounts of Gd chelates needed to produce a signal, the toxic effect of Gd if released from the complex (affects kidneys) and the lower sensitivity compared to SPIO. These issues should be taken into consideration, as they might lead to false quantification of the imaging data. Recently, a new Gd-based contrast agent (Dotarem<sup>®</sup>) was approved by the FDA for Phase III clinical studies for MRI in brain, spine and associated tissues in adult and pediatric patients to detect areas with disruption of the blood-brain barrier and/or abnormal vascularity [23]. These clinical studies showed superiority of the enhanced over the unenhanced images of the CNS lesions. All in all, contrast agents improve the quality of the images, but their side effects have to be taken into consideration.

Safety and efficacy of autologous stem cell therapies remains a big issue and a non-invasive visualization tool like MRI is facilitating the refinement of the procedures. Since MRI provides more biological and functional data than CT-without radiation-the system provides a huge advantage for pediatric patients as well as patients needing multiple scans. This makes it a superior imaging modality in many clinical studies and encourages more patients to sign up for the trials, as the risk for unwanted complications is decreased. However, MRI does not come with excellent sensitivity and abundant molecular probes compared to other techniques, following in this chapter.


### 3. PET imaging

#### 3.1. PET basics

Radionuclide-based positron emission tomography (PET) is one of the most sensitive molecular imaging techniques. Contrary to MRI, this technique uses radiation. The agents used for the visualization are labeled with a positron emitting radionuclide ( $^{11}\text{C}$ ,  $^{13}\text{N}$ ,  $^{15}\text{O}$ ,  $^{18}\text{F}$  etc.) which decays by emitting a positively charged particle ( $\beta^+$ ). A positron is a particle with the same mass as an electron, but with an opposite charge. Every positron-emitting radionuclide has its own positron range (traveling distance), depending on the energy of its  $\beta^+$ -particle. The higher the energy, the longer the distance and, therefore, the larger the loss of spatial resolution. Once most of its energy is lost, the positron eventually annihilates with an electron from the surrounding tissue, whereby their mass is converted into electromagnetic energy in the form of high-energy photons [24]. The PET Imaging technique is based on the coincidence detection of two 511 keV photons emitted simultaneously in opposite directions ( $180^\circ$  apart). They are collected by a ring system of photon-sensitive detectors (scintillation crystals), surrounding the object of interest (Figure 3). Although the exact location of a single annihilation is unknown, the acquisition of a large number of coincidence events over many angles can provide enough information to reconstruct an image of the spatial distribution of radioactivity as a function of time [5].

The idea for the development of the PET technique was developed in the 1950s and was introduced only a few decades later [25] as a clinical device for neurology and cardiology. Later, the need of precise anatomic localization and metabolic readout led to the invention of new imaging strategies. Combining two complementary modalities can add anatomical and/or physiological information to molecular imaging studies using software fusion of data. This technology is most successful for studies of organs and tissues that do not move with time, e.g. the brain [26]. Another approach allowing for simultaneous and/or sequential obtainment of data by a single device is the fusion of PET with CT or MRI. The immense value of combining the benefits of two imaging modalities in one instrument in order to assess molecular as well as morphologic information is of major interest nowadays. These devices allow for more exact attribution of the radioactivity to a specific anatomic site within the patient. Another great impact on the expansion of possible PET applications is the increasing availability of PET radiopharmaceuticals. Many researchers are working towards the devel-





**Figure 3.** PET scanner detects coincidence of two 511 keV photons emitted in opposite directions after annihilation of a positron ( $\beta^+$ ) with an electron ( $e^-$ ) in the surrounding media. The signals are captured by scintillation crystals and amplified by photomultipliers. These events are then collected to construct images depicting the activity distribution.

opment of novel radiotracers for diagnosis and/or therapy of various diseases. Combinations of new technologies and radioligands have already been applied in diverse studies and thus provided many insights for the further development of personalized medicine.

### 3.2. PET applications

Great improvements have been made towards the diagnosis and the therapy monitoring of cancer, brain and heart diseases, as well as for a variety of malignancies and organ/tissue restorations. [ $^{18}\text{F}$ ]fluorodeoxyglucose ([ $^{18}\text{F}$ ]FDG) is the most widely used PET radiopharmaceutical. It is a metabolic tracer and the mechanism of uptake is based on phosphorylation to [ $^{18}\text{F}$ ]FDG-6-phosphate, which is not further metabolized. [ $^{18}\text{F}$ ]FDG has a wide range of applications in oncology, neurology, cardiology and inflammation imaging.

In the past few years many researchers concentrated on cell-based therapies for the restoration of damaged myocardium showing the involvement of different cell types in this process such as: skeletal myoblasts, embryonic stem cells, bone-marrow derived stem cells, cardiac resident cells, mesenchymal stem cells, and circulating progenitor cells. [27]. The introduction of cells into the damaged myocardium seems to be a promising technique and therefore several tools for assessing the viability, localization and metabolism of the injected cells have been evaluated [28]. The implanted cells should be suitably labeled for detection via imaging, in order to be distinguishable from the surrounding cells and structures. This can be achieved by PET imaging using [ $^{18}\text{F}$ ]FDG. It was already shown to be feasible for dynamic tracking of [ $^{18}\text{F}$ ]FDG-labeled progenitor cells during intracoronary injection after acute myocardial infarction [29]. One of the main glucose uptake sites in the body are skeletal muscles. Using PET imaging of this glucose derivate allows for longitudinal assessment of skeletal muscle regeneration and degeneration [30]. This allows for easy visualization by [ $^{18}\text{F}$ ]FDG uptake in response to physical exercise, thus making muscle cells a good diagnostic tool for therapy of muscle disorders [31]. Whether this technology is suitable for regenerative medicine purposes has to be further evaluated.

Another application of this tracer was shown in a clinical study using bone marrow cells for autologous stem cell therapy after myocardial infarction. They included the PET modality in their experimental design and investigated the myocardial flow ( $[^{13}\text{N}]\text{NH}_3$ ) and perfusion/metabolism mismatch ( $[^{18}\text{F}]\text{FDG}$ ) [32]. The usage of PET for tracking *in vivo* cell retention of adipose tissue-derived stem cells for myocardial regeneration also showed promising results [33]. It seems that these cells support the cardiomyocyte regeneration and angiogenesis in the implanted area. The PET/CT modality appears to be a promising technique for effective cell-tracking *in vivo*, which is vital for a more in-depth investigation into future clinical applications.

Another possibility for PET application is the utilization of reporter-gene systems (e.g. Herpes Simplex Virus type 1 thymidine kinase (HSV1-tk)) [34]. The main advantage of this method is that the obtained signal is specific only to viable cells, as they are able to express the reporters. This allows not only for visualization of acute cell retention, but also for viability read-outs [7]. HSV1-tk is currently the most investigated enzyme reporter gene for long term *in vivo* visualization of cells applied in the treatment of various cardiovascular diseases [35-37]. Recent studies also investigated the use of reporter gene tracking via PET imaging to track viable stem cells in large animal models [38-40]. These studies confirm the potential of this novel method to allow for a better understanding of the cell fate after implantation. Using cell-based therapies for tissue engineering with stem and/or progenitor cells for boosting regeneration seems to offer great possibilities in regenerative medicine. Therefore, the development of novel methods for non-invasive imaging of implants *in vivo* is of high priority.

PET/CT has also become an essential tool for assessing prognosis and establishing treatment decisions in oncology. This system found broad application, mainly in defining different stages/locations of metastatic cancer. In this case PET is used for visualizing the increased metabolic activity of the tumor and the addition of CT provides anatomical information on its exact location in the body [41]. This helped immensely in the management of a broad spectrum of malignancies, their diagnosis, staging and therapy-response-assessment. The most commonly used radiopharmaceutical in clinics  $[^{18}\text{F}]\text{FDG}$  was shown to be essential to the treatment of a great range of pathologies. This can significantly contribute to precise therapy response assessment possibly influencing the therapeutic management and treatment planning [42]. Another study revealed a promising application of fluorine-18 labeled amino acid-based radiotracers for small cell lung cancer detection via PET imaging [43]. Furthermore, a recently developed categorization method for differentiation of osteosarcoma phenotypes by comparing SUV values of PET radioligands for glucose metabolism ( $[^{18}\text{F}]\text{FDG}$ ), hypoxia ( $[^{18}\text{F}]\text{FMISO}$ ) and bone remodelling ( $[^{18}\text{F}]\text{fluoride}$ ) showed promising results. These findings can improve the future evaluation of the treatment strategy depending on the specificity of the malignancy [44]. These tracers can be applicable also for regenerative purposes, studying the healing process of e.g. bones. A current clinical study for bone reconstruction of the skull is examining the regeneration after introducing an implant using PET/CT via  $[^{18}\text{F}]\text{fluoride}$ . Succeeding in this would help out many patients with cranial defects and significantly improve their quality of life [45].

Cardiology also gained immense benefits from the development of the hybrid imaging systems (e.g. correction of attenuation and evaluation of coronary classifications), CT for coronary

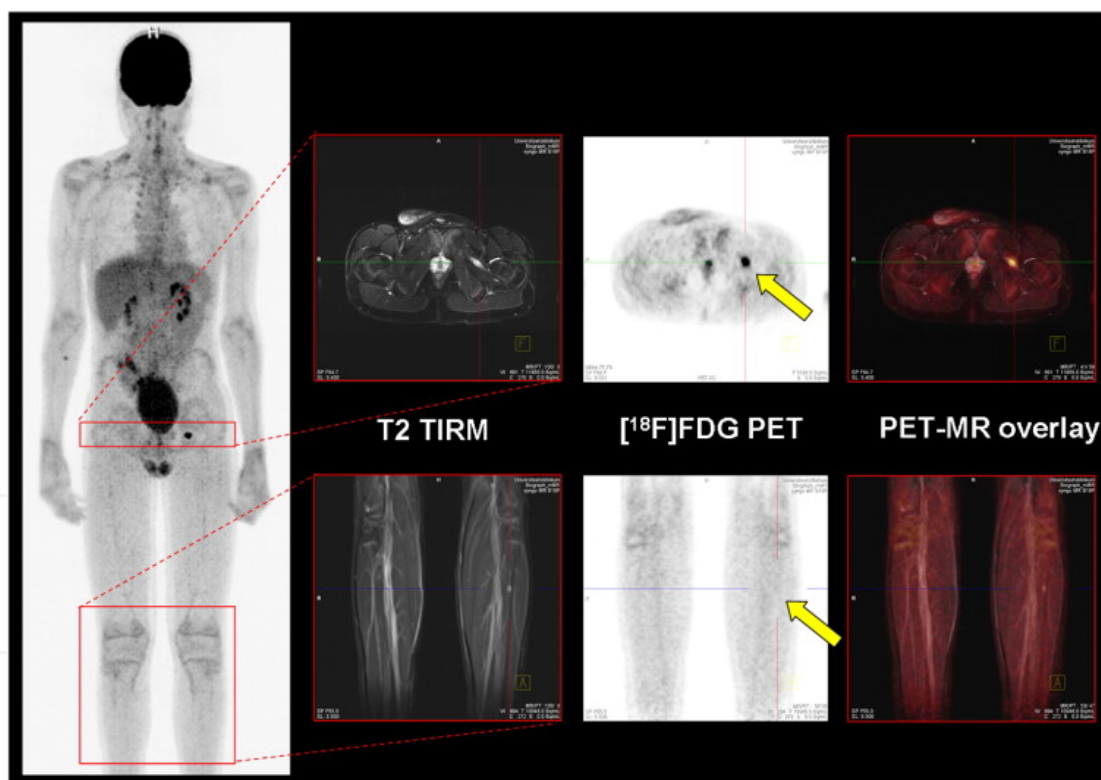
angiography, and acquisition of 3-D hybrid images for the definition of heart viability and diagnosis of cardiac inflammations and infections [46]. Recent advances in stem cell therapy show promising results for myocardium restoration, neovascularization and enhancement of perfusion [47-50].

Research on the central nervous system (CNS) mainly emphasized on mapping different aspects of neurotransmitter activity, e.g. dopaminergic, cholinergic, serotonergic and glutamatergic systems as well as beta-amyloid visualization for Alzheimer's disease (AD) [5, 51, 52]. PET Imaging has been applied widely to detect and quantify subtle abnormalities in CNS diseases. Therefore, this technology is also immensely popular as a modeling tool in CNS drug discovery and development. It is used for evaluation of drug deposition, as well as for studying disease biomarkers to monitor drug effects on brain pathologies [24]. Another CNS utilization of this modality was shown in a promising study regarding spinal cord injury [53]. The combined efforts of stem cell and neuroscience researchers made it possible to visualize the spinal cord regeneration process on the cellular and molecular level. In order to explore the effect of *in vivo* PET on tracking dopamine receptor positive stem cells transplanted into the spinal cord, [<sup>11</sup>C]Raclopride was injected intravenously, followed by a scan. The accumulation of signal in the site of injury showed successful tracking and localization of the injected cells. These results suggest that PET with a radiotracer is a useful technique for functional studies in developing cell-based therapies [54]. Similar experimental setups allowed for more rapid progression of many pre-clinical and clinical studies of various CNS pathologies (e.g. [<sup>11</sup>C]Methionine PET/CT in patients with cancer; [<sup>18</sup>F]FLT in pediatric patients with CNS tumors [55]).

After the successful introduction of the PET/CT system to the clinics, the integration of PET with MRI was the next step. This new hybrid technique allows for simultaneous functional PET imaging combined with soft tissue morphological MR images. The novel approach brings better contrast among soft tissues as well as functional imaging capabilities, when compared to PET/CT. Nevertheless, this technology is still not clinically mature at this point. Technically, the implementation of PET/MR faces three major issues: 1. The photomultiplier-based PET scanners do not work in the proximity of the magnetic field of the MR scanner; 2. Metallic objects (e.g. surface coils used to get the best MR quality images) interfere with gamma rays from PET, resulting in unwanted attenuation; 3. MR data cannot be used for attenuation correction, as CT data, which is a limiting factor for the use of PET in therapy response monitoring [56].

As PET signal processing might disturb the high-frequency signals of MRI, and conventional PET electronics fail in an even weak magnetic field, it soon became clear that new solutions had to be found to circumvent the joint interferences. One possibility would be to leave just the PET crystals in the MR field, whereas the PMTs are positioned outside and connected to the crystals by optical fibres. Another approach to avoid the disturbance would be to place the PET and MR scanners remote to each other, but still linked by a common bed, so that the patient does not move between the two scans. Last, but not least, the PMTs could be replaced by solid state electronics which are not disturbed by the MR field [57]. Hence, various approaches were developed during the last fifteen years for application in small animal studies, where the usage of more PET tracers is allowed and where use is not as legally restricted, as in human studies. For a review, see Herzog, 2012 [57]. Improvements in pre-clinical study design enable smooth

transfer of knowledge and molecular measurements between species thereby facilitating clinical translation. Recently, PET/MRI for human imaging became available as well, towing to support form the industry. Siemens Healthcare first designed prototypes of a BrainPET/MRI device and the first reports of patients have been communicated [58, 59]. This opened new possibilities in the field of molecular imaging and prepared the development of an integrated whole-body PET/MRI scanner. A recent study compared the performance of whole-body PET/MRI to PET/CT of breast cancer patients and claimed that PET/MRI is a feasible technique for usage in clinics, forgoing gamma radiation for high quality imaging with short examination time [60]. Another example for implementation of this new technique was shown in a sarcoma patient, who underwent chemotherapy and autologous stem cell injection. MRI showed lesions in the upper and lower leg, whereas PET revealed high  $^{18}\text{F}$ FDG uptake only in one of the lesions (Figure 4). This case illustrates the benefit of combining different imaging modalities in order to get more precise outcomes, thereby improving the application fields of personalized medicine. This methodology might also be useful for the investigation of regenerative processes in damaged organs or tissues, for example after autologous stem cell therapy for boosting the healing progression.



**Figure 4.** Simultaneous whole-body PET/MRI acquired with a molecular MR (mMR) scanner in a 13-year old boy with a Ewing sarcoma known for six years. The patient underwent standard chemotherapy together with autologous stem cell transplantation. After *i.v.* injection of  $^{18}\text{F}$ FDG whole body PET-MRI was carried out. MR resulted in two suspicious lesions: One in the left upper leg muscle region, and one in the left lower leg. While the lesion in the left upper leg muscles showed intense  $^{18}\text{F}$ FDG uptake, the other one was PET-negative (arrows). Follow-up confirmed a Ewing sarcoma relapse in the left upper leg muscle region. (Reprinted from [60], Copyright (2014), with permission from “Elsevier” and Prof. Dr. med. O. Sabri)

The clinical application of the PET/MRI technique has to be further established. Nevertheless, if MRI can replace CT for anatomical screening, it adds value as well as decreases radiation exposure, which would be of great benefit for the patients. However, the ongoing question of choosing the best suitable visualization method remains unanswered, as there is still insufficient knowledge about which PET/MRI applications are superior to the well-known PET/CT for a variety of clinical cases.


## 4. SPECT imaging

### 4.1. SPECT basics

Unlike PET, single photon emission computer tomography (SPECT) uses radiopharmaceuticals labeled with gamma emitters instead of positron emitters. The concept of transmission and emission tomography, later developed into SPECT, was first introduced in the late 1950s. This period is associated with phenomenal growth of Nuclear Medicine, when some of the most prominent gamma-radiation emitting radionuclides ( $^{131}\text{I}$  and  $^{99\text{m}}\text{Tc}$ ) were produced [61]. While the primary use of  $^{131}\text{I}$  was dedicated to thyroid cancer treatment, its use was later expanded for imaging of the thyroid gland itself, its function and the therapy of hyperthyroidism. The development of a generator system for  $^{99\text{m}}\text{Tc}$  (1960s) was an important breakthrough and today it is the most utilized element in the field of Nuclear medicine. Other typical gamma emitting radionuclides utilized in SPECT are  $^{123}\text{I}$ ,  $^{67}\text{Ga}$  and  $^{111}\text{In}$ . The most common SPECT systems consist of a gamma camera with rotating NaI(Tl) detector modules located between the photomultipliers and collimators (Pb) (Figure 5), an on-line computer for acquisition and processing of data and a display system [62]. Generally, a target-specific SPECT radiopharmaceutical consists of two parts: a gamma-emitting radionuclide and a targeting biomolecule (e.g. peptide, antibody fragment) [63]. Similar to PET, SPECT also enables 3-D imaging and hybrid systems (SPECT/CT) are available as well.

### 4.2. SPECT applications

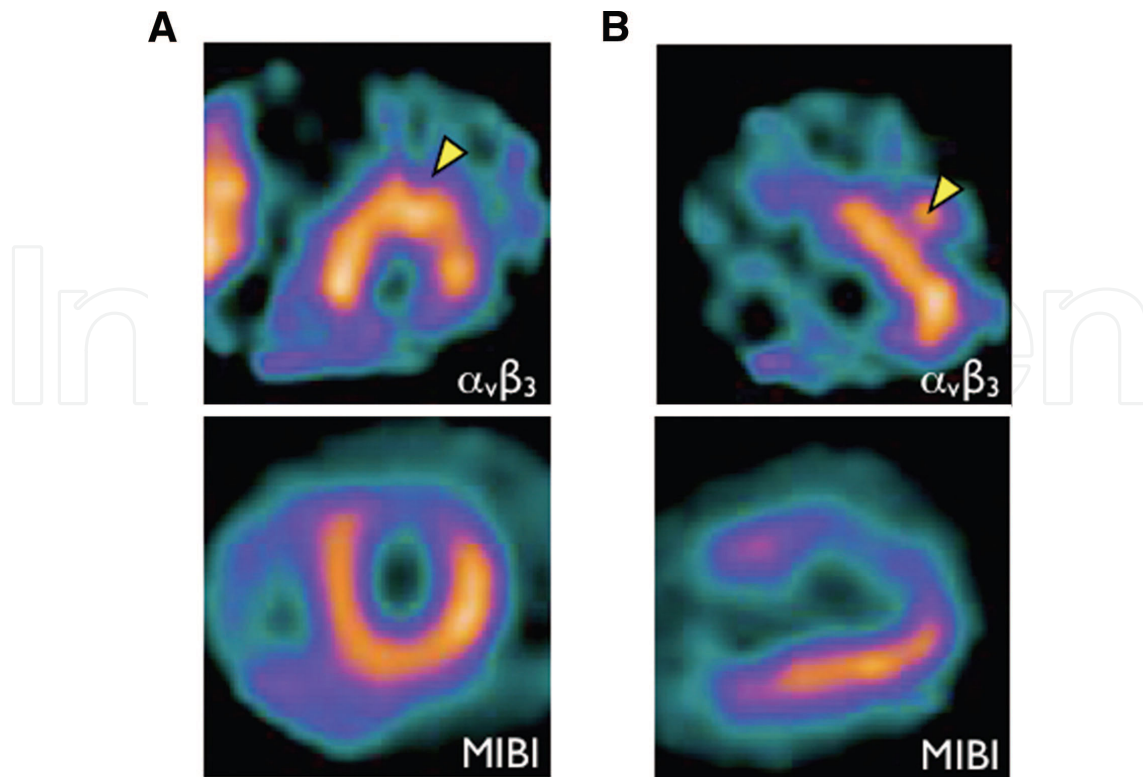
Various stem cells hold promise for the treatment of many human diseases. However, little is known about the exact function, location and survival of the transplanted cells. The usage of the SPECT imaging modality to answer these questions revealed promising results. Clinical studies with SPECT indicated evidence for efficacious imaging of transplanted radiolabeled cells in cardiac disease. Encouraging results were obtained from studies using [ $^{99\text{m}}\text{Tc}$ ]hexamethylpropylenamineoxine (HMPAO)-labeled stem cells. Comparison of intracoronary (IC) and transendocardial (TE) delivery of the cells to the heart showed more intense retention signal 18h after cell injection in the TE patients [64]. Another study could illustrate homing of bone marrow mononuclear cells TE injection after acute myocardial infarction. Cell retention was successfully visualized in the damaged heart tissue [65]. Similar results were obtained by a group showing homing of bone marrow progenitor cells after intracoronary transfer using the same radiotracer [66]. Controversially, further experiments investigating the homing of the same cells after myocardial infarction indicated very heterogeneous uptake of the  $^{99\text{m}}\text{Tc}$ -labeled



**Figure 5.** Underlying principle of SPECT: (1) A radioisotope decays by emitting gamma rays. (2) A rotating gamma-sensitive detector with a collimator in front indicates the scintillation site where gamma rays are parallel to the collimator pinholes. (3) The collected data is then transferred to photomultipliers and finally to a computer for analysis.

cells, but for all patients there was lack of or decreased uptake of cells in walls with perfusion defects. The perfusion imaging was performed with thallium ( $^{201}\text{Tl}$ ) [67]. Although the safety of autologous stem cell transplantation to the heart after infarction has been shown, it is still not known how many of these cells actually remain in the damaged site, or in near proximity to it. To address their homing and apoptotic rate, autologous bone marrow cells were labeled with [ $^{111}\text{In}$ ]oxine and injected *via* intracoronary route. SPECT imaging was performed 24h after the transplantation and showed homogenous tracer accumulation in liver and spleen, while uptake in the heart was focal. Up to 10% of the injected cells were retained in the myocardium [68]. Similar results regarding cell retention were obtained by [ $^{18}\text{F}$ ]FDG labeling of the cells and detection by PET [69]. Further insights in this field were obtained from a trial using  $^{111}\text{In}$ -oxine-labelled pro-angiogenic cells after intracoronary injection in patients at different time points after myocardial infarction. SPECT imaging was utilized to monitor the cell retention, showing highest values in patients with recent onset of the disease, progressively decreasing in patients treated in an intermediate phase or at chronic stage [70]. The substantial amount of radioactivity in the myocardium suggests correct homing of these cells. Nevertheless, most of the injected cells still remain locked in other locations. One possibility for cell homing improvement might be by significantly reducing their entrapment in filter organs.

Further investigations were made to detect angiogenesis after myocardial infarction utilizing SPECT. This was assessed using a novel radiolabelled peptide ( $^{99\text{m}}\text{Tc}$ ]NC100692, Maraciclatide), which has high affinity to an angiogenesis-related integrin ( $\alpha_v\beta_3$ ) [71] (Figure 6). The successful implementation of this tracer led to a follow-up study, addressing the effect of bone marrow stem cells transplantation on angiogenesis in chronic ischaemic heart failure patients [72]. The patients underwent SPECT imaging using the same [ $^{99\text{m}}\text{Tc}$ ]RGD imaging peptide. This new imaging tracer was shown to be feasible in patients with heart failure. However, the changes with stem cell therapy did not reach statistical significance.



**Figure 6.** Illustration of localized angiogenesis-tracer uptake (Maracilatide:top) in a region of perfusion deficit (MIBI: bottom). A: short axis slice; B: long axis slice. Figure was provided by courtesy of Prof. Brian Hutton.

Despite the immense progress in the field of stem cell imaging research, the pre-labeling approach for cell visualization remains challenging for now. Most of the stem cell clinical trials tend to utilize techniques for following the regenerative process (e.g. tissue growth, vascularization and functional recovery), rather than direct tracking of the injected cells [73]. The use of autologous stem cell therapy for heart regeneration is of high importance for cardiomyopathy patients and is showing promising results. However, the therapeutic effect is by now mostly measured by an enhancement of the heart regional and global contractility as a cell treatment outcome [73]. One other factor, often taken into consideration when testing a new approach for cardio-regeneration, is the heart perfusion efficacy. This could be measured by *i.v.* injection of [ $^{99m}\text{Tc}$ ]sestamibi at rest, followed by an induction of pharmacologic stress by *i.v.* adenosine application. Successful SPECT imaging at rest and post stress suggested a trend towards improvement in cell-treated patients [74]. These non-invasive approaches are able to effectively show the outcome of the therapy. Still, they do not answer the questions regarding proper homing, or viability of the injected cells.

Another possibility to assess the regeneration process is by using direct labeling of certain proteins, known to be connected to basic organ functions. This method was performed to estimate the liver self-regeneration after hepatectomy via  $^{99m}\text{Tc}$ -labeled galactosyl-human-serum-albumin. The liver uptake value could be calculated from SPECT/CT images of patients at different time points after surgery [75]. An additional visualization possibility for the hepatic function was shown by [ $^{99m}\text{Tc}$ ]phytate colloid uptake by the liver. As colloid uptake by

perfused Kupffer cells is proportional to perfused hepatocyte mass, this could be used for direct quantification of perfused liver mass by quantitative SPECT in cirrhotic patients [76]. Although the liver is well-known for its self-regeneration capacity, stem cell therapy seems to boost this capacity. Several studies addressed the therapeutic effect of autologous stem cells for liver regeneration [77-79]. Nevertheless, none of them assessed the fate of these cells *in vivo*. Recently, the proper homing of injected autologous mesenchymal stem cells in the liver of patients with advanced cirrhosis could be illustrated, as these cells have previously been shown to have beneficial effect. The cells were labeled with [<sup>111</sup>In]oxine before intravenous infusion and could be detected by SPECT/CT up to 10 days after application. Shortly after injection, accumulation of signal was observed in the lungs, and gradually shifted to the liver and spleen during the following hours to days [80]. Using SPECT for evaluation of stem cell homing seems a feasible technique. However, the safety, exact mechanism of action and timing of cell delivery have to be further estimated. There is need for more essential information about the long-term benefit of stem cell therapies. Critical for the future success of SPECT is the design of new and specific tracers for the detection, localization, and staging of a disease and for monitoring of the regeneration process. In the past few decades, there is an increase in the awareness of the importance of this imaging modality, its significant impact on diagnosis and management of various diseases and successful visualization of potential treatments.

## 5. Conclusions and future directions

There is no perfect imaging modality for non-invasive cell tracking in clinics. The research findings of the last few decades on the arena of imaging have prompted an intense interest of many investors, who facilitated the translation of these ideas into clinics. Nevertheless, to date no state-of-the-art imaging tool is capable of delivering an all-in-one solution. Many factors have to be considered before choosing the proper visualization modality, depending on the question to be addressed. There is emerging need for versatile imaging methods capable of monitoring the autologous stem cells *in vivo*. Although developments in the field of non-invasive visualization add significant costs and have to overcome many regulatory roadblocks, it is the only way of translating the research into clinical treatments and to support future medicine by providing new tailored treatments to patients.

Despite the immense progress in the field of personalized medicine, there are still many black boxes, on which non-invasive imaging is beginning to shed light. One can observe an increased awareness of the importance of these imaging modalities and their significant impact on diagnosis and management of human disorders are being recognized. Brilliant ideas and developments in this field are catalyzing the design of new strategies every day, giving rise to possible solutions. A summary of the characteristics of the “perfect clinical imaging modality” for stem cell tracking is given in Table 2. Nevertheless, such an all-in-one technique is not available yet, but the development of hybrid imaging devices for multimodal imaging was a big step towards the ideal system.



- |   |
|---|
| 1. Safe, non-toxic and biocompatible                                      |
| 2. Single-cell detection at any anatomic location                         |
| 3. Limitless depth of penetration   |
| 4. High spatial and temporal resolution, excellent molecular sensitivity  |
| 5. No genetic modifications of the stem cells                             |
| 6. Insignificant/no dilution with cell division                           |
| 7. Possible quantification of cell number and viability                   |
| 8. Serial and long term monitoring in patients up to several months/years |
| 9. Insignificant/no uptake of tracer by non-target cells                  |
| 10. Multimodality-based approach  |
| 11. Low costs   |

**Table 2.** Requirements for the design of the “perfect clinical imaging modality” for stem cell tracking

The techniques of SPECT/CT, PET/CT and PET/MRI are the state-of-the-art modalities for successful biomedical molecular imaging. Various diseases related to metabolism, apoptosis, tumors, genetics, and stem cells have been identified by these systems [62]. The same approaches are already being successfully transferred in numerous clinical studies using autologous stem cells for organ and tissue restoration. Nevertheless, the selection of a given visualization technique depends on its strengths and weaknesses with respect to the intended use. All currently developed molecular imaging techniques for stem cell tracking have inherent limitations. For imaging of delivery and short-term homing of the injected stem cells in different organs, a direct labelling approach may be the answer (iron oxide or [ $^{18}\text{F}$ ]FDG), even though any potential toxicity must be taken into account. MRI offers the highest spatial resolution and near real-time image guidance for cell delivery, although with significantly lower molecular sensitivity than other modalities, such as PET or SPECT. For long-term cell monitoring, reporter gene imaging, using PET or SPECT, appears to be a better choice. Ultimately, finding the most suitable system or combination of systems for proper diagnosis and/or treatment remains the essence of health care and personalized medicine.

## Acknowledgements

The authors would like to thank Arch. Teofana Haralampieva for the great support in the visualization of the different imaging modalities and Damina Balmer for her editorial assistance in the preparation of this manuscript. A special thank you goes to the team members of the Laboratory for Urologic Tissue Engineering and Stem Cell Therapy at USZ.

## Author details

Deana G. Haralampieva<sup>1,2,3\*</sup>, Simon M. Ametamey<sup>2,3</sup>, Tullio Sulser<sup>1</sup> and Daniel Eberli<sup>1,3</sup>

\*Address all correspondence to: [deana.haralampieva@usz.ch](mailto:deana.haralampieva@usz.ch)

1 Laboratory for Tissue Engineering and Stem Cell Therapy, Division of Urology, University Hospital, Zurich, Switzerland

2 Institute of Pharmaceutical Sciences, ETHZ, Zurich, Switzerland

3 Zurich Center for Integrative Human Physiology (ZIHP), Switzerland

## References

- [1] Piscaglia AC. Stem cells, a two-edged sword: risks and potentials of regenerative medicine. *World J Gastroenterol.* 2008 Jul 21;14(27):4273-9.
- [2] Health USNIo. [www.clinicaltrials.gov](http://www.clinicaltrials.gov) [accessed 5 Mai 2014].
- [3] Kraitchman DL, Bulte JW. Imaging of stem cells using MRI. *Basic research in cardiology.* 2008 Mar;103(2):105-13.
- [4] Srinivas M, Aarntzen EH, Bulte JW, Oyen WJ, Heerschap A, de Vries IJ, et al. Imaging of cellular therapies. *Adv Drug Deliv Rev.* 2010 Aug 30;62(11):1080-93.
- [5] Ametamey SM, Honer M, Schubiger PA. Molecular imaging with PET. *Chem Rev.* 2008 May;108(5):1501-16.
- [6] Dominiotto M, Rudin M. Could magnetic resonance provide histology? *Front Genet.* 2014 Jan 13;4:298.
- [7] Collins SA, Hiraoka K, Inagaki A, Kasahara N, Tangney M. PET imaging for gene & cell therapy. *Curr Gene Ther.* 2012 Feb 1;12(1):20-32.
- [8] Sutton EJ, Henning TD, Pichler BJ, Bremer C, Daldrup-Link HE. Cell tracking with optical imaging. *Eur Radiol.* 2008 Oct;18(10):2021-32.
- [9] James ML, Gambhir SS. A molecular imaging primer: modalities, imaging agents, and applications. *Physiological reviews.* 2012 Apr;92(2):897-965.
- [10] Rinck PA. Magnetic Resonance Imaging – How It All Began <http://www.rinckside.org/Rinckside%20Columns/1990%20MRI%20How%20it%20all%20began.htm2003> [accessed 10 June 2014].
- [11] Nuclear Magnetic Resonance [21 July 2014]. Available from: <http://www.imaios.com/de/e-Courses/e-MRI/NMR>.

- [12] SWISS Multicenter Intracoronary Stem Cells Study in Acute Myocardial Infarction (SWISS-AMI) [Internet]. [cited 10 June 2014]. Available from: <https://clinicaltrials.gov/ct2/show/NCT00355186?term=MRI+stem+cells&rank=2>.
- [13] 19F Hot Spot MRI of Human Adipose-derived Stem Cells for Breast Reconstruction (CS-1000) [Internet]. [cited 10 June 2014]. Available from: <https://clinicaltrials.gov/ct2/show/NCT02035085?term=MRI+stem+cells&rank=5>.
- [14] Evaluation of Autologous Mesenchymal Stem Cell Transplantation (Effects and Side Effects) in Multiple Sclerosis [Internet]. [cited 15 July 2014]. Available from: <http://clinicaltrials.gov/ct2/show/NCT01377870?term=stem+cells+MRI&rank=47>.
- [15] Safety and Efficacy Study of Autologous Bone Marrow Mesenchymal Stem Cells in Multiple Sclerosis [Internet]. [cited 15 July 2014]. Available from: <http://clinicaltrials.gov/ct2/show/NCT01895439?term=stem+cells+MRI&cond=%22Multiple+Sclerosis%22&rank=8>.
- [16] Treatment of Knee Osteoarthritis by Intra-articular Injection of Bone Marrow Mesenchymal Stem Cells [Internet]. [cited 10 July 2014]. Available from: <http://clinicaltrials.gov/ct2/show/NCT02123368?term=stem+cells+MRI&rank=13>.
- [17] Jo CH, Lee YG, Shin WH, Kim H, Chai JW, Jeong EC, et al. Intra-articular injection of mesenchymal stem cells for the treatment of osteoarthritis of the knee: a proof-of-concept clinical trial. *Stem Cells*. 2014 May;32(5):1254-66.
- [18] Safety and Effect of Adipose Tissue Derived Mesenchymal Stem Cell Implantation in Patients With Spinal Cord Injury [Internet]. [cited 18 July 2014]. Available from: [http://clinicaltrials.gov/ct2/show/NCT01769872?term=stem+cells+MRI&no\\_unk=Y&rank=118](http://clinicaltrials.gov/ct2/show/NCT01769872?term=stem+cells+MRI&no_unk=Y&rank=118).
- [19] Safety and Efficacy of Autologous Bone Marrow Stem Cells in Treating Spinal Cord Injury (ABMST-SCI) [Internet]. [cited 17 July 2014]. Available from: [http://clinicaltrials.gov/ct2/show/NCT01186679?term=stem+cells+MRI&no\\_unk=Y&rank=95](http://clinicaltrials.gov/ct2/show/NCT01186679?term=stem+cells+MRI&no_unk=Y&rank=95).
- [20] Park JH, Kim DY, Sung IY, Choi GH, Jeon MH, Kim KK, et al. Long-term results of spinal cord injury therapy using mesenchymal stem cells derived from bone marrow in humans. *Neurosurgery*. 2012 May;70(5):1238-47; discussion 47.
- [21] Guenoun J, Ruggiero A, Doeswijk G, Janssens RC, Koning GA, Kotek G, et al. In vivo quantitative assessment of cell viability of gadolinium or iron-labeled cells using MRI and bioluminescence imaging. *Contrast media & molecular imaging*. 2013 Mar-Apr;8(2):165-74.
- [22] Modo M, Mellodew K, Cash D, Fraser SE, Meade TJ, Price J, et al. Mapping transplanted stem cell migration after a stroke: a serial, in vivo magnetic resonance imaging study. *NeuroImage*. 2004 Jan;21(1):311-7.

- [23] GUERBET Press releases: FDA approves Dotarem [29 July 2014]. Available from: <http://www.imaios.com/de/Technical-Exhibition/Vendors/GUERBET/Press-releases/FDA-Approves-Dotarem-R>.
- [24] Varnas K, Varrone A, Farde L. Modeling of PET data in CNS drug discovery and development. *Journal of pharmacokinetics and pharmacodynamics*. 2013 Jun;40(3):267-79.
- [25] Phelps ME, Hoffman EJ, Mullani NA, Ter-Pogossian MM. Application of annihilation coincidence detection to transaxial reconstruction tomography. *J Nucl Med*. 1975 Mar;16(3):210-24.
- [26] Hill DL, Batchelor PG, Holden M, Hawkes DJ. Medical image registration. *Phys Med Biol*. 2001 Mar;46(3):R1-45.
- [27] Segers VF, Lee RT. Stem-cell therapy for cardiac disease. *Nature*. 2008 Feb 21;451(7181):937-42.
- [28] Zhang Y, Ruel M, Beanlands RS, deKemp RA, Suuronen EJ, DaSilva JN. Tracking stem cell therapy in the myocardium: applications of positron emission tomography. *Curr Pharm Des*. 2008;14(36):3835-53.
- [29] Doyle B, Kemp BJ, Chareonthaitawee P, Reed C, Schmeckpeper J, Sorajja P, et al. Dynamic tracking during intracoronary injection of 18F-FDG-labeled progenitor cell therapy for acute myocardial infarction. *J Nucl Med*. 2007 Oct;48(10):1708-14.
- [30] Ahmad N, Welch I, Grange R, Hadway J, Dhanvantari S, Hill D, et al. Use of imaging biomarkers to assess perfusion and glucose metabolism in the skeletal muscle of dystrophic mice. *BMC Musculoskelet Disord*. 2011;12:127.
- [31] Goncalves MD, Alavi A, Torigian DA. FDG-PET/CT assessment of differential chemotherapy effects upon skeletal muscle metabolism in patients with melanoma. *Annals of nuclear medicine*. 2014 May;28(4):386-92.
- [32] Colombo A, Castellani M, Piccaluga E, Pusineri E, Palatresi S, Longari V, et al. Myocardial blood flow and infarct size after CD133+cell injection in large myocardial infarction with good recanalization and poor reperfusion: results from a randomized controlled trial. *Journal of cardiovascular medicine*. 2011 Apr;12(4):239-48.
- [33] Yang JJ, Liu ZQ, Zhang JM, Wang HB, Hu SY, Liu JF, et al. Real-time tracking of adipose tissue-derived stem cells with injectable scaffolds in the infarcted heart. *Heart Vessels*. 2013 May;28(3):385-96.
- [34] Chen IY, Wu JC. Molecular imaging: the key to advancing cardiac stem cell therapy. *Trends Cardiovasc Med*. 2013 Aug;23(6):201-10.
- [35] Schwaiger M, Bengel FM. From thallium scan to molecular imaging. *Mol Imaging Biol*. 2002 Nov;4(6):387-98.

- [36] Pei Z, Lan X, Cheng Z, Qin C, Wang P, He Y, et al. A multimodality reporter gene for monitoring transplanted stem cells. *Nuclear medicine and biology*. 2012 Aug;39(6): 813-20.
- [37] Roelants V, Labar D, de Meester C, Havaux X, Tabilio A, Gambhir SS, et al. Comparison between adenoviral and retroviral vectors for the transduction of the thymidine kinase PET reporter gene in rat mesenchymal stem cells. *J Nucl Med*. 2008 Nov; 49(11):1836-44.
- [38] Gyongyosi M, Blanco J, Marian T, Tron L, Petnehazy O, Petrasi Z, et al. Serial noninvasive in vivo positron emission tomographic tracking of percutaneously intramyocardially injected autologous porcine mesenchymal stem cells modified for transgene reporter gene expression. *Circ Cardiovasc Imaging*. 2008 Sep;1(2):94-103.
- [39] Willmann JK, Paulmurugan R, Rodriguez-Porcel M, Stein W, Brinton TJ, Connolly AJ, et al. Imaging gene expression in human mesenchymal stem cells: from small to large animals. *Radiology*. 2009 Jul;252(1):117-27.
- [40] Zhang WY, Ebert AD, Narula J, Wu JC. Imaging cardiac stem cell therapy: translations to human clinical studies. *J Cardiovasc Transl Res*. 2011 Aug;4(4):514-22.
- [41] Schoder H, Erdi YE, Larson SM, Yeung HW. PET/CT: a new imaging technology in nuclear medicine. *Eur J Nucl Med Mol Imaging*. 2003 Oct;30(10):1419-37.
- [42] Krause BJ, Schwarzenbock S, Souvatzoglou M. FDG PET and PET/CT. *Recent Results Cancer Res*. 2013;187:351-69.
- [43] Chiotellis A, Mu L, Muller A, Selivanova SV, Keller C, Schibli R, et al. Synthesis and biological evaluation of (1)(8)F-labeled fluoropropyl tryptophan analogs as potential PET probes for tumor imaging. *European journal of medicinal chemistry*. 2013 Dec; 70:768-80.
- [44] Campanile C, Arlt MJ, Kramer SD, Honer M, Gvozdenovic A, Brennecke P, et al. Characterization of different osteosarcoma phenotypes by PET imaging in preclinical animal models. *J Nucl Med*. 2013 Aug;54(8):1362-8.
- [45] Bone Reconstruction of the Skull Using a Metal Ceramic Implant After Previously Failed Reconstruction [Internet]. [cited 16 June 2014]. Available from: <http://clinicaltrials.gov/ct2/show/NCT01899807?term=PET±regeneration&rank=2>.
- [46] Garcia-Orta R, Mahia-Casado P, Gomez de Diego JJ, Barba-Cosials J, Rodriguez-Palmares JF, Aguade-Bruix S, et al. Update on Cardiac Imaging Techniques 2013. *Rev Esp Cardiol*. 2014 Jan 3.
- [47] Mignone JL, Kreutziger KL, Paige SL, Murry CE. Cardiogenesis from human embryonic stem cells. *Circulation journal : official journal of the Japanese Circulation Society*. 2010 Nov;74(12):2517-26.

- [48] Schuster MD, Kocher AA, Seki T, Martens TP, Xiang G, Homma S, et al. Myocardial neovascularization by bone marrow angioblasts results in cardiomyocyte regeneration. *Am J Physiol Heart Circ Physiol*. 2004 Aug;287(2):H525-32.
- [49] Li Z, Lee A, Huang M, Chun H, Chung J, Chu P, et al. Imaging survival and function of transplanted cardiac resident stem cells. *J Am Coll Cardiol*. 2009 Apr 7;53(14):1229-40.
- [50] Gong Z, Niklason LE. Use of human mesenchymal stem cells as alternative source of smooth muscle cells in vessel engineering. *Methods Mol Biol*. 2011;698:279-94.
- [51] Reiman EM, Jagust WJ. Brain imaging in the study of Alzheimer's disease. *Neuro-Image*. 2012 Jun;61(2):505-16.
- [52] Varrone A, Halldin C. New developments of dopaminergic imaging in Parkinson's disease. *Q J Nucl Med Mol Imaging*. 2012 Feb;56(1):68-82.
- [53] Song F, Tian M, Zhang H. Molecular imaging in stem cell therapy for spinal cord injury. *BioMed research international*. 2014;2014:759514.
- [54] Bai JZ LZ, Ding WM, Xu GH, Shen L, Wang F, Tian JH. Tracking neural progenitor cells transplanted into rabbit spinal cord by detection of dopamine receptor 2 with positron emission computed tomography. *Zhonghua Yi Xue Za Zhi*. 2006;86(29):2060-4.
- [55] clinical trials. [cited 12 June 2014]. Available from: <https://clinicaltrials.gov/ct2/results?term=PET+CNS+>.
- [56] von Schulthess GK, Kuhn FP, Kaufmann P, Veit-Haibach P. Clinical positron emission tomography/magnetic resonance imaging applications. *Semin Nucl Med*. 2013 Jan;43(1):3-10.
- [57] Herzog H. PET/MRI: challenges, solutions and perspectives. *Zeitschrift fur medizinische Physik*. 2012 Dec;22(4):281-98.
- [58] Schlemmer HP, Pichler BJ, Schmand M, Burbar Z, Michel C, Ladebeck R, et al. Simultaneous MR/PET imaging of the human brain: feasibility study. *Radiology*. 2008 Sep;248(3):1028-35.
- [59] Herzog H, Langen KJ, Weirich C, Rota Kops E, Kaffanke J, Tellmann L, et al. High resolution BrainPET combined with simultaneous MRI. *Nuklearmedizin*. 2011;50(2):74-82.
- [60] Pace L, Nicolai E, Luongo A, Aiello M, Catalano OA, Soricelli A, et al. Comparison of whole-body PET/CT and PET/MRI in breast cancer patients: lesion detection and quantitation of 18F-deoxyglucose uptake in lesions and in normal organ tissues. *Eur J Radiol*. 2014 Feb;83(2):289-96.
- [61] History of Nuclear Medicine [Internet]. [cited 20 July 2014]. Available from: <http://www.news-medical.net/health/History-of-Nuclear-Medicine.aspx>.

- [62] Saha GB. *Fundamentals of Nuclear Pharmacy*. 6th ed: Springer; 2010.
- [63] Muller C, Schibli R. Single photon emission computed tomography tracer. *Recent Results Cancer Res*. 2013;187:65-105.
- [64] Vrtovec B, Poglajen G, Lezaic L, Sever M, Socan A, Domanovic D, et al. Comparison of transendocardial and intracoronary CD34+cell transplantation in patients with nonischemic dilated cardiomyopathy. *Circulation*. 2013 Sep 10;128(11 Suppl 1):S42-9.
- [65] Silva SA, Sousa AL, Haddad AF, Azevedo JC, Soares VE, Peixoto CM, et al. Autologous bone-marrow mononuclear cell transplantation after acute myocardial infarction: comparison of two delivery techniques. *Cell Transplant*. 2009;18(3):343-52.
- [66] Goussetis E, Manginas A, Koutelou M, Peristeri I, Theodosaki M, Kollaros N, et al. Intracoronary infusion of CD133+and CD133-CD34+selected autologous bone marrow progenitor cells in patients with chronic ischemic cardiomyopathy: cell isolation, adherence to the infarcted area, and body distribution. *Stem Cells*. 2006 Oct;24(10):2279-83.
- [67] Barbosa da Fonseca LM, Xavier SS, Rosado de Castro PH, Lima RS, Gutfilen B, Goldenberg RC, et al. Biodistribution of bone marrow mononuclear cells in chronic chagasic cardiomyopathy after intracoronary injection. *International journal of cardiology*. 2011 Jun 16;149(3):310-4.
- [68] Kurpisz M, Czepczynski R, Grygielska B, Majewski M, Fiszer D, Jerzykowska O, et al. Bone marrow stem cell imaging after intracoronary administration. *International journal of cardiology*. 2007 Oct 1;121(2):194-5.
- [69] Hofmann M, Wollert KC, Meyer GP, Menke A, Arseniev L, Hertenstein B, et al. Monitoring of bone marrow cell homing into the infarcted human myocardium. *Circulation*. 2005 May 3;111(17):2198-202.
- [70] Schachinger V, Aicher A, Dobert N, Rover R, Diener J, Fichtlscherer S, et al. Pilot trial on determinants of progenitor cell recruitment to the infarcted human myocardium. *Circulation*. 2008 Sep 30;118(14):1425-32.
- [71] Verjans J, Wolters S, Laufer W, Schellings M, Lax M, Lovhaug D, et al. Early molecular imaging of interstitial changes in patients after myocardial infarction: comparison with delayed contrast-enhanced magnetic resonance imaging. *Journal of nuclear cardiology : official publication of the American Society of Nuclear Cardiology*. 2010 Dec;17(6):1065-72.
- [72] Mozid AM, Holstenson M, Choudhury T, Ben-Haim S, Allie R, Martin J, et al. Clinical feasibility study to detect angiogenesis following bone marrow stem cell transplantation in chronic ischaemic heart failure. *Nucl Med Commun*. 2014 Aug;35(8):839-48.
- [73] Dimmeler S, Zeiher AM. Cell therapy of acute myocardial infarction: open questions. *Cardiology*. 2009;113(3):155-60.

- [74] Perin EC, Silva GV, Henry TD, Cabreira-Hansen MG, Moore WH, Coulter SA, et al. A randomized study of transendocardial injection of autologous bone marrow mononuclear cells and cell function analysis in ischemic heart failure (FOCUS-HF). *American heart journal*. 2011 Jun;161(6):1078-87 e3.
- [75] Yoshida M, Shiraishi S, Sakamoto F, Beppu T, Utsunomiya D, Okabe H, et al. Assessment of hepatic functional regeneration after hepatectomy using Tc-GSA SPECT/CT fused imaging. *Annals of nuclear medicine*. 2014 Jul 8.
- [76] Zuckerman E, Slobodin G, Sabo E, Yeshurun D, Naschitz JE, Groshar D. Quantitative liver-spleen scan using single photon emission computerized tomography (SPECT) for assessment of hepatic function in cirrhotic patients. *Journal of hepatology*. 2003 Sep;39(3):326-32.
- [77] Mohamadnejad M, Namiri M, Bagheri M, Hashemi SM, Ghanaati H, Zare Mehrjardi N, et al. Phase 1 human trial of autologous bone marrow-hematopoietic stem cell transplantation in patients with decompensated cirrhosis. *World J Gastroenterol*. 2007 Jun 28;13(24):3359-63.
- [78] Levicar N, Pai M, Habib NA, Tait P, Jiao LR, Marley SB, et al. Long-term clinical results of autologous infusion of mobilized adult bone marrow derived CD34+cells in patients with chronic liver disease. *Cell Prolif*. 2008 Feb;41 Suppl 1:115-25.
- [79] Pan XN, Shen JK, Zhuang YP, Chen XL, Li YX, Chen LJ, et al. [Autologous bone marrow stem cell transplantation for treatment terminal liver diseases]. *Nan fang yi ke da xue xue bao=Journal of Southern Medical University*. 2008 Jul;28(7):1207-9.
- [80] Gholamrezanezhad A, Mirpour S, Bagheri M, Mohamadnejad M, Alimoghaddam K, Abdolazadeh L, et al. In vivo tracking of <sup>111</sup>In-oxine labeled mesenchymal stem cells following infusion in patients with advanced cirrhosis. *Nuclear medicine and biology*. 2011 Oct;38(7):961-7.



