

We are IntechOpen, the world's leading publisher of Open Access books Built by scientists, for scientists

4,800

Open access books available

122,000

International authors and editors

135M

Downloads

Our authors are among the

154

Countries delivered to

TOP 1%

most cited scientists

12.2%

Contributors from top 500 universities



WEB OF SCIENCE™

Selection of our books indexed in the Book Citation Index
in Web of Science™ Core Collection (BKCI)

Interested in publishing with us?
Contact book.department@intechopen.com

Numbers displayed above are based on latest data collected.
For more information visit www.intechopen.com



Overview of Local Anesthesia Techniques

Mohammad Ali Ghavimi, Yosef Kananizadeh,
Saied Hajizadeh and Arezoo Ghoreishizadeh

Additional information is available at the end of the chapter

<http://dx.doi.org/10.5772/59214>

1. Introduction

Down through centuries, efforts have been made to use local anesthesia for treatments. In the ancient times, the Assyrians applied pressure over the carotid artery in order to obtain a certain degree of anesthesia, explaining why this artery is called “the artery of sleep” in the Greek literature. In 1532, the Indians of Peru chewed the leaves of coca shrubs to relieve fatigue and hunger and to produce a feeling of exhilaration. A chemical with some anesthetic property was first introduced in the nineteenth century. A German chemist in 1859, however, reported the anesthetic properties of the coca leaf. In 1859, cocaine was first extracted in its pure form by Albert Neimann, a German chemist. In the mid-1860s, Sir Benjamin Ward Richardson introduced the effect of ether spray for skin anesthesia. Around the same time the adverse effects of cocaine on the mood and psyche were demonstrated. As known today, side effects of cocaine include cardiac stimulation, peripheral vasoconstriction, excitation of the central nervous system (CNS) and addiction. In 1943, lidocaine-the first amide local anesthetic was introduced with greater potency, more rapid onset and less allergenicity as compared to the previously introduced esters.

Pain control in dentistry presents one of the greatest challenges. Pain leads to increased stress, release of endogenous catecholamines and unexpected cardiovascular responses. Before anesthetization, dentists should evaluate the medical history of each patient and document data on the systemic and psychological status of the patients in order to determine whether the patient is able to tolerate the treatment with no risk from the systemic and psychological points of views. Before the injection of the local anesthetic, the dentist should recognize the potential risks. However, most adverse reactions to local anesthetics are not related to the drug itself, but to the injection of the drug. The injection of the local anesthesia is the most reported cause for fear and discomfort of dental patients. Vasodepressor syncope and hyperventilation

syndrome are the most common reactions. Others include tonic-clonic spasm, bronchospasm and angina pectoris. Continual research in the field of pain control is still being done in the quest for novel techniques and safer drugs. [1-4].

2. Anatomy

Management of pain in dentistry requires knowledge about the fifth cranial nerve anatomy—the trigeminal nerve. It is the largest of the cranial nerves and has three major divisions: ophthalmic, maxillary and mandibular.

The trigeminal nerve is the major sensory nerve of the face containing both motor fibers for masticatory muscles and sensory fibers. This nerve exits the brain through the area between the pons and the middle cerebellar peduncles.

The ophthalmic branch runs through the lateral wall of the cavernous sinus and, through the superior orbital fissure, enters the orbit, branching again to provide sensation of the lacrimal apparatus, cornea, iris, forehead, ethmoid and frontal sinuses and the nose. The ophthalmic nerve –V1– is the smallest of the three divisions, dividing in to three main branches: the nasociliary, frontal and lacrimal nerves (Figure 1).

The maxillary branch is the second branch of the trigeminal nerve – V2 – passes horizontally forward, through the lateral wall of the cavernous sinus, exiting the cranium through the rotundum foramen which is located in the greater wing of the sphenoid bone. Once outside the cranium, this nerve crosses between the pterygoid plates of the sphenoid bone and the palatine bone. As the maxillary nerve crosses the pterygopalatine fossa, it gives off branches to the posterior–superior alveolar nerve, the sphenopalatine ganglion and the zygomatic region. Branches of this nerve continue through the inferior orbital fissure and infraorbital foramen, providing sensation of the maxillary sinuses, upper jaw, sides of the nose and the cheek (Figure 2). [5, 6]

The branches of the maxillary nerve are given off in four regions:

1. **Cranium**
2. **Pterygopalatine fossa**
3. **Infraorbital canal**
4. **Face**

The branch entering the cranium –the middle meningeal nerve– travels with the middle meningeal artery to provide sensory innervation of the dura mater.

Several branches are given off in the pterygopalatine fossa namely the zygomatic nerve, the pterygopalatine nerve and the posterior superior alveolar nerve.

The greater palatine nerve descends through the pterygopalatine canal and through the greater palatine canal emerges on the hard palate, coursing anteriorly between the osseous

hard palate and the mucoperiosteum supplying sensory innervation to the bone and palatal soft tissues as far anterior as the first premolar.

The lesser palatine nerve travels along with the posterior palatine nerve emerging from the lesser palatine foramen.

The posterior superior alveolar nerve (PSA) branches from the main trunk of the maxillary division into the pterygopalatine fossa just before the maxillary division enters the infraorbital canal.

The maxillary division (V2) gives off two significant branches namely the anterior superior (ASA) and middle superior (MSA) alveolar nerves.

The ASA nerve – given off from the infraorbital nerve – descends within the anterior wall of the maxillary sinus, providing pulpal innervation of the central and lateral incisors, canine and the sensory innervation of periodontal tissues, buccal bone and the mucous membrane of the gums.

The MSA nerve provides sensory innervation of maxillary premolars and, perhaps, the mesiobuccal root of the first molar, periodontal tissues, buccal soft tissues and the bone and gums in the premolar region.

Branches of the face: through the infraorbital foramen, the infraorbital nerve emerges into the face dividing into its terminal branches: the inferior palpebral, external nasal and superior labial.

The mandibular branch (V3) is considered a motor-sensory nerve innervating masticatory muscles, lower jaw and teeth, parotid and sublingual gland, two third of the tongue and the ear canal and exits the skull through the ovale foramen. The mandibular division: The mandibular division – the largest branch of the trigeminal nerve – descends between the medial ramus and the medial pterygoid muscle, entering the mandible through the mandibular foramen (Figure 2.).

The inferior alveolar nerve has the largest diameter of 2.4 ± 0.4 mm at the lingula.

The anterior division of the V3 branch provides sensory innervation of the cheek, mucous membrane in the buccal of the mandibular molars and motor innervation of the masticatory muscles.

The buccal nerve, passing through the two heads of the lateral pterygoid, reaches the external surface of the lateral pterygoid muscle, continuing in an anterolateral direction.

The auriculotemporal nerve passes through the upper part of the parotid gland crossing the posterior portion of the zygomatic arch.

The lingual nerve travels downward and medial to the lateral pterygoid muscle, lying between the ramus and the medial pterygoid muscle in the pterygomandibular space as it descends. The sensory tract of the anterior two-third of the tongue, the mucous membrane of the mouth floor and mandibular lingual gingiva is provided by the lingual nerve.

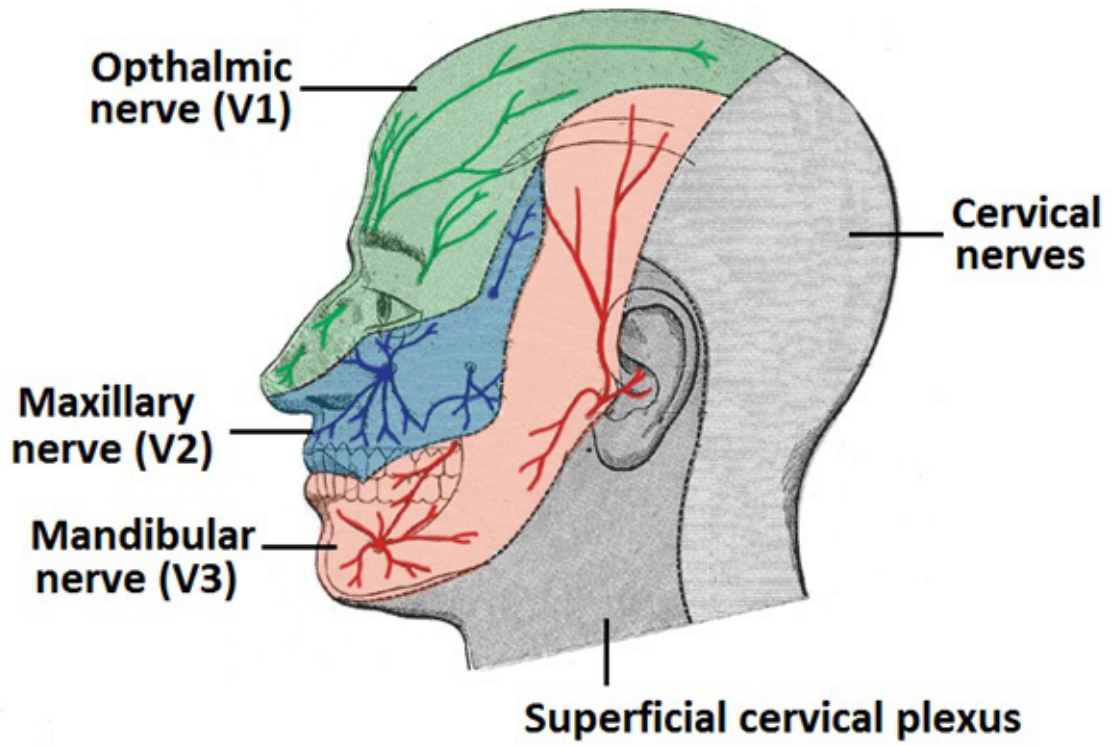


Figure 1. The superficial branches of the trigeminal nerve

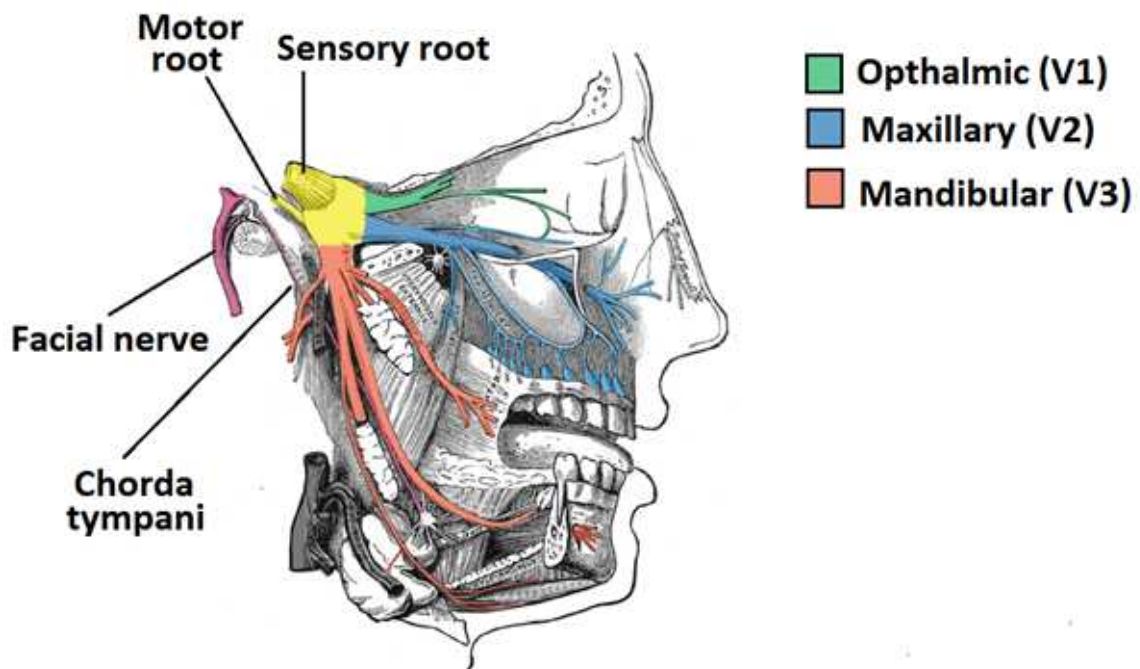


Figure 2. Branches of the trigeminal nerve

The mylohyoid nerve branches off the inferior alveolar nerve just before the entrance of the inferior alveolar nerve into the mandibular canal. This is a mixed nerve providing sensory innervation of the mandibular incisors, and portions of mandibular molars in some. It also provides the motor innervation of the anterior belly of the digastrics and the mylohyoid muscle.

At the mental foramen, the inferior alveolar nerve branches into its terminal branches-- the incisive and the mental nerves:

The incisive nerve, remaining within the mandibular canal, forms a nerve plexus innervating the pulpal tissues of the mandibular first premolar, canine and incisors via the dental branches.

The mental nerve innervates the skin of the chin and the mucous membrane of the lower lip. [1-6]

3. Mandibular anesthesia

There is a great variety of techniques for anesthetizing different regions of the mandible, the most common and useful ones are described in this section.

3.1. Inferior alveolar nerve block

The inferior alveolar nerve block (IANB) is one of the most important and commonly used techniques in dentistry. Unfortunately it is also the most frustrating with the highest percentage of failure even when properly administered [1]. The IANB anesthetizes the IAN (a branch of mandibular division of the trigeminal), incisive nerve, mental nerve and commonly (but not always) the lingual nerve of the injected side. This block effects the sensation of all the teeth on one side of mandible, the bone from the inferior portion of ramus to the midline, the lingual soft tissue and periosteum of the mandible, buccal soft tissues anterior to the mental foramen and anterior two thirds of the tongue and floor of the oral cavity [2].

In one technique, the patient is positioned supine (recommended) or semi-supine. The thumb of the free hand is placed on the coronoid notch retracting the soft tissues. The insertion point of the needle is about 6 to 10 mm above the occlusal plane and at the 3/4 of the anterior posterior distance from the coronoid notch to the pterygomandibular raphe (visual in the oral cavity). The syringe is advanced from across the lower premolar teeth of the opposite side. A long dental needle is used; the bone must be touched while advancing about 25mm of the 35 mm needle into the tissue. After contacting bone the needle is withdrawn slightly, aspiration performed and if negative in two directions 1.5 to 1.8 ml of solution is deposited over a minimum of 60 seconds (Figure 3).. [1]

Two problems occur very commonly with this technique [7]:

1. Contacting the bone too soon: to solve this problem the needle is withdrawn halfway, still remaining in the soft tissue, then the barrel of the syringe is swung over the mandibular

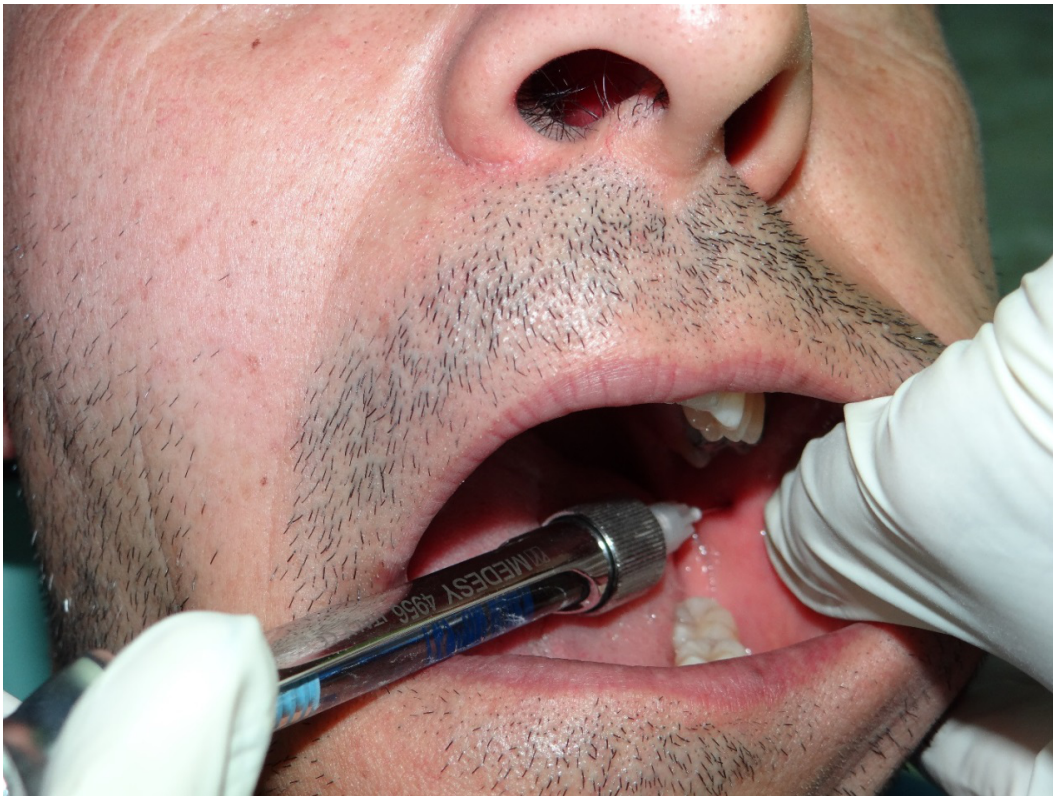

Figure 3. The Inferior Alveolar Nerve Block

teeth of the side being anesthetized, then the needle is advanced about 2.5 mm and the solution is deposited. This is a modification of IANB (the indirect technique) [8].

2. The bone is not contacted after 30 mm of needle insertion: the needle should be withdrawn halfway back then the barrel of the syringe is swung over the molar teeth of the opposite side being anesthetized, and then advanced to touch the bone and then continued as described. When the bone is not touched the solution should not be deposited because the needle could be in the parotid gland near the facial nerve and an injection there could lead to transient paralysis of the facial nerve [1].

One of the most common causes of failure of IANB is depositing the solution too low (below the mandibular foramen) in this case it can be corrected by re-injecting at a higher site, approximately 5 to 10 mm above the previous site.

Mylohyoid nerve is the most common nerve which provides mandible teeth with accessory sensory innervation (most commonly the mesial portion of mandibular first molar). A supplemental injection at the apical region of the tooth in question on the lingual side will solve the problem [9].

Incomplete anesthesia of the central and lateral incisors is due to overlapping fibers of the contralateral inferior alveolar nerve. In this case a supplemental injection with infiltration technique or PDL injection should be done [1].

Olsen reported that in children the mandibular foramen is situated at a level lower than the occlusal plane [10]. Therefore in pediatric patients the injection must be made slightly lower and more posteriorly than for an adult patient.

3.2. Vazirani-Akinosi (closed mouth) mandibular block

Dr. Joseph Akinosi described a close-mouth approach in 1977 [11]. This technique became a successful alternative for inferior alveolar and Gow-Gates mandibular nerve blocks. In 1960 a very similar technique was described by Vazirani, therefore the term "Vazirani-Akinosi" is used for the approach. It is also known as "Close-mouth mandibular nerve block" and "Tuberosity approach". Although this technique can be used whenever mandibular anesthesia is desired, its primary indication is in situations where the patient has a limited mouth opening range such as patients with trismus or when spasm of the masticatory muscles on one side of the mandible occur due to several unsuccessful attempts to anesthetize it with IANB, the Vazirani-Akinosi anesthesia approach provides successful anesthesia and a motor blockade (of V3 division of trigeminal nerve) to relieve trismus if it is produced secondary to muscle spasm.

In 1992, Wolfe described a modification of the Vazirani-Akinosi technique, in which the needle is bent at a 45 degree angle to adapt better with the lingual aspect of the ramus. But due to the increase risk of needle breakage this technique cannot be recommended [12]. If the Vazirani-Akinosi technique administered successfully anesthesia of inferior alveolar, incisive, mental, buccal, lingual and mylohyoid nerves is obtained.

For administration of this technique a 25 or 27 gage needle is used. The patient should be positioned supine or semisupine. The index finger or thumb is placed on the coronoid notch reflecting the tissue on the medial side of the ramus laterally. The patient is asked to occlude gently with cheeks and muscles of masticatory relaxed. The syringe is held parallel to the maxillary occlusal plane, with the needle at the mucogingival junction of maxillary third molar (or second molar). The bevel of the needle should be held toward the bone. The needle is inserted to the soft tissue overlying the medial border of the mandible ramus at the point described, and is advanced 25mm (for an average-sized adult) posteriorly and slightly laterally. After negative aspiration in two planes the anesthesia solution can be deposited. Motor nerve paralysis is the first sign to occur so a patient with trismus will notice increased ability to open the jaw. After 1 to 1.5 minute anesthesia of the lip and tongue is noted, and the dental procedure usually can start within 5 minutes.

It is shown in studies that the Vazirani-Akinosi technique has the same success rate of conventional IANB. But with fewer complications and a lower aspiration rate (<10%) [1].

3.3. Gow-Gates mandibular nerve block

In 1973, George Albert Edwards Gow-Gates described a new approach to mandibular anesthesia which he had experience with and reported a success rate of 99% [13]. In this technique the anesthesia solution is deposited on the medial side of the condylar neck just below the insertion of the lateral pterygoid muscles and truly anesthetizes the entire distribu-

tion of V3, including the inferior alveolar, lingual, mylohyoid, mental, incisive, auriculotemporal and buccal nerves (in 75% of patients). The Gow-gates technique has a higher success rate and a lower incidence of positive aspiration in comparison to IANB.

In this technique the patient is positioned supine or semisupine and is asked to open his mouth widely, then the syringe, fitted with a long needle, is introduced into the mouth through the corner of the mouth on the opposite side. Insertion point is distal to the second molar and in a height of the mesiopalatal cusp of the second molar. The needle is inserted into the tissue and aligned with the plane extending from the corner of the mouth on the opposite side to the intertragus notch on the side of injection, then advanced about 25mm (two third of the needle) until the bone is touched. Then it is withdrawn about 1mm and after negative aspiration in two directions about 1.8 ml of the solution is deposited. If the bone is not contacted, either the patient has partially closed his mouth or the needle is deflected medially (most common cause). In this situation ask the patient to hold his mouth completely open and after withdrawing the needle half way realign the needle anteriorly by swinging the barrel of the syringe somewhat more distally and then advance the needle to contact the bone and continue the process of anesthesia [1, 9](Figure 4).

Due to greater diameter of the mandibular nerve it may require a larger volume of the anesthesia solution, so if the depth of the anesthesia is inadequate after the first injection deposit up to 1.8 ml in the second injection [9].

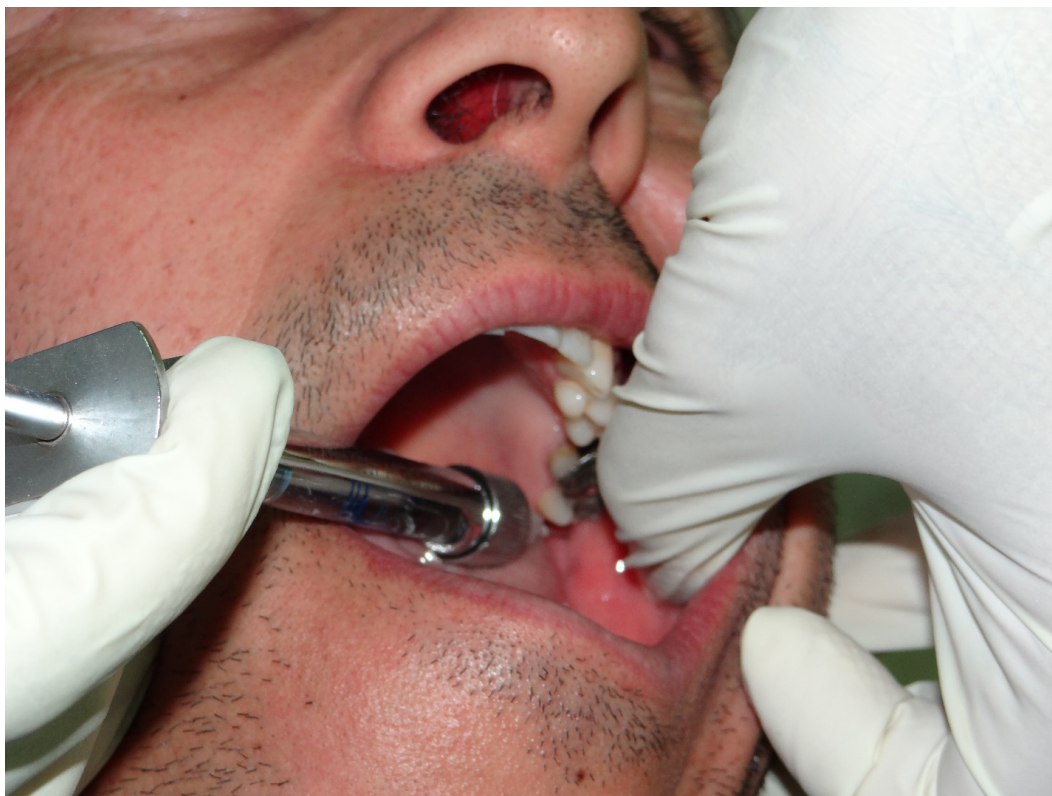

Figure 4. The Gow-Gates technique

3.4. Buccal nerve block

The buccal nerve provides sensory innervation to the buccal gingiva, mucosa and part of the cheek in mandibular molar region. This nerve is consequently not anesthetized during IANB, so if required this nerve must be separately anesthetized. Because the buccal nerve lies immediately beneath the mucous membrane it can be anesthetized easily by depositing about 0.5ml of solution at the coronoid notch (the area distal and buccal to the last molar in the arch). And this nerve block has a success rate of approximately 100% [9].

3.5. Mental and incisive nerve block

The mental nerve and incisive nerve are the terminal branches of the inferior alveolar nerve and provide sensory innervation to the buccal soft tissues lying anterior to the foramen and the soft tissues of the lower lip and chin and those teeth located anterior to the foramen (premolar, canine and incisors) on the injection side. To administer this technique the mental foramen should be located with finger palpation near the apex of the second premolar. The bone immediately around the foramen is rougher to the touch and the patient might feel some soreness when you press your finger against the mental nerve. The needle bevel should be directed toward the bone and the mucosa is penetrated near the mucobuccal fold and the needle is advanced until it reaches the mental foramen, then about 0.6 ml of solution (one third of a cartridge) is deposited. After injection the tissue should be massaged to facilitate entry of the solution into the mental foramen. In the early literature it was emphasized to enter the foramen for a successful nerve block but now it has been shown that this action is completely unnecessary and only increases the risk of damaging the nerve or vessels of the area. Bilateral mental block is very useful when procedures are to be done on anterior or premolar teeth on both sides. [1]

4. Maxillary anesthesia techniques

Different regional blocks and infiltration injections can be used for anesthetizing the maxilla. Some are described herein.

4.1. Supraperiosteal injection (infiltration)

This is the most common technique used for obtaining pulpal anesthesia and is more commonly known as local infiltration. In this technique the patient is asked to partially open his mouth and the syringe is held parallel to the long axis of the tooth. The needle is inserted in the mucobuccal fold above the apex of the tooth and advanced until it touches the bone then withdrawn a little and the solution is deposited at a rate of 30 s/ml (Figure 5). If the solution is deposited while the needle touches the bone the solution is injected below the periosteum which is more painful and may cause post injection discomfort.

This is a very easy technique and has a high success rate but when several teeth require anesthesia or there is an infection or acute inflammation in the area of the injection regional

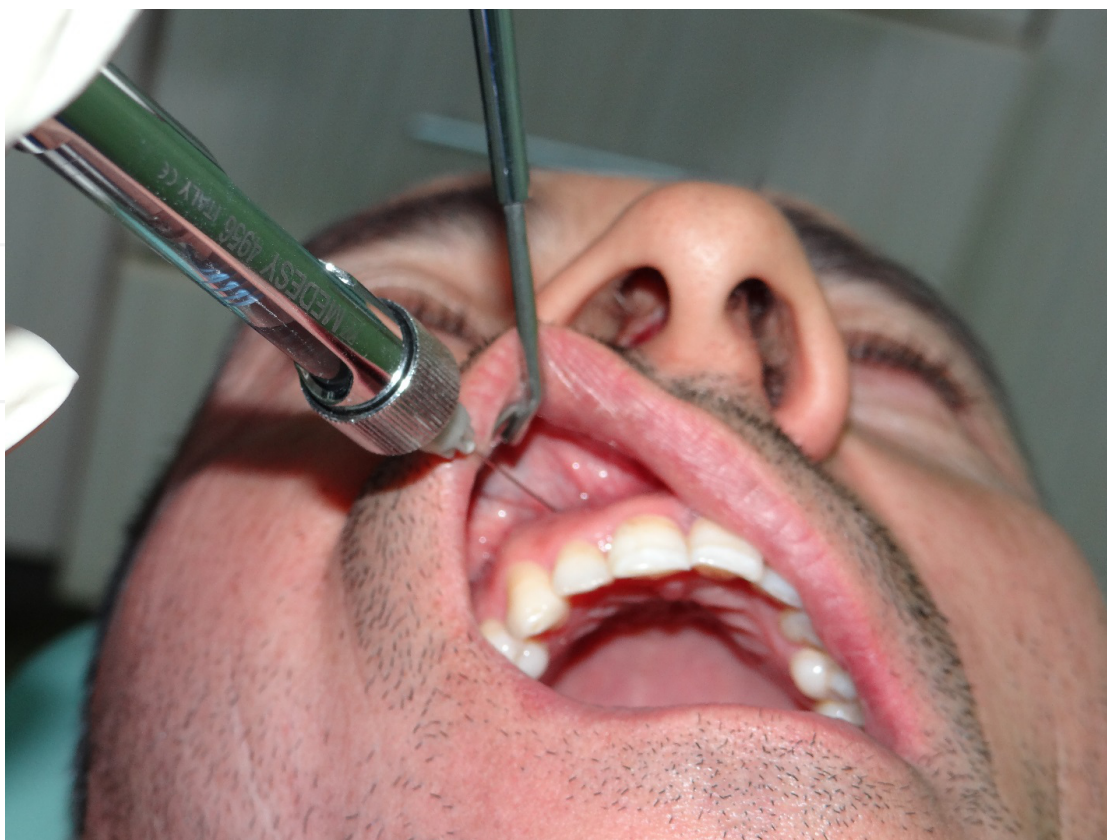

Figure 5. The infiltration technique

nerve blocks are preferred. In pediatric patients infiltration technique can also be used for anesthetizing mandibular primary teeth and in several studies it has been shown that in these patients infiltration technique has a comparable effectiveness to mandibular nerve block for dental procedures [14].

4.2. Maxillary nerve block

The Maxillary (v2) nerve block is an effective method for achieving anesthesia of the hemimaxilla. With a single injection you can anesthetize all maxillary teeth of one side, buccal periodontium and bone overlying these teeth, soft tissue and bone of hard palate and part of the soft palate, skin of the lower eyelid, side of nose, cheek and upper lip. This nerve can be blocked through several approaches:

4.3. High-Tuberosity approach

The patient is positioned supine or semisupine and the patient's mouth partially open, the mandible is pulled toward the side of the injection and the soft tissues are retracted with the index finger. Then injection is done into the mucobuccal fold distal to the second molar at an angle of 45 degrees; next the needle is advanced posteriorly, superiorly and medially about 30mm and the solution is deposited [9].

4.4. Greater foramen approach

In this approach we attend to insert the needle to the pterygopalatine fissure through the greater palatine foramen and affect the maxillary nerve as it passes through the fossa. We ask the patient to hold his mouth wide open. Palpate the greater palatine foramen medial to the distal aspect of the second molar. Insert the needle at an angle of 45 degree superiorly and distally to the foramen. After advancement about 30mm we deposit the anesthesia solution. This technique is painful and may be dangerous is rarely needed if ever and thus, is not recommended.

4.5. Posterior superior alveolar nerve block

By blocking the posterior superior alveolar (PSA) nerve the molar teeth of maxilla, the associated bone and buccal gingiva will be anesthetized. It is shown that only in 28% of patients the middle superior alveolar nerve provides the mesiobuccal root of the first molar with sensory innervation, in this situation an extra injection (usually infiltration) is necessary to anesthetize the accessory innervations.

To block the PSA, we partially open the patient's mouth and pull the mandible to the side of injection. A short needle is used to prevent distal insertion of the needle which can produce a temporary (10 to 14 days) hematoma. The needle is inserted into the mucobuccal fold over the second molar and advanced about 16mm upwards, inwards and backwards. Then, the anesthesia solution is slowly deposited (Figure 6). [1]

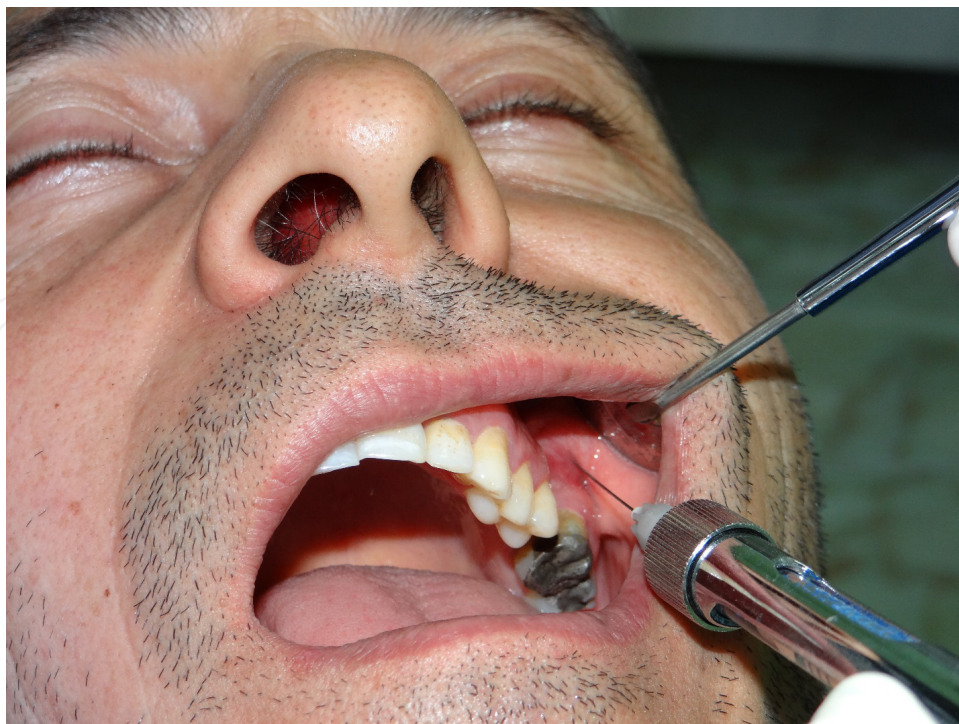

Figure 6. The PSA nerve block

In pediatric patients with primary or early mixed dentition, the thick bone of zygomatic process lies over the buccal roots of the second primary and first permanent molars, attenuating the effectiveness of infiltration injection in this region. So in this situations a PSA nerve block may be used instead [15].

4.6. Middle superior alveolar nerve block

As mentioned before the MSA exist only in 28% of people and provides sensory innervation to maxillary premolars and mesiobuccal root of the first molar. The MSA block is performed by delivering a buccal infiltration at the apex of the second premolar tooth.

4.7. Anterior superior alveolar nerve block

The Anterior Superior Alveolar nerve (ASA) supplies the maxillary incisors and canine teeth on one side and the soft and hard tissue adjacent to it. On the other hand the infraorbital nerve provides sensory innervation to the mucosa and skin surface of one half of the upper lip and part of the skin on lateral aspect of the nose; but because these two nerves can be anesthetized with one approach, the technique is either known as “ASA block” or “Infraorbital nerve block”.

To perform this technique we locate the infraorbital foramen; to do so the infraorbital notch is palpated with the index finger then moved downward from the notch, the bone immediately inferior to the notch is convex, which is the roof of the infraorbital foramen, as we continue inferiorly a concavity is felt, this is the infraorbital foramen. When we press against it the patient senses a mild soreness. After the foramen is located we retract the lip and cheek of the patient, a syringe with a long needle is inserted into the mucobuccal fold at the apex of the first premolar. The syringe is held parallel to the long axis of the tooth and is advanced till it reaches near the foramen. The average depth of insertion into the tissue is 16mm (half of the length of a long needle) for an adult of average height. When the needle is in the target area, slowly deposit 0.9 to 1.2ml of the solution. You would be able to “feel” the anesthesia solution as it is deposited beneath the finger on the foramen. Maintain firm pressure with your finger over the injection site for 1 or 2 more minutes to increase the diffusion of the solution into the infraorbital foramen. For decreasing the pain on insertion of the needle and tearing of the periosteum insert the needle with an angled position (away from the bone) and solution is deposit while the needle is advanced through soft tissue [1].It is in no way necessary to enter the foramen.

4.8. Greater palatine nerve block

It is possible to anesthetize palatine tissue by palatal infiltration technique at any place needed but by performing a greater palatine nerve block the posterior portion of the hard palate and the overlying soft tissue anteriorly as far as the first premolar on one side will be anesthetized. The foramen creates a depression in the palate usually distal to the maxillary second molar, which can be located by palpating the area. Deposition of 0.5ml of anesthesia solution in the region of the greater palatine foramen will block the nerve [9].

A very rare complication is ischemia and necrosis of soft tissue of the injection region and it only happens when highly concentrated vasoconstrictor solution is used for hemostasis over a prolonged period [1]. It is in no way necessary to enter the foramen.

4.9. Nasopalatine nerve block

This block anesthetizes the anterior portion of the hard palate (soft and hard tissue) bilaterally mesial to the first premolars. The technique can be performed by depositing 0.2 to 0.5 ml of anesthetic solution adjacent to the incisive papilla. Because the soft tissue in this area is dense, firmly adherent to underlying bone, and quite sensitive the injection in this area is very painful, so several methods are suggested to decrease the pain. One is anesthetizing the dental papilla between centrals labially and inserting the needle through it to the palatal side near the foramen and depositing a little solution to partially anesthetize the soft tissue overlying the nasopalatine nerve before the main injection [1].

4.10. Anterior middle superior alveolar nerve block

This is a relatively new technique, first demonstrated by Friedman and Hochman during development of a computer-controlled local anesthetic delivery (C-CLAD) system [16, 17]. This technique relies on the slow delivery and penetration of anesthetic solution through the porous cortical bone and the nutrient canals.

About 1.4 to 1.8ml of solution (one cartridge) should be deposited very slowly (0.5ml per minute) into the tissue halfway between the palatal midline and the premolar palatal gingival margin. This method is best performed with a C-CLAD. This method blocks the ASA and MSA so it anesthetizes the palate and the teeth anterior to the first molar and adjacent buccal attached gingiva. In studies the AMSA block is shown as effective as multiple maxillary infiltrations [18].

4.11. Palatal anterior superior alveolar nerve block

This method like the AMSA block relies on slow delivery of anesthetic solution via a C-CLAD system and was defined by Friedman and Hochman in the mid 1990s [8, 17, 19]. In this approach 1.4 to 1.8ml of solution is deposited in the incisive canal at a rate of 0.5 ml per minute. This block anesthetizes the pulp of the incisors and canine bilaterally, facial periodontal tissue associated with these same teeth and anterior hard palate. You should keep in mind that also the injection with a C-CLAD system is not painful but it will take about 3 or 4 minutes which some patients may be reluctant to tolerate.

5. Supplemental anesthesia techniques

These techniques include intraosseous, intrapulpal, intraseptal and intraligamentary methods.

- 1. Intraosseous technique:** This is done through a special tool such as X-TIP. The advantages of this method are rapid onset (less than 30 seconds), mild side effects, without the

numbness of the lips and tongue and an atraumatic technique. Contraindications for this method are infection and severe inflammation at the injection area. In this technique, first, a point is recorded distal to the teeth in 2 mm apical to confluence of two lines consisting of a horizontal line from the gingival margin and a vertical line from the interdental papillae. The perforation of the soft tissue and bone is done at this point and the anesthetic drug is injected into the cancellous bone. In this method, depending on the number of teeth $\frac{1}{4}$ to 1 cartridge is used for the anesthesia. Vasoconstrictors should not be used except where required. The duration of pulpal anesthesia in this technique will be from 15 to 30 minutes [1]. Sixon's study in 2008 revealed the effectiveness of this technique as a primary technique. For a total of 181 children and adults, 225 intraosseous injections were done with 4% articaine. The success of this technique was reported to be 95% for primary teeth and 87.9% for permanent teeth and it was shown that the use of this technique could be an appropriate alternative method to classic infiltration anesthetic techniques in children and adults [20]. Wood compared intraosseous and infiltration anesthetic techniques for changes in heart rate and serum concentrations of the drug in 2005. For both techniques lidocaine 2% with epinephrine 1/100000 was used. Pulse oximetry was used to assess heart rate and blood samples were taken to check the amount of lidocaine in the serum. Results showed significant changes in HR for intraosseous compared to the infiltration technique but in the evaluation of lidocaine in serum, no significant difference was found between the two methods [21].

2. **Intraligamentary technique:** Advantages include minimal anesthetic drug requirements, rapid onset and the lack of tongue and lip numbness. This technique can be used as an adjunct method after a nerve block. Contraindications include infection and primary teeth (due to possible damage to permanent teeth). In this technique, a 27 gauge short needle with its long axis parallel to the tooth is inserted at the mesial or distal of the dental root. If the injection is not possible in the mesial or distal surfaces because of tight proximal contacts, it should be applied into the buccal and lingual surfaces parallel with the long axis of the tooth. The infusion rate must be 0.2 ml over 20 seconds. The duration of anesthesia produced by this method is between 5 to 55 minutes [1]. In a 2005 study on 54 patients in whom IAN block did not provided appropriate anesthesia for treatment, it was found that PDL injection provided successful anesthesia in 56% of patients (30 patients) showed this to be a reliable method [22]. A modified technique is recommended for PDL injection with a needle angle of 30 degrees relative to the longitudinal axis of the tooth and the entrance point in the mesiobuccal and distobuccal area; which is a time-tested method (Figure 7) [23].
3. **Intraseptal technique:** This method is indicated when there is a need for pain control and hemostasis of soft and hard tissue simultaneously. Infection in the injection area is a contraindication for this technique. The benefits are similar to the previous techniques. The short duration of pulpal anesthesia and the requirement of the numerous tissue punctures are in the context of its disadvantages. In this technique, a short 27-gauge needle is inserted into the center of the interdental papilla. The entrance point is 2 mm below the tip of the papilla and the direction of the needle will be towards the apex of the tooth. The

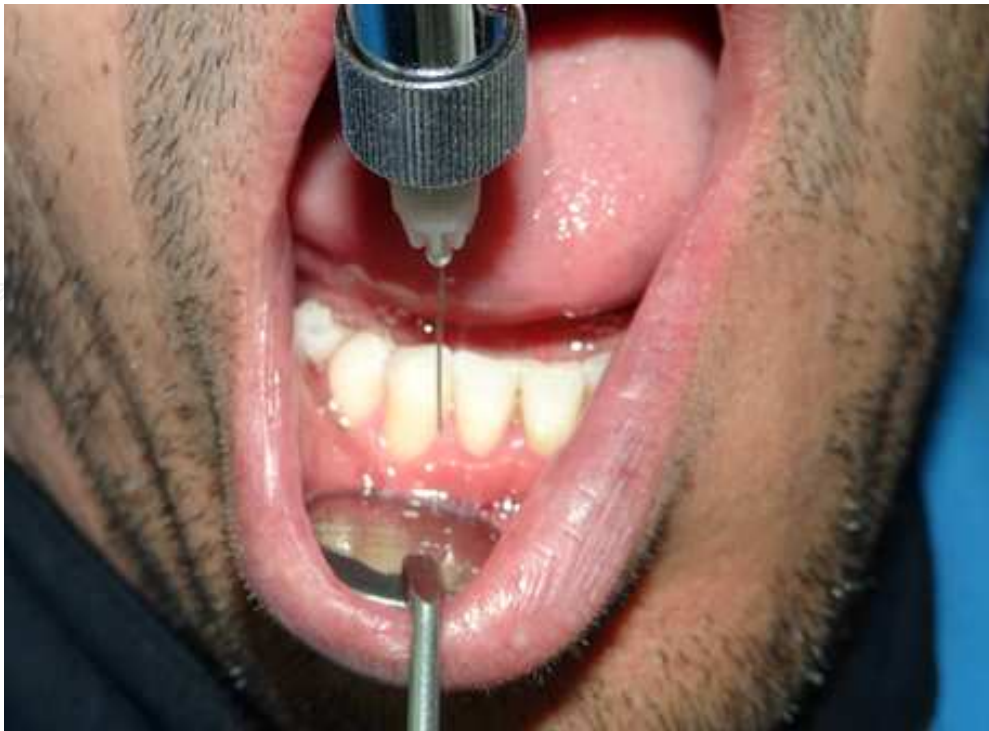

Figure 7. Intraligamentary (PDL) technique

angle of the needle in the frontal plane must be 45 degrees relative to the long axis of the tooth. Then 0.2 to 0.4 ml is injected [1] (Figure 8). This technique can be used for anesthesia in the posterior mandible with dense bone and is comparable to the inferior alveolar nerve block injection [24].

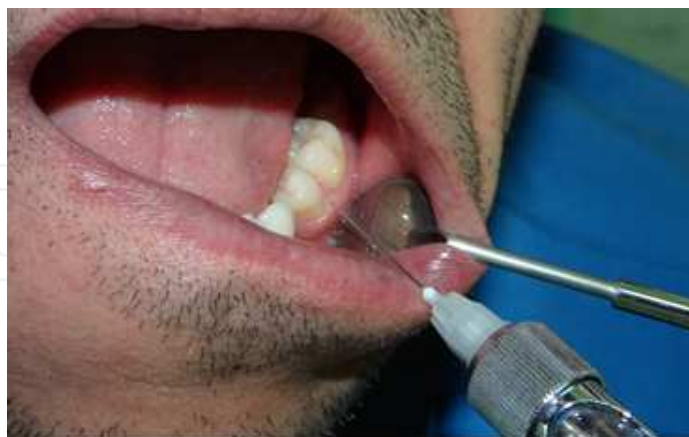

Figure 8. Intraseptal technique

- 4. Intrapulpal technique:** In the absence of adequate anesthesia methods, this method can be used for the endodontic treatment of teeth. The benefits consist of fast onset, mild side effects and the lack of lip and tongue numbness. A major disadvantage is that it requires

exposure of the pulp which limits the ability to use this method only in endodontic therapy [1] or in the course of removal of impacted teeth.

5. **Mandibular infiltration technique:** This has a high success rate in children with primary teeth but its success is reduced when children grow and the teeth change from primary to mixed dentition and mandibular cortical thickness increases. Studies have shown that this technique is more successfully with articaine 4% rather than lidocaine 2% but the mechanism is yet unknown. One theory suggests that there is a thiophene loop in articaine that provides greater penetration compared to lidocaine, which has a benzene loop [25].
6. **Topical anesthesia:** The use of topical anesthesia in dentistry or the treatment of laceration is very useful especially in children. The skin needs a larger amount of drugs for topical anesthesia because of less blood supply than mucosa. Due to the poor solubility in water and thus reducing the systemic absorption, benzocaine is the drug of choice for use on mucosal surfaces. Benzocaine Ointment (20%) is used for this purpose. The onset time is 2 to 3 minutes and the duration of anesthesia is 15 minutes. Lidocaine 5% is another common drug in this category with a similar onset and duration of anesthesia to benzocaine. Tetracaine is the strongest surface anesthetic drug that has been presented in a cold spray type in combination with 14% Benzocaine. Tetracaine is also used for endoscopic procedures and gag control [1, 2]. Topical anesthesia will not cause a completely painless injection and that depends more on the needle gauge and duration of the injection. Topical anesthesia will be helpful for periodontal examinations and very conservative treatments [27].

6. New local anesthetics

1. **LMX:** This consists of liposomal capsules containing lidocaine. Liposomes increase lidocaine absorption in a controlled pattern and prevent its systemic toxicity. This drug should be given 30 minutes before surgical intervention on the area in the amount of 1 to 2 mg, sufficient for an area of skin measuring 10 square centimeters [2]. In a study in 2002, liposomal capsules of ropivacaine were compared to EMLA for topical anesthesia of the palatal mucosa during needle entrance into the tissues in which EMLA was significantly more successful than encapsulated ropivacaine [28]. Studies have shown that other anesthetic drugs such as bupivacaine provide a greater duration of anesthesia into the liposomal formulation as compared to the normal [29].
2. **EMLA:** This cream is used widely for topical anesthesia to treat laceration and lumbar punctures (Figure 9). This medication contains lidocaine 2.5% and prilocaine 2.5% that penetrate well into tissues due to its micron-sized droplets. Its onset time of action depends on blood supply for the area. On the face it starts to work within 15 minutes. Its maximum depth of anesthesia is 5 mm and can be achieved within 120 minutes. So if more depth is needed we should use the usual anesthetic injection techniques. The amount of 1 to 2 mg of this drug is sufficient for an area of 10 square centimeters of skin and should be placed on the area. At least 1 hour before starting the treatment process. Use of this

medication on the mucosa due to its systemic absorption has not yet been approved [2]. Studies have reported that the analgesic effect of EMLA for periodontal probing and scaling is more than 5% prilocaine ointment. The use of 4 g of EMLA for the creation of analgesia is recommended for the removal of arch bars [30]. The study of Hassio in 1990 showed no difference between 10% lidocaine spray and EMLA for topical anesthesia of the gums. The level of anesthesia at 13-14 minutes measured by EMLA-apparatus was equal in both. The sensitivity of the gums returns to normal within 30 minutes. No toxic reactions were observed but it is said that the absorption of EMLA is faster than lidocaine spray [31].

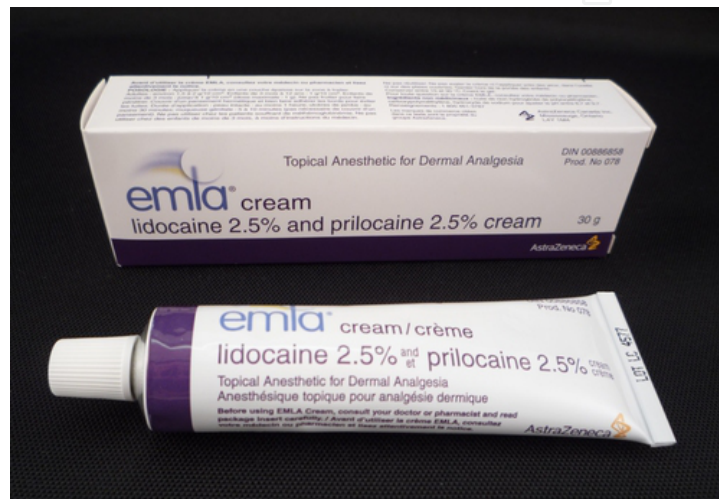

Figure 9. EMLA

- LET:** This drug is a combination of lidocaine 4%, epinephrine 0.1% and tetracaine 5% which is available in two types including methylcellulose gel or an aqueous solution. Often used to repair lacerations in children and because of the presence of epinephrine; this drug should not be used in extremities such as fingers, ears or the nose. LET should be given on the area 20 minutes before the start of the treatment and its duration is 40 minutes [2].
- Microparticulate formulations:** In this formulation, to increase the duration of anesthesia and reduce the side effects, various drugs and combinations are added to the local anesthetic drugs. For example, the addition of dexamethasone to lipid - protein - sugar particles containing bupivacaine caused the doubling of the nerve block time. These techniques can be used for chronic facial pain or to facilitate physiotherapy in muscle dysfunction [2].
- TAC:** TAC is the combination of cocaine 4-11 %, epinephrine 0.025-0.05 % and tetracaine 0.25-0.5 % which begins to work in 10 to 15 minutes and has a duration of 15 to 25 minutes. It can be used to treat children lacerations but has complications such as hypertension, seizures and systemic toxicity [32].

- 6. Drug Combination:** The combination of local anesthetic drugs with systemic analgesic drugs such as morphine can reduce the amount of pain during and after the surgery [33]. In general, the combination of opioid with anesthetic drugs reduces the need for analgesics after surgery and increases the duration of anesthesia but has side effects such as nausea and vomiting. The combination of alpha-2 adrenergic agonists such as clonidine, especially with medium-acting anesthetic medications, increases the potential of these drugs. The drug side effects include bradycardia, hypotension and dryness of the mouth, which of course are caused by doses greater than 2 micrograms per kilogram. Ketamine, midazolam and magnesium can increase the power of anesthetic drugs but they must also be considered for their neurotoxic properties. Symptoms such as hallucination and sedation occur following the use of these drugs [34].

7. New techniques

- 1. Electronic dental anesthesia (EDA):** This technique is based on the TENS (transcutaneous electronic nerve stimulation) and the electronic waves are used to disrupt neural pain transmission to the brain. Research on this technique continues for use in the dental field [1].
- 2. Needle-free injection:** The injection system is based on a piston-pressure system and several systems are introduced such as PED-O-JET, SYRIJET and MED-E-JET. These techniques are widely used for daily injections of insulin in diabetics. In studies, these systems showed less pain compared to conventional injections with a needle gauge of 25 (Figure 10).[1]



Figure 10. SYRIJET needle-free injection.

- 1. Computer controlled injection:** In this technique, computer controls the speed and injection pressure. C-CLADS (computer controlled local anesthetic delivery system) has

less pain and discomfort for patients than conventional syringe injections, but requires greater facilities, more space and higher costs [1].

2. **Ionthophoresis:** This is a new technique for the transdermal administration of lidocaine. In this way, the two external electrodes on the skin are used to make the transition of ionized lidocaine from the stratum corneum layer to the dermis layer to block the nerve ends. Drug penetration rate in this technique is higher than the passive diffusion. The 0.6 to 1 mL of lidocaine 2% with 0 to 4 mA electrical current is used during 10 minutes which causes 5 to 7 mm of drug penetration to the tissue and provides anesthesia [2].
3. **Thermal:** Ice can be used to create a temporary anesthesia for injection or treat small lacerations. For this purpose, the ice should remain on the skin for more than 10 seconds. Ethyl chloride spray as an alternative method can be used for 1-2 seconds, but the duration of anesthesia will be less than caused by ice. These techniques with the saline containing benzyl alcohol are used in hair transplantation [1].
4. **STA system device:** This is an auxiliary system for injection especially made for PDL injections where the dynamic pressure sensory system improves the quality and reduces the side effects of injections. Low-pressure dynamic injection in this technique prevents tissue damage and pain during the injection. In addition, the injected anesthetic drug leakage is detected and prevents creation of an unpleasant taste in the patient's mouth. However, this technique requires the computer system tools [1].
5. **Intranasal local anesthesia:** In the past, the use of nasal mucosa was conventional due to the high blood supply and ability to achieve the systemic effects of drugs. Nowadays for the nasal mucosa and even upper teeth numbness, anesthetic drugs (especially tetracaine) are used on the nasal mucosa. Studies have shown that the use of intranasal tetracaine with a vasoconstrictor such as oxymetazoline can provide tooth anesthesia for the first molar on one side to the first molar on the other side and dental procedures can be performed for the teeth, without need to inject anesthetic drugs [1].
6. **Phentolamine mesylate (Oraverse):** The injectable form of phentolamine (alpha adrenergic receptor antagonist) can be used to terminate drug-induced local anesthesia when it is not required. Especially in high risk populations, where children and the elderly can inadvertently damage the tissues inside the mouth. Soft tissue numbness causes problems with normal functions such as talking, laughing, eating and drinking and can sometimes cause tissue damage. To prevent this situation, a 1.7 mL dental cartridge containing 0.4 mg phentolamine mesylate is used. In this way, the approximate time for the return of normal sensation will be about half. For example, the normal sensation of the tongue will return within 60 minutes with phentolamine mesylate and 125 minutes without it [1].
7. **Electrospun drug-eluting suture:** Contains absorbable sutures with PLGA chemical structures that are combined with bupivacaine. The sutures can slowly release the drug to the surgical site within 12 days and provide appropriate analgesia. Higher concentrations of the anesthetic drug cause a decrease in the suture tensile strength. The suture tissue reaction is comparable to regular PLGA sutures without the combination of anesthetic drugs [35].

8. **Intraoral lidocaine patch (dentipatch):** This patch contains 10-20% lidocaine which is placed on dry mucosa for 15 minutes and provides suitable anesthesia for the mandible and maxilla [36].
9. **Jet-injection:** In this technique, a small amount of anesthetic drug driven into the submucosa without a needle. The air pressure is used for the infiltration of the drug into the mucosa through tiny pores. This method is particularly useful for topical anesthesia for palatal injection [36].
10. **Vibrajet:** It is a device that provides high frequency vibrations in the dental injection syringe which causes a relative decrease in pain during the injection [37].
11. **Accupal:** This is a tool to create pressure and vibration at the injection site. These mentioned irritate the larger nerve fibers and cause the lack of sensitivity during the penetration of the needle [37].
12. **TENS (transcutaneous electronic nerve stimulation):** The result of this method in patient comfort and it provides less pain during the injection. This has been demonstrated especially for IAN nerve block techniques, while topical anesthesia does not cause significant changes to reduce pain during the injection. This technique stimulates the nervous system and it starts before injecting and the pulse rate increases to make a good shake to the patient. The needle is inserted at an area between the electrodes of TENS while generated impulses are continuing at the same level. After withdrawing the injection and removing the needle, pulses are slowly reduced and stopped (Figure 11). [38]




Figure 11. Transcutaneous electronic nerve stimulation

8. Complications

The complications of the injection of local anesthetic drugs can be divided into two parts namely systemic and local complications, explained below.

8.1. Local complications

1. **Pain during injection:** The main reason for this is high-speed injection which can be avoided by injecting each cartridge slowly within a minute. The temperature of the drug also causes pain. The ideal temperature for injection is room temperature. The use of sharp needles, topical anesthesia before injecting and regulating the pH of the drug at 7.4 can help to reduce pain during injection [1].
2. **Trismus:** Its causes include damage to muscles and blood vessels at the infratemporal fossa, damage of the pterygoid muscle, hemorrhage caused by injection and massive volumes of anesthetic drugs. The use of sterile needles, refraining from repeated injections in one area and the use of the minimum effective dose can prevent it. In the case of trismus, it's recommended to use a warm wet towel and physiotherapy for opening the mouth, with the use of anti-inflammatory drugs, analgesics and muscle relaxant drugs such as diazepam. It is important that the patients with continued trismus be referred to a maxillofacial surgeon [1, 2].
3. **Hematoma:** This occurs mostly due to the damage of mental vessels or pterygoid venous plexus. Injections for blocking the inferior alveolar nerve and PSA can cause a large hematoma. The knowledge of the area's anatomy, changes in injection techniques based on patient-specific anatomy and the reduction of frequent needle penetration into the tissues can be helpful in preventing hematoma. Injection for the PSA block is the most common type of anesthetic technique leading to a hematoma. If the hematoma occurs, it is recommended to apply direct pressure on the area, analgesic, anti-inflammatory drugs and placement of ice on the swelling [1]. A study by Bajkin conducted in 2010 showed that there is little risk of hemorrhage and hematoma even in patients taking oral anticoagulant if the correct injection technique is used. Undoubtedly PDL and intraseptal techniques reduce the risk of hematoma more than routine IAN block techniques. Vasoconstrictors and thin needles may help the clinician prevent it [39].
4. **Infection:** This is a very rare complication with contaminated injection needles as the most common cause. The use of sterile needles, disposable cartridges and application of topical antiseptics can be effective in preventing it. Infections have symptoms such as pain and dysfunction. When it occurs, the prescription of antibiotics (penicillin V 500 mg every 6 h for 7-10 days), analgesics, heat, drainage and physiotherapy are recommended for treatment [1, 2].
5. **Breakage of injection needles:** Excessive force during injection, bent needles and unfamiliarity with anatomy are the causes of this rare event. The thin needles (30 gauge) break more often than thicker needles. In case of an accident the patient should be referred immediately to a maxillofacial surgeon. The routes of preventing this in-

clude not using a 30 gauge needle for IAN block injection, not bending the needles, preventing full penetration of the needle into the tissues and precision during injection for young patients or children that can make sudden moves resulting in needle breakage [1]. When the needle breakage occurs during the inferior alveolar nerve block injection, it can often be found in the pterygomandibular space, but can migrate to adjacent vital structures and cause damage to them (Figure 12). An unusual case of broken needle displacement during the IAN block injection into the external auditory canal is reported for a 25-year-old woman [40].

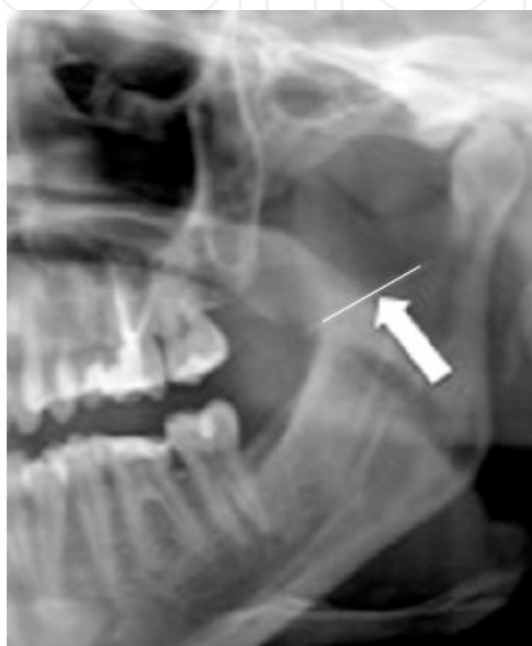

Figure 12. Broken needle shown in the panoramic radiograph

6. **Long-term sensory changes:** This can be due to direct damage to nerves and the contamination of local anesthetic drugs with alcohol that has a neurolytic effect. The most common sensory change is paresthesia. Direct damage is the most common cause of long-term sensory changes, which happens through three mechanisms. Firstly, injury to the nerve fibers. Secondly, the destruction of small vessels in epineurium and the creation of interneural hemorrhage. Finally, the destruction of connective tissue and creation of edema sets in. The dose and concentration of the local anesthetic drugs are contributing factors in this process. According to studies, high concentration drugs such as 4% articaine and prilocaine can cause long-term sensory changes more than other drugs. During injection, the lingual nerve is affected more than other nerves by direct damage. Sensory changes usually resolve within 8 weeks during which the patient should be informed and re-injection of the drug in the affected area should be avoided [2].
7. **Facial nerve paralysis:** Temporary damage to the facial nerve can occur as a result of the spread of local anesthetic drugs to the parotid capsule. Great penetration of the needle in the Akinosi-Vazirani technique or the inappropriate posterior direction of the needle in

the IAN block injection can cause this complication. Prevention is the best cure. When it occurs, inform the patient of the incident, removal of eye lenses and eye protection should be carried out. It must be explained that nerve function will return to normal within a few hours [2].

8. **Soft tissue damage:** After injection, children often bite their lips and cheeks, followed by numbness in these areas (Figure 13). Avoidance of anesthetics with long-term effects, placement of cotton rolls between the teeth and lips, informing the patient to not use warm materials and not bite the oral tissues are effective ways of preventing soft tissue damage. If this happens we need to check for the appropriate use of antibiotics, analgesics and overlying creams on the injury site [1]. In cases of soft tissue injury following numbness, correct diagnosis is very important. Sometimes misdiagnosis causes incorrect treatment such as hospitalization, unnecessary surgical interventions and administration of systemic antibiotics due to improperly suspected bacterial infections. Effective communication between dentists and other medical staffs can help prevent these events [41].

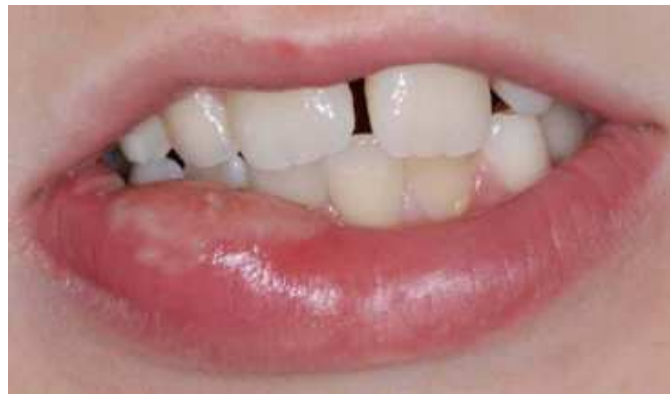

Figure 13. After injection, children often bite their lips and cheeks, because of numbness in these areas.

9. **Burning during the injection:** Burning during injection is a relatively common condition due to low pH and acidity of the local anesthetic with vasoconstrictors, rapid drug injection and contamination of anesthetic drugs with alcohol or sterilizing solutions. To prevent it, the pH of anesthetic drugs should reach 7.4 by buffering the solution before injection. The reduction of injection speed and the maintenance of drugs at room temperature, away from alcohol or sterilizing solution are the other preventing factors. Burning during the injection is transient and does not require specific care [1].
10. **Tissue sloughing:** This occurs due to prolonged use of topical anesthesia drugs or ischemia caused by prolonged use of vasoconstrictor drugs on palatal tissue, of which sterile abscess and epithelial desquamation are symptoms. For prevention, topical anesthetic drugs should only be used for one to two minutes and the use of high concentration vasoconstrictor solutions should be limited. If it occurs, it is not necessary to do anything specific except for pain relief. This condition will resolve spontaneously within 7 to 10 days [1, 2].

11. **Intraoral lesion occurrences after injection:** Recurrent aphthous stomatitis and herpetic lesions originate from this type of lesion that can occur two days after the injection due to the trauma of the needle at the injection site. Treatment will be palliative and the lesions will resolve spontaneously within 7 to 10 days [1].
12. **Eye complications:** Eye complications can occur following the injection of anesthetic drugs in the maxilla and mandible. A permanent loss of vision is reported following a prilocaine injection for tooth extraction in a 73-year-old man prior to surgery for the mitral valve. Visual injury following the injection of anesthetic in dentistry is extremely rare and its mechanism is unknown. A possible etiology is retinal and choroid artery occlusion following the intra-arterial injection which strongly emphasizes the need for aspiration prior to the injection [42]. The next case is a report of paralysis of the right lateral rectus muscle and blurred vision after IAN block and infiltration injections were done in the right maxilla to extract the number 8 tooth in the right mandible and maxilla in a 22-year-old woman who had been normal in terms of systemic health. In this patient, blurred vision and diplopia resolved 6 hours after the injection. The mechanism of this condition is deep anesthetic injections in the retromaxilla, drug diffusion through the greater palatine channel and the lack of the bony barrier between the orbit and this area [43]. In general, the most common ocular complications due to anesthetic injection include: diplopia, mydriasis, eyelids ptosis and abduction disorder and damaged eye. These complications can occur several minutes after the injection and can resolve spontaneously without causing permanent injury and a known mechanism for them is anesthetic drug diffusion to the orbital area [44].
13. **Rare complications:** There are reports of osteonecrosis following the intraosseous injection probably due to the heat of bone drilling done to make a perforation hole for the injection (Figure 14). In addition, systemic disease, such as diabetes and HIV can also have an effect in creating this phenomenon [45].

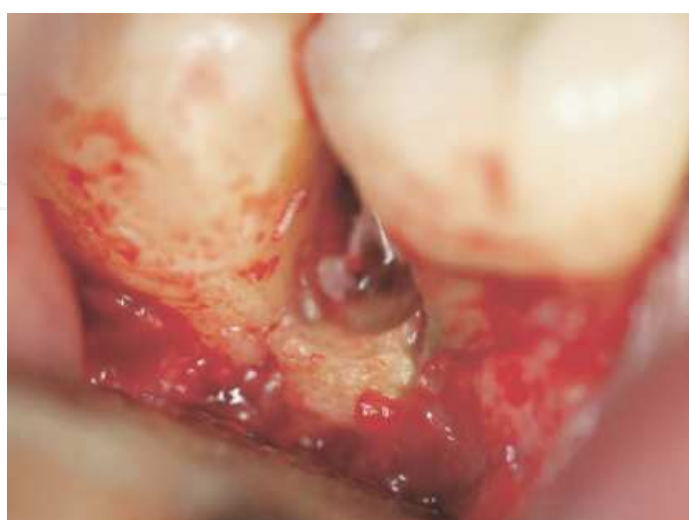

Figure 14. Osteonecrosis following the intraosseous injection

8.2. Systemic complications

- 1. Overdose:** Due to a low dose of local anesthetic drugs in dentistry, its prevalence is low. Early symptoms include muscle twitching, shivering, tremor and tonic-clonic seizures. The next symptom that occurs with increased blood toxicity doses is sedation. Respiratory depression and lethargy and ultimately cardiovascular dysfunction will lead to arrhythmias and bradycardia. Some prognostic factors such as very high and very low ages (because of a lower metabolic rate and increase in the half-life of the drug), patient weight, medications (antidepressant, H2 blocker, anti-dysrhythmia drugs), gender (due to the impairment of renal function the risk of overdose increases during pregnancy) and, genetics (genetic deficiency in serum cholinesterase enzyme) should warn us about the risk of overdose. High drug concentration (> 2%), the absence of vasoconstrictors, high-speed injection and the vascularity of the injection area can increase the risk of overdose. Aspiration in at least two planes before the injection, slow injection, dosage adjustment and review of the patient's age, sex, weight, diseases and medications can prevent or reduce the risk of overdose. If the symptoms of overdose occur, the necessary measures are taken including PABCD protocol (position – airway – breathing – circulation – definitive cure). Definitive cures include oxygen prescription, vital signs monitoring, application of anti-seizure medications such as midazolam and stopping the dental procedure. The overdose of vasoconstrictors (such as epinephrine) can result in a rapid increase in blood pressure (primarily in systolic pressure). Tachycardia and cardiac dysrhythmia which will have symptoms such as tremor, anxiety, dizziness, weakness, fatigue and difficulty in breathing may be seen. Treatment will include PABCD protocol, prescription of oxygen (except in hyperventilation) and monitoring of vital signs [2]. Unfortunately, a large percentage of dentists do not have enough information about how to determine and calculate the dose of anesthetic drugs (87%) and about 53% of them do not aspirate when injecting [46].
- 2. Allergy:** Because of the presence of Para Amino Benzoic Acid (PABA), this occurs more for ester anesthetic drugs. Allergy to an amide local anesthetic drug does not prevent the use of other types of amid anesthetic drugs because the cross-sensitivity to these drugs is not seen. If there is a sensitive reaction to both types of local anesthetic drugs, diphenhydramine solution (0.5 – 1 %) should be used for anesthesia. Allergic reactions include dermatitis, respiratory symptoms (respiratory distress, dyspnea, cyanosis, tachypnea) and generalized anaphylaxis that is a life-threatening condition. Symptoms of anaphylaxis include skin reactions, gastrointestinal smooth muscle spasm (muscle cramps), respiratory distress and cardiovascular collapse. In case of allergies, the PABCD protocol should be implemented. Definitive cure includes prescription of oxygen (5-6 liters per minute), intramuscularly epinephrine in the vastus lateralis with a dose of 0.3 mg for patients weighing more than 30 kg and 0.15 mg for patients weighing less than 30 kg, histamine blocker drugs (50 mg Diphenhydramine or 10 mg Chlorpheniramine), Corticosteroids (100 mg Hydrocortisone) and the cricothyrotomy if needed [2].
- 3. Methemoglobinemia:** It occurs due to the oxidation of the iron atoms in hemoglobin by local anesthetic drugs such as prilocaine that causes a defect in the transportation of

oxygen and leads to cyanotic conditions in patients 1 to 3 hours after the injection of anesthesia. The symptoms of cyanosis are created when levels of methemoglobin reach 10 to 20 percent. Increase of methemoglobin levels causes various symptoms such as dyspnea and tachycardia. Children, with methemoglobin reductase and G6PD enzyme deficiency are at a higher risk than other people to methemoglobinemia. The treatment of methemoglobinemia is the intravenous injection of 1-2 mg/kg methylene blue [1].

4. **Malignant Hyperthermia:** MH is determined by the increase in body temperature, muscle stiffness and increased oxygen consumption. The role of anesthetic drugs in the creation of MH is still controversial. This condition is more common in children than adults [2].
5. **Drug interactions:** There are no absolute contraindications to the use of medicinal drugs together with local anesthesia and vasoconstrictors but sometimes there is a need to reduce or adjust the dose of drugs. The chieftains of these drugs are the blood pressure lowering medications. For example, epinephrine in combination with beta-blocker drugs can greatly increase the systolic blood pressure and calcium channel blockers can cause hyperkalemia related to epinephrine. Also beta-blockers reduce hepatic blood flow and decrease the metabolism of anesthetic drugs leading to their increased toxicity [1, 2].
6. **Hemodynamic alterations:** Following the injection of anesthetic drugs in the presence or absence of vasoconstrictors, diastolic blood pressure increases slightly. In the presence of vasoconstrictors, systolic blood pressure increases more than anesthetic drugs without them. Blood glucose increases by administering anesthetic drugs containing vasoconstrictors [47]. However, changes in blood pressure in the presence of an anesthetic were not significant and do not jeopardize the patient's hemodynamics but studies have shown that if you do not inject anesthetic drugs hypertension will be noticeable during dental treatment [48].

Author details

Mohammad Ali Ghavimi*, Yosef Kananizadeh, Saied Hajizadeh and Arezoo Ghoreishizadeh

*Address all correspondence to: m_ghavimi@yahoo.com

Faculty of Dentistry, Tabriz University of Medical Sciences, Tabriz, Iran

References

- [1] Malamed SF. Handbook of local anesthesia: Elsevier Health Sciences; 2013.
- [2] Fonseca RJ, Frost DE, Hersh EV, Levin LM. Oral and maxillofacial surgery: Saunders Philadelphia, PA; 2009.

- [3] Sisk AL. Evaluation of the Akinosi mandibular block technique in oral surgery. *Journal of maxillofacial surgery*. 1988;44:113-115.
- [4] Shinagma A, Chin VKL, Rabbani SR, Champos AC. A novel approach to Intraoral mandibular nerve anesthesia: changing reference planes in the Gow-Gates block technique. *Journal of maxillofacial surgery*. 2009;68:2609-16.
- [5] Coleman RD, Smith RA. The anatomy of mandibular anesthesia: review and analysis. *Oral surgery*. 1982;54:148-52.
- [6] Fonseca RJ, Walker RV, Barber HD, Power MP, Frost DE. *Oral and maxillofacial trauma*: Saunders Philadelphia, PA; 2013.
- [7] De St Georges J. How dentists are judged by patients. *Dentistry today*. 2004;23(8):96, 8.
- [8] Friedman MJ, Hochman MN. The AMSA injection: A new concept for local anesthesia of maxillary teeth. *Quintessence Int*. 1998;29:297-303.
- [9] Andersson L, Kahnberg K-E, Pogrel MA. *Oral and maxillofacial surgery*: John Wiley & Sons; 2012.
- [10] Olsen NH. Anesthesia for the child patient. *Journal of the American Dental Association* (1939). 1956;53(5):548-55.
- [11] Akinosi J. A new approach to the mandibular nerve block. *British Journal of Oral Surgery*. 1977;15(1):83-7.
- [12] Wolfe S. The Wolfe nerve block: a modified high mandibular nerve block. *Dentistry today*. 1991;11(5):34-7.
- [13] Gow-Gates GA. Mandibular conduction anesthesia: a new technique using extraoral landmarks. *Oral Surgery, Oral Medicine, Oral Pathology*. 1973;36(3):321-8.
- [14] Oulis CJ, Vadiakas G, Vasilopoulou A. The effectiveness of mandibular infiltration compared to mandibular block anesthesia in treating primary molars in children. *Pediatric dentistry*. 1996;18:301-5.
- [15] Dean JA, Avery DR, McDonald RE. *Dentistry for the Child and Adolescent*. St Louis: Mosby Co. 2011:245.
- [16] Friedman M, Hochman M. 21st century computerized injection for local pain control, compend contin. *Educ Dent*. 1997;8:995-1003.
- [17] Lee S, Reader A, Nusstein J, Beck M, Weaver J. Anesthetic efficacy of the anterior middle superior alveolar (AMSA) injection. *Anesthesia progress*. 2004;51(3):80.
- [18] Perry DA, Loomer PM. Maximizing pain control. The AMSA Injection can provide anesthesia with few injections and less pain *Dimensions of Dental Hygiene*. 2003;1:28-33.

- [19] FRIEDMAN MJ, HOCHMAN MN. P-ASA Block Injection: A New Palatal Technique to Anesthetize Maxillary Anterior Teeth. *Journal of Esthetic and Restorative Dentistry*. 1999;11(2):63-71.
- [20] Sixou JL, Barbosa-Rogier ME. Efficacy of intraosseous injections of anesthetic in children and adolescents. *Oral surgery, oral medicine, oral pathology, oral radiology, and endodontics*. 2008;106(2):173-8. Epub 2008/04/22.
- [21] Wood M, Reader A, Nusstein J, Beck M, Padgett D, Weaver J. Comparison of intraosseous and infiltration injections for venous lidocaine blood concentrations and heart rate changes after injection of 2% lidocaine with 1:100,000 epinephrine. *Journal of endodontics*. 2005;31(6):435-8. Epub 2005/05/27.
- [22] Nusstein J, Claffey E, Reader A, Beck M, Weaver J. Anesthetic effectiveness of the supplemental intraligamentary injection, administered with a computer-controlled local anesthetic delivery system, in patients with irreversible pulpitis. *Journal of endodontics*. 2005;31(5):354-8. Epub 2005/04/27.
- [23] Meehan JG. Intraligamentary anaesthesia. *Journal of dentistry*. 1992;20(6):325-32. Epub 1992/12/01.
- [24] Taheritalesh K, Yazdani J, Ghavimi M, Khashabi E. Crestal Anesthesia: Efficient, Fast, and Reliable Technique in Posterior Mandibular Exodontia. *Research Journal of Biological Sciences*. 2009;4(3):369-74.
- [25] Robertson D, Nusstein J, Reader A, Beck M, McCartney M. The anesthetic efficacy of articaine in buccal infiltration of mandibular posterior teeth. *J Am Dent Assoc*. 2007;138(8):1104-12. Epub 2007/08/03.
- [26] Paschos E, Huth KC, Benz C, Reeka-Bardschmidt A, Hickel R. Efficacy of intraoral topical anesthetics in children. *Journal of dentistry*. 2006;34(6):398-404. Epub 2005/10/22.
- [27] Meehan JG. Intra-oral topical anaesthetics: a review. *Journal of dentistry*. 2000;28(1):3-14. Epub 2000/02/10.
- [28] Franz-Montan M, de Paula E, Groppo FC, Silva AL, Ranali J, Volpato MC. Liposomal delivery system for topical anaesthesia of the palatal mucosa. *The British journal of oral & maxillofacial surgery*. 2012;50(1):60-4. Epub 2010/11/26.
- [29] Grant GJ, Piskoun B, Lin A, Bansinath M. An in vivo method for the quantitative evaluation of local anesthetics. *Journal of pharmacological and toxicological methods*. 2000;43(1):69-72. Epub 2000/11/25.
- [30] Pere P, Iizuka T, Rosenberg PH, Lindqvist C. Topical application of 5% eutectic mixture of lignocaine and prilocaine (EMLA) before removal of arch bars. *The British journal of oral & maxillofacial surgery*. 1992;30(3):153-6. Epub 1992/06/01.
- [31] Haasio J, Jokinen T, Numminen M, Rosenberg PH. Topical anaesthesia of gingival mucosa by 5% eutectic mixture of lignocaine and prilocaine or by 10% lignocaine

- spray. *The British journal of oral & maxillofacial surgery*. 1990;28(2):99-101. Epub 1990/04/01.
- [32] Ramamurthi R, Krane EJ. Local anesthetic pharmacology in pediatric anesthesia. *Techniques in Regional Anesthesia and Pain Management*. 2007;11(4):229-34.
- [33] Kaczmarzyk T, Stypulkowska J. Assessment of the effectiveness of peripheral administration of morphine with local articaine anaesthesia for surgery in inflamed oral and maxillofacial tissues. *Pain*. 2005;115(3):348-54. Epub 2005/05/07.
- [34] Biyani G, Chhabra A, Baidya DK. Adjuvants to local anaesthetics in regional anaesthesia e Should they be used? Part II: Cons. *Trends in Anaesthesia and Critical Care*. 2014:1-6. Epub 2014/05/03.
- [35] Weldon CB, Tsui JH, Shankarappa SA, Nguyen VT, Ma M, Anderson DG, et al. Electrospun drug-eluting sutures for local anesthesia. *Journal of controlled release : official journal of the Controlled Release Society*. 2012;161(3):903-9. Epub 2012/05/23.
- [36] Sharma SS, Sharma SA, Saravanan C, Sathyabama. Newer Local Anaesthetic Drugs and Delivery Systems in Dentistry – An Update. *Journal of Dental and Medical Sciences*. 2012;1(4):10-6.
- [37] Saxena P, Gupta SK, Newaskar V, Chandra A. Advances in dental local anesthesia techniques and devices: An update. *National journal of maxillofacial surgery*. 2013;4(1):19-24. Epub 2013/10/29.
- [38] Meechan JG, Gowans AJ, Welbury RR. The use of patient-controlled transcutaneous electronic nerve stimulation (TENS) to decrease the discomfort of regional anaesthesia in dentistry: a randomised controlled clinical trial. *Journal of dentistry*. 1998;26(5-6):417-20. Epub 1998/08/12.
- [39] Bajkin BV, Todorovic LM. Safety of local anaesthesia in dental patients taking oral anticoagulants: is it still controversial? *The British journal of oral & maxillofacial surgery*. 2012;50(1):65-8. Epub 2010/12/07.
- [40] Ribeiro L, Ramalho S, Geros S, Ferreira EC, Faria e Almeida A, Conde A. Needle in the external auditory canal: an unusual complication of inferior alveolar nerve block. *Oral surgery, oral medicine, oral pathology and oral radiology*. 2014;117(6):e436-7. Epub 2013/10/31.
- [41] Chi D, Kanellis M, Himadi E, Asselin ME. Lip biting in a pediatric dental patient after dental local anesthesia: a case report. *Journal of pediatric nursing*. 2008;23(6):490-3. Epub 2008/11/26.
- [42] Rishiraj B, Epstein JB, Fine D, Nabi S, Wade NK. Permanent vision loss in one eye following administration of local anesthesia for a dental extraction. *International journal of oral and maxillofacial surgery*. 2005;34(2):220-3. Epub 2005/02/08.

- [43] Steenen SA, Dubois L, Saeed P, de Lange J. Ophthalmologic complications after intraoral local anesthesia: case report and review of literature. *Oral surgery, oral medicine, oral pathology and oral radiology*. 2012;113(6):e1-5. Epub 2012/06/09.
- [44] Penarrocha-Diago M, Sanchis-Bielsa JM. Ophthalmologic complications after intraoral local anesthesia with articaine. *Oral surgery, oral medicine, oral pathology, oral radiology, and endodontics*. 2000;90(1):21-4. Epub 2000/07/08.
- [45] Woodmansey KF, White RK, He J. Osteonecrosis related to intraosseous anesthesia: report of a case. *Journal of endodontics*. 2009;35(2):288-91. Epub 2009/01/27.
- [46] Khalil H. Local anesthetics dosage still a problem for most dentists: A survey of current knowledge and awareness. *The Saudi Journal for Dental Research*. 2014;5(1):49-53.
- [47] Akinmoladun VI, Okoje VN, Akinosun OM, Adisa AO, Uchendu OC. Evaluation of the haemodynamic and metabolic effects of local anaesthetic agent in routine dental extractions. *Journal of maxillofacial and oral surgery*. 2013;12(4):424-8. Epub 2014/01/17.
- [48] Gortzak RA, Oosting J, Abraham-Inpijn L. Blood pressure response to routine restorative dental treatment with and without local anesthesia. Continuous noninvasive blood pressure registration with a finger manometer. *Oral surgery, oral medicine, and oral pathology*. 1992;73(6):677-81. Epub 1992/06/01.