

We are IntechOpen, the world's leading publisher of Open Access books Built by scientists, for scientists

4,800

Open access books available

122,000

International authors and editors

135M

Downloads

Our authors are among the

154

Countries delivered to

TOP 1%

most cited scientists

12.2%

Contributors from top 500 universities



WEB OF SCIENCE™

Selection of our books indexed in the Book Citation Index
in Web of Science™ Core Collection (BKCI)

Interested in publishing with us?
Contact book.department@intechopen.com

Numbers displayed above are based on latest data collected.

For more information visit www.intechopen.com



Radiation-Induced Brain Injury After Radiotherapy for Brain Tumor

Zihua Yang, Shoumin Bai, Beibei Gu, Shuling Peng,
Wang Liao and Jun Liu

Additional information is available at the end of the chapter

<http://dx.doi.org/10.5772/59045>

1. Introduction

Radiation therapy is used widely for the treatment of diffuse primary and metastatic brain tumors [1]. Especially for nasopharyngeal carcinoma (NPC), the most common type of cancer in southern China, radiation therapy is the first-choice treatment and sometimes the only effective management of the disease. As many as 200,000 patients receive partial large-field or whole-brain irradiation every year, and the population of long-term cancer survivors keeps on growing. During treatment, however, some healthy brain tissues are also exposed to the radiation inevitably, and consequently many patients may experience neurological symptoms associated with damage to these healthy tissues after radiotherapy. Some of these symptoms may even last for months or years. This is known as acute and chronic radiation-induced brain injury (RIBI), also known as radiation encephalopathy (RE). Approximately 100,000 primary and metastatic brain tumor patients each year in the US survive long enough (>6 months) to experience RIBI [2]. For example, the incidence of RIBI for patients with NPC in Guangdong province is up to 3 per 100,000, to our knowledge, 40 times higher than the world average and is the most common one among head and neck tumor. RIBI includes a series of clinical manifestations, such as focal neurological deficits, secondary epilepsy, mental and behavioural disorders, elevated intracranial pressure, and the progressive deterioration of the hippocampal-associated learning and memory functions [3], which can be especially devastating to patients and caregivers.

The American Cancer Society center (ACS) stresses that in order to maximize the quality of life for tumor patients after radiotherapy, the future research should focus on preventing and curing complications of cancer therapy. RIBI, a common and devastating complication of

radiotherapy for brain tumor, is now emerging as a major health problem in the treatment of brain tumor.

2. Pathogenesis

Based on the time between onset of clinical expression and radiation therapy administration, RIBI has been classified into acute, early delayed, and late delayed injury, which was first reported by Sheline [4]. Acute brain injury occurs during and/or in days to weeks after irradiation. Early delayed brain injury occurs 6–12 weeks post-irradiation [5], while some other researchers consider this time course is 1-6 months [6]. Although both of these early injuries can result in severe reactions, they rarely occur and normally resolve spontaneously or reversible after short-term treatment. In contrast, late delayed brain injury, usually developing 6 months post-irradiation, which is most significantly higher than that of acute and early delayed RIBI, have been viewed as irreversible and progressive continuously due to the pathogenesis [7].

The knowledge of the mechanisms underlying the RIBI following irradiation is the basis for improving the therapies and prophylaxes, but it is not wholly clear.

The most direct affecting risk of RIBI is the radiation doses, fractionation schemes, and adjuvant treatments. [8, 9] Liu Y and Xiao S et al. found that single-dose irradiation at 10Gy failed to induce any significant effects in young male rats whereas an exposure at 20 to 40Gy induced acute brain injury at both cognitive and pathologic levels. [10] Zhou H. and Liu Z. et al. reported that fractionated irradiation of 20 to 40Gy could also induce acute brain injury in young rats which indicated the role of fractionation schemes. [11] Furthermore, Ruben JD et al. not only demonstrated the risk of radiation dose and fraction size, but the subsequent administration of chemotherapy as well. [9]

In general, ionizing radiation can cause RIBI by either direct or indirect way and it is likely that the successful unraveling of this puzzle will not come true without the basic study of subtle molecular, cellular, or microanatomic changes in the brain. Hereon, we will discuss the pathogenesis of RIBI from oxidative stress, nonspecific inflammation, blood brain barrier(BBB) disruption as well as apoptosis and inhibition of neurogenesis which act alone or accompanied.

2.1. Oxidative stress

It is reported that in the unilaterally irradiated animals, irradiated hemispheres showed similarly significant changes in oxygenation compared to unirradiated controls. [12]

Due to radiation therapy, the microglia is activated and immune cells begin to infiltrate the brain. These cells then produce reactive oxygen species (ROS) whose production and detoxification are normal physiological processes. Nevertheless, an imbalance between ROS production and ROS removal may lead to oxidative stress [13, 14]. Several components of ROS can cause damage to cardinal cellular components, such as lipids, proteins, and DNA, initiating

subsequent cell death via necrosis or apoptosis [15]. Thus, ROS can be contributed to neuronal toxicity and implicated in both acute injury and chronic neuropathological conditions [16].

Many related molecules have been reported. Jun showed hydrogen peroxide (H₂O₂)-induced oxidative stress and apoptosis in HT22 cells accompany by up-regulated expression of p-ERK 1/2, p-JNK, and p-P38 [13]. What is more, the effectiveness of edaravone (a new agent of ROS scavenger), peroxisome proliferator-activated receptor (PPAR) gamma agonists, and antioxidants/antioxidant enzymes in preventing or mitigating the severity of RIBI also provided an evidence of the oxidative stress. [13, 17]

2.2. Nonspecific inflammation

Irradiation can cause an acute endothelial cell apoptosis which leads to BBB breakdown, chronic hypoxia and peritumoral tissue edema. [18] Meanwhile, nonspecific inflammation cascades which further promote the microenvironmental changes, radiation necrosis, and neurogenesis inhibition was activated [19].

Radiation could induce astrocyte proliferation and secrete a great quantity of pro-inflammatory mediators after irradiation, which may aid the infiltration of leukocytes into the brain via blood-brain barrier (BBB) breakdown [20, 21]. Microglia could also be activated by quantity of irradiation through rapid proliferation, as well as increased production of ROS and other cytokines which are involved in mediating neuroinflammation [22].

Plenty of experiments have found up-regulation of pro-inflammatory transcription factors after irradiation which constituted the evidence of nonspecific inflammation cascades in the process of RIBI. Moore, A. H. suggest that radiation-induced changes in vascular permeability are dependent on cyclooxygenase 2 (COX2), one of two isoforms of the obligate enzyme in prostanoic acid synthesis and the principal target of non-steroid anti-inflammatory drugs activity. [23] Lee et al. found mRNA and protein of pro-inflammatory mediators including tumour necrosis factor-alpha (TNF-alpha), interleukin-1beta (IL-1beta), and monocyte chemoattractant protein-1 (MCP-1) activated significantly in regions isolated from irradiated rat brain. [24] TNF-alpha is thought to be able to up-regulate other pro-inflammatory cytokines and increase BBB permeability, increase leukocyte adhesion, activate astrocytes, and induce endothelial apoptosis. And the further research demonstrated that anti-inflammation factor (TNF-alpha) successfully inhibited radiation-induced effects in the local as well as abscopal region in the brain. [12] Peroxisome proliferator-activated receptor (PPAR) gamma is a ligand-activated transcription factor that belongs to the steroid/thyroid hormone nuclear receptor superfamily. And the effectiveness of PPAR-gamma agonists is also a strong demonstration of nonspecific inflammation. [25]

What is more, radiation could induce the loss of oligodendrocyte type-2 astrocyte (O-2A) progenitor cell, the most radiosensitive type of glial cell, which leads to transient demyelination soon after irradiation. Since all the brain gliocytes including oligodendrocyte, astrocytes and microglia would participate in the radioactive damage process in different ways and RIBI is predominated by white matter necrosis and demyelination, the pathological mechanism is well known as Gliocyte Hypothesis. However, there is conflicting conclusion that the targeted

anti-inflammatory agent has no effect on gliocytes, but can still ameliorate RIBI [26]. Consequently, pathological mechanism of RIBI cannot be explained so simply by the Gliocyte Hypothesis despite the large amount of evidence supporting this hypothesis.

Due to the synergistic effect of oxidative stress and nonspecific inflammation after irradiation, endothelial cell nuclear, blood vessel density, and blood vessel length are vulnerable to have a reduction. The vascular damage can result in brain ischemia and even white matter necrosis. [7]. All of this elicited the Vascular Hypothesis. Paradoxically, radiation-induced necrosis has also been reported in the absence of vascular changes [27]. In addition, the PPAR γ agonist, pioglitazone, and the ACE inhibitor, ramipril, which are believed to prevent RIBI in the rat do not reverse the reduction in vascular density and length that occurs after fWBI [28, 29].

Therefore, RIBI cannot be completely explained by any single cell or tissue despite a host of evidence supporting these hypotheses. It is supposed to occur and develop due to active interactions between the multiple cells. These participating cells are considered to play a synergistic rather than initial role in the radiation brain injury [30].

2.3. Blood Brain Barrier(BBB) disruption

A number of data from laboratory animals has demonstrated acute BBB disruption which was initiated by apoptosis of endothelial cells and mediated by the ASMase pathway after irradiation [18]. As a result, change of BBB permeability has been thought to be the most sensitive and reliable index for detection of early RIBI. [31] Breakdown of the BBB may also enhance the effectiveness of chemotherapeutic agents, with the unintended consequence of contributing to injury of the peritumoral tissue. Liu Y. and Xiao S. et al. found that a single-dose exposure at 20 to 40 Gy induced acute brain injury at cognitive is more or less accompanied with increased brain water content and deteriorated BBB function, though mild histopathologic alternations were only noticed in the 40-Gy-irradiated rats at 20 days. [10] Zhou H. and Liu Z. et al. reported disrupted BBB permeability was detected after fractionated irradiation of 20 to 40Gy in young rats and thus proved that the change in BBB permeability could be one of the most sensitive and reliable indices of fractionated-radiation-induced acute RIBI. [11] Besides, increased astrogliosis in the hippocampus could be detected at 4 weeks' postirradiation for 40-Gy group.

2.4. Apoptosis and neurogenesis inhibition

The pathogenesis of RIBI may also relate to the process of neuronal apoptosis and inhibition of neurogenesis.

Even gray matter contains neuronal cell bodies which is quite oxygen-dependent, neurons have been considered radioresistant since they could no longer divide. However, it is reported that apoptosis occurs in the young adult rat brain after ionizing irradiation and recent studies also demonstrated that there exists direct radiation-induced damage to hippocampal neurons with associated cognitive decline. The hippocampus consists of the DG, CA3, and CA1 regions. Irradiating the hippocampus resulted in an increase in apoptosis in the subgranular zone of the DG which are capable of both self-renewal and generating neurons, astrocytes, and

oligodendrocytes [32, 33]. And blocking neurogenesis which was associated with alterations of microenvironment including disruption of the microvascular angiogenesis and increase in the number and activation status of microglia within the neurogenic zone can contribute to the deleterious side effects of radiation treatment. [14]

Neurogenesis is also related to inflammation for the reason that anti-inflammatory drug was proved to be capable of restoring and augments neurogenesis after cranial irradiation. [19] However, these changes could also be observed in the absence of demyelination, blood vessel density alternation and inflammatory cellular infiltration by a doses of ≤ 2 Gy that fail to produce these changes [34].

3. Clinical characteristics of RIBI

3.1. Latency

The latency of RIBI exists a long time span. Chandler reported the time interval between the end of radiotherapy to the onset of RIBI was 1 month to 16 years [35]. JY Qin et al. documented the latency of RIBI was 3 months to 38 months, median time of which was 21.7 months [36]. We collected data of 130 NPC cases who suffered RIBI post radiotherapy, the latency of them underwent a large time span from 0 to 32 years, the mean time was about 6 years [37].

Therefore, being focus on the mechanism research to get early differentiation, diagnosis, explore therapeutic strategies of late delayed RIBI become more and more urgent.

3.2. Clinical features and classification

Acute effects occur during and/or shortly after the radiation exposure and are characterized by symptoms of fatigue, dizziness, and signs of increased intracranial pressure. The acute effects are considered to be secondary to edema and disruption of the BBB. Early delayed effects of post-irradiation and usually show reversible symptoms generalized weakness and somnolence, partly resulting from a transient demyelination. It is, however, the late delayed effects that may lead to severe irreversible neurological consequences.

According to the site of involvement and corresponding clinical manifestations, the subtypes of RIBI were divided into cerebellum type, brain stem and cranial type, cerebellum type and mixed type.

3.2.1. Cerebral hemisphere type

Focal delivery of one large radiation fraction during radiotherapy can lead to focal injury of the brain adjacent to the irradiated lesion [38]. Clinically, patients present with focal neurological deficits, which are often accompanied by focal increased intracranial pressure.

The most common and serious delayed complication of cerebral radiotherapy is cognitive dysfunction. Take NPC for example, since inferior temporal lobes inevitably expose to the

radiation, the prominent and earliest seen symptom of RIBI is distinctive cognitive impairment. Recently, Hsiao demonstrated that nasopharyngeal cancer patients treated with intensity-modulated radiotherapy (IMRT) had a worse cognitive outcome if >10% of their temporal lobe volume received a total fractionated dose of >60 Gy than patients who received < 60 Gy [39]. The feature of cognitive impairment is different from those with Alzheimer's disease, it is characterized by decreased verbal memory, spatial memory, attention, novel problem-solving ability, and even executive function. Patients usually accompanied with negative emotions including depression, anxiety as well as somatization. Mental disorders such as stupor state, hallucinations and delusions could also be observed as the injury progresses [20].

It should be noted that significant cognitive impairment can be seen in the absence of radiographic or clinical evidence of demyelination or white matter necrosis after irradiation [40]. Therefore, conducting cognitive evaluations shortly post-irradiation at regular intervals is becoming more and more important. Once cognitive decline is detected, no matter whether there is imaging findings of brain lesions, prophylactic treatment should be given to the patients immediately. The mini-mental status examination (MMSE), a test to assess global cognitive function, is relatively insensitive to radiation-induced cognitive impairment [39, 41]. As the cognitive domains that are most affected by brain irradiation is distinct from the common causes of dementia such as Alzheimer's disease and vascular dementia, current Radiation Therapy Oncology Group (RTOG) study has established a series of tests that focuses on the cognitive domains affected by brain irradiation, such as Dutch adult reading test for assessing intelligence, vline bisection test for perception, visual verbal learning test for memory and stroop color word test for executive function [42]. The Montreal cognitive assessment (MoCA) is used to assess different cognitive domains including attention and concentration, executive functions, memory, language, visuoconstructional skills, conceptual thinking, calculations, and orientation. Sensitivity and specificity of MoCA application in radiation-induced cognitive impairment has not been reported.

Another most common injury after radiotherapy is unilateral or/and bilateral temporal lobe edema which might elevate intracranial pressure. If the pathogenesis develops persistently, the area of edema could expand to the parietal lobes and then cause rapidly deteriorating clinical course. Signs of increased intracranial pressure such as headache, nausea and vomiting would get worse progressively. Severe cerebral edema could result in compression of cerebral peduncle and cerebral hernia, which would lead to hemiplegia and even to death. Once that occurs, surgical treatment will be needed. Moreover, cerebral edema could at last get liquefactive necrosis with formation of cystic spaces. Figure.1

3.2.2. Brain stem and cranial type

It has been reported that each pair of cranial nerve could get involved in injury after irradiation in NPC patients [43]. Due to the irradiation fields mainly cover the lower part of brain stem, the last four cranial nerves, glossopharyngeal nerve, vagus nerve, accessory nerve and hypoglossal nerve, were commonly affected and leading to corresponding clinical manifestations, such as atrophy of tongue muscle, dysphagia, dysphonia and dysdipsia. Severe bulbar

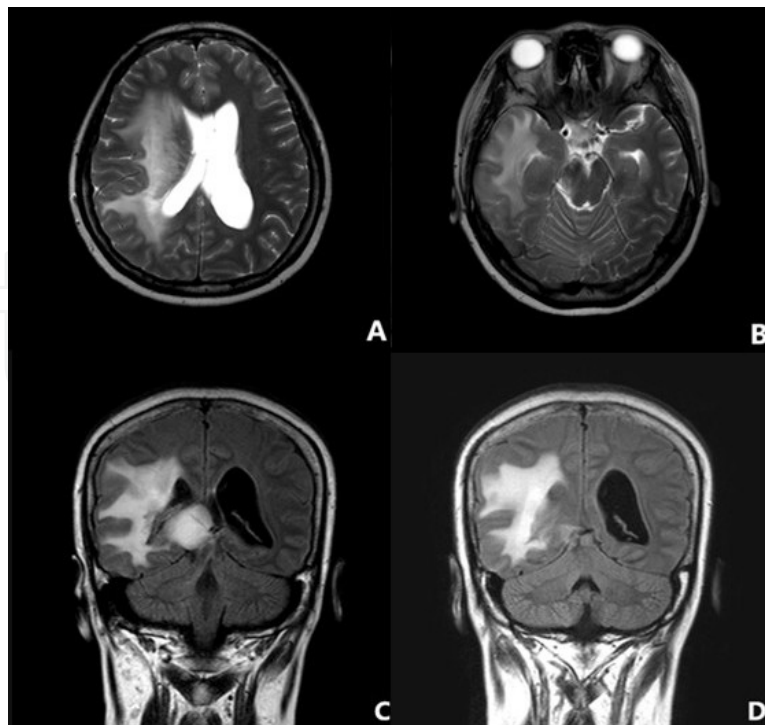


Figure 1. Cerebral edema and atrophy of a 39-year-old female cerebral hemangioma patient. 8 years after the treatment of gamma knife. Lumps-like abnormal signal was shown in the right-basolateral region, heterogeneous high signal was shown on T2W, surrounded by low signal, a large fingerlike high signal of the white matter around lesions on T2W. Cerebral gyri of the frontal and parietal lobe narrow and cerebral sulci widen which is the sign of cerebral atrophy. A.T2WI B. T2WI C.FLARE D.FLARE

palsy may significantly decrease the life quality of patients and sometime is fatal caused by subsequent lung infection and/or malnutrition [43]. And the frequency of upper cranial nerve injury increased greatly if the patients have to conduct re-radiotherapy.

Some other common involved cranial nerve is cochleovestibular nerve caused by not only direct effect of irradiation to the nerve but also the indirect effect of the inner ear damage after radiotherapy such as secretory otitis media or even intractable suppurative otitis media. The prime symptoms of disorders of the cochleovestibular nerve are vertigo, tinnitus and pain. Irreversible hearing loss caused by nerve deafness, conduction deafness and mixed deafness will happen in the end [43].

Radiation-induced optic neuropathy (RION) is a rare but usually devastating side effect of radiotherapy for NPC. The most frequent clinical symptoms of RION typically present with sudden, painless, irreversible vision loss in one or both eyes after radiotherapy, and occur most commonly from 3 months to more than 9 years after radiotherapy. Liu et al. reported RION in NPC patients [44]. Ophthalmologic examinations showed flake bleeding in the retina, optic nerve atrophy and cotton-wool spots. T1-weighted enhanced MRI images showed enhancement of the optic nerve and optic chiasm in six cases.

One more severe clinical manifestation is syncope. Damage to descending sympathetic nerve fibers, which anatomically run along the brain stem, may result in hazardous syncope as well

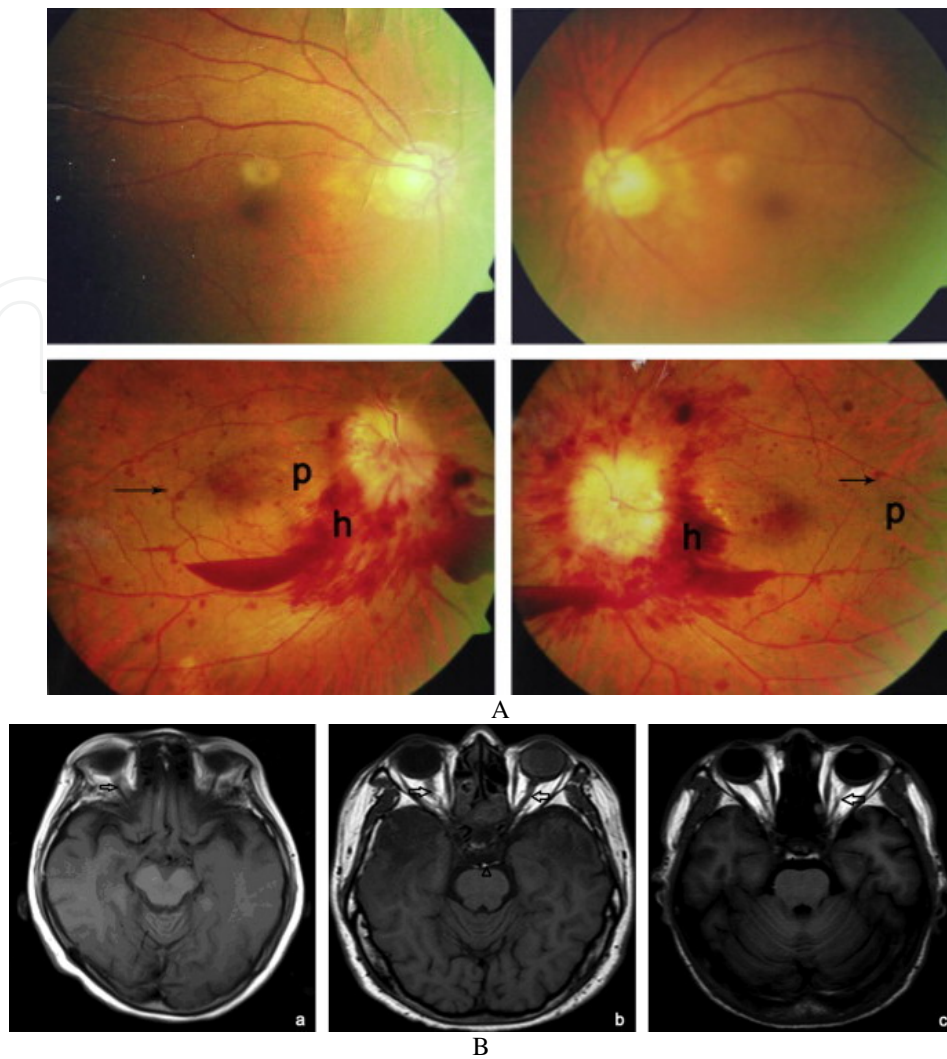


Figure 2. A. Fundus examination in radiation-induced optic neuropathy: ocular fundus showing flame-shaped and dot hemorrhage (bottom row, h, arrow) and cotton-wool spots (top row, bottom row, p). B. Axial MRI of three patients showing: (a, b) tortuous optic nerve with blurring of edges, and (b) optic nerve atrophy; (b, c) T1-weighted enhanced MRI showing enhancement of the optic nerves and optic chiasm.

as Horner syndrome. Crossed hemiplegia might also occur when pyramidal tract is involved simultaneously [43].

3.2.3. Cerebellum type

It is the least common type of RIBI. Damage to cerebellum results in edema of cerebellar hemisphere and leads to symptoms such as vertigo, stumbling, ataxia and other discomfort. The injury to cerebellum has the same prognosis as that in cerebral hemisphere and eventually develop into the tonsillar hernia.

3.2.4. Mixed type

It is a combination of two or more subtypes mentioned above.

4. Value of neuroimaging in RIBI diagnosis

Neuroimaging, including computed tomography (CT), magnetic resonance imaging (MRI) especially neurological functional imaging technology, provide valuable information in early diagnosis and differential diagnosis of RIBI. In this paragraph, we will provide a variety of neuroimaging information to readers. Including not only traditional CT/MRI imaging, but also proton magnetic resonance spectroscopy (MRS) and diffusion tensor imaging (DTI).

4.1. Computed Tomography (CT)

CT findings of focal radiation brain edema and necrosis are generally low density, while the affected white matter is usually symmetric and exhibit no enhancement or irregular peripheral enhancement with contrast material. The brain lesions would range from small foci near the frontal or occipital horns to a confluent band extending from the ventricles to the corticomedullary junction. Figure.3

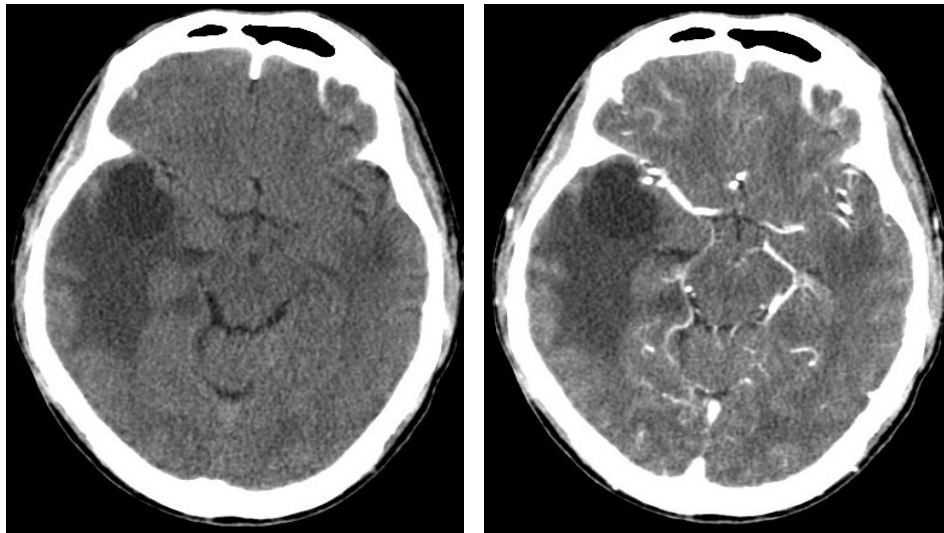


Figure 3. CT founding of a 59-year-old male patient with NPC after radiotherapy for over 10 years. A. cystic liquefactive necrosis of the right temporal lobe with edema around lesions. B. no enhancement.

4.2. Magnetic resonance Imaging (MRI)

MRI is definitely more valuable for the diagnosis of RIBI than CT. The appearance of finger like edema and focal necrosis which shows low signal intensity on T1WI and high signal on T2WI are typical feature of MR imaging in patients with RIBI. Ringlike or irregular enhancement in the bilateral temporal lobes are also frequently seen on T1WI enhanced MR imaging while haemorrhage with heterogeneous signals is relative rare. (Figure.4)These findings on conventional MRI technology are not specific and insufficient to distinguish RIBI from tumor recurrence or other diseases. Thus various new technologies of MRI are employed to make up for this shortcoming.

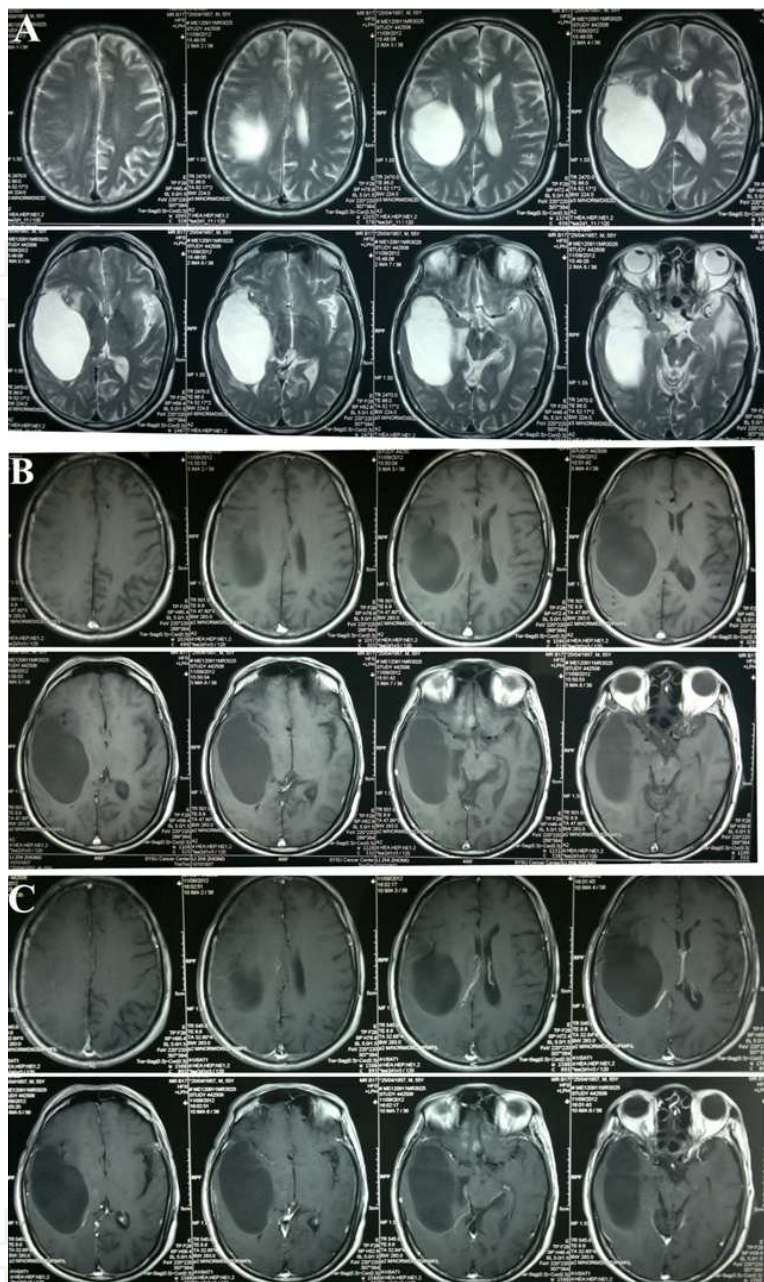


Figure 4. Radiation necrosis and edema. MRI performed 8 years after radiotherapy of one 54-years-old male patient with NPC. Necrosis of right-temporal and right-parietal lobe shows low signal intensity on T1WI and high signal on T2WI with enhanced boundary. Edema of the left-temporal lobe shows finger like low signal intensity on T1WI and high signal on T2WI with non-enhanced boundary. A. T2WI; B. T1WI; C. T1WI+C

4.3. Proton magnetic Resonance Spectroscopy (MRS)

MRS is used to display metabolite changes in normal appearing white matter after fWBI in the brain. Brain metabolites are quantified including choline(Cho), creatine(Cr), glutamate(Glu), glutamine(Gln), N-acetyl-aspartate (NAA) and lactate. It is reported that NAA, Cr and Cho change regularly from the center of the visible lesions. In the liquefaction and necrosis foci,

NAA, Cr and Cho are nearly absent. In the visible lesions, the levels of NAA increase slightly, while the contents of Cr and Cho decreased obviously. Certain extent away from the visible lesions, the contents of NAA decrease and the levels of Cr and Cho increase. Farther away from the lesions, the levels of the three substances gradually become normal. Consequently the ratios of NAA/Cr and Cho/Cr alter from periphery to the lesion, decrease from a value above 1 to one less than 1. A ratio of NAA/Cr and Cho/Cr less than 1 may be highly indicative of nerve and cell structure damage in the brain tissue [45, 46]. In view of this, MRS is supposed to indentify a larger area of abnormal metabolism in RIBI than visible lesion in MRI, which makes it possible to detect RIBI in early stage.

4.4. Diffusion Tensor Imaging (DTI)

DTI is a novel way to assess tissue microstructure by measuring the diffusion of water molecules in three-dimensional (3D) space. It is often applied to distinguish demyelination from axonal injury within white matter bundle. In a DTI study of childhood survivors after fWBI for acute lymphoblastic leukemia, fractional anisotropy (FA) decreases significantly in the frontal and parietal lobes related to declines in intelligence quotient [47]. In another study of adult survivors post fWBI for acute leukemia, FA values reduced obviously in normal appearing cerebral white matter of the temporal lobe, hippocampus, and thalamus [48]. DTI is thought to be a promising technique to detect early changes in white matter integrity before image evidence of radiation-induced demyelination or necrosis. However, the application of DTI to RIBI is just in its infancy. Figure.5

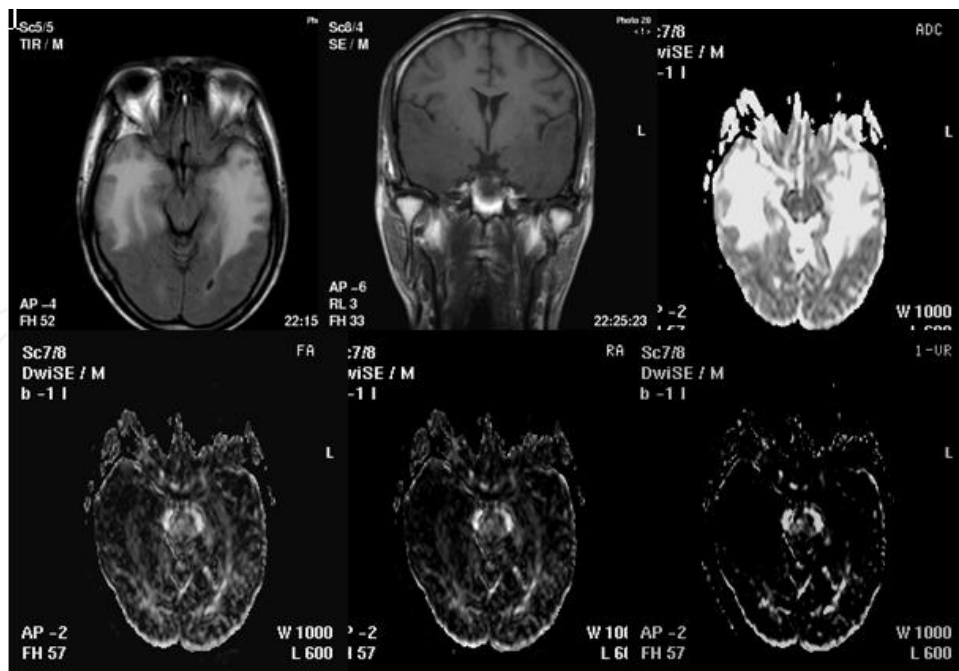


Figure 5. Delayed RIBI of bilateral temporal. Edema is obvious. Isotropic map shows high signal in the lesion area which is wider than FLAIR. Anisotropic map shows low signal in the bilateral temporal lobe and white matter fiber of the normal temporal lobe shows high signal and blurred.

5. Treatment strategies

Up to now, there has been no proven effective treatment to reverse or terminate the pathogenesis brain irradiation injury, which could be particularly devastating to patients and caregivers since the exact mechanisms of RIBI is unclear. Potential therapeutic strategies to prevent RIBI will be discussed in this part.

5.1. Glucocorticoids

Glucocorticoids play a vital role in the comprehensive therapy for RIBI. A large number of experimental and clinical studies have confirmed its polyvalent efficacy of narrowing lesions, relieving symptoms as well as improving their prognosis by counteracting the radiation-induced vascular endothelial damage and inflammatory cascade [49]. Dispute still remains over the opportunity, dose and course of glucocorticoid therapy. Many a researchers recommend maintenance therapy with regular dose for more than 3 months while some others affirm the effect of early large dosage of corticosteroids for shorter periods [49]. Some patients may be weaned off after a period of symptomatic exacerbation while in some cases symptoms can return after steroid cessation and lead to necessitating long-term steroid use. Unfortunately, the prolonged systemic administration will result in immunosuppression, psychiatric disturbances, myopathy and sequelae of endocrinologic compromise such as hypertension, diabetes mellitus, osteoporosis, weight changes and thickening of facial subcutis [49].

5.2. Antiplatelets and anticoagulation

Radiation induced vascular endothelial injury may lead to subsequent mural thrombosis, thus antiplatelets may play a crucial part in preventing the RIBI. Currently existed antiplatelet drugs mainly include cyclooxygenase(COX) inhibitors and adenosine diphosphate (ADP) receptor antagonists. Phosphodiesterase inhibitors, a new type of antiplatelet agents, have been proved to be protective for intravascular thrombosis after radiation [2].

Another kind of drug to control thrombosis is anticoagulation drugs. It's reported that the use of heparin and warfarin lead to partial recovery of function in five of eight patients with cerebral radiation necrosis when they were proved to be unresponsive to steroid therapy [50]. One case concerning a patient experienced a recurrence of symptoms following discontinuation of anticoagulation therapy and was reversed again by resuming anticoagulation treatment [50] demonstrated the limited success of anticoagulation drug. However, this treatment need to be validated in larger trials before clinical application.

5.3. Reactive Oxygen Species (ROS) scavengers

Edaravone, a new agent of ROS scavenger, has been verified effective in reducing the vascular endothelial cell injury, inhibiting brain encephaledema and preventing neuronal cell necrosis [51]. Our clinical trails on 42 NPC patients suffered RIBI has demonstrated that efficiency (50.0%) and total efficiency (88.9%) in the edaravone administration group were significantly higher than that in the contrast group (14.3% and 42.9%). After a 4-week treatment, the lesion

volume on MRI was smaller than before in edaravone group, and the scores of 6 domains, 19 aspects and the overall quality of life in edaravone group were significantly higher than those in non-edaravone group [52]. However, ROS scavengers have received not so much attention because they are likely to protect brain tumors to the same extent as they protect normal brain [2]. Another antioxidant and radioprotective drug is vitamin E. The administration of Vitamin E significantly reduced the severity of radiation-induced brain damages and increased the activity of superoxide dismutase and catalase enzymes in the brain. [53]

5.4. Refactoring microcirculation

The butyl-phthalide, a neotype of drugs reforming the microcirculation, has multiple effects of increasing the perfusion in the ischemia area, protecting the mitochondria from hypoxic injury, and also reducing neuronal apoptosis. Human urinary kallidinogenase for injection, another new agent of this type, may be instrumental in vasodilation of brain blood vessels, increasing haemoglobin in the cerebral blood flow, and also improving glucose metabolism in ischemic brain tissues [54].

5.5. Reconstructing the nerve function

Radiation injury could destroy the nerve structure and then lead to loss of neuron function. Therefore neural plasticity is thought to play a vital role in the comprehensive treatment for RIBI. As our data from animals and humans shows that gangliosides is helpful in promoting the recovery of nerve function in lesioned brain, spinal cord and also peripheral nerve. A host of in vivo and in vitro studies also demonstrated that neurotrophic factors are neuroprotective in radiation-induced neuropathy. Curative effect has been proved in patients with temporal lobe injury after two-month injection with mouse nerve growth factor, both MR imaging and cognitive function of them were improved significantly [55].

5.6. Renin–Angiotensin System(RAS) inhibitors

The RAS has been viewed as a classical systemic hormonal system. Recently several intra-organ RAS including a brain RAS have been identified. The brain RAS is involved in modulation of the BBB, stress, memory, and cognition. Both angiotensin-converting enzyme inhibitors (ACEI) and angiotensin receptor blockers (ARB) have been proved effective in treating experimental radiation nephropathy and pneumopathy [56, 57]. As for their effect on encephalopathy, studies of Jenrow et al. (2010) show that administration of the ACEI, ramipril has modest protection against WBI-induced decreases in neurogenesis, but did not modulate radiation-induced neuroinflammation while other report has different conclusion with a different timing of chronic administration of theramipril and/or the response after single or fractionated doses on rodent [58, 59]. Whether all of the drug mentioned above can be useful for the patient of RIBI remains to be further elucidated.

5.7. Symptomatic treatment

Dehydration medicine such as mannitol and albumin should be given to patients with high cranial pressure. Antiepileptic drugs (AED) should be chosen according to the forms of

epilepsy seizures. Serotonin (5-HT) reuptake inhibitors and psychological therapies might be preferred when anxiety and depression are the cardinal symptoms.

It should be mentioned that there has been no known preventive medications for radiation-induced cognitive impairment in humans, although several pharmacologic agents have been assessed for symptomatic management [2]. The Wake Forest Community Clinical Oncology Program Research Base completed a phase II study using 10mg/day of a cholinesterase inhibitor namely donepezil, which showed significant improvement in energy level, mood, and cognitive function in radiation-induced brain injury survivors [60]. Memantine, an NMDA receptor antagonist being able to block ischemia-induced NMDA excitation, was proven to be effective in vascular dementia. Thus it is supposed to be conducive to radiation-induced cognitive impairment if radiation-induced ischemia occurs after fWBI. Other potential pharmacological mediators based on preclinical researches suggesting that anti-inflammatory agents could prevent or ameliorate radiation-induced cognitive function. As for anti-inflammatory peroxisome proliferator-activated PPAR γ agonists, researchers have found some evidence that they might prevent/ameliorate radiation-induced cognitive impairment when given for only a few weeks after fWBI on rodent [61].

5.8. Surgical management

Surgical resection can be considered when the patient's necrosis are symptomatic and have not taken a turn for the better after medical treatments. For example, when suffering from large area-cerebral edema, and the condition progressively exacerbated active medications although has been given, patients should also be recommended to surgically remove the focal brain lesions in time when the location is in a region that is surgically accessible. During this process, the surgeon should avoid incurring additional significant neurologic morbidity. [85]

5.9. Neural Stem Cells(NSCs) therapies

In addition to drug therapeutics, there has been increased interest in the use of various NSCs therapies. Pioneering researchers directly inject NSCs into rodent brains after WBI and found it partially restores cognitive function [62, 63]. Interestingly, these NSCs not only differentiate into neurons, but also oligodendrocytes, astrocytes and endothelial cells that can alter the hippocampal microenvironment [63]. However, the use of exercise or NSCs transplantation to prevent/ameliorate RIBI in humans will require considerably more research before it can be translated to the clinic.

5.10. Organ-sparing approach

To date, one of the strategies to prevent RIBI in the clinic involves organ-sparing approach which is based on neuroanatomical target theory. Technology has evolved to potentially allow for selective avoidance of the regions of adult neurogenesis, including the hippocampus and neural stem cell niche in the periventricular regions. With the help of advanced radiation techniques, such as 3D conformal image guidance [64], inverse-planned intensity modulated radiotherapy (IMRT) [65] and proton beam radiotherapy [66], it is expected to reduce the

occurrence of RIBI by limiting the dose to critical organs and possibly increasing locoregional tumor control. [67]

5.11. Anti-VEGF antibody

As is mentioned above, the necrosis is partly due to increasing capillary permeability which is caused by cytokine release leading to extracellular edema. The edema is the most common pathology of RIBI is just sustained by endothelial dysfunction, tissue hypoxia as well as subsequent necrosis. Consequently, it is a logical option to block the vascular endothelial growth factor (VEGF) at an early stage to reduce the development of radiation necrosis and thus decrease the vascular permeability. After the patient with radiation-induced necrosis was treated with an anti-VEGF antibody (bevacizumab), the improvement neurologic signs and symptoms in accordance with the decrease in T1-weighted fluid-attenuated inversion recovery signals put bevacizumab as a treatment direction for patients with RIBI [68].

5.12. Hyperbaric Oxygen Treatment (HBOT)

HBOT is proven to be able to stimulate angiogenesis and restore the regional blood supply by reaching the goal of increasing parenchymal oxygen concentration. HBOT treatment has been demonstrated to be beneficial in pediatric patients with radiation necrosis [69] and in smaller series and case reports [70, 71]. However, Jun L et al. reported that HBOT treatment did not reduce visual loss or blindness in patients with RION [44]. As single institution studies vary widely due to patient selection bias, it would be necessary to conduct more randomized trials to delineate the true benefit of HBOT. [72]

6. Problems and prospects

Although a great many treatment strategies have eliminated acute and early delayed brain injury as well as most delayed demyelination and white matter necrosis, radiotherapy is still carries a risk of RIBI which may seriously affect the life quality of survivors. This risk is further exacerbated while the patient need to use chemotherapeutic agents at the same time [2].

To get more knowledge about the mechanism of RIBI is the key to the solution. Although many theories have been proposed, it is likely that the pathogenesis in long term survivors of various tumors like small cell lung cancer, NPC, low-grade glioma, non-parenchymal tumors, primary brain tumors and metastatic brain tumors are different just because they were treated differently. There is not a solely theory that can be used to fully answer this question.

As a result, it is imperative to detect the pathological change non-invasively as early as possible. However, there still a lot of difficulties which need to be solved in clinical practice. It is explicit that the most important issue is to differentiate radiation necrosis and tumor progression. Fortunately, there are multiple radiological and nuclear medicine techniques available to help us even these anatomic and metabolic imaging techniques all have inherent limitations in sensitivity and specificity.

Researchers all over the world have tried hard but have had only modest success in modulating RIBI to date. However, the future looks promising since we have attached importance to RIBI and find some innovative treatments such as the NECs or anti-VEGF therapy which can be the alternative offer [72].

Over the next decade, we will continue paying more attention to the investigation that how radiation-induced brain injury develops and how it can be treated [2].

Acknowledgements

We are grateful for support from the National Natural Science Foundation of China (no. 81372919) and the Natural Science Foundation of Guangdong Province, China (no. S2013010013964).

Author details

Zhihua Yang¹, Shoumin Bai², Beibei Gu³, Shuling Peng³, Wang Liao⁴ and Jun Liu^{4*}

*Address all correspondence to: docliujun@hotmail.com

1 Department of Neurology, the First Affiliated Hospital, Guangzhou Medical University, Guangdong, China

2 Department of Oncology, Sun Yat-Sen Memorial Hospital, Sun Yat-Sen University, Guangdong, China

3 Department of Anesthesiology, Sun Yat-Sen Memorial Hospital, Sun Yat-Sen University, Guangdong, China

4 Department of Neurology, Sun Yat-Sen Memorial Hospital, Sun Yat-Sen University, Guangdong, China

References

- [1] Tsao, M.N., et al., Radiotherapeutic management of brain metastases: a systematic review and meta-analysis. *Cancer Treat Rev*, 2005. 31(4): p. 256-73.
- [2] Greene-Schloesser, D., et al., Radiation-induced brain injury: A review. *Front Oncol*, 2012. 2: p. 73.

- [3] Roman, D.D. and P.W. Sperduto, Neuropsychological effects of cranial radiation: current knowledge and future directions. *Int J Radiat Oncol Biol Phys*, 1995. 31(4): p. 983-98.
- [4] Sheline, G.E., Radiation therapy of brain tumors. *Cancer*, 1977. 39(2 Suppl): p. 873-81.
- [5] Schultheiss, T.E. and L.C. Stephens, Invited review: permanent radiation myelopathy. *Br J Radiol*, 1992. 65(777): p. 737-53.
- [6] Yan, L., Z. Xi and B. Drettner, Epidemiological studies of nasopharyngeal cancer in the Guangzhou area, China. Preliminary report. *Acta Otolaryngol*, 1989. 107(5-6): p. 424-7.
- [7] Brown, W.R., et al., Capillary loss precedes the cognitive impairment induced by fractionated whole-brain irradiation: a potential rat model of vascular dementia. *J Neurol Sci*, 2007. 257(1-2): p. 67-71.
- [8] Lee, A.W., et al., Factors affecting risk of symptomatic temporal lobe necrosis: significance of fractional dose and treatment time. *Int J Radiat Oncol Biol Phys*, 2002. 53(1): p. 75-85.
- [9] Ruben, J.D., et al., Cerebral radiation necrosis: incidence, outcomes, and risk factors with emphasis on radiation parameters and chemotherapy. *Int J Radiat Oncol Biol Phys*, 2006. 65(2): p. 499-508.
- [10] Liu, Y., et al., An experimental study of acute radiation-induced cognitive dysfunction in a young rat model. *AJNR Am J Neuroradiol*, 2010. 31(2): p. 383-7.
- [11] Zhou, H., et al., Fractionated radiation-induced acute encephalopathy in a young rat model: cognitive dysfunction and histologic findings. *AJNR Am J Neuroradiol*, 2011. 32(10): p. 1795-800.
- [12] Ansari, R., et al., Anti-TNFA (TNF-alpha) treatment abrogates radiation-induced changes in vacular density and tissue oxygenation. *Radiat Res*, 2007. 167(1): p. 80-6.
- [13] Zhao, Z.Y., et al., Edaravone protects HT22 neurons from H₂O₂-induced apoptosis by inhibiting the MAPK signaling pathway. *CNS Neurosci Ther*, 2013. 19(3): p. 163-9.
- [14] Monje, M.L., et al., Irradiation induces neural precursor-cell dysfunction. *Nat Med*, 2002. 8(9): p. 955-62.
- [15] Gorman, A.M., et al., Oxidative stress and apoptosis in neurodegeneration. *J Neurol Sci*, 1996. 139 Suppl: p. 45-52.
- [16] Pettmann, B. and C.E. Henderson, Neuronal cell death. *Neuron*, 1998. 20(4): p. 633-47.
- [17] Ramanan, S., et al., Role of PPARs in Radiation-Induced Brain Injury. *PPAR Res*, 2010. 2010: p. 234975.

- [18] Li, Y.Q., et al., Endothelial apoptosis initiates acute blood-brain barrier disruption after ionizing radiation. *Cancer Res*, 2003. 63(18): p. 5950-6.
- [19] Monje, M.L., H. Toda and T.D. Palmer, Inflammatory blockade restores adult hippocampal neurogenesis. *Science*, 2003. 302(5651): p. 1760-5.
- [20] Zhou, H., et al., Fractionated radiation-induced acute encephalopathy in a young rat model: cognitive dysfunction and histologic findings. *AJNR Am J Neuroradiol*, 2011. 32(10): p. 1795-800.
- [21] Wilson, C.M., et al., Radiation-induced astrogliosis and blood-brain barrier damage can be abrogated using anti-TNF treatment. *Int J Radiat Oncol Biol Phys*, 2009. 74(3): p. 934-41.
- [22] Conner, K.R., et al., Effects of the AT1 receptor antagonist L-158,809 on microglia and neurogenesis after fractionated whole-brain irradiation. *Radiat Res*, 2010. 173(1): p. 49-61.
- [23] Moore, A.H., et al., Radiation-induced edema is dependent on cyclooxygenase 2 activity in mouse brain. *Radiat Res*, 2004. 161(2): p. 153-60.
- [24] Lee, W.H., et al., Irradiation induces regionally specific alterations in pro-inflammatory environments in rat brain. *Int J Radiat Biol*, 2010. 86(2): p. 132-44.
- [25] Zhao, W. and M.E. Robbins, Inflammation and chronic oxidative stress in radiation-induced late normal tissue injury: therapeutic implications. *Curr Med Chem*, 2009. 16(2): p. 130-43.
- [26] Persson, H.L., et al., Radiation-induced cell death: importance of lysosomal destabilization. *Biochem J*, 2005. 389(Pt 3): p. 877-84.
- [27] Schultheiss, T.E. and L.C. Stephens, Invited review: permanent radiation myelopathy. *Br J Radiol*, 1992. 65(777): p. 737-53.
- [28] Zhao, W., et al., Administration of the peroxisomal proliferator-activated receptor gamma agonist pioglitazone during fractionated brain irradiation prevents radiation-induced cognitive impairment. *Int J Radiat Oncol Biol Phys*, 2007. 67(1): p. 6-9.
- [29] Zhao, W., D.I. Diz and M.E. Robbins, Oxidative damage pathways in relation to normal tissue injury. *Br J Radiol*, 2007. 80 Spec No 1: p. S23-31.
- [30] Tofilon, P.J. and J.R. Fike, The radioresponse of the central nervous system: a dynamic process. *Radiat Res*, 2000. 153(4): p. 357-70.
- [31] Nakata, H., et al., Early blood-brain barrier disruption after high-dose single-fraction irradiation in rats. *Acta Neurochir (Wien)*, 1995. 136(1-2): p. 82-6; discussion 86-7.
- [32] Palmer, T.D., J. Takahashi and F.H. Gage, The adult rat hippocampus contains primordial neural stem cells. *Mol Cell Neurosci*, 1997. 8(6): p. 389-404.

- [33] Gage, F.H., et al., Multipotent progenitor cells in the adult dentate gyrus. *J Neurobiol*, 1998. 36(2): p. 249-66.
- [34] Machida, M., G. Lonart and R.A. Britten, Low (60 cGy) doses of ⁵⁶Fe HZE-particle radiation lead to a persistent reduction in the glutamatergic readily releasable pool in rat hippocampal synaptosomes. *Radiat Res*, 2010. 174(5): p. 618-23.
- [35] Sundgren, P.C. and Y. Cao, Brain irradiation: effects on normal brain parenchyma and radiation injury. *Neuroimaging Clin N Am*, 2009. 19(4): p. 657-68.
- [36] Ji-yong, Q., Diagnosis, prevention and treatment of radiation brain damage of nasopharyngeal carcinoma patients treated by radiotherapy, L.K.J. Yun-he, L.K.J. Yun-he^Editors. 2006. p. 942-943.
- [37] Gu, B., et al., Radiation-induced Brachial Plexus Injury After Radiotherapy for Nasopharyngeal Carcinoma. *Jpn J Clin Oncol*, 2014. 44(8): p. 736-42.
- [38] Flickinger, J.C., et al., Development of a model to predict permanent symptomatic postradiosurgery injury for arteriovenous malformation patients. Arteriovenous Malformation Radiosurgery Study Group. *Int J Radiat Oncol Biol Phys*, 2000. 46(5): p. 1143-8.
- [39] Kondziolka, D., et al., Radiosurgery with or without whole-brain radiotherapy for brain metastases: the patients' perspective regarding complications. *Am J Clin Oncol*, 2005. 28(2): p. 173-9.
- [40] Sundgren, P.C. and Y. Cao, Brain irradiation: effects on normal brain parenchyma and radiation injury. *Neuroimaging Clin N Am*, 2009. 19(4): p. 657-68.
- [41] Herman, M.A., et al., Neurocognitive and functional assessment of patients with brain metastases: a pilot study. *Am J Clin Oncol*, 2003. 26(3): p. 273-9.
- [42] Chang, E.L., et al., Neurocognition in patients with brain metastases treated with radiosurgery or radiosurgery plus whole-brain irradiation: a randomised controlled trial. *Lancet Oncol*, 2009. 10(11): p. 1037-44.
- [43] Rong, X., et al., Radiation-induced cranial neuropathy in patients with nasopharyngeal carcinoma. A follow-up study. *Strahlenther Onkol*, 2012. 188(3): p. 282-6.
- [44] Zhao, Z., et al., Late-onset radiation-induced optic neuropathy after radiotherapy for nasopharyngeal carcinoma. *J Clin Neurosci*, 2013. 20(5): p. 702-6.
- [45] Qiu, S.J., et al., Proton magnetic resonance spectroscopy for radiation encephalopathy induced by radiotherapy for nasopharyngeal carcinoma. *Nan Fang Yi Ke Da Xue Xue Bao*, 2007. 27(3): p. 241-6.
- [46] Rabin, B.M., et al., Radiation-induced changes in the central nervous system and head and neck. *Radiographics*, 1996. 16(5): p. 1055-72.

- [47] Khong, P.L., et al., White matter anisotropy in post-treatment childhood cancer survivors: preliminary evidence of association with neurocognitive function. *J Clin Oncol*, 2006. 24(6): p. 884-90.
- [48] Dellani, P.R., et al., Late structural alterations of cerebral white matter in long-term survivors of childhood leukemia. *J Magn Reson Imaging*, 2008. 27(6): p. 1250-5.
- [49] Shaw, P.J. and D. Bates, Conservative treatment of delayed cerebral radiation necrosis. *J Neurol Neurosurg Psychiatry*, 1984. 47(12): p. 1338-41.
- [50] Glantz, M.J., et al., Treatment of radiation-induced nervous system injury with heparin and warfarin. *Neurology*, 1994. 44(11): p. 2020-7.
- [51] He, F., et al., Effect of edaravone on Abeta1-40 induced enhancement of voltage-gated calcium channel current. *CNS Neurosci Ther*, 2012. 18(1): p. 89-90.
- [52] Tang, Y., et al., Psychological disorders, cognitive dysfunction and quality of life in nasopharyngeal carcinoma patients with radiation-induced brain injury. *PLoS One*, 2012. 7(6): p. e36529.
- [53] Sezen, O., et al., Vitamin E and L-carnitine, separately or in combination, in the prevention of radiation-induced brain and retinal damages. *Neurosurg Rev*, 2008. 31(2): p. 205-13; discussion 213.
- [54] Brown, W.R., et al., Vascular damage after fractionated whole-brain irradiation in rats. *Radiat Res*, 2005. 164(5): p. 662-8.
- [55] Liu, Y., et al., An experimental study of acute radiation-induced cognitive dysfunction in a young rat model. *AJNR Am J Neuroradiol*, 2010. 31(2): p. 383-7.
- [56] Moulder, J.E., B.L. Fish and E.P. Cohen, ACE inhibitors and AII receptor antagonists in the treatment and prevention of bone marrow transplant nephropathy. *Curr Pharm Des*, 2003. 9(9): p. 737-49.
- [57] Molteni, A., et al., Control of radiation-induced pneumopathy and lung fibrosis by angiotensin-converting enzyme inhibitors and an angiotensin II type 1 receptor blocker. *Int J Radiat Biol*, 2000. 76(4): p. 523-32.
- [58] Jenrow, K.A., et al., Ramipril mitigates radiation-induced impairment of neurogenesis in the rat dentate gyrus. *Radiat Oncol*, 2010. 5: p. 6.
- [59] Lee, T.C., et al., Chronic administration of the angiotensin-converting enzyme inhibitor, ramipril, prevents fractionated whole-brain irradiation-induced perirhinal cortex-dependent cognitive impairment. *Radiat Res*, 2012. 178(1): p. 46-56.
- [60] Shaw, E.G., et al., Phase II study of donepezil in irradiated brain tumor patients: effect on cognitive function, mood, and quality of life. *J Clin Oncol*, 2006. 24(9): p. 1415-20.

- [61] Robbins, M.E., et al., The AT1 receptor antagonist, L-158,809, prevents or ameliorates fractionated whole-brain irradiation-induced cognitive impairment. *Int J Radiat Oncol Biol Phys*, 2009. 73(2): p. 499-505.
- [62] Acharya, M.M., et al., Rescue of radiation-induced cognitive impairment through cranial transplantation of human embryonic stem cells. *Proc Natl Acad Sci U S A*, 2009. 106(45): p. 19150-5.
- [63] Joo, K.M., et al., Trans-differentiation of neural stem cells: a therapeutic mechanism against the radiation induced brain damage. *PLoS One*, 2012. 7(2): p. e25936.
- [64] Gutierrez, A.N., et al., Whole brain radiotherapy with hippocampal avoidance and simultaneously integrated brain metastases boost: a planning study. *Int J Radiat Oncol Biol Phys*, 2007. 69(2): p. 589-97.
- [65] Barani, I.J., et al., Neural stem cell-preserving external-beam radiotherapy of central nervous system malignancies. *Int J Radiat Oncol Biol Phys*, 2007. 68(4): p. 978-85.
- [66] Munck, A.R.P., et al., Photon and proton therapy planning comparison for malignant glioma based on CT, FDG-PET, DTI-MRI and fiber tracking. *Acta Oncol*, 2011. 50(6): p. 777-83.
- [67] Wang, X., C. Hu and A. Eisbruch, Organ-sparing radiation therapy for head and neck cancer. *Nat Rev Clin Oncol*, 2011. 8(11): p. 639-48.
- [68] Matuschek, C., et al., Bevacizumab as a treatment option for radiation-induced cerebral necrosis. *Strahlenther Onkol*, 2011. 187(2): p. 135-9.
- [69] Chuba, P.J., et al., Hyperbaric oxygen therapy for radiation-induced brain injury in children. *Cancer*, 1997. 80(10): p. 2005-12.
- [70] Bui, Q.C., et al., The efficacy of hyperbaric oxygen therapy in the treatment of radiation-induced late side effects. *Int J Radiat Oncol Biol Phys*, 2004. 60(3): p. 871-8.
- [71] Kishi, K., et al., Preferential enhancement of tumor radioresponse by a cyclooxygenase-2 inhibitor. *Cancer Res*, 2000. 60(5): p. 1326-31.
- [72] Siu, A., et al., Radiation necrosis following treatment of high grade glioma--a review of the literature and current understanding. *Acta Neurochir (Wien)*, 2012. 154(2): p. 191-201; discussion 201.

