

# We are IntechOpen, the world's leading publisher of Open Access books Built by scientists, for scientists

4,800

Open access books available

122,000

International authors and editors

135M

Downloads

Our authors are among the

154

Countries delivered to

TOP 1%

most cited scientists

12.2%

Contributors from top 500 universities



WEB OF SCIENCE™

Selection of our books indexed in the Book Citation Index  
in Web of Science™ Core Collection (BKCI)

Interested in publishing with us?  
Contact [book.department@intechopen.com](mailto:book.department@intechopen.com)

Numbers displayed above are based on latest data collected.  
For more information visit [www.intechopen.com](http://www.intechopen.com)



---

# Contemporary Management of Frontal Sinus Injuries and Frontal Bone Fractures

---

Petr Schütz, Hussein Hassan Hamed Ibrahim and Bashar Rajab

Additional information is available at the end of the chapter

<http://dx.doi.org/10.5772/59096>

---

## 1. Introduction

Frontal bone (FB) fractures are found in about 12% of craniomaxillofacial trauma patients. [1, 2] They are more strongly associated with concomitant brain injuries than other facial fractures, which is the reflection of the amount of energy required to produce a fracture in this region. Recently, increase in the incidence of FB fractures was reported, while the incidence of fractures of other facial sites decreased. [3] This increase in frontal bone fractures (FBFs) incidence may be related to the emergence of causes other than road traffic accidents (RTAs), especially all terrain vehicle (ATV) accidents. The aims of FBF treatment are restoration of facial appearance, restoration of skull integrity and protection of brain, and prevention of late complications. The most important factor in management of FBF is involvement of frontal sinus (FS). Despite the relative frequency of FS injuries, there is no general consensus about their optimal management and numerous treatment algorithms were published during the recent years. The purpose of this chapter is to provide an overview of advances in surgical management of traumatized FS and to share our experience with this type of injury.

## 2. Development and growth of the frontal bone

Ossification of the intra-membranous calvarial bones depends on the presence of the brain; in its absence (anencephaly), no bony calvarium forms. A pair of FBs appears from single primary ossification centers, forming in the region of each superciliary arch at the 8th week post-conception. Three pairs of secondary centers appear later in the zygomatic processes, nasal spine and trochlear fossae. Fusion between these centers is complete at 6 to 7 months post-

conception. At birth, the frontal bones are separated by the metopic suture. Synostotic fusion of this suture usually starts about the 2nd year and unites the frontal bones into a single bone by 7 years of age. The metopic suture persists into adulthood in 10 to 15% of skulls. In such cases, the frontal sinuses are absent or hypoplastic. [4]

The cranial and facial bones are first made of fibrous connective tissue. In the third month of fetal development, fibroblasts become more specialized and differentiate into osteoblasts, which produce bone matrix. From each center of ossification, bone growth radiates outward as calcium salts are deposited in the collagen model of the bone. This process is not complete at birth; a baby has areas of fibrous connective tissue remaining between the bones of the skull. These are called fontanel, which permit compression of the baby's head during birth without breaking the still thin cranial bones. The fontanel also permit the growth of the brain after birth. By the age of 2 years, all the fontanel have become ossified. [5]

Growth of the calvarial bones is a combination of suture growth, surface apposition and resorption (remodeling), and centrifugal displacement by the expanding brain. The proportions attributable to the various growth mechanisms vary by age. Accretion to the calvarial bones is predominantly sutural until about the 4th year of life, after which surface apposition and remodeling become increasingly important.

The bones of the newborn calvarium are unilaminar and lack diploë. From about 4 years of age, lamellar compaction of cancellous trabeculae forms the inner and outer tables of the cranial bones. The tables become continuously more distinct into adulthood. This differential bone structure creates a high stiffness - to - weight ratio, with no relative increase in the mineral content of cranial bone from birth to adulthood. Whereas the behavior of the inner table is related primarily to the brain and intracranial pressures, the outer table is more responsive to extracranial muscular and buttressing forces. The internal plate becomes stable at 6 to 7 years of age, reflecting the near cessation of cerebral growth. The thickening of the frontal bone in the midline at the glabella results from separation of the inner and outer tables with invasion of the FS between the cortical plates. Growth of the external plate during childhood produces the superciliary arches and other bony landmarks that are all absent in the neonatal skull. [4]

FS is a small out-pouching at birth and undergoes almost all of its development thereafter. The FS may develop from one or several different sites (primary pneumatization): as a rudiment of the ethmoid air cells, as a mucosal pocket in or near the frontal recess, as an invagination of the frontal recess, or from the superior middle meatus. The process starts 3 to 4 months post conception, but they do not yet invade the frontal bone. Secondary pneumatization takes place between the ages of 6 months to 2 years postnatally and it develops laterally and vertically. FS itself cannot be identified radiographically until approximately the age of 6 to 8 years, and most pneumatization is completed by the time the child is 12 to 16 years- old, but it continues until the age of 40. [4,6] In 10% of persons, FS develops unilaterally, in 5% it is a rudimentary structure, and in 4% it is absent altogether, so that almost one-fifth of individuals have aberrant sinus development (Figure 1).[7]

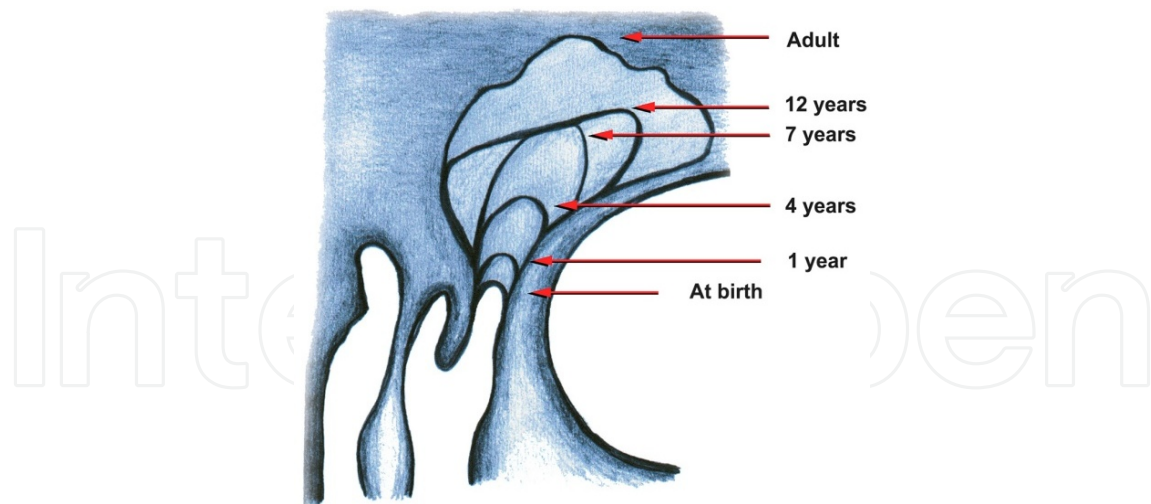


Figure 1. Postnatal development of the frontal sinus.

### 3. Frontal bone anatomy

The frontal bone forms the forehead and the anterior part of the top of the skull, the anterior cranial fossa and the roofs of the orbits. It consists of two parts, vertical called the squamous part and horizontal called the orbital part. From the nasion FB extends approximately 12.5 cm superiorly, 8.0 cm laterally, and 5.5 cm posteriorly. [8]

**The squamous part** has a convex outer surface which forms the main substance of the forehead and the anterior part of the vault of the skull. The squamous part of FB has the nasal notch which articulates with the nasal bone on either side of the middle line and more laterally with the frontal process of maxilla and with the lacrimal bone. The squamous part of the frontal bone consists of two layers of compact bone separated by a layer of cancellous bone (the diploë) which contains red bone marrow and a number of diploic veins.

**Its outer surface** shows the following features:

**Frontal eminences** are the most prominent parts of FB.

**Superciliary arches**, thick curved ridges lie little above the medial portions of the supraorbital margins. They are well developed in males and less marked or even totally absent in females.

**Supraorbital margins**, which form the upper boundaries of the orbits, end laterally at each side in the zygomatic processes of the FB. They have the supraorbital notches at the junctions of the middle and intermediate thirds. In some cases there may be foramina instead of notches. Supratrochlear foramina are located medially to the supraorbital foramina or notches and laterally to the nasal bones. The smooth area of the frontal bone just above the root of the nose is called the glabella. Temporal line, a well-marked ridge, runs from the zygomatic process of FB upward and backward (Figure 2).

**The inner surface** of the squamous part is concave and forms the anterior cranial fossa.



**The sagittal groove** lies in the upper part of the middle line. The two edges of this groove unite below to form a ridge - the frontal crest. The sagittal groove accommodates the anterior part of the venous superior sagittal sinus.

**The frontal crest** gives attachment to the falx cerebri, a fold of dura matter. The frontal crest ends below in a small hole called the foramen caecum between the frontal and the ethmoid bone. The foramen caecum does not usually transmit any structure but may transmit a vein from the nose to the superior sagittal sinus. [5, 8, 9]

**The orbital parts** of the FB extend laterally from the nasal notch, become concave and form the orbital roofs. A spine or concavity exists along the medial anterior orbital roof, where the trochlea of the superior oblique muscle is attached. The arched roofs of the orbits are separated from one another by a median gap called the ethmoid notch. In the intact skull the ethmoid notch is filled by the cribriform plate of ethmoid bone. The margins of the ethmoid notch of the frontal bone contain many half cells which unite with corresponding half cells on the upper surface of the ethmoid bone to form together the ethmoid air cells (Figure 2).

The frontal bone articulates with 12 other cranial bones: two parietals, two nasals, two maxillae, two lacrimal, two zygomatic, the sphenoid and the ethmoid. The bones are separated by sutures which hold the bones firmly together in the mature skull. Occasionally the squamous part of FB may be separated into two halves by a midline metopic suture persistent from early childhood. Normally, two halves of the frontal bone unite completely by the 8th year.

**The arterial blood supply** to the frontal bone is by the supraorbital, anterior superficial temporal, anterior cerebral and middle meningeal arteries. The venous drainage is transosseous through the anastomosis of vessels of the subcutaneous, orbital, and intracranial structures. The primary venous drainage is through the supratrochlear, supraorbital, superficial temporal, frontal diploic (veins of Breschet), superior ophthalmic, and superior sagittal sinuses. [4, 10, 11]

**The frontal sinus** may consist of one or more compartments, depending on the source of pneumatization. The inter-sinus septum, which separates the left and right cavities of the sinus, is continuous with the crista galli and cribriform plate inferiorly. The septum is usually deviating from the midline sagittal plane. FSs vary in size in different people. The average height of the sinuses is 32 mm, and their average width is 26 mm. The surface area is approximately 720 mm<sup>2</sup>. [6-8, 12] The FS is in critical approximation to anatomical structures, which underscores the importance of its management in injury. Posteriorly, the cribriform plate, dura mater, and frontal lobes of brain are in close apposition to one another and to the posterior wall of the sinus. The dura is densely adherent to the deep surface of the posterior table and becomes more adherent and thinner along the caudal edge, where it turns to cover the fovea ethmoidalis. [13] The lateral floor of the FS is the roof of the orbit, whereas the medial floor of the frontal sinus contains the opening of the nasofrontal duct. Each sinus opens into the anterior part of the corresponding nasal middle meatus by the ethmoidal infundibulum or nasofrontal duct (NFD), traversing the anterior part of the ethmoid labyrinth. Anatomically significant variations exist in the width, length, and shape of the NFD. The duct opening usually lies in the posteromedial floor of the sinus. It is a funnel shaped constriction that passes between the

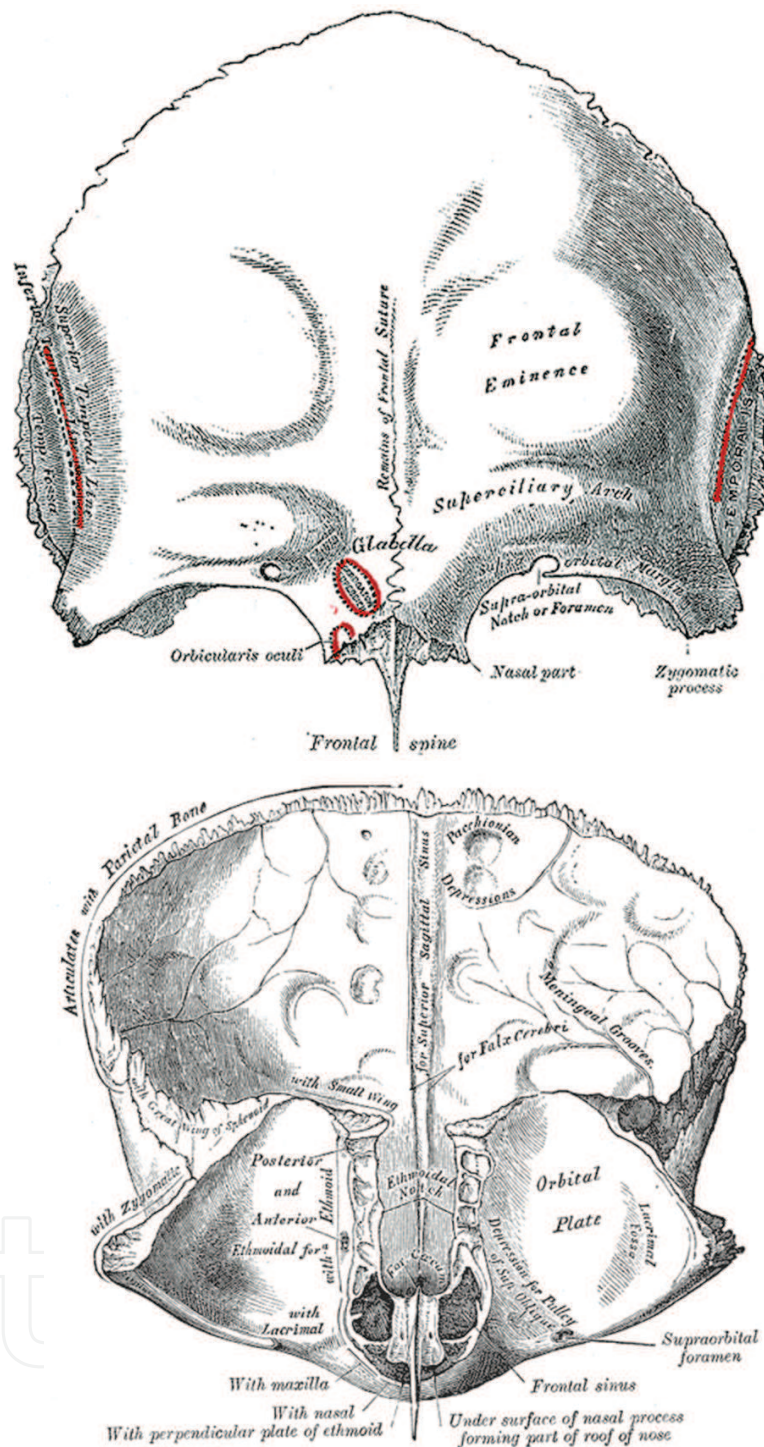
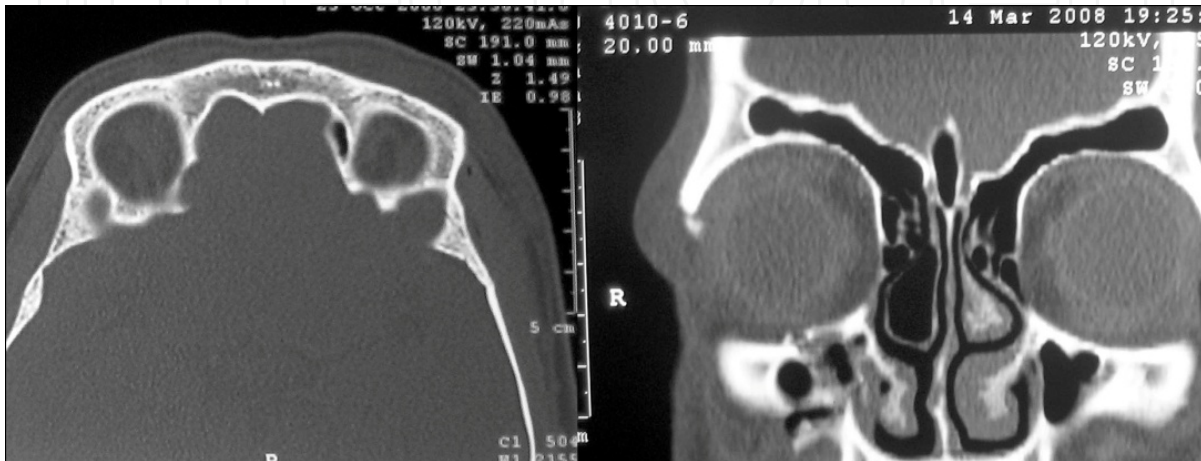


Figure 2. Frontal bone (Gray's Anatomy)

cancellous part of the anterior wall underlying the glabella and the anterior ethmoidal cells. Its course is highly variable, running caudally from a few millimeters to up to 2 cm. The NFD terminates at the unciniate process in the nasal cavity, which is a thin bone plate that is covered on either side by mucosa. When the unciniate process is attached to the lamina papyracea, the drainage is medial to the unciniate process through the middle meatus. This type of drainage

pattern is seen in 66-88 % of cases. When the uncinete process attaches superiorly to more medial structures (middle turbinate, cribriform, or skull base), the drainage of the sinus is lateral to the uncinete process. This type of drainage pattern is seen in 12-34% of cases. A true identifiable duct may be absent in up to 85% of FSs. In this situation, the FS drains indirectly through ethmoid air cells to the middle meatus. Therefore, some investigators chose the term *nasofrontal outflow tract* (NFOT) or *frontal sinus outflow tract* (FSOT) for the drainage path of the FS (Figure 3). [7, 12-18]



**Figure 3.** Opposite extremes of frontal sinus development; aplasia (left) versus hypertrophy (right).

#### 4. Frontal sinus physiology

The mucosa of the frontal sinus consists of pseudostratified ciliated epithelium, mucus producing goblet cells, a thin basement membrane, and a thin lamina propria that contains seromucous glands. It covers the entire surface of the sinus and ranges in thickness from 0.07 to 2.0 mm. When the mucosa is healthy, a blanket of mucin overlies the epithelium. The cilia beat at 250 cycles/min. The mucin blanket flows in a spiral fashion in a medial-to-lateral direction; the flow is slowest at the roof and fastest at the NFD. The mucin empties at the NFD at a daily rate of 5.0 g/cm<sup>2</sup>. [14, 19, 20,]

The frontal sinus is unique in that it is the only sinus that has a recirculation phenomenon. The mucus travels along the lateral side of the sinus and turns medially over the sinus floor and down the lateral frontal recess wall. Of the secretion, 60% is directed back into the sinus cavity as it reaches the frontal recess. [13] Clinically significant anatomical structures of the mucosa of the frontal sinus are the foramina of Breschet, first described over 60 years ago. These foramina are sites of venous drainage of the mucosa and can serve as the route of intracranial spread of infection. The mucosa is found deeply penetrating these foramina. If mucosa is not completely removed microscopically from these foramina in obliteration or cranialization procedures, there is a high risk of mucocele formation. [13]

## 5. Frontal sinus pathology and concept of “safe sinus”

Pathology of FS is rare but most commonly is associated with trauma, which causes fracture of the frontal sinus walls.

Fractures of FS have many forms and a variety of classifications. Basically, they can be classified as anterior or posterior wall fractures. These fractures can be simple with no displacement, or complex displaced and comminuted with or without brain injury. Displaced anterior wall fracture usually leads to a simple aesthetic deformity. Posterior wall fracture usually results from high impact injury and bears a risk of placing the intracranial content in direct communication with the nasal cavity. A complicating factor is involvement of the NFOT. Its obstruction can lead to mucus retention and late infectious complications. [21]

A more detailed classification of the frontal sinus fractures which is suggested by many authors [22-25] and can be as follows:

### **Anterior wall fractures:**

Anterior wall fractures with no displacement

Anterior wall fractures with displacement and intact FSOT.

Anterior wall fracture with displacement and FSOT injury.

### **Posterior wall fractures:**

Posterior wall fracture without displacement and no cerebro-spinal fluid (CSF) leak.

Posterior wall fractures without displacement and positive CSF leak.

Posterior wall fracture with displacement and no CSF leak.

Posterior wall fracture with displacement and positive CSF leak.

Infection of the sinus, which causes sinusitis, may give rise to serious complications due to the proximity of FS to the cranial cavity, orbit, and nasal cavity. Complications can develop into orbital cellulitis, epidural abscess, subdural abscess, meningitis, and in long-term into mucopyocele.

Mucocele formation is a complication, which can develop years after trauma and the symptoms may go unnoticed for a long period of time. [26] Therefore it is desirable to treat injured FS in such way as to make it “safe”. This means either to obliterate it completely including all mucosa lining, or to restore it to the functional state with unobstructed NFOT.

## 6. Diagnosis of frontal bone fracture

### 6.1. Physical examination

Findings suggestive of FBF include tenderness, paresthesia, forehead abrasions, lacerations, contour irregularities and hematoma. Forehead lacerations should be examined under sterile



conditions to assess the integrity of the underlying bone. Through-and-through injuries of the frontal sinus have high morbidity, and prompt surgical treatment is indicated. Conscious patients should be questioned regarding the presence of watery rhinorrhea or salty-tasting postnasal dripping suspicious for CSF leak. Suspicious fluid can be grossly evaluated bedside with a "halo test". The bloody fluid is allowed to drip onto filter paper. If CSF is present, it will diffuse faster than blood and result in a clear halo around the blood. Glucose or  $\beta$ 2-transferrin are the laboratory tests to confirm a CSF leak. [27]

## 6.2. Radiological examination

Plain radiographs do not adequately characterize FS fractures. Computed tomography (CT) is the gold standard for the assessment of FS injuries. Advances in the equipment used for CT imaging can now produce reformatted images of a very high quality. Patients are scanned in one axial plane, in a supine position with thin cut spiral CT, creating data set allowing generation of reformatted and reconstructed diagnostic images. Sagittal reconstructions can be made to evaluate the posterior wall defect. Special importance belongs to evaluation of the involvement and severity FSOT. [28]

Gross outflow tract obstruction (fracture fragments lying in the tract) can be observed in some cases. FSOT injury is strongly suggested when the CT scan demonstrates the involvement of the base of FS, the anterior ethmoid complex, or both. Fracture in the floor of the sinus can be seen best with sagittal and coronal views, anterior ethmoid cell injury with coronal more than axial views, and obstruction best with the coronal view (occasionally axial). Thus, the nasofrontal tract complex should be evaluated in the axial, coronal and sagittal planes. Unfortunately, the involvement of the FSOT is not always easily discernible with CT imaging. [16] Three-dimensional (3D) reconstructions may help to visualize the external contour deformity as well as associated facial skeleton injuries.

## 7. Historic development of operative methods

The evolution of surgical methods dealing with diseased or injured FS is described in several publications. The following summary is based on synopsis of two of them [1, 13]. In the preantibiotic era frontal sinusitis and its complications were fearsome, with high morbidity and mortality secondary to intracranial spread. The first reported procedure on FS for a mucopyocele was performed by *Wells* in 1870. Operations of limited extent involved puncturing the anterior table, some with limited removal of the mucosa, packing of the sinus or creation of an external draining sinus tract.

In 1898 *Reidel* first described ablation of the anterior sinus wall. This radical, disfiguring operation involved removal of the frontal bone and supraorbital bar to the posterior table of the frontal sinus. *Killian* modified this approach in 1904 by preserving the supraorbital rims to improve the patient's appearance but still removing the anterior table and contents of FS and then collapsing the skin to the posterior table of FS. The Killian procedure produced less disfigurement but had significant rates of failure because of persistent disease at the naso-

frontal ducts and incomplete removal of all FS mucosa. The next significant advance was the *Lynch* operation, described in 1921. The floor of FS and ethmoids were removed and the mucosa extirpated through a medial periorbital incision in an effort to re-establish drainage. Complete removal of the mucosa via this approach proved difficult. Disappointing results were also due to re-stenosis of NFD, either by scarring or by herniation of the orbital tissues into the created communication with the nasal cavity. Several modifications using stents and mucoperiosteal flaps were devised later in an attempt to maintain patency of this artificial conduit.

In 1955, *Bergara and Itoiz* described the osteoplastic approach, which consisted of first defining the extent of FS and then elevating the anterior sinus wall on an inferior pedicle of periosteum. This provided adequate surgical access to allow for visualization and complete removal of the sinus mucosa and obliteration of the remaining sinus with autologous free fat grafts. It also improved forehead cosmesis. The osteoplastic flap operation has been subsequently modified for use in trauma of the frontal sinus by elevating the pericranium with the scalp flap and exploring the frontal sinus by removal of the free bone fragments.

Later studies published by *Goodale* (1958) and *Montgomery* (1964) recognized the importance of NFD injury and popularized obliteration of FS with autologous fat. A variety of materials such as bone, muscle, fascia, and hydroxyapatite have been successfully used to obliterate the sinus cavity by later authors. In 1974, *Nadell and Kline* described a procedure to primarily reconstruct depressed frontal skull fractures involving the sinus and cribriform plates.

*Donald and Bernstein* (1982) described a cranialization, procedure in which the intracranial contents were isolated from the nose and the sinus was completely ablated. They validated this approach in a cat model by demonstrating respiratory mucosa regrowth and an infection rate of 44% with untreated posterior table defects.

## 8. Surgical approaches to frontal bone

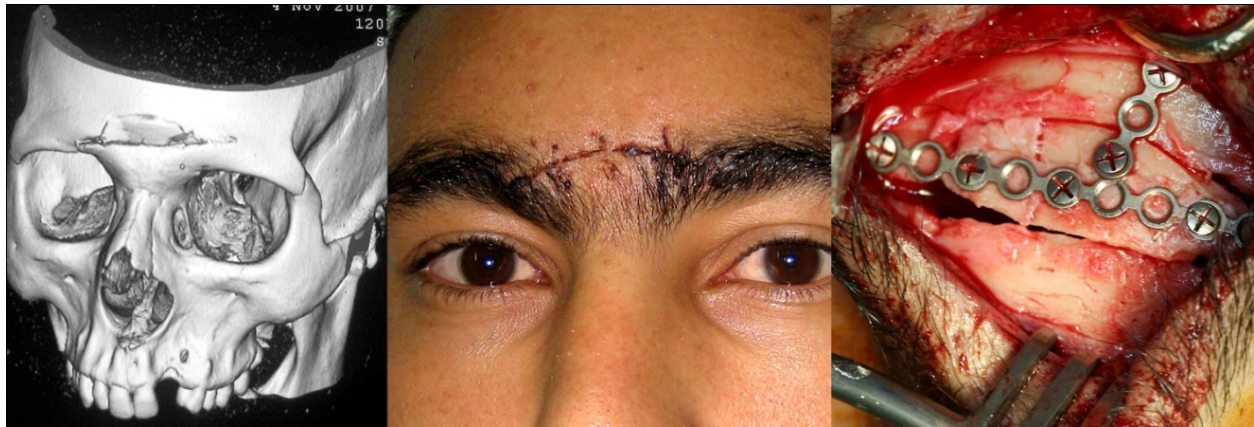### 8.1. Traumatic wounds

Only in exceptional cases an existing traumatic wound can be used to address an isolated fracture of the anterior FS wall. It can be considered in limited injuries without involvement of the FSOT and/or the medial orbital rim, in the absence of other associated regional cranio-facial injuries (Figure 4). [13]

### 8.2. Coronal incision

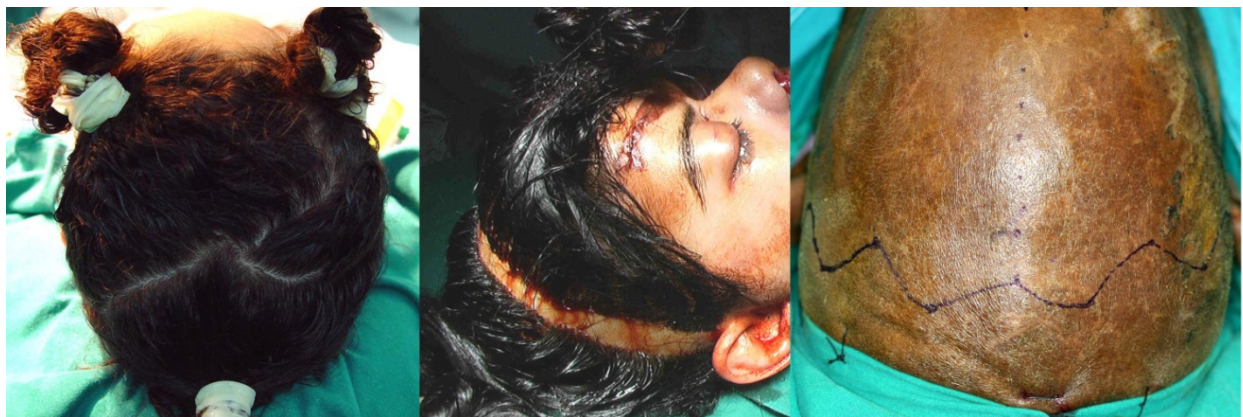The main purpose of coronal approach is to avoid visible facial scars. Coronal incision more or less follows the course of the coronal suture of the neurocranium, which joins FB to the parietal bones. Therefore in the literature frequently encountered term *bicoronal incision* is a misnomer, because there is just one coronal suture on the skull. Acceptable alternative term is *bitemporal incision*. The extent and design of the incision depends on the targeted anatomic area and intended surgical procedure. A fully developed coronal flap with preauricular or post-auricular extensions provides access to FB, zygomatic arches, bodies of the zygomatic bones,





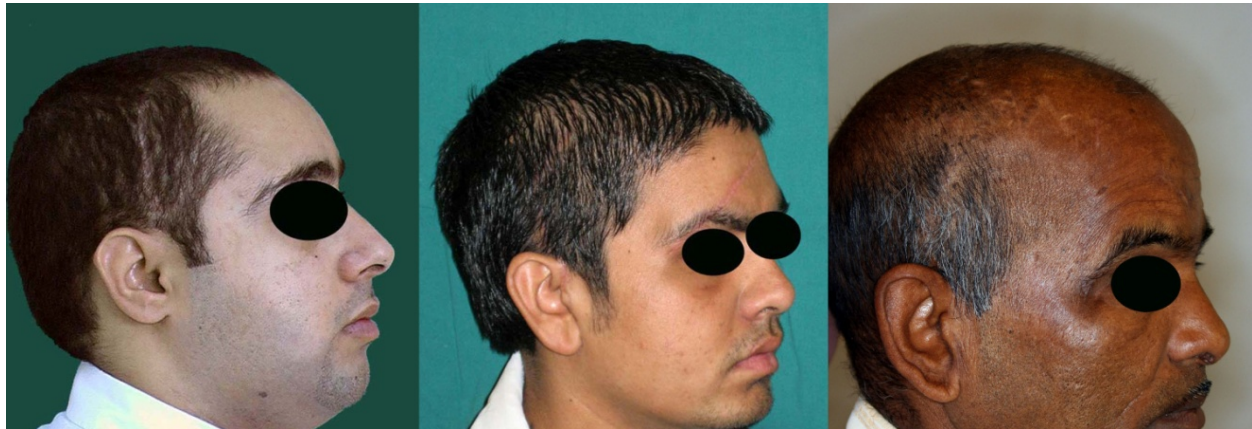**Figure 4.** Industrial accident; re-opening of traumatic wound for fracture exposure

medial, superior and lateral orbital margins and much of the corresponding orbital walls, as well as nasal bones. Via preauricular extension it is possible to address the temporomandibular joint and the upper neck of the condylar process of the mandible. Coronal incision also allows harvesting of calvarial bone grafts. There is general agreement that it is not necessary to shave the hair, however shaving facilitates wound closure. In female patients with long hair, who are understandably more distressed by prospect of hair shaving, the hair can be divided by a comb and braided. Alternatively, 2 cm wide strip of shaven skin is sufficient. In consenting male patients there is no harm in a complete hair shave, which makes suturing of the flap much more comfortable and subsequent wound care easier and more hygienic (Figure 5).



**Figure 5.** Scalp preparation for coronal incision: hair braiding, strip shaving and full head shave.

After proper skin disinfection and draping the planned line of incision is marked with a surgical pen. The incision line runs from ear to ear across the top of the head in either straight, anteriorly curved, sinusoid or zigzag fashion. There is always some hair loss in the incision line and the scar is much less prominent if it is not straight, especially in a patient with a short hair-cut and when the hair is wet (Figure 6).



**Figure 6.** Straight incision is more prominent in closely cropped hair, while zigzag incision gives good results even in bald scalps.

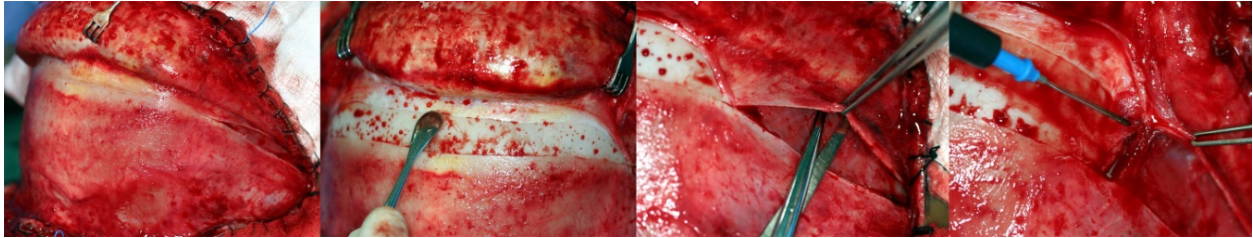
The inferior extent of the incision depends on the target region. When desired exposure is limited FB, it is sufficient to confine the incision to the level of upper ear attachment. The placement of the incision line should take into consideration future balding patterns in men, and anterior migration of the scar due to growth of the cranium in young children. There is no advantage in placing the incision more ventrally, because the extent of exposure is given by the caudal extent of the incision: the lowest points define the axis around which the flap will rotate. Sufficient dorsal extension will also preserve the deep branch of the supraorbital nerve and avoid sensory loss behind a too-anteriorly placed incision. It is desirable to make the incision of the scalp parallel to the hair follicles. Avoiding the transection of hair follicles avoids alopecia at the edges of the wound. [13]

Vascularization of the scalp is very rich and due to the presence of subcutaneous fibrous septa the vessels gape and bleed profusely when cut. To reduce the initial bleeding and make establishment of the proper dissection level easier, the sub-galeal layer is infiltrated with saline or diluted local anesthetic with vasoconstrictor (e.g. adrenalin 1:200 000). The incision starts on the top of the head and progresses step by step latero-caudally to both sides, while arresting bleeding after each step. Hemostasis is mainly achieved by compression of wound margins by Raney clips, Tessier scalp clamps, or running interlocking silk sutures. Use of electrocautery should be minimized and only bipolar coagulation should be employed to protect hair follicles.

The three superficial layers of the scalp (skin, subcutaneous layer and galeal aponeurotica) make up one functional unit. [29] The incision penetrates through these layers and stops just above the pericranium inside the fourth layer of loose areolar tissue (subgalea fascia). Dissection inside this level is initially facilitated by undermining the incision line with a spreading hemostat. Below the superior temporal line the galea continues as temporoparietal fascia. The dissection should be kept below this fascia, just on the top of temporalis fascia, which can be identified as a tough white glistening layer. Branches of superficial temporal artery and vein are usually transected here and need to be ligated or cauterized. After the whole length of the incision has been developed to the proper depth, the scalp is pulled forward with a pair of cat



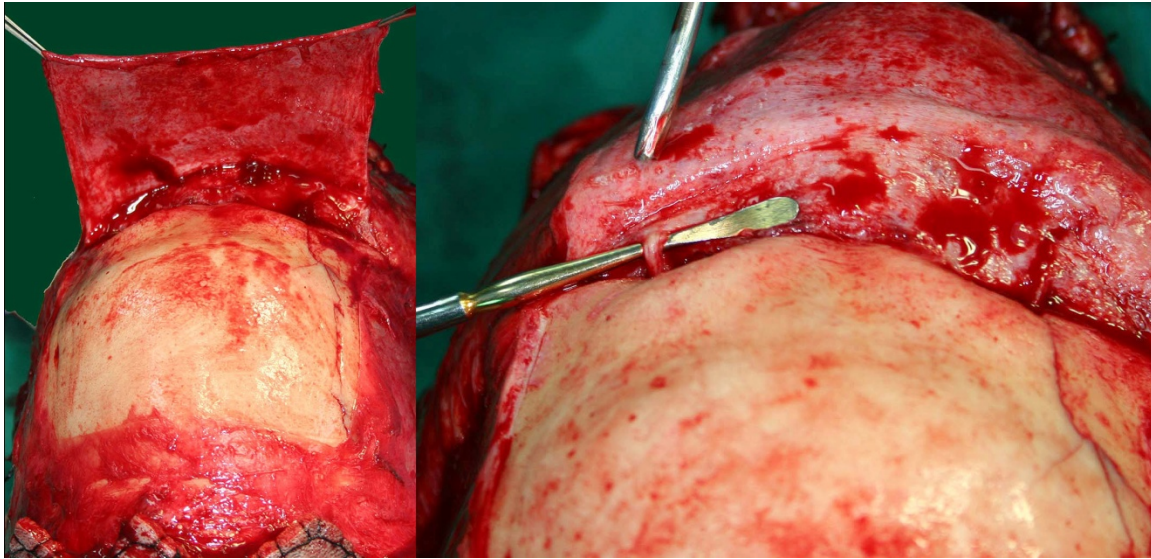
paw retractors and the flap is dissected further by reverse cutting with a large blade until it can be turned inside out (Figure 7).



**Figure 7.** Dissection of coronal flap: subperiosteal dissection over top of skull, dissection under temporalis fascia below the level of the temporal line. In this case pericranial flap is not developed.

Anterior dissection progresses to the point where the base of the flap dissected so far reaches a 45° angle with the zygomatic arches. The temporal and zygomatic branches of the facial nerve leave the parotid gland and cross close to the periosteum of the zygomatic arch into the temporoparietal fascia, 15–28 mm ventral to the external acoustic meatus. [30] To protect them, further dissection in the temporal areas must continue under the temporalis fascia. The temporalis fascia is incised over the root of the zygoma and the incision progresses firstly through the external leaflet of fascia, just over the temporal fat pad. Above the line of fusion of external and deep layer of temporalis fascia the dissection progressed just above the temporalis muscle fibers, alongside the base of the developing flap, to the superior temporal line. At this point it is necessary to consider if a pericranial flap will be needed for anterior cranial fossa repair or sinus obliteration. If this is the case, its design must be incorporated into the periosteal dissection instead of cutting the periosteum straight across the frontal bone. If pericranial flap is not needed, right and left incisions in the temporalis fascia are connected by incising the pericranium between them. The forward dissection of the coronal flap continues in the subpericranial level, then subfascial level over the temporalis muscles and temporalis fat pads. The connection between the periosteum and temporalis fascia at the superior temporal line is firmly adherent to the underlying bone and requires sharp dissection, which is best done by diathermy in cutting mode (Figure 8).

When the dissection reaches the orbital margins, careful attention is paid to identification and freeing of the supraorbital neurovascular bundles. This is easy if only supraorbital notches are present. If the bundles pass through supraorbital foramina, these must be converted into notches by resecting the foramina's inferior margins with a fine chisel. The periosteum must be subsequently elevated beyond the orbital margin and inside the orbital cavity to allow free retraction of the flap. [31] The contentious point of the above described technique is the dissection in the temporal area. If the dissection proceeds as described, it jeopardizes innervation and vascularization of the temporal fat pad. It can lead to postoperative temporal hollowing as a consequence of a fat atrophy. [13] For this reason some authors prefer to keep the dissection completely above temporalis fascia, but “maintaining the integrity of tempor-



**Figure 8.** Elevation of pericranial flap and release of supraorbital nerve.

oparietal fascia” to protect the facial nerve branches. [32] To overcome this dilemma between jeopardizing either the facial nerve or temporal fat pad, *Luo et al.* recently described an alternative dissection technique: the supratemporalis approach. The temporal fascia was incised 5-6 cm up the zygomatic arch. The flap was composed of skin, subcutaneous fat, temporoparietal fascia, temporal fascia, and temporal fat pad on the surface of the temporalis muscle. The authors operated 40 cases with no temporal fossa depression observed in any of them. [33]

### 8.3. Alternative skin incisions

The coronal scalp approach provides excellent operative field exposure and results in a hidden scar. However, it is also associated with certain disadvantages and complications. These include longer operating times, increased blood loss, scalp hematoma, postoperative infection, a large scar with related alopecia, potential injury to the branches of the facial nerve with frontalis muscle paresis and brow ptosis, injury to auriculotemporal, supraorbital and supratrochlear nerves with numbness and paresthesia, parietal scalp pain, temporal fossa depression, scar irregularities and ptosis of facial soft tissues. [13, 34, 35] In attempts to avoid these problems different simplified methods of surgical access were reported for management of uncomplicated anterior table FS fractures. If the posterior table is involved then the technique is contraindicated. Also FSOT must be intact. Careful selection of patients is vital. A small skin incision can be made parallel to the margin of the eyebrow to approach the fracture. It is often possible to introduce a small periosteal elevator through the inferior edge of the fracture. If this is not possible, a 5 mm burr hole is created near or on the fracture site. A narrow periosteal elevator is introduced into FS and fracture is reduced with careful pressure. The bony opening may be used to confirm adequate reduction endoscopically. [34] A similar technique with wider exposure of fracture utilizes an upper blepharoplasty incision. [44] Another alternative approach is incision through the frontalis rhytid crease. [36]

## 9. Current operative methods of frontal sinus management

According to the clinical presentation of the fractures, treatment can range from reconstruction of the sinus walls to obliteration or cranialization. The degree of the displacement of the fracture and the involvement of FSOT and/or the brain will determine the type of management of the fracture.

### 9.1. Reconstruction of frontal sinus

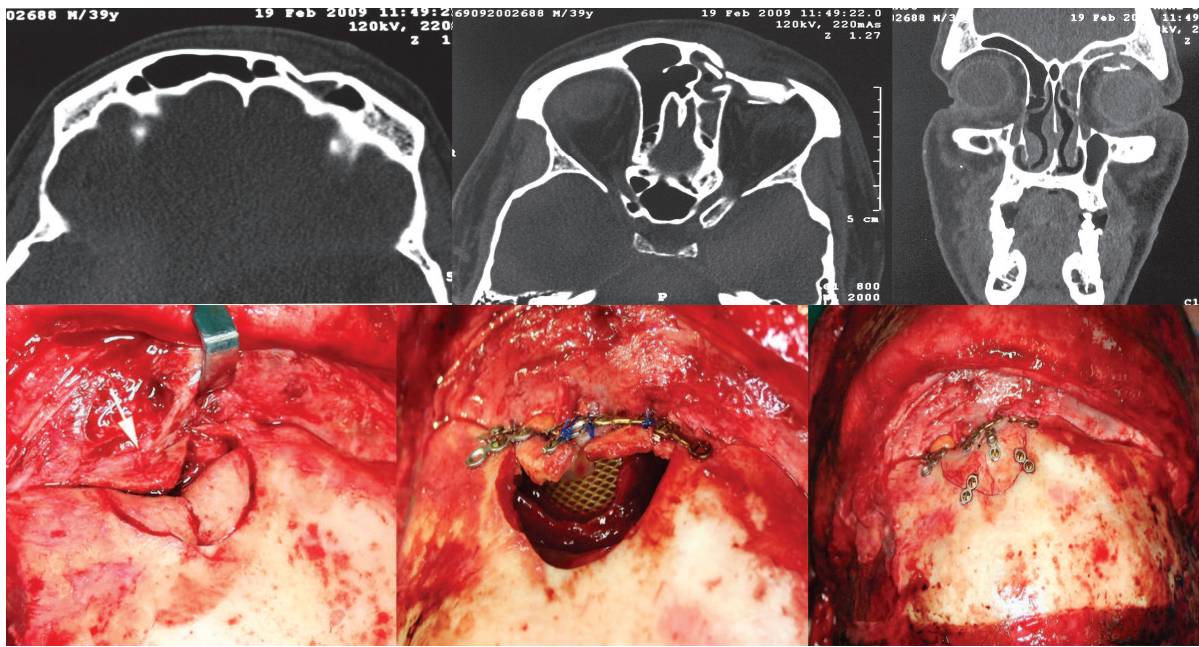
Common treatment for simple FS fracture without FSOT involvement requires adequate surgical exposure, an anatomic reduction and plating. Frontal sinus function and anatomy can be preserved this way in the majority of cases. [1]

#### 9.1.1. Open methods

The surgical approach is usually through coronal incision or alternatively through existing lacerations if access is adequate. [37] After complete exposure of the fracture it is necessary to remove fragments of the anterior sinus wall to gain unobstructed access and to be able to evaluate integrity of posterior sinus wall, FSOT and sinus mucosa. In case of comminuted fracture with multiple fragments these can be lifted using periosteal elevator or small bone hook. Reduction of noncomminuted, compressed fractures can be challenging. When the convex surface of the frontal bone is fractured, it goes through a compression phase before it becomes concave. Fracture reduction requires enough force to pull the bone fragments back through the compression phase. [38] It may be necessary to remove bone from fracture line using cutting burr and widen it to gain enough space and relieve pressure for lifting of impacted fragment. It can be helpful to place a screw in the depressed segment, grasp it with a heavy hemostat, and pull upward - technique similar to use of Carrol-Girard screw for zygoma reduction. It is important to record orientation of removed fragments to prevent confusion during reassembly. Placing the fragments atop a drawing of the fracture will help to maintain the anatomic orientation of each fragment. Damaged or diseased mucosa of sinus should be removed as well as mucosa covering mobilized fragments, but intact mucosa should be left undisturbed.

FSOT can be visually evaluated and if there is doubt about its patency, it can be tested by application of fluorescein or diluted methylene blue followed by inspection of nasal contents. Any suspicion of blockage of FSOT as evidenced by preoperative imaging studies or by intraoperative inspection and testing warrants treatment by sinus obliteration. Sinus preservation with duct reconstruction with the help of drainage tube or stent has been attempted in the past [39-41]. Unfortunately, a rate of stenosis of the duct following stent removal can be as high as 30%. [28] Recently there has been tendency to preserve and reconstruct sinuses despite injuries of FSOT with the help of endoscopic sinus surgery (ESS). [42] The final step is reassembly of fragments and reconstruction of anterior sinus wall using microplates or miniplates. Small gaps (4 to 10 mm) can be reconstructed with titanium mesh (Figure 9). [38]





**Figure 9.** Fracture of FS with displacement of fragment into left orbit. Fragment is impinging on levator palpebrae superioris and displacing the globe. Reconstruction of orbital roof with titanium mesh after removal of the fragment.

### 9.1.2. Endoscopic methods

Throughout all surgical fields, less invasive approaches have been employed to decrease the potential morbidity of traditional open procedures. Endoscopic procedures and their applications for management of FS fractures allow for more conservative management and sinus preservation in selected patients. [43] Trephination and endoscopic visualization of FS can be useful to assess the frontal recess as well as the extent of any posterior table injury. Skin incision is placed midway between the medial canthus and the glabella and a small cutting burr is used to open a 4- to 5-mm frontal sinusotomy. The posterior table and nasofrontal recess can be examined with a 0-degree and/or 30-degree endoscope. A Valsalva maneuver can assist with the diagnosis of a CSF leak. [44, 45]

*Shumrick* reported on endoscopic reduction of FS fractures on 19 patients. The author's technique is similar endoscopic forehead lifting, with one central and two lateral hairline incisions. The forehead soft tissues are elevated subperiosteally, and the fractures are visualized by means of a 30-degree endoscope. An attempt is made to elevate the fragments with endoscopic elevators. However, it is usually necessary to approach the fragments directly through small forehead incisions (preferably hidden in the brow). The fractures are elevated using percutaneous nerve hooks, or by drilling into the fragments and grabbing them with threaded Steinmann pins. With gentle retraction, the fragments often elevate into a reduced position and are stable without the need for rigid fixation. Residual surface irregularities can be camouflaged with patches of Vicryl mesh. In four patients endoscopic fracture repair was unsuccessful, the fracture segments were unstable. These cases were converted to an open approach with coronal incisions and rigid fixation. The described technique is appropriate



only for anterior wall FS fractures that have several large segments without extensive comminution. [44]

Alternative technique of endoscopic transnasal reduction in combination with balloon support has also been reported. [45]

Endoscopic technique can also be used for camouflage of cosmetic deformity resulting from untreated depressed anterior table FS fractures above the orbital rim. The repair is performed 2 to 4 months after the injury when all forehead swelling has resolved. A 3-5 cm parasagittal working incision should be placed above the fracture, 3 cm behind the hairline and carried through the periosteum onto bone. A 1-2 cm subperiosteal endoscope incision is then placed at the same height, 6 cm medial to the working incision. Using an endoscopic brow lift elevator and external palpation, subperiosteal dissection is performed down to the level of the fracture and the periosteum is carefully elevated over the defect. Once the limits of the fracture have been visualized, alloplastic implant is fitted to the defect and fixed with self-drilling screws transcutaneously. [38]

Another usage of endoscopic surgery is reestablishing of patency of compromised FSOT. The endoscopic surgery can be either part of primary FS management or can be kept in reserve for delayed FSOT recanalization, should the obstruction develop or not resolve postoperatively. [42, 45]

## 9.2. Obliteration of the frontal sinus

The principle of FS obliteration is turning it into self-contained cavity devoid completely of mucosa, including microscopic remnants and extensions into pits of Breschet, and filling it by choice of material, or leaving it empty for spontaneous ossification. After gaining satisfactory access through some of the above mentioned surgical approaches, the anterior wall of sinus is removed and preserved for later reconstruction. This can be achieved by careful removal of fractured fragments. It is important to record orientation of removed fragments to prevent confusion during reassembly. Placing the fragments atop a drawing of the fracture will help to maintain the anatomic orientation of each fragment. With incomplete fractures, it is often necessary to remove the intact remainder of the anterior table or to perform formal frontal sinusotomy. To keep the bone cut within the confine of FS and prevent violation of intracranial space, it is necessary to mark the extent of the sinus. This can be done using pre-prepared sterilized film cut out or tin template based on posteroanterior skull x-ray in Caldwell projection with the patient placed 1.8 meters (6 feet) from the x-ray tube. [46] Alternatively, one tine of a two-pronged instrument, like tweezers, artery forceps or bipolar cautery can be placed through defect or trephination on each side of the anterior table. The internal tine is then used to probe the periphery of the sinus, while the outer tine is used to mark its outline. Another technique involves trans-illumination with a light source inserted into a fracture line. [38] Intraoperative navigation is the most accurate but requires specialized equipment. Sometimes it is possible to preserve contralateral FS if the contralateral sinus is not injured and the interlining septum remains intact. After the limits of the sinus have been defined, mini-plates can be pre-applied, spanning the osteotomy site. This allows accurate re-approximation of the bone fragments at the end of the procedure. During osteotomy, a burr or a saw should

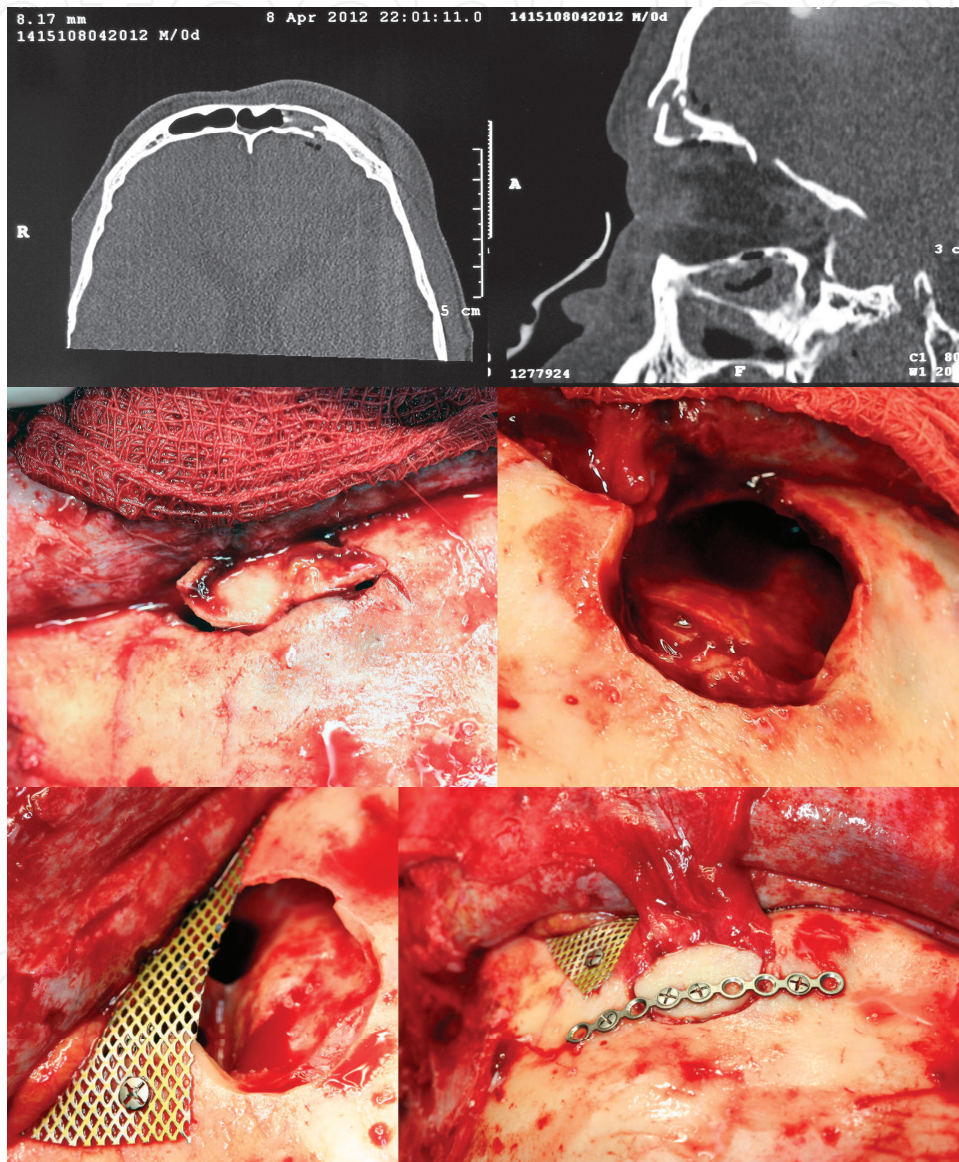
be angled toward the sinus cavity to avoid intracranial penetration. Care should be taken to avoid obliteration of the predrilled miniplate holes while performing the osteotomy. After complete exposure of the sinus, integrity of the posterior table is evaluated. If it is stable and free of large defects, sinus obliteration is acceptable. All sinus mucosa must be meticulously removed from all walls of the sinus. This applies also to temporarily removed fractured or osteotomized segments of anterior sinus wall. Inner walls of FS are reduced with a large cutting burr and smaller diamond burrs, as the surgeon proceeds deeper into the sinus. Access to the peripheral extensions of the sinus, especially above the orbital roofs, can be extremely difficult in patients with pronounced pneumatization. Special attention must be paid to the scalloped areas deep in the sinus. If the orbital roof has significant convexity, it may be necessary to remove a portion of the roof to gain access the posterior sinus mucosa. After complete removal of the sinus mucosa, the mucosa of the FS infundibulum is elevated and inverted into the frontal recess. A small temporalis muscle or pericranium plug is then placed over the FSOT to obliterate it. It can be held in place by packed oxycellulose (Surgicel®) or fibrin glue. Finally two bone chips obtained from the calvarium can be inserted to complete isolation of FS from the nasal cavity. [38] The FSOT can be further secured using the pedicled pericranial flap, which is rotated into the sinus. The rest of the sinus is packed with autologous or alloplastic material and anterior wall of FS is reassembled and stabilized with titanium miniplates. A number of autogenous and alloplastic materials have been used as fillers in FS obliteration.

**Autogenous fat** is probably the most widely used and has the longest tradition [47]. The advantages of fat grafts include ease of harvest, minimal donor site morbidity, ample available volume, and favorable handling characteristics. However, complication rate was reported as high as 18% [48]. Magnetic resonance study 24 months post-operatively found vital fatty tissue in only 6 out of 11 cases of obliteration of FS via an osteoplastic approach. Fatty necrosis occurred five times; whereas in four cases a transformation into granulation tissue and in one case into connective tissue could be seen [49]. The harvest of the fat is performed using sterile technique: the surgeon will rescrub and a separate set of instruments that have not come in contact with the infected field is used. A transverse incision is made in the left lower abdominal quadrant, and subcutaneous fat is removed. Alternatively, a periumbilical incision can also be made. Bleeding is controlled using monopolar cautery, but excessive cauterization should be avoided because it may harm the fat cells and result in graft failure. Drainage of the abdomen is usually not necessary. [46]

**Autogenous muscle** graft harvested from temporalis muscle has advantage of being located within the operative field and being available in adequate volume. Like autogenous fat graft, this nonvascularized graft undergoes necrosis and eventual replacement by fibrous tissue. Donor site morbidity, including temporal hollowing and trismus, is unacceptable. [37]

**Autogenous bone** graft for FS obliteration was first described in 1969 [50]. Since then, cancellous bone grafts, most often harvested from the ilium, have been widely used as a filler material. Cancellous bone promotes re-ossification from both the periphery of the defect and centrally. The main contributions of the grafts are their osteoconductive properties and osteoinductive factors that are released from them during the process of resorption. [51] Another advantage of cancellous bone over adipose or muscle tissue for obliteration is that it

is easier to distinguish radiographically in postoperative period between resorption, infection, and mucocele formation.[13,37] The greatest disadvantage to the use of cancellous bone grafts lies with the potential donor site morbidity. [52] Much more comfortable and safer is to harvest bone chips from adjacent calvarium. It can be done using bone scraper. In case the harvested amount of bone is not sufficient for filling of a large sinus, it can be augmented by admixture of bone substitute such as demineralized bone matrix (Figure 10) [53].



**Figure 10.** Fracture of left FS with minimal defect in posterior sinus wall and displacement of supraorbital rim. Reconstruction with titanium mesh and obliteration of the left FS with small pericranial flap.

**Pericranial flap** has been widely used in anterior cranial fossa repair, reconstruction of the middle third of face defects, full-thickness scalp defects, and orbital defects. It is composed of the skull periosteum and the subgaleal fascia. The anteriorly based flap receives its blood supply from the supraorbital and supratrochlear arteries. Branches of the superficial temporal



artery supply the laterally based flap. In contrast to all other avascular grafts used for sinus obliteration, the anteriorly based pericranial flap is composed of a well-vascularized tissue. The high vascularity makes this flap less prone to infections and turns it into an ideal method for obliteration of an infected cavity in a contaminated surgical field. [54]

**Allografts** like lyophilized cartilage [55] have the advantage of unlimited availability and lack of donor site morbidity. They are easy to handle, well adaptable to the defect, and thus reduce the operative time. Nevertheless, a failure in revascularization or subsequent osseointegration may occur, with associated risk of infection and extrusion [56]. Allogenic transplantation may be associated with increased risk of transmitting such diseases as hepatitis, AIDS or bovine spongiform encephalopathy.

**Alloplastic materials.** *Methyl methacrylate* has been widely used alloplastic material since its introduction in 1940. It is well tolerated by soft tissues and has a density similar to bone, low thermal conductivity, and acceptable strength. However, the material produces a significant exothermic reaction during polymerization and foreign body reaction has been noted when it is polymerized in contact with tissue. [57]

**Hydroxyapatite** is a nonceramic calcium phosphate substance (*BoneSource, Stryker Leibinger*). It has osteoconductive properties, may be contoured to a defect, adheres to adjacent bone, has the ability to resist mucosal ingrowth, is resistant to infection, and is gradually replaced by native bone without a loss of volume. It has been investigated in experimental and clinical frontal sinus obliteration, but no long term observation results were reported [58]. Currently the use of hydroxyapatite cement in FS is not recommended. Significant problems related to material failure have been reported. [37]

**Glass-ionomer cement** is a hybrid glass polymer composite consisting of inorganic glass particles in an insoluble hydrogel matrix and bonded by ionic cross-links, hydrogen bridges, and chain entanglements. It is widely used in dentistry and also has been used in frontal sinus reconstruction [59]. However, because of severe complications after using glass ionomer cement next to dura mater this material has been taken off the market. [51]

**Proplast**, a polytetrafluoroethylene (*Teflon*) polymer with vitreous carbon fibers with pore sizes of 200 to 500  $\mu\text{m}$ , is extremely porous to body fluids. Fibrous tissue ingrowth occurs rapidly and acts to mechanically stabilize the material. The material can cause a mild foreign body reaction. [51, 60]

**Glass ceramic** (*bioactive glass*) has proved biocompatible, non-toxic and bone conducting material for occlusion of bone cavities. Total accurate obliteration of the sinus is achieved with different sizes of granules and blocks. Uneventful recovery and clinical outcome were seen in 92% of patients. Histopathological samples revealed a healing process progressing from the fibrous tissue phase to bone formation with scattered fibrous tissue and granule remnants. Bone produced by replacement of material was similar to natural frontal bone. Microbiologic cultures obtained with histological samples revealed no growth of bacteria. [61, 62]

**Spontaneous obliteration** was reported long ago by Samoilenko (1913), who found obliteration by osteofibrous ingrowth in an experimental study on cats and dogs. His results were

confirmed by later experimental studies that found subsequent replacement of obliterated FSs by cancellous bone to a variable degree. [51] Because FS after removal of all of its mucosa and occluding the nasofrontal duct is nothing more than an isolated bone cavity, it is not irrational to expect its gradual ossification. [63]

### 9.3. Cranialization of the frontal sinus

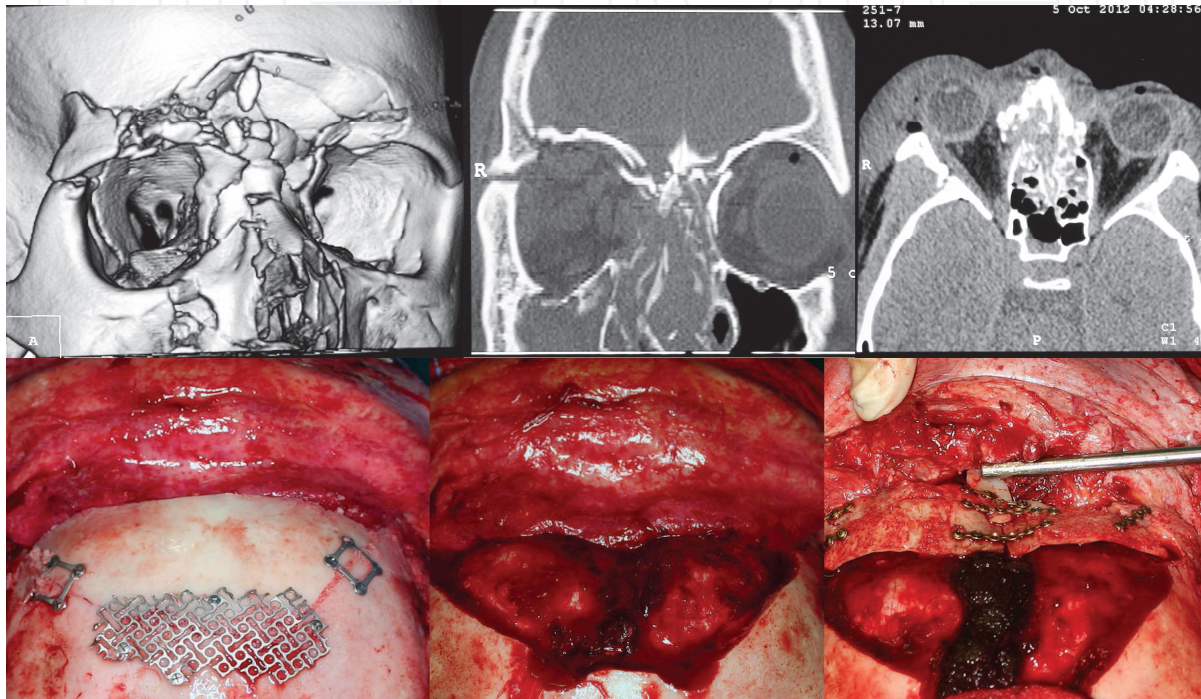
Cranialization is the most radical method of FS management. It can be considered an extension of obliteration procedure with complete removal of the posterior table. In effect, it increases the volume of anterior cranial fossa at the expense of cranialized FS, and the brain is allowed to expand into this additional extradural dead space. Because intracranial space is entered, and there is a possibility of encountering dura and brain injury, cranialization should always be performed in cooperation with a neurosurgeon. The approach to FS cranialization should be as a rule performed via a coronal incision. This approach provides wide access to the entire upper facial skeleton, allowing repair of associated naso-orbito-ethmoid fractures. Furthermore, it allows dissection of a pericranial flap and harvesting of split calvarial bone grafts when necessary. [32] Maintaining integrity of the pericranial flap is critical for isolation of expanded intracranial space from FSOT and ethmoid cells.

Cranialization can be achieved either through sinusotomy as described in previous segment dealing with FS obliteration [13], or through frontal craniotomy. The choice is usually dependent on the degree of brain damage and preference of the neurosurgeon. [39]

In the former case, once access to the posterior table has been achieved, this is removed carefully in pieces with a rongeur. Larger pieces are saved in moist gauze for possible use replacing defects in the anterior table, instead of separately harvested bone grafts. When the dura is exposed, any adherent posterior table bone fragments should be carefully dissected off. The brain should be gently retracted and the remaining posterior table bone is then removed using straight and angled (Kerrison) rongeurs. Small overhangs at the periphery of the sinus should be smoothed completely, using a cutting burrs and the posterior table edge should be made flush with the anterior sinus walls, floor, and anterior cranial fossa. [32]

In most cases cranialization is performed through frontal craniotomy. This will allow thorough evaluation and repair of dural lacerations, immediate reconstruction of the orbital roof, medial orbital wall, or naso-orbito-ethmoidal fractures. [37] If a craniotomy has been performed, the portions of the posterior table associated with the craniotomy bone flap can be removed easily and safely, working on a sterile side table. [32] Also split calvarial bone grafts can be harvested from inner compacta of the craniotomy bone flap. Care should be taken during craniotomy to maintain the integrity of the cribriform plate and to avoid injury to the sagittal sinus. Once all the sinus mucosa and the posterior bony table have been removed the nonviable bone, soft tissue or damaged brain, are debrided and dural lacerations repaired. The next step is a reconstruction of the orbital roof, naso-orbital-ethmoid complex, or cribriform plate/fovea ethmoidalis, as necessary. Establishing a secure barrier between the cranial fossa and the nose is mandatory to prevent CSF leak and meningitis, but also to prevent ascending regrowth of the sinonasal mucosa with late mucocele. The frontal recess and FSOT are occluded as previously described in FS obliteration. Pericranial flap is sutured as far back as possible to

the cranial base dura over the anterior cranial fossa to provide additional isolating layer of vascularized tissue. Because the wide pedicle of this flap will prevent the access to supraorbital rims, glabella and nasal skeleton, osteosynthesis of these parts must be completed first. A small bony defect (slit) must be left between supraorbital rims and inferior margin of repositioned craniotomy flap to prevent compression and ischemia of the pericranial flap. After repositioning of craniotomy flap the anterior table of FS is reconstructed as described in FS reconstruction section previously (Figure 11).



**Figure 11.** Severe comminuted fracture involving anterior cranial fossa, supraorbital rims and naso-orbito-ethmoidal complex. Nasal dorsum, supraorbital rims and glabella are reconstructed with bone grafts harvested from inner corticis of craniotomy flap. Pericranial flap covers anterior cranial fossa.

## 10. Indications and treatment algorithms

Injured FS can be managed in four basic ways: 1-observation, 2-exploration and fracture reduction without or with internal fixation, 3- obliteration and 4-cranialization. [13] The choice of method is dependent on following factors:

- a. Involvement of anterior, posterior or both walls of the sinus.
- b. Degree of displacement and comminution.
- c. Involvement and patency of fronto-nasal communication - FSOT.
- d. Involvement and degree of displacement of sinus floor – orbital roof.
- e. Presence or absence of CSF leak.



#### f. Associated neurological injuries

Other circumstances important for treatment planning are associated facial injuries, patient's general health condition, expected compliance and availability for follow-up, as well as availability of specialized services that could help in solving complications, namely endoscopic sinus surgery.

Degree and combination of anterior and posterior table, with or without FSOT involvement, would best help to determine the management protocol for FSFs, from observation to surgery [28, 38].

Improvement in diagnostic imaging, especially introduction of CT, and surgical technology has led to a wide variety of philosophies, protocols, and procedures. There is no universal agreement as to how the best achieve treatment goals, and no consensus on when surgical intervention is indicated. The choice of surgical method largely depends on the extent of the injury, the status of the FSOT and presence or absence of CSF leak. [63, 64] Most surgeons agree that nondisplaced fractures should be treated non-operatively. Management of patients with more complex injuries remains controversial. Many of the previously published reports are of poor quality (level 4 evidence) and represent retrospective case series consisting of highly censored samples with little reference given to exclusion or inclusion criteria. Additionally, most previous reports fail to include patients who were treated non-operatively, so little is known about the outcome of these patients or the relative frequency of procedures in the context of a population of trauma patients. [1]

#### 10.1. Anterior table fractures without FSOT involvement

Nondisplaced or minimally displaced (less 2 mm) anterior table fractures can be observed. The risk of an aesthetic deformity increases with the degree of displacement (>2 mm). An endoscopic repair or repair through alternative skin incision may be indicated in this patient population. However, many authors found it to be technically challenging.

Another option is to assess the degree of deformity after all facial edema has resolved. At this point, the patient can make an informed decision as to whether he/she desires surgical intervention, which can be endoscopic camouflage. A significant number of patients will opt for no surgical intervention. [27]

More complex anterior table fractures and those extending below the orbital rim may require open reduction using a coronal incision. The presence of improperly reduced bone segments, comminuted sequestrae, foreign bodies, devitalized and torn sinus mucosa expose the patient to a greater risk of infectious complications. [39] Reconstruction of the anterior wall using miniplates is a procedure virtually free of significant complications when the FSOT is patent.

#### 10.2. Anterior table fractures with FSOT involvement

This is the point, where controversy about appropriate treatment of FS injuries begins. The traditional treatment for FS fractures with FSOT involvement is obliteration followed by anterior table reconstruction. [23,64] Some authors are not only strong proponents of obliteration

ation, but employ this method also for some cases on nondisplaced anterior table fractures with FSOT involvement and even cranialize patients with nondisplaced and displaced fractures with FSOT involvement. [65]

On the other hand, the advancement in endoscopic surgery of frontal recess and modern imaging has enabled sinus preservation as a viable alternative to FS obliteration in cases with suspected FSOT involvement in the fracture. High-resolution, thin-section CT with sagittal reformatting may evaluate the involvement and severity of injury of the FSOT preoperatively and help in planning of its management. Sinus preservation may apply for displaced anterior wall FS fractures, even with concomitant minimally displaced posterior wall fractures, and without significant intracranial injury or persistent CSF leak. [28]

*Thong and Lee* [42] reported on primary endoscopic management. Patients with depressed anterior table FS fractures that involved FSOT were managed by ORIF via a coronal incision plus endoscopic fronto-ethmoidectomy with removal of any obstructing bony fragments, and insertion of a stent into the fronto-ethmoidal recess. Middle meatal nasal packs were left in situ for 1 week and patients were discharged home with prophylactic antibiotics. Frontal stents were removed after 1 month. Patients were followed up by regular endoscopic surveillance and CT scans were performed annually. There were no complications.

*Smith et al.* [45] treated 14 patients with FS and concurrent facial fractures. Seven patients were included in the modified treatment algorithm. Postoperatively, 5 patients had spontaneous FS ventilation. Two patients, both of whom had naso-orbito-ethmoid fractures, had persistent FSOT obstruction. These patients were successfully managed with an endoscopic FS procedure. The decision to repair, obliterate, or cranialize the sinus is often made intraoperatively, based on the extent of FSOT obstruction found during the procedure. [37]

### 10.3. Posterior table fractures

The primary decision criteria for surgical intervention are the degree of fracture displacement and the presence of a CSF leak. Traditionally as a rule of thumb, a width of the posterior table displacement is considered significant. [14, 32]

#### 10.3.1. Fractures without significant displacement

Patients with posterior table displacement less than one table width and no CSF leak may be observed. Long-term follow-up with repeat CT scans at 2 months and 1 year is appropriate to rule out mucocele formation. If a CSF leak is present at time of injury, 1 week of observation is indicated; 50% will resolve spontaneously. The methods of conservative treatment include complete bed rest with oral acetazolamide 250 mg every 8 hours, prescription of laxatives and prophylactic antibiotics, and avoidance of breath holding and straining. Acetazolamide is a carbonic anhydrase inhibitor and is intended to reduce CSF secretion. Laxatives are given to prevent increases in intracranial pressure caused by constipation, and antibiotics to prevent infection. CSF drainage can be performed if the patient has intracranial infection or rapid leakage. Persistent leak openings in the posterior wall of the frontal sinus warrant repair via

craniotomy. CT cisternography facilitate highly accurate preoperative localization of the fistula. [66]

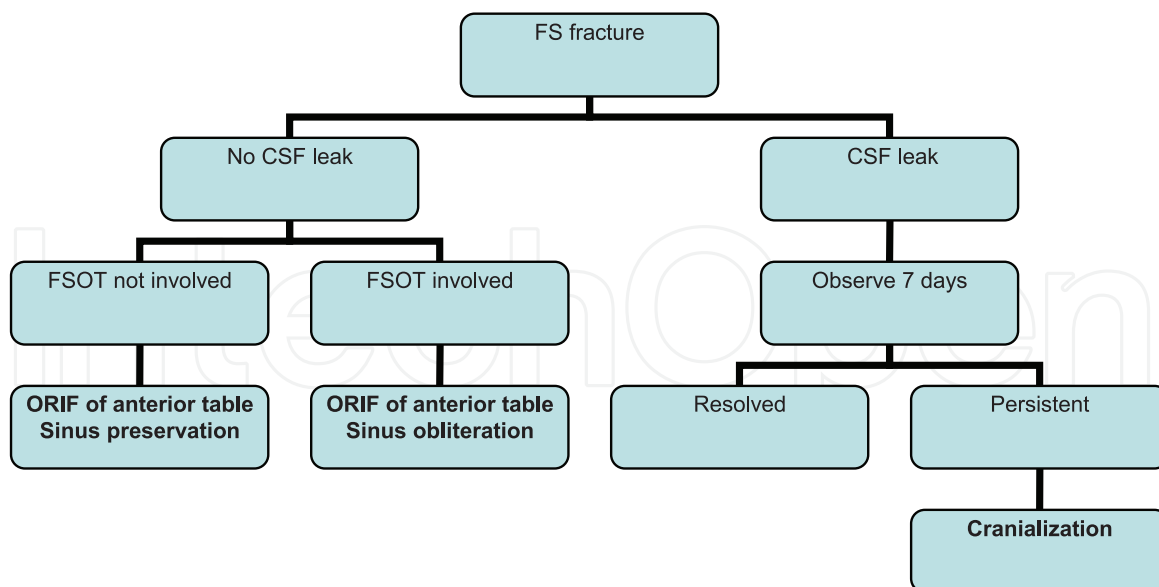
### 10.3.2. Fractures with significant displacement

Patients with posterior table displacement greater than one table width, no CSF leak, and only mild comminution should be considered for sinus obliteration. More severe injuries, with a frank CSF leak and/or moderate to severe comminution, will likely require removal of posterior table bone to repair the dural tear. If the injury or surgical repair results in disruption of more than 25 to 30% of the posterior table, sinus cranialization should be considered. [32]

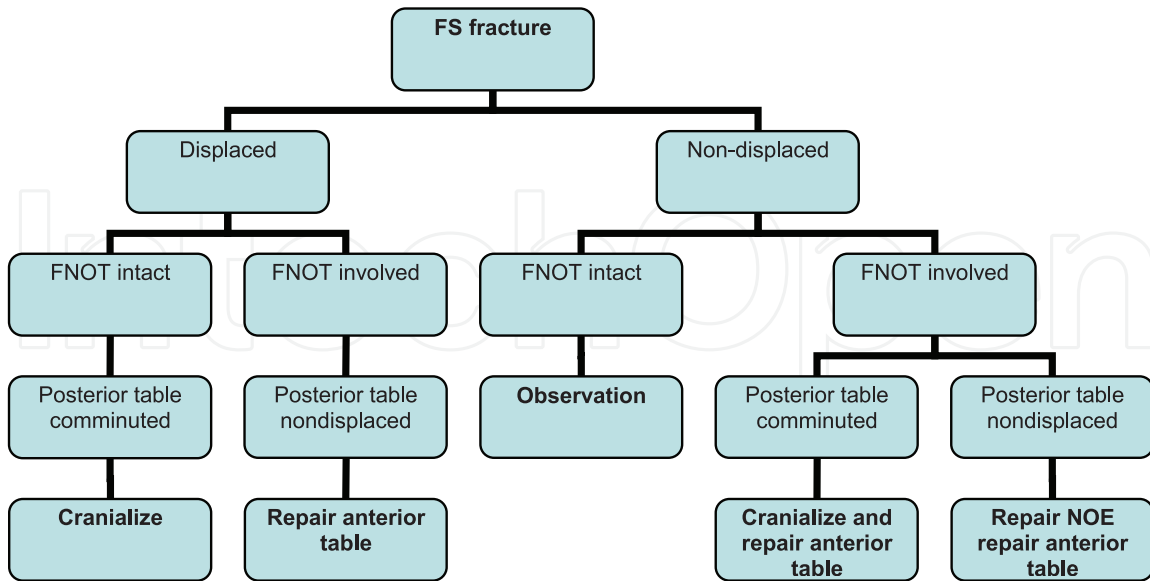
## 10.4. Treatment algorithms

In an effort to optimize functional and cosmetic outcomes in complex clinical situations, while minimizing serious short- and long-term sequelae, algorithms were developed to determine which patients should receive operative intervention and which frontal sinus procedure is most appropriate in a given case. Following are examples of such algorithms placing emphasis on different aspects of FSF characteristics:

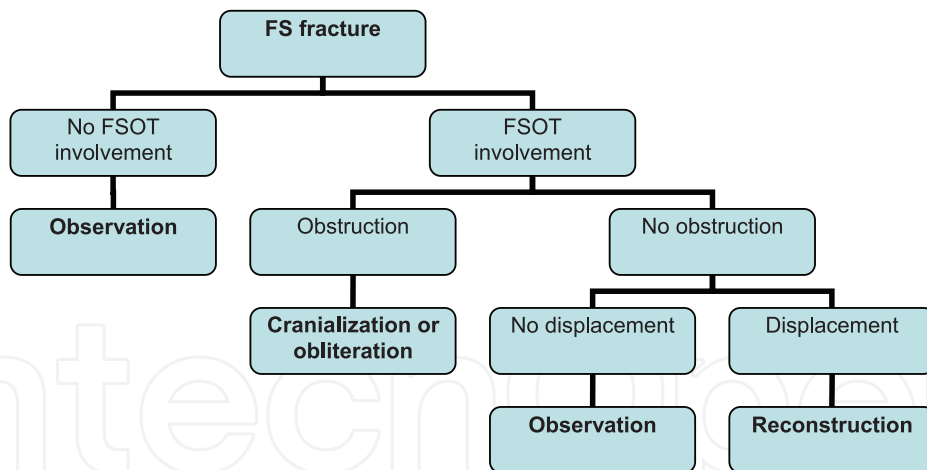
It seems to be obvious that all these algorithms are to some extent simplified. To develop algorithm taking into account all possible characteristics and circumstances would probably result in a too -complicated diagram.



According to Chen et al., 2006 [64]



According to Bell et al., 2007 [37]



According to Rodriguez et al., 2008 [65]

## 11. Complications of frontal sinus fractures

Frontal sinus fractures carry a risk of complications, which can be characterized as early or late. Complication rates for patients with FS fractures range from 10% to 17%. [67] The most

serious are early infectious complications that can endanger patient's life. There is a greater urgency of operative treatment in cases where intracranial infection can develop through potential communication of the neurocranium with the non-sterile sinuses. Bellamy et al. [68] found that delay in repair beyond 48 hours was associated with a greater than fourfold increased risk of serious infection, even when controlling for clinical and statistical confounders. However, FS fracture patients often present with other, more severe intracranial and bodily injuries. Thus, definitive management is often delayed until the patient's neurologic and medical condition has stabilized. Several additional factors are associated with serious infection, among them use of an external cerebrospinal fluid drainage catheter and soft-tissue infection that predisposes to deeper infection in these patients.

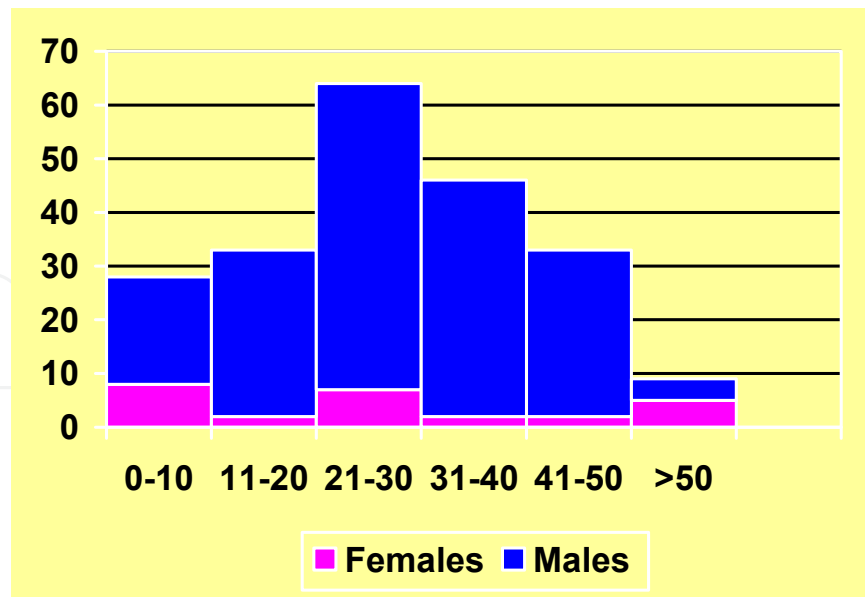
The recommendation of 7-days waiting period for management of persistent CSF leaks was borne out of historical studies that predate the modern research. According to recent opinion, there is no evidence to support 7 days as a particularly important threshold for cerebrospinal fluid leak management to prevent intracranial infection. [68]

The efficacy of antibiotic prophylaxis, especially beyond the perioperative period, in frontal sinus and skull base injury remains unclear. The risks of antibiotic use, evolving drug resistances and associated patient and epidemiologic costs require careful evaluation. To date, there is no standard of care for postoperative antibiotic administration, though many surgeons continue to administer antibiotics beyond the immediate perioperative period.[68] A variety of adverse events can occur after fixation of a frontal sinus fracture, such as frontal sinusitis, mucocele, mucopyocele, cerebrospinal fluid leakage, deformity, hardware infection, headache, and chronic pain in the area of the injury.[67] Potentially life threatening late complications include thrombosis of the cavernous sinus, encephalitis, mucopyocele, or brain abscess. [21] In the literature there is no consensus regarding the follow-up. Because of the possible long period after trauma until complications, namely mucocele, develops, some advise to continue to follow these patients for a lifetime. Others suggest a follow-up period of 5 or 7 years. [26]

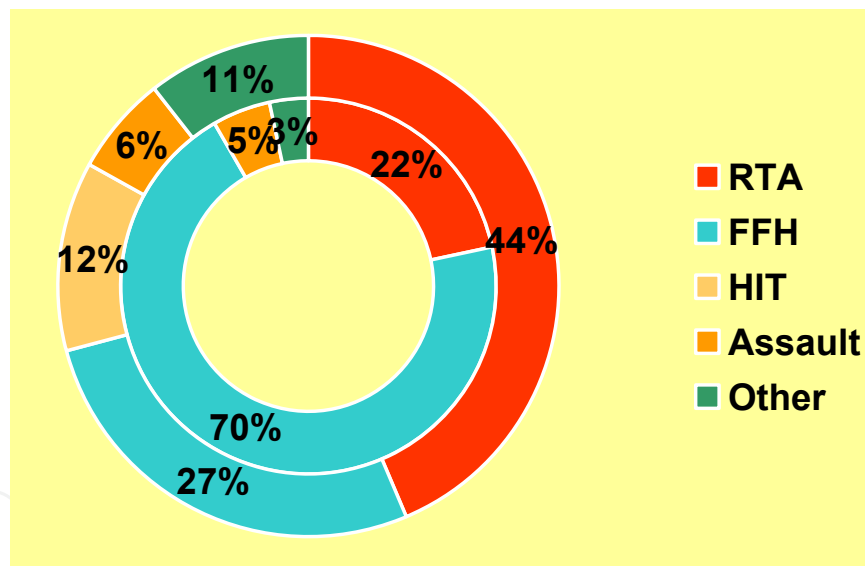
## **12. Our experience in treatment of frontal bone fractures**

### **12.1. Patients' demographics**

During a period of 10 years beginning from 2004 we treated 188 males (90%) and 22 females (10%) admitted with diagnosis of FBF. The most frequent etiology overall was road traffic accidents (43%), followed by falls from heights (26%) and impact of fast moving objects (11%). Fifty injuries (24%) were work-related, most of them falls from heights at construction sites. However, in females 70% of accidents were caused by falls from heights. These female patients were mostly domestic helpers, who either tried to commit suicide or avoid abuse (Graphs 1 and 2).



Graph 1. Age and sex distribution



Graph 2. Etiology distribution by sex: males; outer circle, females; inner circle

### 12.2. Associated injuries

Solitary FBF was found in 116 patients, 82 patients suffered concomitant midfacial fracture(s), 3 patients associated mandibular fracture and 9 patients had panfacial fractures. Central nervous injury was found in 80 patients, of whom 11 died. Seven of these fatalities were polytraumatized with multiple non-head fractures and internal organ injuries. Non-head injuries were found altogether in 74 patients. Serious ocular injuries (bulbus rupture and/or traumatic optic neuropathy) were present in 14 patients (below).



Brain injury, contusion, edema, bleeding (died)	80 (11)
Non-facial fractures (spine)	68 (17)
Eye injuries	14
Internal organ injuries	9

### 12.3. Our classification scheme

We founded our classification solely on CT examination. We did not attempt to include involvement of FSOT, because its CT evaluation is often not reliable. Decisions based on status of FSOT were done intraoperatively. We had five types namely:

Type 1	Outside frontal sinus (Figure 12)
Type 2	Non-displaced, involving one or both frontal sinus walls (Figure 13)
Type 3	Displaced anterior sinus wall, posterior wall intact or nondisplaced (Figure 14)
Type 4	Displaced anterior + posterior sinus wall (Figure 15)
Type 5	Displaced posterior sinus wall, anterior wall intact or non-displaced (Figure 16)

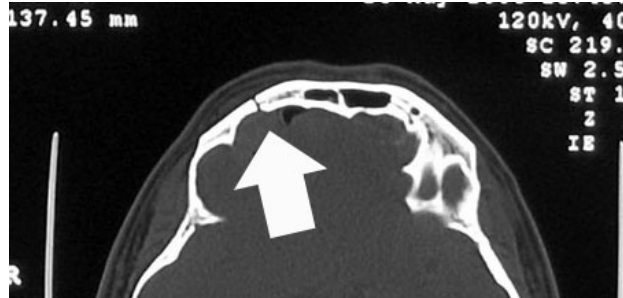


Figure 12. Type 1: fracture outside sinus.

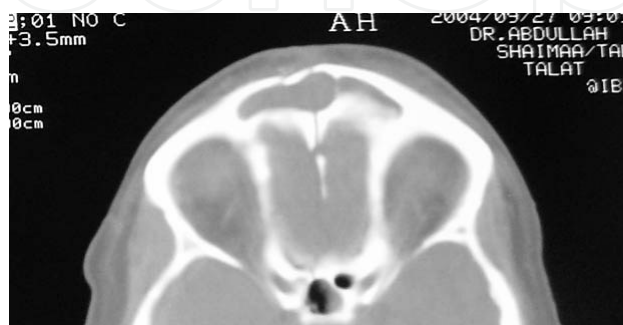

Figure 13. Type 2: nondisplaced fracture involving anterior and/or posterior sinus wall.

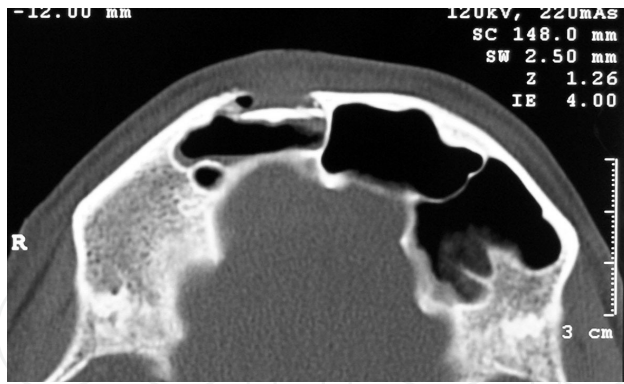


Figure 14. Type 3: displaced fracture of anterior sinus wall with posterior sinus wall intact or undisplaced.

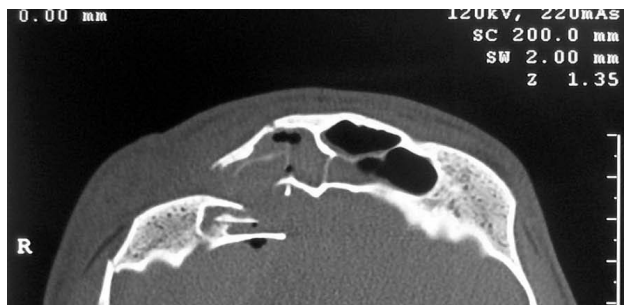
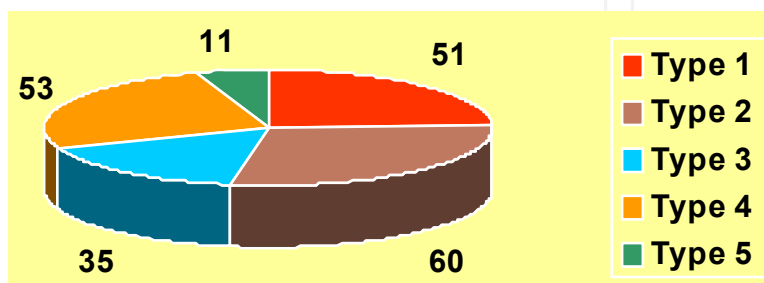


Figure 15. Type 4: displaced fracture of both anterior and posterior sinus walls.

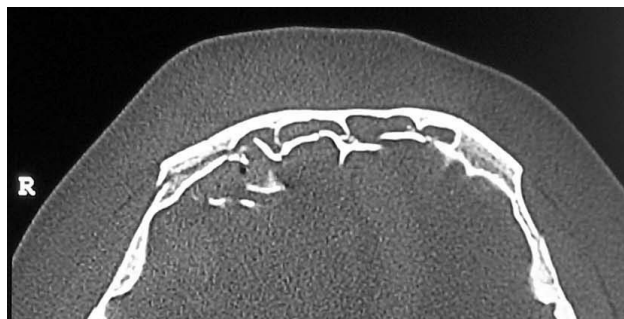

Figure 16. Type 5: displaced and comminuted posterior sinus wall with anterior wall intact or nondisplaced.



Graph 3. Distribution by types of fracture.

## 12.4. Surgical procedures

From patients with **Type 1** injuries 4 patients died due to concomitant CNS trauma. Two patients were operated: both of them were children with severe disruption of FB and the purpose of surgeries was to repair calvarial defects. Only one patient from **Type 2** group was operated to remove a foreign body from the FS. In patients with **Type 3** fractures, there was the highest relative incidence of operative treatment: 24 patients were operated with 1 sinus obliteration and 23 anterior wall reconstructions.

**Type 4** group had 33 operated patients, 31 of them received cranialization and 2 obliteration of FS. Dural tears were found in 21 patients in this group despite only 5 cases of CSF leak noticed preoperatively.

**Type 5** group had the lowest relative incidence of operated cases and only 4 patients were operated. In five cases we were not able to reach an agreement with neurosurgery service about the indication to operate. The overview of operative treatment and reasons for not operating cases are given in the following table.

Type	No.	CSF leak	CNS injury	Other injuries	Operated	Died	Refused	Unfit	Transfer	Neurosurgeon Disagree
1	51	2	18	20	2	4	-	-	-	-
2	60	0	18	23	1	0	-	-	-	-
3	35	0	6	6	24	0	7	4	-	-
4	53	5	33	19	33	7	6	3	3	1
5	11	1	5	0	4	0	1	1	-	5
$\Sigma$	210	8	80	68	64	11	14	8	3	6

## 12.5. Discussion

Surprisingly, only one of our operated patients developed an early infectious complication-soft tissue abscess in the vicinity of the orbital rim, which responded to local incision and antibiotic treatment. The other 2 patients had persistent postoperative CSF leakage and were successfully treated by lumbar drain and bed rest. Similar to other studies we were not able to maintain long term follow-up in the majority of operated cases, not mentioning conservatively managed cases. Supposedly, had serious complication developed and the patient was still living in Kuwait, he/she would have looked for help in our unit, like other maxillofacial trauma patients, who are usually refused even simple tooth extraction in other facilities other than ours once the patient's trauma history is known to a care provider.

We recognize the importance of close cooperation with the neurosurgery service in instances of cranio-facial injuries. However, we sometimes run into difficulties when deciding on indications for operative treatment in patients who are in good general condition and without signs of external deformity or CSF leakage. These are mainly patients with type 5 injuries. More

often than not a neurosurgeon takes only short term perspective on a case without consideration of possible development of late complications many years later.

## Author details

Petr Schütz\*, Hussein Hassan Hamed Ibrahim and Bashar Rajab

\*Address all correspondence to: [petrschutz@yahoo.com](mailto:petrschutz@yahoo.com)

Al-Farwaniya Dental Center, Al-Farwaniya Hospital, Ministry of Health, State of Kuwait

## References

- [1] Bell RB, Dierks EJ, Brar P, Potter JK, Potter BE. A protocol for the management of frontal sinus fractures emphasizing sinus preservation. *Journal of Oral and Maxillofacial Surgery* 2007;65(5):825-839.
- [2] Mithani SK, St-Hilaire H, Brooke BS, Smith IM, Bluebond-Langner R, Rodriguez ED. Predictable patterns of intracranial and cervical spine injury in craniomaxillofacial trauma: analysis of 4786 patients. *Plastic and Reconstructive Surgery* 2009;123(4): 1293-1301. doi: 10.1097/PRS.0b013e31819e26f2.
- [3] Roden KS1, Tong W, Surrusco M, Shockley WW, Van Aalst JA, Hultman CS. Changing characteristics of facial fractures treated at a regional, level 1 trauma center, from 2005 to 2010: an assessment of patient demographics, referral patterns, etiology of injury, anatomic location, and clinical outcomes. *Annals of Plastic Surgery* 2012;68(5): 461-466. doi: 10.1097/SAP.0b013e31823b69dd.
- [4] Sperber GH, Guttman GD, Sperber SM. *Craniofacial Development*. BC Decker Inc, 2001
- [5] Scanlon VC; Sanders T: *Essentials of anatomy and physiology*. F.A. Davis, 5th ed., 2007.
- [6] Brown WA, Molleson TI, Chinn S. Enlargement of the frontal sinus. *Annals of Human Biology* 1984;11:221-226.
- [7] McLaughlin RB, Rehl RM, Jr., Lanza DC. Clinically relevant frontal sinus anatomy and physiology. *Otolaryngologic Clinics of North America*. 2001;34(1):1-22.
- [8] Williams P, Warwick R. The paranasal sinuses. In: Warwick R, ed. *Gray's anatomy*. WB Saunders 1980.
- [9] Saladin: *Anatomy & Physiology: The Unity of Form and Function, Third Edition*, The McGraw-Hill Companies, 2003.
- [10] El-Rakhawy MT. *Illustrative anatomy head and neck*. Al Al-Bayt University 2002
- [11] Salentijn L. Anatomy and embryology. In: Freidman W, ed. *Surgery of the paranasal sinuses*. W. B. Saunders 1985; p. 15-19.

- [12] Urken ML, Som PM, Lawson W, et al. The abnormally large frontal sinus. I. A practical method for its determination based upon an analysis of 100 normal patients. *Laryngoscope* 1987;97(5):602–605.
- [13] Manolidis S, Hollier LH Jr. Management of frontal sinus fractures. *Plastic and Reconstructive Surgery*. 2007;120(Suppl 2):32S-48S.
- [14] Rohrich RJ, Hollier LH. Management of frontal sinus fractures. Changing concepts. *Clinics in Plastic Surgery* 1992;19(1):219–232.
- [15] Harris, L, Marano GD, and McCorkle D. Nasofrontal duct: CT in frontal sinus trauma. *Radiology* 1987;165(1)195-198.
- [16] Stanwix MG, Nam AJ, Manson PN, Mirvis S, Rodriguez ED. Critical computed tomographic diagnostic criteria for frontal sinus fractures. *Journal of Oral and Maxillofacial Surgery* 2010;68(11):2714-2722. doi: 10.1016/j.joms.2010.05.019.
- [17] Kennedy DW, Senior BA. Endoscopic sinus surgery: A review. *Otolaryngologic Clinics of North America* 1997;30(3)313-330.
- [18] Landsberg R, Friedman M. A computer-assisted anatomical study of the nasofrontal region. *Laryngoscope* 2001;111(12)2135-2130.
- [19] Rohrich RJ, Hollier L. The role of the nasofrontal duct in frontal sinus fracture management. *Journal of Cranio-maxillofacial Trauma* 1996;2(1):31–40.
- [20] Tos M, Mogensen C, Novotny Z. Quantitative histologic features of the normal frontal sinus. *Archives of Otolaryngology* 1980;106(3):143–148.
- [21] Tiwari P, Higuera S, Thornton J, Hollier LH. The management of frontal sinus fractures. *Journal of Oral and Maxillofacial Surgery* 2005;63(9):1354-1360.
- [22] Laskin D, Abubaker A. Decision Making in Oral and Maxillofacial Surgery. *Quintessence*; 2007. p74-76.
- [23] Stevens M, Kline SN: Management of frontal sinus fractures. *Journal of Cranio-maxillofacial Trauma*. 1995;1(1):29-37.
- [24] Stanley RB Jr, Becker TS. Injuries of the nasofrontal orifices in frontal sinus fractures. *Laryngoscope*. 1987;97(6):728-731.
- [25] Stanley RB Jr. Management of severe frontobasilar skull fractures. *Otolaryngologic Clinics of North America*. 1991;24(1):139-150.
- [26] Koudstaal MJ, van der Wal KG, Bijvoet HW, Vincent AJ, Poublon RM. Post-trauma mucocele formation in the frontal sinus; a rationale of follow-up. *International Journal of Oral and Maxillofacial Surgery* 2004;33(8):751-754.
- [27] Strong EB. Frontal sinus fractures: current concepts. *Cranio-maxillofacial Trauma & Reconstruction* 2009;2(3):161-175. doi: 10.1055/s-0029-1234020.
- [28] Koento T. Current advances in sinus preservation for the management of frontal sinus fractures. *Current Opinion in Otolaryngology & Head and Neck Surgery* 2012;20(4):274-279. doi: 10.1097/MOO.0b013e328355a54a.



- [29] Tremolada C, Candiani P, Signorini M, Vigano M, Donati L. The surgical anatomy of the subcutaneous fascial system of the scalp. *Annals of Plastic Surgery* 1994;32(1):8–14.
- [30] Miloro M, Redlinger S, Pennington DM, Kolodge T. In situ location of the temporal branch of the facial nerve. *Journal of Oral and Maxillofacial Surgery* 2007;65(12):2466–2469.
- [31] Schütz P, Andersson L: Midfacial fractures. In: Andersson L, Kahnberg KE, Pogrel MA (Eds.): *Oral and Maxillofacial Surgery*. Wiley-Blackwell, 2010.
- [32] Ruggiero FP, Zender CA. Frontal sinus cranialization. *Operative Techniques in Otolaryngology – Head and Neck Surgery* 2010;21(1):143-146.
- [33] Luo W, Wang L, Jing W, Zheng X, Long J, Tian W, Liu L. A new coronal scalp technique to treat craniofacial fracture: the supratemporalis approach. *Oral Surgery, Oral Medicine, Oral Pathology and Oral Radiology* 2012;113(2):177-1782. doi: 10.1016/j.tripleo.2011.01.037.
- [34] Meiklejohn BD, Lynham A, Borgna SC. A simplified approach for the reduction of specific closed anterior table frontal sinus fractures. *British Journal of Oral and Maxillofacial Surgery* 2014 52(1):81-84. doi: 10.1016/j.bjoms.2013.09.012.
- [35] Rontal ML. State of the art in craniomaxillofacial trauma: frontal sinus. *Current Opinion in Otolaryngology & Head and Neck Surgery*. 2008;16(4):381-386. doi: 10.1097/MOO.0b013e328308672c.
- [36] Noury M, Dunn RM, Lalikos JF, Fudem GM, Rothkopf DM. Frontal sinus repair through a frontalis rhytid approach. *Annals of Plastic Surgery*. 2011;66(5):457-459. doi: 10.1097/SAP.0b013e3182185f14.
- [37] Bell RB. Management of frontal sinus fractures. *Oral and Maxillofacial Surgery Clinics of North America*, 2009;21(2):227-242. doi: 10.1016/j.coms.2008.12.003.
- [38] Strong EB. Frontal sinus fractures. *Operative Techniques in Otolaryngology – Head and Neck Surgery* 2008;19(2):151-160.
- [39] Gerbino G, Rocca F, Benech A, Caldarelli C. Analysis of 158 frontal sinus fractures: current surgical management and complications. *Journal of Cranio-maxillo-facial Surgery* 2000;28(3):133-139.
- [40] Luce EA. Frontal sinus fractures: guidelines to management. *Plastic and Reconstructive Surgery*. 1987;80(4):500-510.
- [41] Gabrielli MF, Gabrielli MA, Hochuli-Vieira E, Pereira-Fillho VA. Immediate reconstruction of frontal sinus fractures: review of 26 cases. *Journal of Oral and Maxillofacial Surgery* 2004;62(5):582-586.
- [42] Thong JF, Lee J. Single-stage strategy for management of anterior table frontal sinus fractures involving the frontal sinus outflow tract. *European Journal of Plastic Surgery* 201;34(4):299–303.
- [43] Carter KB Jr, Poetker DM, Rhee JS. Sinus preservation management for frontal sinus fractures in the endoscopic sinus surgery era: a systematic review. *Cranio-maxillofacial Trauma & Reconstruction* 2010;3(3):141-149. doi: 10.1055/s-0030-1262957.



- [44] Shumrick KA. Endoscopic management of frontal sinus fractures. *Otolaryngologic Clinics of North America* 2007;40(2):329–336.
- [45] Smith TL, Han JK, Loehrl TA, Rhee JS. Endoscopic management of the frontal recess in frontal sinus fractures: a shift in the paradigm? *Laryngoscope*. 2002 May;112(5):784-90.
- [46] Kim E, Duncavage J. Osteoplastic flap with and without fat obliteration. *Operative Techniques in Otolaryngology – Head and Neck Surgery* 2010;21(2):134-137.
- [47] Goodale RL, Montgomery WW. Anterior osteoplastic frontal sinus operation. Five years' experience. *Annals of Otology, Rhinology & Laryngology* 1961;70(3):860-880.
- [48] Hardy JM, Montgomery WW: Osteoplastic frontal sinusotomy: An analysis of 250 operations. *Annals of Otology, Rhinology & Laryngology* 1976;85(4):523-532.
- [49] Keerl R, Weber R, Kahle G, Draf W, Constantinidis J, Saha A. Magnetic resonance imaging after frontal sinus surgery with fat obliteration. *Journal of Laryngology & Otology* 1995;109(11):1115-1119.
- [50] Dickinson JT, Cipicic JA, Kamerer DB. Principles of frontal reconstruction. *Laryngoscope* 1969;79(6):1019-1074.
- [51] Weber R, Draf W, Kahle G, Kind M. Obliteration of the frontal sinus – state of the art and reflections on new materials *Rhinology*. 1999;37(1):1-15.
- [52] Barone A, Ricci M, Mangano F, Covani U. Morbidity associated with iliac crest harvesting in the treatment of maxillary and mandibular atrophies: a 10-year analysis. *Journal of Oral and Maxillofacial Surgery* 2011;69(9):2298-2304. doi: 10.1016/j.joms.2011.01.014.
- [53] Zubillaga Rodríguez I, Lora Pablos D, Falguera Uceda MI, Díez Lobato R, Sánchez Aniceto G. Frontal sinus obliteration after trauma: analysis of bone regeneration for two selected methods. *International Journal of Oral and Maxillofacial Surgery* 2014; 43(7):827-833. doi: 10.1016/j.ijom.2014.02.012.
- [54] Mlynarek AM, Seikaly H. Vascularized anteriorly based pericranial flap for frontal sinus obliteration. *Operative Techniques in Otolaryngology – Head and Neck Surgery* 2009;20(1),88-91.
- [55] Sailer HF, Grätz KW, Kalavrezos ND: Frontal sinus fractures: Principles of treatment and long-term results after sinus obliteration with the use of lyophilized cartilage. *Journal of Cranio-maxillo-facial Surgery* 1998;26(4):235-242.
- [56] Peltola MJ, Aitasalo KM, Aho AJ, Tirri T, Suonpää JT. Long-term microscopic and tissue analytical findings for 2 frontal sinus obliteration materials. *Journal of Oral and Maxillofacial Surgery* 2008;66(8):1699-1707. doi: 10.1016/j.joms.2007.11.020.
- [57] Olson NR, Newman MH. Acrylic frontal cranioplasty. *Archives of Otolaryngology* 1969;89(5):774-777.
- [58] Moeller CW, Petruzzelli GJ, Stankiewicz JA: Hydroxyapatite-based frontal sinus obliteration. *Operative Techniques in Otolaryngology – Head and Neck Surgery* 2010;21(2),147-149.

- [59] Cole I, Dan N, Anker A. Bone replacement in head and neck surgery: a biocompatible alternative. *The Australian and New Zealand Journal of Surgery* 1996;66(7):469-472.
- [60] Schenck NL, Tomlinson MJ. Frontal sinus trauma: experimental reconstruction with proplast. *Laryngoscope*. 1977;87(3):398-407.
- [61] Peltola M, Suonpää J, Aitasalo K, Varpula M, Yli-Urpo A, Happonen RP. Obliteration of the frontal sinus cavity with bioactive glass. *Head & Neck* 1998;20(4):315-319.
- [62] Peltola M, Aitasalo K, Suonpää J, Varpula M, Yli-Urpo A. Bioactive glass S53P4 in frontal sinus obliteration: a long-term clinical experience. *Head & Neck*. 2006;28(9):834-841.
- [63] Kalavrezos N. Current trends in the management of frontal sinus fractures. *Injury* 2004;35(4):340–346.
- [64] Chen KT, Chen CT, Mardini S, Tsay PK, Chen YR. Frontal sinus fractures: a treatment algorithm and assessment of outcomes based on 78 clinical cases. *Plastic and Reconstructive Surgery*. 2006;118(2):457-468.
- [65] Rodriguez ED, Stanwix MG, Nam AJ, St Hilaire H, Simmons OP, Christy MR, Grant MP, Manson PN. Twenty-six-year experience treating frontal sinus fractures: a novel algorithm based on anatomical fracture pattern and failure of conventional techniques. *Plastic and Reconstructive Surgery*. 2008;122(6):1850-1866. doi: 10.1097/PRS.0b013e31818d58ba.
- [66] Liu P, Wu S, Li Z, Wang B. Surgical strategy for cerebrospinal fluid rhinorrhea repair. *Neurosurgery*. 2010;66(6 Suppl Operative):281-285; discussion 285-6. doi: 10.1227/01.NEU.0000369660.30126.02.
- [67] Sivori LA 2nd, de Leeuw R, Morgan I, Cunningham LL Jr. Complications of frontal sinus fractures with emphasis on chronic craniofacial pain and its treatment: a review of 43 cases. *Journal of Oral and Maxillofacial Surgery* 2010;68(9):2041-2046. doi: 10.1016/j.joms.2010.05.041.
- [68] Bellamy JL, Molendijk J, Reddy SK, Flores JM, Mundinger GS, Manson PN, Rodriguez ED, Dorafshar AH. Severe infectious complications following frontal sinus fracture: the impact of operative delay and perioperative antibiotic use. *Plastic and Reconstructive Surgery* 2013;132(1):154-162. doi: 10.1097/PRS.0b013e3182910b9b.

