

# We are IntechOpen, the world's leading publisher of Open Access books Built by scientists, for scientists

4,800

Open access books available

122,000

International authors and editors

135M

Downloads

Our authors are among the

154

Countries delivered to

TOP 1%

most cited scientists

12.2%

Contributors from top 500 universities



WEB OF SCIENCE™

Selection of our books indexed in the Book Citation Index  
in Web of Science™ Core Collection (BKCI)

Interested in publishing with us?  
Contact [book.department@intechopen.com](mailto:book.department@intechopen.com)

Numbers displayed above are based on latest data collected.

For more information visit [www.intechopen.com](http://www.intechopen.com)



---

# The Role of EUS – Diagnosis and Therapeutic Interventions in Patients with Acute Pancreatitis

---

José Celso Ardengh, Eder Rios de Lima Filho, Rafael Kemp and José Sebastião dos Santos

Additional information is available at the end of the chapter

<http://dx.doi.org/10.5772/58948>

---

## 1. Introduction

Acute pancreatitis (AP) is defined as an acute inflammatory process involving the pancreatic gland with variable involvement of other adjacent or distant organs. Its incidence ranges from 2 to 50/100.000 habitants and seems to have grown from the 80s, probably due to increased alcohol consumption among young people and the formation of gallstones in some specific areas [1, 2].

These two etiologies account for about 80% of all cases of AP. Fortunately, most cases are mild and self-limiting [3-5]. However about 30% manifest as a severe form. Necrotizing acute pancreatitis (nAP) is a severe condition and is associated with local or systemic complications and can be fatal [6-8]. Many causes have been attributed to AP, but in some episodes, they are difficult to be identified [9, 10]. When some etiological factors can be identified and eliminated, prognosis is better and new outbreaks can be prevented.

The abuse of alcohol and gallstones are common causes of AP and account for 50-80% of cases [11]. The first is more frequent in males and the latest in women. These conditions can be easily identified by the patient's history (alcohol use) or by abdominal ultrasound (US) in cholelithiasis [12].

Gallstones are responsible for approximately 60% of all cases of AP due theoretically, to a transitory impaction of gallstones through the duodenal papilla. Indeed, biliary stones are often found in the gallbladder and common bile duct during surgical exploration in patients with AP are also found in more than 90% of all cases, after wet sieving of stools in the first 24 hours of the acute episode [13-17].

When analyzing all the episodes of biliary AP, gallstones are identified in 80% by US after the resolution of the attack [18]; 10% are visualized by endoscopic retrograde cholangiopancreatography (ERCP) [19] and/or Magnetic Resonance Cholangiopancreatography (MRCP) [20, 21] and the remaining gallstones are detected during laparotomy or postmortem examination [14, 22, 23]. Six to 8% of individuals with gallstones present episodes of AP [24] and in those with microlithiasis the rate of AP reach 22% [25]. In some patients, the outbreak of AP is relate to hypertriglyceridemia, hypercalcemia, reactions to drugs, abdominal trauma, surgery, or ERCP [26].

## 2. The role of EUS diagnosis in acute pancreatitis

EUS can be used in two situations: for diagnosis of parenchymal abnormalities in AP [27] or used for determining the etiologic diagnosis in cases of UAP [28-30].

### 2.1. Unexplained Acute Pancreatitis (UAP)

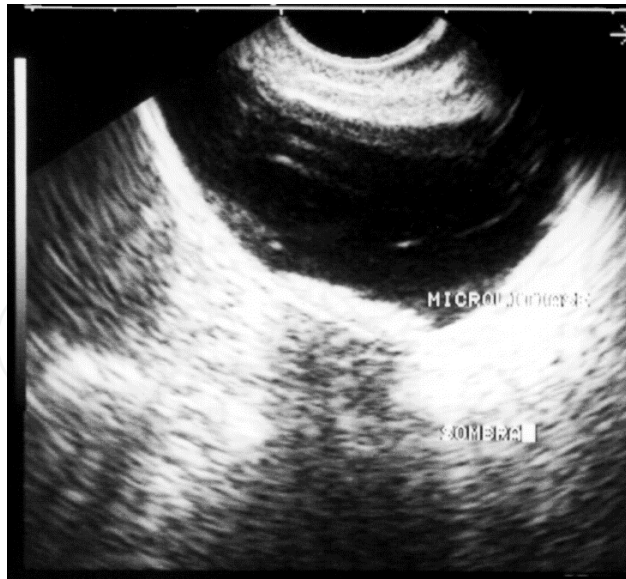
Notwithstanding the foregoing, in many episodes of AP the cause is not identified, even after a clinical history, physical examination and laboratory tests such as US, serum triglycerides and calcium which reveal normal. Such episodes are labeled as having "no apparent cause" [26]. Despite the propaedeutic methods available, the frequency of UAP is around 10% to 30% and 25-50% will present recurrence two years after the first episode [31, 32]. UAP has a high rate of morbidity and mortality due to the tendency for recurrence [33, 34]. It is important to establish the etiology of AP, not only for its prognostic implications, but to adopt the appropriate treatment, enhancing patient outcome and reducing the risk of recurrence [35, 36].

Ranson [37], Miquel et al. [38] and Tarnasky & Hawes [26] showed that approximately 30% of UAP are secondary to undiagnosed microlithiasis of the gallbladder (GML). They easily tend to migrate through the cystic duct [39] with impaction in the duodenal papilla [13] and causing biliary colic, jaundice and AP [40]. Therefore, endoscopic ultrasound (EUS) is very useful in these patients.

#### 2.1.1. Microlithiasis and biliary sludge

Some peculiarities of Microlithiasis such as radiolucency [41] and small size (maximum size 3 mm) [42], make it difficult to identify by conventional image methods such as US, CT, ERCP, MRCP [41]. According to these authors, stones presenting these characteristics constitute microlithiasis (Figure 1 and 2).

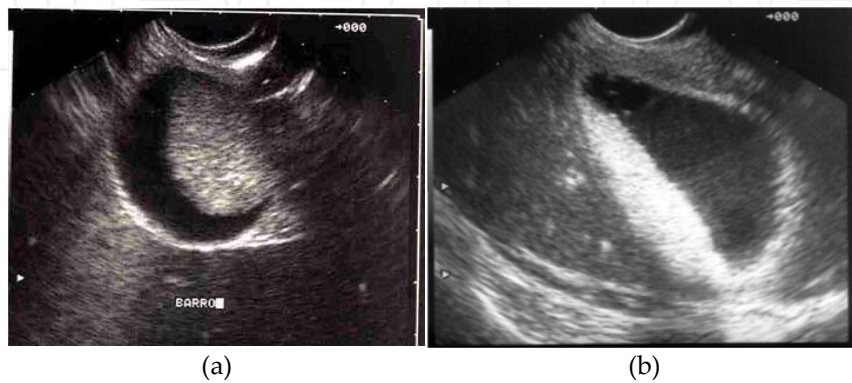Biliary sludge appears in ultrasound or EUS as multiple hyperechoic mobile signals, without acoustic shadow, forming levels within the gallbladder and are labeled as microlithiasis (Figure 3 and 4) [43, 44].



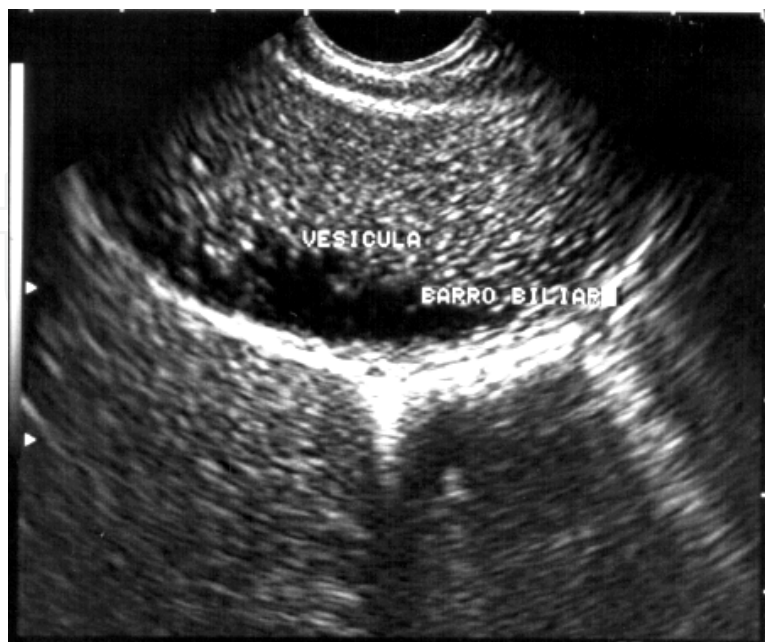
**Figure 1.** Electronic sectorial EUS. Hyperechoic image forming level, with the presence of acoustic shadow of gallbladder body in a patient with multiple episodes of AP.



**Figure 2.** Small stones (less than 3 mm), causing episodes of AP. Stones up to 3 mm, found in the surgical specimen are also included.



**Figure 3.** EUS images (a e b) shows mobile multiple hyperechoic signals, without acoustic shadow, forming levels within the gallbladder.

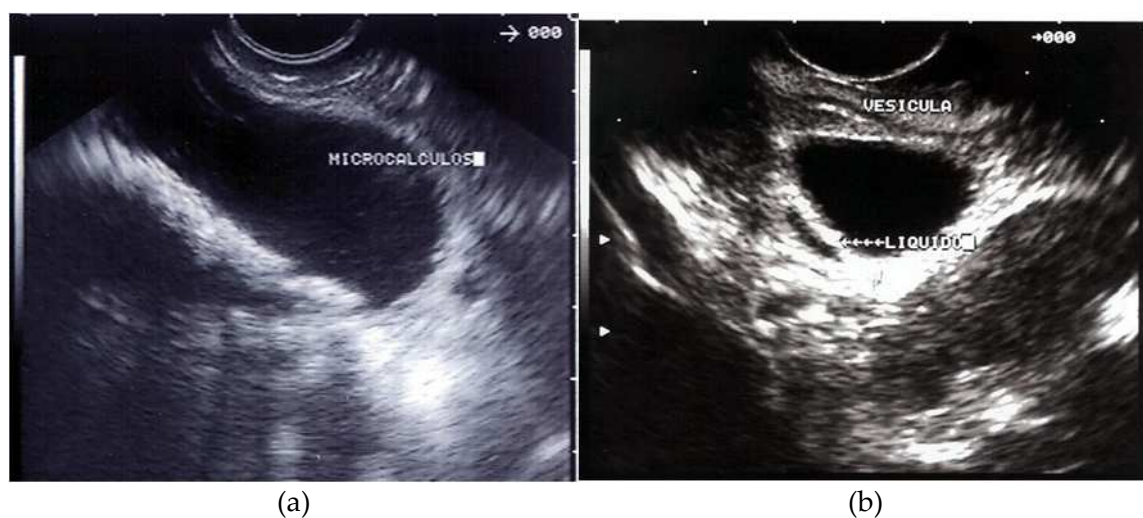

**Figure 4.** Electronic sectorial EUS shows wall thickening (acute cholecystitis) and multiple hyperechoic mobile signals without acoustic shadow, producing level within the gallbladder (biliary sludge).

### 2.1.2. Genesis of the episode of AP in patients with GML

The risk of AP in these patients is related to the size of the stones, the caliber of the cystic duct and the size and length of the Oddi's sphincter. Armstrong et al. demonstrated, in a prospective study, that the diameter of the cystic duct was  $4.94 + 2.3$  mm in patients with AP, in contrast to a shorter diameter found in those patients without AP (control group) [24]. Additionally, revealed that in 64.5% of patients with GML, the passage through the cystic duct was easy, while in the control group the passage of GML occurred in only 22.4% due to the smaller diameter of the cystic duct. A mechanical important factor is the diameter of the Oddi's sphincter, which ranges from  $2 + 1$  mm, constituting an obstacle to the passage of stones, which could cause AP [45].

The length of the common bile duct seems to be involved in the genesis of the outbreaks of AP as it is much larger in these patients than in those without the condition [24]. Starting from this premise, it is inferred the importance of this anatomical condition which increases the migration time of microlithiasis [24, 45]. Such concepts strongly advocated a theory that patients with AP have anatomical conditions that facilitate the migration of gallbladder microlithiasis (GML) to the common bile duct and whose expulsion is delayed due to a longer route to reach duodenum [24, 45]. Another author showed that besides the larger diameter of the cystic duct, the number of stones is higher in patients with AP [23]. This finding was confirmed in our study where all patients with GML showed multiple stones (Figures 1, 2, 3, 4 and 5) [46].



**Figure 5.** EUS Images obtained from patients with UAP. (a) Multiple hyperechoic echoes, some of them showing acoustic shadow. Histologic examination of the surgical specimen revealed cholesterosis. (b) Gallbladder image shows perivesicular fluid. Surgical procedure revealed the presence of microlithiasis undetected by EUS and pathological examination of the surgical specimen revealed cholesterosis.

### 2.1.3. Diagnosis

#### 2.1.3.1. Parenchymal changes in AP

Sugiyama et al. used EUS in 23 patients with AP (16 mild AP and 7 nAP). The following criteria were observed: focal or diffuse parenchymal increasing and pancreatic echotexture ranging from normal (compared to the liver), diffusely hypoechoic, focal intrapancreatic masses (well-defined hypoechoic areas and hyperechoic dots). They observed an increase in pancreatic parenchyma in edematous form in 62.5% and in all patients with nAP. Echotexture was normal in 25% of patients with nAP and diffusely hypoechoic in the other 75%. Among the 7 patients with nAP, 5 (71.4%) had well-defined hypoechoic areas and 2 (28.6%) showed hypoechoic areas with hyperechoic dots. The location and size of focal masses corresponded to areas of pancreatic necrosis seen on CT. The main pancreatic duct (MPD) was considered normal (up to 2mm) in 11 patients and slightly dilated (2-4mm) in 7. Extrapancreatic extension was identified as hypoechoic areas. EUS was able to identify all cases of fluid collection in cul de sac. Retroperitoneal involvement was observed in 77.7% (7 of 9 patients). In this situation the extrapancreatic extension was limited according to the range of transducer (5-7cm). Subsequently, the hypoechoic areas with hyperechoic dots progressed to pancreatic abscesses [27].

In another study involving 36 patients with biliary AP (mild and necrotizing), Chak et al evaluated the following parameters: increasing of the pancreatic parenchyma, peripancreatic fluid, echogenicity, echotexture and heterogeneity, and edema of the gastroduodenal wall, correlating them with the hospitalization time until clinical condition improves [47]. Understandably, patients with peripancreatic fluid collection present a longer hospital stay. However, the authors were unable to explain the correlation between the coarse echotexture and a longer hospital stay [47]. We agree it would be very difficult to explain.

### 2.1.4. Biliary etiology

#### 2.1.4.1. Choledocholithiasis

According to Sugiyama et al [27], mentioned above, EUS sensitivity for diagnosis of choledocholithiasis was 100% against 43% and 57%, for US and CT respectively. The US sensitivity for diagnosis of gallstones varies between 87 and 98% [48] and for choledocholithiasis between 22 and 75% [49]. Table 1 shows the results of several studies evaluating US, CT, and EUS findings, in the diagnosis of choledocholithiasis.

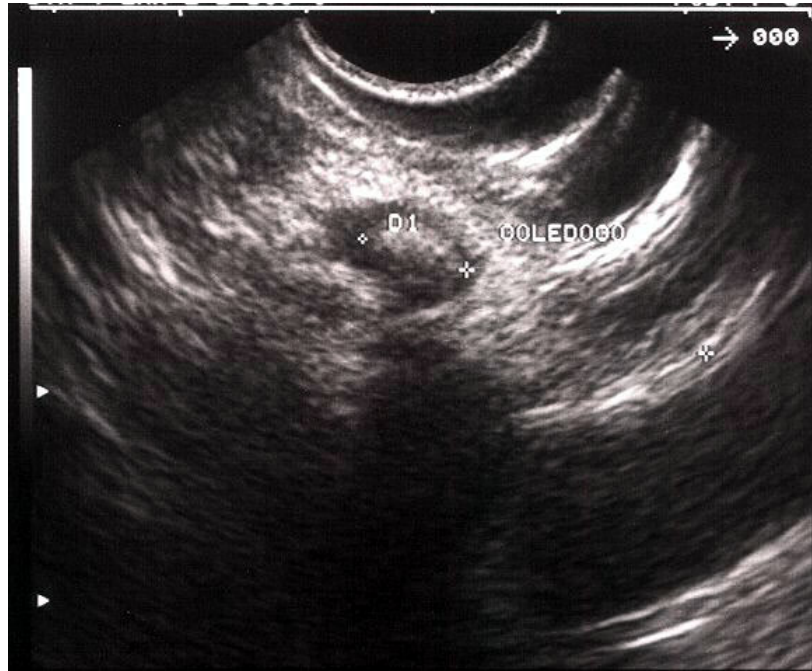
Author, year	n	Method	Sensitivity%	Specificity%	VP+%	VP-%	Accuracy%
Amuoyal, 1994 [49]	62	US	25	100	100	56	-
		CT	75	94	92	78	-
		EUS	97	100	100	97	-
Sugiyama, 1995 [27]	23	US	43	-	-	-	-
		CT	57	-	-	-	-
		EUS	100	100	-	-	100
Sugiyama, 1997* [50]	142	US	63	95	-	-	83
		CT	71	97	-	-	87
		EUS	96	100	-	-	99
Sugiyama, 1998[51]	35	US	47	90			71
		CT	47	95			74
		EUS	100	100			100
Chak, 1999 [47]	36	US	50	100	100	74	83
		ERCP	92	87	79	94	89
		EUS	91	100	100	95	97
Ardengh, 2000 [52] **	22	ERCP	53.3	100	100	50	68.2
		EUS	86.7	80	92.9	66.7	77.3
Liu, 2001 [29]	100	US	26	100	-	-	75
		ERCP	97	95	-	-	96
		EUS	97	98	-	-	98

\*patients with or without history of AP

\*\*choledochal microlithiasis

**Table 1.** Results of different image methods in the diagnosis of choledocholithiasis.

In our experience, we evaluated 22 patients with suspected choledochal microlithiasis during outbreaks of AP. We found that EUS identified the presence of stones in 86.7% of cases (mean stone size: 5mm), when compared to ERCP (sensitivity of 53.3%). The common bile duct was studied in all patients. No procedure-related complications were observed. We conclude that EUS is able to identify small stones and biliary dilatation, and should be considered as a diagnostic alternative in patients with suspected choledochal stones (Figure 6) [52].



**Figure 6.** EUS image shows hyperechoic arciform area, with acoustic shadow, within choledocolithiasis in a patient with UAP. This finding was confirmed by ERCP.

#### 2.1.4.2. Microlithiasis

After systematic diagnostic investigation (clinical, biochemical and by imaging methods) to identify the etiology of AP, about 10% to 30% of patients have no known cause and were labeled as UAP [53, 54]. It is at least controversial the assertion that if the etiology of an episode of AP remains unclear, after detailed endoscopic investigation (ERCP or ERCP + bile collection), this condition should be labeled as "idiopathic" [26, 32].

The identification of patients with microlithiasis arouses great interest due to the possibility of recurrent outbreaks of AP, and allowing early treatment, especially when the disease is silent or little symptomatic [25, 36, 55]. For this reason, the introduction of sensitive diagnostic and minimally invasive methods, and the resurgence of old methods (collection of bile for crystals search) became attractive along with more invasive methods such as endoscopic manometry [56].

About this point of view, seem to loom in importance the advanced endoscopic techniques: ERCP, ERCP with bile collection, for research of crystals [81, 82] and EUS in order to detect GML [57-62]. Thus, the diagnosis of stones less than 3 mm (ML) is of fundamental importance for the adoption of an appropriate therapeutic measure.

The radiological demonstration of biliary stones depends on the difference of tone between the stone and the environment that surrounds it [63]. Patients with migrant and radiolucent stones have episodes of biliary colic, AP recurrence and transient jaundice [14], despite normal



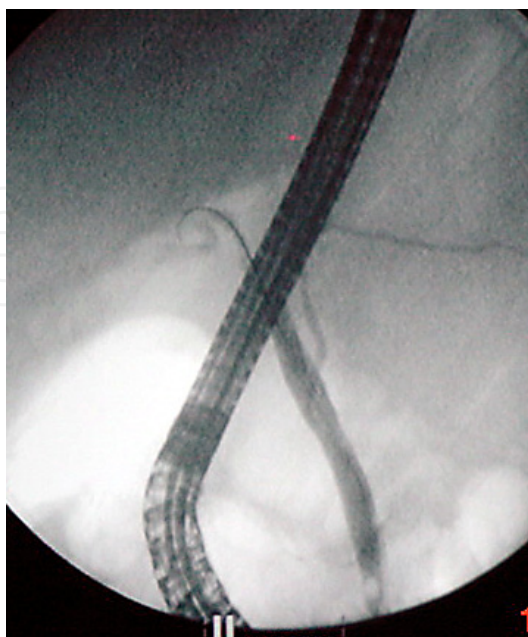
appearance of the biliary tract seen in MRCP, ERCP, and US. We consider the biliary sludge (Figures 3, 4 and 5a) as ML, because biliary sludge and stones larger than 4 mm diameter, present acoustic shadow, can be identified by the US, [64], and being confused "in vivo" according to Simeone et al. [65] and can be differentiated "in vitro" according to Filly et al. [43].

Simeone et al. [65] showed the presence of microlithiasis in 8.3% of patients with "biliary sludge" undergoing surgery. Filly et al. [43] concluded that the presence of "biliary sludge" should be considered abnormal because there may be calcium bilirubinate or cholesterol precipitates (ML).

The possibility of finding GML in a patient with gallstones detected by imaging methods, according to the concept of less than or equal to 3 mm diameter size, is around 25% [25, 42]. This rate increases to 40% when the stone changes from 3 mm to 5 mm. When the criterion of radiolucency is used, it drops to 10% [66, 67].

Thus, due to the small size, stones smaller or equal to 3 mm are difficult to identify by MRCP, ERCP, and US, remaining a diagnostic challenge, especially for the latter, due to possible confusion with biliary sludge. Patients with AP recurrence that have no changes in US may present stones during surgery. The size and density of the stones are the most important factors in the occurrence of false results [68].

The ERCP is used in the etiological diagnosis of patients with UAP, identifying potentially treatable conditions in 30% to 70% of cases and stones (Figure 7) between 4% to 15% [56, 57]. But one must keep in mind that this test is able to raise the levels of amylase in 30% to 75% of asymptomatic patients, and that AP is the most frequent complication after this procedure, ranging from 0.5% to 17% [69]. Thoeni et al reported CT signs varying from mAP to nAP in 28% of patients undergoing diagnostic ERCP [70].



**Figure 7.** ERCP image showing microlithiasis within the bile duct without dilatation.

Dahan et al, in a prospective study, compared the accuracy of EUS and collecting bile for detecting biliary crystals in patients with suspected biliary etiology. They had symptoms of AP, transient jaundice and cramping in the right upper quadrant, and a negative US for biliary stones. The study included 45 patients, 24 with gallstones confirmed by surgery. The sensitivity, specificity, positive and negative predictive values for EUS were, 96%, 86%, 89% and 95% and for the collection of bile, 67%, 91%, 89% and 70%, respectively. The major problem related to EUS was the existence of 3 false positives. According to this author the images taken as stones were due to acoustic reverberation produced by the movement of the gallbladder wall, forming artifacts confused with ML [71].

In our study involving 36 patients with UAP, sensitivity was 92.6% and positive predictive value was 86.2%, for identifying GML. Based on these data, it appears that EUS is safe and provides good diagnostic accuracy. The probable responsible factors for a high rate of GML detection include the proximity of gallbladder related to stomach and duodenal wall; the reduced distance (0.5 mm) between the EUS transducer and the gallbladder compared to the US abdominal transducer. Besides that the facility to obtain the ideal focal point to produce undistorted images; the study of the entire gallbladder (infundibulum, body, and fundus) and cystic duct, even in patients with nAP and the use of frequencies of 5.0, 7.5 and 12 MHz, producing detailed images [72].

Moreover, specificity and negative predictive value were 55.6% and 71.4%, respectively. These data are questionable and imprecise. The main responsible factors for these rates, to a greater or lesser degree include a very small sample of individuals without the disease and the greater likelihood of patients included in the study having biliary etiology as the cause of episodes of AP [72].

In a study involving 168 patients with UAP, Frossard et al using EUS could identify the presence of gallstones in 103 (61%) cholelithiasis or microlithiasis in 52, biliary sludge in 12 choledocholithiasis in 10, and more than one of these findings in 29. Ruling out other causes (chronic pancreatitis, tumors, etc.), only 37 remained with unchanged diagnosed [58]. A similar study using EUS in 44 patients with UAP, Norton & Alderson found a definite cause for AP in 18 patients (41%) and a probable etiology in 14 (31.8%). Only 9 had no diagnosis. EUS showed 2 false-positive results, and due to technical problems in 1 patient it was not possible to do the procedure [48].

Liu et al prospectively studied 89 patients with UAP. All of them underwent CT, ERCP, and US up to 24 hours from hospital admission. After these procedures, 18 patients were labeled as having UAP. All underwent EUS, which revealed GML in 14 (77.7%) and 3 had concomitant stones in the common bile duct (21.4%). These findings suggest that a patient with AP should not be labeled as UAP before underwent EUS [73].

Tandon & Topazian evaluated the role of EUS in etiological diagnosis of UAP episodes. In 21/31 patients (68%) EUS revealed the etiologic factor. Biliary stones in 14%, initial chronic pancreatitis in 45%, pancreas divisum in 6.5%, and tumor in 3.2%. In 32% of cases, EUS was normal and could not identify the cause. The results of this study show that EUS is less invasive than ERCP, effectively demonstrating the etiology of AP in more than two thirds of cases [30].

In biliary AP, EUS performed before ERCP helps in selecting patients requiring endoscopic therapy, reducing the need for diagnostic cholangiography (and its potential risks) in about 50% of them [51].

Levy et al in a multicenter study evaluated various factors to predict biliary etiology of AP. In 213 patients with AP, biliary etiology was present in 62%, alcohol in 35% and other causes in 13%. In 15% of patients with biliary etiology, only EUS was able to make diagnosis. The other tests were negative. The authors conclude that EUS is useful to confirm or exclude biliary stones, as a source of AP, and the age, sex and alanine transaminase obtained during admission are the only predictive factors in favor of biliary origin [73].

Shimpi et al demonstrated the diagnostic accuracy of EUS and ERCP in patients with UAP. EUS revealed the diagnosis in 44% [28/63] of patients, whereas ERCP made the diagnosis in 71% [45/63]. The rate of occurrence of AP after ERCP and manometry was 17%. There was no adverse event related to EUS and EUS-FNA in two patients. The authors conclude that EUS has an important role in diagnosis of UAP etiology [56].

#### 2.1.4.3. *Personal casuistic*

From 1999 to 2006, we studied prospectively 143 patients (76 women) with a mean age of 51 years (8-84y). According to ultimate etiology, the causes included biliary, parenchymal and/or ductal, vesicular and neoplasm. We compared the results of EUS and surgery in 103 patients. Forty patients had a mean follow up of 36 months (13-56m). The final diagnosis was obtained by EUS [72], surgery [16], EUS-FNA [12] and ERCP [9]. EUS detected changes in 101 patients (70%). The cause of AP was biliary in 68 patients, parenchymal and/or ductal in 14, neoplastic in 14, vesicular in 9, and no cause in 37. When compared to a multidisciplinary investigation, EUS (diagnosis of biliary, parenchymal, neoplastic, and vesicular etiologies) we found these rates for diagnostic accuracy: 89.7%, 64%, 44% and 86.6%, respectively. EUS clarified the etiology of AP in 89.7%. Therefore, EUS is of great value in identifying the etiology of patients with UAP. This diagnosis should be made after EUS evaluation.

Moreover, EUS-FNA can help diagnose of UAP episodes. In the former group, 16 patients underwent EUS-FNA. Previously, all had undergone at least to US and CT, which revealed no biliary-pancreatic alterations, and 64% of patients had more than one episode of AP. EUS findings, up to 1 week of the outbreak, found solid [11] and cystic lesions [5]. The final diagnosis of malignancy [11] and benign lesion [5] was confirmed in 15 cases by surgery and in 1 by clinical follow-up. We compared the results of EUS-FNA with surgical findings and follow-up. In this population of patients with UAP [143], the finding of tumors occurred in 9.8%. The final etiologic diagnosis was ductal adenocarcinoma [7], intraductal mucin-producing neoplasm [3], cystadenocarcinoma [2], inflammation of the common bile duct with stenosis [2], mucinous cystadenoma [1] and neuroendocrine tumor [1]. Isolated EUS and EUS-FNA showed sensitivity, specificity, positive and negative predictive values, and accuracy for diagnosis of malignancy of 92.3% and 80%, 33.3% and 100%, 85.7% and 100%, 50% and 75%, 81.3% and 87.5%, respectively. In this series, no adverse events occurred. EUS-FNA is safe and effective for diagnosing of neoplastic etiology in patients with UAP, and should be performed in suspected tumors, because it increases the specificity and negative predictive value.

### 3. The role of EUS-therapeutic intervention in acute pancreatitis

The pancreatic fluid collections (PFC) develop by fluid extravasation or from liquefaction of pancreatic necrosis after an episode of AP, chronic pancreatitis (CP), surgery or abdominal trauma. The Atlanta classification defined the nomenclature of PFC. The presence of underlying ductal injury; the severity of AP and the maturation of PFC relative to the beginning of AP are factors that influence formation and composition of a PFC (Figure 8) [74, 75].

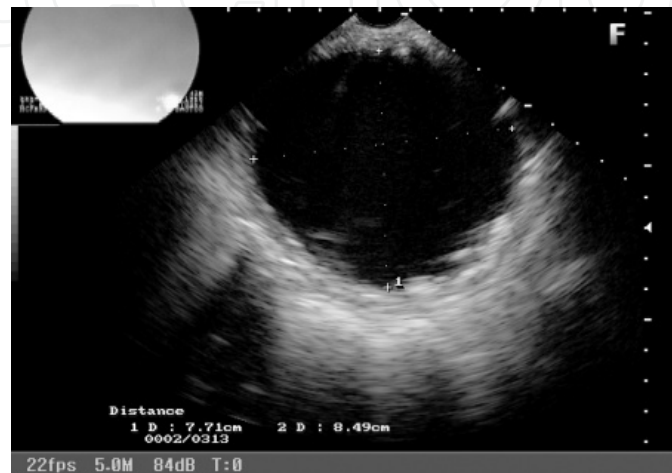

Figure 8. Pancreatic fluid collection without debris after 8 weeks from acute pancreatitis.

#### 3.1. Pseudocyst (PSC)

PSC is the most common cystic lesion of the pancreas. By definition it is a localized fluid collection, rich in pancreatic secretions, within or adjacent to the gland, surrounded by a non-epithelial wall, which results from an episode of AP or CP, pancreatic ductal obstruction or trauma. The pancreatic secretion leakage causes an inflammatory response, resulting in a cystic wall formation composed by fibrotic tissue, granulation tissue, which appears weeks after the clinical onset. The development of a well-defined wall of granulation tissue differentiates a PSC from an acute fluid collection and thus facilitates the therapeutic approach [74].

The term PSC emphasizes the non-neoplastic origin of this encapsulated collection, which should be differentiated from pancreatic cystic neoplasm (PCN), which contains an epithelial lining [76, 77]. Moreover, they must be distinguished from other forms of evanescent fluid collections often seen by imaging. The most important are the acute fluid collections that occur in more than 50% of patients with moderate or severe AP. These collections should not be confused with PSC, as over 50% resolve spontaneously. They generally occur near the pancreas and have no granulation tissue wall. They represent an exudative reaction to a pancreatic injury, with inflammation, and have no communication with the MPD. Pancreatic enzymes are present in low concentrations, being similar to plasma fluid. Seen by image methods, these collections are irregular in shape and have no interface with the adjacent organs (Table 2) [76, 77]. Therefore, PSC is a cystic cavity lined by the pancreas and inflammatory epithelium [78].

Acute fluid collections	Pseudocysts
Moderate / severe AP	CP, ductal obstruction or trauma
About 65% have spontaneous resolution	Located liquid Collection
No well-defined wall	Well defined wall without epithelial lining
Irregular Shape	Rounded or oval
May be multiple	Located, adjacent to the pancreas
No communication with the pancreatic duct	Frequent communication with the duct
Can turn into PSC	Spontaneous resolution in 30%

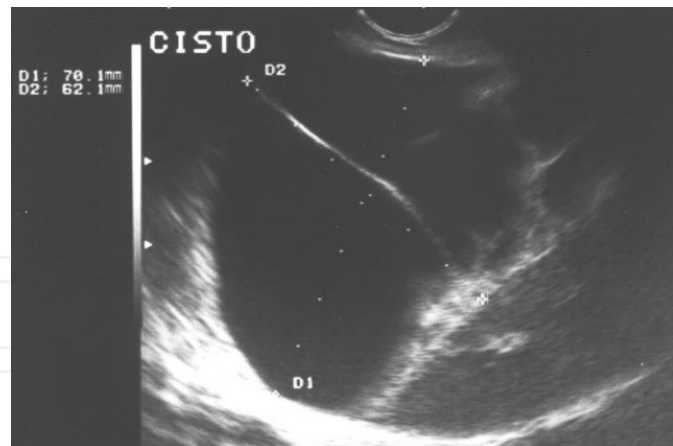
**Table 2.** Fluid collection within or adjacent to pancreas in AP [2, 6, 7].

### 3.1.1. Incidence and etiology

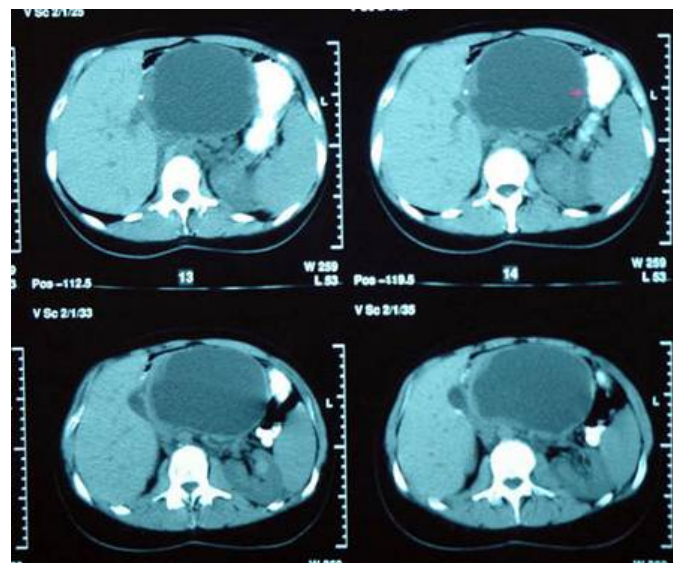
The incidence of PSC varies from 1.6 to 69% [75, 78, 79]. This wide variation is due to the diagnostic method used. In the past, studies based on contrast radiography of the esophagus, stomach and duodenum reported very low incidences (1-3%) [80]. From the 70s, with the advent of US and CT, its diagnosis has become more frequent [81-83]. They appear as a complication of AP in 10 to 50% of cases, and 20 to 40% appear after CP, which is the most common etiology. PSC accounts for approximately 75% of pancreatic cystic lesions. Retention cysts account for 10% of the cystic lesions, and represent a MPD dilatation near a local obstruction, caused by CP or carcinoma. Other cystic lesions include congenital cysts (5%) and PCN (10%) [77, 81, 83]. PSC is associated to AP and is frequently seen in patients between 30 and 50 years old. Chronic pancreatitis (CP) secondary to alcoholism seems to be the main cause in most studies, accounting for 59-78% of cases [77, 81, 83]. However, most of these studies are retrospective. In a French study, chronic PSC was associated with chronic alcoholic pancreatitis in 94% of cases, and acute PSC was associated with cholelithiasis in 45% [84].

### 3.1.2. Differential diagnosis

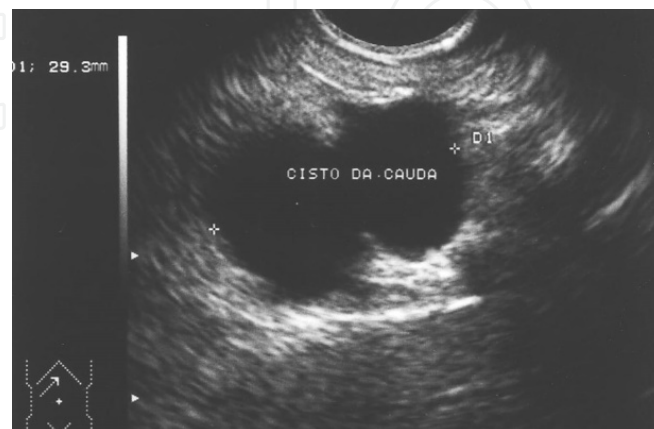
Approximately 90% of pancreatic (or peripancreatic) cystic lesions are PSC (Figure 9). The remaining 10% are due to others disorders [83]. The differentiation between PSC and PCN is essential in determining the best therapeutic approach, especially before draining. In a prospective study based on clinical and radiological criteria Sand et al. considered a cystic lesion as a PSC when it occurs after AP of known cause, preceded by CP of known cause, or when ERCP showed changes compatible with CP. The cystic lesion was considered as a probable PCN when there was no history of AP or CP or when ERCP showed a normal pancreatography [85]. However, Warshaw et al did not show any reliable clinical or radiological criteria for the differentiation of cystic lesions (Figure 10) [86]. In this context, EUS is an excellent method for diagnosis of PCN, which can identify structural details (wall and contents) [12, 29, 44, 45]. Mucin producers PCNs (intraductal papillary neoplasms) shows similar appearance to PCS when delineated by CT and US. Mucinous PCN frequently are complex cysts with thick walls and irregular internal septa (Figure 11) [29].



**Figure 9.** EUS Image of a pancreatic pseudocyst. Note the debris inside, which can be confused with PCN.



**Figure 10.** Tomographic image of alleged pancreatic pseudocyst. Note the thickness of the cyst wall located in the body of pancreas.



**Figure 11.** EUS image shows a 2.9 cm anechoic area, bilobed, and homogenous. This lesion was located in the tail. The pathologic study revealed a mucinous cystadenoma.

Solid components inside and calcifications in the walls can also be found. EUS images can often differentiate mucinous cystadenomas from mucinous cystadenocarcinoma and mucin producing intraductal neoplasms. These tumors may present regional MPD dilatation, with elevated areas and mass inside. Pancreatic parenchyma may be normal or shows atrophy, without calcifications and / or fibrosis. Intraductal tumors are premalignant lesions. EUS can identify focal mass [87].

Serous cystadenomas appear as large solid-cystic masses with predominantly microcysts, but macrocystic serous cystadenomas may cause confusion with PCS. These cysts contain fluid without "debris" inside. These lesions are not associated with mass or changes in MPD, but may show calcifications inside. The accuracy of EUS for differentiate serous and mucinous cystadenoma is around 84% and is superior to helical CT. EUS associated with fine needle aspiration (EUS-FNA) has been used to differentiate PSC and PCN. The fluid analysis includes the determination of amylase, CA19-9, CEA, and microhistopathology (Table 3) [88-90]. Although PSC shows low levels of CEA, high values may occasionally be found, especially in infected PSC. The tumor marker CA 19-9 is commonly elevated in inflammatory conditions and is not specific for malignancy. There is some concern about the possibility of infection after diagnostic puncture of a pancreatic lesion [91]. Wiersema et al observed infectious complications in 14% of patients with cystic lesions underwent puncture, well above the 0.5% after punctures of solid masses. In addition, a negative puncture does not completely rule out the presence of PCN. For these reasons, some authors do not advocate routine puncture in all cystic lesions [91, 92].

	PSC	Serous cystadenoma	Mucinous Neoplasia	Cystadenocarcinoma
<b>Viscosity</b>	low	Low	Often High	High
<b>Amylase</b>	High	Variable	Variable	Variable
<b>CEA*</b>	Low	Low	High	High
<b>CA 19-9</b>	Variable	Variable	Variable	Variable
<b>Cytology</b>	Inflammatory	Cells rich in glycogen	Mucinous cells	Mucinous cells

\* Carcinoembryonic antigen

**Table 3.** Tumor Markers in fluid aspirated from pancreatic cystic lesions [46-49].

## 3.2. Endoscopic and EUS-guided Management

### 3.2.1. Which PSC need drainage?

In a review of published articles, Andren-Sandberg & Derwinis [93], showed a wide variation in spontaneous resolution of PSC range from 20% to 70%. Bradley et al. [94] followed 31 patients with PSC after AP and 62 after CP. The spontaneous resolution has occurred in 10/24 patients (42%) in PSC occurring in less than 6 weeks. However, only 1/23 (8%) of PSC which persisted for 7 to 12 weeks had spontaneous resolution. None of the remaining 12 PSC resolved during 18 months of follow-up. Vitas & Sarr [95] followed 68 patients with spontaneous resolution in 57% of 24 patients with satisfactory radiological follow up. In 38% resolution time

was longer than 6 months. Maringhini et al [96] reported that 65% of PSC resolved until 1 year after diagnosis, and those less than 5 cm resolved more quickly than larger ones. Aranha et al [97] show that only 4/26 PSC greater than 6 cm resolved spontaneously. The average PSC, which resolved spontaneously had 4 cm compared to 9 cm with no resolution.

Thus, we think there are still some conflicting data about PSC drainage, although there is a greater tendency for resolution in those less than 6 cm and in asymptomatic cysts. Until recently, surgical treatment was the only approach, with mortality rates of 5-12% and morbidity of 21-50%. Due to these data and with the advancement of imaging methods and treatment, other modalities have been adopted [98].

#### *3.2.1.1. Endoscopic drainage*

The endoscopic treatment of PSC can be accomplished in two ways: transpapillary or transmural (cystogastrostomy or cystoduodenostomy) approach [99]. Success rates and recurrence are similar to open surgery [100]. However, in experienced hands, endoscopic therapy has significantly lower morbidity and mortality. In a literature review encompassing 437 patients undergoing endoscopic drainage, Lo et al found initial success in 94%, with resolution of PCS in 90%, recurrence in 16%, and 20% morbidity and mortality in 0.23% of cases [101].

#### **Transpapillary drainage**

It is possible only in cases where there is a communication between PSC and the MPD which occurs in 55-80% of cases, more commonly CP (49%) against 20% in AP [75, 102]. The procedure starts with pancreatography for delineate MPD communication. Then, a guide wire is inserted into MPD, reaching PSC cavity. A pancreatic sphincterotomy (optional) is performed, followed by insertion of a 5 or 7 plastic stent over the guide wire. Some authors advocate advancing the prosthesis through PSC, while others claim a transpapillary prosthesis, or a simple sphincterotomy are sufficient if there is no ductal stenosis [74]. The prosthesis stays for an average period of 2-3 months [103]. About 6% of patients experience pain or pancreatitis by occlusion of transpapillary prosthesis [104]. Removal or exchange must be done after 4-6 weeks due to high occlusion rate after this period, reaching 100% after 9 weeks. Due to the possibility of infection, antibiotic prophylaxis is always indicated.

Transpapillary drainage was successful in 84% of 117 patients treated by Beckingham et al [98] with recurrence in 9% and complications in 12%. There were no deaths. The most frequent complication was mild and self-limiting AP (6 patients), followed by infection (3 patients), treated with prosthesis replacement. The presence of a stent within MPD duct can lead to irregularities, similar to those found in CP, in 50% of patients. For this reason, some authors prefer a transmural approach or simple pancreatic sphincterotomy in patients with acute PSC and normal pancreatography. The success is higher for drainage in cephalic portion. In caudal portion, success is lower because MPD diameter diminish as it progresses from proximal to distal gland.

#### **Transmural drainage**

Transmural endoscopic therapy, by either cystogastrostomy or cystoduodenostomy, is only possible if there is a clear bulging of gastrointestinal wall. Furthermore, the distance between



the lumen of the digestive system and the cyst should not exceed 10 mm by CT and/or EUS [105, 106]. When gastroduodenal bulging is not well defined or absent, during the endoscopic examination, the chance of perforation is 10%. In these patients, in particular, EUS can identify the best site for puncture and drainage [107].

Some authors advocate enlarging the hole of puncture with a balloon dilation, thus reducing the risk of bleeding [107-109]. Others prefer to puncture the cyst with a needle, injecting contrast material and aspirating cyst to reduce the possibility of hemorrhage. Cremer [110] has shown success in cystogastrostomy and cystoduodenostomy in 100% and 96%, and recurrence in 18% and 9%, respectively. Complications are rare in cystoduodenostomy, but significant in cystogastrostomy (18%). A review covering 50 patients, showed success of cystogastrostomy in 82%, with recurrence in 18%. There were no deaths. However, 8% had bleeding and 8% had perforation. In 71 patients undergoing cystoduodenostomy, the success rate was 89%, with recurrence in only 6%. Severe bleeding and perforation were observed in 4% of cases [82]. Based on these data, endoscopic drainage of PCS is considered one of the greatest risk endoscopic procedures [111].

In some cases, transmural and transpapillary drainage can be combined. This combination should be reserved for very large cysts associated with MPD stenosis, particularly if the cyst present very dense material or "debris". In a retrospective study comparing surgery and endoscopy (between 1985 and 1990), Froeschle et al [112] observed similar results after a follow up period of 33 months (50% improvement after surgery and 52% after endoscopic treatment). Similar results were observed by Barthet et al [113] in 143 patients. In summary, the guidelines for endoscopic drainage of PSC are listed in Table 4.

- |  |
|--|
| 1. Wait enough time until PCS become "mature"  |
| 2. Identify pseudoaneurysm   |
| 3. Evaluate the presence of portal hypertension and gastric varices                                      |
| 4. Ensure proximity between the cyst and gastric / duodenal wall   |
| 5. Perform a pancreatography before draining   |
| 6. Identify the presence of "debris" in PSC  |
| 7. Use the transpapillary route whenever possible  |
| 8. Use a needle to test the drainage site before puncture (hemorrhage seems to be avoided)               |
| 9. Clinical findings should confirm the nature of PSC  |
| 10. If there is some doubt between a PSCS and PCN, use EUS-FNA and collect material before the procedure |

**Table 4.** Guidelines for safe endoscopic drainage of PSC.

### 3.2.2. EUS-guided drainage of PSC

EUS is a "weapon" available to endoscopists for approaching PSC, as it can obtain high quality pancreatic images. It is considered useful in the detection and treatment of PSC, and can be

used prior to drainage, acting as a complement to conventional endoscopy or can be used for treatment itself. EUS meets several principles listed in Table 5 and for this reason, several authors recommend its use in the treatment of this disease. The main advantages of EUS are listed in Table 5 [108, 111].

1. Safely measure the distance between PCS and the gastrointestinal wall
2. Identifies gastric varices (high sensitivity)
3. Detects gastric submucosal vessels
4. Identifies pseudoaneurysm
5. Identifies "debris" inside the cystic cavity
6. Differentiates between PCS and PCN
7. Shows the puncture site in the absence of bulging [29, 86]
8. Allows drainage of PCS in a single procedure

**Table 5.** Applications of EUS- guided drainage in PSC.

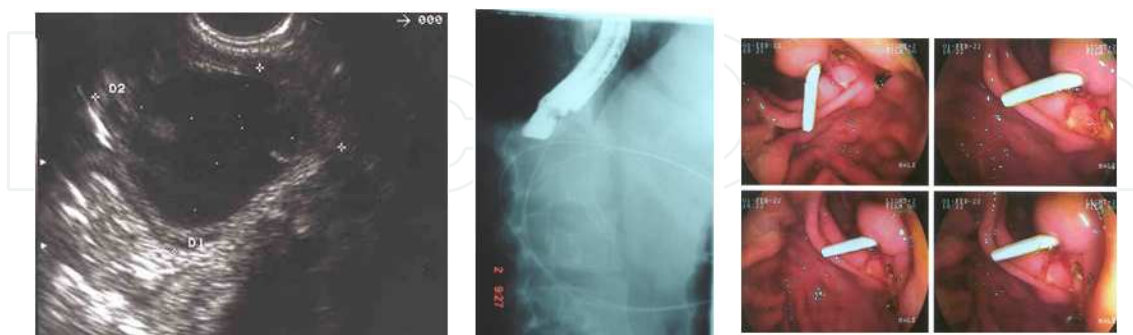The development of therapeutic echoendoscopes with an operative channel of large diameter represented a great technological advancement in the treatment of PCS. The passage of large caliber prostheses can be achieved without the necessity to replace the device (for a duodenoscope) and no fluoroscopy is used [107]. Wiersema et al [114] reported the first case of drainage performed entirely by EUS in 1996 using a Pentax FG 36UX device. Vilmann et al [115] described a new method of EUS-guided drainage ("one step"), using the Pentax FG 38UX device. Regardless of some small technical variations of EUS-guided PSC drainage includes the following steps:

1. location of the cyst and the contact zone between it and the gastric / duodenal wall;
2. evaluation of gastric/duodenal wall with Doppler to rule out the presence of large vessels;
3. puncture of the cyst, which can be performed in two ways:
4. with a 19G needle,
5. with a cistostomo catheter
6. removing the "needle-knife" wire, and using the teflon sheath
7. passage of a guidewire (0.035 inch) through the teflon sheath up to the cyst;
8. enlarge the tract by balloon dilatation (up to 20mm) and
9. exploration of the cystic cavity with endoscopic ultrasound device and
10. introducing one or two "pig tail" prostheses over the guidewire to maintain the hole.

Some studies show the effectiveness of this technique. Giovannini et al [116] conducted drainage of 15 patients with PSC and of 20 with pancreatic abscess. Thirty-three patients

underwent cystogastrostomy and 2 were submitted to cystoduodenostomy. Endoscopy revealed gastric bulging in only 1 patient. Plastic stents of 8.5 F or 7 F nasocystic drains were placed. The drainage was successful in 33 of 35 patients (failure in 2 cases of abscess), with only one episode of pneumoperitoneum, treated by clinical measures. One patient had recurrence of PSC (treated with new puncture) and 2 had recurrence of abscesses. Four patients with abscess underwent surgery (final successful 31/35 to 88.5%). No bleeding was observed. A potential disadvantage of this approach is not performing a pancreatography, thus the identification of stenosis or disruption of the MPD is not possible. In theory, this limitation may lead to a higher rate of relapse.

Ardengh et al [117] treated 12 patients with PSC without bulging (8 drainages and 4 aspirations), all by EUS. After a 12 months follow up, 10 had complete resolution, 1 recurred and undergone a new EUS-guided drainage, and 1 required surgical treatment. This technique allows the insertion of prostheses in unusual locations such as PSC in the uncinata process and tail, placement of drains near the esophageal hiatus, and allow drainage of PSC without bulging of the wall of the digestive system (Figure 12). In an attempt to reduce the rates of complications related to endoscopic drainage, some authors advocate the use of EUS, and compared it with the traditional technique. Poley et al [118] performed 53 drainages in 49 patients with PSC. Twenty-five submitted to the endoscopic drainage and 28 EUS-guided drainage. In the first technique there were fewer cases of abscess and infected necrosis compared to EUS group ( $p = 0.016$ ). The success of EUS group was 96% [27/28] versus 56% [14/25] for endoscopic group ( $p < 0.001$ ). A higher number of prostheses was insert in the EUS group compared to endoscopic (average of 3 to 1 with  $p < 0.001$ ). The long-term results were superior to patients undergoing EUS: 81% [22/27] versus 42% [10/22] for endoscopic group ( $p = 0.003$ ). More complications occurred in this group: 28% [7/25] vs. 7% [2/28] for those undergoing EUS ( $p = 0.04$ ). In this work, although some cases has been analyzed retrospectively, has a great impact and endorses the opinion of these authors that the EUS-guided drainage of PSC should be the method of choice when endoscopic technique is the best way of proceeding.



**Figure 12.** Steps of a PCS echo-guided drainage without bulging the wall. A) Identification of PCS. b) Fluoroscopic control of guide wire insertion and c) endoscopic view of prosthesis positioned in duodenal wall.

Lopes et al [119] demonstrated that EUS-guided drainage is a minimally invasive, safe and effective procedure for patients with PSC or abscesses. The authors retrospectively studied 51 patients who underwent 62 EUS-guided procedures. This procedure was successful in 94% of

patients; 3 patients were referred to surgery. There were two minor complications treated medically and recurrence at 39 weeks was 17.7%. There was no mortality in this series. The insertion of a nasocystic drain for treat abscesses did not reduce the possibility of complications, but the insertion of two prosthesis diminished the number of complications.

We studied 77 patients with sterile non-necrotic pancreatic or peripancreatic collections. Patients were referred for echoendoscopic evaluation after CT scans [75], MRI [29] and ERCP [47]. None had a bulging or communication with MPD according to endoscopic pancreatography or MRI. Thus, transpapillary or endoscopic transmural drainage (cystoduodenostomy or cystogastrostomy) was not feasible. All patients had some type of symptom such as persistent abdominal pain or cholestasis. Simple EUS-guided aspiration was indicated in the following situations: patients with PSC without debris or visible wall, parenchymal collection, when the gap between the gastric wall and cyst was greater than 2.0 cm, and for cysts up to 3.0 cm in diameter. Thirty-three underwent EUS-guided aspiration using a 19G needle (Group II) and 44 were treated by transmural EUS-guided drainage and prosthesis placement (Group I). The vast majority of patients was treated (90.6%). A complete cyst aspiration occurred in all cases (100%) and transmural EUS-guided drainage, based on intention to treat, occurred in 83.3%. No complications occurred in group II. In group I occurred 3 complications (4.4%). These results reveal that EUS-guided drainage is possible in most patients with PSC. Those who underwent aspiration showed a high relapse rate. Thus, EUS-guided aspiration is an alternative in cases where EUS-guided transmural drainage is difficult.

### 3.3. Abscess

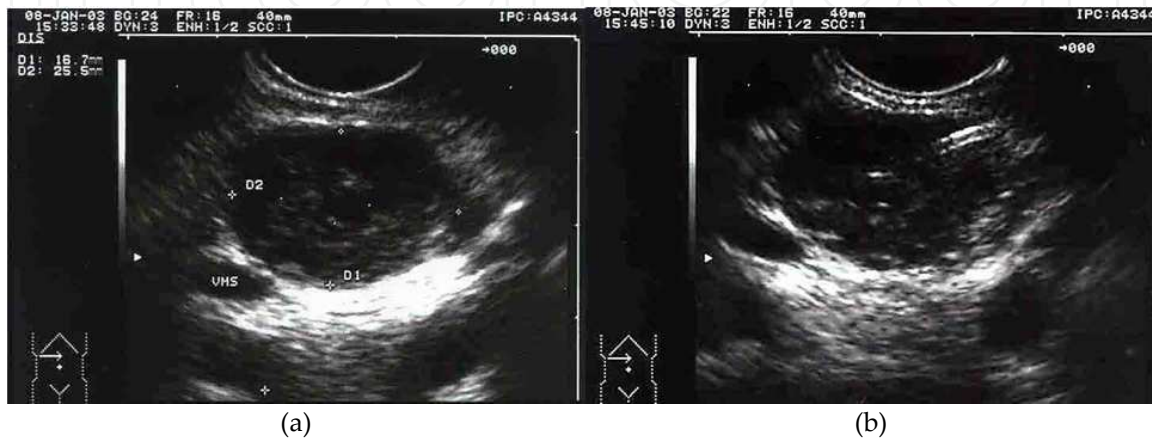#### 3.3.1. Definition, incidence and etiology

Defined by the Atlanta classification as a "circumscribed collection of pus containing little or no necrotic pancreatic tissue, which arises as a consequence of AP or trauma [120]. Its incidence has been estimated at around 1% to 5% [121] with mortality rates around 20% to 60% in some studies [122]. As a large proportion of patients are affected by episodes of severe AP, a greater number have developed this condition secondary to pancreatic infections. The search for a correct nomenclature has created discussions in the literature. Several reports in the literature between the years 60-80, named pancreatic abscess as an "infected pancreatic necrosis". With a better understanding of the pathophysiology of AP we know that infectious complications occur early in the course of AP resulting in infected pancreatic necrosis [123].

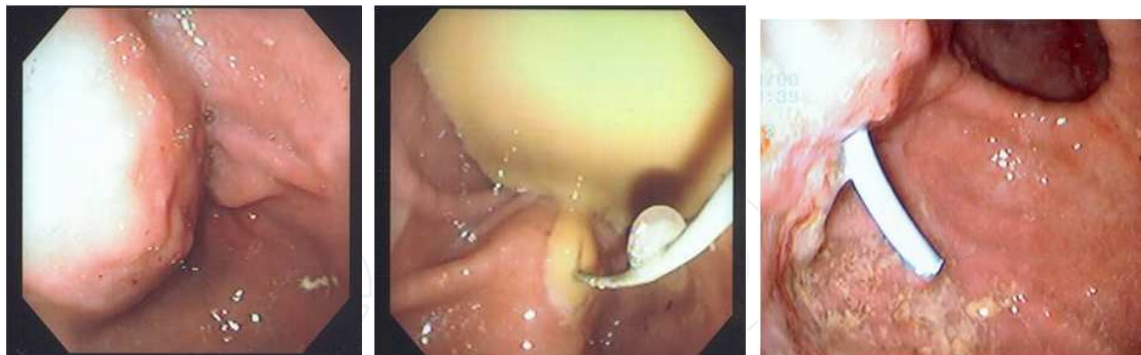The difference between the natural history of pancreatic abscess and infected pancreatic necrosis and the management of these conditions has been better understood over time. In a series of 1,200 patients, Lumsden & Bradley [124] reported that alcohol is the main etiological factor (34%), followed by lithiasis (25%), postoperative complications (22%), idiopathic (10%), trauma (3%), and post-endoscopic retrograde cholangiopancreatography (ERCP) in 8%. The average time between the episode of AP and pancreatic abscess formation has been reported. Analyzing the literature reviews, Widdison et al. [125], showed that 50% of patients developed pancreatic abscess two weeks after the episode of AP. Kaushik et al. [126] reported an average period of 3-60 days. Warshaw & Jin [127] reported an average time of 32 days, and, in 58% of patients, the onset occurred in 2 weeks.

### 3.3.2. Diagnosis

Laboratory tests are nonspecific for this clinical condition, but leukocytosis with left shift may be an important factor. The abdominal X-ray shows the presence of gases, fluid level, and aspect of soap bubble or speckled gas in up to 35% of cases. Chest X-ray may show pleural effusion. CT and US allow not only defining the exact location of abscess as well as its follow-up during treatment. Magnetic resonance imaging (MRI) offers no advantage besides having a higher cost. EUS allows locating, characterizing, and draining it (Figures 13 e 14).



**Figure 13.** (a) echoendoscopic aspect of infected pancreatic collection. Note the numerous debris scattered throughout the content, which is not homogeneous. (b) echo-guided aspirative puncture performed at Intensive Care Unit for confirming the type of bacteria and then echo-guided drainage was performed using a plastic stent.



**Figure 14.** Endoscopic drainage of pancreatic abscess. A) Note an enormous bulging on the gastric wall. B) After puncturing the bulge, a guide wire is insert. C) Then the placement of a prosthesis.

### 3.3.3. Treatment

The best treatment is surgery. CT-guided percutaneous drainage has become an option, but is still a controversial method. Sunday et al. [128] reported bad a success rate of around 25% in patients with infected pancreatic collections when submitted to CT-guided drainage. Steiner et al [129] showed the results in 25 patients with pancreatic abscess. Nineteen were initially

treated by percutaneous drainage and 6 required surgery after percutaneous drainage due to the presence of residual collection. Among 19, eight were cured, 1 died and the remaining 10 required surgery for proper drainage. In the group of 6 patients who underwent surgery after percutaneous drainage, all had a good outcome. We conclude that percutaneous drainage alone is not effective as an initial method, but that may be a good option for treating residual collections. However, other studies show conflicting results; Baril et al [130] evaluated 42 patients with positive culture of peripancreatic abscess, or collection. Among these, 25 were initially treated with percutaneous drainage and 6 required surgery after this drainage due to the presence of residual collection. None among these six required percutaneous drainage for a residual collection after surgery. In this six patients the surgical indication was: 3 with persistent sepsis, 1 with colon perforation after percutaneous drainage, 1 with thrombosis of the splenic vein evolving to variceal bleeding and 1 underwent surgical intervention due to a worsening in clinical condition. Of the 19 initially underwent percutaneous drainage, 18 were cured and 1 died, with success of 72% in this group. Van Sonnenberg et al [131] reported 86% success with percutaneous drainage in 59 patients with pancreatic abscess.

Endoscopic therapy also has its place. Park et al [132] drained 11 pancreatic abscess compressing the stomach, duodenum, or both through the creation of a fistula between the abscess and the digestive wall, washing the abscess cavity and stenting. The resolution was considered complete in the absence of symptoms and by CT imaging. Ten abscesses resolved within 32 days after placement of prosthesis. In 2 there was a need to put a nasocystic drain for washing and cleaning the abscess cavity of debris. Bleeding and relapse occurred in 1% and 13%, respectively, after a period of 18 months.

In recent years, EUS has gained acceptance in the therapeutic armamentarium for pancreatic abscesses. Giovannini et al [116] drained PSC and abscesses in 35 patients with an average size of 7.8 cm. A 7 F nasocystic drainage was successfully located in 18/20 cases of pancreatic abscess. The surgery was performed in 2 other patients. Drainage of PSC with 8.5 F prosthetic was successfully in 10 patients. The overall success of EUS was 31/35 patients (88.5%), and only 4 patients with abscess required surgery. Seewald et al [133] drained 13 patients with pancreatic necrosis and abscess, avoiding an emergency surgery. Transpapillary drainage was carried out by ERCP and transmural drainage was performed by EUS. Surgery was avoided in 9 patients with a mean follow up of 8.3 months. Surgery was combined with endoscopy in 1 case because of the extension of the abscess. Lopes et al [119] demonstrated that DEE is feasible and safe and that nasocystic drain did not reduce the possibility of complications, but the insertion of two prosthesis reduced the number of complications.

Our experience includes 12 patients. All had a strong suspicion of pancreatic abscess and were referred for an attempt to EUS-guided drainage. The presence of abscess was confirmed in 100%. Ten were drained successfully by EUS with 10 F prosthesis interposition and 2 underwent aspiration to confirm the presence of infection. Once confirmed, we opted for surgical treatment. There was no mortality in this series. None of the patients had bulging of the wall of the digestive system. In 3 cases surgical intervention was necessary because EUS-guided drainage was not sufficient. These results demonstrate that EUS-guided is a good method for the treatment of pancreatic abscess.

### 3.4. Walled off pancreatic necrosis

#### 3.4.1. EUS-guided necrosectomy

The Atlanta classification defines pancreatic necrosis as focal or diffuse areas of non-viable pancreatic parenchyma, typically associated with peripancreatic fat necrosis, and sometimes accompanied by the development of severe pancreatic duct disruption. During several weeks, an initial focus of necrosis can expand and may contain liquid and/or solid residues. In many cases, pancreatic necrosis progresses, reaching the retroperitoneal space with corrosion of retroperitoneal vessels. The radiological iconography of organized pancreatic necrosis (OPN) may be similar to an acute pseudocyst by CT. Radiographically, some characteristics help to identify the presence of solid residues. These include significant necrosis of the gland and large filling defects seen during contrast injection in CT and MRI, which indicates the presence of solid residues. Pancreatic abscess is defined as an intrabdominal circumscribed purulent collection, usually located near the pancreas, containing little or no necrosis. It has a well-defined wall, can be multilocular and is prone to rupture [123, 134].

The surgery is the preferred treatment to pancreatic necrosis and abscess, however, this modality is associated with high rate morbimortality. In selected patients the CT-guided percutaneous drainage may be effective but this method is not effective, when the fluid is thick and contains purulent debris. Furthermore, a catheter is invariably associated with bacterial colonization and fistula formation of difficult treatment. Endoscopic drainage of pancreatic fluid collections has been performed for more than two decades. It is noteworthy that pancreatic necrosis and abscesses are the biggest challenges to deal rationally and consciously! The development of EUS has expanded the indications for transmural drainage of collections without bulging the wall of the digestive system and allows the treatment of high risk fluid collections. Endoscopic therapy involves in most cases: ERCP/pancreatic sphincterotomy, transmural stent, EUS-guided puncture, dilation and drainage, endoscopic necrosectomy and exhaustive washing associated with a gastrocystic/duodenocystic fistula [135].

#### 3.4.2. Technique and accessories

The procedure starts with a puncture 19 G needle, through which can be passed a 0.035-inch terumo or Teflon type guide wire. The fistulous tract should be enlarged with a 20 mm (Maxforce; Microvasive) wire guided balloon. Another attractive accessory for necrosectomy are the 10F or 6.5F cistostomy catheters (EndoFlex, Voerde, Germany) used before insertion of one or more double pigtail" stents. An appropriate "input window" is necessary before start drainage, to define the patient's anatomy and to distinguish whether the content is a simple fluid, or complex, with solid debris. Most expert authors using this technique recommend assessing the integrity of the main pancreatic duct by endoscopic retrograde pancreatography. We are included this salutary practice.

The decision to the endoscopic intervention in patients with WOPN should be carefully discussed, because it is not easy to decide the moment of intervention. This technique, although safe, has high rate of adverse events, and involves patients in poor condition. Generally it should be performed when the collection is already organized, a fact that occurs after the fourth

week of the initial episode. On the other hand if identified infected collection should be treated immediately. A pancreatic abscess is already infected by definition, requiring a faster approach. The absence of bulging of a pancreatic collection in the wall of the digestive system, the presence of portal hypertension, which carries a high likelihood of bleeding, failure of transmural endoscopic therapy and the need to exclude a cystic neoplasm, are reasonable arguments to priority the use of EUS as an approach for endoscopic drainage. Only skilled endoscopists in ERCP and EUS should perform these procedures. Moreover, it should be done in a tertiary hospital where pancreatobiliary surgeons and interventional radiologists are able to deal with an eventual complication.

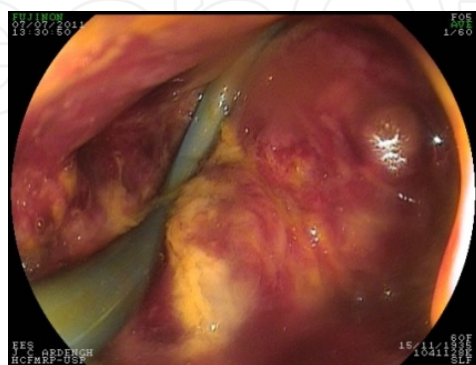### 3.5. Patient preparation

Endoscopic drainage is a lengthy and technically difficult procedure involving the use of fluoroscopy and ultrasound in several stages. Therefore, the aid of anesthesia is recommended. All patients should receive antibiotics before and during the procedure.

### 3.6. Evaluation prior to drainage

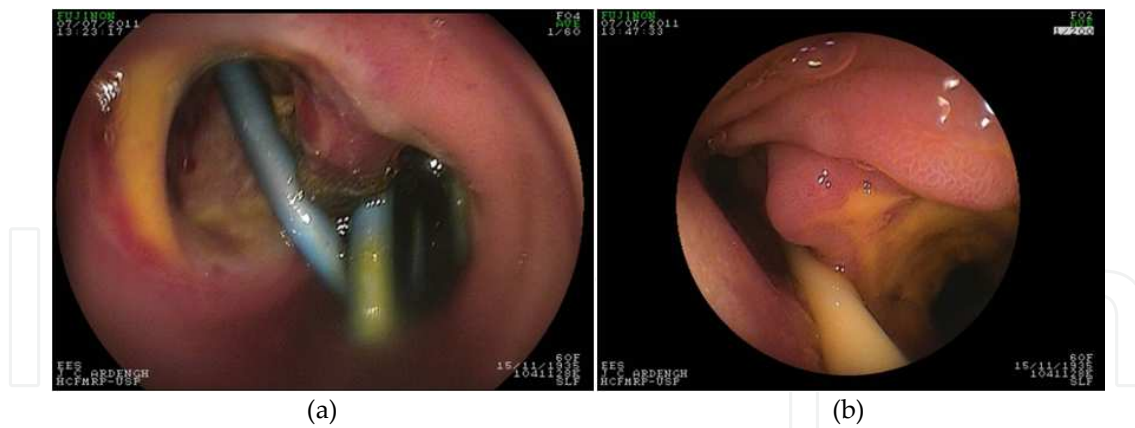#### 3.6.1. Description of the procedure

As described by Baron, transmural drainage is the preferred method for such collections. After entering the collection through the stomach or duodenal wall, the hole is enlarged to 15 mm, allowing the output of solid material around the endoprosthesis (generally two pigtail 10 F stents). A 7F tube located inside the retrogastric space for irrigation and removal of solid debris is realized (Figure 15) [136]. Initially, up to 200 or 400 ml of saline is infused through the tube every 4-6 h. Preventive antibiotics should be administered. After irrigation, patients should be hospitalized for observation. Antibiotics and irrigation should be continued until latent serial imaging revealed complete resolution of the collection. Thus, internal drains can be removed endoscopically (Figure 16).



**Figure 15.** Note the 10 F-pigtail prosthesis inside the cavity with debris. Frontal vision endoscope shows the gastrocystic fistula.





**Figure 16.** The same patient shown in the previous figure. Note another prosthesis "pig tail" passing through duodenocystic fistula (a). (b) Note the introduction of a Dobbhoff feeding tube passing near another duodenocystic fistula, located in the second portion of duodenum, below the papilla.

As described by Seewald, the procedure involves a aggressive algorithm. The first session includes ERCP with transpapillary sphincterotomy, then, EUS-guided transmural access, with balloon dilatation of the fistulous tract and after this procedure is followed by repetitive necrosectomy for washing [137]. The technique of endoscopic necrosectomy is performed day-by-day until full evacuation of liquid and purulent necrosis. A basket or a rat tooth forceps can be used to remove necrotic material. Endoscopic wash is performed using a 10 F spray catheter connected to a Water-Jet Endo system. After MPD has been evaluated, if there is a communication between that and the cavity, a 7 F teflon nasopancreatic catheter should be placed over the guide wire after pancreatic sphincterotomy.

Coelho & Ardengh [135] described an aggressive algorithm similar to those described by Sewald et al In patients with WOPN the first session includes the following sequence: ERCP with detailed assessment of the pancreatic duct, and then, EUS. Depending on the aspect of MPD, according to Takishima classification, we choose the type of drainage (transpapillary, transmural or combined). If there is bulging a necrosectomy is made without performing an EUS, but if the bulging is not evident an endoscopic ultrasound is performed for approaching necrosis (Figures 15 and 16). If we opt for EUS to make a transmural access, a 20 mm balloon is used for dilation, and then a front-view endoscope is introduced for suction of liquid content and mobilization of solid residues. This procedure is performed every 7 days until the apparent improvement in the patient's condition. The technique of EUS-guided necrosectomy is performed every 7 days until complete evacuation of fluid and purulent necrosis. A basket (FG-18Q-1, Olympus, Tokyo, Japan) or rat tooth forceps can be used to remove necrotic material.

#### 4. Literature review of EUS-guided necrosectomy

In 2002, Baron et al, compared the results of endoscopic drainage for acute pancreatic necrosis, pseudocysts, and chronic pancreatic pseudocysts. In this retrospective study, patients with

necrosis and chronic pseudocysts showed no satisfactory resolution after endoscopic drainage with rates ranging from 72% to 74%, respectively. These rates were lower than the resolution rate of 92% for the drainage of acute pseudocysts. In patients with necrosis the complications were more frequent (37%) than patients with acute pseudocysts (19%), or chronic pseudocysts (17%). Recurrence of collections occurs more frequently in patients with necrosis (29%) than in patients with acute (9%) or chronic pseudocysts (12%) [74].

Park et al [132] assessed 11 pancreatic abscesses in nine patients drained endoscopically. Ten abscesses (91%) completely disappeared after stenting during 32 days. In two patients, one nasopancreatic catheter was necessary for irrigation, dilution of thick pus and disintegration of necrotic residues. There was one case of uncomplicated bleeding. The recurrence rate was 13% during a median follow-up of 18 months.

In 2000, Venu, et al [138], have shown similar results using the transpapillary approach. In this study, 11 patients underwent endoscopic transpapillary drainage with technical success in 10 patients (90%). Eight (74%) had resolution of pancreatic abscess. The installation of an intracavitary nasopancreatic drain and instillation of gentamicin were used in two patients. The patient who presented failure of endoscopic treatment underwent percutaneous drainage successfully.

In 2000, Seifert et al [139] were the first to describe the use of EUS for transmural approach in necrotizing pancreatitis or abscess, followed by dilation of the fistula created to perform an endoscopic direct debridement of the retrogastric space. The gastric fenestration and debridement of infected necrosis by pneumoretroperitoneoscopy was performed in three patients. This method obtained rapid clinical improvement and no adverse events.

Other study with EUS-guided drainage of PSC and abscesses in 35 patients (20 abscesses). The drainage was successful in 18/20 patients with a 7F nasocystic drain. Two patients required surgery, and a median follow-up of 27 months two relapses were observed [116].

Another retrospective study with a EUS-guided procedure associated or not with transpapillary drainage, and followed by balloon dilatation of the fistula (cystogastrostomy or cystoduodenostomy), was done in patients with WOPN and abscess. Endoscopic necrosectomy were performed daily. In 13 consecutive patients, 5 with infected necrosis, and 8 with abscesses. This technique was successful in solving the infection in 12/13 patients during a mean follow-up of 9.5 months. One patient required a surgical treatment for necrosis resection in paracolic space. Two patients with ductal rupture developed recurrent collections after 2 and 4 months. These patients required resection of the pancreatic head. Three episodes of locally controlled hemorrhage were reported. The average number of necrosectomies was 7 [133].

In 2006, Hookey et al [140] evaluated the results of endoscopic drainage for pancreatic collections in 116 patients. Eighty had necrosis and 9 had pancreatic abscess. In this study, drainage of organized necrosis showed failure rates significantly greater than in other collections. The clinical and technical success of necrosis drainage was only 25% and 50%, respectively. Six of the eight undergone to a nasocavitary catheter insertion and one had recurrence. There were two complications related to the procedure in this subgroup. Nine patients underwent endoscopic drainage of pancreatic abscess. Seven/9 were treated by

nasocavitary catheter. All procedures were successful, and 8/9 (88.9%) patients had clinical success. One had abscess relapse and there was no procedure-related complications.

In 2007 Papachristou et al [141] performed a retrospective analysis of 53 patients underwent endoscopic transmural drainage/debridement of sterile collection (27 patients) and infected WOPN (26 patients). An average of three sessions per patient were performed. The result after the initial endoscopic intervention proved successful in 81% (43 patients) and persistence of organized pancreatic necrosis in 19% (10 patients). Twenty-one patients (40%) required simultaneous radiologic/echo-guided drainage, and 12 patients (23%) required open surgery, due to the persistence of organized pancreatic necrosis [3], recurrence [2], fistula formation [2], technical failure [1], persistent pain [1], colonic obstruction [1], perforation [1], and abscess [1].

Coelho & Ardengh treated 56 patients with WOPN. 49/56 (87%) patients were successfully treated by 20 mm balloon dilation in serial sessions every 7 days. During this period, we had 3 cases of recurrence and no case of death. Ardengh et al in the DDW 2013 presented the results of programmed EUS-guided necrosectomy in patients with severe necrotizing acute pancreatitis. The programmed EUS-guided necrosectomy allows created multiple transluminal gateways to improve transmural removal of necrosis. We treated 17 patients with infected WOPN with this technique. One or more transmural fistulas were performed. The necrosectomy was performed and after a plastic pigtail stents were placed. The average sessions was 2.5 [1-6]. Successful resolution of WOPN occurred in 15/17 (88.2%) patients. Plastic pigtail were placed in 12, self-expandable metallic stents (SEMS) in 3, and in 2 patients no stents were placed. Three patients experienced bleeding (entry side [2], inside cavity [1]) and worsening of infection (33.3%), all of which were successfully treated endoscopically by another session of EUS-N. The mortality rate was (11.7%). One underwent surgery (5.8%) and other patient died due to poor medical conditions. The mean duration of hospital stay was 19 days (6-48 days). We concluded that the programmed EUS-N is an effective option for the treatment of infected WOPN because it eliminates the need for surgery and can be performed in the absence of a visible bulging [142].

One of the biggest challenges during EUS-guided drainage was the sequential transgastric stent placement and positioning of nasocystic drain, which can be difficult due to a reduced visual field. Abundant fluid, the tangential axis of puncture, and the presence of solid residues makes the passage of a catheter up to cavity, a difficult maneuver. The use of conventional plastic stents for drainage of necrosectomies is troublesome. The insertion of a removable self-expandable metallic stent, maybe facilitate drainage of infected pancreatic necrosis after several unconventional necrosectomies, but this approach needs to be better evaluated [143].

## 5. Conclusion

PSC, WOPN and abscess are the most serious adverse events of acute pancreatitis. The endoscopic approach for these problems has developed and, more recently, we have seen an increasing in drainage of pancreatic fluid collections. A variety of studies has been conducted and the opinion of experts has been analyzed searching for the answer to the question: the

endoscopic drainage is superior to surgical or radiological intervention? However, to date no randomized, controlled, multicentric, and prospective study was performed. Anyway, endoscopic approach is minimally invasive, eliminating the morbidity associated with postoperative healing of surgical drainage and the possibility of fistula after percutaneous drainage.

The advantages of EUS-guided drainage include: the ability to accurately define the characteristics of pancreatic fluid collections, the exclusion of other possible diagnoses and determine the presence of vascular structures which at least hypothetically could reduce one of the complications of endoscopic drainage. From a therapeutic standpoint, we can access collections without bulging in sites of difficult access. The biggest disadvantage of endoscopic treatment is that it is not available in all institutions, and the general time is over for its implementation, especially if we decided to use EUS. Placing nasocystic drainage is associated with patient discomfort when the daily necrosectomy is required. The development of new accessories and stents can make it more effective and safe.

## Author details

José Celso Ardengh<sup>1,2\*</sup>, Eder Rios de Lima Filho<sup>3</sup>, Rafael Kemp<sup>4</sup> and José Sebastião dos Santos<sup>3</sup>

\*Address all correspondence to: [jcelso@uol.com.br](mailto:jcelso@uol.com.br)

1 Endoscopy Unit, Hospital 9 de Julho, São Paulo, Brazil

2 Endoscopy Unity, Division of Surgery and Anatomy, Ribeirão Preto School of Medicine – University of São Paulo, Brazil

3 Department of Surgery, Hospital Federal dos Servidores do Estado, Rio de Janeiro, Brazil

4 Endoscopy Unity, Division of Surgery and Anatomy, Ribeirão Preto School of Medicine – University of São Paulo, Brazil

## References

- [1] Marshall JB. Acute pancreatitis. A review with an emphasis on new developments. *Arch Intern Med.* 1993 May 24;153(10):1185-98. PubMed PMID: 8494472.
- [2] Mehdi M, Deutsch JP, Arrive L, Ayadi K, Ladeb MF, Tubiana JM. [Acute pancreatitis]. *Ann Radiol (Paris).* 1996;39(1):37-44. PubMed PMID: 8794575.
- [3] United Kingdom guidelines for the management of acute pancreatitis. British Society of Gastroenterology. *Gut.* 1998 Jun;42 Suppl 2:S1-13. PubMed PMID: 9764029.

- [4] Dalzell DP, Scharling ES, Ott DJ, Wolfman NT. Acute pancreatitis: the role of diagnostic imaging. *Crit Rev Diagn Imaging*. 1998 Sep;39(5):339-63. PubMed PMID: 9791748.
- [5] Pandol SJ. Acute pancreatitis. *Curr Opin Gastroenterol*. 2006 Sep;22(5):481-6. PubMed PMID: 16891878.
- [6] Bittner R, Block S, Buchler M, Beger HG. Pancreatic abscess and infected pancreatic necrosis. Different local septic complications in acute pancreatitis. *Dig Dis Sci*. 1987 Oct;32(10):1082-7. PubMed PMID: 3308374.
- [7] Bradley EL, 3rd, Allen K. A prospective longitudinal study of observation versus surgical intervention in the management of necrotizing pancreatitis. *Am J Surg*. 1991 Jan;161(1):19-24; discussion -5. PubMed PMID: 1987854.
- [8] Calleja GA, Barkin JS. Acute pancreatitis. *Med Clin North Am*. 1993 Sep;77(5):1037-56. PubMed PMID: 7690443.
- [9] Grendell JH. Idiopathic acute pancreatitis. *Gastroenterol Clin North Am*. 1990 Dec;19(4):843-8. PubMed PMID: 2269520.
- [10] Levy MJ, Geenen JE. Idiopathic acute recurrent pancreatitis. *The American journal of gastroenterology*. 2001 Sep;96(9):2540-55. PubMed PMID: 11569674.
- [11] Steinberg WM. Predictors of severity of acute pancreatitis. *Gastroenterol Clin North Am*. 1990 Dec;19(4):849-61. PubMed PMID: 2269521.
- [12] Glasbrenner B, Adler G. [Acute pancreatitis: diagnosis]. *Ther Umsch*. 1996 May;53(5):333-41. PubMed PMID: 8685850.
- [13] Acosta JM, Ledesma CL. Gallstone migration as a cause of acute pancreatitis. *N Engl J Med*. 1974 Feb 28;290(9):484-7. PubMed PMID: 4810815.
- [14] Dayan L, Cherif-Zahar K, Lepage B, Bories-Azeau A. [Diagnostic traps and procedure to follow in radio-invisible biliary calculi]. *J Chir (Paris)*. 1976 Apr;111(4):431-42. PubMed PMID: 956297.
- [15] Lankisch PG, Schirren CA, Schmidt H, Schonfelder G, Creutzfeldt W. Etiology and incidence of acute pancreatitis: a 20-year study in a single institution. *Digestion*. 1989;44(1):20-5. PubMed PMID: 2599279.
- [16] Patti MG, Pellegrini CA. Gallstone pancreatitis. *Surg Clin North Am*. 1990 Dec;70(6):1277-95. PubMed PMID: 2247815.
- [17] Thomson SR, Hendry WS, McFarlane GA, Davidson AI. Epidemiology and outcome of acute pancreatitis. *Br J Surg*. 1987 May;74(5):398-401. PubMed PMID: 3594136.
- [18] Goodman AJ, Neoptolemos JP, Carr-Locke DL, Finlay DB, Fossard DP. Detection of gall stones after acute pancreatitis. *Gut*. 1985 Feb;26(2):125-32. PubMed PMID: 2578422.

- [19] Lee SP, Nicholls JF. Nature and composition of biliary sludge. *Gastroenterology*. 1986 Mar;90(3):677-86. PubMed PMID: 3943697.
- [20] Aube C, Delorme B, Yzet T, Burtin P, Lebigot J, Pessaux P, et al. MR cholangiopancreatography versus endoscopic sonography in suspected common bile duct lithiasis: a prospective, comparative study. *AJR Am J Roentgenol*. 2005 Jan;184(1):55-62. PubMed PMID: 15615951.
- [21] Moon JH, Cho YD, Cha SW, Cheon YK, Ahn HC, Kim YS, et al. The detection of bile duct stones in suspected biliary pancreatitis: comparison of MRCP, ERCP, and intra-ductal US. *The American journal of gastroenterology*. 2005 May;100(5):1051-7. PubMed PMID: 15842578.
- [22] De Bolla AR, Obeid ML. Mortality in acute pancreatitis. *Ann R Coll Surg Engl*. 1984 May;66(3):184-6. PubMed PMID: 6721405.
- [23] McMahon MJ, Shefta JR. Physical characteristics of gallstones and the calibre of the cystic duct in patients with acute pancreatitis. *Br J Surg*. 1980 Jan;67(1):6-9. PubMed PMID: 7357248.
- [24] Armstrong CP, Taylor TV, Jeacock J, Lucas S. The biliary tract in patients with acute gallstone pancreatitis. *Br J Surg*. 1985 Jul;72(7):551-5. PubMed PMID: 4016539.
- [25] Houssin D, Castaing D, Lemoine J, Bismuth H. Microlithiasis of the gallbladder. *Surg Gynecol Obstet*. 1983 Jul;157(1):20-4. PubMed PMID: 6857468.
- [26] Tarnasky PR, Hawes RH. Endoscopic diagnosis and therapy of unexplained (idiopathic) acute pancreatitis. *Gastrointest Endosc Clin N Am*. 1998 Jan;8(1):13-37. PubMed PMID: 9405749.
- [27] Sugiyama M, Wada N, Atomi Y, Kuroda A, Muto T. Diagnosis of acute pancreatitis: value of endoscopic sonography. *AJR Am J Roentgenol*. 1995 Oct;165(4):867-72. PubMed PMID: 7676983.
- [28] Levy MJ. The hunt for microlithiasis in idiopathic acute recurrent pancreatitis: should we abandon the search or intensify our efforts? *Gastrointestinal endoscopy*. 2002 Feb;55(2):286-93. PubMed PMID: 11818945.
- [29] Liu CL, Lo CM, Chan JK, Poon RT, Lam CM, Fan ST, et al. Detection of choledocholithiasis by EUS in acute pancreatitis: a prospective evaluation in 100 consecutive patients. *Gastrointestinal endoscopy*. 2001 Sep;54(3):325-30. PubMed PMID: 11522972.
- [30] Tandon M, Topazian M. Endoscopic ultrasound in idiopathic acute pancreatitis. *The American journal of gastroenterology*. 2001 Mar;96(3):705-9. PubMed PMID: 11280538.
- [31] Khalid A, Slivka A. Approach to idiopathic recurrent pancreatitis. *Gastrointest Endosc Clin N Am*. 2003 Oct;13(4):695-716, x. PubMed PMID: 14986794.

- [32] Steinberg WM. Acute pancreatitis--never leave a stone unturned. *N Engl J Med*. 1992 Feb 27;326(9):635-7. PubMed PMID: 1734255.
- [33] Lee SP, Nicholls JF, Park HZ. Biliary sludge as a cause of acute pancreatitis. *N Engl J Med*. 1992 Feb 27;326(9):589-93. PubMed PMID: 1734248.
- [34] Ros E, Navarro S, Bru C, Garcia-Puges A, Valderrama R. Occult microlithiasis in 'idiopathic' acute pancreatitis: prevention of relapses by cholecystectomy or ursodeoxycholic acid therapy. *Gastroenterology*. 1991 Dec;101(6):1701-9. PubMed PMID: 1955135.
- [35] Millat B, Guillon F. [Prognostic indices in acute pancreatitis. Practical implications]. *Gastroenterol Clin Biol*. 1995;19(5 Pt 2):B33-40. PubMed PMID: 8522100.
- [36] Neoptolemos JP, Carr-Locke DL, London NJ, Bailey IA, James D, Fossard DP. Controlled trial of urgent endoscopic retrograde cholangiopancreatography and endoscopic sphincterotomy versus conservative treatment for acute pancreatitis due to gallstones. *Lancet*. 1988 Oct 29;2(8618):979-83. PubMed PMID: 2902491.
- [37] Ranson JH. Acute pancreatitis: pathogenesis, outcome and treatment. *Clin Gastroenterol*. 1984 Sep;13(3):843-63. PubMed PMID: 6386241.
- [38] Miquel JF, Rollan A, Guzman S, Nervi F. Microlithiasis and cholesterolosis in 'idiopathic' acute pancreatitis. *Gastroenterology*. 1992 Jun;102(6):2188-90. PubMed PMID: 1587452.
- [39] Seror J, Rives J, Stoppa R. [Importance of the concept of microlithiasis in biliary pathology; sphincteral and choledochal incidences.]. *Afr Francaise Chir*. 1961 3d Trimest; 19:166-9. PubMed PMID: 13910846.
- [40] Moskovitz M, Min TC, Gavalier JS. The microscopic examination of bile in patients with biliary pain and negative imaging tests. *The American journal of gastroenterology*. 1986 May;81(5):329-33. PubMed PMID: 3706246.
- [41] Pfefferman R, Luttwak EM. Gallstone pancreatitis. Exploration of the biliary system in pancreatitis of undetermined origin. *Arch Surg*. 1971 Oct;103(4):484-6. PubMed PMID: 5094553.
- [42] Bertrand L, Lamarque JL. [Biliary microlithiasis. Medico-radiological observations]. *Nouv Presse Med*. 1975 Dec 20;4(44):3135-8. PubMed PMID: 1219621.
- [43] Filly RA, Allen B, Minton MJ, Bernhoft R, Way LW. In vitro investigation of the origin of echoes with biliary sludge. *J Clin Ultrasound*. 1980 Jun;8(3):193-200. PubMed PMID: 6769957.
- [44] Lee SP, Hayashi A, Kim YS. Biliary sludge: curiosity or culprit? *Hepatology*. 1994 Aug;20(2):523-5. PubMed PMID: 8045512.
- [45] Barraya L, Pujol Soler R, Yvergneaux JP. [The region of Oddi's sphincter: millimetric anatomy]. *Presse Med*. 1971 Dec 25;79(55):2527-34. PubMed PMID: 5157911.

- [46] Ardengh JC, Malheiros CA, Ganc AJ, Ferrari A. Endoscopic ultrasound (EUS) in the diagnosis of gallbladder microlithiasis in patients with idiopathic acute pancreatitis. *Digestion*. 1998;59(3):40(136).
- [47] Chak A, Hawes RH, Cooper GS, Hoffman B, Catalano MF, Wong RC, et al. Prospective assessment of the utility of EUS in the evaluation of gallstone pancreatitis. *Gastrointestinal endoscopy*. 1999 May;49(5):599-604. PubMed PMID: 10228258.
- [48] Norton SA, Alderson D. Endoscopic ultrasonography in the evaluation of idiopathic acute pancreatitis. *Br J Surg*. 2000 Dec;87(12):1650-5. PubMed PMID: 11122178.
- [49] Amouyal P, Amouyal G, Levy P, Tuzet S, Palazzo L, Vilgrain V, et al. Diagnosis of choledocholithiasis by endoscopic ultrasonography. *Gastroenterology*. 1994 Apr;106(4):1062-7. PubMed PMID: 8143973.
- [50] Sugiyama M, Atomi Y. Endoscopic ultrasonography for diagnosing choledocholithiasis: a prospective comparative study with ultrasonography and computed tomography. *Gastrointestinal endoscopy*. 1997 Feb;45(2):143-6. PubMed PMID: 9040999.
- [51] Sugiyama M, Atomi Y. Acute biliary pancreatitis: the roles of endoscopic ultrasonography and endoscopic retrograde cholangiopancreatography. *Surgery*. 1998 Jul;124(1):14-21. PubMed PMID: 9663246.
- [52] Ardengh JC, Ganc AJ, Ferrari A, Malheiros CA, Rahal F. Accuracy of endoscopic ultrasonography (EUS) for diagnosis of microcholedocholithiasis in patients with acute pancreatitis. *Endoscopy*. 2000;32:A27(P68).
- [53] Norton SA, Cheruvu CV, Collins J, Dix FP, Eyre-Brook IA. An assessment of clinical guidelines for the management of acute pancreatitis. *Ann R Coll Surg Engl*. 2001 Nov;83(6):399-405. PubMed PMID: 11777135.
- [54] Uomo G, Visconti M, Manes G, Calise F, Laccetti M, Rabitti PG. Nonsurgical treatment of acute necrotizing pancreatitis. *Pancreas*. 1996 Mar;12(2):142-8. PubMed PMID: 8720660.
- [55] Neoptolemos JP, Davidson BR, Winder AF, Vallance D. Role of duodenal bile crystal analysis in the investigation of 'idiopathic' pancreatitis. *Br J Surg*. 1988 May;75(5):450-3. PubMed PMID: 3390676.
- [56] Shimpi RA, Ho S, Branch MS, Jowell PS, Baillie J, Gress FG. The Diagnostic Utility of Endoscopic Ultrasound (EUS) and ERCP in Evaluating Patients with Idiopathic Acute Recurrent Pancreatitis (IARP): An Update. *Gastrointestinal endoscopy*. 2006;63(5):AB262 (W1304).
- [57] Feller ER. Endoscopic retrograde cholangiopancreatography in the diagnosis of unexplained pancreatitis. *Arch Intern Med*. 1984 Sep;144(9):1797-9. PubMed PMID: 6476999.



- [58] Frossard JL, Sosa-Valencia L, Amouyal G, Marty O, Hadengue A, Amouyal P. Usefulness of endoscopic ultrasonography in patients with "idiopathic" acute pancreatitis. *Am J Med.* 2000 Aug 15;109(3):196-200. PubMed PMID: 10974181.
- [59] Gregor JC, Ponich TP, Detsky AS. Should ERCP be routine after an episode of "idiopathic" pancreatitis? A cost-utility analysis. *Gastrointestinal endoscopy.* 1996 Aug; 44(2):118-23. PubMed PMID: 8858315.
- [60] Scapa E. To do or not to do an endoscopic retrograde cholangiopancreatography in acute biliary pancreatitis? *Surg Laparosc Endosc.* 1995 Dec;5(6):453-4. PubMed PMID: 8611991.
- [61] Scholmerich J, Lausen M, Lay L, Salm R, Ruckauer K, Gross V, et al. Value of endoscopic retrograde cholangiopancreatography in determining the cause but not course of acute pancreatitis. *Endoscopy.* 1992 May;24(4):244-7. PubMed PMID: 1612037.
- [62] Siegel JH, Veerappan A, Cohen SA, Kasmin FE. Endoscopic sphincterotomy for biliary pancreatitis: an alternative to cholecystectomy in high-risk patients. *Gastrointestinal endoscopy.* 1994 Sep-Oct;40(5):573-5. PubMed PMID: 7988821.
- [63] Block MA, Priest RJ. Acute pancreatitis related to grossly minute stones in a radiographically normal gallbladder. *Am J Dig Dis.* 1967 Sep;12(9):934-8. PubMed PMID: 6039573.
- [64] Good LI, Edell SL, Soloway RD, Trotman BW, Mulhern C, Arger PA. Ultrasonic properties of gallstones. Effect of stone size and composition. *Gastroenterology.* 1979 Aug;77(2):258-63. PubMed PMID: 447040.
- [65] Simeone JF, Mueller PR, Ferruci JT, Jr., Harbin WP, Wittenberg J. Significance of non-shadowing focal opacities at cholecystosonography. *Radiology.* 1980 Oct;137(1 Pt 1): 181-5. PubMed PMID: 7422843.
- [66] Farrar JT. Underdiagnosis of biliary tract disorders? *Gastroenterology.* 1966 Dec; 51(6):1074-5. PubMed PMID: 5958606.
- [67] Goinard P, Pelissier G. [Biliary micro-lithiasis.]. *Presse Med.* 1962 Feb 3;70:260-1. PubMed PMID: 13899584.
- [68] Venu RP, Geenen JE, Toouli J, Stewart E, Hogan WJ. Endoscopic retrograde cholangiopancreatography. Diagnosis of cholelithiasis in patients with normal gallbladder x-ray and ultrasound studies. *Jama.* 1983 Feb 11;249(6):758-61. PubMed PMID: 6185702.
- [69] Aliperti G. Complications related to diagnostic and therapeutic endoscopic retrograde cholangiopancreatography. *Gastrointest Endosc Clin N Am.* 1996 Apr;6(2): 379-407. PubMed PMID: 8673333.
- [70] Thoeni RF, Fell SC, Goldberg HI. CT detection of asymptomatic pancreatitis following ERCP. *Gastrointest Radiol.* 1990 Fall;15(4):291-5. PubMed PMID: 2210197.

- [71] Dahan P, Andant C, Levy P, Amouyal P, Amouyal G, Dumont M, et al. Prospective evaluation of endoscopic ultrasonography and microscopic examination of duodenal bile in the diagnosis of cholecystolithiasis in 45 patients with normal conventional ultrasonography. *Gut*. 1996 Feb;38(2):277-81. PubMed PMID: 8801211.
- [72] Ardengh JC, Malheiros CA, Rahal F, Pereira V, Ganc AJ. Microlithiasis of the gallbladder: role of endoscopic ultrasonography in patients with idiopathic acute pancreatitis. *Rev Assoc Med Bras*. 2010 Jan-Feb;56(1):27-31. PubMed PMID: 20339782. Epub 2010/03/27. eng.
- [73] Liu CL, Lo CM, Chan JK, Poon RT, Fan ST. EUS for detection of occult cholelithiasis in patients with idiopathic pancreatitis. *Gastrointestinal endoscopy*. 2000 Jan;51(1):28-32. PubMed PMID: 10625791.
- [74] Baron TH, Harewood GC, Morgan DE, Yates MR. Outcome differences after endoscopic drainage of pancreatic necrosis, acute pancreatic pseudocysts, and chronic pancreatic pseudocysts. *Gastrointest Endosc*. 2002 Jul;56(1):7-17. PubMed PMID: 12085029.
- [75] Pitchumoni CS, Agarwal N. Pancreatic pseudocysts. When and how should drainage be performed? *Gastroenterol Clin North Am*. 1999 Sep;28(3):615-39. PubMed PMID: 10503140.
- [76] Hawes RH. Endoscopic management of pseudocysts. *Rev Gastroenterol Disord*. 2003 Summer;3(3):135-41. PubMed PMID: 14502117.
- [77] Howell DA, Elton E, Parsons WG. Endoscopic management of pseudocysts of the pancreas. *Gastrointest Endosc Clin N Am*. 1998 Jan;8(1):143-62. PubMed PMID: 9405756.
- [78] Kloppel G. Pseudocysts and other non-neoplastic cysts of the pancreas. *Semin Diagn Pathol*. 2000 Feb;17(1):7-15. PubMed PMID: 10721803.
- [79] Kloppel G, Kosmahl M. Cystic lesions and neoplasms of the pancreas. The features are becoming clearer. *Pancreatology*. 2001;1(6):648-55. PubMed PMID: 12120249.
- [80] Wade JW. Twenty-five year experience with pancreatic pseudocysts. Are we making progress? *Am J Surg*. 1985 Jun;149(6):705-8. PubMed PMID: 3925799.
- [81] Etzkorn KP, DeGuzman LJ, Holderman WH, Abu-Hammour A, Schlesinger PK, Harig JM, et al. Endoscopic drainage of pancreatic pseudocysts: patient selection and evaluation of the outcome by endoscopic ultrasonography. *Endoscopy*. 1995 May;27(4):329-33. PubMed PMID: 7555940.
- [82] Imrie CW, Buist LJ, Shearer MG. Importance of cause in the outcome of pancreatic pseudocysts. *Am J Surg*. 1988 Sep;156(3 Pt 1):159-62. PubMed PMID: 2458684.
- [83] Lawson JM, Baillie J. Endoscopic therapy for pancreatic pseudocysts. *Gastrointest Endosc Clin N Am*. 1995 Jan;5(1):181-93. PubMed PMID: 7728343.

- [84] Walt AJ, Bouwman DL, Weaver DW, Sachs RJ. The impact of technology on the management of pancreatic pseudocyst. Fifth annual Samuel Jason Mixter Lecture. *Arch Surg*. 1990 Jun;125(6):759-63. PubMed PMID: 2189377.
- [85] Sand J, Nordback I. The differentiation between pancreatic neoplastic cysts and pancreatic pseudocyst. *Scand J Surg*. 2005;94(2):161-4. PubMed PMID: 16111099.
- [86] Warshaw AL, Compton CC, Lewandrowski K, Cardenosa G, Mueller PR. Cystic tumors of the pancreas. New clinical, radiologic, and pathologic observations in 67 patients. *Ann Surg*. 1990 Oct;212(4):432-43; discussion 44-5. PubMed PMID: 2171441.
- [87] Ardengh JC, Lopes CV, de Lima-Filho ER, Kemp R, Dos Santos JS. Impact of endoscopic ultrasound-guided fine-needle aspiration on incidental pancreatic cysts. A prospective study. *Scand J Gastroenterol*. 2014 Jan;49(1):114-20. PubMed PMID: 24188361.
- [88] Brugge WR. Approach to cystic pancreatic lesions. *Gastrointest Endosc Clin N Am*. 2005 Jul;15(3):485-96, viii. PubMed PMID: 15990053.
- [89] Brugge WR, Lewandrowski K, Lee-Lewandrowski E, Centeno BA, Szydlo T, Regan S, et al. Diagnosis of pancreatic cystic neoplasms: a report of the cooperative pancreatic cyst study. *Gastroenterology*. 2004 May;126(5):1330-6. PubMed PMID: 15131794.
- [90] Sarr MG, Kendrick ML, Nagorney DM, Thompson GB, Farley DR, Farnell MB. Cystic neoplasms of the pancreas: benign to malignant epithelial neoplasms. *Surg Clin North Am*. 2001 Jun;81(3):497-509. PubMed PMID: 11459267.
- [91] Bhutani MS. Endoscopic ultrasound in pancreatic diseases. Indications, limitations, and the future. *Gastroenterol Clin North Am*. 1999 Sep;28(3):747-70, xi. PubMed PMID: 10503148.
- [92] Wiersema MJ, Vilman P, Giovannini M, Chang KJ, Wiersema LM. Endosonography-guided fine-needle aspiration biopsy: diagnostic accuracy and complication assessment. *Gastroenterology*. 1997 Apr;112(4):1087-95. PubMed PMID: 9097990.
- [93] Andren-Sandberg A, Dervenis C. Pancreatic pseudocysts in the 21st century. Part I: classification, pathophysiology, anatomic considerations and treatment. *Jop*. 2004 Jan;5(1):8-24. PubMed PMID: 14730118.
- [94] Bradley EL, Clements JL, Jr., Gonzalez AC. The natural history of pancreatic pseudocysts: a unified concept of management. *Am J Surg*. 1979 Jan;137(1):135-41. PubMed PMID: 758840.
- [95] Vitas GJ, Sarr MG. Selected management of pancreatic pseudocysts: operative versus expectant management. *Surgery*. 1992 Feb;111(2):123-30. PubMed PMID: 1736380.
- [96] Maringhini A, Uomo G, Patti R, Rabitti P, Termini A, Cavallera A, et al. Pseudocysts in acute nonalcoholic pancreatitis: incidence and natural history. *Dig Dis Sci*. 1999 Aug;44(8):1669-73. PubMed PMID: 10492151.

- [97] Aranha GV, Prinz RA, Esguerra AC, Greenlee HB. The nature and course of cystic pancreatic lesions diagnosed by ultrasound. *Arch Surg.* 1983 Apr;118(4):486-8. PubMed PMID: 6830440.
- [98] Beckingham IJ, Krige JE, Bornman PC, Terblanche J. Long term outcome of endoscopic drainage of pancreatic pseudocysts. *Am J Gastroenterol.* 1999 Jan;94(1):71-4. PubMed PMID: 9934733.
- [99] Weckman L, Kylanpaa ML, Puolakkainen P, Halttunen J. Endoscopic treatment of pancreatic pseudocysts. *Surg Endosc.* 2006 Apr;20(4):603-7. PubMed PMID: 16424988.
- [100] Chan AT, Heller SJ, Van Dam J, Carr-Locke DL, Banks PA. Endoscopic cystgastrostomy: role of endoscopic ultrasonography. *Am J Gastroenterol.* 1996 Aug;91(8):1622-5. PubMed PMID: 8759673.
- [101] Lo SK, Rowe A. Endoscopic management of pancreatic pseudocysts. *Gastroenterologist.* 1997 Mar;5(1):10-25. PubMed PMID: 9074916.
- [102] Binmoeller KF, Seifert H, Walter A, Soehendra N. Transpapillary and transmural drainage of pancreatic pseudocysts. *Gastrointest Endosc.* 1995 Sep;42(3):219-24. PubMed PMID: 7498686.
- [103] Kozarek RA, Ball TJ, Patterson DJ, Raltz SL, Traverso LW, Ryan JA, et al. Transpapillary stenting for pancreaticocutaneous fistulas. *J Gastrointest Surg.* 1997 Jul-Aug;1(4):357-61. PubMed PMID: 9834370.
- [104] Libera ED, Siqueira ES, Morais M, Rohr MR, Brant CQ, Ardengh JC, et al. Pancreatic pseudocysts transpapillary and transmural drainage. *HPB Surg.* 2000;11(5):333-8. PubMed PMID: 10674749.
- [105] Will U, Wegener C, Graf KI, Wanzar I, Manger T, Meyer F. Differential treatment and early outcome in the interventional endoscopic management of pancreatic pseudocysts in 27 patients. *World J Gastroenterol.* 2006 Jul 14;12(26):4175-8. PubMed PMID: 16830368.
- [106] Yusuf TE, Baron TH. Endoscopic transmural drainage of pancreatic pseudocysts: results of a national and an international survey of ASGE members. *Gastrointest Endosc.* 2006 Feb;63(2):223-7. PubMed PMID: 16427925.
- [107] Ardengh JC, Coelho DE, Coelho JF, de Lima LF, dos Santos JS, Modena JL. Single-step EUS-guided endoscopic treatment for sterile pancreatic collections: a single-center experience. *Dig Dis.* 2008;26(4):370-6. PubMed PMID: 19188730.
- [108] Andersson B, Nilsson E, Willner J, Andersson R. Treatment and outcome in pancreatic pseudocysts. *Scand J Gastroenterol.* 2006 Jun;41(6):751-6. PubMed PMID: 16716977.

- [109] Shah RJ, Martin SP. Endoscopic retrograde cholangiopancreatography in the diagnosis and management of pancreatic diseases. *Curr Gastroenterol Rep.* 2000 Apr;2(2):133-45. PubMed PMID: 10981015.
- [110] Cremer M, Deviere J, Engelholm L. Endoscopic management of cysts and pseudocysts in chronic pancreatitis: long-term follow-up after 7 years of experience. *Gastrointest Endosc.* 1989 Jan-Feb;35(1):1-9. PubMed PMID: 2920879.
- [111] Chak A. Endosonographic-guided therapy of pancreatic pseudocysts. *Gastrointest Endosc.* 2000 Dec;52(6 Suppl):S23-7. PubMed PMID: 11115944.
- [112] Froeschle G, Meyer-Pannwitt U, Brueckner M, Henne-Bruns D. A comparison between surgical, endoscopic and percutaneous management of pancreatic pseudocysts--long term results. *Acta Chir Belg.* 1993 May-Jun;93(3):102-6. PubMed PMID: 8372580.
- [113] Barthet M, Bugallo M, Moreira LS, Bastid C, Sastre B, Sahel J. Management of cysts and pseudocysts complicating chronic pancreatitis. A retrospective study of 143 patients. *Gastroenterol Clin Biol.* 1993;17(4):270-6. PubMed PMID: 8339886.
- [114] Wiersema MJ. Endosonography-guided cystoduodenostomy with a therapeutic ultrasound endoscope. *Gastrointest Endosc.* 1996 Nov;44(5):614-7. PubMed PMID: 8934175.
- [115] Vilmann P, Hancke S, Pless T, Schell-Hincke JD, Henriksen FW. One-step endosonography-guided drainage of a pancreatic pseudocyst: a new technique of stent delivery through the echo endoscope. *Endoscopy.* 1998 Oct;30(8):730-3. PubMed PMID: 9865567.
- [116] Giovannini M, Pesenti C, Rolland AL, Moutardier V, Delpero JR. Endoscopic ultrasound-guided drainage of pancreatic pseudocysts or pancreatic abscesses using a therapeutic echo endoscope. *Endoscopy.* 2001 Jun;33(6):473-7. PubMed PMID: 11437038.
- [117] Ardengh JC, Ferrari A, Libera ED. Endosonography-guided treatment of pancreatic pseudocysts. *Endoscopy.* 2000;32(2):A38(P100).
- [118] Poley JW, Haringsma J, Murad SD, Dees J, Van Eijck CHJ, Kuipers EJ. Endoscopic Ultrasound (EUS) Guided Drainage of Pseudocysts: Safer and More Effective Compared to Standard Endoscopic Drainage. *Gastroint Endosc.* 2006;63:AB266(1320).
- [119] Lopes CV, Pesenti C, Bories E, Caillol F, Giovannini M. Endoscopic-ultrasound-guided endoscopic transmural drainage of pancreatic pseudocysts and abscesses. *Scand J Gastroenterol.* 2007;42:1-6.
- [120] Bradley EL, 3rd. A clinically based classification system for acute pancreatitis. Summary of the International Symposium on Acute Pancreatitis, Atlanta, Ga, September 11 through 13, 1992. *Arch Surg.* 1993 May;128(5):586-90. PubMed PMID: 8489394.

- [121] Frey CF. Surgical management of pancreatic abscess. In: Bradley ELI, editor. *Acute Pancreatitis Diagnosis and therapy*. New York: Raven Press; 1994. p. Ch.21.
- [122] Beger HG. Surgery in acute pancreatitis. *Hepatogastroenterology*. 1991 Apr;38(2): 92-6. PubMed PMID: 1855779.
- [123] Das SL, Singh PP, Phillips AR, Murphy R, Windsor JA, Petrov MS. Newly diagnosed diabetes mellitus after acute pancreatitis: a systematic review and meta-analysis. *Gut*. 2014 May;63(5):818-31. PubMed PMID: 23929695.
- [124] Lumsden A, Bradley EL, 3rd. Secondary pancreatic infections. *Surg Gynecol Obstet*. 1990 May;170(5):459-67. PubMed PMID: 2183376.
- [125] Widdison AL, Alvarez C, Reber HA. Surgical intervention in acute pancreatitis: when and how. *Pancreas*. 1991;6 Suppl 1:S44-51. PubMed PMID: 1788252.
- [126] Kaushik SP, Vohra R, Verma GR, Kaushik S, Sabharwal A. Pancreatic abscess: a review of seventeen cases. *Br J Surg*. 1984 Feb;71(2):141-3. PubMed PMID: 6692108.
- [127] Warshaw AL, Jin GL. Improved survival in 45 patients with pancreatic abscess. *Ann Surg*. 1985 Oct;202(4):408-17. PubMed PMID: 4051596.
- [128] Sunday ML, Schuricht AL, Barbot DJ, Rosato FE. Management of infected pancreatic fluid collections. *Am Surg*. 1994 Jan;60(1):63-7. PubMed PMID: 8273976.
- [129] Steiner E, Mueller PR, Hahn PF, Saini S, Simeone JF, Wittenberg J, et al. Complicated pancreatic abscesses: problems in interventional management. *Radiology*. 1988 May; 167(2):443-6. PubMed PMID: 3357953.
- [130] Baril NB, Ralls PW, Wren SM, Selby RR, Radin R, Parekh D, et al. Does an infected peripancreatic fluid collection or abscess mandate operation? *Ann Surg*. 2000 Mar; 231(3):361-7. PubMed PMID: 10714629.
- [131] vanSonnenberg E, Wittich GR, Chon KS, D'Agostino HB, Casola G, Easter D, et al. Percutaneous radiologic drainage of pancreatic abscesses. *AJR Am J Roentgenol*. 1997 Apr;168(4):979-84. PubMed PMID: 9124154.
- [132] Park JJ, Kim SS, Koo YS, Choi DJ, Park HC, Kim JH, et al. Definitive treatment of pancreatic abscess by endoscopic transmural drainage. *Gastrointest Endosc*. 2002 Feb;55(2):256-62. PubMed PMID: 11818936.
- [133] Seewald S, Groth S, Omar S, Imazu H, Seitz U, de Weerth A, et al. Aggressive endoscopic therapy for pancreatic necrosis and pancreatic abscess: a new safe and effective treatment algorithm (videos). *Gastrointest Endosc*. 2005 Jul;62(1):92-100. PubMed PMID: 15990825.
- [134] Maravi-Poma E, Patchen Dellinger E, Forsmark CE, Layer P, Levy P, Shimosegawa T, et al. [International multidisciplinary classification of acute pancreatitis severity: the 2013 Spanish edition]. *Medicina intensiva / Sociedad Espanola de Medicina Intensiva y Unidades Coronarias*. 2014 May;38(4):211-7. PubMed PMID: 23747189. Clasifica-

cion Internacional y Multidisciplinaria de la Pancreatitis Aguda: Edicion Espanola 2013.

- [135] Coelho D, Ardengh JC, Eulalio JM, Manso JE, Monkemuller K, Coelho JF. Management of infected and sterile pancreatic necrosis by programmed endoscopic necrosectomy. *Dig Dis*. 2008;26(4):364-9. PubMed PMID: 19188729.
- [136] Baron TH. Endoscopic pancreatic necrosectomy. *Gastroenterology & hepatology*. 2008 Sep;4(9):617-20. PubMed PMID: 22798744. Pubmed Central PMCID: 3394485.
- [137] Seewald S, Ang TL, Richter H, Teng KY, Zhong Y, Groth S, et al. Long-term results after endoscopic drainage and necrosectomy of symptomatic pancreatic fluid collections. *Digestive endoscopy : official journal of the Japan Gastroenterological Endoscopy Society*. 2012 Jan;24(1):36-41. PubMed PMID: 22211410.
- [138] Venu RP, Brown RD, Marrero JA, Pastika BJ, Frakes JT. Endoscopic transpapillary drainage of pancreatic abscess: technique and results. *Gastrointest Endosc*. 2000 Apr; 51(4 Pt 1):391-5. PubMed PMID: 10744807.
- [139] Seifert H, Dietrich C, Schmitt T, Caspary W, Wehrmann T. Endoscopic ultrasound-guided one-step transmural drainage of cystic abdominal lesions with a large-channel echo endoscope. *Endoscopy*. 2000 Mar;32(3):255-9. PubMed PMID: 10718392.
- [140] Hookey LC, Debroux S, Delhaye M, Arvanitakis M, Le Moine O, Deviere J. Endoscopic drainage of pancreatic-fluid collections in 116 patients: a comparison of etiologies, drainage techniques, and outcomes. *Gastrointest Endosc*. 2006 Apr;63(4):635-43. PubMed PMID: 16564865.
- [141] Papachristou GI, Takahashi N, Chahal P, Sarr MG, Baron TH. Peroral endoscopic drainage/debridement of walled-off pancreatic necrosis. *Ann Surg*. 2007 Jun;245(6): 943-51. PubMed PMID: 17522520. Pubmed Central PMCID: 1876949.
- [142] Ardengh JC, Baron TH, Taglieri E, Micelli-Neto O, Orsini ET, Mota GA, et al. Programmed EUS-Guided Necrosectomy for Infected Walled-off Pancreatic Necrosis After Severe Acute Pancreatitis. *Gastrointest Endosc*. 2013;77.
- [143] Antillon MR, Shah RJ, Stiegmann G, Chen YK. Single-step EUS-guided transmural drainage of simple and complicated pancreatic pseudocysts. *Gastrointest Endosc*. 2006 May;63(6):797-803. PubMed PMID: 16650541.