

We are IntechOpen, the world's leading publisher of Open Access books Built by scientists, for scientists

4,800

Open access books available

122,000

International authors and editors

135M

Downloads

Our authors are among the

154

Countries delivered to

TOP 1%

most cited scientists

12.2%

Contributors from top 500 universities



WEB OF SCIENCE™

Selection of our books indexed in the Book Citation Index
in Web of Science™ Core Collection (BKCI)

Interested in publishing with us?
Contact book.department@intechopen.com

Numbers displayed above are based on latest data collected.

For more information visit www.intechopen.com



Complications in Spinal Anaesthesia

Alparslan Apan and Özgün Cuvaş Apan

Additional information is available at the end of the chapter

<http://dx.doi.org/10.5772/58817>

1. Introduction

Spinal anaesthesia is one of the most popular and widely used anaesthetic procedures. It is a simple, cost effective and efficient technique that provides complete sensory and motor block, as well as postoperative analgesia with a high success rate. Several advantages of spinal anaesthesia include a decreased incidence of deep vein thrombosis, reduced intraoperative blood loss, as well as the prevention of pulmonary aspiration in case of emergency, especially in patients with potential airway problems and known respiratory diseases.

Due to the invasive nature of spinal anaesthesia, there are several types of complications that may occur with different incidence. At least some of these problems appear to be inevitable and as such, it is not possible to eliminate them all. Fortunately, more severe neurological complications such as death, neuropathy, arachnoiditis and permanent neurologic injury are seldom observed. In a national survey performed in the UK, the incidence of permanent neurologic injury and death ranged from 0.7 to 1.8 in 100,000 patients [1]. On the other hand, proper patient selection, meticulous attention to detail, well-known patient related changes and in the case of difficult circumstances, using image techniques [x rays, fluoroscopy and ultrasound] as a guide may help to prevent or decrease complications.

Increasing co-morbidities, concomitant medication, surgery for advanced malignancy, patients with compromised immune systems, as well as instances of infection poses a real challenge to the use of spinal anaesthesia. Patients with degenerative vertebral anomalies or who have undergone previous spinal surgeries are also difficult cases; these require further evaluation and an increase in efforts for properly performing intrathecal anaesthesia and analgesia in contexts where it may lead to undesirable consequences.

2. Hypotension

Hypotension is an inevitable complication of spinal anaesthesia that occurs when the sympathetic chain becomes blocked, especially when higher dermatome levels are needed. A drop in blood pressure may initiate nausea and vomiting, indicating ischaemia on the spinal cord, which in turn induces an undesired condition for the patient and operating staff. Blood pressure changes between the left lateral to supine position has been determined as an indicator for predicting a perioperative decrease in obstetric patients undergoing caesarean delivery under spinal anaesthesia [2].

In a non-obstetric study population, changing patients to the Trendelenburg position for 10 minutes immediately following a spinal block has been demonstrated as efficient, as has loading with a lactated ringer or 6% hydroxyl ethyl starch solution by means of maintaining cardiac output. Co-hydration is more efficient than pre-hydration and colloid loading is better for maintaining cardiac output and blood pressure [3]. In their report, Shin et al. [4] investigated the influence of crystalloid and colloid loading on cerebrospinal fluid movements in volunteers, as well as the spread of local anaesthetics in patients. Although crystalloid pre-treatment delayed the cranial spread of the block, it induced cerebrospinal fluid production, which may be valuable in the case of post-dural-puncture headache [PDPH].

In case of pregnancy, a decrease in blood pressure at the critical level may affect both mother and baby, and result in more serious outcomes over a longer period. Increased venodilatation under the influence of progesterone or prostaglandins may also contribute to changes in blood pressure. The presence of hypertension, advanced age, increased body mass index, higher birth weight and higher block are considered as risk factors in hypotension performed with spinal anaesthesia. Fluid loading, lateral tilt or wedge performed under the right buttock to prevent aortocaval compression, or vasopressor therapy, constitutes preventive measurements to treat hypotension in obstetric patients. The influence of aortocaval pressure or other determinants remain controversial in terms of how they contribute to haemodynamics during spinal anaesthesia. In order to attenuate the effect of hypotension, the influence of positioning the patient on a lateral decubitus position for a brief period was investigated. The hypotension episode showed a slight delay, but the incidence of hypotension or drug use was the same as observed in patients lying supine] [5]. In an editorial, Sharwood-Smith and Drummond [6] criticized the role of vena caval compression in light of the presence of persistent vasoconstriction, such as observed in patients with pre-eclampsia, which is known to be volume depleted or hypovolemic; hypotension, however, was observed to a lesser extent. These observations justify vasopressor therapy and indicate that sympathetic block affecting arterial vasculature might be a major concern related to arterial pressure drop [6].

Time, duration and the selection of vasoactive drugs are controversial issues where obstetric patients are concerned. Ephedrine may stimulate beta adrenergic receptors by crossing the umbilical cord and increasing foetal acidosis; therefore, phenylephrine has become the vasopressor of choice [7]. Variable infusion has been demonstrated as being superior to the fixed infusion and $25\text{--}50\ \mu\text{g min}^{-1}$ was demonstrated to be sufficient or maintaining hemodynamic status. Non-invasive cardiac output monitoring might be indicated for a patient with

severe cardiac disease [8]. On the other hand, a phenylephrine infusion may induce bradycardia, presumed (or) indicated by the baroreflex receptor mediated mechanism [9].

3. Hypothermia

A decrease in body temperature is commonly encountered after neuraxial anaesthesia. Subarachnoid local anaesthetic administration blocks all afferents of skin temperature that patients are unable to release the decrease in core temperature. Vasodilation due to sympathetic blockade increases skin blood flow, which allows for lowering the body's core temperature in a reliable manner. In preparing the skin for surgery with antiseptic solutions, especially when performed on a large area, evaporation from surgical field and irrigation solutions, or fluid infusion at a higher rate, may also contribute to hypothermia during surgery. [Fig 1] A decrease in core temperature may initiate shivering, especially during the postoperative period, which increases oxygen consumption. Hypothermia is known to induce hyper coagulation and infections. Special care should be exerted to decrease this physiologic stress, especially in paediatric, obstetric and patients in advanced age, since it may lead to serious consequences, including low perfusion to the vital organs, coronary ischaemia and infection [10].

It is crucial to warm the patient with blankets, surgical thermal mattresses, forced air heaters, by using pre-warmed irrigation, intravenous solutions and blood products in order to decrease the severity of this complication.

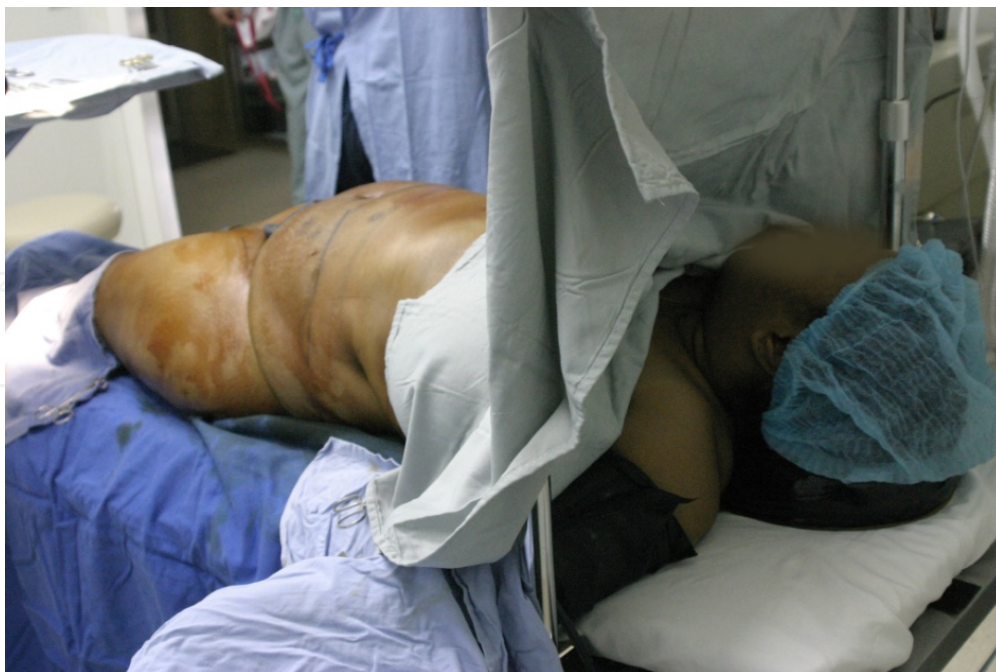

Figure 1. Large areas of skin prepped with a Povidone-iodine solution and uncovered during surgery favour hypothermia and its complications [Source: www. anestesia-dolor. org].

4. Post-dural-puncture headache

PDPH is a troublesome complication, mostly observed in middle-aged women and the obstetric population. Lower body mass index, previous PDPH and the presence of chronic headaches are other risk factors. Headache rarely occurs in the paediatric population, especially in neonates, but some physicians believe that this may be due to the inability to communicate pain in early childhood. PDPH also decreases with age, which may be related to changes in the composition of cerebral content, which increase on cerebrospinal fluid [CSF] that may compensate and prevents its occurrence.

PDPH requires differentiation from other causes of headache [11]. It typically occurs in the fronto-occipital region with nuchal rigidity and initiates when moving from the supine position to sitting or standing up. It may vary from mild to severe and the type of pain may be dull, throbbing or burning. Vertigo, nausea and vomiting might be observed due to PDPH in some patients. Headache typically appears on the second day following the dural puncture and can range from lasting one to four days, but may be observed as early as 20 min after the dural puncture [12]. The leaking of CSF across the dural hole may initiate PDPH. This is explained by the following mechanisms: a decrease in intracranial pressure causes the traction of pain sensitive cranial structures, the depletion of CSF volume may induce compensatory cerebral vasodilatation [the Monroe-Kelly doctrine] and the activation of adenosine receptors may cause cerebral vasodilatation [13].

The incidence of PDPH has been reported at a level of 2.5% when using a 25 G pencil point needle in obstetric patients [14]; in the non-obstetric population, the incidence of PDPH is as low as 0.37% when using fine spinal needles [15]. Cutting edge needles are not recommended for spinal anaesthesia, due to the increased incidence of PDPH, even when using fine needles in patients undergoing anorectal surgery [16].

Accidental dural entry is a more distressing event that occurs while advancing the Tuohy needle or epidural catheter, resulting in PDPH at a level of about 75%. The epidural catheter is presumed to introduce from weak points of dura which may occur with Tuohy needle. Incidence of this occurring has been reported as 0.5% in an obstetrical referral centre [17]. It is not possible to recognize or observe clear CSF in needles or catheters in all patients. Therefore, as a treatment tool, re-inserting the epidural catheter in a different lumbar interspace, or leaving the catheter in the perforated dura mater with the intent to decrease PDPH does not succeed in all patients.

Patient position when performing spinal anaesthesia, the experience of the physician and using finer needles do not appear to influence the occurrence of PDPH [17]. Pneumocephalus with subsequent PDPH is a rare but well-described complication of unintentional dural puncture. It has late clinical onset manifestations and can induce a long-lasting headache as a result of accidental dural entry when epidural anaesthesia is performed by means of the loss of resistance technique, using air [18].

The treatment algorithm depends on the severity of PDPH. Conservative treatment consists of bed rest and oral or intravenous fluid replacement. Pharmacological therapy includes

analgaesics, vasoconstrictors or drugs that increase CSF production. Paracetamol or non-steroidal anti-inflammatory drugs are used as first step treatment. Vasoconstrictors, such as caffeine and Sumatripan, have been used but with limited benefits. Caffeine should be prescribed with caution due to the patient having a lowered convulsion threshold and long term administration is not advised. Gabapentin has also been used successfully for the treatment of PDPH. Drug therapy may provide relief, but do not completely resolve the symptoms. Epidural morphine has also been demonstrated as beneficial but may leak from the dural hole into the intrathecal space and has well-known side effects such as pruritus, nausea and vomiting [19].

Although controversies surrounding it remain, the epidural blood patch [EBP] remains the gold standard for treating PDPH. A sterile sample of 15-20 mL autologous blood is drawn from the patient and immediately injected at the same or a lower level inside the epidural space, until backache or dullness can be felt. It is generally performed after waiting 24 hours following the epidural block. If PDPH persists, a second EBP a week later may be necessary. A third EBP is seldom needed. In a series of cases, the volume of blood needed was reduced while performing EBP under fluoroscopy guidance [20].

The witnessed accidental dural entry has different treatment options. Advancing an epidural catheter to the subarachnoid space, injecting 10 mL of saline initially and leaving the catheter in place for 24 hours are helpful for decreasing the incidence of PDPH. A catheter is believed to induce inflammatory reaction to the dural hole and closure may occur during withdrawal of catheter. At the very least, the presence of the epidural catheter may impede CSF leakage. Epidural catheter placement in a different interspace has also shown potential benefits. Epidural saline or a dextran infusion for creating a fluid column has limited therapeutic efficacy, possibly due to the easy reabsorption from dural veins [21]. Fibrin glue was also used, especially in patients who refuted the therapy or any other contraindications such as coexisting systemic infection [22]. Surgical treatment is the final step; this only occurs if chronic leakage persists [23].

Cranial hypotension and long-lasting CSF loss may distract cerebral bridging veins that can easily rupture and lead to acute or chronic subdural or subarachnoid haematoma occurring. Caution should be applied when spinal anaesthesia is implemented in a patient who has experienced recent cranial trauma, the likes of which may either facilitate or confuse the outcome. Neurological investigation should be performed when the headache lasts more than a few days and is resistant to the conservative treatment [2]. Spinal haematoma is a rare event that may relate to the direct needle trauma [25].

Chronic leakage and cranial hypotension may influence cranial nerves and nerve palsies may rarely occur due to compression or altered blood supply. It mostly affects the VI cranial nerve; the reason for this might be attributed to its longer course (or path) in cranium [26]. Treatment modalities against CSF leakage and specific therapy for nerve palsy, including corticosteroids, have been demonstrated as being beneficial [27]. Altered mental status and speech or stupor may be observed with intracranial hypotension, headache, nausea and vomiting, and determined as posterior reversible encephalopathy syndrome presenting as oedema in the posterior cerebral portions with MRI. This syndrome is largely related to the systemic illness that was

first described in an obstetric patient following spinal anaesthesia. The late onset and course of the syndrome implicates compression of posterior portion of the brain vault due to chronic loss of CSF [28]. Reversible cerebral vasoconstrictor syndrome is another entity that has similar clinical features such as headache but lacks imaging findings [29].

Hearing loss is another complication related to loss of CSF during spinal anaesthesia. Hearing disability especially affects low frequencies on audiometry and commonly occurs at the second post spinal block. Studies have shown that aims to decrease incidences of leaking CSF using fine and pencil-point-tipped spinal needles can decrease this complication [30]. Type intravenous fluid loading either using crystalloid or colloid do not seem to largely influence or prevent the presence of auditory malfunctions [31].

5. Transient neurologic symptoms

Radicular symptoms, including pain, a burning sensation on the buttocks, dysaesthesia and paraesthesia may be observed following spinal anaesthesia. These symptoms generally subside within two days. But these clinical features are alarming for possible serious consequences. There is no representation of these symptoms on radiographs, CT or MRI. Ambulatory surgery, lithotomy position, the type of local anaesthetic used, as well as the concentration of dextrose and osmolarity has been mentioned as contributing factors for transient neurologic symptoms. The use of spinal lidocaine is one factor that may increase the incidence of transient neurologic symptoms, especially when some factors are combined. An increase in local anaesthetic concentration by pooling and maldistribution may also increase the incidence of this complication [32]. In a review by Zaric et al. [33], the authors indicated that the relative risk was about seven-to eight-fold lower with other local anaesthetics such as bupivacaine, mepivacaine, and prilocaine.

6. Urinary retention

Bladder distension during the postoperative period produces discomfort to patients and unless relieved, leads to more severe complications, including permanent injury to the detrusor muscle. Spinal anaesthesia influences urination by blocking all afferent nerve fibres, rendering the patient unable to feel bladder distension or urinary urgency. Bladder catheterization is not innocuous; it carries the risk of urethral trauma and more severe complications, including infection and haematologic spread that may reach the surgical site [34]. Urodynamic studies indicate that the function of the detrusor muscle returns to normal after about 100 min longer than the sensorial level regression from the S2 to S3 level [35]. It has been demonstrated that spontaneous urination may be influenced by an intrathecal local anaesthetic; long-acting agents require a longer time to recover from urinary function [36].

Several surgical risk factors may increase the incidence of urinary retention, such as anorectal surgery, inguinal hernia, orthopaedic [especially hip] surgery, abdominal surgery, instrumen-

tal delivery, prolongation of labour and gynaecologic surgery [37]. Patient characteristics showed that being predisposed to urinary retention included the male gender, 50 years and older and the presence of urination problems [38]. Besides neuraxial anaesthesia, some of the anaesthesia-related or intraoperative factors are prolongation of anaesthesia or surgery, increased intraoperative fluid volume [>750 mL], a required atropine, decreased body temperature and opioid-based anaesthesia, which may increase urinary retention [38, 39]. Spinal anaesthesia may also contribute to this complication by increasing or contributing to the requirements of at least several factors mentioned above.

Commonly used additives such as opioids or epinephrine may also increase the time leading up to urinating. In a meta-analysis, hydrophilic opioids were more prone to contribute to urinary retention than lipophilic compounds, which are especially important for outpatient surgery [40]. The gap between general anaesthesia and neuraxial blocks are decreased when systemic opioids are predominantly used for pain control [38]. The duration of spinal anaesthesia performed with hyperbaric local anaesthetics is shorter than more plain solutions, which may also be preferred [41]. Interestingly, when compared to the same intrathecal dose, more dilute solutions of local anaesthetics regressed earlier and regained bladder function faster [42]. Short-acting local anaesthetics, the administration of which should be given in as low a dose as possible, a plain or hyperbaric solution with no additives and avoiding an unnecessary increase of sensorial levels may decrease this complication in susceptible individuals within the outpatient setting. Indeed, a meticulous review indicates that there is no risk involved in single shot spinal anaesthesia when such precautions are taken [43]. Bladder volume is also an important issue during admission to the intensive care unit. Single bladder catheterization may be necessary during the peri-operative period or immediately following surgery. Ultrasound may precisely determine the bladder volume in adults and can be an important part of routine use in post-anaesthesia care units [44]. A multimodal approach for postoperative pain regarding the decrease of systemic opioids might be beneficial to avoid unnecessary hospital re-admissions. Non opioids, non-steroid anti-inflammatory drugs and other regional techniques such as wound infiltration and peripheral nerve blocks have also been demonstrated to decrease urinary retention [43].

7. Haematologic complications

Spinal haematoma following spinal anaesthesia is a severe complication that requires early surgical intervention to prevent permanent neurological damage. Classically, the incidence of this condition has been accepted as 1 in 220, 000 patients undergoing spinal anaesthesia, but the actual incidence remains unknown and is presumed to be on the increase. Advanced age, female gender, patients receiving drugs that influence coagulation, difficulty in performing block and placement of the indwelling epidural catheter are mentioned as risk factors [45]. A study investigating neurologic complications after neuraxial block, performed in Sweden over a period of ten years, indicates an increased incidence in female patients undergoing hip fracture surgery – 1 in 22, 000 compared to 1 in 480, 000 when all patients were included [46]. Haematoma was more frequently encountered with epidural anaesthesia or catheter place-

ment, because of the increased vascularity of the epidural space. The presence of haematoma is frequently suspected in the case of an unexpected increase in the duration of motor block or delay on recovery. Neurosurgery within eight hours after the epidural haematoma is mandatory to regain motor functions without neurologic harm. Should neurologic harm be suspected, imaging studies, including computed tomography or preferably MRI, should be implemented as early as possible. Unfortunately, neurologic outcomes have been poor for the majority of patients, even when surgery was performed within eight hours. Spinal catheters should be considered as epidural catheters, for which placement or removal requires strict adherence to withdrawal guidelines to avoid having an effect on anticoagulation therapy.

Many drugs interfere with blood clotting, thereby requiring adherence to recommendations for the removal of neuraxial catheters. A number of regional anaesthesia societies have published their own recommendations [47, 48, 49]. Recent evidence indicates spinal anaesthesia to be safe, provided the half-life of the drug or residual effects are monitored. Non-steroidal anti-inflammatory drugs are considered safe, but concomitant drug use can increase the risk of haematoma. Therefore, patients receiving more than one drug affecting coagulation should be carefully evaluated. Additionally, some herbal drugs only or in combination with anticoagulants can increase the risk of spinal haematoma [45].

Central neuraxial blocks in patients with pre-existing haematologic disorders or disease affecting coagulation do not appear to be a significant problem. In their review, Choi and Brull [50] investigated the outcome of neuroaxial anaesthesia in patients with common bleeding disorders. A total of 78 spinal anaesthetics, 53 diagnostic lumbar punctures and two combined spinal and epidural anaesthetics were performed. No bleeding complications were observed, except in one infant, who was an unknown haemophilia A, developed spinal haematoma and needed surgical decompression. Spinal anaesthesia appears to be safe in patients with known bleeding disorders, provided that the status of coagulation is monitored. Although there is no consensus concerning a safe platelet count, 50,000 to 80,000 mm^3 is generally considered a critical number for spinal or epidural anaesthesia. Individual patient assessment should be conducted in patients with lower platelet counts [51]. For more details, the reader is referred to the chapter on spinal haematoma included in this book.

8. Infectious complications

Although bacterial meningitis following neuraxial anaesthesia is an uncommon complication, in cases where it does occur it may result in severe harm, including permanent neurologic disability and death. The presence of a fever and neurologic disturbance may provide a differentiation from PDPH. Epidural abscess is generally caused by skin flora; the bacteria most frequently involved is *S. aureus*. It is therefore prudent to initiate treatment with synthetic penicillin, even in the absence of a positive culture. Other less common causes of infection are aerobic and anaerobic streptococci, and anaerobic gram-negative bacilli. The incidence of meningitis varies between 1 in 50,000 and mostly occurs as a result of airborne pathogens. The exact mechanism for how the microorganism reaches the spinal

cord remains controversial. It may occur during preparation or performing the block, with a droplet from medical personal is the predominant source. Infection is more likely to occur in streptococci in most of the cases, emphasizing the need for strict adherence to precautions while performing spinal anaesthesia [52].

A case report and review from the literature indicates 179 cases of bacterial meningitis related to the central neuraxial puncture for any indication covering the period 1952 to 2005, in which 54% was related to spinal anaesthesia and 5% was observed for the combined spinal and epidural technique, which included 15 obstetric patients. Technical difficulties during placement of the needle or repeated attempts to spinal anaesthesia appear to be contributing factors [53].

Spinal anaesthesia in patients with coexisting infection is a controversial issue. In their study, Gritsenko et al. [54] retrospectively reviewed patients who had undergone removal of an infected prosthesis due to hip or knee arthroplasty performed under neuraxial anaesthesia to look for possible associations between perioperative infection and postoperative neuraxial complications regarding meningitis or epidural abscess. Although higher incidence of positive joint culture or pus was found during these procedures, none of the patients included in the 474 cases demonstrated infectious complications during the postoperative period. A study performed by Bader et al. [55] investigated 319 obstetric patients with chorioamnionitis, eight of whom had bacteraemia, but none developed neuraxial infection following neuraxial anaesthesia. A similar study of 517 patients with the same pathology, including 13 cases of systemic infection, demonstrated no meningitis or epidural abscess [56]. These results indicate that the possibility of haematologic spread through the spinal cord from the remote site as an infectious source is less likely to occur; regardless, clinicians are advised to perform the block under empirical antibacterial therapy.

Spinal anaesthesia in a patient with immunodeficiency is another instance where the presence of infection has been observed to lead to positive CSF culture and infection [57]. Therefore, performing spinal anaesthesia in such patients requires strict attention and may be attempted in combination with antibiotic treatment.

On the other hand, in a large prospective study including obstetric patients, general anaesthesia was associated with a higher incidence of surgical site infection and post-operative hospital stay compared to the use of spinal or epidural blocks [58].

9. Neurologic complications

A review by Brull et al. [59], which included a large series of neurologic complications, reported that the incidence of permanent neurological injury following spinal anaesthesia varied between 0 to 4.2 per 10 000 patients. In a French survey, permanent neurological injury other than that caused by haemorrhage was more common and included injury to the conus medullaris, and the estimated risk was calculated as 1:78 660 spinal anaesthesia patients; incidence was nearly half the amount in obstetric patients compared to the non-obstetric

population. Pre-existing spinal pathology or disease increases the incidence of postoperative neurologic complications following neuraxial blockade. Repeated attempts or improper positioning of patients may facilitate neurologic injury [60]. Lumbar canal stenosis is another contributing factor for adverse neurologic outcome [61]. The presence of scoliosis with or without prior surgery constitutes difficulties for performing neuraxial anaesthesia. When compared to spinal blocks, the success rate was lower with epidural anaesthesia, due to technical difficulties and improper distribution of local anaesthetics [62]. Although the precise mechanism was not determined, hydrostatic pressure performed during an epidural block was indicated as a possible source of injury. On the other hand, direct needle trauma appears to be one of the preventable reasons for neurological complications. It is best to withdraw the needle in the case of paraesthesia, which is highly associated with postoperative radiculopathy and repeating local anaesthetic injection should be avoided in order to prevent toxic concentrations in the spinal cord [63].

Reynolds [64] reported a series of cases of conus medullaris injury that including one non-obstetric and six obstetric female patients, resulting in long-lasting neurologic damage. Spinal anaesthesia was performed in three of the patients, while combined spinal and epidural anaesthesia was accomplished in the rest of the other patients. Only one patient suffered pain during needle placement. The possible reasons for this were indicated as misplacement of the needle at the lower end of the spinal cord, misidentification of Tuffier's line or that the arachnoid membrane may have been attached to the conus like a web. Author concluded that Tuffier's line was an unreliable method for identifying the correct intervertebral level [64]. Possibly, the addition of cutaneous and subcutaneous tissue over the crista iliaca in obese patients, or in the case of pregnancy, may erroneously lead to performing a higher intervertebral space for needle placement. Indeed, Broadbent et al. [65] demonstrated that an anaesthesiologist incorrectly identified the correct intervertebral space by palpation. Assuming the correct intervertebral space was correct in only 30% of patients using palpation and in 71% using ultrasound [66]. In a MRI study of 690 patients, Kim et al. [67] indicated that caution should be exercised when selecting the appropriate intervertebral space, especially in obese and elderly patients. The level of conus medullaris might be lower than expected in female patients with thoracic vertebral compression fractures [68]. These points have also been highlighted along with determining lateral needle deviation or placement as a source of possible reasons for neurological injury in a study group by the American Society of Regional Anesthesia [ASRA]; clinicians are advised to especially be aware of challenging surface anatomical changes [69]. Ultrasound imaging can also be used to guide proper accomplishment of neuraxial anaesthesia. Although promising results have been published on facilitating neuroaxial anaesthesia in difficult cases by means of decreasing the time and number of attempts [70], to date, it is not yet possible to conclude that using an ultrasound guide may decrease complications [69]. Anaesthesiologists should also be cautious concerning patients with pre-existing comorbidities, such as peripheral vascular disease and diabetes mellitus, which may present subclinical neuropathies that could predispose the patient to neurological deficits following spinal anaesthesia [71].

Skin antiseptics like chlorhexidine have proven to be superior to iodopovidone-based solutions. ASRA advises using chlorhexidine in an alcohol solution prior to all regional anaesthetic interventions to prevent infectious complications [72]. In a recent retrospective study, the neurological complication rate when using chlorhexidine was found to be similar to the findings of other surveys [57]. However, using chlorhexidine is not entirely devoid of risk. In an editorial, Bogod [73] published two cases of chlorhexidine inducing permanent neurological injury. In one case, chlorhexidine solution was inadvertently administered into the epidural space. In the second case, 0.1 mL antiseptic of solution (chlorhexidine) mixed with a local anaesthetic was wrongly administered to the subarachnoid space. The author advised using a spray formulation for skin preparation, warning against high concentrations [more than 2%]. Applying one puff was concluded to be sufficient and emphasize was placed on waiting for the skin to dry.

Figure 2 shows medullaris cone injury secondary to attempted spinal anaesthesia in an obstetric patient undergoing a caesarean section. This patient had severe pain during bupivacaine injection. The injury was managed with steroids. Final neurological damage was minimal.

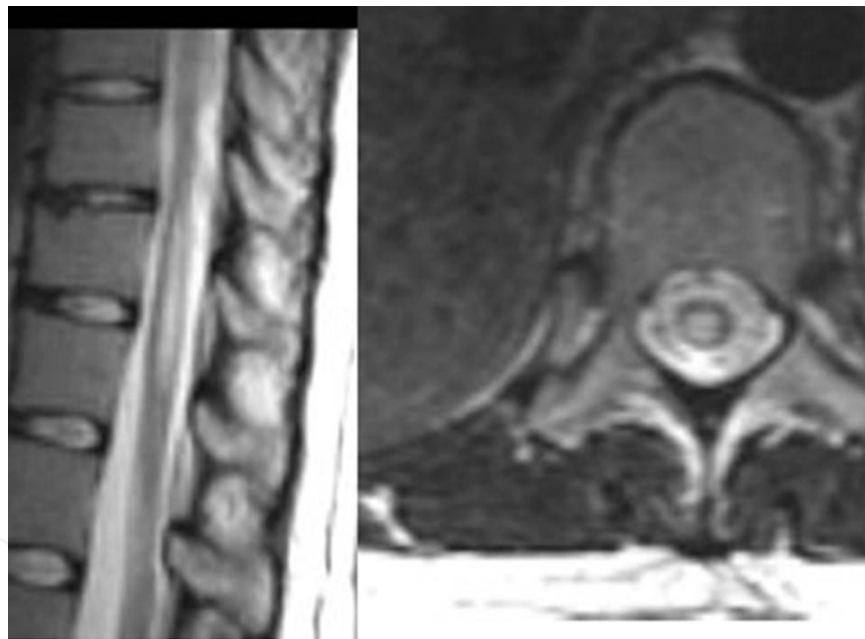


Figure 2. Sagittal and axial images of the conus medullaris T2 weighted FSE in which a high signal is noted at the centre position, with conus oedema and/or haemorrhage caused by a spinal needle (Source: www.anestesia-dolor.org).

10. Neurological diseases

Patients with pre-existing neurological diseases such as multiple sclerosis, amyotrophic lateral sclerosis, or a post-poliomyelitis condition have previously been considered as

relative contraindications for neuraxial anaesthesia. A double crush phenomenon was described to explain the deterioration of neurological disease in the case of vulnerable neurons. It is believed that mechanical trauma caused by a needle or catheter, toxicity induced by local anaesthetics or neural ischaemia due to additives could worsen the patient's neurological status. Increased stress may induce inflammation deteriorates the clinical course, that may confuse with neural injury due to the procedure. However, recent evidence has demonstrated that spinal anaesthesia might be an option in this patient group [72].

Neuraxial anaesthesia in patients with spinal canal pathology, including lumbar disk disease, spinal stenosis or previous surgery, is another issue that requires special concern. In a retrospective review, Hebl et al. [74] found that patients with pre-existing spinal canal pathology demonstrated a higher rate of neurological complications. However, a lack of control groups receiving general anaesthesia presents a difficulty for describing results pertaining to whether complications occur due to surgery or because of the natural progression of disease. Additionally, due to data combinations, it is also impossible to conclude the particular role of single shot spinal anaesthesia. Trauma and complications may be more common when using large gauge Tuohy needles, or during catheter placement. Epidural anaesthesia and catheter placement in patients with previous spinal surgery appear to be more complicated, even when performed by experienced hands [75]. These patients require special attention in terms of evaluating the use of neuraxial anaesthesia, preoperative neurological evaluation and special care in order to prevent additional injuries.

In rare instances, silent pathologies involving the spinal column may induce acute post-operative neurological complications such as tuberculosis [76] or unrecognized spinal tumour [77]. Patients with coexisting or previous low back pain and paraesthesia or neurologic deficits should be carefully assessed preoperatively and their evaluation should include a detailed neurologic examination and radiological images. Moreover, patients with neural tube defects should be assessed earlier to determine the conus medullaris level or other possible associated anomalies to decide whether neuraxial techniques will provide them with safe anaesthetic options.

Patients like those described above are at higher risk of neurological complications than the rest of the general population [78]. Postoperative neurological complications were observed in a patient presenting adhesive arachnoiditis, extensive syringomyelia and a giant arachnoid cyst in the patient had been managed with a combination of spinal and epidural anaesthesia. These rare complications were linked to a reaction caused by the subarachnoid, the epidural drug, or as a result of catheter induced inflammation or trauma [79].

The images in Figure 3 show a case of multiple neurofibromatosis with intrathecal participation, which was managed with uncomplicated spinal anaesthesia.

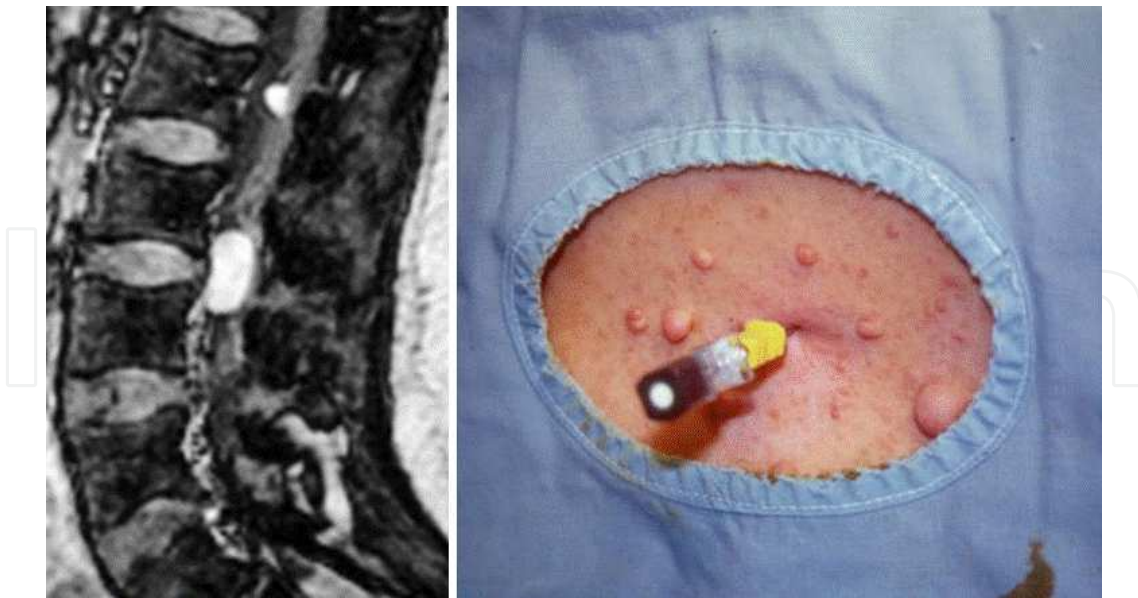

Figure 3. Forty-year-old patient with multiple neurofibromatosis. She was anesthetized successfully with spinal anaesthesia for an abdominal hysterectomy. The back of the patient shows numerous skin tumours and some cafe au lait spots. The sagittal image of the lumbar spine in post-spin echo fat-suppressed contrast demonstrates intradural solid tumours in cauda equina nerves (Source: www.anestesia-dolor.org).

11. Cardiac arrest and perioperative death

Bradycardia and cardiac arrest are the most worrisome complications related to spinal anaesthesia. The incidence of these conditions has been observed to be higher with spinal block in comparison with general anaesthesia. Patients are generally healthy, ASA class I or II, athletic and male with parasympathetic overtones. The influence of cardio-accelerator fibres originating between T1 to T4 plays a crucial role in maintaining blood pressure and heart rate according to the level of anaesthesia induced by spinal block, depleted vascular volume or insufficient replacement with fluids, and the presence of deep sedation is considered a risk factors for bradycardia and cardiac arrest. Surgical intervention may also trigger bradycardia and cardiac arrest by vagal discharge or embolization. In the case of severe bradycardia, early administration of epinephrine is important, especially in unresponsive cases to atropine and ephedrine that should be administered previously [80]. Most patients are monitored in the operating theatre, therefore early recognition of bradycardia and cardiac arrest and intervention is possible. Survival rate is higher in patients with cardiac arrest observed during spinal anaesthesia compared to cases using general anaesthesia. [81]. A study by Chatzmichali and colleagues [82] showed that assessment of heart rate variability in the preoperative period may help to determine perioperative severe bradycardia. Clinicians must be cautious when performing deep intravenous sedation, especially in patients with increased body weight, since it may lead to death in the early postoperative period.

12. Miscellaneous complications

Myoclonus occurs rarely as a complication of spinal anaesthesia in the postoperative period. It may commonly be observed in the presence of systemic illness, drug use or with a pre-existing vitamin B deficiency. Although the underlying mechanism for myoclonus in this instance is unclear, the possibility of subclinical neuropathy has been mentioned [83]. Long-term treatment, including neuroleptics and benzodiazepines, might be required to relieve the symptoms of myoclonus [83].

Exposure to the halogenated compounds during general anaesthesia is an interesting topic, especially in the context of the brain, which is currently under development as it relates to aged patients. Spinal anaesthesia appears to be safe for preventing postoperative delirium and cognitive dysfunction in the elderly, especially when additional measurements such as early pain management, supplemental oxygen, fluid, caloric replacement and morphine avoidance are applied [84].

Table 1 is a summary of the complications of neuraxial anaesthesia found in Finland. The authors reported 1:17 741 spinal block cases and 1:24 285 cases of epidural blocks. Complications were more severe in the application of spinal anaesthesia.

Claim motive	Spinal	Epidural	Total
Cardiac arrest	2 [2]	0	2
Neurological	31 [19]	7 [4]	38
Infectious	4 [4]	6 [2]	10
Local anaesthetics acute toxicity	0	2 [2]	2
Opioid overdose	0	1 [1]	1
PDPH	9	8	17
Others	13	3	16

Patients who died or contracted permanent neuronal damage are shown in parentheses

Table 1. Severe complications associated with epidural and spinal anaesthesia [85].

13. Conclusions

Various complications may occur during spinal anaesthesia and are widely related to the procedure itself or drugs used during the procedure. These complications occur with differing incidence and in the case of at least some, appear to be inevitable and to be expected due to the invasive nature of the blockade.

Many of these complications can be reduced with meticulous attention to the details during the performance of the spinal block. The procedure may be rendered more patient-oriented

and convenient by selecting the appropriate technique, drugs and their doses. It is of prime importance that the incidence of hypotension should be decreased, as this can induce serious adverse outcomes. Ultrasound guides may be helpful for decreasing complications in difficult cases. In order to decrease serious complications, patient selection and adherence to the guidelines appears to be fundamental. (such as patients with previous lumbar surgery as mentioned)

Author details

Alparslan Apan and Özgün Cuvaş Apan

Giresun University Faculty of Medicine Department of Anaesthesiology and Intensive Care Medicine , Giresun, Turkey

References

- [1] Cook TM, Counsell D, Wildsmith JAW. Major complication of central neuraxial block: report on the third national audit project of the Royal College of Anaesthetists. *Br J Anaesth.* 2009;102:79-90.
- [2] Jeon YT, Hwang JW, Kim MH, Oh AY, Park KH, Park HP, Lee Y, Do SH. Positional blood pressure change and the risk of hypotension during spinal anesthesia for cesarean delivery. *Anesth Analg.* 2010;111:712-5.
- [3] Zorko N, Kamenik M, Starc V. The effect of Trendelenburg position, lactated ringer's solution and hydroxyethyl starch solution on cardiac output after spinal anesthesia. *Anesth Analg.* 2009;108:655-9.
- [4] Shin BS, Kim CS, Sim WS, et al. A comparison of the effects of preanesthetic administration of crystalloid versus colloid on intrathecal spread of isobaric spinal anesthetics and cerebrospinal fluid movement. *Anesth Analg.* 2011;112:924-30.
- [5] Hwang JW, Oh AY, Song IA, Na HS, Ry JH, Park HP, Jeon YT, Do SH. Influence of prolonged lateral position in induction of spinal anesthesia for cesarean delivery: a randomized controlled trial. *Minerva Anesthesiol.* 2012;78:646-52.
- [6] Sharwood-Smith G, Drummond GB. Hypotension in obstetric spinal anaesthesia: a lesson from pre-eclampsia. *Br J Anaesth.* 2009;102:291-4.
- [7] Nygan Kee WD, Khaw KS, Lau TK, Ng FF, Choi K, Ng KL. Randomized double-blinded comparison of phenylephrine vs. ephedrine for maintaining blood pressure during spinal anaesthesia for non-elective Caesarean section. *Anaesthesia.* 2008;63:1319-26.

- [8] Langesaeter E, Dyer RA. Maternal haemodynamic changes during spinal anesthesia for caesarean section. *Curr Opin Anesthesiol.* 2011;24:242-8.
- [9] Nygan Kee WD, Khaw KS, Ng FF, Lee BB. Prophylactic phenylephrine infusion for preventing hypotension during spinal anesthesia for cesarean delivery. *Anesth Analg.* 2004;98:815-21.
- [10] Crowley LJ, Buggy DJ. Shivering and neuraxial anesthesia. *Reg Anesth Pain Med.* 2008;33:241-52.
- [11] Bezov D, Lipton RB, Ashina S. Post-dural puncture headache: part I diagnosis, epidemiology, etiology, and pathophysiology. *Headache.* 2010;50:1144-52.
- [12] Lomax S, Qureshi A. Unusually early onset of post-dural puncture headache after spinal anaesthesia using a 27 g Whitacre needle. *Br J Anaesth.* 2008;100:707-8.
- [13] Hendricks M, Stocks GM. Post-dural puncture headache in the parturient. *Anaesth Intensive Care Med.* 2007;8:309-11.
- [14] Douglas MJ, Ward ME, Campbell DC, Bright SB, Merrik PM. Factors involved in the incidence of postdural puncture headache with 25 gauge Whitacre needle for obstetric anesthesia. *Int J Obstet Anesth.* 1997;6:220-3.
- [15] Satanen U, Rautoma P, Luurila H, et al. Comparison of 27 gauge Whitacre and Quincke spinal needles with respect to postdural puncture headache and non-dural puncture headache. *Acta Anaesthesiol Scand.* 2004;48:474-9.
- [16] Schmittner MD, Terboven T, Dluzak M, Janke A, Limmer ME, Weiss C, Bussen DG, Burmeister MA, Beck GC. High incidence of post-dural puncture headache in patients with spinal saddle block induced with Quincke needles for anorectal surgery: a randomized clinical trial. *Int J Colorectal Dis.* 2010;25:775-81.
- [17] Van Der Velde M, Schepers R, Berends N, Vandermeersh E, De Buck F. Ten years of experience with accidental dural puncture headache in a tertiary anaesthesia department. *Int J Obstet Anesth.* 2009;17:329-35.
- [18] Velickovic IA, Rostislav P. Pneumocephalus complicated by postdural puncture headache for unintentional dural puncture. *Anesth Analg.* 2007;104:747-8.
- [19] Al-metwalli RR. Epidural morphine injections for preventing of post dural puncture headache. *Anaesthesia.* 2008;67:847-50.
- [20] Kawaguchi M, Hashizume K, Watanabe K, Inoue S, Furuya H. Fluoroscopically guided epidural blood patch in patients with postdural puncture headache after spinal and epidural anesthesia. *J Anesth.* 2011;25:450-3.
- [21] Boyle JAH, Stocks GM. Post-dural puncture headache in the parturient an update. *Anaesth Intensive Care Med.* 2010;11:302-4.

- [22] Schievink WI, Maya MM, Moser FM. Treatment of spontaneous intracranial hypotension with percutaneous placement of fibrin sealant: report of four cases. *J Neurosurg.* 2004;100:1098-100.
- [23] Schievink WI, Morreale VM, Atkinson JL, Meyer FB, Piepgras DS, Ebersold MJ. Surgical treatment of spontaneous spinal cerebrospinal fluid leaks. *J Neurosurg.* 1998;88:243-6.
- [24] Zeidan A, Chaaban M, Farhat O, Barka A. Cerebral rebleeding by spinal anesthesia in a patient with undiagnosed chronic subdural hematoma. *Anesthesiology.* 2006;104:613-4.
- [25] Lam DH. Subarachnoid haematoma after spinal anaesthesia mimicking transient radicular irritation: a case report and review. *Anaesthesia.* 2008;63:423-7.
- [26] Arcand G, Girard T, McCormack M, Chouinard P, Boudreault D, Williams S. Bilateral sixth cranial nerve palsy after unintentional dural puncture. *Can J Anaesth.* 2004;51:821-3.
- [27] Fang JY, Lin JW, Li Q, Jiang N, Gao Y. Trigeminal nerve and facial nerve palsy after combined spinal-epidural anesthesia for cesarean section. *J Clin Anesth.* 2010;22:56-8.
- [28] Ho CM, Chan KH. Posterior reversible encephalopathy syndrome with vasospasm in a postpartum woman after postdural puncture headache following spinal anesthesia. *Anesth Analg.* 2007;105:770-2.
- [29] Takeuchi S, Nagatani K, Otani N, Nawashino H. PRES after spinal anesthesia. *J Headache Pain.* 2011;12:389.
- [30] Malhotra SK, Iyer BA, Gupta AK, Raghunatan M, Nakra D. Spinal analgesia and auditory functions: a comparison of two sizes of Quincke needle. *Minerva Anesthesiol.* 2007;73:395-9.
- [31] Yildiz TS, Solak M, Iseri M, Karaca B, Toker K. Hearing loss after spinal anesthesia: the effect of different solutions. *Otolaryngol Head Neck Surg.* 2007;137:79-82.
- [32] Enron S, Gurstieva V, Ezri T, Gladkov V, Shopin S, Herman A, Sidi A, Weitzman S. Transient neurologic symptoms after isobaric subarachnoid anesthesia with 2% lidocaine: the impact of needle type. *Anesth Analg.* 2007;105:1494-9.
- [33] Zaric D, Christiansen C, Pace NL, Punjaswadwong Y. Transient neurologic symptoms after spinal anesthesia with lidocaine versus other local anesthetic: systematic review of randomized, controlled trial. *Anesth Analg.* 2005;100:1811-6.
- [34] Karason S, Olafsson TA. Avoiding bladder catheterization in total knee arthroplasty: patient selection criteria and low dose spinal anesthesia. *Acta Anaesthesiol Scand.* 2013;57:639-45.

- [35] Kamphuis ET, Kuipers PW, van Venrooij GE, Kalkman CJ. The effects of spinal anesthesia with lidocaine and sufentanil on lower urinary tract functions. *Anesth Analg*. 2008;107:2073-8.
- [36] Kamphuis ET, Ionescu TI, Kuipers PWG, de Gier J, van Venrooij GEMP, Boon TA. Recovery of storage and emptying functions of the bladder after spinal anesthesia with lidocaine and with bupivacaine in men. *Anesthesiology*. 1998;88:310-6.
- [37] Lau H, Lam B. Management of postoperative urinary retention. A randomized trial of in-out versus overnight catheterization. *ANZ J Surg*. 2004;74:658-61.
- [38] Keita H, Diouf E, Tubach F, Brouwer T, Dahmani S, Mantz J, Desmonts JM. Predictive factors of early postoperative urinary retention in the postanesthesia care unit. *Anesth Analg*. 2005;101:592-6.
- [39] Dreijer B, Møller MH, Barthody J. Post-operative urinary retention in a general surgical populations. *Eur J Anaesthesiol*. 2011;28:190-4.
- [40] Pöpping DM, Elia N, Marret E, Wenk M, Tramèr MR. Opioids added to local anesthetics for single-shot intrathecal anesthesia in patients undergoing minor surgery: a meta-analysis of randomized trials. *Pain*. 2012;153:784-93.
- [41] Choi S, Mahon P. Neuroaxial anesthesia and bladder dysfunction in the perioperative period: a systematic review. *Can J Anaesth*. 2012;59:681-703.
- [42] Kawamata YT, Nishikawa K, Kawamata T, Omote K, Igarashi M, Yamauchi M, Sato K, Nakayama M, Namiki A. A comparison of hyperbaric 1% and 3% solutions of small-dose lidocaine in spinal anesthesia. *Anesth Analg*. 2003;96:881-4.
- [43] Baldini G, Bagry A, Aprikian A, Carli F. Postoperative urinary retention. *Anesthesiology*. 2009;110:1139-57.
- [44] Lamonerie L, Marret E, Deleuze A, Lember N, Dupont M, Bonnet F. Prevalence of postoperative bladder distention and urinary retention detected by ultrasound measurements. *Br J Anaesth*. 2004;92:544-6.
- [45] Horlocker TT. Regional anaesthesia in the patient receiving antithrombotic and antiplatelet therapy. *Br J Anaesth*. 2011;107:i96-i106. (no)
- [46] Moen V, Dahlgren N, Irestedt L. Severe neurological complications after central neuraxial blockades in Sweden 1990-1999. *Anesthesiology*. 2004;101:950-9.
- [47] Horlocker TT, Wedel DJ, Rowlingson JC, Enneking FK, Kopp SL, Benzon HT, Brown DL, Heit JA, Mulroy MF, Rosenquist RW, Tryba M, Yuan CS. Regional anesthesia in the patient receiving antithrombotic or thrombolytic therapy: American Society of Regional Anesthesia and Pain Medicine evidence-based guidelines. *Reg Anesth Pain Med*. 2010;35:64-101.

- [48] Gogarten W, Vandermeulen E, Van Aken H, Kozek S, Llau JV, Samma CM. Regional anaesthesia and antithrombotic agents: recommendations of the European Society of Anaesthesiology. *Eur J Anaesthesiol*. 2010;27:999-1015.
- [49] Breivik H, Bang U, Jalonen J, Vigfusson G, Alahuhta S, Lagerranser M. Nordic guideline for neuraxial blocks in disturbed haemostasis from the Scandinavian Society of Anaesthesiology and Intensive Care Medicine. *Acta Anaesthesiol Scand*. 2010;54:16-41.
- [50] Choi S, Brull R. Neuraxial techniques in obstetric and non-obstetric patients with common bleeding diatheses. *Anesth Analg*. 2009;109:648-60.
- [51] Van Veen JJ, Nokes TJ, Makris M. The risk of spinal haematoma following neuraxial anaesthesia or lumbar puncture in thrombocytopenic individuals. *Br J Hematol*. 2009;148:15-25.
- [52] Schulz-Stübner S, Pottinger JM, Coffin SA, Herwaldt LA. Nosocomial infections and infection control in regional anesthesia. *Acta Anaesthesiol Scand*. 2008;52:1144-57.
- [53] Baer ET. Post-dural puncture bacterial meningitis. *Anesthesiology*. 2006;105:381-93.
- [54] Gritsenko K, Marcello D, Liguori GA, Jules-Elysée K, Memtsoudis SG. Meningitis or epidural abscesses after neuraxial block for removal of infected hip or knee prosthesis. *Br J Anaesth*. 2012;108:485-90.
- [55] Bader AM, Gilbertson L, Kirz L, Datta S. Regional anesthesia in woman with chorioamnionitis. *Reg Anesth*. 1992;17:84-6.
- [56] Goodman EJ, DeHorta E, Taguiam JM. Safety of spinal and epidural anesthesia in parturients with chorioamnionitis. *Reg Anesth Pain Med*. 1996;21:436-41.
- [57] Sviggum HP, Jacop AK, Arendt KW, Mauermann ML, Horlocker TT, Hebl JR. Neurologic complications after chlorhexidine antisepsis for spinal anesthesia. *Reg Anesth Pain Med*. 2012;37:139-44.
- [58] Tsai PS, Hsu CS, Fan YC, Huang CJ. General anaesthesia is associated with increased risk of surgical site infection after caesarean delivery compared with neuraxial anaesthesia: a population-based study. *Br J Anaesth*. 2011; 21:275-80.
- [59] Brull R, McCartney CJ, Chan VW, El-Beheiry H. Neurological complications after regional anesthesia: contemporary estimates of risk. *Anesth Analg*. 2007;104:965-74.
- [60] Hebl JR. The importance and implications of aseptic techniques during regional anesthesia. *Reg Anesth Pain Med*. 2006;31:311-23.
- [61] de Sèze MP, Sztark F, Janvier G, Joseph PA. Severe and long-lasting complications of the nerve root and spinal cord central neuraxial blockade. *Anesth Analg* 2007;104:975-9.

- [62] Ko JY, Leffert LR. Clinical implications of neuraxial anesthesia in the parturient with scoliosis. *Anesth Analg*. 2009;109:1930-4.
- [63] Horlocker TT. Complication of regional anesthesia and acute pain management. *Anesthesiol Clin*. 2011;29:257-78.
- [64] Reynolds F. Damage to the conus medullaris following spinal anaesthesia. *Anaesthesia*. 2001;56:238-47.
- [65] Broadbent CR, Maxwell WB, Ferrie R, Wilson DJ, Gawne-Cain M, Russel R. Ability of anaesthetists to identify a marked lumbar interspace. *Anaesthesia* 2000;55:1122-6.
- [66] Furnes G, Reilly MP, Kuchi S. An evaluation of ultrasound imaging for identification of lumbar intervertebral level. *Anaesthesia*. 2002;57:277-80.
- [67] Kim JT, Bahk JH, Sung T. Influence of age and sex on the position of the conus medullaris and Tuffier's line in adults. *Anesthesiology*. 2003;99:1359-63.
- [68] Lin N, Bebawy JF, Hua L, Wang BG. Is spinal anaesthesia at L2-L3 interspace safe in disorders of the vertebral column? A magnetic resonance imaging study. *Br J Anaesth*. 2010;105:857-62.
- [69] Neal JM, Bernardis CM, Hadzic A, Hebl JR, Hogan QH, Horlocker TT, Lee LA, Rathmell JP, Sorenson EJ, Suresh S, Wedel DJ. ASRA practice advisory on neurologic complications in regional anesthesia and pain medicine. *Reg Anesth Pain Med*. 2008;33:404-15.
- [70] Chin KJ, Perlas A, Chan V, Brown-Shreves D, Koshkin A, Vaishnav V. Ultrasound imaging facilitates spinal anesthesia in adults with difficult surface anatomic landmarks. *Anesthesiology*. 2011;105:94-101.
- [71] Angadi DS, Garde A. Subclinical neuropathy in diabetic patients: a risk factor for bilateral lower limb neurological deficit following spinal anesthesia? *J Anesth*. 2012;26:107-10.
- [72] Hebl JR, Horlocker TT, Schroeder DR. Neuraxial anesthesia and analgesia in patients with preexisting central nervous system disorder. *Anesth Analg*. 2006;103:223-8.
- [73] Bogod D. The sting in the tail: antiseptics and the neuraxis revisited. *Anaesthesia*. 2012;67:1305-9.
- [74] Hebl JR, Horlocker TT, Kopp SL, Schroeder DR. Neuraxial blockade in patients with preexisting spinal stenosis, lumbar disk disease, or prior spine surgery: efficacy and neurologic complications. *Anesth Analg*. 2010;111:1511-9.
- [75] Daley MD, Rolbin SH, Hew EM, Morningstar BA, Stewart JA. Epidural anesthesia for obstetrics after spinal surgery. *Reg Anesth*. 1990;15:280-4.
- [76] Karaaslan P, Candan S, Basaran C. Paraplegia after spinal anesthesia as a result of previous undiagnosed vertebral tuberculosis. *Anesth Analg*. 2006;102:1300-1.

- [77] Cerroni A, Carvalho JA, Tancredi A, Volpe AR, Floccare A. Acute bleeding after spinal anesthesia due to puncture of unsuspected lumbar myxopendimoma. *Eur J Anaesthesiol*. 2010;27:1072-4.
- [78] Valente A, Frassanito L, Natale L, Draisci G. Occult spinal dysraphism in obstetric: a case of caesarean section with subarachnoid anaesthesia after remifentanyl intravenous analgesia for labour. *Case reports in Obstet Gynecol*. 2012;472482:1-3.
- [79] Hirai T, Kato T, Kawabata S, Enomoto M, Tomizawa S, Yoshi T, Sakaki K, Shinomiya, Okawa A. Adhesive arachnoiditis with extensive syringomyelia and giant arachnoid cyst after spinal and epidural anesthesia. *Spine*. 2012;237: E195-E198.
- [80] Limongi JAG, de Melo Lins RSA. Cardiopulmonary arrest in spinal anesthesia. *Rev Bras Anesthesiol*. 2011;61:110-20.
- [81] Kopp SL, Horlocker TT, Warner ME, Hebl JR, Vachon CA, Schroeder DR, Gould AB Sprung V. Cardiac arrest during neuraxial anesthesia: frequency and predisposing factors. *Anesth Analg*. 2005;100: 855-65.
- [82] Chatzimichali A, Zoumprouli A, Metaxari M, Apostolakis I, Daras T, Tzanakis N, Askitopoulou H. Heart rate variability may identify patients who will develop severe bradycardia during spinal anaesthesia. *Acta Anaesthesiol Scand*. 2010;55:234-41.
- [83] Menezes FV, Venkat N. Spinal myoclonus following combined spinal-epidural anesthesia for cesarean section. *Anaesthesia*. 2006;61:597-600.
- [84] Björkelund KB, Hommel A, Thorgren KG, Gustafson L, Larsson S, Lundberg D. Reducing delirium in elderly patients with hip fracture: a multi-factorial intervention study. *Acta Anaesthesiol Scand*. 2010;54:678-88.
- [85] Aromaa U, Lahdensuu M, Cozanitis DA. Severe complications associated with epidural and spinal anaesthesia in Finland 1987-1993. A study based on patient insurance claims. *Acta Anaesthesiol Scand*. 1997;41:445-452.

