

We are IntechOpen, the world's leading publisher of Open Access books Built by scientists, for scientists

4,800

Open access books available

122,000

International authors and editors

135M

Downloads

Our authors are among the

154

Countries delivered to

TOP 1%

most cited scientists

12.2%

Contributors from top 500 universities



WEB OF SCIENCE™

Selection of our books indexed in the Book Citation Index
in Web of Science™ Core Collection (BKCI)

Interested in publishing with us?
Contact book.department@intechopen.com

Numbers displayed above are based on latest data collected.

For more information visit www.intechopen.com



Diabetic Retinopathy – An Update on Pathophysiology, Classification, Investigation and Treatment

Vikas Tah, Sonia Mall, James Myerscough,
Kamran Saha, Elizabeth Emsley, Andrew Swampillai,
Ganeshan Ramsamy, Daren Hanumunthadu and
Mandeep Bindra

Additional information is available at the end of the chapter

<http://dx.doi.org/10.5772/58567>

1. Introduction

The global prevalence of diabetes was estimated at 285 million in 2010.[1] The countries with the most significant number of sufferers in 2010 were India, China, United States, Russia and Brazil.[1] Countries with a low and middle income experience the worst burden of diabetes, compared with higher income countries.[1]

The total prevalence of diabetes in children and adults in the United States was 25.8 million in 2011, which is 8.3% of the entire population.[2] It is estimated that 18.8 million of this figure are diagnosed and 7 million remain undiagnosed.[2] 79 million individuals in the United States are expected to be at risk of diabetes.[2] The overall cost of diabetes in the United States in 2012 was \$245 billion, with \$176 being directly related to medical costs and \$69 billion related to reduced productivity.[2] In the UK, 2.6 million individuals were diagnosed with diabetes in 2009,[3] and this is expected to exceed 4 million in 2024.[4] It is also expected that up to 500,000 other UK individuals remain undiagnosed.[5] An estimated one in 20 individuals in England have diabetes-both diagnosed and undiagnosed, and this is marginally reduced UK-wide.[1] For adults in the UK it is estimated that 10% of individuals with diabetes mellitus (DM) have Type 1 diabetes mellitus and 90% have type 2 diabetes mellitus.[1, 6]

Effective management of diabetes reduces complication risk.[7] However failure to control the condition can lead to microvascular and macrovascular complications. At the time of diagnosis, 50% of those with type 2 diabetes mellitus face complications.[8] Complications may begin

five to six years prior to diagnosis, whilst the onset of diabetes itself may precede the clinical diagnosis by a decade.[9]

Diabetic retinopathy (DR) is the most frequent complication associated with diabetes mellitus, and is the number one cause of blindness in individuals of working age in developed nations. [10] Indeed individuals with diabetes are 10 to 20 times at greater risk of developing blindness than those without the diagnosis.[11] DR prevalence in the Wisconsin Epidemiological Study of Diabetic Retinopathy (WESDR) was identified as 50.1% and 54.2% in the diabetes control and complications trial (DCCT) in insulin-dependent diabetes mellitus (IDDM)[12, 13] DR prevalence in non-insulin dependent diabetes mellitus (NIDDM) was found to be 35-39% in the United Kingdom Prospective Diabetes Study.[14] During 2005-2008, 4.2 million (28.5%) of diabetics in the United States aged 40 years and above suffered from diabetic retinopathy, with 0.7 million (4.4% of these diabetics) experiencing advanced DR, thus risking severe loss of vision.[2] In the WESDR, 1.4% of patients with IDDM were able to achieve a best-corrected visual acuity of 20/80 to 20/160, with 3.6% having an acuity of 20/200 or worse in the better eye. [15] 3% of the older-onset group had vision ranging from 20/80 to 20/160, and 1.6% were 20/200 or worse in the best eye.[15]

1.1. Incidence of visual impairment

10 years following diabetes mellitus (DM) onset, blindness (a visual acuity of equal to or worse than 20/200 in the best eye) was 1.8% in the type 1 cohort, 4.0% in the insulin-treated type 2 group and 4.8% in the non-insulin-treated type 2 patients.[16] Further, in these groups the incidence of visual impairment at 10 years (loss of 15 letters on a 0-70 letter scale) was identified as 9.4, 37.2 and 23.9 respectively.[16]

There appear to be few paediatric cases of DR, though it has been identified in children as young as 5.5 years in an American study, and severe blindness has also been described in adolescents as the microvascular effects of diabetes, including DR, can develop during puberty years.[17]

1.2. Historical developments

The Diabetic Retinopathy Study in the 1970s and the Early Treatment Diabetic Retinopathy Study in the 1980s, identified the major effects of retinal photocoagulation on visual loss associated with proliferative diabetic retinopathy and macular oedema, as well as influencing guideline and screening programme development for early identification and management of diabetic retinopathy.[18, 19, 20] Following this, both the incidence and progression risk of diabetic retinopathy has reduced from an estimated 90% of patients with diabetes, to less than 50%.[20] In the WESDR, which focused on individuals with type 1 diabetes mellitus, the yearly incidence of proliferative diabetic retinopathy reduced by 77% from 1980 to 2007, with a 57% reduction in visual impairment during this same time period.[21] Evidence from a range of international studies, including those from Sweden, Denmark and the United States, indicate that individuals recently diagnosed with type 1 or type 2 diabetes mellitus have a significantly reduced risk of proliferative diabetic retinopathy, macular oedema and visual impairment,

compared with those diagnosed in the past.[22, 23, 24, 25, 26] The considerable decrease in the prevalence and incidence of diabetic retinopathy and visual impairment over the previous few decades suggests improved glycaemic, blood pressure and lipid level management.[26]

1.3. A global epidemic

However the number of individuals with diabetes is expected to exponentially increase internationally to 429 million by 2030, attributed to the increased prevalence of obesity, an ageing population and enhanced identification of the disease.[27, 28] This represents a major public health concern. As an exemplar, in India 32 million individuals were diagnosed with diabetes in 2000 and an estimated 79 million will be affected by 2030, and if complication prevalence remains the same, around 0.7 million Indians will suffer from proliferative diabetic retinopathy and 1.8 million will have macular oedema with clinical manifestations.[29] This identifies a large population at risk of visual impairment attributed to their diabetes, and highlights the importance of effective epidemiological surveillance of developing countries as there may be reduced delivery of health care capacity compared with developed nations.[20]

2. Pathophysiology

The DCCT and United Kingdom Prospective Diabetes Study (UKPDS) both support the significant association between a long-term hyperglycaemic status and the establishment, as well as progression, of DR.[36, 37] However the mechanism which result in microvascular injury attributed to hyperglycaemia is uncertain.[36, 37] Several interlinking molecular pathways have been discussed as being possibly involved in the mechanism, and these include enhanced polyol pathway activity, diacylglycerol-(DAG)-PKC pathway activation, enhanced growth factor expression for example vascular endothelial growth factor (VEGF) and insulin-like growth factor-1 (IGF-1), haemodynamic alterations, faster advanced glycation endproducts (AGEs) production, oxidative stress, renin-angiotensin-aldosterone system (RAAS) activation, inflammation and leukostasis.[38] However the final metabolic pathway resulting in the establishment of DR is uncertain.[39]

2.1. Polyol pathway

The polyol pathway is involved in the metabolism of surplus glucose.[38]

Aldose reductase (AR), which exists in the retina, is involved in the reduction of glucose into sorbitol, employing nicotinamide adenine dinucleotide phosphate (NADPH) as a cofactor.[38] Sorbitol is then converted to fructose using sorbitol dehydrogenase (SDH).[38] Sorbitol is impermeable to cellular membranes, and therefore there is an intracellular accumulation of it, which is followed by the gradual metabolism of sorbitol to fructose.[40] NADPH is also employed as a cofactor for glutathione reductase in the regeneration of intracellular glutathione, therefore limiting the antioxidant capability of the cells.[38]

Sorbitol accumulation may have multi-injurious effects on retinal cells, such as osmotic injury.[41] Further, the fructose formed in the polyol pathway can undergo a phosphorylation

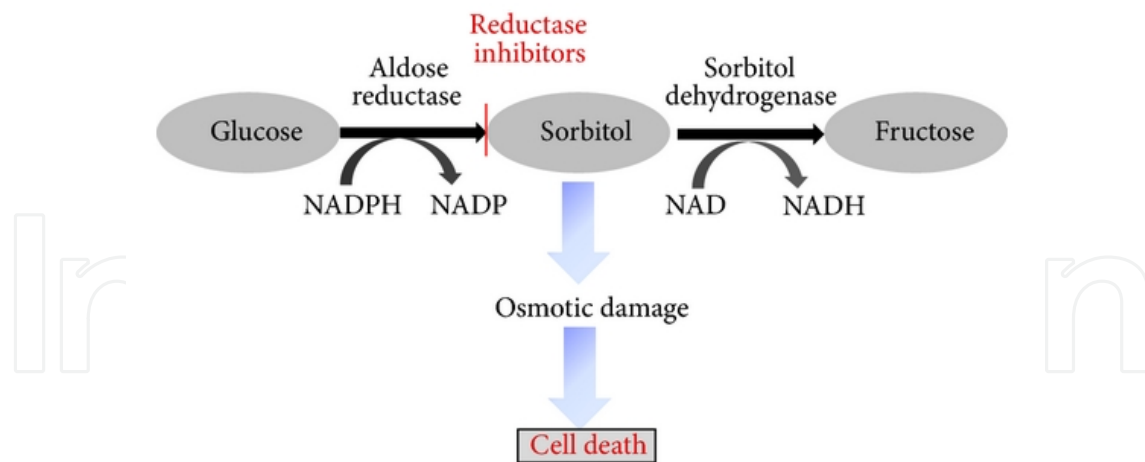


Figure 1. Polyol pathway

reaction, forming fructose-3-phosphate, with the potential for further degradation to 3-deoxyglucosone.[42] Both of these products are potent glycating mediators and can support the production of AGEs.[42] Moreover employment of NADPH in the polyol pathway, reduces NADPH availability for glutathione reductase, thereby preventing the production of reduced glutathione, resulting in reduced protection against oxidative stress.[43]

More recently, evidence suggests that AR is localised in retinal cells such as pericytes,[44] retinal endothelial cells,[45] ganglion cells,[45] Muller cells,[45] retinal pigment epithelial cells and neurons.[45, 46] Enhanced AR activity may be involved in retinal cell destruction.[43] Importantly, pericyte or endothelial cell exposure to enhanced concentrations of glucose or galactose reduces the survivability of these cells,[38] with reversal of this cell death on the administration of ARIs.[47] Generally, electrolyte imbalance attributed to high aldose reductase levels results in cellular death, in particular retinal pericytes, which contribute to microaneurysm formation.[48]

The polyol pathway is also associated with other pathophysiological characteristics in DR, including a thickened retinal capillary basement membrane,[49] with ARI preventing this thickening in rat models.[50] ARIs are also effective in reducing leukocyte adhesion in endothelial cells,[51] which results in leukostasis and is discussed later, as well as preventing enhanced vascular permeability and blood retinal barrier breakdown which is a hallmark feature of DR.[46] Genetically, AR may also contribute to DR establishment.[52]

Thus far, ARIs employed in animal models at the onset of diabetes has been useful in preventing DR, though limited clinical benefit has been shown.[38]

2.2. Protein glycation

The establishment and accumulation of AGEs is a significant contributor to DR.[53] AGEs are molecules produced non-enzymatically when sugars are reduced with free amino groups of proteins, lipids and nucleic acids.[38] Normally, AGEs are produced at a constant and gradual

rate, commencing at the embryonic stage and accumulating with time.[38] In the context of increased glucose availability in diabetes, their production is accelerated.[54]

AGEs are important in several diabetic complications.[38] For example, they have been identified in the retinal vessels of diabetics, and these AGE levels have been correlated with those found in the serum, as well as retinopathy severity.[55] AGE interaction with certain cell surface receptors such as RAGE, CD36 and the macrophage scavenger receptor have been described in DR development.[55]

Animal studies suggest significantly high AGE exposure is contributory to renal and vascular complications.[56, 57] In rats which developed diabetes, retinal capillaries had enhanced AGE accumulation, as well as a loss of pericytes.[53] Treatment with AGE formation inhibitors considerably reduced AGE accumulation, and stopped microaneurysm formation, acellular capillaries and pericyte loss.[53] In another study, rats with a diabetes duration of 29 weeks, there was an increase in acellular capillaries by more than three times compared to previously, and there was increased thickening of the basement membrane.[56] A thickened capillary basement membrane and enhanced deposition of extracellular matrix components is a contributor to the development of abnormal retinal haemodynamics.[58] Again, treatment with an AGE formation inhibitor prevented capillary dropout and reduced basement membrane protein formation.[56]

These studies, which are still in their infancy, identify AGE formation and activation of their respective receptors as important targets for pharmacotherapeutic strategies.[38]

2.3. Activation of Protein Kinase C (PKC)

PKC is a kinase involved in signal transduction activity in response to a stimulus which may be hormonal, neuronal or growth factor in origin.[38] The Beta1/2 isoform of PKC is associated with DR development.[59] Raised blood glucose increases glucose flux in the glycolysis pathway, thereby increasing diacylglycerol (DAG) production. DAG is a major PKC activator.[60] Clinical and experimental research has identified an increase in DAG and PKC activation in diabetes.[59]

PKC can also influence other physiological pathways therefore having the capability to alter endothelial permeability, retinal haemodynamics and expression of vascular endothelial growth factor (VEGF) in the retina and enhanced leukostasis.[59, 61, 62]

In particular, the expression of the PKC beta1/2 isoform is increased in diabetics, thereby contributing to DR pathogenesis by extracellular matrix (ECM) protein synthesis, remodeling of the ECM, increased angiogenic factor production, endothelial and leukocyte cell abnormalities, ultimately resulting in occluded capillaries and leukostasis, with alterations in retinal blood flow.[38] The PKC pathway also influences other activities such as inflammatory changes, neovascularisation and aberrant haemodynamics.[38] This further progresses the pathogenic changes in DR. Experimentally, PKC-beta1/2 inhibitors significantly reduce DR progression.[63] In clinical trials, inhibitors do not prevent DR but considerably reduce the associated vision loss.[64]

2.4. Haemodynamic alterations

Hypertension, which has a high incidence in diabetes, is likely to contribute to DR progression.[38] This may involve the mechanical stretch and shear stresses associated with hypertension, injuring endothelial cells. Enhanced retinal perfusion and increased blood viscosity can also lead to endothelial dysfunction.[65] Further, the endocrine mechanisms which have regulatory influences over blood pressure are also independently involved in DR pathogenesis.[66]

2.5. Renin-angiotensin-aldosterone system involvement

RAAS is fundamental in blood pressure and fluid regulation, with aberrant changes identified in this system in diabetics.[66] There is an increase in the expression of certain receptors and signaling molecules in the retina, in PDR, including renin, angiotensin converting enzymes (ACE) and angiotensin receptors.[66, 67] This is independent of systemic blood pressure.[38] In experimental studies, ACE inhibitor use prevents neovascularization and several clinical studies suggest that targeting of RAAS reduces the incidence of retinopathy in type 1 diabetes and prevents progression of DR.[68]-[70]

The exact mechanism of RAAS involvement in DR is uncertain, though in vitro evidence identifies association with PKC activation and VEGF signaling.[71]

2.6. Inflammatory changes and Leukostasis

The importance of inflammation, in particular subclinical inflammation in DR development is considerable, though complex.[38] The hyperglycaemic state, oxidative stress, AGE production and hypertension are all contributory to the inflammation. Moreover, the inflammation is self-propagating by means of cytokines, adhesion molecules, VEGF activity, increased RAGE expression, nitric oxide regulatory changes and NF- κ B signaling.[38] This subclinical retinal inflammation increases intraocular blood pressure by the involvement of endothelial nitric oxide synthase (eNOS), formation of new but weak vessels and their enhanced VEGF permeability which results in retinal haemorrhages, as well as leukostasis attributed to multiple proinflammatory agents.[38] Leukostasis is crucial in DR pathogenesis, resulting in capillary occlusion, reactive oxygen species (ROS)-related cellular death and local retinal amplification of the inflammatory activities.[72]-[75]

There is a considerable increase in systemic proinflammatory cytokine expression, soluble and cell surface adhesion molecule activation and chemokine expression in the DR retina.[76] The increase in serum proinflammatory cytokines, adhesion agents and immune cell activation in diabetes correlates with DR progression.[77, 78] Endothelial abnormalities, as well as increased proinflammatory cytokines and adhesion molecules, contribute to leukostasis by increasing leukocyte and endothelial cell interaction.[79, 80] Localised inflammation including the activation of microglia, macrophages and immune cells is considered important in DR pathogenesis.[81] This is corroborated by the use of minocycline, an antibiotic and anti-inflammatory agent, which prevents microglial activation and thereby prevents DR.[81]

2.7. Oxidative stress

Oxidative stress occurs when the level of ROS or oxygen radicals increase to a degree where the antioxidant defences are unable to cope.[82] Oxidative stress established by hyperglycaemia is pivotal in microvascular complications.[83] Correlation between hyperglycaemia, alterations in redox homeostasis and oxidative stress is essential in DR pathogenesis.[84, 85] Increased ROS are likely to be involved in both the development and progression of DR.[86] It has been proposed that oxidative stress may be a “unifying mechanism” linking several injurious pathways induced by the hyperglycaemic state in DR.[87] ROS derived from mitochondria cause DNA breaks, which activate poly-(ADP-ribose)-polymerase (PARP).[87] PARP activation results in inhibition of glyceraldehyde phosphate dehydrogenase (GAPDH) activity, causing glycolytic metabolite accumulation.[87] These metabolites cause the activation of AGE, PKC-beta-2, polyol and hexosamine pathways.[87] NADPH oxidase-derived ROS may also be involved in the pathogenesis.[87]

2.8. Growth factor involvement

The importance of growth factors in DR is confirmed by the rare observation of serious DR in growth hormone deficient diabetic dwarfs,[88] and this is further corroborated by slowed DR progression in individuals with pituitary ablation in the 1970s.[89]

The growth factor most frequently considered in DR is VEGF, which promotes angiogenesis, causes blood-retinal barrier breakdown, endothelial cell growth stimulation and neovascularization, as well as increased vascular permeability in an ischaemic retina.[90]-[92] Ischaemia in the retina causes angiogenic factors, such as vascular endothelial growth factor (VEGF) to establish neovascularization, resulting in proliferative diabetic retinopathy (PDR). VEGFs are produced by retinal pigment epithelium, pericytes and retinal endothelial cells.[39] Animal and clinical evidence suggests VEGF, especially the 165 isoform, is important in the development and progression of DR.[93, 94]

Anti-VEGF agents have clinical efficacy in the treatment of DMO, but are not effective in all patients.[38] Further long-term use of anti-VEGF agents should be considered with caution in DR.[38]

2.9. Carbonic Anhydrase (CA)

Enhanced intraocular VEGF concentrations correlates with increased vascular permeability, contributing to haemorrhage, exudate formation, vascular leakage, and ultimately leading to NPDR, angiogenesis and vasculogenesis leading to PDR.[38]

CAs are ubiquitous metalloenzymes which cause conversion of carbon dioxide to bicarbonate and protons.[38] Diabetics have considerably higher CA concentrations than controls,[95] and CA inhibitors reduce DR progression and prevents visual loss in animal and clinical research.[96] The mechanisms involved may include reduced humour secretion, induction of vasodilatation and improved ocular blood flow, platelet aggregation inhibition and reduction in vascular permeability.[95]

2.10. Neurodegeneration in the retina

As well as the changes already described, structural and functional alterations can injure certain non-vascular cells.[38] It is believed that neurodegeneration of retinal neurons and glia may even precede microaneurysm development.[97]

3. Risk factors

Epidemiologic studies have shown several risk factors associated with the incidence of diabetic retinopathy and subsequent macular oedema (table 1). Several other risk factors have also been implicated in disease progression such as sleep apnoea [98], non-alcoholic fatty liver disease, genetic mutations[21, 99] and serum prolactin, homocysteine and adinopectin levels [33, 31, 34]. However the exact contribution of these factors to disease progression remains unknown. The precise association of smoking with diabetic retinopathy appears complex and is unclear.

Type of diabetes
Duration of diabetes
Poor glycaemic control
Hyperlipidaemia
Hypertension
Pregnancy

Table 1. Recognised risk factors associated with diabetic retinopathy

3.1. Type of diabetes

Type 1 diabetic patients are at substantially higher risk than type 2, which is independent of the duration of the disease process[100, 101]. Both severity and prevalence increase with age in the former group but not the later.

3.2. Duration of diabetes

A clear correlation exists between diabetic retinopathy and disease duration[1]. This risk factor has influenced the formation of guidelines for early examination of suspected patients to decrease disease progression. In two studies [100, 102] evidence was shown that after 15 years retinopathy would be present in virtually all type 1 diabetics and up to 75% of type 2 diabetics, with 2% becoming blind and up to 10% developing severe visual impairment. Puberty is now an accepted risk factor for retinopathy in type 1 diabetes, due to the acceleration of microvascular compromise as a result of physiological changes post puberty [103]. One study found that younger post-menarchal subjects were up to 3.2 times more likely to develop retinopathy, in comparison to pre-menarchal subjects[104]. Subjects older than 13 years at the time of diagnosis were more likely to suffer from retinopathy, than those younger. A four year follow-

up also showed that the same post-menarchal had greater progression of their retinopathy than pre-menarchal ($P=0.06$). While the exact mechanism is not known, hormonal factors have been speculated to play a part.

3.3. Glycaemic control

The relationship between glycaemic control and onset/progression of diabetic retinopathy is well documented. Intensive metabolic control has shown a decreased in diabetic related complications [105]. Studies such as the Early Treatment of Diabetic Retinopathy Study (ETDRS) and Diabetes Control and Complication Trial (DCCT)[13] show that risk of progression is reduced with aggressive glycaemic control. Glycosylated haemoglobin levels have shown a relationship with the severity of proliferative diabetic retinopathy[106]. However, while glycosylated haemoglobin remains a formidable risk factor, it only accounted for 11% of all risks for retinopathy in DCCT [107].

3.4. Hyperlipidaemia

Association of hyperlipidaemia and diabetes is well documented [108]. A statistically significant association between elevated serum total cholesterol and low density lipoprotein cholesterol and the severity of retinal hard exudation in patients with diabetic retinopathy was confirmed by the ETDRS group and the Wisconsin Epidemiologic Study of Diabetic Retinopathy (WESDR) found [109]. As reported by Chew found patients with serum cholesterol level more than 240mg/dl were twice as likely to have more hard exudates as those patients with serum cholesterol level 200 mg/dl [110].

3.5. Hypertension

A major risk factor of cardiovascular disease in diabetics is hypertension. An age-adjusted 82% increase in risk of diabetes-related death is thought to come from this risk factor alone.[111] This is accorded with the theory that increased blood pressure is implicated in the onset of diabetic retinopathy [112, 113]. The UK Prospective Diabetic Study (UKPDS) showed that tight blood pressure control (144/82 vs 155/87) was associated with a 34% reduction in retinopathy with a 47% reduction in deterioration of visual acuity of three lines [14]. The use of angiotensin-converting-enzyme (ACE) inhibitors and their role in directly affecting the progression of retinopathy (as opposed to their therapeutic effects in hypertension) was the subject of much debate. ACE inhibitors were found to be associated with reduced levels of vascular endothelial growth factor in diabetic retinopathy patients[114]. However in the UKDPS group demonstrated an overall reduction of blood pressure was proven to be effective in slowing down the progression of retinopathy, rather than the type of antihypertensive drug used [115]. More recently, the 'DIabetic REtinopathy Candesartan Trial' (DIRECT) study recently posited that while candesartan did not have any beneficial effect on the progression of retinopathy in type 1 diabetic patients, it did yield improvement in type 2 patients with mild to moderate retinopathy [69, 68].

3.6. Pregnancy

Many studies have concluded that diabetic women in pregnancy have a substantial risk of worsening their retinopathy [116, 117] although resolution of ocular changes in post-partum period is reported [116, 118]. Studies by Phelps et al [119] and the Diabetes in Early Pregnancy Study (DIEP) group [120] concluded that retinopathy was most likely to progress in those who had the poorest control at baseline. DIEP also found that a disease duration of more than 15 years and severity of existing retinopathy were the most important factors in the development and progression of retinopathy in pregnancy. Type 1 diabetic women are most at risk and should be undergo an ophthalmic examination prior to pregnancy and counselled on good glycaemic control. The exact mechanism of progressive retinopathy in pregnant diabetic woman is the subject of much debate. Factors thought to be involved include duration of diabetes, co-existing hypertension, poor glycaemic control and its rapid normalisation during pregnancy [121].

4. Signs

Microaneurysms are out-pouchings of the capillary wall that form by either focal dilatation of the capillary wall in the absence of pericytes, or fusion of the two arms of a capillary loop. Clinically these are seen as tiny red dots. Retinal haemorrhages are divided into intraretinal, retinal nerve fibre layer and deeper dark round haemorrhages. Intraretinal haemorrhages are located in the middle layers of the retina and give rise to dot/blot configuration. Retinal nerve fibre layer haemorrhages are flame-shaped and arise from larger superficial pre-capillary arterioles. Deeper dark round haemorrhages represent retinal infarcts within the middle layers and are marker for progression to retinal neovascularisation. Cotton wool spots result from nerve fibre layer infarcts. Axon disruption causes accumulation of neuronal debris in the nerve fibre layer. Clinically these are seen as small fluffy lesions that can obscure underlying blood vessels. Exudates are composed of lipoprotein and lipid-filled macrophages located within the outerplexiform layer. They are seen as waxy yellow lesions with relatively distinct margins. They tend to progress as retinopathy worsens and can affect the macula resulting in macular oedema. Exudates reabsorb spontaneously when leakage ceases over a period of months. Venous changes include beading of blood vessels, tortuosity, and focal narrowing with dilatation called 'beading'. The extent of venous change correlates well with the proliferative change. IRMA, or intraretinal microvascular abnormalities are arteriolar venous shunts that run from retinal arterioles to venules. They bypass capillary beds and are seen in areas of capillary hypoperfusion. Arteriolar narrowing often can be marker for ischaemic dysfunction. Proliferative retinopathy is seen as new preretinal vessels that may arise at the optic disc or elsewhere in the retina or iris. There are fine fragile vessels that can develop fibrous tissue over time.

Diabetic macula oedema is one of or a combination of focal, diffuse or ischaemia. It is the main reason for visual impairment and represents foveal oedema, exudates or ischaemia. Focal maculopathy has retinal thickening and exudates. Fluorescein angiogram shows late focal

hypofluorescence from leakage. Diffuse maculopathy can be associated with cystoids changes and diffuse retinal thickening. Fluorescein angiogram shows late hypofluorescence with a flower petal pattern if cystoids macula oedema is present. Ischaemic maculopathy often has a relatively normal looking macula in the presence of reduced visual acuity. Fluorescein angiogram shows non-perfusion and an enlarged foveal avascular zone.

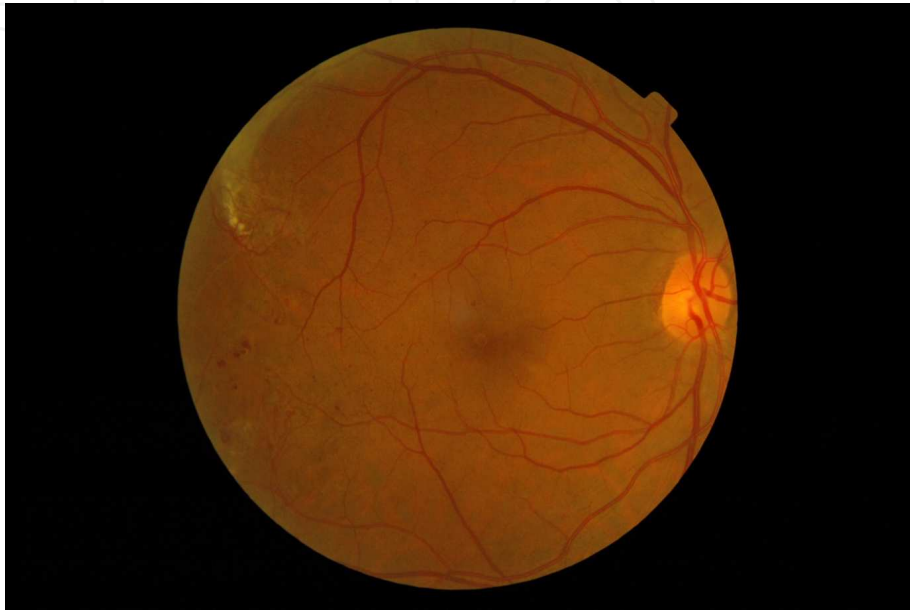


Figure 2. Microaneurysms at the macular and blot haemorrhages temporally

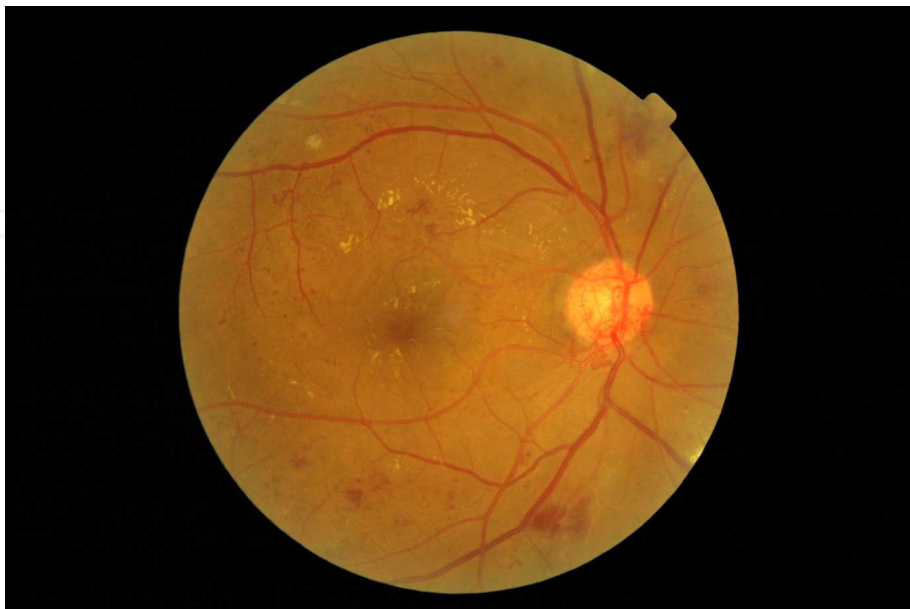

Figure 3. Exudates and microaneurysms at the macula, blot haemorrhages at the arcades, new vessels on the disc and cotton wool spots, IRMA and venous beading supoertemporally.

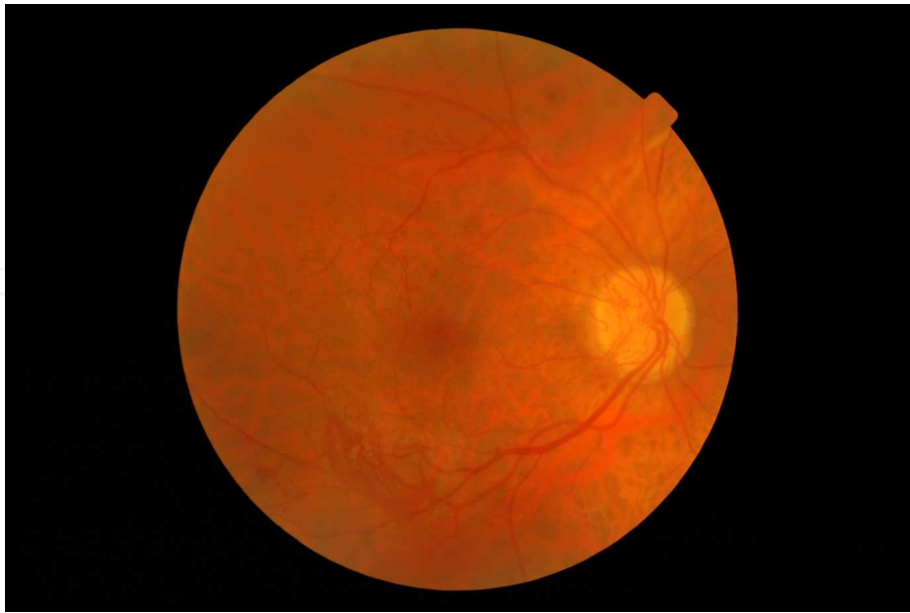


Figure 4. New vessels on disc and elsewhere inferotemporally

5. Classification

Diabetic retinopathy classification is based on who is classifying the disease. One approach has been for screening and one is based on grading severity in the context of ophthalmic signs. There are different screening systems in different parts of the developed world. In the UK, the English National Screening Criteria[122] is used to merit ophthalmological referral, seen in the table below. Two commonly used classification systems for classification in the context of ophthalmic signs are the Airlie House Classification [123] and the international (AAO) classification [124]. There are similarities and overlap in both. For the purpose of this chapter we will focus on the Airlie House classification.

The Airlie House classification was the original classification that has subsequently undergone modification in the Early Treatment of Diabetic Retinopathy Study (EDTRS)[125] aimed at grading retinopathy in the context of ophthalmic signs. EDTRS was first developed in 1997, but has undergone change and development for countries without significant screening and programmes and for the purpose of research. The sight threatening risk of diabetic retinopathy was incorporated into the later clinical grading system. Broadly this incorporates low risk non-proliferative retinopathy (3 substages), severe non-proliferative diabetic retinopathy, proliferative retinopathy and the presence of macula oedema.

Below is based on the Airlie House classification:

Mild Nonproliferative Diabetic Retinopathy (NPDR): At least one microaneurysm

Moderate NPDR: Severe retinal haemorrhages in at least one quadrant, cotton wool spots, venous beading or IRMA.

Severe NPDR: Severe retinal haemorrhages in four quadrants or venous beading in two quadrants; or extensive IRMA in one quadrant

Proliferative diabetic retinopathy: based on location and risk

Location: new vessels at disc (NVD) or elsewhere (NVE)

Risk: Low risk where neovascularisation of the optic disc is less than one-quarter to a third of the disc area with no vitreous haemorrhage.

High risk: mild NVD with vitreous haemorrhage.

Moderate to severe NVD (one quarter to a third disc areas)

New vessels elsewhere more than one half disc areas with vitreous haemorrhage.

ENSC Grade	Features
Retinopathy grade	
R0	No retinopathy
R1	Retinal microaneurysms, haemorrhages and or exudates not within the definition of maculopathy
R2	(Pre-proliferative) venous beading, venous loop or IRMA, dot or blot haemorrhages and cotton wool spots
R3	Proliferative: NVD, NVE or pre-retinal or vitreous haemorrhage, pre-retinal fibrosis and tractional retinal detachment
M0	No maculopathy
M1	Exudate within 1 disc diameter of fovea centre, or circinate exudates within the macula, or retinal thickening within 1 disc of fovea centre only if associated with vision of 6/12 or worse
P	Focal/grid laser to macula or peripheral scatter
U	Unobtainable

Table 2. The English National Screenin Committee Guidelines

Maculopathy

Focal: Well circumscribed areas of leakage with oedema and exudates, that may surround microaneurysms

Diffuse: Generalised leaking with oedema

Ischaemic: Reduced visual acuity with relatively normal clinical appearance but macula ischaemia on FFA.

Mixed: A combination of the above

Clinical significant macula oedema (CSMO)

- Retinal thickening at or within 500µm of the centre of the macula
- Hard exudates at or within 500µ of the centre of the macula if associated with adjacent retinal thickening
- Retinal thickening of > 1 disc area any part of which is within one disc diameter of the centre of the macula.

More recently the terms centre involving and non-centre involving macula oedema have been used.

6. Investigations

Diabetes Mellitus is a complex disease requiring a multidisciplinary approach. The systemic investigations requested for a patient identified with ocular manifestations of the disease may provide valuable information regarding other organ systems affected which are not yet clinically apparent. Some of the general investigations below may be requested by an ophthalmologist depending on the local health setting but require referral for result interpretation and subsequent management by diabetologist colleagues.

6.1. Systemic Investigations

6.1.1. HbA1C

The Diabetes Control and Complication Trial (DCCT) [126] and subsequent follow-up study, Epidemiology of Diabetes Interventions and Complications (EDIC), highlighted that the effect of good glycaemic control on progression of retinopathy is significant and persists for at least 10 years. Due to the 8-12 week turnover of erythrocytes the glycosylated haemoglobin molecule is a more useful marker of glucose control than a random blood glucose measurement.

6.1.2. Lipids

Recent studies [127] have identified the importance of cholesterol lowering medications to both treatment naïve and previously treated hypercholesterolaemic type 2 diabetics in reducing the risk of clinically significant macular edema (CSME), and diabetic retinopathy progression [127, 128]. Fasting lipids should therefore be requested in new patients.

6.1.3. Urea & electrolytes

Diabetic nephropathy is an important consequence of microvascular disease and all patients should be screened for any renal dysfunction.

6.1.4. Genetic markers

Various clinical studies have looked at retinopathy clusters in families with type 1 diabetes. Genetic studies have analysed risk genes for retinopathy [The Diabetes Control and Compli-

cations Trial Research Group, 1997][126]. No study has provided an evidence base for genetic testing in diabetic patients to predict the rate of retinopathy progression and therefore genetic testing is not currently recommended for routine practice.

6.1.5. Blood pressure

Patients should be referred to a physician for investigation of all modifiable risk factors including blood pressure and smoking cessation, both known to contribute to the rate of diabetic retinopathy progression. [Gaede *et al.* 2008][129]

7. Imaging

7.1. Fundus Photography

Fundus photography provides a useful photographic record of the posterior pole and is useful in the Diabetic Screening Programme, but relies on 2-dimensional surrogate markers of macular thickening since it cannot quantify actual thickening.

7.2. Optical Coherence Tomography (OCT)

Optical Coherence Tomography is a non-invasive imaging technique which is non-contact and facilitates high resolution cross-sectional imaging of the anterior segment, vitreous, retina and optic nerve head. Rather than the sound waves of B-scan ultrasonography, OCT uses light interferometry (near-infrared) to interpret the interference patterns of wave superposition.

OCT is useful is very sensitive in detecting change in macula thickness and therefore useful in the diagnosis of diabetic macula oedema. It is also able to identify the loss of ganglion cells in the retina, which precedes vascular changes. Because OCT gives a quantitative measure of retinal thickness it is critical in monitoring retinal thickness in response to treatment e.g. Macula laser or Anti-VEGF agents.

Different tissue reflectivities are depicted by different colours; red denotes high reflectivity, green-yellow intermediate reflectivity and blue-black low reflectivity. In addition to numerical measures of retinal thickness a topographical map is created which is colour coded according to thickness.

7.3. Fundus Fluorescein Angiography (FFA)

Fundus Fluorescein Angiography involves the injection of an orange water-soluble dye; sodium fluorescein into the systemic circulation. It remains predominantly intravascular and is fluorescent; i.e. it emits light of a longer wavelength when stimulated by light of a lower wavelength. After intravenous injection, fundus photography is performed in a rapid sequence. Blue filtered light is absorbed by the molecule as it enters the retinal circulation and in turn emits yellow-green light.

The FFA image maps the retinal vasculature and the structural and functional integrity of the vessels.

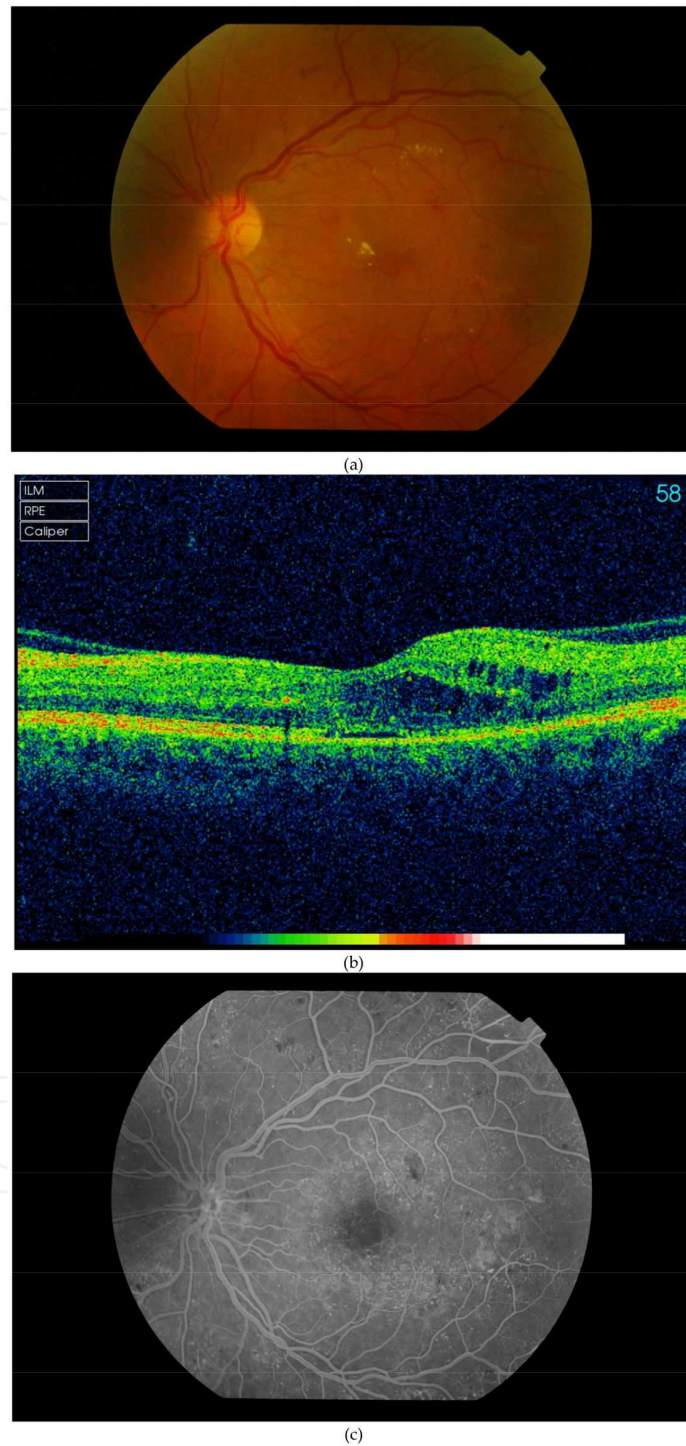


Figure 5. a. Fundus photograph of Diabetic Maculopathy (Circinate hard exudates, haemorrhages) **b.** Optical Coherence Tomography of Diabetic Maculopathy (Intraretinal cystic thickening) **c.** Fundus Fluorescein Angiogram of Diabetic Maculopathy

Normally 10-15 seconds elapse between dye injection and arrival of the dye in the short ciliary arteries. Choroidal circulation precedes retinal circulation by 1 second. Transit of dye through the retinal circulation takes approximately 15 to 20 seconds.

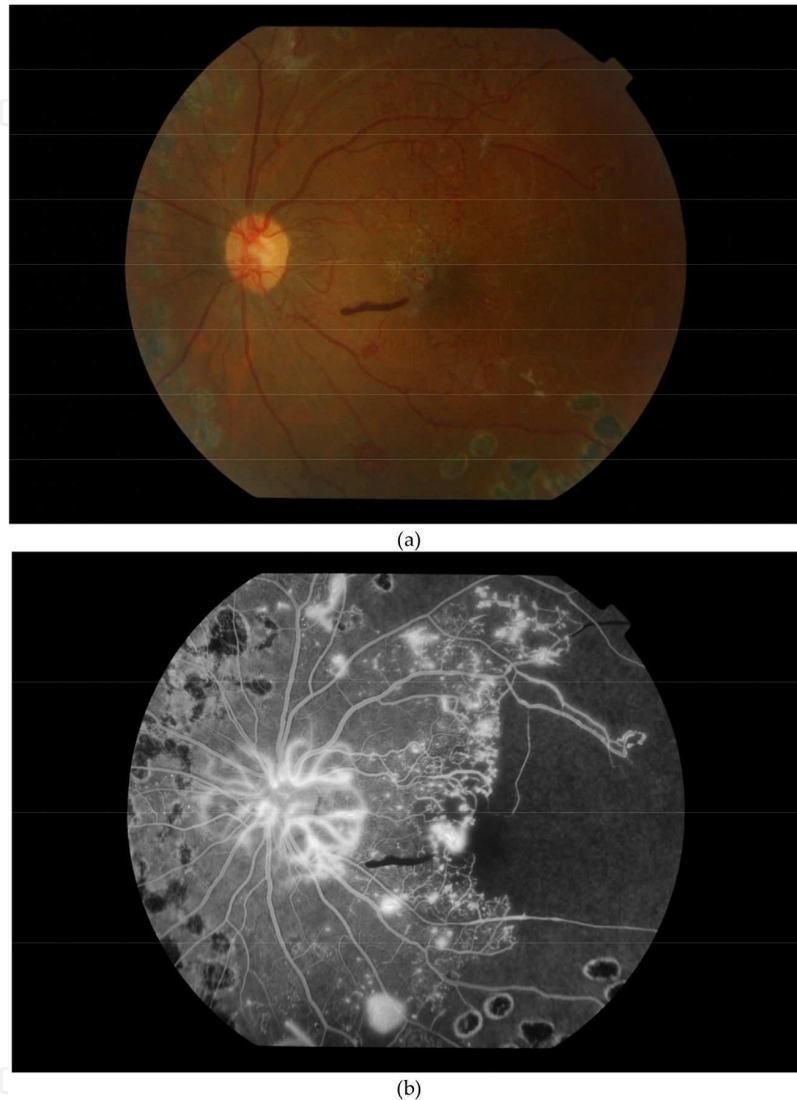


Figure 6. a. Fundus Photograph of New Vessel at Disc (NVD). Note PRP laser scars **b.** Fundus Fluorescein Angiogram of New Vessel at Disc (NVD) with evidence of peripheral ischaemia

The normal angiogram can be divided into five phases

1. **Choroidal phase:** The choroid is filled by the short ciliary arteries resulting in initial patching filling of lobules, quickly followed by a diffuse blush as dye leaks out of the choroidocapillaris.
2. **Arterial phase:** The central retinal artery fills about 1 second after choroidal filling
3. **Capillary phase:** The capillaries quickly fill following the arterial phase. The perifoveal capillary network is particularly prominent, as the underlying choroidal circulation is

masked by luteal pigment in the retina and melanin pigment in the retinal pigment epithelium (RPE). At the centre of this capillary ring is the foveal avascular zone 500µm in diameter.

4. **Venous phase:** Early filling of the veins is from tributaries joining their margins, resulting in a tramline effect. Later the whole diameter of the veins is filled.
5. **Late (recirculation) phase:** 10 to 15 minutes later only a little dye remains within the blood circulation. Dye which has left the blood to ocular structures is particularly visible during this phase.

Below images are taken from clinical practice for common diabetic pathology (Images kindly provided by Mr Jignesh Patel, Essex County Hospital, Colchester).

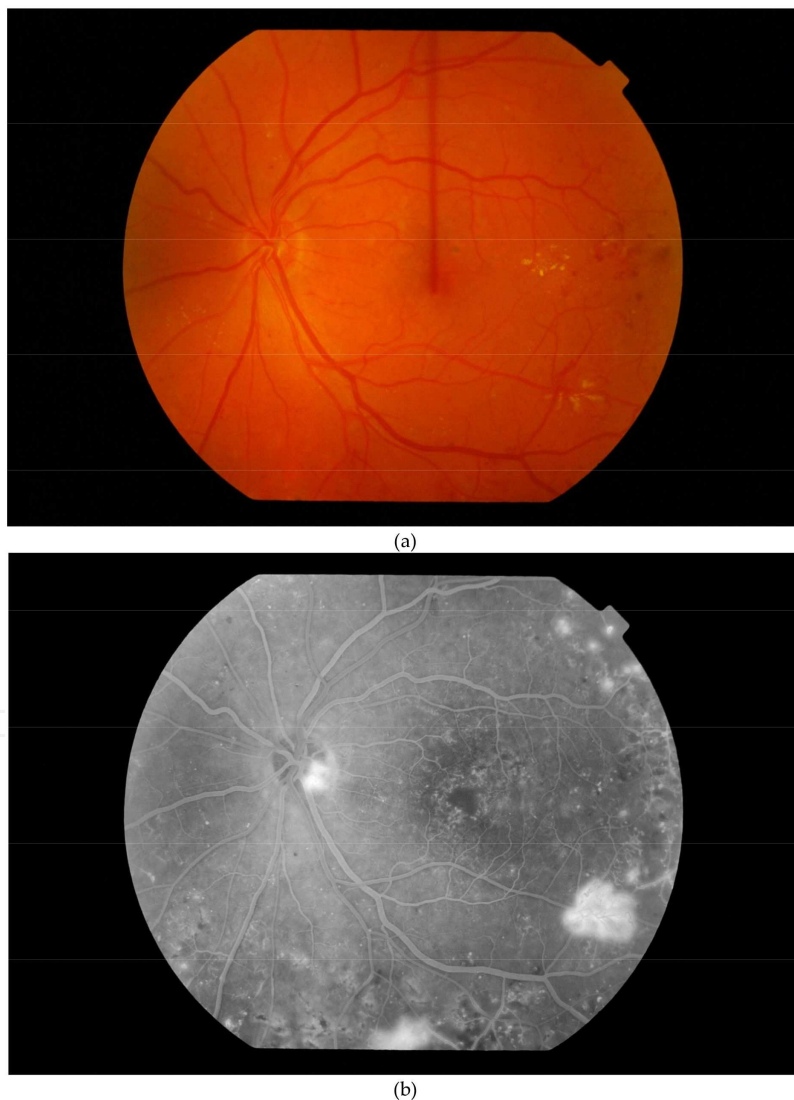


Figure 7. a. Fundus Photograph of New Vessels Elsewhere (NVE). **b.** Fundus Fluorescein Angiogram of New Vessels Elsewhere (NVE)

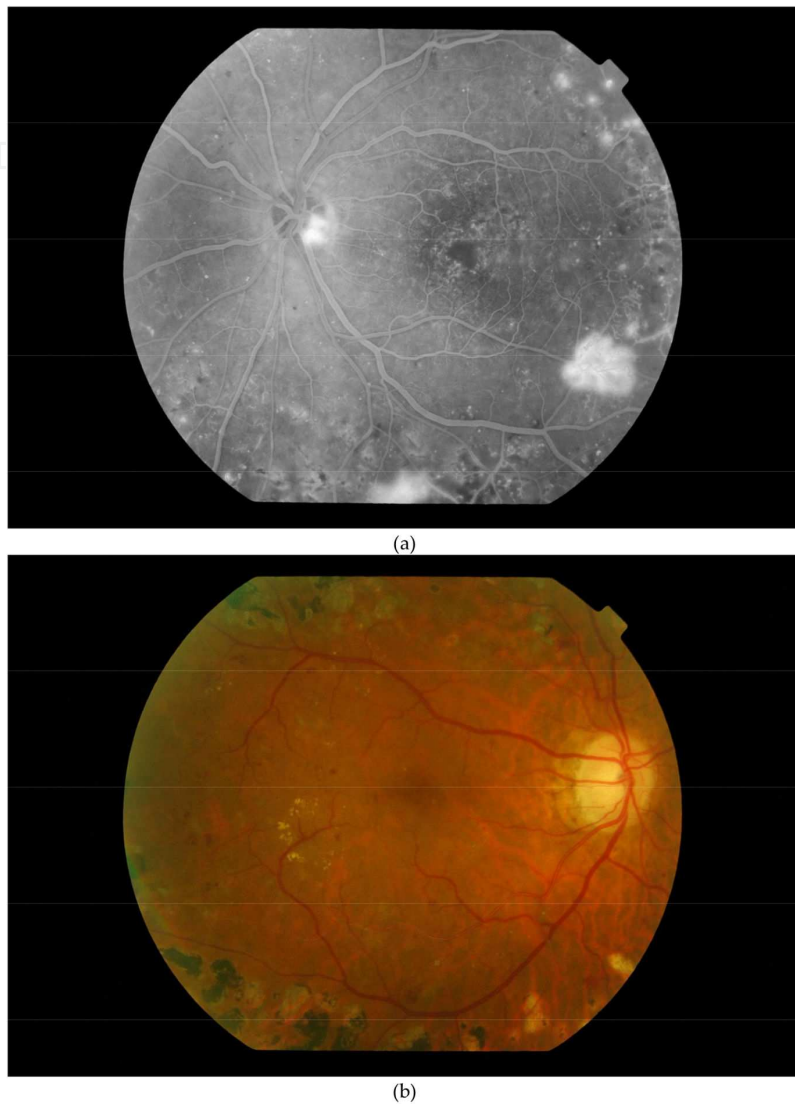


Figure 8. a. Fundus Photograph demonstrating PRP laser burns **b.** Fundus Fluorescein Angiogram of the above patient showing laser scars

8. Management of diabetic retinopathy

The management of diabetic retinopathy involves a multidisciplinary approach with involvement of the ophthalmologist, physician and dietician. The underlying diabetes and risk factors should be managed concurrently with the ocular complications of diabetes.

8.1. Medical management

8.1.1. Blood glucose control

Tight glycaemic control reduces the incidence and progression of diabetic retinopathy. The Diabetes Control and Complications Trial (DCCT)[131] showed that in type 1 diabetics effective glycaemic control reduced the incidence of diabetic retinopathy by 76% and progression of diabetic retinopathy by 54%. Similarly the United Kingdom Prospective Diabetes Study (UKPDS)[132] reported reduced microvascular complication, by 25% and the need for laser photocoagulation by 29% in type 2 diabetics.

8.1.2. Blood pressure control

The current British Hypertension Society guidelines define hypertension as systolic blood pressure ≥ 140 mmHg and/or diastolic blood pressure ≥ 90 mmHg [133]. In diabetes treatment targets should be systolic level <130 mm Hg and diastolic <80 mm Hg. Lower levels may be required for younger patients with Type 1 diabetes and microvascular complications. In this group of patients treatment with ACE inhibitors resulted in a 50% reduction in the progression of retinopathy and progression to proliferative diabetic retinopathy by 80% in the EURODIAB Controlled Trial of Lisinopril in Insulin Dependent Diabetes Mellitus (EUCLID) trial [134]. Type 2 diabetics in the UKPDS study showed that tight BP control prevented the progression of retinopathy. The beneficial effects of anti-hypertensive medication are immediate on commencing treatment, however the effects wear off as soon as control is lost. It is imperative therefore that blood pressure is measured at every clinical visit.

8.1.3. Lipid control

Observational studies suggest that dyslipidaemia increases the risk of diabetic retinopathy particularly diabetic macula oedema[135, 136].

In the Fenofibrate Intervention and Event Lowering in Diabetes (FIELD) study [137], type 2 diabetic patients were treated with fenofibrate. Those patients treated with fenofibrate were less likely than controls to need laser treatment (5.2% vs 3.6%, $p<0.001$).

8.1.4. Cigarette smoking

In type 1 diabetes smoking increases the risk of diabetic retinopathy, nephropathy and neuropathy. Discontinuation of smoking is recommended for reducing the development of other complications of diabetes especially cardiovascular disease.

8.1.5. Management of macula oedema

Diabetic macula oedema is the most common cause for visual impairment particularly in type 2 diabetic patients. The management of clinically significant macula oedema depends on whether there is evidence of central macular thickening or vitreomacular traction. There are a wide variety of new treatments available currently some licensed and some unlicensed. A

summary guideline as to the use of these treatments and their indications are summarized in Table 3.

Is the centre involved?	Visual Acuity	Phakic/ Pseudophakic	OCT- central retinal thickness	Treatment options
No		Either		Focal/Grid laser
Yes	Normal or ≥ 78 letters	Either		Focal/Grid laser/Observation if lesions too close to fovea
Yes	78-24 letters or symptomatic	Phakic	≥ 250 microns	Intravitreal anti- VEGF with or without laser. If unresponsive consider flucinolone implant.
Yes	78-24 letters	Pseudophakic	≥ 250 microns	Intravitreal anti- VEGF or intravitreal triamcinolone preservative free with or without laser. If unresponsive consider flucinolone implant.
Yes	< 24 letters	Pseudophakic	≥ 250 microns	Observation especially if long standing or unrepnsive to laser. Consider macula ischaemia. Otherwise consider anti-VEGF or intravitreal steroid
Yes		Either	Vitreomacular traction	Consider vitrectomy with or without adjunctive intravitreal anti-VEGF or steroid treatment

Management of diabetic maculopathy. Adapted from Royal College of Ophthalmologists. Diabetic Retinopathy Guidelines December 2012 (19)

Table 3. Table for management of CMO in Royal College of Ophthalmology

8.1.6. Laser photocoagulation

There is a strong evidence from the Early treatment of Diabetic retinopathy Study that focal and grid laser photocoagulation for clinically significant macula oedema reduces the chance

of moderate vision loss (3 ETDRS lines) by 50%, (from 24% for the control group to 12% for the treatment group) at 3 years [19].

It is important to perform a fundus fluorescein angiography prior to treatment to delineate the area of leakage and identify areas of macula ischaemia. In focal maculopathy, focal laser treatment burns are applied directly to microaneurysms and microvascular lesions in the centre of rings of exudates located 500-3000 microns from the centre of the macula. The spot size is 50-100 microns and exposure time 0.1 second with sufficient power to obtain gentle whitening or darkening of the microaneurysm. In macula grid laser treatment burns are applied to areas of diffuse retinal thickening more than 500 microns from the centre of the macula and 500 microns from the temporal margin of the optic disc. The spot size is 100 microns and exposure time 0.1 sec giving a very light intensity burn. Treatment should be lighter if significant macular ischaemia is present.

In addition to argon laser treatment two other forms of laser treatment frequency-doubled Nd:YAG laser and micropulse laser are available for the treatment of macula oedema which reduce the degree of retinal collateral thermal damage. The 'Pattern Scan Laser' (Pascal) uses frequency-doubled micropulse YAG in single shot mode or in a predetermined array of upto 56 shots applied in less than a second. This not only reduces the potential destructive retinal effect but allows the operator to apply multiple spots simultaneously with a single foot pedal depression.

Using a micropulse mode laser, energy is delivered with a train of repetitive short pulses, micropulse power as low as 10%-25% of the visible threshold power has been demonstrated to be sufficient to show RPE-confined photothermal effect.

8.1.7. Intravitreal anti-vascular endothelial growth factors (anti-VEGF) agents

Multiple studies have demonstrated the benefit of the anti-VEGF agents including pegaptanib, ranibizumab and bevacizumab for the treatment of central involving diabetic macula oedema. A large multicenter trial DRRCRnet(The Diabetic Retinopathy Research Network Laser-Ranibizumab-Triamcinolone Study)[138] showed that intravitreal injection of 0.5mg ranibizumab initially given monthly for 3 months with prompt or deferred (≥ 24 weeks) macular laser had significantly superior visual and OCT outcomes to laser alone in eyes with diabetic macula oedema involving the fovea.

The READ-2 (Ranibizumab for oedema of macula in diabetes) [139], RESOLVE (Safety and Efficacy of Ranibizumab in diabetic macula oedema) [140], RESTORE (Ranibizumab monotherapy or combined with laser versus laser monotherapy for diabetic macula oedema) [141], and BOLT (Bevacizumab or Laser therapy)[142] studies have all demonstrated that centre-involving macula oedema should be considered for treatment with a VEGF inhibitor alone or in conjunction with focal laser.

Ranibizumab is now licensed for use in the European Union for the treatment of centre involving diabetic macula oedema and NICE have approved its use in patients with a central retinal thickness of ≥ 400 microns on OCT.

The Da VINCI trial (14) evaluated the safety and efficacy of intravitreal aflibercept for diabetic macula oedema. Four treatment regimes were studied versus laser positive results have been reported at 1 year with aflibercept. The maximum letters gain with aflibercept has been 13.1 letters vs 1.3 letters in the laser treated group. It is expected that this treatment will be licensed for Diabetic retinopathy in 2014.

8.1.8. Intraocular steroid

DRCRnet[138] study found that in pseudophakic eyes intravitreal triamcinolone injection followed by prompt laser may be as effective as ranibizumab at improving vision and reducing retinal thickening. However, there was a significant risk of an elevation of intraocular pressure. No corresponding visual benefit above laser was shown for phakic eyes, which also has had a substantially increased rate of cataract surgery by two years.

Flucinolone acetonide is a non-biodegradable intravitreal insert (Iluvain) with sustained release flucinolone and is licensed for use in the UK for chronic diabetic macula oedema unresponsive to other treatment options but it is not yet approved by NICE. Studies have shown that Iluvein can provide treatment benefit for three years-the best corrected visual acuity showed an improvement of 15 or more letters in 28.7% of the low dose group vs 16.2% in controls[144]. The longer acting nature is advantageous in that the patient would not require monthly injections as is the case with the anti-VEGFs. However there is a greater chance of development of cataract and raised intraocular pressure.

8.1.9. Pars plana vitrectomy

A vitrectomy with or without ILM peel may be indicated when macular oedema with or without ischaemia is associated with tangential traction from a thickened and taut posterior hyaloid. Often the oedema is unresponsive to laser and optical coherence tomography scanning may show vitreomacular traction.

8.2. Management of Proliferative Diabetic Retinopathy (PDR)

8.2.1. Pan retinal photocoagulation

This is indicated in the presence of new vessels at the optic disc, iris, angle or elsewhere with or without associated vitreous haemorrhage. Where possible PRP laser treatment should be initiated on the same day and maximum within 2 weeks.

PRP laser treatment should be applied as far peripheral as possible using the laser contact lens up to the ora serrata as the main areas of retinal ischaemia exist in the far peripheral retina. The laser settings depend on the type of lens that is used. With a Goldmann lens the spot size is set at 200-500 microns but with a panfundoscopic-type lens it is set at 100-300 microns. The burn duration should be set between 0.05-0.1 seconds and the power should be sufficient to produce only a light intensity burn.

Initial treatment involves 1500-2000 burns in a scatter pattern extending from the posterior fundus to cover the peripheral retina in one or more sessions. PRP completed in one session

carries a higher risk of complications and therefore treatment should be staggered. The number of burns recommended is dependent on the stage of PDR ; early PDR 1200-1800 burns, in moderate PDR 2000-2500 burns and in severe PDR 3000 burns.

The Diabetic Retinopathy Study[145] found that the risk of severe visual loss (5/200) was reduced by 50% in the "high-risk" group treated with PRP. Patients with early proliferative diabetic retinopathy were evaluated in the ETDRS study. In this group PRP decreased the risk of patients developing high risk characteristics by 50%.

The main side effects of PRP laser treatment is the progression or development of diabetic macula oedema, vitreous haemorrhage, tractional retinal detachment, loss of night vision and constricted peripheral visual fields. Vision loss within 6 weeks of treatment has also been reported in 10-23% of patients compared with 6 % of controls.

8.2.2. VEGF inhibitors

VEGF is implicated in the development of retinal neovascularization. Intravitreal anti-VEGF is likely to have an increasing role in the treatment of proliferative diabetic retinopathy, probably as an adjunct to laser. Anti-VEGFs can also be used in the setting of proliferative diabetic retinopathy and vitreous haemorrhage to facilitate sufficient clearing of the haemorrhage and allow administration of PRP.

8.2.3. Vitrectomy

Indications for pars plana vitrectomy are listed below:

1. Severe persistent vitreous haemorrhage

The surgical goal is to remove the vitreous opacity through a 3 port pars plana vitrectomy. The posterior hyaloid face should be removed as this provides a scaffold for fibrovascular proliferation. The Diabetic Retinopathy Vitrectomy Study (DRVS)[146] 2 year results demonstrate that in eyes with central vitreous haemorrhage that reduced acuity to 50/200 or less for at least a month, vitrectomy carried out before 6 months resulted in an increase in the number of eyes achieving 20/40 or better acuity compared with eyes in which vitrectomy was deferred to a year. Patients with vitreous haemorrhage should be monitored weekly to ensure early detection of retinal detachment.

Type 2 diabetics are less likely to have severe proliferative retinopathy, however there is a growing trend to operate within 3 months as opposed to deferred surgery in both type 1 and type 2 diabetics.

2. Tractional retinal detachment

Tractional retinal detachment recently involving or imminently threatening the fovea is another common indication for surgery. Progressive traction produces a retinal break usually posterior to the equator and near an area of fibrous proliferation. These detachments progress quickly and usually result in a worse prognosis. Fibrovascular tissue proliferation and

contraction attached to multiple retinal foci results in macular distortion (heterotropia) or tractional detachment.

3. Combined tractional/rhegmatogenous retinal detachments

These should be treated urgently even if the macula is not involved as subretinal fluid is likely to spread quickly and involve the macula.

4. Premacular subhyaloid haemorrhage

If dense and persistent should be considered for vitrectomy because if untreated the internal limiting membrane or posterior hyaloid face may serve as a scaffold for subsequent fibrovascular proliferation and consequent tractional macular detachment or macular epiretinal membrane formation.

5. Ghost Cell Glaucoma

Vitrectomy has also been shown in case series to be of benefit when there is ghost cell glaucoma [147]. Raised intraocular pressure may be caused by partially lysed red cells (erthyroclasts) particularly in eyes with a disrupted anterior hyaloid face after previous vitrectomy for vitreous haemorrhage or in aphakic eyes with vitreous haemorrhage.

8.2.4. Management of Rubeosis Iridis

This occurs in eyes with severe retinal ischaemia or persistent retinal detachment. New vessels on the iris should be treated with PRP laser to induce regression of these vessels.

Current practice for new vessels on the iris and at the angle includes full PRP and an intravitreal anti-VEGF injection to prevent the progression to neovascular glaucoma. Treatment for neovascular glaucoma include cycloablative procedures, trabeculectomy with anti-proliferatives and implantation of a drainage tube.

Eyes that have become blind from neovascular glaucoma should be kept comfortable with topical steroids and atropine.

9. Conclusion

The global pandemic of diabetes means that retinopathy and associated visual difficulties are an ongoing problem. Further research is needed into the impact of diabetes on the neurovascular unit to facilitate greater understanding of pathophysiology. Improved screening and outcomes of treatment in developed countries mean vision can be maintained for longer. Ideally however, socioeconomic barriers need to be overcome to facilitate translational research to all parts of the world, including poorer areas. Most importantly, education on risk factors and tight glycaemic control are paramount to help prevent visual problems occurring.

Author details

Vikas Tah^{1,3}, Sonia Mall², James Myerscough⁴, Kamran Saha³, Elizabeth Emsley⁵, Andrew Swampillai⁶, Ganeshan Ramsamy¹, Daren Hanumunthadu³ and Mandeep Bindra¹

1 Stoke Mandeville Hospital, UK

2 Oxford Eye Hospital, UK

3 Moorfields Eye Hospital, UK

4 Colchester Hospital University Foundation Trust, UK

5 Imperial College London, UK

6 Barts and The London, School of Medicine and Dentistry, UK

References

- [1] Diabetes in the UK 2010: Key statistics on diabetes. Diabetes UK. 2010.
- [2] American Diabetes Association. Diabetes Basics. Available from: <http://www.diabetes.org/diabetes-basics/diabetes-statistics/> (accessed 27th July 2013)
- [3] Quality and Outcomes Framework (QOF) 2009:England: http://www.ic.nhs.uk/statistics-and-data-collections/supporting-information/audits-andperformance/the-quality-and-outcomes-framework/qof-2008/09/data-tables/prevalence-data-tablesScotland:http://www.isdscotland.org/isd/servlet/FileBuffer?namedFile=QOF_Scot_200809_Boards_all_prevalence.xls&pContentDisposition-Type=attachment
- [4] Figures based on PBS diabetes prevalence model phase 3: key findings, Yorkshire and Humber Public Health Observatory, May 2008. The PBS model estimates that by 2025 there will be 3.6 million people with diabetes in England and that the diabetes prevalence will be 6.48 per cent of the population in England. The total UK figures have been calculated by including forecasts for the population of Wales, Scotland and Northern Ireland which gives a total of 4.2 million people with diabetes by 2025.
- [5] Figures based on PBS diabetes prevalence model phase 3: key findings, Yorkshire and Humber Public Health Observatory, May 2008. The PBS model estimates that by 2025 there will be 3.6 million people with diabetes in England and that the diabetes prevalence will be 6.48 per cent of the population in England. The total UK figures have been calculated by including forecasts for the population of Wales, Scotland and Northern Ireland which gives a total of 4.2 million people with diabetes by 2025.

- [6] Department of Health (2007). About diabetes www.dh.gov.uk/en/Healthcare/NationalServiceFrameworks/Diabetes/DH_074762
- [7] Stratton IM, Adler AI, Neil HAW et al (2000). Association of glycaemia with macrovascular and microvascular complications of Type 2 diabetes (UKPDS 35): prospective observational study. *BMJ* 321;405–412
- [8] Stratton IM, Adler AI, Neil HAW et al (2000). Association of glycaemia with macrovascular and microvascular complications of Type 2 diabetes (UKPDS 35): prospective observational study. *BMJ* 321;405–412
- [9] Harris MI, Klein R, Welborn TA et al (1992). Onset of NIDDM occurs at least 4-7 years before clinical diagnosis. *Diabetes Care* 15 (7); 815–819
- [10] Stitt A, Lois N, Medina R, et al. Advances in our understanding of diabetic retinopathy. *Clinical Science*. 2013;125;1-17
- [11] Hamilton AMP, Ulbig MW, Polkinghorne P (1996). Management of diabetic retinopathy, London:BMJ Publishing
- [12] Williams R, Airey M, Baxter H. Epidemiology of diabetic retinopathy and macular oedema: A systematic review. *Eye*. 2004;18;963-83.
- [13] Malone J, Morrison A, Pavan P, et al. Diabetic Control and Complications Trial: Prevalence and significance of retinopathy in subjects with type 1 diabetes of less than 5 years duration screened for the diabetes control and complications trial. *Diabetes Care*. 200;124;522-6.
- [14] Kohner E, Aldington S, Stratton I. United Kingdom Prospective Diabetes Study, 30: Diabetic retinopathy at diagnosis of non-insulin-dependent diabetes mellitus and associated risk factors. *Arch Ophthalmol*. 1998;116;297-303.
- [15] Klein R, Klein B, Moss S. Visual impairment in diabetes. *Ophthalmology*. 1984;91;1-9.
- [16] Moss S, Klein R, Klein B. Ten-year incidence of visual loss in a diabetic population. *Ophthalmology*. 1994; 101(6); 1061-70.
- [17] Forlenza G, Stewart M. Diabetic retinopathy in children. *Pediatr Endocrinol Rev*. 2012-13; 10(2);217-26.
- [18] Photocoagulation treatment of proliferative diabetic retinopathy: the second report of Diabetic Retinopathy Study findings. *Ophthalmology*. 1978;85;82-105.
- [19] Photocoagulation for diabetic macular oedema: Early Treatment Diabetic Retinopathy Study report number 1. *Arch Ophthalmology*. 1985;103;1796-806.
- [20] Antonetti D, Klein R, Gardner T. Diabetic retinopathy. *NEJM*. 2012;366;1227-39.
- [21] Klein R, Lee K, Gangnon R, et al. The 25-year incidence of visual impairment in type 1 diabetes mellitus: the Wisconsin Epidemiologic Study of Diabetic Retinopathy. *Ophthalmology*. 2010;117;63-70.

- [22] Hovind P, Tarnow L, Rossing K, et al. Decreasing incidence of severe diabetic microangiopathy in type 1 diabetes. *Diabetes care*. 2003;26;1258-64.
- [23] Nordwall M, Bojestig M, Arnqvist H, et al. Declining incidence of severe retinopathy and persisting decrease of nephropathy in an unselected population of Type 1 diabetes – the Linköping Diabetes Complications Study. *Diabetologia*. 2004;47;1266-72.
- [24] Kempen J, O'Colmain B, Leske M, et al. The prevalence of diabetic retinopathy among adults in the United States. *Arch Ophthalmol*. 2004;122;552-63.
- [25] Sloan F, Belsky D, Ruiz D, et al. Changes in incidence of diabetes mellitus-related eye disease among US elderly persons 1994-2005. *Arch Ophthalmol*. 2008;126;1548-53.
- [26] Klein R, Klein B. Are individuals with diabetes seeing better? A long term epidemiological perspective. *Diabetes*. 2010;59;1853-60.
- [27] Wild S, Roglic G, Green A, et al. Global prevalence of diabetes: estimates for the year 2000 and projections for 2030. *Diabetes Care*. 2004;27;1047-53.
- [28] Al-Rubeaan K. Type 2 diabetes mellitus red zone. *Int J Diabetes Mellitus*. 2010;2(1); 1-2.
- [29] Rema M, Premkumar S, Anitha B, et al. Prevalence of diabetic retinopathy in urban India: the Chennai Urban Rural Epidemiology Study (CURES) eye study. *Invest Ophthalmol Vis Sci*. 2005;46;2328-33.
- [30] Targher G, Bertolini L, Chonchol M, et al. Non-alcoholic fatty liver disease is independently associated with an increased prevalence of chronic kidney disease and retinopathy in type 1 diabetic patients. *Diabetologia*. 2010;53;1341-8.
- [31] Nguyen T, Alibrahim E, Islam F, et al. Inflammatory, haemostatic and other novel biomarkers for diabetic retinopathy: the multi-ethnic study of atherosclerosis. *Diabetes Care*. 2009;32;1704-9.
- [32] West S, Groves D, Lipinski H, et al. The prevalence of retinopathy in men with Type 2 diabetes and obstructive sleep apnoea. *Diabet Med*. 2010;27;423-30
- [33] Arnold E, Rivera J, Thebault S, et al. High levels of serum prolactin protect against diabetic retinopathy by increasing ocular vasoinhibins. *Diabetes*. 2010;59;3192-7.
- [34] Zietz B, Buechler C, Kobuch K, et al. Serum levels of adiponectin are associated with diabetic retinopathy and with adiponectin gene mutations in Caucasian patients with diabetes mellitus type 2. *Exp Clin Endocrinol Diabetes*. 2008;116;532-6.
- [35] Nathan D, Zinman B, Cleary P et al. Modern day clinical course of type 1 diabetes mellitus after 30 years' duration: the Diabetes Control and Complications Trial/ Epidemiology of Diabetes Interventions and Complications and Pittsburgh Epidemiology of Diabetes Complications experience (1983-2005). *Arch Intern Med*. 2009;169; 1307-16.

- [36] Matthews D, Stratton S, Aldington S, et al. Risks of progression of retinopathy and vision loss related to tight blood pressure control in type 2 diabetes mellitus: UKPDS 69. *Archives of Ophthalmology*. 2004; 122 (11); 1631-1640.
- [37] White N, Cleary P, Dahms W, et al. Beneficial effects of intensive therapy of diabetes during adolescence: outcomes after the conclusion of the Diabetes Control and Complications Trial (DCCT). *The Journal of Paediatrics*. 139 (6); 804-812.
- [38] Tarr J, Kaul K, Chopra M, et al. Pathophysiology of Diabetic Retinopathy. *ISRN Ophthalmology*. 2013;343560.
- [39] Singh R, Ramasamy K, Abraham C, et al. Diabetic retinopathy: an update. *Indian Journal of Ophthalmology*. 2008;56(3);179-188.
- [40] Gabbay K. Hyperglycaemia, polyol metabolism and complications of diabetes mellitus. *Annual Review of Medicine*. 1975;26;521-536.
- [41] Gabbay K. The sorbitol pathway and the complications of diabetes. *The New England Journal of Medicine*. 1973;288(16);831-836.
- [42] Szwergold B, Kappler F, Brown T. Identification of fructose 3-phosphate in the lens of diabetic rats. *Science*. 1990;247(4941);451-454.
- [43] Barnett P, Gonzalez R, Chylack L, et al. The effect of oxidation on sorbitol pathway kinetics. *Diabetes*. 1986;35(4);426-432.
- [44] Hohman T, Nishimura C, Robison E. Aldose reductase and polyol cultured pericytes of human retinal capillaries. *Experimental Eye Research*. 1989;48 (1);55-60.
- [45] Chakrabarti S, Sima A, Nakajima T. Aldose reductase in the BB rat: isolation, immunological identification and localisation in the retina and peripheral nerve. *Diabetologia*. 1987;30(4);244-251.
- [46] Cheung A, Fung M, Lo A, et al. Aldose reductase deficiency prevents diabetes-induced blood-retinal barrier breakdown, apoptosis and glial reactivation in the retina of db/db mice. *Diabetes*. 2005;54(11);3119-3125.
- [47] Dagher Z, Park Y, Asnaghi V, et al. Studies of rat and human retinas predict a role for the polyol pathway in human diabetic retinopathy. *Diabetes*. 2004;53(9); 2404-2411.
- [48] Kuwabara T, Cogan D. Retinal vascular patterns. VI. Mural cells of the retinal capillaries. *Arch Ophthalmol*. 1963; 69; 492-502.
- [49] Roy S, Lorenzi M. Early biosynthetic changes in the diabetic-like retinopathy of galactose-fed rats. *Diabetologia*. 1996;39(6);735-738.
- [50] Glover J, Jacot J, Basso M, et al. Retinal capillary dilation: early diabetic-like retinopathy in the galactose-fed rat model. *Journal of Ocular Pharmacology and Therapeutics*. 2000;16(2);167-172.

- [51] 51. Hattori T, Matsubara A, Taniguchi K, et al. Aldose reductase inhibitor fidarestat attenuates leukocyte-endothelial interactions in experimental diabetic rat retina in vivo. *Current Eye Research*. 2010;35(2);146-154.
- [52] Chung S, Chung S. Genetic analysis of aldose reductase in diabetic complications. *Current Medicinal Chemistry*. 2003;10(15);1375-1387.
- [53] Hammes H, Martin S, Federlin K, et al. Aminoguanidine treatment inhibits the development of experimental diabetic retinopathy. *Proceedings of the National Academy of Sciences of the United States of America*. 1991;88(24);11555-11558.
- [54] Peppas M, Uribarri J, Vlassara H. Advanced glycation end products and diabetes complications: what is new and what works. *Clinical Diabetes*. 2003;21(4);186-187.
- [55] Zong H, Ward M, Stitt A. AGEs, RAGE and diabetic retinopathy. *Current Diabetes Reports*. 2011;11(4);244-252.
- [56] Stitt A, Gardiner T, Anderson N, et al. The AGE inhibitor pyridoxamine inhibits development of retinopathy in experimental diabetes. *Diabetes*. 2002;51(9);2826-2832.
- [57] Hammes H, Weiss A, Fuhrer D, et al. Acceleration of experimental diabetic retinopathy in the rat by omega-3 fatty acids. *Diabetologia*. 1996; 39(3); 251-255.
- [58] Williamson J, Kilo C. Extracellular matrix changes in diabetes mellitus. In: Scarpelli D, Migahi D, editors. *Comparative pathobiology of major age-related diseases*. New York: Liss, 1984. Pp 269-88.
- [59] Koya D, King G. Protein kinase C activation and the development of diabetic complications. *Diabetes*. 1998;47(6);859-866.
- [60] Wang Q. PKC at the crossroads of DAG and PKC signaling. *Trends in pharmacological sciences*. 2006;27(6);317-323.
- [61] Aiello L, Bursell S, Clermont A, et al. Vascular endothelial growth factor-induced retinal permeability is mediated by protein kinase C in vivo and suppressed by an orally effective beta-isoform-selective inhibitor. *Diabetes*. 1997;46(9);1473-1480.
- [62] Aiello L, Clermont A, Arora V, et al. Inhibition of PKC beta by oral administration of ruboxistaurin is well tolerated and ameliorates diabetes-induced retinal haemodynamic abnormalities in patients. *Investigative Ophthalmology and Visual Science*.
- [63] Joy S, Scates S, Bearelly S, et al. Ruboxistaurin, a protein kinase C Beta inhibitor, as an emerging treatment for diabetes microvascular complications. *Annals of Pharmacotherapy*. 2005;39(10);1693-1699.
- [64] Clarke M, Dodson P. PKC inhibition and diabetic microvascular complications. *Best practice and research: clinical endocrinology and metabolism*. 2007;21(4);573-586.
- [65] Kohner E. The retinal blood flow in diabetes. *Diabete et Metabolisme*. 1993;19(5); 401-404.

- [66] Wilkinson-Berka J. Angiotensin and diabetic retinopathy. *International Journal of Biochemistry and Cell Biology*. 2006;38(5-6);757-765.
- [67] Funatsu H, Yamashita H, Nakanishi Y, et al. Angiotensin II and vascular endothelial growth factor in the vitreous fluid of patients with proliferative diabetic retinopathy. *British Journal of Ophthalmology*. 2002;86(3);311-315.
- [68] Sjolie A, Klein R, Porta M, et al. Effect of candesartan on progression and regression of retinopathy in type 2 diabetes (DIRECT-Protect 2): a randomised placebo-controlled trial. *The Lancet*. 2008;372(9647);1385-1393.
- [69] Chaturvedi N, Porta M, Klein R, et al. Effect of candesartan on prevention (DIRECT-Prevent 1) and progression (DIRECT-Protect 1) of retinopathy in type 1 diabetes: randomised, placebo-controlled trials. *The Lancet*. 2008;372(9647);1394-1402.
- [70] Mauer M, Ziman B, Gardiner R, et al. Renal and retinal effects of enalapril and losartan in type 1 diabetes. *The New England Journal of Medicine*. 2009;361(1);40-51.
- [71] Otani A, Takagi H, Suzuma K, et al. Angiotensin II potentiates vascular endothelial growth-factor induced angiogenic activity in retinal microcapillary endothelial cells. *Circulation Research*. 1998;82(5);619-628.
- [72] Schroder S, Palinski W, Schmid-Schonbein G. Activated monocytes and granulocytes, capillary nonperfusion and neovascularization in diabetic retinopathy. *American Journal of Pathology*.
- [73] Luty G, Cao J, McLeod D. Relationship of polymorphonuclear leukocytes to capillary dropout in the human diabetic choroid. *American Journal of Pathology*. 1997;151(3);707-714.
- [74] Chibber R, Ben-Mahmud M, Coppini D, et al. Activity of the glycosylating enzyme, core 2 GlcNAc (Beta1,6) transferase, is higher in polymorphonuclear leukocytes from diabetic patients compared with age-matched control subjects: relevance to capillary occlusion in diabetic retinopathy. *Diabetes*. 2000;49(10);1724-1730.
- [75] Chibber R, Ben-Mahmud B, Mann G, et al. Protein kinase C Beta2-dependent phosphorylation of core 2 GlcNAc-T promotes leukocyte-endothelial cell adhesion: a mechanism underlying capillary occlusion in diabetic retinopathy. *Diabetes*. 2003;52(6);1519-1527.
- [76] Kaul K, Hodgkinson A, Tarr J, et al. Is inflammation a common retinal-renal-nerve pathogenic link in diabetes? *Current Diabetes Reviews*. 2010;6(5);294-303.
- [77] Hernandez C, Segura R, Fonollosa A, et al. Interleukin-8, monocyte chemoattractant protein1 and IL-10 in the vitreous fluid of patients with proliferative diabetic retinopathy. *Diabetic Medicine*. 2005;22(6);719-225.

- [78] Doganay S, Evereklioglu C, Er H, et al. Comparison of serum NO, TNF-alpha, IL-1beta, SIL-2R, IL-6 and IL-8 levels with grades of retinopathy in patients with diabetes mellitus. *Eye*. 2002; 16(2);163-170.
- [79] Takami S, Yamashita S, Kihara S, et al. High concentration of glucose induces the expression of intercellular adhesion molecule-1 in human umbilical vein endothelial cells. *Atherosclerosis*. 1998;138(1);35-41.
- [80] Larson E, Springer T. Structure and function of leukocyte integrins. *Immunological Reviews*. 1990;114;181-217.
- [81] Sfikakis P, Grigoropoulos V, Emfietzoglou I, et al. Infliximab for diabetic macular edema refractory to laser photocoagulation: a randomized, double-blind, placebo-controlled, crossover, 32-week study. *Diabetes Care*. 2010;33(7);1523-1528.
- [82] Baynes J. Role of oxidative stress in development of complications in diabetes. *Diabetes*. 1991;40(4);405-412.
- [83] Cui Y, Xu X, Bi H, et al. Expression modification of uncoupling proteins and MnSOD in retinal endothelial cells and pericytes induced by high glucose: the role of reactive oxygen species in diabetic retinopathy. *Experimental Eye Research*. 2006; 83(4); 807-816.
- [84] Kowluru R, Chan P. Oxidative stress and diabetic retinopathy. *Experimental Diabetes Research*. 2007;43603.
- [85] 85. El-Remessy A, Bartoli M, Platt D, et al. Oxidative stress inactivates VEGF survival signaling in retinal endothelial cells via PI 3-kinase tyrosine nitration. *Journal of Cell Science*. 2005;118(1);243-252.
- [86] Hartnett M, Stratton R, Browne R, et al. Serum markers of oxidative stress and severity of diabetic retinopathy. *Diabetes Care*. 2000;23(2);234-240.
- [87] Brownlee M. The pathobiology of diabetic complications: a unifying mechanism. *Diabetes*. 2005;54(6);1615-1625.
- [88] Grant M, Mames R, Fitzgerald C, et al. The efficacy of octreotide in the therapy of severe nonproliferative and early proliferative diabetic retinopathy: a randomised controlled study. *Diabetes Care*. 2000;23(4);504-509.
- [89] Zimmerman B, Molnar G. Prolonged follow up in diabetic retinopathy treated by sectioning the pituitary stalk. *Mayo Clinic Proceedings*. 1977;52(4);233-237.
- [90] Comer G, Ciulla T. Pharmacotherapy for diabetic retinopathy. *Current Opinion in Ophthalmology*. 2004;15(6);508-518.
- [91] Ishida S, Usui T, Yamashiro K, et al. VEGF164 is proinflammatory in the diabetic retina. *Investigative Ophthalmology and Visual Science*. 2003;44(5);2155-2162.
- [92] Zhang X, Wen L, Chen Y et al. Vascular endothelial growth factor upregulates the expression of intracellular adhesion molecule-1 in retinal endothelial cells via reac-

- tive oxygen species, but not nitric oxide. *Chinese Medical Journal*. 2009;122(3);338-343.
- [93] Adamis A, Shima D, Yeo K, et al. Synthesis and secretion of vascular permeability factor/vascular endothelial growth factor by human retinal pigment epithelial cells. *Biochemical and Biophysical Research Communications*. 1993;193(2);631-638.
- [94] Wirostko B, Wong T, Simo R. Vascular endothelial growth factor and diabetic complications. *Progress in Retinal and Eye Research*. 2008;27(6);608-621.
- [95] Gao B, Clermont A, Rook S, et al. Extracellular carbonic anhydrase mediates haemorrhagic retinal and cerebral vascular permeability through prekallikrein activation. 2007;13(2);181-188.
- [96] Weiwei Z, Hu R. Targeting carbonic anhydrase to treat diabetic retinopathy: emerging evidences and encouraging results. *Biochemical and Biophysical Research Communications*. 2009;390(3);368-371.
- [97] Park S, Park J, Park S, et al. Apoptotic death of photoreceptors in the streptozotocin-induced diabetic rat retina. *Diabetologia*. 2003;46(9);1260-1268.
- [98] West SD, Groves DC, Lipinski HJ, et al. The prevalence of retinopathy in men with Type 2 diabetes and obstructive sleep apnoea. *Diabet Med* 2010;27:423-430
- [99] Tong Z, Yang Z, Patel S, et al. Promoter polymorphism of the erythropoietin gene in severe diabetic eye and kidney complications. *Proc Natl Acad Sci U S A* 2008;105:6998-7003
- [100] Klein R, Klein BE, Moss SE, Davis MD, DeMets DL. The Wisconsin epidemiologic study of diabetic retinopathy. II. Prevalence and risk of diabetic retinopathy when age at diagnosis is less than 30 years. *Arch. Ophthalmol* 1984; 102(4), 520–526
- [101] Roy MS. Diabetic retinopathy in African Americans with type 1 diabetes: The New Jersey 725: I. Methodology, population, frequency of retinopathy, and visual impairment. *Arch Ophthalmol* 2000;118:97–104
- [102] Klein R, Klein BE, Moss SE, Davis MD, DeMets DL. The Wisconsin epidemiologic study of diabetic retinopathy. III.
- [103] Harvey JN. The influence of sex and puberty on the progression of diabetic nephropathy and retinopathy. *Diabetologia* 2011;54(8), 1943–1945
- [104] Klein BE, Moss SE, Klein R. Is menarche associated with diabetic retinopathy? *Diabetes Care* 1990; 13(10), 1034–1038
- [105] EDIC research group. Retinopathy and nephropathy in type 1 diabetes patients four years after trial of intensive therapy. *N Engl J Med*. 2000;342:381–9

- [106] The Diabetes Control and Complications Trial Research Group. The effect of intensive treatment of diabetes on the development and progression of long-term complications in insulin-dependent diabetes mellitus. *N Engl J Med*. 1993;329:977–86
- [107] Hirsch IB, Brownlee M. Beyond hemoglobin A1c — need for additional markers of risk for diabetic microvascular complications. *JAMA* 2010;303:2291-2
- [108] Kern PA. Lipid disorders in diabetes mellitus. *Mt Sinai J Med* 1987;54: 245-252.
- [109] Ferris III FL, Chew KY, Hoogwerf HJ. Serum lipids and diabetic retinopathy. Early treatment diabetic retinopathy study research group. *Diabetes Care* 1996; 19: 1291
- [110] Chew EY. Diabetic retinopathy and lipid abnormalities. *Curr Opin Ophthalmol*. 1997; 8: 59-62
- [111] Hypertension in Diabetes Study (HDS). II. Increased risk of cardiovascular complications in hypertensive type 2 diabetic patients. *J Hypertens* 1993;11:319-25
- [112] Patel V, Rassam S, Newsom R, Wiek J, Kohner EM. Retinal blood flow in diabetic retinopathy. *BMJ*. 1992;305:678-683
- [113] Rassam SMB, Patel V, Kohner EM. The effect of experimental hypertension on retinal autoregulation in humans: a mechanism for the progression of diabetic retinopathy. *Exp Physiol*. 1995;80:53-68
- [114] Hogeboom van Buggenum IM, Polak BC, Reichert-Thoen JW, et al. Angiotensin converting enzyme inhibiting therapy is associated with lower vitreous vascular endothelial growth factor concentrations in patients with proliferative diabetic retinopathy. *Diabetologia*. 2002;45:203-209
- [115] UK Prospective Diabetes Study Group: Efficacy of atenolol and captopril in reducing risk of macrovascular and microvascular complications in Type 2 diabetes. *UKPDS 39. Br Med J* 1998;317:713-20.
- [116] The Diabetes Control, Complications Trial Research Group. Effect of pregnancy on microvascular complications in the Diabetes Control and Complications Trial. *Diabetes Care* 2000; 23: 1084–1091
- [117] Klein BE, Moss SE, Klein R. Effect of pregnancy on progression of diabetic retinopathy. *Diabetes Care* 1990; 13: 34–40
- [118] Axer-Siegel R, Hod M, Fink-Cohen S, Kramer M, Weinberger D, Schindel B, Yassur Y. Diabetic retinopathy during pregnancy. *Ophthalmology* 1996; 103(11): 1815-1819
- [119] Phelps RL, Sakol P, Metzger BE, Jampol LM, Frienkel N. Changes in diabetic retinopathy during pregnancy. Correlations with regulation of hyperglycaemia. *Arch Ophthalmol* 1986; 104: 1806–1810
- [120] Diabetes in Early Pregnancy Study. Metabolic control and progression of retinopathy. *Diabetes Care* 1995; 18: 631–637

- [121] Chew EY, Mills JL, Metzger BE, Remaley NA, Jovanovich-Peterson L, Knopp RH. Metabolic control and the progression of retinopathy. The diabetes in Early Pregnancy Study. *Diabetes Care* 1995; 18: 631–637
- [122] Harding, S., R. Greenwood, S. Aldington, J. Gibson, D. Owens, R. Taylor, E. Kohner, P. Scanlon, and G. Leese. 2003. Grading and disease management in national screening for diabetic retinopathy in England and Wales. *Diabet Med* 20:965.
- [123] Diabetic Retinopathy Study Research Group. Report 7. A modification of the Airlie House classification of diabetic retinopathy. *Invest Ophthalmol Vis Sci* 1981;21:210–26.
- [124] Wilkinson, C. P., F. L. Ferris, 3rd, R. E. Klein, P. P. Lee, C. D. Agardh, M. Davis, D. Dills, A. Kampik, R. Pararajasegaram, and J. T. Verdaguer. 2003. Proposed international clinical diabetic retinopathy and diabetic macular edema disease severity scales. *Ophthalmology* 110:1677.
- [125] Grading diabetic retinopathy from stereoscopic colour fundus photographs--an extension of the modified Airlie House classification. ETDRS report number 10. Early Treatment Diabetic Retinopathy Study Research Group. *Ophthalmology* 1991. 98:786.
- [126] The Diabetes Control and Complications Trial Research Group (1997) Clustering of long-term complications in families with diabetes in the diabetes control and complications trial. The Diabetes Control and Complications Trial Research Group. *Diabetes* 46: 1829–1839.
- [127] Chew, E., Klein, M., Ferris, F., III, Remaley, N., Murphy, R., Chantry, K. et al. (1996) Association of elevated serum lipid levels with retinal hard exudate in diabetic retinopathy. early treatment diabetic retinopathy study (ETDRS) report 22. *Arch Ophthalmol* 114: 1079–1084
- [128] Keech, A., Mitchell, P., Summanen, P., O'Day, J., Davis, T., Moffitt, M. et al. (2007) Effect of fenofibrate on the need for laser treatment for diabetic retinopathy (FIELD study): a randomised controlled trial. *Lancet* 370: 1687–1697
- [129] Gaede, P., Lund-Andersen, H., Parving, H. and Pedersen, O. (2008) Effect of a multifactorial intervention on mortality in type 2 diabetes. *N Engl J Med* 358: 580–591.
- [130] Images courtesy of Mr Jignesh Patel, Essex County Hospital, Colchester.
- [131] Diabetes Control and Complications Trial/Epidemiology of Diabetes Interventions and Complications Research Group. Retinopathy and nephropathy in patients with type 1 diabetes mellitus four years after a trial of intensive therapy. *N Eng J Med*. 2000;342:381-9
- [132] UK Prospective Diabetes Study (UKPDS) Group. Intensive blood-glucose control with sulphonylureas or insulin compared with conventional treatment and risk of complications in patients with type 2 diabetes (UKPDS 33). *Lancet*.1998;352:837-53.

- [133] Guidelines from the British Hypertensive Society. *BMJ*. 2004;328:593-4.
- [134] Chaturvedi N, Sjolie AK, Stephenson JM et al; EUCLID Study Group. Effect of lisinopril on progression of retinopathy in normotensive people with type 1 diabetes. *Lancet*. 1998;351 (9095):28-31
- [135] Van Leiden HA, Dekker HA, Moll AC, et al. Blood pressure, lipids, and obesity are associated with retinopathy: the Hoorn study. *Diabetes Care*. 2002;25:1320-5.
- [136] Klein R, Sharrett AR, Klein BE, et al. The association of atherosclerosis, vascular risk factors, and retinopathy in adults with diabetes: the atherosclerosis risk in communities study. *Ophthalmology*. 2002;109:1225-34
- [137] Keech A, Simes RJ, Barter P, et al. Effects of long term fenofibrate therapy on cardiovascular events in 9795 people with type 2 diabetes mellitus (the FIELD study): randomized controlled trial. *Lancet*. 2005; 366:1849-61
- [138] Diabetic Retinopathy Clinical Research Network. A randomized trial comparing intravitreal triamcinolone acetonide and focal/grid photocoagulation for diabetic macular oedema. *Ophthalmology*. 2008;115:1447-59.
- [139] Nguyen QD, Shah SM, Khwaja AA, et al. Two year outcomes of ranibizumab for oedema of the macula in diabetes (READ-2) study. *Ophthalmology*. 2010;117:2146-51.
- [140] Massin P, Bandello F, Garweg JG, et al. Safety and efficacy of ranibizumab in diabetic macula oedema (RESOLVE Study): a 12 month, randomized, controlled, double-masked multicenter phase II study. *Diabetes Care*. 2010;33:2399-405.
- [141] Mitchell P, Bandello F, Schmidt-Erfurth U et al. The RESTORE study: ranibizumab monotherapy or combined with laser versus laser monotherapy for diabetic macular edema. *Ophthalmology*. 2011;118:615-25.
- [142] Michaelides M, Kaines A, Hamilton RD, Fraser-Bell S, et al. A prospective randomized trial of intravitreal bevacizumab or laser therapy in the management of diabetic macula edema (BOLT study) 12-month data: report 2. *Ophthalmology*. 2010;117:1078-86.
- [143] Do DV, Nguyen QD, Boyer D, Schmidt-Erfurth U, Brown DM, Vitti R, Berliner AJ, Gao B, Zeitz O, Ruckert R, Schmelter T, Sandbrink R, Heier JS; DAVINCI Study Group. One-Year Outcomes of the DA VINCI Study Group of VEGF Trap-Eye in Eyes with Diabetic Macula Edema. *Ophthalmology* 2012. April 24 epub ahead of print.
- [144] Campochiaro PA, Brown DM, Pearson A, et al. FAME Study Group Sustained Delivery Fluocinolone Acetonide Vitreous Inserts Provide Benefit for at Least 3 years in Patients with Diabetic Macula Edema, *Ophthalmology* 2012 Jun 21 (epub ahead of print)

- [145] The Diabetic Retinopathy Research Group. Indications for photocoagulation treatment of diabetic retinopathy: Diabetic Retinopathy Study No.14 *Int Ophthalmol Clin* 1987;27:239-252.
- [146] Diabetic Retinopathy Vitrectomy Study Research Group. Early Vitrectomy for severe vitreous haemorrhage in diabetic retinopathy. Two year results of a randomized trial. DRVS report No 2. *Archives of Ophthalmology*. 1985;103:1644
- [147] Brucker AJ, Michels RG, Green WR. Pars plana vitrectomy in the management of blood-induced glaucoma with vitreous haemorrhage. *Ann Ophthalmol*. 1978;10:1427-37
- [148] Royal College of Ophthalmologists. Diabetic Retinopathy Guidelines December 2012 <http://www.rcophth.ac.uk/page.asp?section=451§ionTitle=Clinical+Guidelines>

IntechOpen

