

We are IntechOpen, the world's leading publisher of Open Access books Built by scientists, for scientists

4,800

Open access books available

122,000

International authors and editors

135M

Downloads

Our authors are among the

154

Countries delivered to

TOP 1%

most cited scientists

12.2%

Contributors from top 500 universities



WEB OF SCIENCE™

Selection of our books indexed in the Book Citation Index
in Web of Science™ Core Collection (BKCI)

Interested in publishing with us?
Contact book.department@intechopen.com

Numbers displayed above are based on latest data collected.
For more information visit www.intechopen.com



Clinical Research Progress of Glaucomatocyclitic Crisis

He-Zheng Zhou, Wen-Shan Jiang, Han-Guang Jie,
Chang Feng, Wen-Qiang Zhang, Qian Ye,
Jian-Guo Wu, Yan-Ping Song and Qin Ding

Additional information is available at the end of the chapter

<http://dx.doi.org/10.5772/58348>

1. Introduction

1.1. Definition

Glaucomatocyclitic crisis was initially described in detail by Posner and Schlossman in 1948, so it was also called Posner – Schlossman syndrome (PSS). PSS is a special form of anterior uveitis with glaucoma, mainly seen in young adults, characterized by non-granulomatous iridocyclitis with significant elevation of intraocular pressure. In most cases, the disease takes an acute form of recurrent and monocular onset.

1.2. Morbidity

This disease is often seen in people aged from 20 to 50, and rarely in people above 60 years old. Five percent or less of PSS cases were reported in people above 60 years old [3]. The disease is rare in Western countries, it was reported that 19 in one million people have suffered from PSS in Finland [4]. As PSS is a kind of disease attacks intermittently, it is difficult to diagnose PSS in intermittent period for the lack of diagnostic signs and investigate the morbidity with epidemiology methods. We used the full text VIP Chinese literature retrieval system and Medline retrieval system to find PSS reports from 1975 to 2011 in both English and Chinese literature and divided into review, case, experimental study and clinical report four categories, then analyzed the regional distribution of the authors and cases (Chinese reports were divided into the Yangtze river and the other, English reports were divided into Asia and the other).

The report which contained the most number of cases was chosen if there were more than two from a same author statistical results shows that 1262 cases were reported by 33 Chinese clinical reports in which 991 cases were reported by 20 reports from the area near the Yangtze river,

and 271 cases were reported by 13 reports from the other area. The other 211 cases were reported by 16 English clinical reports in which 144 cases were reported by 7 reports from the Asia area and 67 cases reported by 9 reports from the other area. The results above suggest that there are much more literature and cases related to PSS in the area near the Yangtze river and infer that the prevalence of PSS in that area may be higher.

Literature types	Region	Review	Case	Experimental research	Clinical report	Aggregate
Chinese	Near the Yangtze river basin	0	11	1	20	32
	Other areas	2	11	0	13	26
English	Asia	2	0	2	7	11
	Other areas	3	12	0	9	24
Aggregate		7	34	3	49	93(total)

Table 1. The regional distribution of the authors

1.3. Possible etiology

1. Many factors were considered to be related to the onset of PSS, such as allergy, fatigue, mental fatigue, mental stress, decreased body resistance, infection, hypothalamic disorders, autonomic dysfunction, abnormal reactions of ciliary vascular and nervous system and abnormal development in angle of anterior chamber.[1]
2. Recent research had confirmed that concentration of prostaglandins (PGs) in the anterior chamber aqueous increased obviously in the PSS cases, especially that of PGE. [5]
3. Infection by herpes virus.

The conclusion that PSS was caused by herpes simplex virus (HKS) was reported by Yainamotos in 1995, and was confirmed by many following researches. A recent report showed that antiviral treatment reduced the frequency of the outbreak of the disease. [6-7]

It was reported that aqueous humor of a binocular PSS case was collected after suffering from herpes viral keratitis for five months with anterior chamber paracentesis, then DNA of cytomegalovirus (CMV) and HKS were measured by means of quantitative polymerase chain reaction(PCR), the results showed CMV was positive but HKS was negative. It was speculated that CMV which belongs to herpes virus genera would also lead to PSS. It was considered that PSS is not a separate disease, but a kind of anterior uveitis relating to infections of herpes virus.

A study from Singapore showed that the CMV DNA of aqueous humor was positive for 24 of 104 anterior uveitis cases with monocular high IOP, in which 18 cases were PSS, 5 cases were Fuchs heterochromic iridocyclitis (FHI). [8]Another study showed CMV DNA was positive in 35 of 67 PSS cases (52.2%) and in 15 of 35 FHI cases (41.7%). Although the keratic precipitates (KP) in CMV DNA positive anterior uveitis cases was consider to be accompanied with an

endothelial halo, clinical difference was not so significant between CMV DNA positive and negative cases as less aqueous humor in sample and weak sensitivity of detection method. In 2008, aqueous analysis for CMV by PCR was performed in 103 eyes of 102 patients with presumed PSS or FHI at the Singapore National Eye Centre. Their records were reviewed for clinical features and human immunodeficiency virus (HIV) status of the CMV-positive patients. The main parameters were age, gender, maximum intraocular pressure, endothelial cell count, endothelial changes, PCR results, and presence of uveitic cataract and/or glaucoma. It was found that there was no clinically detectable differences between CMV-positive and negative presumed PSS eyes. CMV-positive presumed FHI patients are more likely to be male, older at diagnosis or have nodular endothelial lesions. [9]

4. Helicobacter pylori infection.

It was reported in South Korean that there was a significant difference of the positive rate of helicobacter pylori serum antibody between cases with PSS (80%) and cases without PSS (56.2%). In another prospective study, 40 cases with PSS and 73 cases without PSS received serologic analysis for the presence of H. pylori infection by an enzyme-linked immunosorbent assay. The positive rate of serum anti-H. pylori IgG was compared between the two groups. It was proved that H. pylori infection occurred significantly more often in PSS patients. This study suggests that exposure to H. pylori infection is associated with PSS in Korea. [10]

1.4. Clinical features of typical cases [1, 2, 3, 11, 12, 13]

1. In most cases, the disease always attacks the identical eye repeatedly, binocularly affected cases is not common; PSS results in paroxysmal increase of IOP repeatedly, which reaches as high as 40 to 60 mmHg, and lasts for 1 to 14 days generally, 1 month occasionally, 2 months rarely; interval of onset is from months to 2 years;
2. Symptoms are not obvious, just mild discomfort for most cases;
3. Eyesight is normal generally, blurred vision when suffers from corneal edema at onset;
4. Pupil becomes slightly bigger with normal reaction to light, and never adheres to lens;
5. The KP of PSS appeared in a few days after or before the elevation of IOP with number of 1 to 25, took a form of hoar and suet-shaped and disappeared days to 1 month after the IOP returned normal, distributed mainly in the inferior part of the cornea or concealed in the trabecular meshwork. There were no or at most a few planktonic cells in aqueous while the flare was negative. There is no inflammatory cell in vitreous body (See Figure 1);
6. The anterior chamber angle is open, no matter IOP is normal or elevated; visual field and fundus of most cases are normal generally, but a reversible expanding of vascular shadow may occur during an acute onset.
7. Coefficient of outflow facility (C value) descends in episodes and recovers in intermission; various stimulation tests for glaucoma are negative in intermission;
8. The forms of onset of PSS could be divided into three kinds: KP, high IOP and intermediate type, according to relationship between KP and IOP.

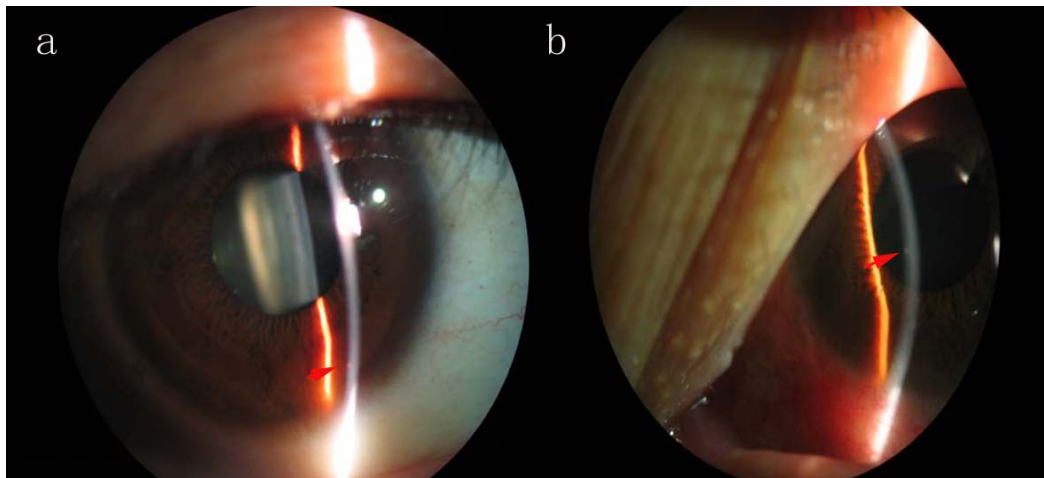


Figure 1. Anterior segment of a case with PSS in episodes. Arrows indicate the typical hoar and suet-shaped KP.

Typical case

A patient complained of her blurred vision two months ago, examination in other hospital showed: conjunctiva of her left eye wasn't congestive and the cornea was edematous mildly, IOP: 34/ 18(R/L) mmHg; there were some round lipid-like KP in the left cornea, aqueous flare(-). She came to our hospital on June 7, 2012, ophthalmologic examination: vision was 0.5/ 1.5(R/L), best corrected vision of left eye was 1.2(-1.25DS), IOP: 18/ 13 (R/L) mmHg. Her right eye was normal, conjunctiva of her left eye wasn't congestive and there were five rounds lipid-like KP in the left cornea, binocular C/D was 0.4. Her KP faded away after the treatment of chloromethyl and pranopulin (three times a day) for three weeks. Examination of FFA, ICGA and Virus screening were normal on July 10. The measurement of her 24 hours IOP performed two weeks after she ceased the drugs was 20-14mmHg(R), 15-12 mmHg (L). The result of her visual field and the OCT for glaucoma was normal. She was diagnosed as PSS in left eye and suggested to be observed and treated timely.

1.5. Treatment of typical cases in episodes

1. Anti-inflammation: Corticosteroid drugs is needed in most cases, but it should not be used too long at a time, so as not to cause the corticosteroid glaucoma.
2. It is a better select in some cases to apply non-steroidal anti-inflammatory drugs (NSAIDs) such as eye drops of pranoprofen, indomethacin and flufenamic acid.
3. Reducing IOP: Eye drops of epinephrine, timolol, or clonidine was needed singly or jointly for common patient, carbonic anhydrase inhibitor orally when the IOP is higher than 30mmHg and mannitol of intravenous drip when the IOP is higher than 40mmHg.
4. The antiviral treatment systemically or implanting long-acting agents may be helpful to reduce the frequency of attack, but it has worrying and serious side effects and costs too much. [12]

1.6. The outstanding clinical questions and the main points of the chapter

It was considered in the early years that PSS have a favorable prognosis without glaucomatous damage of optic disk and visual field, however, a number of authors have confirmed that part of the PSS cases suffered from glaucomatous damage similar to that in primary glaucoma patients in recent years. A lot of questions remained vague such as monocular or binocular explode, age of onset, the detailed features of its IOP and KP, the incidence and degree and relating factors of glaucomatous damage, especially the clinical approaches via which the damage occurred and disease complicated with PSS. These brought about to two undesirable consequences: on the one hand, PSS patients were misdiagnosed as primary glaucoma and received incorrect treatment even led to serious adverse consequences due to the lack of knowledge on the clinical characteristics of PSS; on the other hand, most cases of PSS combined with primary glaucoma especially those with primary angle-closed glaucoma were failed to be diagnosed correctly without delay, thus the best opportunity of treatment was lost ; severe damage occurred.

In recent decades, although there were some clinical observations reported by a number of authors on these clinical problems mentioned above, no report of continuous and systematic study was found. A mountain of work in this field had been done in our hospital and some research results were obtained. A brief introduction of our results will be shown in this chapter in combination with the research achievements of other authors.

2. The main results of our clinical research

The main results of our clinical research included 4 fields as follows: the clinical characteristics of PSS; the glaucomatous optic nerve damage in PSS patients; the clinical approach of optic nerve damage in PSS patients; other diseases concomitant with PSS.

2.1. Study on the clinical characteristics of the PSS

The research about clinical characteristics of the PSS included four aspects: clinical observation and analysis of monocular primary open-angle glaucoma(POAG) and binocular PSS; clinical features of elderly PSS patients; characteristics and clinical value of the intraocular pressure and the C-value in PSS patients ; the characteristic of postural intraocular pressure change in PSS patients.

2.1.1. Clinical observation and analysis of monocular primary open-angle glaucoma and binocular PSS

Background: As we knew, most of POAG patients are binocularly involved, while monocular attack is one of typical features of PSS. However, clinically suspected monocular POAG patients are not rare and binocular PSS cases are often reported. So following questions should be put forward based on the facts as follows [3, 11, 14]: Does monocular POAG really exist? What are the differences between monocular and binocularly involved PSS cases? Is there any relationship between the monocular POAG and binocular PSS?

Objects and methods: A long-term, systematic clinical observation and analysis were completed on 121 cases with tentative diagnosis of POAG (22 cases of monocular) and 126 cases of PSS (17 cases of which was binocular). (See figure2)

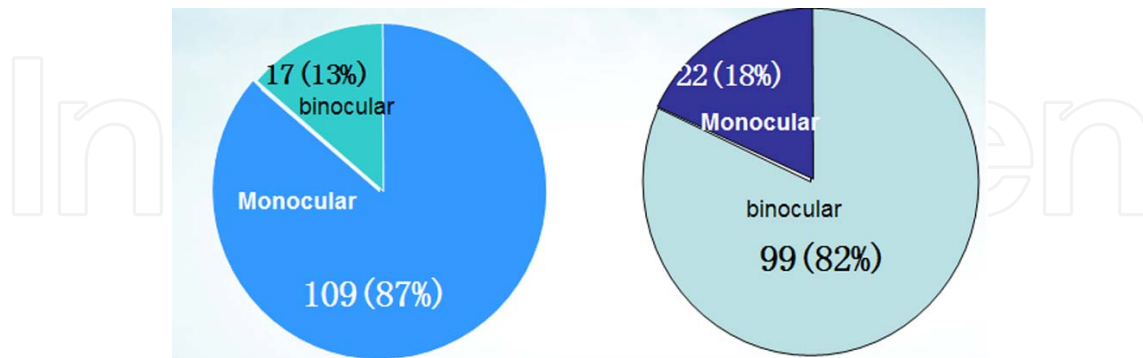


Figure 2. Distribution of monocular and binocular cases in PSS and POAG

Results

1. Glaucomatous visual field damage of monocular/ binocular PSS and binocular POAG

analysis of the clinical data of patients without doubt with the chi-square test showed: (1) The incidence of glaucomatous visual field damage in binocular PSS (15/16) was much higher than that in monocular cases (30/85), ($X^2=27.43$, $P<0.01$). (2) The damage in 26 of 30 monocular cases were in early stage, while that in 9 of 15 binocular cases were in middle/last stage, the difference was significant ($X^2=3.53$, $P<0.01$). (3) There is no significant difference in incidence and degree of glaucomatous visual field damage between binocular PSS and binocular POAG. (See Table 2)

2. Visual field damage in binocular PSS

15 of 17 binocular PSS cases were confirmed with glaucomatous visual field damage, that was much more serious than in monocular cases; however, no remarkable difference was found between the course of disease in monocular and binocular cases. (See Figure3)

The result suggests that the course of disease cannot explain the severity of visual field damage in binocular PSS. We speculate that binocular PSS may be more relevant to POAG essentially through the following two ways. First, the insufficiency in adjusting IOP results in combination with POAG in some cases; secondly, the weak resistance of optic nerve to high IOP make it easy for a cumulative effect of high intraocular pressure during attacks of pure PSS to bring about visual field damage.

2. Results of clinical follow-up to monocular POAG

The results of clinical follow-up observation on the 22 cases with clinically suspected monocular POAG are as follows: 15 of the 22 cases were confirmed not to be POAG, 9 of them had been proved to be PSS. Although no definite diagnoses were made in the other 7 cases, but

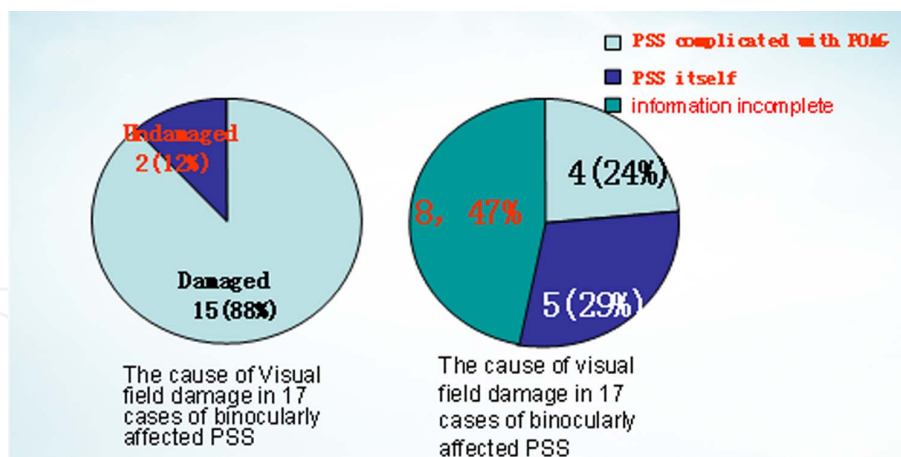


Figure 3. Results of visual field examination and defect in binocular PSS.

clinical manifestations contradictory with POAG were found in most cases, 3 of them were suspected of PSS.(See Figure4)

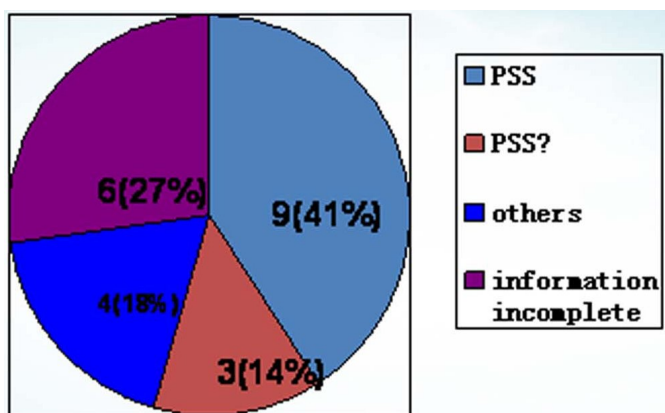


Figure 4. Results of clinical follow-up to monocular POAG.

The result suggests that the diagnosis of monocular POAG should be very careful, in addition to angle closure glaucoma and other secondary glaucoma, PSS which appears late or last transiently should not be ignored. Close attention to slit lamp examination for KP and its relationship with IOP should be paid for such cases.

All in all, it cannot be stated too strongly: we should be very deliberative when making a diagnosis of monocular POAG or binocular PSS, as half part of suspicious monocular POAG cases were confirmed with PSS after clinical follow-up, and there was a closer connection between binocular PSS and POAG. [15]

2.1.2. Clinical observation of aged PSS cases

Background: Among the cases of PSS, the 50s are rare; the 60s are seldom. What is the feature of the aged PSS cases?

Objects and methods: The clinical data of 14 cases aged above 50 with a definite diagnosis of PSS collected in the past 4 years were summarized and analyzed. Clinical data met all the requirements were obtained in 11 cases. The cases aged from 50 to 73 years old, with an average of 61.4 years. One case had a course of the disease beyond 30 years, 4 beyond 10 years and 6 beyond 5 years.

Results: Visual acuity of more than half of the cases was inferior to 0.5, 9 of 11 cases had visual field damage that was of moderate or advanced stage in most cases.

Conclusion: The aged PSS cases had a longer course of the disease and much more frequent and serious visual function damage. [16, 17, 18]

2.1.3. The characteristics and clinical value of the intraocular pressure and the C-value in PSS cases

Background: It is generally acknowledged that IOP of the attacked eye increased and C-value of attack eye decreased in episodes, and both were normal in intermission. Individual author reported that the IOP of the affected eye was lower than that of the fellow one in part of cases, and C-value was higher. It was not confirmed that whether this phenomenon could be considered as the unique characteristic of PSS and what clinical significance should it mean. [3, 19, 20]

Objective and methods: Binocular IOP measurement and tonography were done in 90 cases of PSS; According to the symptom, sign and results of examination for IOP, fundus, visual field, our cases were divided into 3 groups. Group A (typical type): with a normal optic disc, visual field and the diagnostic tests for glaucoma in intermission. Group B (development type): with a damaged optic disc and visual field; except for high intraocular pressure in episodes, binocular IOP and C values were normal. Group C (mixed type): with a damaged optic disc, visual field and abnormal results of binocular IOP, IOP diurnal variation and C value in both episodes and intermission. Another group case of primary glaucoma with a great fluctuation and difference in IOP level between his or her right and left eye was taken as the control group.

Results: IOP of PSS cases in group A and B increased in episodes, and were obviously higher than that of the fellow eye; C-value of them decreased and was lower. In intermission, binocular IOP and C-value turned normal, moreover, IOP of attacked eye was lower than that of the fellow one, and its C-value was higher. It means that binocular IOP and C-value in episodes and intermission were crossed-over.

Crossed-over phenomenon of binocular IOP and C-value had not appeared in the control group (primary glaucoma) as well as Group C (PSS combined with POAG).

Conclusion: Such an inference could be deduced based on our results that Crossed-over phenomenon of IOP and C-value was one characteristic for pure PSS cases, it is conducive to distinguish pure PSS from primary glaucoma and PSS combined with POAG to observe this phenomenon.

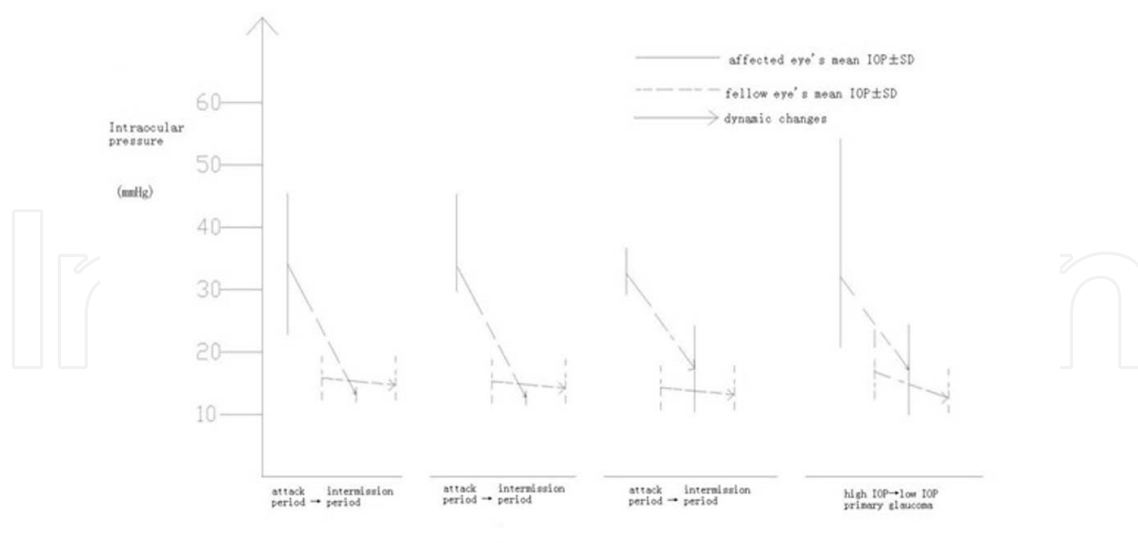


Figure 5. The difference of C-value and its dynamic changes between 3 PSS groups (A, B, C) and primary glaucoma

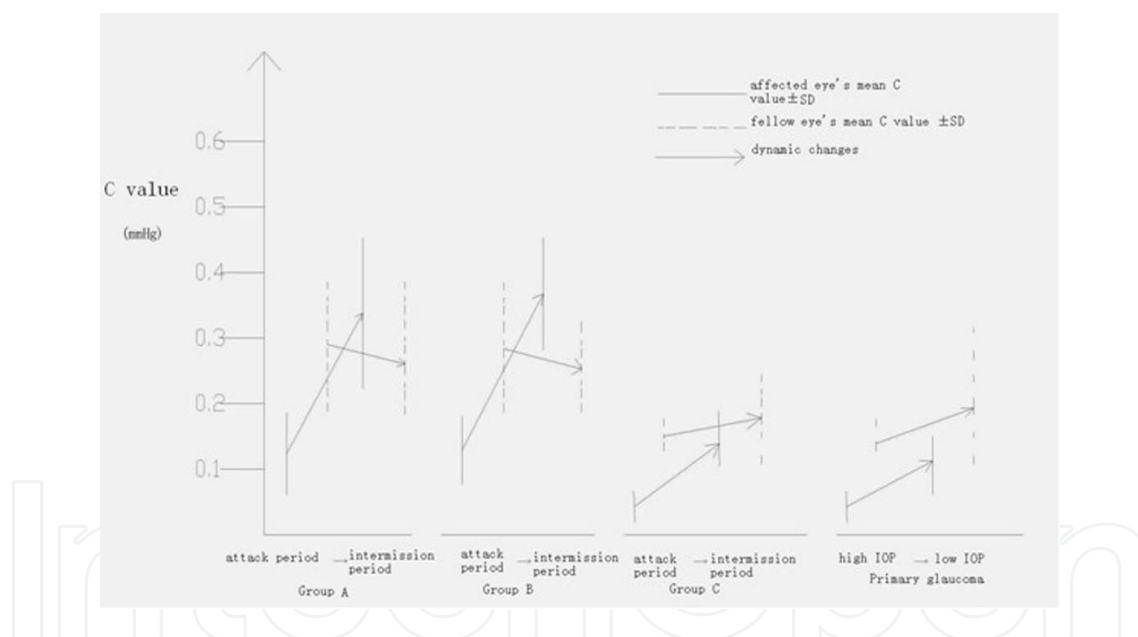


Figure 6. The difference of IOP and its dynamic changes between 3 PSS groups (A, B, C) and primary glaucoma

2.1.4. The characteristics of postural IOP change in PSS cases

Background: It is well known that the recumbent IOP is higher than sedentary one in most of people; however, such an IOP change in PSS cases was not reported so far.

Objective: The cases of PSS with regular IOP change, 42 cases of POAG and 61 cases of PACG with a great wave in IOP level. [21]

Methods: IOP measurement was performed with a handheld applanation tonometer before and after lying for five and thirty minutes, and a tonography was finished 1~3 days before or after postural IOP measurement. (See Figure7)

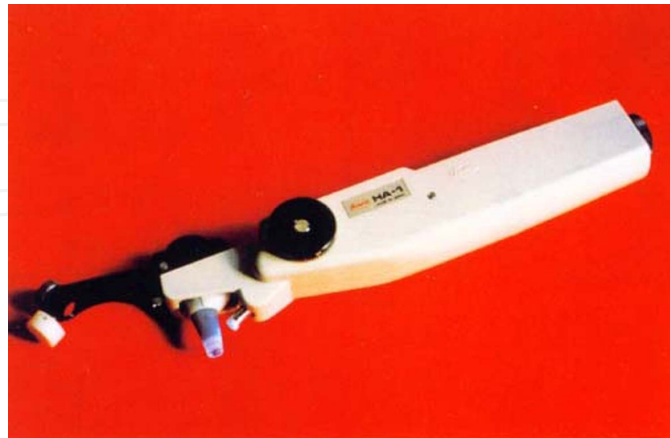

Figure 7. Handheld applanation tonometer.

Results: 1) Recumbent IOP is much higher than sedentary one in cases of all groups, however, their rising degrees after lying were different. 2) There was no significant difference in rising degrees after lying in three kinds of glaucoma when IOP was high; when the IOP turned normal, however, the rising degrees in POAG, PACG were much higher than in PSS. 3) When the sedentary IOP is higher than 24mmHg, the number of cases with recumbent IOP elevated more than 5mmHg in three kinds glaucoma wasn't different statistically; When the sedentary IOP is lower than 24mmHg, cases with recumbent IOP elevated more than 5mmHg were rare in PSS group, much less than that in the other two groups. 4) The IOP increment after lying in the attacked eye of PSS cases in episodes was much higher than that of the fellow eye and the both eye in intermission. 5) The IOP increment was related to C value significantly for POAG when IOP was high and normal, for PACG when IOP was normal only; but wasn't related for PSS no matter IOP was high or normal.

Conclusion: Measurement of postural IOP change is beneficial to diagnose suspicious glaucoma cases with a normal or slightly elevated IOP, it may be as valuable as tonography clinically but more convenient, comfort and safer than tonography, complications such as corneal scratches were rarely seen in the measurement of postural IOP change

Discussion: Different pathogenesis of the three kinds of glaucoma brought about the different pattern in correlation between the IOP increment and C value in different conditions. PACG is caused by the closed anterior chamber angle, when the IOP is high, the increased IOP is related to C value significantly as the closed anterior chamber angle loses the ability to reduce IOP, however, the adjustability recovery as the anterior chamber angle open partly when the IOP is low. Degeneration of trabecular meshwork which result in more and more futile eduction function of aqueous humour was the primary mechanism for the increased IOP in POAG, so the IOP increment in POAG cases is related to C value significantly whenever the

IOP is high or low as the adjustability for IOP had been declining eventually. PSS is a secondary glaucoma for which the intermittent increased release of PGs maybe the primary mechanism. Increases PGs may expand the blood vessels and recedes eduction function of trabecular meshwork. On the contrary, the diluent PGs in remission promotes eduction function of aqueous humour and inturn IOP and C value to normal or even better. Therefore, there is no significant correlation between the IOP increment and C value no matter IOP was high or normal. [20, 22, 23]

2.2. The visual field damage in PSS cases

Although reports about that glaucomatous optical neural damage occurred in some cases of PSS were constantly released for past twenty years, we saw little of the systematic research aimed at the incidence, severity and probable relating facts of the damage. [3, 9]

2.2.1. Incidence and severity of the damage

Objective: To study the incidence and severity of the visual field damage in PSS cases.

Methods: Visual field examinations at regular intervals with perimeter of Goldmann or Humphrey 750 type were completed in 145 cases of PSS followed up for 5 to 15 years and 166 cases of POAG observed meanwhile (as the control). [17]

Results: The prevalence of visual field damage in PSS and POAG was 35.43% and 93.42% ($P < 0.001$), 72.11% of the field damage in PSS cases was of early or suspected stage, 78.92% of that in POAG cases was of middle or late stage ($P < 0.001$), 10% of PSS cases suffered a field damage of middle or late stage, 2 became absolute blind and one case had developed into bullous keratitis at last. (See Figure 8)

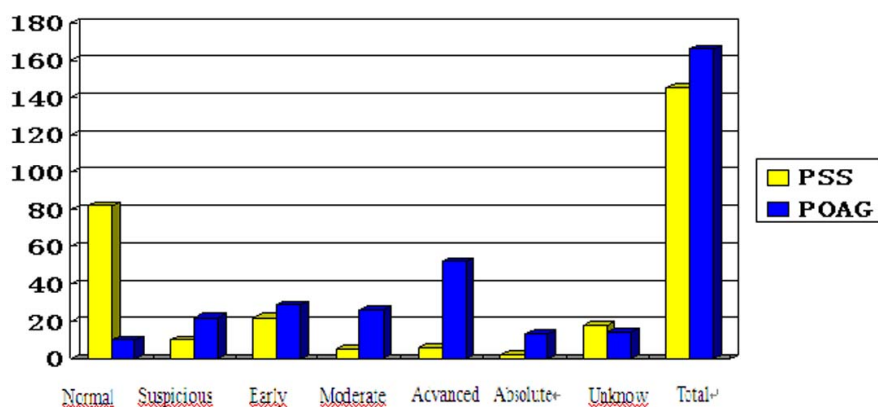


Figure 8. The stage distribution of visual field damage in PSS and POAG.

Conclusions: Even though the visual field damage in cases of PSS was less and slighter than that in cases of POAG, it is necessary to treat PSS efficiently and timely, as recurrent attacks of PSS for long period would result in a sad outcome like POAG.

2.2.2. The characteristic of the visual field damage in PSS

Objective: To study the characteristic of the visual field damage in PSS.

Methods: Compare the visual field damage in glaucoma cases with higher and lower IOP (PSS belongs to that with higher IOP). [24]

Results: 1) The visual field damage in cases with lower IOP is less and slighter than that in cases with higher IOP. 2) Paracentral, arcuate and ring scotoma was more seen in cases with normal IOP, while constriction of visual field and nasal field were more common in cases with higher IOP. 3) Most of the visual field damages in cases with higher IOP come from the periphery. (See Figure 9)

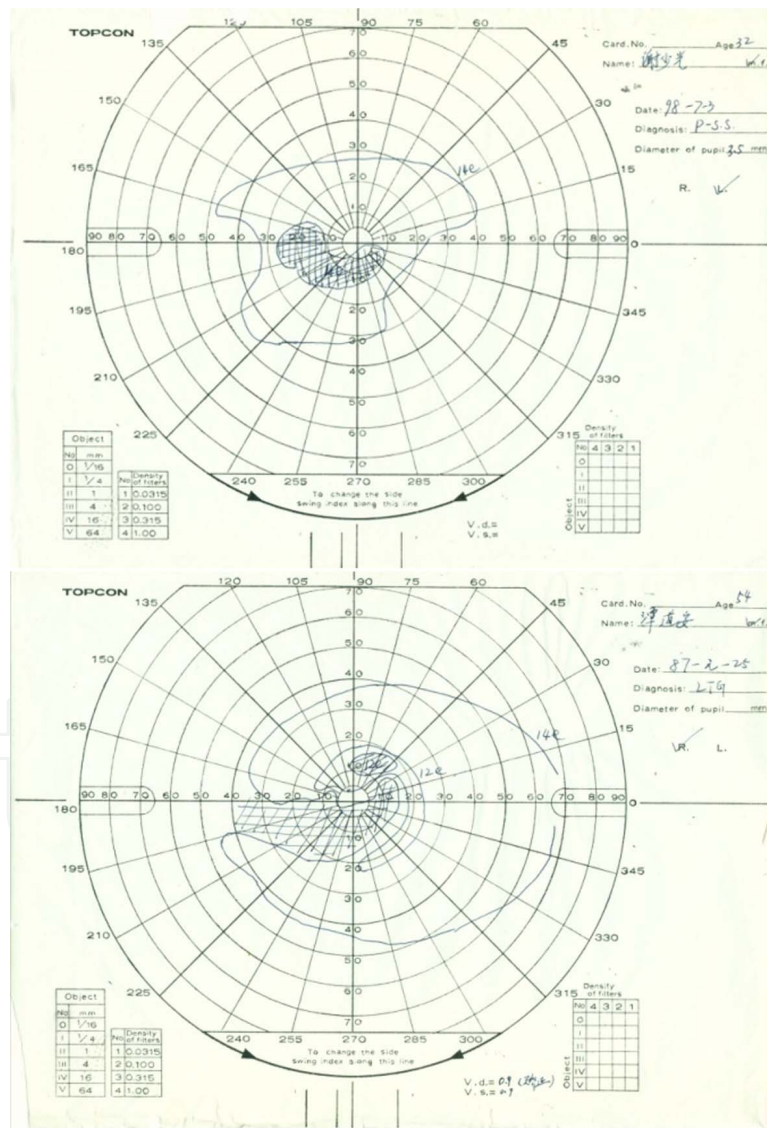


Figure 9. Visual field of a PSS case and a LG case. The visual field damages in PSS case exist in the periphery area(A), on the contrary, those in glaucoma case with normal IOP exist in the centre area(B).

Conclusions: There are difference in visual field defects between higher IOP patients and lower IOP patients.

2.2.3. Relating factors of the visual field damage in PSS

Objective: To study the relating factors of the visual field damage in PSS.

Methods: Analysis the clinical data of 145 PSS cases and 166 POAG cases for recent 15 years. Results about the incidence and severity of visual field damage in the two kinds of glaucoma had been showed above.

Results: 1) Compared with the undamaged group of PSS, the damaged cases were older and with longer course of the disease while there was no remarkable difference in the averaged IOP value during crisis. 2) There was a much higher risk for the visual field damage in binocular cases of PSS. Most of the cases of PSS reported were monocular affected, but later, there were reports about some binocularly affected cases. In our study, 15 of the 35 cases with definite damage were binocularly affected while only one of the 82 cases without damage was affected binocularly. It needs further study to determine whether there is different pathological mechanism for the monocular and binocularly involved cases of PSS. 3) IOP manifestation: although no great difference in the average IOP value during crisis was found between the two groups of PSS, the damage group showed a higher average IOP between crises and included much more cases with an abnormal diurnal and nocturnal variance of IOP or without the IOP crossed-over phenomenon than the undamaged group. These data indicated that the adjustment of IOP between crises was insufficient in those PSS patients with visual field damage. Loss of IOP crossed-over phenomenon meant that other than PSS there were some factors affecting the IOP. [25]

Conclusions: These data indicated that the harmful effect of the raised IOP during crises of PSS on the optic disc could be accumulated.

2.3. The clinical approach of optic nerve damage in Posner Schlossman syndrome

In recent years a number of authors have confirmed that glaucomatous optic nerve damage similar to that in primary glaucoma cases occurred in part of the PSS cases, but the clinical approach of the occurrence was not reported. Clinical data of cases with PSS during a period of 25 years in our hospital was collected and analyzed, and four clinical approaches via which the damage occurred in PSS cases were deduced.

Propose

To investigate the clinical approaches of optic nerve damage in PSS patients.

Methods

208 cases with PSS during the recent 25 years collected in our hospital (male 124 cases, female 84 cases), from 9 to 71 years old, with an average of 39.56 ± 12.80 . Diagnosis standard for PSS was basically accorded to clinical features described by Posner and Schlossman, except for the cases who suffered binocularly or had damage were contained in. [23, 26]

Research project of first diagnosis at the first attendance in our hospital

History, eyesight, intraocular pressure of episode and intermission, depth of anterior chamber, gonioscope or UBM, intraocular pressure during 24 hours in intermission without eyedrops more than five days, panretinal scope or OCT, FFA in episode of part cases, and so on.

Analytical methods

1. Analysis for damage

Standard: repeatable glaucomatous visual field damage and corresponding fundus performance

2. Stage division standard of glaucomatous visual field damage(see Table2)

Without defect	static visual field: no more than 2 clusters of spots with sensitivity reduces more than 5dB, no spot with sensitivity reduces more than 5dB; dynamic visual field: no nasal step and temporal quadrantanopsia more than 10 degrees, no significantly constriction of visual field (except for refractive interstitial lesions and retinopathy)
Early stage	paracentral scotoma, nasal step, temporal quadrantanopsia, arcuate scotoma not linked with physiological blind spot
Moderate stage	arcuate scotoma linked with physiological blind spot, nasal hemianopsia,ring scotoma, constriction of visual field more than 30 degrees,
Advanced stage	tubular visual field
Absolute stage	no light perception

Table 2. Staging standard of glaucomatous visual field defect

3. Classification method

According to the results of comprehensive and dynamical analysis of the clinical data of each cases and classification method as shown in table 3, each case was discriminated for the clinical approach of optic nerve damage. [20,21,22,24,27,28]

	A		B		C		D	
	Early stage	Later stage	Early stage	later stage	Early stage	later stage	Early stage	later stage
Age of onset	middle-aged and aged people		middle-aged and aged people		most middle-aged and aged people		middle-aged and aged people	
Family history of glaucoma	usually not		usually not		sometimes have		most have	
Monocular/ binoculus	monocular		monocular		monocular KP, binocular high IOP or eyes alternate		monocular KP,binocular high IOP	
Typical PSS course	positive	positive	positive	negative	Intermittent attack with binocular high IOP		positive	negative

		A		B		C		D	
		Early stage	Later stage	Early stage	later stage	Early stage	later stage	Early stage	later stage
Episodes	Sick eye	rise	rise	rise	rise	higher	higher	rise	rise
	another eye	normal	normal	normal	normal	high	high	high*/normal	high*/normal
Intermission	Sick eye	normal	normal	normal	rise	high	high	high*/normal	high*/normal
	another eye	normal	normal	normal	normal	high	high	high*/normal	high*/normal
IOP	Cross phenomenon of IOP	positive	positive	positive	negative	negative	negative	positive */ negative	positive */ negative
	IOP of 24 hours in period of intermittent	normal	normal	normal	abnormal	abnormal	abnormal	abnormal */ normal	abnormal */ normal
Anterior chamber depth		normal	normal	normal	normal	normal	normal	A little shallow	Very shallow
Anterior chamber angle		medium width	medium width	medium width	medium width	medium width	medium width	narrow II-III	narrow III-IV

Table 3. Classification method of the clinical approach for optic nerve damage in PSS

Results

1. Incidence and stage distribution of glaucomatous optic nerve damage

190 cases of 208 patients with PSS had a set of complete material. There were 71 cases (34.1%) with optic nerve damage, in which 12 cases (16.9%) regarded as suspicious damage, 59 cases(83.1%) regarded as definite damage.

Stage distribution of glaucomatous optic nerve damage was shown in Table 4:

Early stage	Moderate stage	Advanced stage	Absolute stage	total
35	11	11	2	59
59.32%	18.64%	18.64%	3.39%	100%

Table 4. Stage of glaucomatous optic nerve damage in 59 cases regarded as clear damage

2. The clinical approach of optic nerve damage

Four clinical approaches via which the damage occurred in PSS were deduced, they were represented as Type A, B, C and D.

Type A Cumulative effect of repeated episode of high intraocular pressure of pure PSS leads to visual field damage: 27 cases

Type B Recurrent attacks of PSS which results in secondary trabecular meshwork damage causes secondary open-angle glaucoma: 6 cases

Type C PSS combined with primary open-angle glaucoma: 19 cases

Type D PSS combined with primary closed-angle glaucoma: 7 cases

Composition of the clinical approach in 59 cases regarded as definite glaucomatous optic nerve damage was showed in Figure10

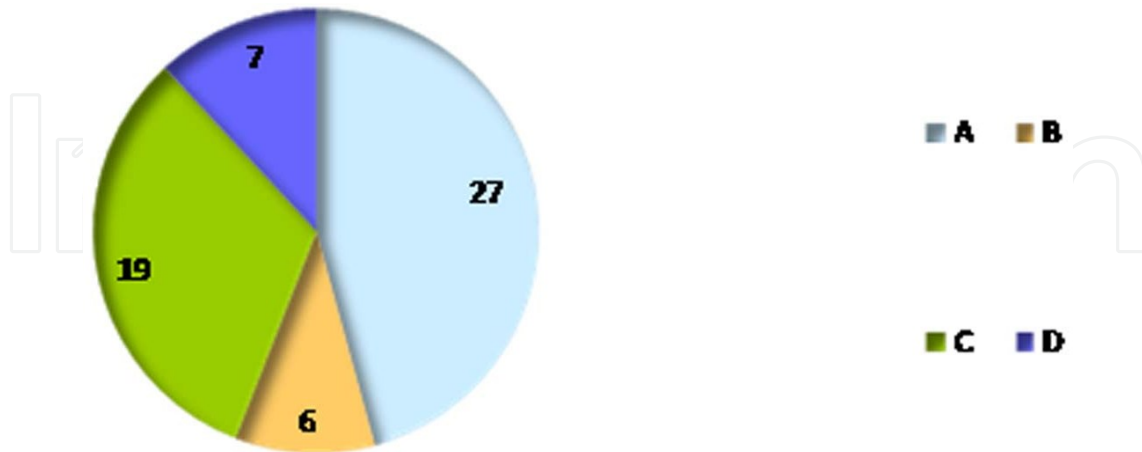


Figure 10. The distribution of clinical approach of optic nerve damage in PSS.

Distribution of stage of visual field damage in different optic nerve damage approaches was showed in Table 5.

	Early stage	moderate stage	advanced stage	absolute stage	total
Type A	17	7	1	2	27
Type B	2	2	2	0	6
Type C	5	7	7	0	19
Type D	2	3	2	0	7

Table 5. Visual field damage in different type of PSS patients

There is no significant difference in the stage distribution of visual field damage in different type of PSS patients. ($X^2=6.904, P>0.05$). Make the early and moderate stage as one group, advanced and absolute stage as another group, Statistical result shows that there is significant difference in the stage distribution of visual field damage in different type of PSS patients. The incidence of early stage of glaucomatous visual field damage in Type A (63%) was higher. While 7 of 19 Type C cases were in advanced stage.

Conclusion: Most cases in type A suffered an early stage damage, and most in other types suffered a moderate or advanced stage damage, but there were 2 cases in type A who had gone to absolute stage.

Discussion

1. The clinical approach of optic nerve damage in Posner-Schlossman syndrome.

In the past PSS was considered to be a self-limited disease and has a favorable prognosis, however, in recent years a number of authors have confirmed that part of the PSS cases suffered glaucomatous optic nerve damage similar to those in primary glaucoma cases, but the incidence, degree, related factors and clinical approach of the occurrence is unknown. This part focused on the clinical approach of optic nerve damage in Posner-Schlossman syndrome after aforementioned researches. Reports about optic nerve damage caused by PSS combined with primary open-angle glaucoma were common; the other types were seldom reported. Systematic research aiming at this question has never been seen so far at home and abroad. We determined the damage approach by analyzing each patient's clinical data dynamically and comprehensively according to the discrimination method established on the basis of relating literatures and the results of our long-term systematic study, and got the conclusion that there were four clinical approaches via which the damage occurred. Beyond all question, further research, supplement and correct is necessary in this field, but the method and result of our study may be a wind vane for the further researches.

2. Clinical features and treatment principle for cases with damage from different clinical approach

(1) Type A Cumulative effect of repeated episodes of high intraocular pressure of pure PSS leads to damage

Clinical features

Except for visual field damage, type A cases complied with the basic characteristics of typical PSS: monocular attacked; intermittently onset of high intraocular pressure with hoar and suet-shaped KP ; normal intraocular pressure(including 24 hours intraocular pressure) of the fellow eye in episode and the both eyes in intermission ; Crossed-over phenomenon and postural changes of IOP; normal anterior chamber depth; wide anterior chamber angle; visual field change of vascular shadow usually appears in episode and recover in intermission at the initial in most cases, and true visual field damage is of mild and early stage usually, but loss of light perception can be seen in a few cases; the attack lasts a long time frequently in middle-aged and aged people for long course, also with higher IOP; heterochromia iridis occurred in later stage in some cases. (See Figure11) [20, 22, 29]

Treatment principle

Enough attention should be paid to treatment for each attack, in which the most important is controlling intraocular pressure timely and effectively. Surgery is necessary for the cases with excessive frequent attacks, heavy damage or obvious progress of his damage.

The surgery method and the time: glaucoma valve or EX-press glaucoma filtration device implantation may be suit for cases with excessive frequent attack, high IOP but light inflammation (intermission or episodes); trabeculectomy could be selected for cases with low attack frequency, high IOP as well as severe inflammation (intermission only).

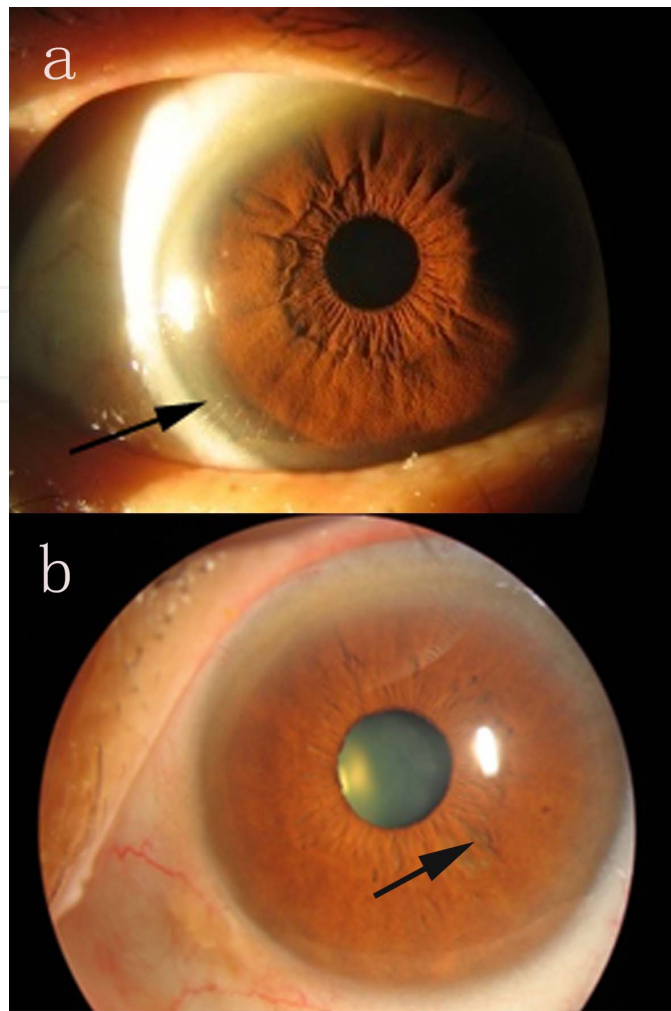


Figure 11. The iris of a PSS patient.(A)is that of the normal eye,(B) is that of the affected eye.

Typical cases 1) A patient visited our hospital and was diagnosed as glaucomatocyclitis crisis of left eye in other hospital six years ago. In the initial stage, she attacked once or twice per year with duration of 3-7 days for each attack and ceased spontaneously, then the frequency of attack increased and the duration extended. This attack happened one month before this visits to our hospital and stop one week ago without use of any drug. Examination at first visit: Vision 1.0(OU), IOP19.7mmHg(R), 12mmHg (L), anterior chambers of both eyes were not shallow, iris color was symmetrical, KP (-).Fundus examination: C/D0.3(R) 0.6(L), there wasn't other abnormalities. She was diagnosed as secondary glaucoma of left eye. On September 13 (10 days after withdrawal), the 24 hours IOP of both eyes were measured: right eye: 14-18mmHg, left eye 12-14mmHg, Corneal thickness: right eye: 584 μ m, left eye: 575 μ m. She was diagnosed as "glaucomatocyclitis crisis in left eye." Another onset lasted for more than 10 days, IOP of the left eye was 43mmHg, there was 2hoar and suet-like KP and faded iris pigment in left eye. There were total seven attacks in one year, with the duration from 1 week to 20 days, during one of which the KP appeared 9day after the occurrence. 24 hours IOP during this episode: right

Eye: 14-19mmHg, left Eye: 23-29mmHg; iris depigmentation of her left eye exacerbated, no abnormal was found with fundus angiography. The recent onset occurred in September this year, the medication of hormone and pranopulin continued for 3 months, with another minor attack during that this period.

She made another visit to our hospital one year later. It was found that the iris of her left eye appeared a typical "rain dozen sand samples", meanwhile, there were two off-white round medium-sized lipid-like KP and she was diagnosed as "left eye glaucomatocyclitic crisis with heterochromatic iris." Since then, the attack occurred more frequently, with frequency of 1 to 2 times per month, the visual field damage exacerbated. She was hospitalized in our department, and the surgery of glaucoma valve implantation was performed. Postoperative intraocular pressure: 19mmHg for her right eye and 6mmHg for her left eye; visual acuity 1.0 left eye (with pin hole) for her both eye, and the syndrome did not attack postoperation. (Clinical data please see Figure 12)

Typical Case 2)

A patient was hospitalized in our hospital for the reason of "intermittent pain of left eye for 25 years, decrease of vision for 20 years, blind for 1 year". The patient had a history of intermittent episodes of pain and blurred vision with his left eye for 25 years, which occurred 1 to 2 times per month with the duration of 3 to 5 days, and then self-cured. In many hospitals he was diagnosed as "glaucomatocyclitic crisis" and treated with medication irregularly. The occurrence becomes more frequently in the recent 10 years, and the duration longer, and the vision recessions gradually. In the intermittent period, he was hospitalized for systematic examination. The visual acuity was 1.0 for his right eye and no light perception for his left eye. All the results of IOP, tonography, 24 hours IOP measurement and other tests during the intermittent period were normal for his both eyes. The result of the medical examination at this hospitalization showed as following: his right eye had a corrected visual acuity of 1.0, IOP 14mmHg, C/D 0.4, wide anterior chamber angle; his left eye had no light perception, intraocular pressure 56mmHg, C / D 1.0, width of N1 ~ N3 for the anterior chamber angle with some small limited adhesions; corneal edema, a dozen of round lipid-like KP.

Without any treatment, the IOP of his fell to 14mmHg within one week. All results of examinations including 24 hours IOP measurement, drinking water experiment, dark room prone test for his right eye were normal. Laboratory results of systemic body check were normal.

His left eye still had attacks of PSS after he left hospital and each attack was self-limited. The IOP and 24-hour IOP during the intermittent period were measured to be normal, and his left eye had an IOP lower than that of his right eye, a typical IOP cross phenomenon appeared every time. Three years later, the fundus and visual field of his right eye kept normal. (Clinical data see Figure 13)

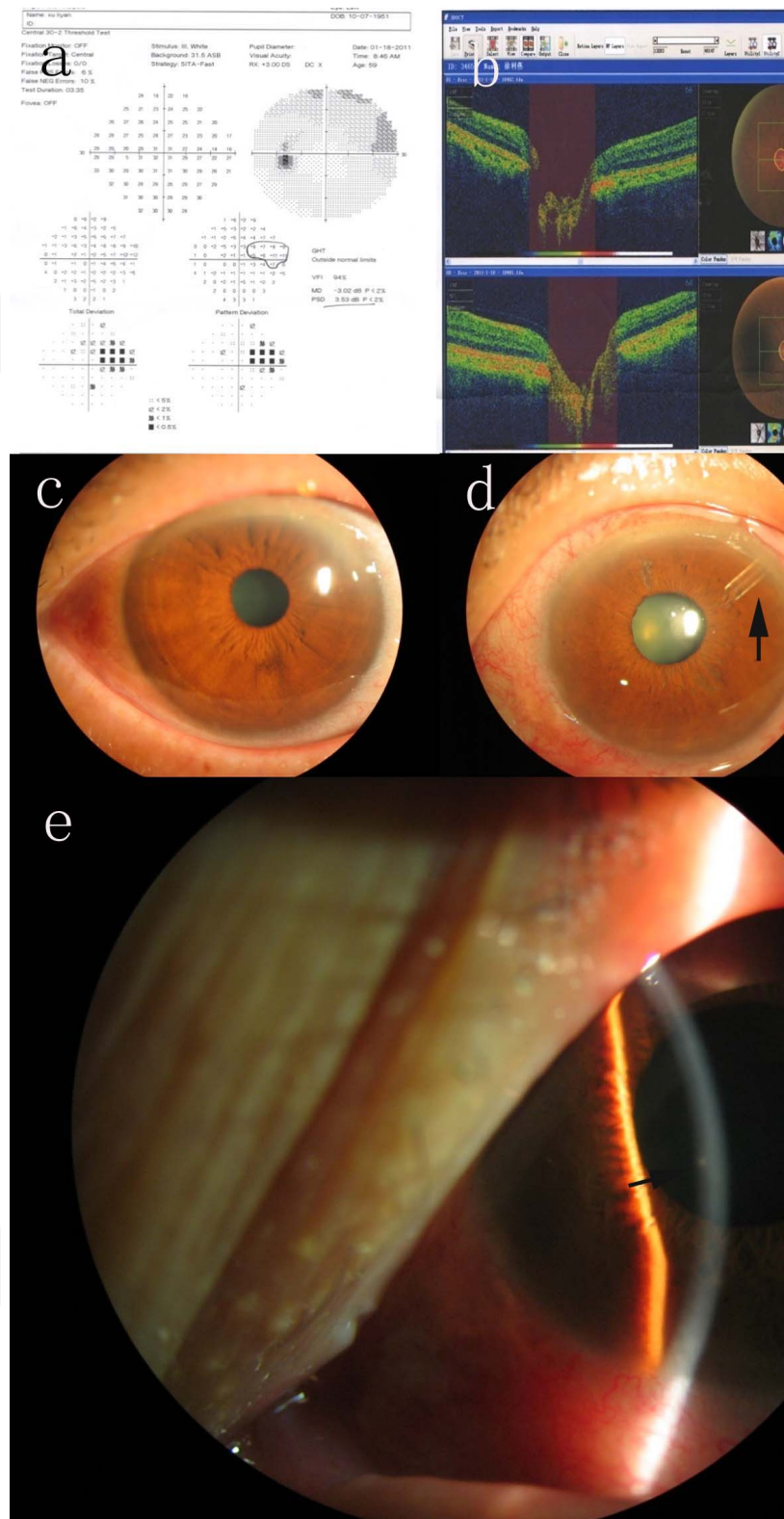


Figure 12. Clinical data of a cases suffered from PSS with glaucomatous optic nerve damage combined with heterochromia iris (Clinical number 488368). Visual field (A) and Optical Coherence Tomography (B) indicate glaucoma damages; Anterio segment of normal right eye(C) and left eye(D), arrow shows heterochromia iris and KP in the attacked eye(E).

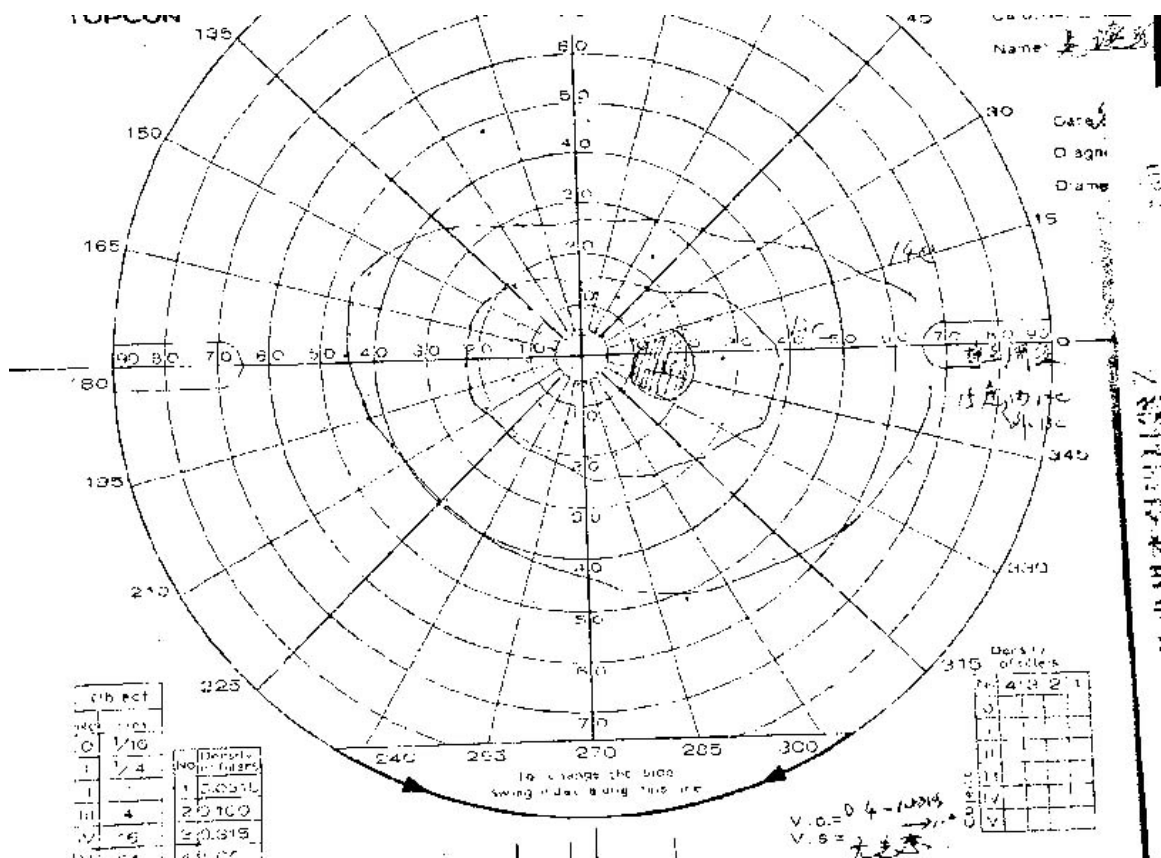


Figure 13. Visual field of the right eye of patient (Clinical number 241163). PSS results in blind of his left eye, but the visual field of his right eye without PSS is normal.

(2) Type B secondary open-angle glaucoma from secondary damage to trabecular meshwork by recurrent attacks of PSS

Clinical features

Type B cases complied with the basic characteristics (above mentioned) of typical PSS in early stage. These characteristics lost eventually as the damage to trabecular meshwork gradually accelerated, the attack takes place more frequently and lasts a longer and longer time with a higher and higher IOP, and serious visual field damage developed at last.[30, 31] However, the fundus, visual field, IOP in intermittent and episode of the fellow eye maintained normal. Patients of this type usually had a long course of the disease with an older age.

Treatment principle

It is necessary to reduce IOP with drugs according to extent and characteristics of elevated IOP and diminish inflammation with hormone of weak effect on elevating IOP for short time, for example, lotemax. PGA is useful and myotic is prohibitive. Surgery or other treatment (SLT, trabeculectomy, glaucoma valve or EX-press implantation) should be taken into account according to the IOP level controlled by drugs in intermittent and the situation of visual field damage.

Typical case

A patient was diagnosed as “left eye PSS” with the complain of vision decline associated with distending pain of his left eye in other hospitals five years ago. The medical records of other hospitals showed: IOP and other relating examinations of the right eye in episode and these in intermittent period of his both eyes was normal at the initial stage. The visual acuity decreased gradually, IOP fluctuated from 32 to 48 mmHg in recent years. He was hospitalized in our hospital three times, the results of clinical observation showed: IOP including 24 hours IOP in intermittent period, the fundus and visual field of his right eye appeared normal; while IOP of his left eye was high frequently and higher when PSS attacked, 24 hours IOP in intermittent period appeared abnormal including the highest IOP and IOP variation. The left eye was diagnosed as secondary open-angle glaucoma from secondary damage to trabecular meshwork by recurrent attacks of PSS, and then a trabeculectomy was performed on his left eye. Postoperative IOP of his left eye was from 12 to 10mmHg in intermittent period, 20 to 31 mmHg in episodes, while his right eye kept normal in all ways. (Clinical data see Figure 14)

(3) Type C PSS combined with primary open-angle glaucoma

Clinical features

Monocular/ binocular paroxysmal increased IOP with mild cyclitis; wide anterior chamber angle; binocular abnormal IOP and visual field damage; high average IOP; great fluctuation of IOP level; absence of IOP cross phenomenon; PSS attacks at the same eye in most cases; at the two eyes alternately or at the same time in a few cases; visual field damage was serious, and more serious in the eye often attacked by PSS.[27, 32]

Treatment principle

Enough attention should be given to the treatment for cases of this type, whose incidence reached up to 31% as reported. Drug treatment is similar to that of POAG, but in episode of PSS, corticosteroid is useful transitorily, while PGA and myotic is prohibitive. Indication of surgery is similar to that of POAG, but classical trabeculectomy should be performed in intermission, and the effect and safety of non-penetrating trabeculectomy, implantation of Ahmed glaucoma valve or EX-PRESS Glaucoma Filtration Device has not been confirmed. Laser trabeculoplasty(ALT), Selective laser trabeculoplasty (SLT) or Pneumatic trabeculoplasty (PNT) should be adopted in intermission, however, there has no related report. [11, 33, 34, 35]

Typical cases

A patient reported of discomfort and blurred vision of her left eye for more than 1 year, the patient was diagnosed as POAG in other hospital 10 days ago. Clinical date of that time showed: KP (-), IOP16.3/42.7(R/L), and she was treated with Travoprost Eye Drops to her left eye and brimonidine and brinzolamide to the both eye. 1 week after treatment, her IOP turned to 36/17(R/L), the treatment had been changed to travoprost, brimonidine and brinzolamide for the both eye. The results of examination in our hospital showed as follows: visual acuity R1.0 (-1.25DS),L0.05(-3.75DS), IOP17(OU); absence of conjunctiva hyperemia; cup/disc ratios 0.8 OD and0.9OS,and inferior RNFLD(by OCT:) in the both eye; severe glaucomatous visual

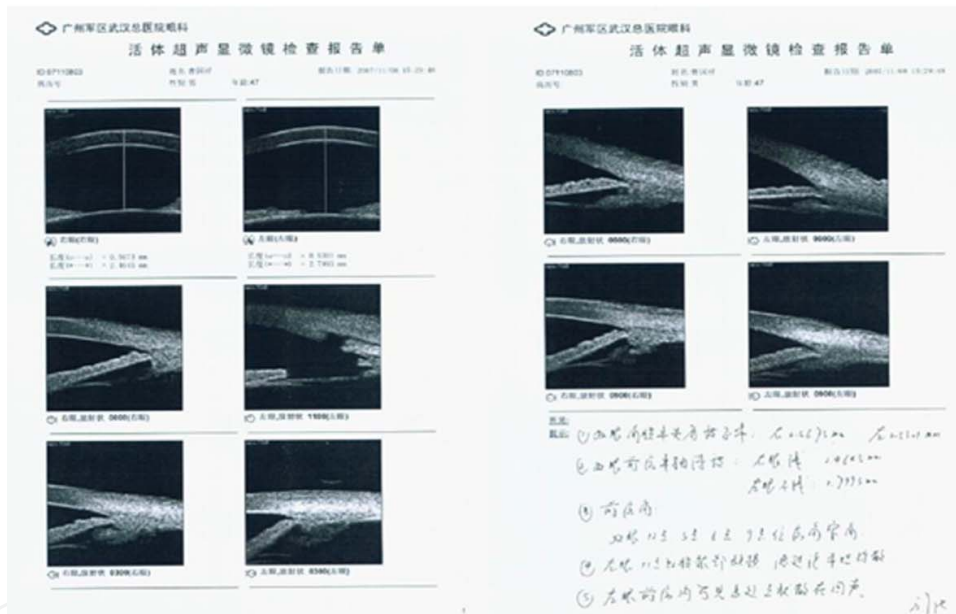
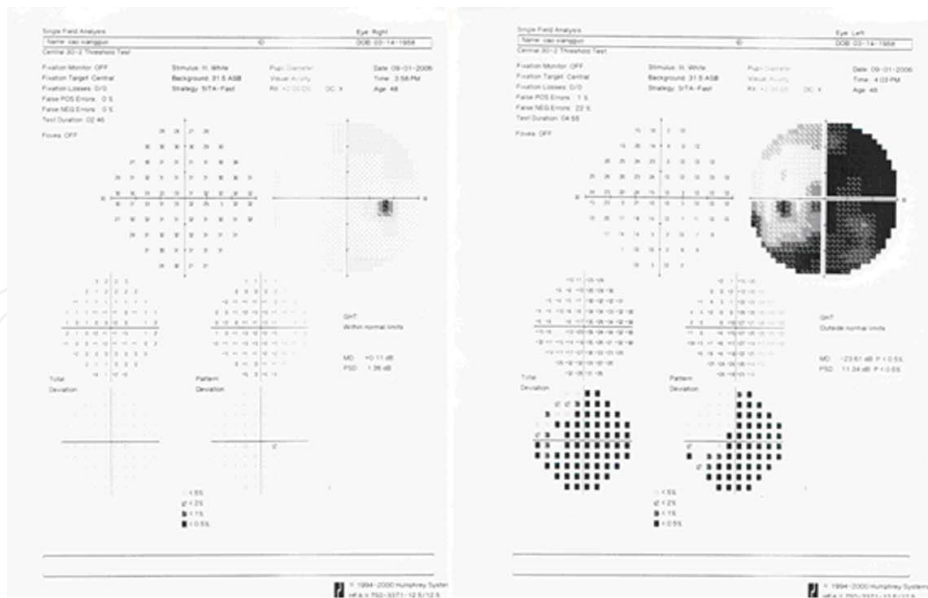


Figure 14. Clinical data of a patient suffered from PSS with glaucomatous optic nerve damage due to secondary open angle glaucoma (Clinical number 813064). Normal visual field in right eye(A) and advanced visual field defect in left eye (B);UBM shows the normal right eye and the affected left eye post-operation(C).

field damage in both eye, extended latent time and descended amplitude on VEP; CCT:540/520 (R/L),corneal endothelium cells 1730/2747(R/L); center anterior chamber depth ≥ 3.0 mm and open anterior chamber angle in every direction for the both eye by UBM. She was diagnosed as binocular POAG, and treated successively with travatan, alphagan and brinzolamide to binoculus, but her IOP was not controlled well. Thus, a trabeculectomy was performed the left eye. Two weeks after the operation, the filtration bubble turned fibrosed, and IOP increased. By 3 times of pin-delamination with 5-fluorouracil and eyeball massage, IOP was controlled

on 12 to 14 mmHg. Her right eye was treated with travatan, carteolol hydrochloride and brimonidine, IOP was controlled from 12 to 14 mmHg. She was discharged from hospital. Four months later, the right eye appeared 5 small rounds and mutton-fat like KP, IOP increased to 19mmHg. A week later, KP played down, IOP descended to 12 mmHg. A month later; KP appeared again, IOP increased to 37, after treatment in hospital for a week, the IOP decreased to 12 mmHg. She was diagnosed as POAG combined with PSS. Two months later PSS of her right attacked again, IOP increased to 44 mmHg; visual field damage has progressed remarkably. FFA showed optic atrophy without any other abnormal. She was hospitalized again, and a implantation of Ahmed valve to her right eye was done on the next day. During the operation, the valve appeared out of control; we dealt it well with removable restraint line processing; the IOP and anterior chamber stability was controlled. 2 month after the operation, the IOP increased to 22 mmHg because of the draining disc was packaged. By pin-delamination and eyeball massage, IOP was controlled near to 20mmHg. Carteolol hydrochloride was added and the IOP was controlled well in intermittent, but PSS attacked frequently and the IOP was out of control during episode. She was hospitalized once more and the right eye was treated with no-penetrating glaucoma surgery. One month after surgery, the IOP was controlled well, binocular IOP was 10mmHg. 2 month after surgery, PSS attack was seen in her right eye again, IOP increased to 20 mmHg. This attack faded a week later and IOP of her both maintained 14mmHg below until now. (Clinical data please see Figure 15)

(4) Type D PSS combined with primary closed-angle glaucoma

Research status

Except for our data, there had been only two individual reports about PSS combined with PCAG in China and none in abroad. Cases of PSS combined with PCAG at home are much more than those in abroad due to the higher incidence of PCAG as well as PSS at home. In 2004 we reported 6 cases and completed a systematic clinical analysis. It was often reminded by many ophthalmologists that cases of PSS had be mistaken as PACG, but enough attention has not been paid to this type of PSS. [18, 28, 36, 37, 38]

Clinical features

There is a typical history of PSS attack with binocular shallow anterior chamber and narrow or closed anterior chamber angle. PSS hardly attacked synchronously with PACG, the anterior chamber angle is open in episodes of PSS. Type D cases complied with the basic characteristics of typical PSS in early stage: binocular IOP is normal in intermission; with cross phenomenon of IOP; however, when PACG became more advanced, although the IOP of the PSS attacked eye was much higher than that of the unattacked eye in the episode of PSS, binocular IOP turned higher than normal even in intermission of PSS without obvious cross phenomenon. Most cases were diagnosed as PACG previously, PSS appeared after the treatment for PACG had been completed and the anterior chamber angle been opened, a few cases were typical PSS with narrow anterior chamber angle when they were young; PACG appeared as anterior chamber angle became narrower and narrower with age. Most of the cases of this type were elder with a longer course of PSS and a more advanced visual field damage.

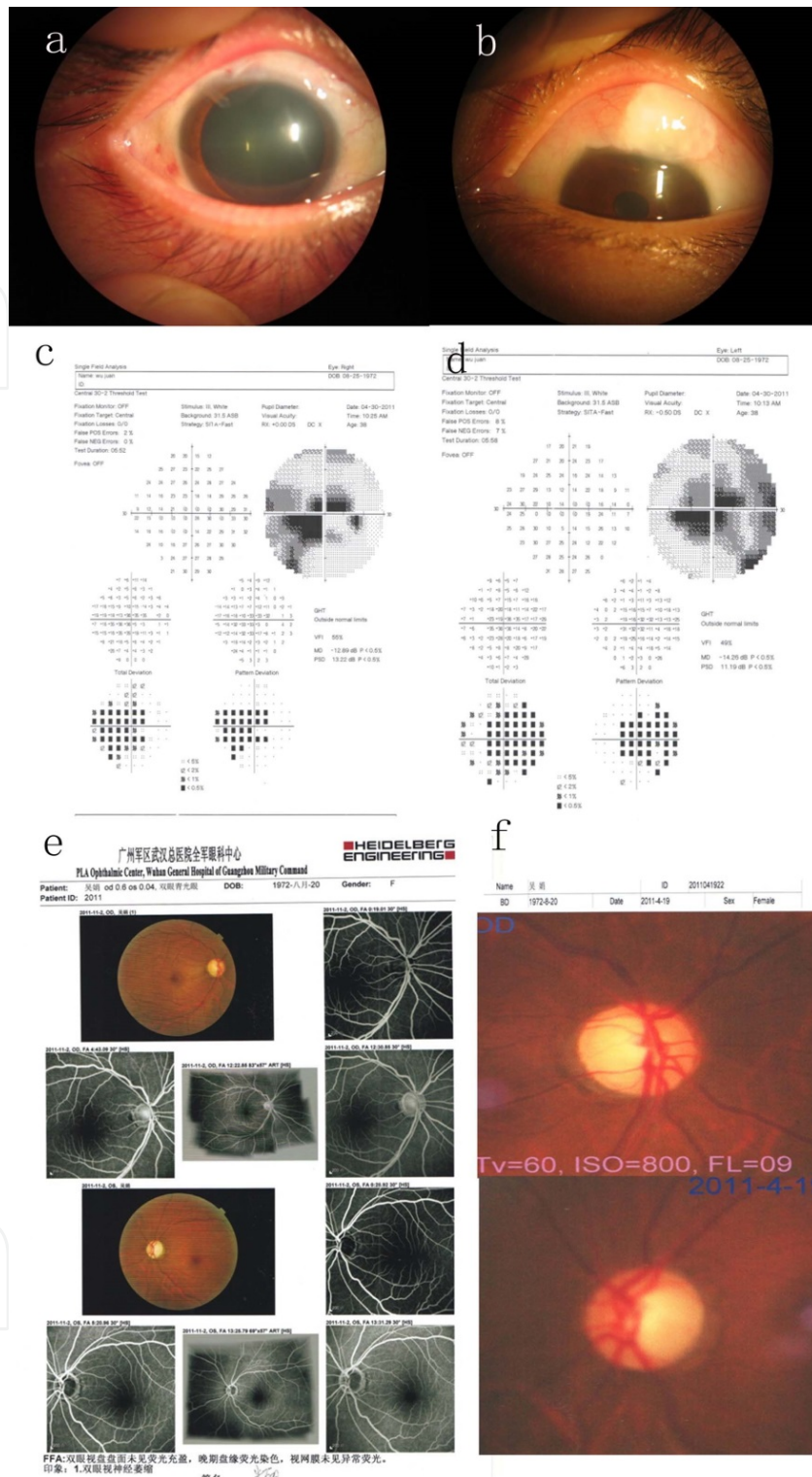


Figure 15. Clinical data of patient suffered from PSS(right eye) with glaucomatous optic nerve damage combined with POAG(both eye),the right eye is treated with Ahmed value implantation surgery(A),the left eye is treated with normal trabeculectomy(B), visual field of right eye(C) and left eye(D)show typical glaucoma damages,the fundus angiography indicates no vascular disorder except of optic atrophy(E) and the optic cups of right eye and left eye are non-symmetrical.

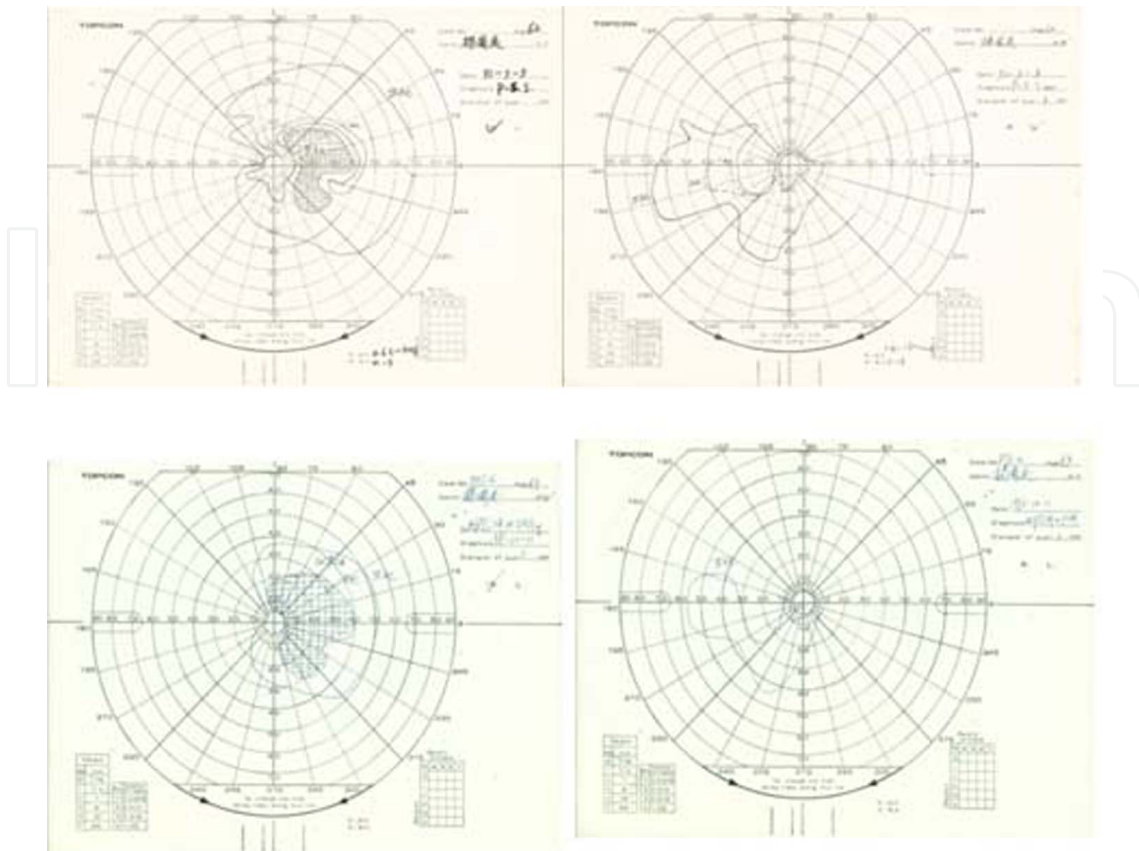


Figure 16. Visual field of patient (Clinical number 232036) with binocular PSS combined with POAG. After drug treatment, the damage of binocular visual field between 1991(A) and 1998(B) has no significant advance.

Diagnosis standard

The first is that the anterior chamber angle is open when PSS is diagnosed at episode, either in the intermission of PACG or after PACG was treated with Laser/surgery/drug; the second is that the cases complied with the basic characteristics of typical PSS described by Posner-Schlossman. In our study, 2 cases was diagnosed as PSS at a younger age with binocular narrow anterior chamber angle (first was narrow II, narrow III-IV four years later), 5 cases was diagnosed as PSS after treatment of PACG (similar to the two cases reported at home).[28, 39]

Diagnostic summary

To find out PACG complicated with PSS as soon as possible, it is necessary to carry out a set of comprehensive and careful examinations relating to PACG in the intermission of PSS for PSS patients with factors as follows: the old-aged, with a serious visual field damage, longer course of the disease, with a shallow anterior chamber or an narrow anterior chamber angle, and binocularly attacked.

When IOP appeared as repeated, intermittent and sudden elevation in a patient with PACG whose anterior chamber angle had been opened and the IOP been controlled well for a period after treatment by means of laser and/or surgery and/or drugs, it is very important to pay sufficient attention to the depth of the binocular anterior chamber and anterior chamber angle

when the IOP is higher, and to make clinical follow-up observations for KP and its relationship with IOP, so as to ascertain whether PSS is the cause of elevating IOP, so that unnecessary surgery can be avoided.

Treatment principles

According to condition of PACG, laser and/or surgery and/or drugs may become options.

Laser treatment:

1. Indications of that for cases of PSS combined with PACG is similar to that PACG patients, except for that examination and treatment should be done in the intermission of PSS;
2. Curative effect on cases with typical cross phenomenon of IOP should be better;
3. The iris surrounding excision mouth by laser must be thoroughly penetrated and the hole should be big enough;
4. Corticosteroids and drugs for reducing IOP should be sufficient after laser operation;
5. It is import to pay attention to the treatment for PSS which continue to attack after laser therapy, and to the monitor of IOP and its dynamic change. Additional drug treatment even trabeculectomy should be adopted timely when necessary;[27]

It is necessary to prevent the attack of PACG in either episodes or intermission of PSS for these untreated PACG cases with the appropriate use of miosis drug.

Typical cases 1)

A patient was diagnosed as "PSS" in our hospital because of pain and discomfort of his right eye, then he was diagnosed as "acute angle-closure glaucoma " in other hospital because of severe sore of his both eyes and switched to our hospital after remission seven years later.

Examination revealed mutton-fat like KP in the right eye. His right eye was diagnosed as PSS combined with PACG with analysis by synthesis combining history and test results of IOP, fundus, visual field and anterior chamber angle. The right eye was treated with "glaucoma drainage surgery" and the left eye with "YAG laser iridectomy ".

IOP of his both appeared stable for six months after operation, then the right eye was attacked by PSS once again. This attack of PSS appeared as typical KP, open angle and slightly increased IOP. (Clinical data please see Figure 17)

Typical cases 2)

A patient came to our clinic because of "repeated intermittent attacks of eye pain and impaired vision for her left eye and right eye as well for more than 14 years". She was treated with YAG laser iridotomy in other hospital for PACG binocularly twice each. Her left eye had been still attacked intermittently ever since. Clinical date from her medical record showed that KP and IOP rising appeared nearly simultaneously on each episode and the IOP turned persistently higher than normal even if in intermission since 2 years ago and the drugs could not control the IOP well. Examination at this time showed: Vision R 1.0, L 0.4; IOP R 14 mmHg and L 46

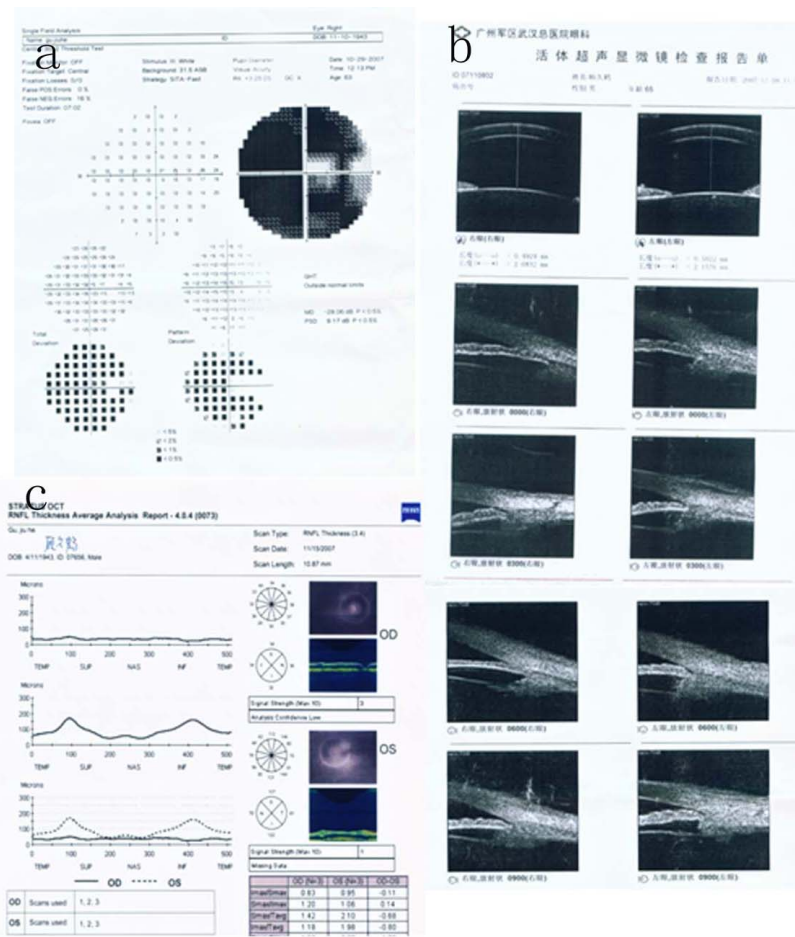


Figure 17. Typical clinical data of patient (Clinical number :406013)with diagnosis of right PSS combined with binocular PACG and treatment with classical trabeculectomy.The visual field show advanced glaucoma damage (A),OCT(C) also shows retinal nerve fiber layer defect.UBM indicate binocular closed angle(B).

mmHg; two mutton-fat like KP in the left eye ; shallow anterior chamber and angle multiple adhesions in both eyes; several trace of laser therapy on iris of her both eye, the only peetrated hole on the right eye be covered with fibrous membrane, and that on the left eye be too small; cup/disc ratios R 0.4and L 0.8.A diagnosis of “binocular PACG complicated with PSS in left eye” was established. A complementary laser therapy was given to her right eye just at that moment; after this laser therapy, her right had been kept well until now with only the help of 2% Carteolol Hydrochloride eye drops twice a day. Three weeks later, when this attack of PSS faded away, she was hospitalized in our hospital, and a trabeculectomy was performed on her left eye, and she was discharged 10 days after a IOP of 14mmHg. Six weeks after the surgery, an attack of PSS occurred with a IOP of 32mmHg and lasted a week; such attack occurred once or twice a year after that with a maximal IOP of 25mmHg. The IOP in intermission had maintained near 15mmHg during the first 4 years, but the result of 24h IOP measurement showed 13~20mmHg in the right eye and 15~24mmHg in the left eye. Iris heterochromia appeared in the left eye. Such a therapeutic schedule was established and kept 3 years since then: 2% Carteolol Hydrochloride Eye Drops twice a day to the both eye in intermission of PSS; 2% Carteolol twice a day plus brimonidine 3 times a day with shortly use of Lotemax for

the left eye during episode of PSS. IOP of the both eye maintained 15mmHg or below, and the visual field maintained stable in the 3 years. Several attacks of PSS had been recorded with a IOP up to 40mmHg, and her visual field turned worsen, and “rain dozen sand-like” appearance in the iris of her left eye got more pronounced in the last 2 years. She was hospitalized once more, and another trabeculectomy was performed on the left eye near the first one, at the end of which the two filtering blebs (an original and a just manufactured) were merged into one. She was discharged with an IOP of 12mmHg; the left eye was no longer attacked after this trabeculectomy, and the IOP kept stable. (Clinical data see Figure 18)

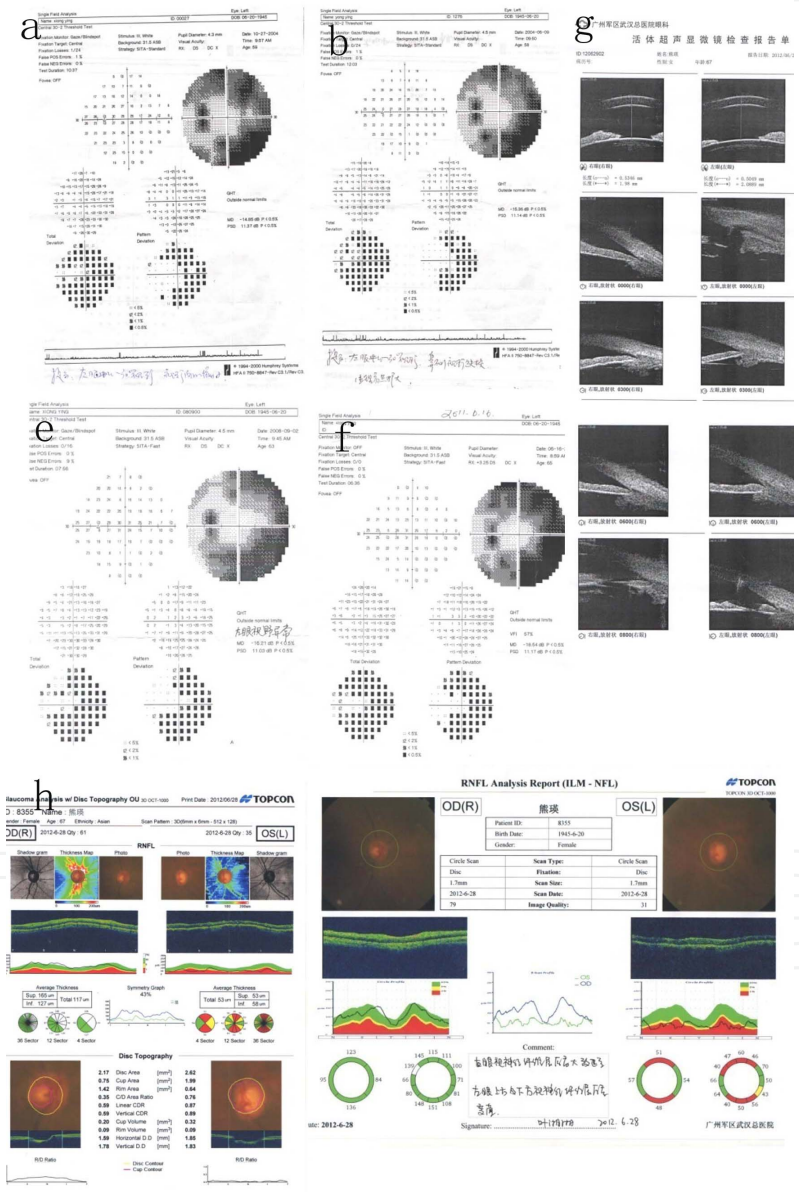


Figure 18. Typical clinical data of patient (Clinical number :341555) with diagnosis of left PSS combined with binocular closed-angle glaucoma. The visual fields of right eye(A) and left eye(B) become worse 4years later(C) and (D),UBM indicate binocular aqueous humour outflow after the 1 st trabeculectomy(E) and the OCT results show serious retinal nerve fiber layer defect in left eye(F).

3. Differential diagnosis and main points in diagnosis and treatment of complications of PSS

On the one hand, PSS is often misdiagnosed as other diseases, other diseases are often misdiagnosed as PSS; on the other hand, PSS can also be merged with or cause other diseases. Although the differential diagnosis of these conditions is complex, but we should be able to complete the work well through a careful clinical observation and analyzation rely on the basic characteristics of PSS described by Posner and Schlossman and new discoveries introduced above.,,.

3.1. The differential diagnosis of PSS and other diseases.

3.1.1. Analysis the situation of misdiagnosis

There were a total of 37 articles about misdiagnosis of PSS among the domestic documents about PSS since 1990. Here are the results of our analysis of these documents.

1. Other diseases misdiagnosed as PSS

There were 5 cases in which Fuchs syndrome was misdiagnosed as PSS, in 5 cases viral keratitis misdiagnosed as PSS and in 4 cases acute retinal necrosis misdiagnosed as PSS.

2. PSS misdiagnosed as other diseases

There were 76 cases of PSS misdiagnosed as acute angle-closure glaucoma, 42 misdiagnosed as iridocyclitis, 42 cases misdiagnosed as primary open-angle glaucoma, 22 cases misdiagnosed as uveitis, 4 cases misdiagnosed as conjunctivitis, 4 cases misdiagnosed as Fuch's syndrome, 1 case misdiagnosed as high intraocular pressure and 1 case misdiagnosed as keratitis.

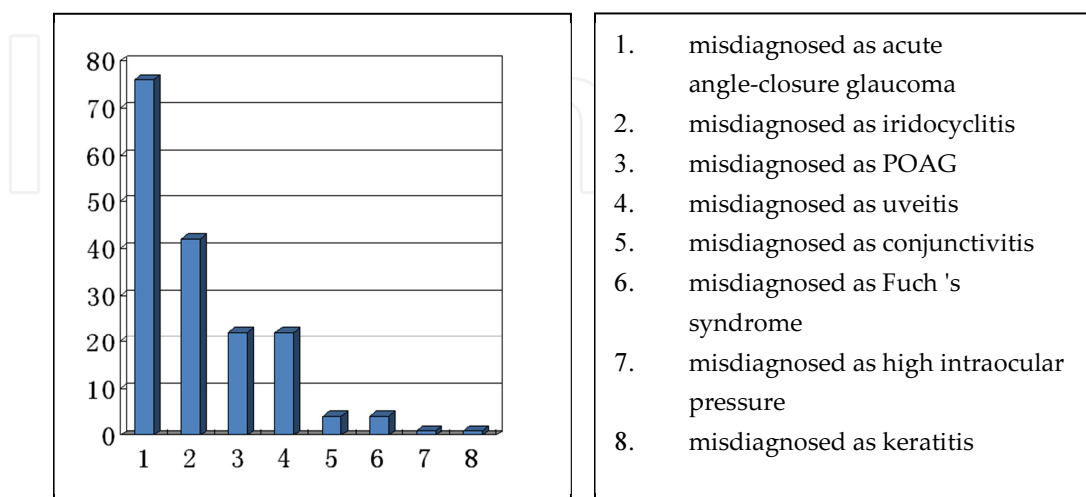


Figure 19. Number of cases of PSS misdiagnosed as other diseases

3. About the harms of misdiagnosis for the patients. PSS patients were misdiagnosed as primary glaucoma and inappropriately treated, even the surgery that should not be done had been performed. Primary glaucoma merged with PSS were missed diagnosis, result in the lost the optimal timing of treatment. Such diseases as Fuch's syndrome, acute retinal necrosis and viral keratitis were misdiagnosed as PSS, lead to the delay of treatment.

	PSS	POAG	PCAG
age at first onset	usually under the age of 50 years	middle-aged or older	
KP	Yes, accompany with elevated IOP	No	pigmented KP sometimes after a outburst
Anterior chamber angle			or closed
Affected eye	most	most binocular	binocular, usually
Visual field damage	Little and light, more began in the peripheral, usually	usually binocular and centrally located	more binocular, often irregular
IOP	In episodes the is normal, in intermission both eyes are normal	invariably	Invariably or paroxysmal
IOP cross	Yes	No	No in chronic cases, Yes in acute cases sometimes after an outburst
postralar IOP change	Not related to C value no matter IOP is high or low	Related to C value no matter IOP is high or low	Related to C value only when IOP is high

Table 6. The key points about differential diagnosis between PSS and POAG or PACG

3.1.2. The differential diagnosis of several kinds of common diseases

1. The differential diagnosis of PSS and other glaucoma. The differential diagnosis between PSS and POAG or PACG can be carried out in reference to table 7. [23 24, 27, 28, 40]
2. The differential diagnosis of PSS and other uveitis

The characteristics of common uveitis

Iridocyclitis: Ciliary hyperemia, eyesight drops significantly, smaller KP, aqueous humor of turbidity, fast and heavy adhesion of iris, higher or lower IOP.

Choroiditis: significantly dropped vision, with or without KP, vitreous of turbidity, no iris adhesion usually, lower IOP, corresponding pathological changes in retinal and choroiditis.

All uveitis: ciliary hyperemia, significantly dropped vision, KP in most cases, muddy aqueous humor, vitreous of turbidity, fast and heavy adhesion of iris, higher or lower IOP, corresponding pathological changes in retinal and choroiditis.

Intermediate uveitis: a kind of uveitis limited in the pars plana of ciliary body, peripheral retina and vitreous base, without any clinical symptoms in some cases or with muscae volitantes, blurred vision and temporary myopia in most cases, normal or mild declined vision in most cases but significant vision loss in case with cystoid macular edema and other

complications or sudden severe vision loss in case with acute vitreous hemorrhage, retinal detachment,, mild to moderate anterior segment inflammation in most cases but severe ciliary hyperemia, a large number of KP, obvious aqueous flare and a lot of inflammatory cells in the anterior chamber in a few cases at first onset with severe anterior segment reaction occasionally, change in the vitreous and the pars plana of ciliary body (the most common and important performance of the disease) such as vitreous inflammatory cells, snow ball turbidity due to cell agglutination, snowbank like lesion stretches from the pars plana and vitreous base into vitreous cavity, vitreous degeneration, hemorrhage and hyperplastic vitreous retinopathy at late stage, a variety of retinopathy, such as macular edema, diffuse retinal edema, retinal vasculitis and perivascular inflammation, exudation, hemorrhage, retinal neovascularization, hyperplastic retinopathy, retinal detachment, usually normal IOP in early time but a persistent high IOP once elevated, sporadic KP with no association with IOP.

3. The differential diagnosis of PSS and keratitis

Keratitis

Sign Obvious hyperaemia, matrix and endothelial change, KP with different forms mainly distributed in lesion site of the cornealand seldom inhealthy area.

Characteristics The eye with angle-closure glaucoma induced by keratitis have the basic characteristics of angle-closure glaucoma; A monocular open-angle glaucoma would occurred in the affected eye if keratitis spread to the trabecular meshwork with an intraocular pressure changes over the cornea edema.

Course of disease:They are not self-limited and repeated outbreaks tend to occur.

3.2. Main points in diagnosis and treatment of complications of PSS

Other kinds of glaucoma which PSS concurred with or lead to were not introduced before. PSS can also concur with or cause iris heterochromia, ischemic optic neuropathy, complicated cataract and other diseases, such as retinal detachment. Main points in diagnosis and treatment of these complications were briefly introduced as follows:

3.2.1. PSS combined with iris heterochromia

Typical cases

Case 1) A patient consulted at our hospital because his left eye suffered from intermittent recurrent pain and blurred vision for more than one year. Intraday examinations showed: best corrected visual acuity is 1.0/0.6(R/L), IOP: 16.7/ 13.7(R/L) mmHg, FFA in both eyes are normal, optic cup in his left eye is expand. He was suspected of glaucoma. Intermittent recurrent pain and blurred vision kept to attack his left eye for more than half a year after then. These attacks usually ceased a few days late, with or without the help of 0.5% timolol eye drop and other drugs. During this period, the highest IOP record of his left eye was 35mmHg with a normal record of his right eye. The patient returned to our hospital one year later after stopping use of any drugs for two weeks. Ophthalmologic examination at this time showed: visual acuity1.2

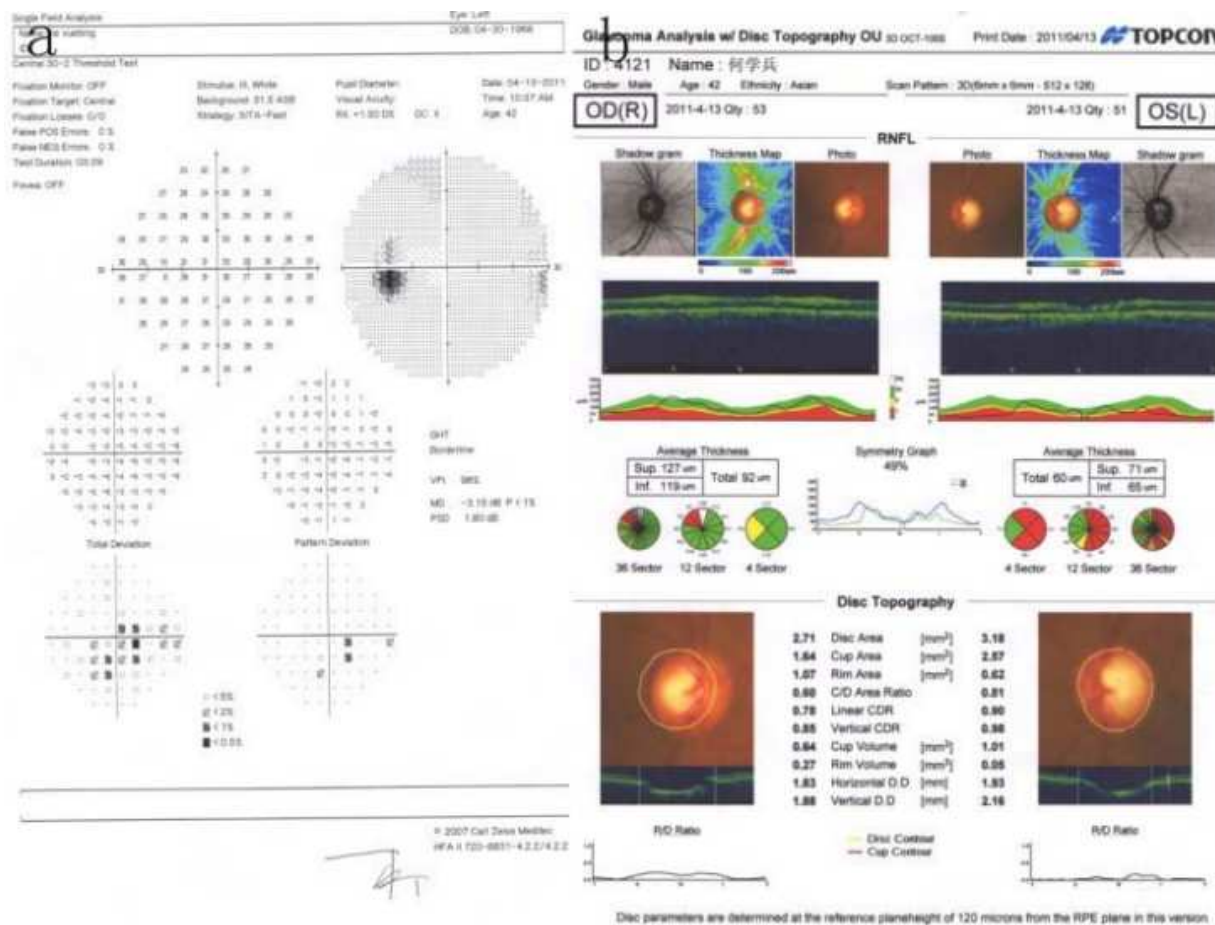


Figure 20. Typical clinical data of patient (ID :11041302)with diagnosis of left PSS combined with iris heterochromia. The visual fields of left eye show nasal defect (A) ,binocular OCTresults indicate ocular cups expand (B)and (C) obvious retinal nerve fiber layer defect (C).

both eyes, IOP 17/15(R/L)mmHg, a lot of small lipid-like KP in the inferior of the left cornea, “rain dozen sand-like” appearance in the iris of his left eye, C/D rate 0.6/0.7(R/L),CCT 553/560(R/L). Results of his visual field and OCT showed in Figure below. UBM showed wide-angle in the both eyes. Fundus fluorescein angiography and contrast sensitivity revealed no special finds. 24 hours IOP measurements (2 weeks after KP disappeared): 13~16/ 12~15(R/L)mmHg. Diagnosis of “PSS complicated with iris heterochromia” for his left eye was confirmed than. He was asked to treat every onset of the disease in time with drugs dropping IOP as well as anti-inflammatory medicine. (Clinical data see Figure 20)

Case 2) A patient was admitted to our hospital because her right eye suffered from repeated episodes of pain with blurred vision for more than nine years, and her vision decreased 3 months, with a primary diagnosis of “secondary glaucoma” for her right eye. A lot of intermittent recurrent pain and blurred vision had attacked her right eye from nine years ago, 2 or 3 times a year. Each attack lasted about one week, than resolved spontaneously. Three months ago her sense of vision went to recession. She felt that her right eye was attacked again recent days, so she can to our hospital. Ophthalmologic examination in this time showed: visual

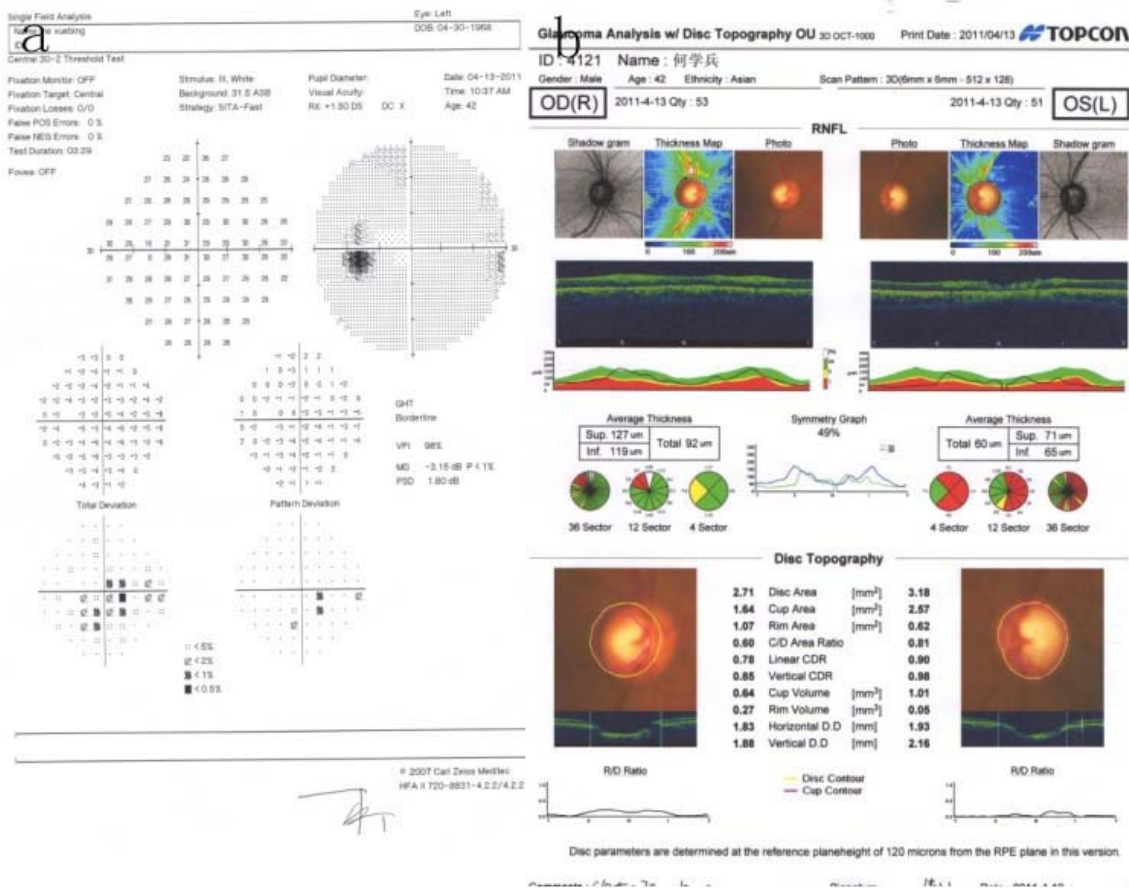


Figure 21. Typical clinical data of patient (ID :11041302)with diagnosis of left PSS combined with iris heterochromia. The visual fields of left eye show nasal defect(A),binocular OCT results indicate ocular cups expand(B) and (C) obvious retinal nerve fiber layer defect (C).

acuity: 0.15/ 1.0(R/L), IOP: 43/12(R/L) mmHg, mist edema in her cornea of her right eye with a lot of fat-like KP, pale and “rain scating beach-like” appearance in her left iris with a round pupil about 3mm in diameter, her optic disk appeared pale in color with a C/D 0.9, her anterior

chamber was not shallow, ultrasound biomicroscopy (UBM) showed a wide angle in both eye. Her left eye showed no KP with a C/D less 0.3. Her systemic examination and routine inspection and examination showed no special finds. Treatment with drugs dropping IOP such as carteolol and brimonidine and mannitol as well as steroids loteprednol kept about a week, KP significantly reduced but the intraocular pressure is still high. Operation of Ahmed valve implantation was performed on her right eye two weeks later. She was discharged a week postoperative with an IOP of 9mmHg in the operated eye. Her IOP was controlled well with fewer attacks of PSS and a stable visual field in the recent 3 years after the surgery. (Clinical data see Figure 21)

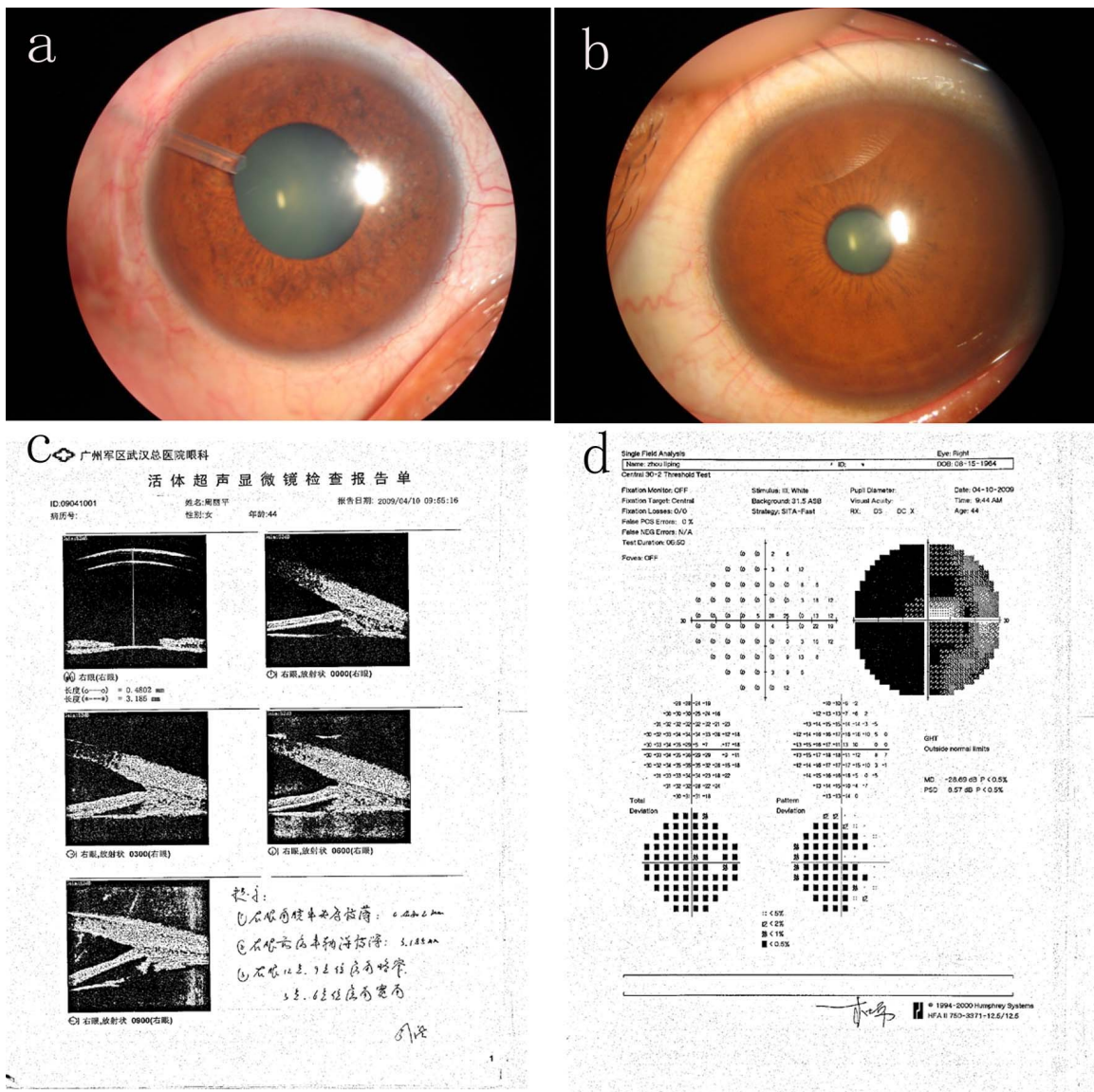


Figure 22. Typical clinical data of patient (Clinical number :437614)with diagnosis of right PSS combined with iris disorder. The right eye is after Ahmed implantation and arrow indicate iris heterochromia(A),the left eye is normal(B).UBM indicate a wild angle in right eye (C),but the visual field show serious damages in right eye(D).

Discussion

1. Clinical performance of PSS complicated with iris heterochromia

Four cases of PSS complicated with iris heterochromia were reported [40]. They were two males and two females aged 35 to 45 years. In addition to typical PSS performance, the iris showed "rain scattering sand-like" appearance in all of the 4 patients. All of them are monocular repeatedly attacked at the same eye. Each attack kept 3 to 7 days with a significantly increased IOP up to 30.00 ~ 60.00 mmHg and a few of fat-like KP, than relieve itself or extinct with the help of medication. Intraocular pressure (including 24 hours intraocular pressure) in intermittent period appeared normal after discontinuation of all medication with a typical crossed-over phenomenon.

2. Key-points in the differential diagnosis between PSS complicated with iris heterochromatic and FHI (Fuchs heterochromic iridocyclitis). The two diseases are different clinically in the following five aspects: the attacked eye and sex of patients, manifestation of intraocular pressure, character of KP, appearance of the Lens and glaucomatous damage of optic nerve and visual field.

(1) The attacked eye and sex of patients

Most of PSS cases had monocular presentation, a few of cases were binocular, but usually one eye was affected at a time, in extremely rare cases was binocularly attacked simultaneously. Male patients were more common than female in PSS. FH is generally believed that no gender more predisposed than the other more than 90% of the cases were monocularly affected.

(2) Manifestation of intraocular pressure

The IOP in patients of PSS with iris heterochromatic appeared as an intermittent and abruptly rising when the attack comes with the appearance of typical KP in pure PSS patients. IOP elevation in patients of PSS with iris heterochromatic usually lasted 3 ~ 10 days, and then turned to subside spontaneously with the disappearance of the KP after this period, it is also sensitive to drugs dropping IOP and anti-inflammatory medicine. On the contrary, IOP of patient with FH appeared normal in the initial stage for a long time, after that, elevated in part of the cases gradually; however, once the intraocular pressure elevated, it often appeared persistently higher, although there maybe some fluctuations. The elevated IOP and KP in patient with FH had no characteristic of intermittent, were difficult to be controlled and poorly responded to corticosteroids therapy. The IOP in patients with PSS complicated with iris heterochromia kept the characteristic of crossed-over, that is, the IOP of the attacked eye was higher than that of contra lateral eye during the episode but lower (3 ~ 5 mmHg) than the other eye between attacks. IOP in patients with Fuchs syndrome had no such characteristic, once elevated; it is always higher if untreated.

(3) Keratic Precipitates

The KP in patient with PSS complicated with iris heterochromia appeared only in a short period during the attack in most cases. This KP is of following characteristics: small round suet-like, medium sized, isolated, with no pigment in initial stage, mainly located in the lower part of

the cornea, usually disappeared naturally within a few days after or before IOP reduction. On the contrary, KP in patients with Fuchs syndrome has different characteristics as following: persistence for very long time even always in most cases, white transparent small dot or star-like coexisting with pigmented KP, diffuse distribution in the cornea, sometimes connected each other with fibrous filaments, poor response to corticosteroids therapy. (Clinical data see Figure 22)

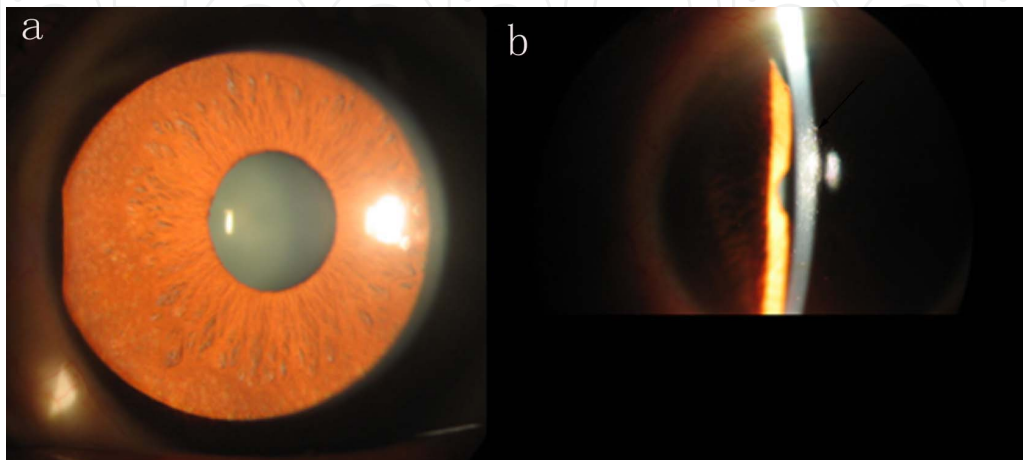


Figure 23. Heterochromatic iris and KP in FHI. There is a typical iris such as "rain dozen sand-like"(A) arrow shows a lot of star-like KPs(B).

(4) Lens situation

Fuchs syndrome complicated with cataract is common at later stage; however the complicated cataract is uncommon in the PSS cases with iris heterochromia.

(5) Glaucomatous retinal and visual damage

Glaucomatous damage in PSS cases appeared later and to a lesser extent, however that of FH cases occur earlier and quicker.

3.2.2. PSS combined with ischemic optic neuropathy

Typical cases

A patient came to our hospital because her vision of the left eye sudden dropped 2 months ago. She was examined 2 months ago: visual acuity: 1.0/ 0.5(R/L) IOP: 17.3/ 15(R/L) mmHg. The optic disc of her left eye was pale, visual field showed an inferior fan like defect. Fundus fluorescein angiography(FFA) of her left eye showed ischemic optic neuropathy. The anterior segment, fundus, vision, and FFA of her right eye were normal. She was diagnosed as "left eye ischemic optic neuropathy". She was admitted to our hospital, and examinations showed: visual acuity: 1.0/ 0.15(R/L). IOP: 17.3/ 50.62(R/L), anterior chamber of both eyes were not shallow, Right eye showed no abnormality. Left cornea had mild edema and there was a medium size fat-like KP below the pupil. The boundary of optic papillae in left eye was clear, the color was off white, and the C / D was about 0.3, the angle of left eye was N1 ~ N2. Systemic

examination such as X-ray, electrocardiogram and routine laboratory tests were normal. Visual field of right eye was normal and that of the left eye showed a centripetal narrow with an inferior fan like defect. She was diagnosed as "Left eye PSS, complicated with ischemic optic neuropathy", and treated with drugs for reducing IOP and nutrition curing to optic nerve for about a week. She was discharged with IOP 12mmHg disappeared KP, vision 0.2 of her left eye. (Clinical data see Figure 23)

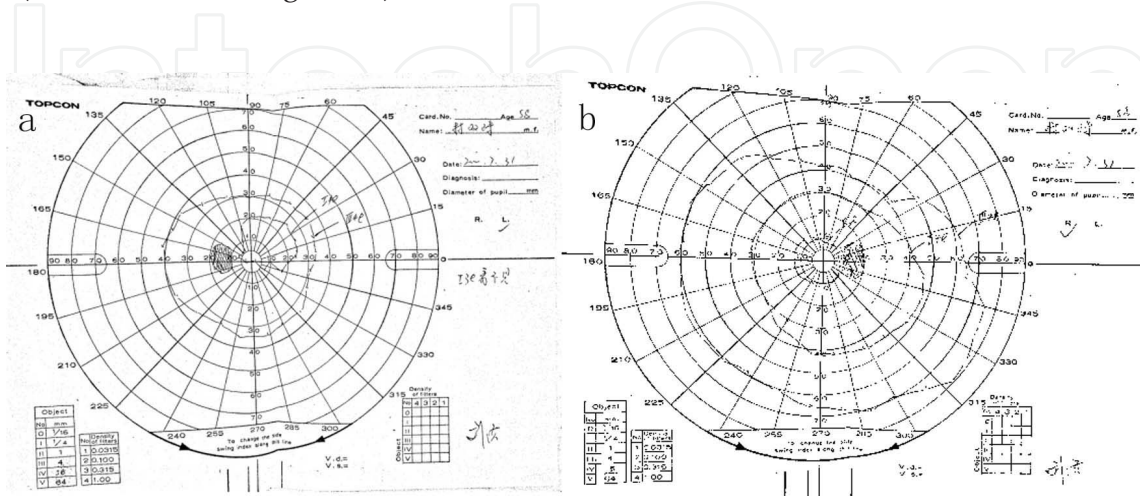


Figure 24. visual field of patient (Clinical number :294450) The case suffered from left eye PSS combined with ischemic optic neuropathy. inferior visual field defect and serious contraction of left(A),and that of the normal right eye(B).

Discussion

In 2003 1 case of PSS complicated with non-arteritic anterior ischemic optic neuropathy (AION) was reported. The vision of the case improved significantly after the attack of PSS had been controlled, but the vision and optic neuropathy damaged continually. The authors emphasized that the IOP of PSS patients complicated with AION should be promptly controlled as it is one of the risk factors [41]. It is useful to use drugs with dual role of reducing IOP and improving retinal blood supply in intermittent period. Our case appeared a sudden vision loss and significant discomfort two months ago. The result of examinations in other hospital such as visual field defect of arcuate below and FFA supported the diagnosis of left eye ischemic optic neuropathy. Results of examinations, reaction to treatment and course of the disease during her hospitalization in our hospital In July 2000 conformed with diagnostic criteria of PSS. The structure of the optic nerve, damage of blood vessels and blood state are related to ischemic optic neuropathy, the severely sudden rising of IOP during attack of PSS maybe the inducing factors. So it is necessary to reduce the IOP during each attack of PSS as soon and effective as possible for the cases of PSS combined with ischemic optic neuropathy or with the risk factors for that.

3.2.3. PSS combined with rhegmatogenous retinal detachment

Typical cases

A patient was hospitalized in our hospital for the reason that there was shadow before his right eye with a diagnose of rhegmatogenous retinal detachment. The IOP of his right eye elevated

to 29 mmHg 3 days after hospitalization and a fat-like KP appeared in his right eye, than he was diagnosed as rhegmatogenous retinal detachment combined with PSS. Retinal detachment surgery (Condensation+cerclage+scleral pressure technique) were done after reducing IOP with the treatment of drugs. Postoperative recovery was good. PSS recurred 4 months later and recovered 5 days late.

Discussion

The pathogenesis of PSS combined with rhegmatogenous retinal detachment is unknown. Increased concentration of PG (especially PGE) resulted from retinal S-antigen entered into the vitreous cavity after blood-eye barrier breakdown during the formation of retinal breaks may leads to the inflammation of the uvea, and the higher concentration of PGs and inflammatory products results in the IOP elevation.

3.2.4. PSS combined with cataract

Typical cases

A patient complained of recurrent pain and decreased vision of her right eye for four years. Results of examinations intraday showed: visual acuity:0.08/0.4(R/L); corrected visual acuityR: 0.3(-0.75DS/1.50DC*111),L: 0.9(-1.25DS/-0.50DC*83) ;IOP: 12/ 14(R/L) mmHg; a few of time worn pigmented KP on the central and lower part of her clear corneal; round pupil about3mm in diameter; normal iris, opacification of posterior capsule of lens; C/D of optic papillaeo.4.Her left eye appeared normal. She was hospitalized with the diagnosis of PSS and was treated with carteolol, brimonidine, mannitol for reducing IOP, tobradex for anti-inflammation and methycobal to maintain optic nerve. She was discharged once the attack of PSS faded away every time. The PSS attacked her1 to 2 month a time, her vision of right eye declined gradually without other discomfort. (Clinical data see Figure 24)

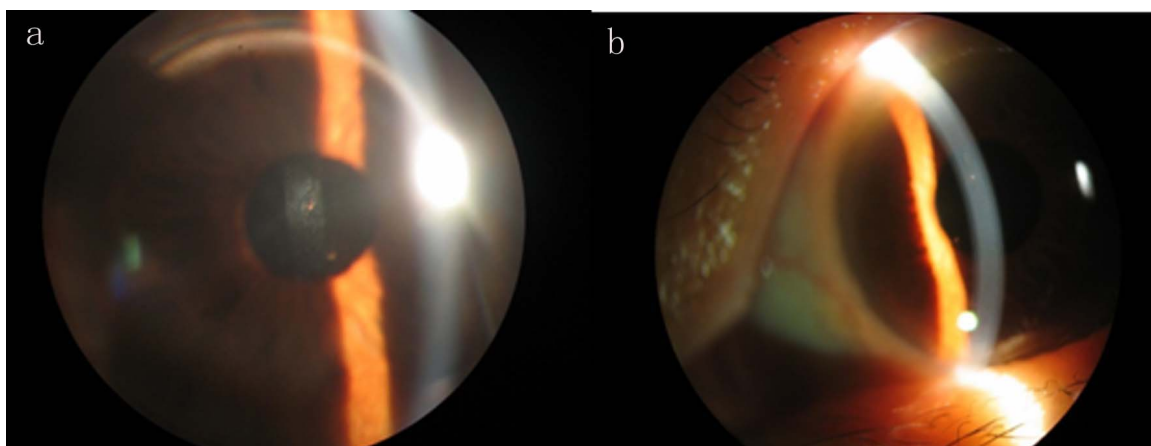


Figure 25. Anterior segment slit-lamp photography of patient (Clinical number 394998) with the diagnosis of PSS combined with cataract. Arrows show an opacities area at posterior capsule (A) and few typical fat-shaped KPs(B).

Discussion

The possible pathogenesis: repeated onset of IOP elevation and anterior segment inflammation cause disorders of nutrition and metabolism of the lens.

Surgical opportunity: Cataract surgery should be done after the inflammation has been subsidized for more than 3 months. The rest of the indication is the same to the conventional cataract. Considering the PSS is an inflammation of the nature of the disease and the literature PSS patients of corneal endothelial cell density is low, PSS patients combined cataract surgery methods should also do more thinking. Femtosecond laser cataract surgery with accurate positioning, and the advantage of less influence on corneal endothelial, compared with the phaco, whether merger of cataract in patients with PSS has advantages, is worth our discussion.[42]

Prospect

With the deepening of the research on PSS, the pathogenic factors, pathogenesis, clinical characteristics, especially the clinical pathway via which the glaucoma optic nerve damage occurred in PSS cases will become clearer. For example, if hormone treatment was used excessively in PSS cases, would glucocorticoid-induced glaucoma take place? If a poor blood supply to the optic disc of a patient with PSS or a weak structure of the papilla of optic nerve or a lower intracranial pressure, in such cases, would a normal-tension glaucoma appear? All these problems need to be continuously explored through our joint efforts.

Author details

He-Zheng Zhou*, Wen-Shan Jiang, Han-Guang Jie, Chang Feng, Wen-Qiang Zhang, Qian Ye, Jian-Guo Wu, Yan-Ping Song and Qin Ding

*Address all correspondence to: zhoueye@qq.com

Department of Ophthalmology, Wuhan General Hospital of Guangzhou Command, China

References

- [1] Posener A, Schlossman A. Syndrome of unilateral attacks of glaucoma with cyclic-symptoms. Arch ophthalmol.1948,39:5-28
- [2] Theodore FH. Observation on glaucomatocycliticcrisis(Posner Schlodman Syndrome).Br J Ophthalmol.1952,36:207-213
- [3] Dao-Ping Lu, Ran-Ran Xi. [Clinical analyzation of 177 cases with Posner Schlodman Syndrome]. Chin J Ophthalmology. 1982,18:34-37

- [4] Paivonsalo HT, Tuminen J, Vaahtoranta LH, et al. Incidence and prevalence of different uveitides in Finland. *Acta Ophthalmologica Scand.* 1997, 75:76-81.
- [5] Kanjiro M. The relationship between elevation of intraocular pressure and prostaglandin in cases with glaucomatocyclitic crisis. *clinical ophthalmology.* 1975,29:689-692
- [6] Yamamoto S, Pavan-Langston D, Tada R, et al. Possible role of herpes simplex virus in the origin of Posner-Schlossman syndrome. *Am J Ophthalmol.* 1995, 119: 796-798
- [7] Yang SY, Chen MJ, Chen KH, et al. Cytomegalovirus and herpes simplex virus as causes of bilateral anterior uveitis in an immunocompetent patient. *J Chin Med Assoc.* 2011,74:48-50
- [8] Blich-Michel E, Dussaix E, Cerqueti P, et al. Possible role of cytomegalovirus infection in the etiology of the Posner-Schlossman syndrome. *Int Ophthalmol.* 1987,11:95-96
- [9] Chee SP, Jap A. Presumed Fuchs heterochromic iridocyclitis and Posner-Schlossman syndrome: comparison of cytomegalovirus-positive and negative eyes. *Am J Ophthalmol.* 2008,146:883-889
- [10] CY Choi, MS Kim, JM Kim, SH Park, KH Park, C Hong. Association between Helicobacter pylori infection and Posner-Schlossman syndrome. *Eye.* 2010, [11] Zhi-Hui Li, Xun-Chuan Ji, Shu-Chu Chen, et al. [The Long-term follow-up of Posner-Schlossman Syndrome]. *Chin J Ophthalmology.* 1982,18:306-308
- [11] Nan-Xiang Peng. [Clinical analysis of 52 cases with Posner-Schlossman Syndrome]. *Contemporary Medicine.* 2008, 5:141-141
- [12] Wen-Xue Hu. [Clinical observation of early stage of Posner-Schlossman syndrome]. *Int J Ophthalmology.* 2011; 11: 1980-1982
- [13] Puri P, Verma D. Bilateral glaucomatocyclitic crisis in a patient with Holmes-Adie syndrome. *J Postgrad Med.* 1998,44:76-77
- [14] Yu-Hong Wang, Xing-Huai Sun. [Clinical analysis of the operative effect in patients with glaucomatocyclitic crisis]. *Chinese Journal of Practical Ophthalmology.* 2005, 10:23-30
- [15] Wen-Bing Zhou, Shou-Xiong Peng. [glaucomatocyclitic crisis and Primary Open-angle Glaucoma]. *Chinese Ophthalmic Res.* 1994,12:34-36
- [16] He-Zheng Zhou, Yuan-Hong Du. [The related factors about Posner-Schlossman syndrome damage of visual field]. *Chinese Journal of Practical Ophthalmology.* 2002,10:768-769
- [17] Hua-Xin Chen, He-Zheng Zhou, Bai-Chuan Wang et al. [The Clinical Observation of 14 cases elderly Posner-Schlossman syndrome]. *Military medical journal of South China.* 2007; 21: 43-45

- [18] Raitta C, Vannas A. Glaucomatocyclitic crisis. *Arch Ophthalmology*. 1977, 95:608-612
- [19] He-Zheng Zhou, Yi-Jia Yang. [Characteristics and clinical value of the intraocular pressure and the C-value in Posner Schloddman Syndrome]. *Chinese Journal of Practical Ophthalmology*.1992, 10:143-145
- [20] Ying-Bo Shui, Hou-Ren Wei. [Influence of Postural Change on Intraocular Pressure of Normal Eyes]. *Chinese Ophthalmic Res*. 1987; 3 : 182-185
- [21] He-Zheng Zhou. [Tonography and postural change of intraocular pressure in patients with glaucoma]. *Chinese Journal of Practical Ophthalmology*.1991,9:598-602
- [22] He-Zheng Zhou, Wen-Shan Jiang. [Differential diagnosis of Posner-Schlossman syndrome]. *Military medical journal of South China*.2012,2:32-35
- [23] He-Zheng Zhou, Yuan-Hong Du, Yan-Ping Song, Guang-Jie Wang, Jian-Guo Wu. [Visual field damage of glaucomatocyclitic crisis and its relating factors]. *Fourth MilMed Univ*.2001,22:1674-1677
- [24] Yi-Lin Tang. [Clinical analysis of damage of visual field with Posner Schlossman syndrome]. *International Journal of Ophthalmology*. 2010,10:1204-1205
- [25] Jap A, Sivakumar M, Chee SP. Is Posner-Schlossman syndrome benign? *Ophthalmology*.2001,108:913-991
- [26] He-Zheng Zhou, Bai-Chuan Wang, Xiong Zhou. [Unilateral Primary Open-Angle Glaucoma and Bilateral Posner-Schlossman syndrome]. *Chin J Misdiagn*. 2001,1:334-336
- [27] He-Zheng Zhou, Wen-Qiang Zhang, Bai-Chuan Wang. [Glaucomatocyclitic crisis with primary close-Angle glaucoma]. *International Journal of Ophthalmology*,2004,4(5): 844-847
- [28] Darchuk V, Sampaolesi J, Mato L, Nicoli C, Sampaolesi R. Optic nerve head behavior in Posner-Schlossman syndrome. *Int Ophthalmol*,2001;23:373-379
- [29] Rong-Xin Wu. [Operative effect in 1 Case with Posner-Schlossman syndrome]. *Ocular trauma professional eye disease magazine*. 2002,24:328
- [30] Lei Sheng, Yu-Pu Li, Gui-Lan Lan. [1 Case of Posner-Schlossman syndrome]. *Chinese Journal of Practical Ophthalmology*.2008,26:572
- [31] Bo Zhao, Da-Yong Bai, Hui Zhao, et al. [Posner-Schlossman syndrome and primary open-angle glaucoma]. *Chin J Pract Ophthalmology*. 2004,22:142-143
- [32] Xiu-Feng Ke, Dan-Ning Z, Li Yuan. [Observation the clinical operation curative effect of Posner-Schlossman syndrome]. *Chinese Journal of Practical Ophthalmology*. 2007,6:642-643
- [33] Dinakaran S, Kayarkar V. Trabeculectomy in the management of Posner-Schlossman syndrome. *Ophthalmic Surg Lasers*.2002,33:321-322

- [34] Stavrou P, Murray PI. Does trabeculectomy influence the course of uveitis? *OculImmunolInflamm*. 1999,7:103-108
- [35] Xiao-Ping Zhang, Ji-Zhong Chen, Ru-Yong Song,[Analyze the Diagnostic of Posner-Schlossman syndrome]. *Journal of clinical ophthalmology*.2002,10:137-139
- [36] Jin-Fu Ying, Ling-Ling Wu, [Posner-Schlossman syndrome complicated with Primary Closed-Angle Glaucoma]. *Chinese Journal of Practical Ophthalmology*. 1993.11:491-492
- [37] Chang-lin Zhao, Han-Ping Xie. [A case report of primary angle closure glaucoma accompanied by glaucomatocyclitic crisis]. *Acta Academiae Medicinae Militaris Tertiae*. 2004.10.25; 26: 1798
- [38] Li-Hong Guan. [2 cases of Posner-Schlossman syndrome complicated with Primary Closed-Angle Glaucoma]. *Modern Medicine & Health*. 2008, 24: 152
- [39] Wen-Shan Jiang, He-ZhengZhou,Yun-Hui Chen, Ling Hong [Differential diagnosisof the Posner-Schlossman syndrome with heterochromic iris and the Fuchs syndrome—clinical report about three cases]. *International Journal of Ophthalmology*, 2009; 9 (9): 1762-1763
- [40] Irak I, Katz BJ, Zabriskie NA, Zimmerman PL.Posner-Schlossman syndrome andnarteritic anterior ischemic optic neuropathy. *J Neuroophthalmol*. 2003,23: 264-267
- [41] Schultz T, Conrad – Hengerer I, Hengerer FH, et al. Intraocular pressure variation during femtosecond laser – assisted cataract surgery using a fluid–filled interface. *J Cataract Refract Surg* 2013; 39 (1): 22–27

