

We are IntechOpen, the world's leading publisher of Open Access books Built by scientists, for scientists

4,800

Open access books available

122,000

International authors and editors

135M

Downloads

Our authors are among the

154

Countries delivered to

TOP 1%

most cited scientists

12.2%

Contributors from top 500 universities

**WEB OF SCIENCE™**Selection of our books indexed in the Book Citation Index
in Web of Science™ Core Collection (BKCI)

Interested in publishing with us?
Contact book.department@intechopen.com

Numbers displayed above are based on latest data collected.

For more information visit www.intechopen.com

Anti Oxidative, Anti Peroxidative and Hepatoprotective Potential of *Phyllanthus amarus* Against Anti Tb Drugs

Sangeeta Shukla, Neelu Sinha and Amita Jaswal

Additional information is available at the end of the chapter

<http://dx.doi.org/10.5772/57373>

1. Introduction

The liver plays an astonishing array of vital functions in the maintenance and performance of the body. Additionally, it is also handling the metabolism and excretion of drugs and other xenobiotics from the body thereby providing protection against foreign substances by detoxifying and eliminating them (Saleem et al., 2010). Large numbers of xenobiotics are reported to be potentially hepatotoxic. Free radicals generated from the xenobiotic metabolism can induce lesions of the liver and react with the basic cellular constituents such as proteins, lipids, RNA and DNA (Ajith et al., 2007). A growing international health concern is Tuberculosis caused by *Mycobacterium tuberculosis* (Abdelaal et al., 2009). India is the highest TB burden country accounting for one fifth (21%) of the global incidence (WHO, 2010). The first line anti-tuberculosis drugs isoniazid (INH), rifampicin (RIF), pyrazinamide (PZA) and Ethambutol (ETH) continues to be the effective drugs in the treatment of tuberculosis, however, the use of these drugs is associated with toxic reactions in tissues, particularly in the liver, leading to hepatitis (Eminzade et al., 2008). This is one of the most serious adverse effects of anti-tuberculosis drugs (ATD). Liver injury or liver dysfunction is a major health problem that challenges not only health care professionals but also the pharmaceutical industry and drug regulatory agencies (Saleem et al., 2010). It has great capacity to detoxify and synthesize useful substances, and therefore damage to the liver has grave consequences (Devaraj et al., 2011). Currently, there is no effective treatment against ATD induced hepatic damage. Plants are an important component of the health

care system in India and have been found to be effective in the treatment of different diseases and are the beacon of the therapeutic sources for curing diseases from times immemorial (Merina *et al.*, 2012). *Phyllanthus amarus* Linn. is commonly known as *bhumi amla* (Joshi&Parle2007). It is reported to possess antiviral (Lee *et al.*, 1996), anticancer (Rajeshkumar *et al.*, 2002). But there is no scientific evidence for its hepatoprotective activity against ATD induced liver injury. Hence the present study was undertaken to explore the key behind the use of *P.amarus* as a hepatoprotective formulation against xenobiotics induced hepatic adverse effect.

2. Materials and methods

2.1. Chemicals

Anti TB drug *i.e.*, Rifampicin, Isoniazid, Pyrazinamide as anti TB kit was generously obtained from Government TB hospital, Gwalior (M.P.). All the other chemicals used in this study were of analytical grade and were procured from Sigma–Aldrich (USA), E Merck (Germany), Ranbaxy Pvt. Ltd. and BDH Company (India).

2.2. Preparation of plant extract

Whole plant of *Phyllanthus amarus* was obtained from the authenticated ayurvedic dealer and was identified by the experts of Botany Department, Jiwaji University Gwalior, India. The shade dried plant was pulverized and extracted with 75% alcohol for 10 days with concomitant shaking and then filtered. The filtrate was evaporated in vacuum to yield a brownish powder (*P. amarus*) powder it was stored in refrigerator at 4°C and administered orally according to body weight of animals at different concentration.

2.3. Animal maintenance and feeding

Female albino rats of *Sprague Dawley* strain (160±10 g, b.w.) were used for the present investigation. Animals were housed in polypropylene cages under standard conditions (25±2°C temperature, 60%-70% relative humidity and 14 h light and 10 h dark) and were fed on standard pellet diet (Pranav Agro Industries Ltd., New Delhi, India) and drinking water *ad libitum*. Animals used in this study were treated and cared for in accordance with the guidelines recommended by the Committee for the Purpose of Control and Supervision of Experiments on Animals (CPCSEA), Government of India, Ministry of Culture, Chennai.

2.4. Experimental design

Animals were divided into various groups of six animals each. *P.amarus* and anti TB drugs were given alternatively for 8 weeks (3 days/week). The groups were treated as follows:

Group I: Control (normal saline, 0.9%).

Group II: *Per se* - 400mg/kg, b.w., *P.amarus* (p.o.), daily.

Group III: Experimental control-RIF+INH+PZA+ETH at 52, 70,175,140 mg/kg, b.w., (p.o.), 3days/week.

Group VI- VII: INH+RIF+PZA (as in group III) + *P.amarus* at 100, 200, 300 and 400 mg/kg, b.w., (p.o) 3days/week.

Group VIII: Positive control-Silymerin -50mg/kg b.w. (p.o.), daily.

All the animals were euthanized 24hours after the last treatment to perform various biochemical and histological analysis.

2.4.1. Blood biochemical investigations

Blood was drawn from retro-orbital venous sinus and serum was isolated. Serum Urea, Uric acid and Creatinine determined by commercially prepared kit method (E-Merck, Germany). Serum AST and ALT activity were determined with Reitman and Frankel, 1957.

2.4.2. Tissue biochemical investigations

The tissues viz., liver and kidney were quickly excised, washed in ice cold, normal saline and blotted individually freed from extraneous material on ash-free filter paper. The tissues were then homogenized separately in hypotonic buffer (0.008% NaHCO₃), pH 7.4, using a Potter-Elvehjem homogenizer at 600-1000 rpm in ice cold conditions.

The crude tissue homogenate was centrifuged at 2000 rpm for 15 min (0-4°C). The supernatant was collected and stored at -20°C until used for estimating tissue biochemical parameters. Lipid Peroxidation (LPO) was determined by measuring thiobarbituric acid reactive substances (TBARS) in tissues according to Sharma and Krishnamurthy, 1968. SOD and Catalase activity were determined according to Misra and Fridovich, 1972 and Aebi, 1974 respectively.

2.4.3. Histopathological investigations

Tissues were fixed with Bouin's solution. They were later sectioned using a microtome, dehydrated in graded alcohol, embedded in paraffin section, and stained with hemotoxylin and Eosin (H & E).

2.5. Statistical analysis

Results are presented as mean \pm S.E. of six animals used in each group. Data were subjected to statistical analysis through one-way analysis of variance (ANOVA) at 5% significance level followed by Student's t-test at $p \leq 0.05$ (Snedecor and Cochran, 1989).

3. Results — Table 1-6 and histopathology

Treatment	AST (IU/L)	ALT (IU/L)
Group I	69 ± 3.81	52 ± 2.87
Group II	74 ± 4.09	53.6±2.96
Group III	345±19.07#	188 ± 10.39#
Group IV	120.22 ± 6.65* (81.44%)	81 ± 4.48* (78.67%)
Group V	112.34 ± 6.21* (84.29%)	71 ± 3.92* (86.02%)
Group VI	100.7 ± 5.57* (88.51%)	63 ± 3.48* (91.91%)
Group VII	94.4 ± 5.22* (90.79%)	60 ± 3.32* (94.11%)
Group VIII	83 ± 4.59* (94.92%)	59 ± 3.26* (94.85%)
ANOVA F Value	141.88@	90.172@

Data are mean ± S.E., n=6. ANOVA (F Values at 5% level). # P≤0.05 vs. Control, *P ≤0.05 vs. ATD, @ Significant

Table 1. Therapeutic effect of *P.amarus* against ATD induced blood biochemical alterations

Treatment	SALP (U/L)	Albumin (g/dl)	Bilirubin(mg/dl)
Group I	193.3±10.68	4.1 ± 0.23	0.19 ± 0.010
Group II	220±12.16	4.0 ± 0.22	0.2±0.011
Group III	462±25.54#	3.0±0.17#	0.8± 0.044#
Group IV	381.3±21.08* (30.03%)	3.5 ± 0.19 (45.45%)	0.65± 0.036* (24.59%)
Group V	305.25±16.87* (58.33%)	3.6 ± 0.199 (54.54%)	0.58 ± 0.032* (36.06%)
Group VI	257±14.21* (76.29%)	3.7 ± 0.20* (63.63%)	0.34± 0.018* (75.4%)
Group VII	236±13.05* (84.10%)	3.8± 0.21* (72.72%)	0.32 ± 0.017* (78.68%)
Group VIII	216±11.94* (91.55%)	4.0± 0.22* (90.9%)	0.3 ± 0.016* (81.96%)
ANOVA F Value	39.135@	3.631@	89.61@

Table 2. Curative effect of *P.amarus* against ATD on selected serological parameters serum

Treatment	Urea (mg/dl)	Uric acid (mg/dl)	Creatinine (mg/dl)
Group I	19.5±1.08	5.3± 0.292	0.4± 0.022
Group II	24±1.33	5.6± 0.309	0.5±0.027
Group III	52.6±2.91 [#]	10±0.552 [#]	0.8± 0.044 [#]
Group IV	47±2.59 (16.91%)	7.6± 0.420* (51.06%)	0.7± 0.038* (25%)
Group V	44.1±2.44* (25.67%)	6.22± 0.343* (80.42%)	0.66± 0.036* (35%)
Group VI	35.7±1.97* (51.05%)	6.1± 0.337* (82.97%)	0.6± 0.033* (66%)
Group VII	30.7±1.70* (66.16%)	6± 0.331* (88.90%)	0.575± 0.032* (75%)
Group VIII	27.8±1.544* (74.92%)	5.8± 0.320* (89.36%)	0.55± 0.030* (83%)
ANOVA F Value	32.005[@]	20.642[@]	16.887[@]

Data are mean ± S.E., n=6.ANOVA (F Values at 5% level).[#] P≤0.05 vs. Control,*P ≤0.05 vs. ATD,[@] Significant

Table 3. *P.amarus* efficiency in reducing Anti TB drugs induced renal alterations.

Treatment	Lipid Peroxidation (n mole of TBARS/mg protein)		Reduced glutathione (μ mole / g)	
	Liver	Kidney	Liver	Kidney
Group I	0.31±0.017	0.3± 0.016	7.97± 0.441	7.5± 0.441
Group II	0.341±0.018	0.33± 0.018	8.136±0.449	7.78± 0.449
Group III	1.94±0.107 [#]	1.28±0.071 [#]	6.8± 0.376 [#]	6.17± 0.376 [#]
Group IV	0.69±0.038* (76.68%)	1.096± 0.061* (18.77%)	7.08± 0.391 (23.93%)	6.69± 0.391 (39.09%)
Group V	0.57±0.034* (84.04%)	1.096± 0.061* (18.77%)	7.18± 0.396 (32.47%)	7.0± 0.397 (62.40%)
Group VI	0.44±0.0243* (92.02%)	0.737± 0.041* (55.47%)	7.4± 0.409 (51.28%)	7.25± 0.409 (81.20%)
Group VII	0.431±0.0238* (92.57%)	0.721± 0.039* (57.04%)	7.75± 0.428 (81.19%)	7.33± 0.428 (87.21%)
Group VIII	0.335±0.018* (98.46%)	0.665± 0.037* (62.75%)	7.85± 0.434 (89.74%)	7.34± 0.434 (87.96%)
ANOVA F Value	174.79[@]	70.42[@]	1.566	1.971

Data are mean ± S.E., n=6.ANOVA (F Values at 5% level).[#] P≤0.05 vs. Control,*P ≤0.05 vs. ATD,[@] Significant

Table 4. Effect of *P.amarus* against AT drugs treated animals in tissue biochemical estimations.

Treatment	SOD		Catalase	
	(U/min./mg protein)		(μ mole of H_2O_2 oxidised/min/mg protein)	
	Liver	Kidney	Liver	Kidney
Group I	70.7 \pm 3.908	48.78 \pm 2.696	50.7 \pm 2.802	70.1 \pm 3.875
Group II	76 \pm 4.201	51.2 \pm 2.830	51.8 \pm 2.863	62.14 \pm 3.435
Group III	37.52 \pm 2.074 [#]	24.39 \pm 1.348 [#]	38.1 \pm 2.106 [#]	50.8 \pm 2.808 [#]
Group IV	44 \pm 2.432 (19.52%)	33.3 \pm 1.840* (36.53%)	42.02 \pm 2.322 (31.11%)	59.67 \pm 3.298 (45.95%)
Group V	45.6 \pm 2.520 (24.35%)	35.9 \pm 1.984* (47.19%)	42.5 \pm 2.349 (34.92%)	59.97 \pm 3.315 (47.51%)
Group VI	55 \pm 3.040* (52.68%)	41.15 \pm 2.274* (68.71%)	44.05 \pm 2.435 (47.22%)	61.96 \pm 3.425* (57.82%)
Group VII	60.9 \pm 3.366* (70.46%)	43.13 \pm 2.384* (76.83%)	45.2 \pm 2.498 (56.34%)	62.1 \pm 3.432* (58.54%)
Group VIII	68 \pm 3.759* (91.86%)	41.83 \pm 2.312* (71.50%)	50.6 \pm 2.775* (96.03%)	62.57 \pm 3.458* (58.54%)
ANOVA F Value	22.664[@]	12.569[@]	4.464[@]	2.911[@]

Data are mean \pm S.E., n=6. ANOVA (F Values at 5% level). # $P \leq 0.05$ vs. Control, * $P \leq 0.05$ vs. ATD, [@] Significant

Table 5. Effect of *P.amarus* on SOD, Catalase activity in liver and kidney against anti TB drugs.

Treatment	ATPase Liver	ATPase Kidney
	(mgPi/100gm/min)	
Group I	1971 \pm 108.95	2449.99 \pm 135.44
Group II	2114 \pm 116.86	2257.14 \pm 124.77
Group III	1335.71 \pm 73.84 [#]	1785.7 \pm 98.72 [#]
Group IV	1721.4 \pm 95.16* (60.71%)	1814.28 \pm 100.29 (4.30%)
Group V	1864.28 \pm 103.06* (83.02%)	1907.14 \pm 105.43 (18.28%)
Group VI	1889 \pm 104.43* (87.09%)	2042.85 \pm 112.93 (38.71%)
Group VII	1966.06 \pm 108.69* (99.22%)	2149.99 \pm 118.85* (54.83%)
Group VIII	1969 \pm 108.85* (99.68%)	2107.14 \pm 116.48 (48.38%)
ANOVA F Value	6.350[@]	4.696[@]

Data are mean \pm S.E., n=6. ANOVA (F Values at 5% level). # $P \leq 0.05$ vs. Control, * $P \leq 0.05$ vs. ATD, [@] Significant.

Table 6. Therapeutic Effect of *P.amarus* on ATPase against ATD

4. Discussion

The liver diseases remain one of the serious health problems as variedly exposed to xenobiotics. Modern medicines have little to offer for alleviation of hepatic diseases. Although *P. amarus* is reported to possess varied medicinal properties such as antiviral, anticancer, antioxidant, anti-inflammatory, hepatoprotective (Joshi and Parle, 2007), there is no previous report about the hepatoprotective activity of this plant against anti TB drugs. The present investigation reports the hepatoprotective effect of *P. amarus*. In the present study, hepatotoxicity model in albino rats was successfully produced by administering RIF, INH and PZA.

Effects of administration of Anti TB Drugs and *Phyllanthus amarus* orally on selected biochemical parameters in rat tissue and blood serum is presented in Table 1-6.

Significant rise above the normal upper limits in the measured serum transaminases in toxicant group on day 60 of the experiment was a biochemical indication of liver injury. Elevated levels of serum enzymes, AST and ALT are indicative of cellular leakage, and loss of functional integrity of cell membrane in liver (Ranawat *et al.*, 2010). Oral administration of *P. amarus* extract at doses (100, 200, 300 and 400 mg/kg) showed significant recoument in a dose dependent manner ($P \leq 0.05$) (Table1).

The increased level of serum alkaline phosphatase is reliable marker of liver damage, which occurs due to the *de novo* synthesis by the liver cells (Muriel and Escobar, 2003). Serum albumin concentration is affected by hepatic protein and its synthesis is a typical function of normal liver cells (Thirunavukkarasu and Skthisenkarana, 2003). Bilirubin is one of the most frequent clinical test to evaluate the extent of chemically induced hepatotoxicity (Zimmerman, 1973). Toxicants administration caused significant increase in the serum alkaline phosphatase activity. Stabilization of SALP and bilirubin levels by the treatment of *P. amarus* is clear indication of improvement in functional status of liver cells. Results suggested that *P. amarus* at a dose of 400mg/kg, b.w., have protective effect on plasma membrane of hepatocytes. (Table2)

As a measure of renal function status, serum urea, uric acid and creatinine are often regarded as reliable markers (Adebisi *et al.*, 2000). Serum creatinine has been used to estimate glomerular filtration rate. Thus, elevations in the serum concentrations of these markers are indicative of renal injury (Adebisi *et al.*, 2000; Adewole *et al.*, 2007). The same was observed after toxicant administration. It may be due to dysfunctional and dystrophic changes in the liver and kidney. Experiment has shown that *P. amarus* at different doses, showed significant protective but the highest protection was observed at 300 and 400 mg/kg with mere difference indicating normal glomerular filtration rate thereby improved functional status of kidney. (Table 3)

Various biochemical parameters were measured in liver and kidney tissues. The levels of TBARS in liver and kidney tissues of ATD intoxicated rats were significantly elevated when compared to the level of TBARS in control animals. The increased lipid peroxidation results in changes in cellular metabolism of the hepatic and extra hepatic tissues, which ultimately leads to the whole cell deformity and cell death (Arun and Balasubramanian, 2011). The administration of herbal drug *P. amarus* at the different therapeutic doses showed reduction

in TBARS level. The standard hepatoprotective drug Silymarin maintained the decreased lipid peroxidation level to the normal limits in the liver.

Concomitant cellular oxidative stress was manifested by reduced GSH levels and increased lipid peroxidation. The inverse linear relationship between the ROS level and the GSH level indicated that free radical species were generated by exposure to anti TB drugs which reduced intracellular antioxidant levels. The results indicate that, the herbal drug *Phyllanthus amarus* has very good hepatoprotective effect in liver damage. The results were presented in the Table 4.

Superoxide dismutase and Catalase mutually function as important enzymes in elimination of Reactive oxygen species (ROS). SOD is the major attractive metalloprotein in the antioxidant family. The defensive antioxidant enzyme next to SOD is CAT. CAT is an enzymatic antioxidant widely distributed in all animal tissues, and the highest activity is found in the red cells and liver. Both are the key component of the antioxidant defense system. In the present study, the observed decrease in SOD and CAT activities were presumably associated with the increased oxidative stress caused by these toxicants that might be due to low level of zinc (a metal constituent of the enzyme SOD) in liver tissue (Arun and Balasubramanian, 2011) Therapy at 200-400 mg/kg b.w. reversed the SOD and CAT activity in the liver tissues and protected from free radical induced oxidative stress. These observations are substantiated by author (Gnanadesigan *et al.*, 2011).(Table 5)

ATPase is a membrane bound enzyme. Since, phosphatase is a constituent of all the body tissues; it plays an important role in inorganic pyrophosphates activity. ATPase activity may be considered as a marker for assessing hepatocellular damage induced by hepatotoxic agents. (Table 6)

In our experiment, a concurrent fall was found in ATPase in liver after toxicants exposure. It might be due to dysfunctional and dystrophic changes in the mitochondria and cell membrane permeability. This damage was also very clearly visible in histopathological studies after toxicant administration. These observations are substantiated by other authors (Gao and Zhou, 2005; Krithika and Verma, 2009).The effect of the extracts on ATPase was as pronounced with 100mg/kg as with 200-400mg/kg b.w.

Liver damage induced by toxicant was associated with a variety of biochemical abnormalities following loss of integrity of the cell membrane or interference with normal hepatocytes metabolism and function.

The reason for hepatoprotective effect of the extracts may be due to presence of lignans and flavonoids which might have scavenged the free radical offering hepato protection.

5. Conclusion

The results of this study showed that common medicinal plant, *P. amarus* even at minimal dose 300mg/kg was found to have beneficial hepatoprotective properties in albino rats as all the

major parameters showed percent protection level above 50% at dose levels 300 and 400mg/kg. All these properties make *P. amarus*, a novel herb for treating oxidative stress and anti Tb drug associated hepatic toxicity. There is, however, the need of further experiments for chronic study to exercise on excessive and prolonged use of this plant.

6. Histopathological studies

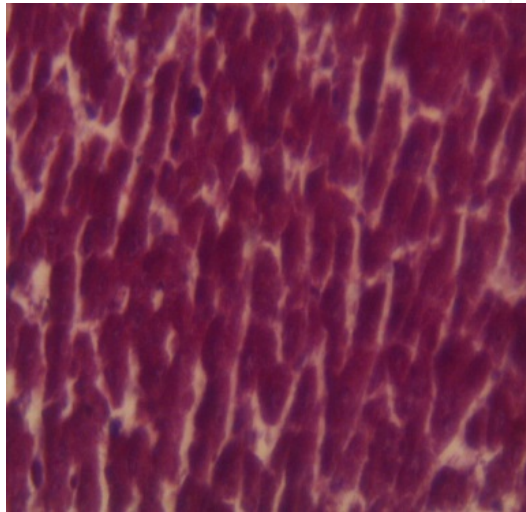


Figure 1. Hepatocytes of the normal control group showed a normal lobular architecture of the liver (400 x).

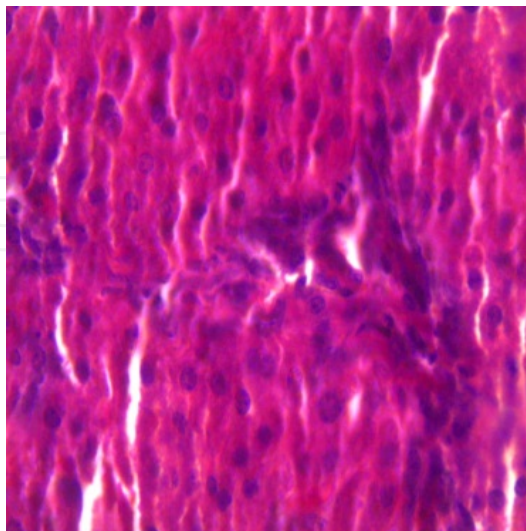


Figure 2. Hepatocytes of the INH + RIF+ PZA treated group showed liver cell necrosis and inflammation also observed in the centrilobular region with portal triaditis (400 x).

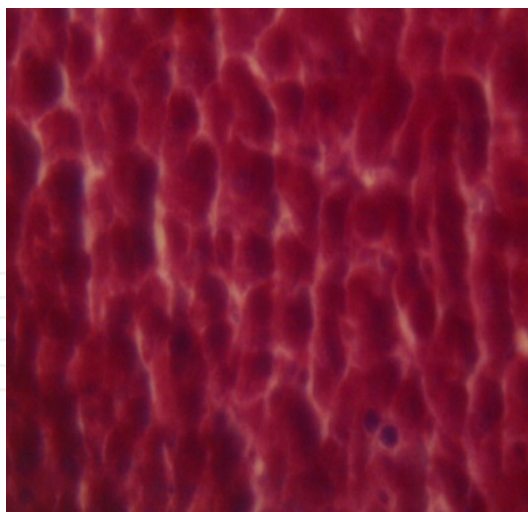


Figure 3. Hepatocytes of the *P.amarus* treated group showed cuboidal hepatocytes with moderate portal triaditis and their lobular architecture was normal (400 x).

Acknowledgements

Authors are grateful to Jiwaji University for providing lab facility and UGC for financial assistance.

Author details

Sangeeta Shukla*, Neelu Sinha and Amita Jaswal

*Address all correspondence to: profsshukla@gmail.com

School of Studies in Zoology, Jiwaji University, Gwalior, India

References

- [1] Saleem TSM, Chetty CM, Ramkanth S, Rajan VST, Kumar KM, Gauthaman K (2010).Hepatoprotective Herbs – A Review. Int. J. Res. Pharm. Sci.1:1, 1-5.
- [2] Ajith TA, Hema U and Aswathy MS (2007). Zingiber officinale Roscoe prevents acetaminophen-induced acute hepatotoxicity by enhancing hepatic antioxidant status. Food Chem. Toxicol.; 45(11): 2267-72.
- [3] Abdelaal A, El-Ghaffar HA, Hosam M, Zaghoul E, El mashad N, Badran E and Fathy A (2009).Genotypic detection of rifampicin and isoniazid resistant Mycobacteri-

- um tuberculosis strains by DNA sequencing: a randomized trial. *Annals of Clinical Microbiology and Antimicrobials*, 8:4.
- [4] Eminzade S, Uras F and Izzettin FV. (2008). Silymarin protects liver against toxic effects of anti-tuberculosis drugs in experimental animals. *Nutrition & Metabolism*, 5:18.
- [5] Devaraj VC, Gopala KB, Viswanatha GL, Kamath JV, Kumar S (2011). Hepatoprotective activity of Hepax-A polyherbal formulation. *Asian Pacific Journal of Tropical Biomedicine*. 142-146.
- [6] Joshi H, Parle M (2007). Pharmacological evidences for anti-amnesic potentials of *Phyllanthus amarus* in mice. *African Journal of Biomedical Research*, Vol. 10; 165 – 173.
- [7] Lee S B, Bablanian R and Esteban M. (1996). Regulated expression of the interferon-induced protein kinase p68 (PKR) by vaccinia virus recombinants inhibits the replication of vesicular stomatitis virus but not that of poliovirus. *Journal of Interferon and Cytokine Research* 16, 1073-1078.
- [8] Reitman and Frankel. (1957). A colorimetric method for the determination of serum glutamic oxalacetic and glutamic pyruvic transaminases. *Amer. J. Clin. Pathol.* 28: 56-63.
- [9] Sharma SK and Krishnamurthy CR (1968). Production of lipidperoxides of brain. *J Neurochem*; 15: 147-9.
- [10] Misra HP and Fridovich I (1972). The role of superoxide anion in the autoxidation of epinephrine and a simple assay for superoxide dismutase. *J Biol Chem.* 247: 3170–3175.
- [11] Aebi H (1984). Catalase in vitro; *Methods Enzymol.* 105. 121–126
- [12] Ranawat L, Bhatt J and Patel J. (2010). Hepatoprotective activity of ethanolic extracts of bark of *Zanthoxylum armatum* DC in CCl₄ induced hepatic damage in rats. *J. Ethnopharmacol.* 127(3):777-780.
- [13] Muriel P, Escobar Y (2003). Kupffer cells are responsible for liver cirrhosis induced by carbon tetrachloride. *J. App. Toxicol.*, 23(2):103-108.
- [14] Thirunavukkarasu C, Sakthisekaran D (2003). Influence of sodium selenite on glycoprotein contents in normal and N-nitrosodiethylamine initiated and Phenobarbital promoted rat liver tumors. *Pharmacol Res* 48(2):167-73.
- [15] Zimmerman L (1973). Podiatry and the law. *J Am Podiatry Assoc*, 63; 691-3.
- [16] Adebisi SA, Oluboyo PO, Okesina AB (2000). Effect of drug-induced hyperuricaemia on renal function in Nigerians with pulmonary tuberculosis. *Afr J Med Med Sci.* 3-4:297-300.

- [17] Adewole SO, Salako AA, Doherty OW, Naicker T (2007). Effect of melatonin on carbon tetrachloride-induced kidney injury in Wistar rats. *Afr. J. Biomed. Res.*, 10: 153-164.
- [18] Arun K and Balasubramanian U (2011). Comparative study on hepatoprotective activity of *phyllanthus amarus* and *eclipta prostrata* against alcohol induced in albino rats. *International journal of environmental sciences* volume 2:1.
- [19] Gnanadesigan M, Ananad M, Ravikumar S, Maruthupandy M, Syed Ali M, Vijayakumar V, Kumaraguru AK (2011). Antibacterial potential of biosynthesized silver nanoparticles using *Avicennia marina* mangrove plant, *Applied Nanoscience*.
- [20] Gao H, Zhou YW (2005). *World. J. Gastroenterol.* 11, 3671.
- [21] Krithika R and VERMA R J (2009). Ameliorative potential of *phyllanthus amarus* against carbon tetrachloride-induced hepatotoxicity. *Acta Poloniae Pharmaceutica ñ Drug Research*, 66(5)-579-583.
- [22] Snedecor GW, Cochran, WG (1989). *Statistical method*. 8th edition Ames, IA: Affiliated east-West Press; 217-36.
- [23] Rajeshkumar NV, Joy KL, Kuttan G, Ramsewak RS, Nair MG, Kuttan R (2002). Antitumour and anticarcinogenic activity of *Phyllanthus amarus* extract. *J Ethnopharmacol.* 81(1):17-22.
- [24] Narah M, Kalita JC, Kotoky J (2012). Medicinal plants with potential anticancer activities: a review. *International Research Journal of Pharmacy.* 3 (6)