

# We are IntechOpen, the world's leading publisher of Open Access books Built by scientists, for scientists

**4,800**

Open access books available

**122,000**

International authors and editors

**135M**

Downloads

Our authors are among the

**154**

Countries delivered to

**TOP 1%**

most cited scientists

**12.2%**

Contributors from top 500 universities



**WEB OF SCIENCE™**

Selection of our books indexed in the Book Citation Index  
in Web of Science™ Core Collection (BKCI)

Interested in publishing with us?  
Contact [book.department@intechopen.com](mailto:book.department@intechopen.com)

Numbers displayed above are based on latest data collected.

For more information visit [www.intechopen.com](http://www.intechopen.com)



---

# Laparoscopic Approach to Incarcerated/Sliding Indirect Inguinal Hernia in Children in Comparison with Open Approach

---

Masao Endo, Michinobu Ohno, Fumiko Yoshida,  
Miwako Nakano, Toshihiko Watanabe and  
Etsuji Ukiyama

Additional information is available at the end of the chapter

<http://dx.doi.org/10.5772/58285>

---

## 1. Introduction

Usual elective open herniorrhaphy for pediatric indirect inguinal hernia is technically easy, with little variation. It becomes, however, much more difficult and troublesome, with a high incidence of postoperative complications, when the hernia contains incarcerated and/or sliding viscera [1 – 3].

Although the laparoscopic approach during pediatric herniorrhaphy has flourished worldwide, analysis of cohorts of hernia patients with incarcerated/sliding viscera or comparisons between traditional open herniorrhaphy and the laparoscopic approach have been scarce. The laparoscopic approach to such conditions is considered theoretically superior in terms of identifying the correct relation of the anatomic structures under direct vision [4 – 6]. The purpose of this paper is to analyze findings on indirect hernias with incarceration/sliding and to validate the efficacy of the laparoscopic approach in comparison with the open approach.

## 2. Materials and method

A consecutive series of 91 children with incarcerated/sliding hernia (I/SH), chosen from among 1, 768 children with indirect inguinal hernia/hydrocele, experienced during 11 years, were analyzed. The cohort consisted of 1, 043 boys and 725 girls, 83 with bilateral hernia, 1, 023 with

right hernia and 662 with left. Open herniorrhaphy (OH) with/without diagnostic laparoscopy or laparoscopic herniorrhaphy (LH) was selected according to parental preference under informed consent. Medical records of children with I/SH were selected and analyzed in terms of distribution of sex, age, kinds of viscera contained in the sac, operation time, intraoperative findings, and complications between OH and LH groups. Data from the whole cohort (WC) served as control. Children whose I/SH were solved by manual reduction before the operation were excluded from the analysis. Twenty patients who had complex procedures during the period of development of LH were excluded from the analysis and patients who underwent combined procedures affecting definitive herniorrhaphy were also excluded from the analysis of the operation time.

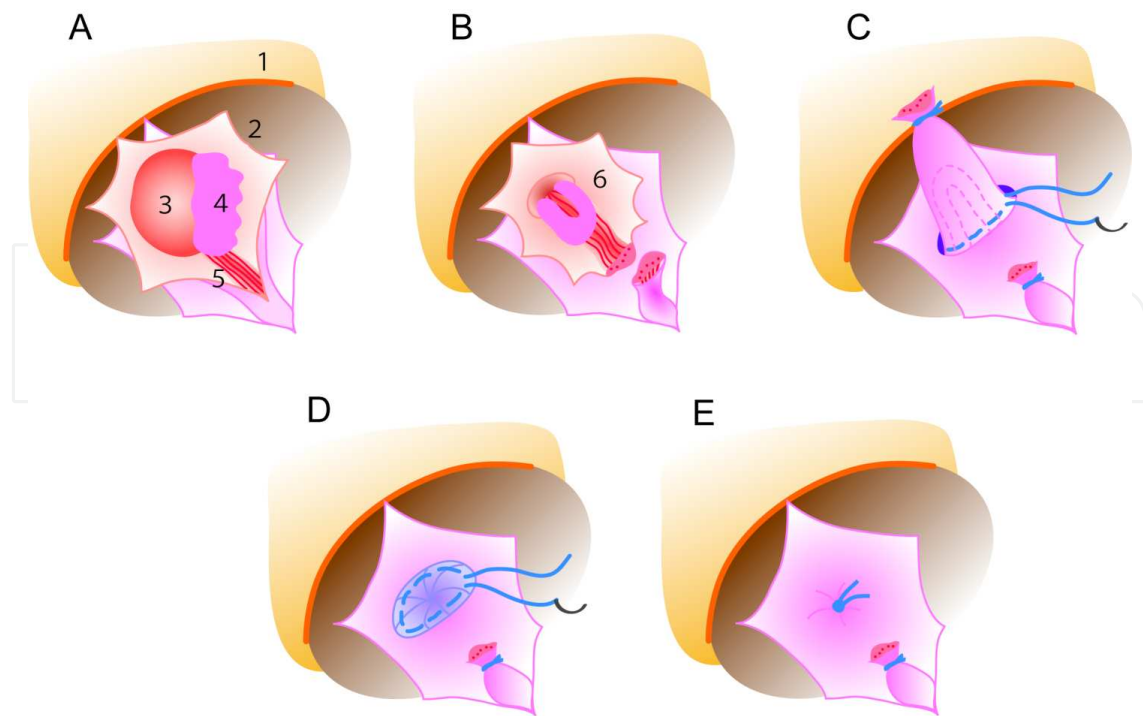
[Statistical analysis] Continuous data were expressed as the mean $\pm$  standard deviation (SD). Statistical significance was calculated using a two-tailed *t*-test. For proportional data, the chi-square test was used.

Operation method: In LH, bilateral internal inguinal rings (IIRs) and the condition of prolapsed viscera were inspected using a 5 mm laparoscope inserted through an umbilical incision with the assistance of a 2 mm grasper inserted through a stab wound in the midline just below the umbilicus. After the hernial content was reduced by a combined technique of external manual pressure and internal lead with a grasper, a circuit suture was placed around the IIR using an Endoneedle technique and knotted extracorporeally, resulting in complete closure of the IIR without any skip area. In female patients, after reducing the prolapsed viscera back into the peritoneal cavity, a circuit suture was placed distal to the U-turned Fallopian tube. The details of the patent processus vaginalis (PPV) closure have been described in a previous report [7, 8]. For infants below the age of 1y 6m, the IIR was closed with double ligation [7]. If a contra-lateral PPV (cPPV) was identified, it was closed.

In OH, the traditional procedure described in reference [9] was performed through a crease incision on the affected side. The hernial sac was opened and the prolapsed organ was pushed back into the abdomen. When a cPPV was noted by diagnostic laparoscopy via ipsilateral hernia sac, it was closed through a crease incision. For ovary/adnexa-containing inguinal hernia, IIR was closed using a modified Woolley technique [10] (Fig. 1).

### 3. Results

Demographic data of the patients are listed in Table 1. Ages in I/SH group averaged 1y11m in contrast to 3y10m in the WC ( $p < 0.05$ ). There were six patients with sliding or incarcerated cecum/appendix (0.3% of WC), 14 with incarcerated bowel loops (0.8%), 18 with incarcerated omentum (1.0%) and 53 with sliding/incarcerated ovary/adnexa (3.0% of WC and 7.3% of total girls). The average ages of the cecum/appendix group, the bowel loops group and the ovary/adnexa group were 8, 9 and 7 months, respectively. The ages of children with omental incarceration were different from those with other visceral incarceration/sliding (6y10m on average;  $p < 0.01$ ). Distinct distribution by sex was characteristic among kinds of contained viscera. Thirty-two I/SH (35.6%) were found in boys and 59 (64.8%) in girls. Of 725 hernias



**Figure 1.** Modified Wooley technique. Incarcerated ovary and fimbria are seen in the opened hernial sac (A). The ovary and fimbria have been pushed back into the peritoneal space. U – turned Fallopian tube remains in the sac. The round ligament is divided (B). The hernial sac is closed and ligated distal to the U – turned Fallopian tube. A purse – string suture is placed around the neck of the hernial sac (C). The proximal sac is then invaginated into the peritoneal cavity through the internal ring (D). The Purse – string suture is ligated. Z – suture placed through the transversals fascia is added if needed for tight closure. Numbers indicate; 1, upper leaf of the incision; 2, opened hernial sac; 3, ovary; 4, fimbria; 5, round ligament; 6, Fallopian tube.

in girls, 59 (8.1%) presented with I/SH, whereas, of 1, 043 hernias in boys, 32 (0.1%) presented with I/SH, suggesting a higher incidence of I/SH in girls than in boys ( $p < 0.05$ ). There was male preponderance accounting for 84.2% of group cecum/appendix, omentum and bowel loops. Laterality of hernia appearance showed right – side preponderance in the WC (bilateral 4.7%, right 57.9%, left 37.4%), while the I/SH group showed various distributions. Cecum/appendix incarceration/sliding was seen in the right – side group only; omental incarceration was seen in the right – and left – side groups at nearly equal rates, while bowel loops and ovary/adnexa revealed left – side preponderance (64% and 55%, respectively).

Distribution of operative procedures is seen in Table 2. Among 91 patients with S/IH, 76 (5.3% of whole LH) underwent LH and 15 (4.8% of whole OH) underwent OH (statistically not significant). LH/OH ratio in S/IH was compatible with those in the WC. The OH group consisted of one patient in each group, cecum/appendix, bowel loops and omentum, respectively. In the ovary/adnexa group, the LH/OH ratio (LH:OH=1:0.3) was compatible with those in the WC (1:0.2).

Mean operation time in the OH group was longer than in the LH group (53.7 minutes vs. 38.0). The difference between the LH and OH groups was statistically significant ( $p < 0.01$ ). Furthermore, the operation time in the OH group exceeded the averaged operation time of bilateral

OH in the WC (47.4 minutes,  $p < 0.05$ ), while in the LH group it was 38.0 minutes, resembling the bilateral LH in the WC (37.6 minutes) (Table 3). Regarding intraoperative complication, one girl in the OH group had an injury to the Fallopian tube and underwent anastomosis under a surgical microscope. Other major complications were not recognized in either group.

	Number	Age (year)	Sex	Sites
	(ratio to WC, %)	(mean +/- SD)	male : female	right : left : bilateral
Whole cohort (WC)	1,768	3.8 +/- 3.0	1.0 : 0.7	1.0 : 0.7 : 0.1
Incarceration/sliding	91 (5.1)	1.9 +/- 2.9	1.0 : 1.8	1.0 : 1.0 : 0.1
Cecum/appendix	6 (0.3)	0.7 +/- 0.6	1.0 : 0.00	1.0 : 0.0 : 0.0
Bowel loops	14 (0.8)	0.8 +/- 0.8	1.0 : 0.08	1.0 : 1.8 : 0.3
Omentum	18 (1.0)	6.8 +/- 2.8	1.0 : 0.04	1.0 : 0.9 : 0.1
Ovary/adnexa	53 (3.0, 7.3*)	0.6 +/- 0.8	0.0 : 1.00	1.0 : 1.2 : 0.1

Note: \*, ratio to total numbers of girl in the WC

**Table 1.** Demographic data of patients.

	Operative procedure				
	LH	LH : OH	OH	miscellaneous	Total
Whole cohort (WC)	1,438	1.0 : 0.2	310	20	1,768
Incarceration/sliding	76	1.0 : 0.2	15	0	91
Cecum/appendix	5	1.0 : 0.2	1		6
Bowel loops	13	1.0 : 0.08	1		14
Omentum	17	1.0 : 0.06	1		18
Ovary/adnexa	41	1.0 : 0.3	12		53

Abbreviations: LH, laparoscopic herniorrhaphy; OH, open herniorrhaphy

**Table 2.** Distribution of operative procedures.

	LH		OH
	(minutes, mean +/- SD)		(minutes, mean +/- SD)
Whole cohort *	37.6 +/- 13.9 (n=623)	$P < 0.01^{**}$	47.4 +/- 19.8 (n=62)
	n.s.***		$p < 0.05^{***}$
Incarceration/sliding	38.0 +/- 11.8 (n=73)	$P < 0.01^{**}$	53.7 +/- 22.7 (n=12)

Note: \*, operation time for bilateral repair; \*\*, statistical difference between LH and OH;

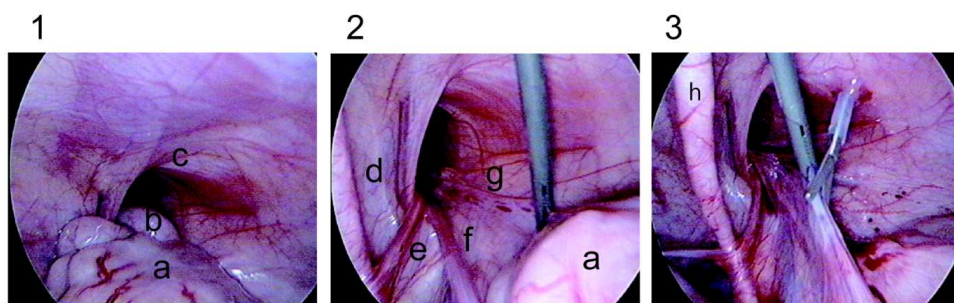
\*\*\*, statistical difference between whole cohort and Incarceration/sliding; n.s., not significant

**Table 3.** Operation times.

## 4. Characteristic findings according to the prolapsing viscera.

### 4.1. Cecum/appendix

Five of six patients underwent LH. Three exhibited appendicial sliding only. One of two boys with LH had a mesoappendix consisting of the hernial sac. The remaining three had cecum and appendix sliding. Two of these had a paracecal ligament sliding into the hernial sac. No inflammatory adhesion with PPV wall or appendicitis was noted and none of these patients had blood perfusion disorder. Appendectomy was not done in any case. After division of each ligament and reduction of the cecal wall and appendix, the IIR was closed just distal to the viscera. A representative case is shown in Fig. 2.



**Figure 2.** H.F., m, 7m, right indirect inguinal hernia. The cecum and appendix were found to slide into the hernial sac (1), which were easily pulled out remaining the paracecal ligament connecting to the vaginalis process (2). The paracecal ligament is being divided with an electro – scissors to make the cecum free in advance to closure of the PPV (3). Alphabets indicate; a, cecum; b, appendix; c, IIR; d, inferior epigastric vessels; e, spermatic cord; f, spermatic vessels; g, paracecal ligament; h, umbilical plica.

### 4.2. Bowel loops

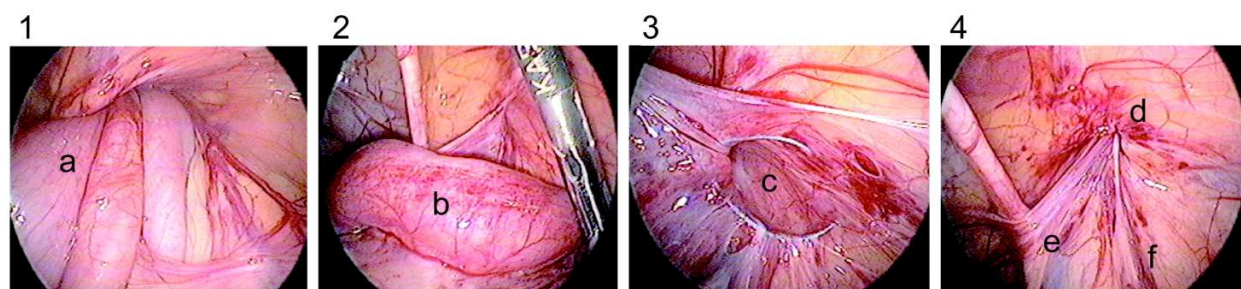
Thirteen out of 14 patients were found in the LH group. Nine out of the 14 patients exhibited large hernia with long small intestinal loop slipping into the PPV without strangulation, of whom one boy underwent OH. These patients had been born prematurely and had widely open IIR and large hernial sac, and the loops were easily reduced. Four boys had strangulated loops, which were reduced by extracorporeal manual pressure under laparoscopic control with the assistance of internal pulling with a grasper. They revealed various degrees of perfusion disorder associated with petechiae, and viability was ascertained during the procedure (Fig. 3).

Their PPV orifices were found to be disproportionately small. In one girl, sliding ovary/adnexa appeared after reducing incarcerated bowel loops (Fig. 4). One boy had a sigmoid colon incarceration, in which no mesosigmoid sliding into the hernial sac was seen.

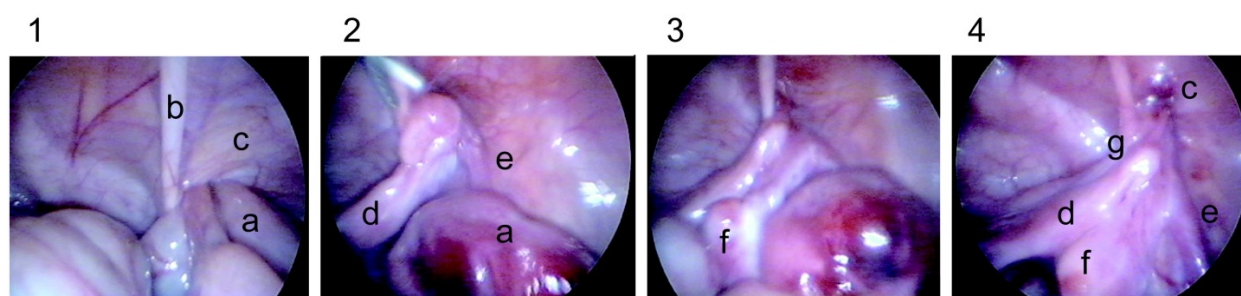
### 4.3. Omentum

In three patients, the preoperative diagnosis had been hydrocele. Seventeen out of 18 patients were included in the LH group. In six patients the omentum was found to slip into the PPV,





**Figure 3.** Y.H., m, 2y11m, right indirect inguinal hernia. Two loops of the small intestine were found to incarcerate into the hernial sac (1). The loops were pushed back into the peritoneal cavity from outside. Soon after released, the strangulated loop recovered leaving subserosal spotty hemorrhage (2). The suture has been placed around the IIR extraperitoneally, while the testicular vessels and spermatic cord were left intact (3). The end of the closure (4). Alphabets indicate; a, incarcerated bowel loop; b, subserosal petechiae; c, IIR encircled by extraperitoneally placed suture; d, closed IIR; e, spermatic cord; f, spermatic vessels.

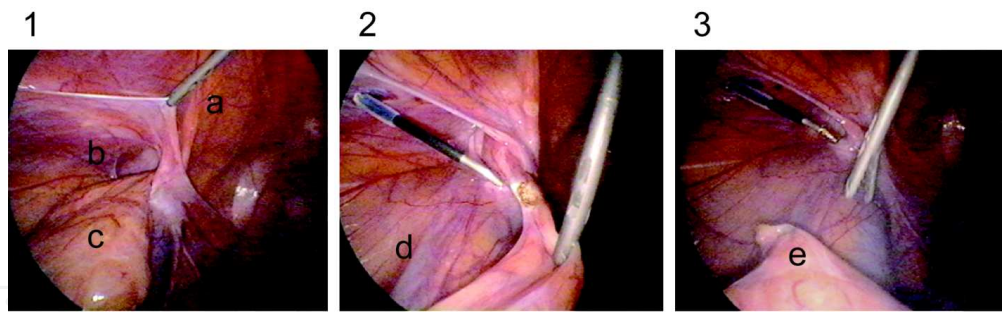


**Figure 4.** M.K., f, 8m, right indirect inguinal hernia. The incarcerated bowel loops are shown (1). The strangulated bowel loops have been released, while the ovary and adnexa remained in the sac. The bowel wall was partially associated with blood perfusion disorder with subserosal hemorrhage (2). In the next step, the ovary and adnexa were reduced. Spotty subserosal hemorrhages were seen also on the ovary (3). The IIR was closed distal to the U – turned Fallopian tube (4). Alphabets indicate; a, Incarcerated bowel loop; b, umbilical plica; c, IIR; d, uterus; e, ovarian vessels; f, ovary; g, U – turn point of Fallopian tube.

and was easily drawn out with a grasper. The remaining 12 patients had incarcerated omentum, where the tip of the omentum adhered to the bottom of the hernial sac. In two patients who underwent second – look herniorrhaphy for recurrence after previous OH, the omentum adhered to the operation scar in the recanalized PPV. In these cases, the omentum was reduced after dividing the tip with an electric scalpel (Fig. 5). Transient fluid accumulation in a distal sac with infarcted omental remnant occurred in one LH patient with incarceration of the omentum, which spontaneously disappeared during several days without sequela.

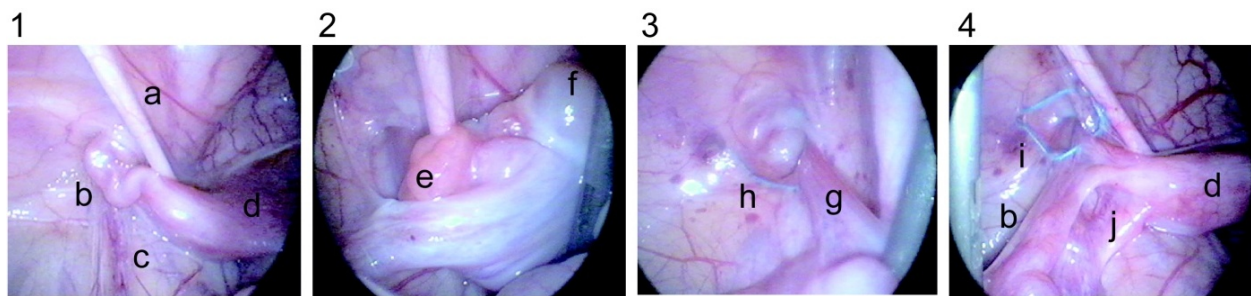
#### 4.4. Ovary/adnexa

Twelve out of 53 patients were repaired by OH. There were four patients with uterine protrusion adding to ovary/adnexa sliding, where the LH findings showed a part of the uterus shared their wall with the hernial sac as a true sliding component. Fifteen patients had ovary/adnexa incarceration, of whom one had bilateral ovarian incarceration. Thirty – four patients had ovary/adnexa sliding, of whom two had bilateral ovarian sliding and one was associated with small bowel loop incarceration – the same case as described in “bowel loops”. In all of



**Figure 5.** J.Y., m, 10y8m, left indirect inguinal hernia. The omentum had slipped into the vaginal process and its tip adhered to the bottom of the hernia sac (1). The omentum has been drawn out and is being cut off by an electrocautery at the adhesion point (2). The tip of the sliding omentum detached from the IIR (3). Alphabets indicate; a, umbilical plica; b, IIR; c, incarcerated omentum; d, spermatic vessels; e, detached omentum.

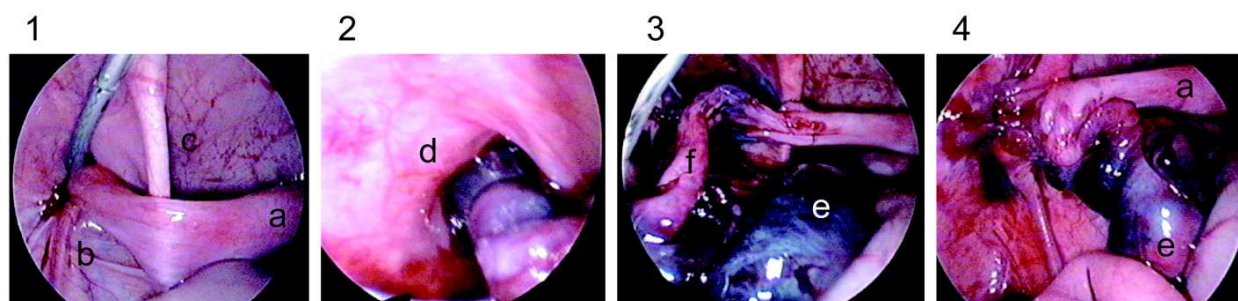
the patients, the uterus was found to be shifted to the affected side with shortened round ligament and the suspensory ligaments dislocated near the affected IIR (Fig. 6).



**Figure 6.** H.U., f, 2m, left indirect inguinal hernia. Sliding adnexa and the uterus shifting to the left side are shown (1). A scene showing released ovary and Fallopian tube (2). The ligamentum teres uteri stretched by a grasper with the sac inside out (3). The IIR encircled doubly (the first suture in a fashion of complete encircling and the second suture in interrupted one) distal to the running of the Fallopian tube (4). Alphabets indicate; a, umbilical plica; b, Fallopian tube running into the IIR; c, ovarian vessels; d, uterus shifted to the left; e, fimbria; f, ovary; g, round ligament; h, IIR encircled with first suture; i, IIR encircled with second suture; j, ovarian suspensory ligament.

In all of the patients with ovarian incarceration, the trapped ovary was twisted 240 to 1,080 degrees (Fig. 7). The uterus – containing hernia patients, whose ages ranged from one to 3 months, were repaired with OH in one case, whose prolapsing viscera were pushed back into the peritoneal cavity and the IIR was closed with a modified Woolley, and LH in three, in whom after reducing the prolapsed organs into the peritoneal cavity, an extraperitoneal circuit suture was placed doubly just distal to the uterine and adnexa, without any complication. In LH, all ovaries and uteri with Fallopian tube were released ultimately without conversion to OH, although extracorporeal manual reduction was not so easy, and pulling of the adnexa with grasper was not advisable because of the risk of damage to the Fallopian tube. One girl with ovarian sliding suffered an accidental cut of the Fallopian tube during OH, which was anastomosed under microscopic surgery.





**Figure 7.** M.S., f, 6m, bilateral indirect inguinal hernia. Incarcerated adnexa with blood around the left IIR (1). The adnexa rotating 1,080 degrees with strangulation (2). Released adnexa and ovary, which seemed necrotic (3). The IIR closed distal to the adnexa. Blood perfusion seems to begin returning (4). Alphabets indicate; a, uterus; b, ovarian vessels; c, umbilical plica; d, left IIR; e, ovary; f, Fallopian tube.

## 5. Discussion

Literature of the OH era has reported 12% incidence of incarceration/strangulation among 2,764 pediatric hernias on admission [11]. Operation for incarcerated hernia in infants is particularly difficult because the sac is edematous and readily torn, rendering the testicular vessels and the vas vulnerable to trauma [9]. Repair of the hernial sac is not easy and inspection of the hernial sac contents after reduction is extremely difficult [5]. The complication rate was higher in cases of incarcerated hernia [1]. The overall complication rate after elective hernia repair was approximately 2%; this rose to 19% to 31% following operation for incarcerated hernia [3, 11]. Reported complications include infarction or atrophy of the testis or ovary, acquired undescended testis, vas transaction, bowel obstruction, intestinal necrosis, wound infection, and recurrent hernia [3, 4]. Nah et al. [4] stated, in comparing the outcomes of laparoscopic vs. open repair of incarcerated inguinal hernia, that the laparoscopic technique appeared safe, avoided the difficult dissection of edematous sac in the groin, allowed inspection of the reduced hernia content and permitted the repair of a cPPV if present.

Our series involved patients with S/IH in 5.1% of 1,768 hernias, which showed lower incidence than Rowe's series [11], because our series contained only those patients who exhibited actual prolapse of the viscera into the hernial sac at the time of operation, and the patients whose S/IH had been reduced preoperatively was excluded. It has been stated that 45% to 84% of patients with incarcerated hernia on admission have successful manual reduction [3, 5].

Regarding the age distribution, 69% to 85% of the hernias occurred during the first year of life [3, 11]. In our series, 84.9% of patients were younger than one year of age. The reason why visceral protrusion tends to occur in young infants may be that in young infants the external inguinal ring is located so close to the IIR that the shortened inguinal canal becomes uncovered by musculature, and is thus vulnerable to increased intra-abdominal pressure [7]. In contrast, the average age of the patients with omental incarceration was six years. The reason here is that in the younger infants the omentum is still not well developed and needs several years to grow enough to reach the pelvic pouch.

Interestingly, Esposito et al. [5] reported that incarcerated hernia was more frequent in boys (65.2%) than in girls (27%), while Rowe et al. [11] mentioned slightly higher incidence in girls (17%) than in boys (12%). Our series showed significantly high incidence in girls. This may suggest higher rates of preoperative manual reduction in boys, while ovarian sliding or incarceration was not easy to be manually reduced. Actually, the incidence of I/SH in viscera other than ovary/adnexa was overwhelmingly high in boys (84.2%). In Rowe's series, 29% of incarcerated hernias in females required surgical reduction, compared with 17% in boys [11].

The proportion of OH and LH in ovary/adnexa S/IH was equal to the ratio in the WC, while those in the cecum/appendix, bowel loops and omentum groups were largely shifted to LH. This difference might be due to a bias of consideration of likelihood of operative difficulty in OH for incarcerated hernias. There was a tendency to attempt preoperative manual reduction more in the OH group among surgeons. The hernia content in 25 non – reducible hernias was reported as 60% in the adnexa/ovary, 36% in the bowel loops, 20% in the omentum group and 8% for the appendix group [5]. This was compatible with our series in terms of kinds and proportion of hernia content.

The presence of a vermiform appendix in the inguinal hernial sac is called Amyand's hernia, after the surgeon Claudius Amyand who reported the first case [12]. Most of these patients were male and the conditions of the herniated appendix were reported as normal, inflamed, or perforated. Some appendixes were found adhered to the inner hernial sac surface [13]. Preoperative diagnosis is said to be almost impossible, although ultrasound and computed tomography can help [14]. None of our patients underwent preoperative imaging, but intraoperative diagnosis was quite easy. Our series did not include the inflamed appendix. Fifty percent of our patients had mesoappendix or paracecal ligament sliding into the hernial sac. We are not aware of any paper that has reported cecal S/IH.

Bowel loop incarceration is the most serious condition in male infants. The conventional treatment is trial of manual reduction and to delay of surgical repair in order to reduce the surgical risk in a traumatized edematous anatomy [6]. In our OH group, patients were managed in this way, while in the LH group a too – strong manual reduction was avoided to prohibit the damage to the strangulated loop, because the loop should be controlled under laparoscopic direct vision. Our patients consisted of two groups: infants with a widely open IIR and large hernial sac, in which many bowel loops were contained but easily reduced by external manual compression under intraperitoneal direct inspection, and infants with narrow IIR and sac containing loops with various degrees of perfusion disorder. In the latter cases, difficulty was encountered at the IIR in reducing the bowel, although a combined technique of external manual pressure and internal pulling by forceps was ultimately successful. Vigorous grasping and pulling of the bowel loop induced damage to the intestinal serosa. In these cases, the dilation of the IIR with a retractor or adding of an incision to the internal oblique muscle would be recommended in OH [9].

Omental incarceration causing hydrocele has been reported [15]. Here, the average age was 4.5 years, a little bit lower than our series. In our series, three of 18 patients had been preoperatively diagnosed as hydrocele. In omental incarceration, 67% of patients had their omental tip adhered to the wall of the PPV. This might be an outcome of the role of the omentum, which

moves to the damaged part of the intraperitoneal organs, for example with inflammation, wall defect or hernia. The hernial sac containing omentum closely mimicked the soft hydrocele on palpation, especially when it was not reducible due to adhesion with the bottom of the hernial sac. The groin mass was soft, not reducible without pain or tenderness.

The advantage of LH was highlighted in female infants with sliding or incarcerated ovary/adnexa. Articles have reported that 15 – 22.4% of the inguinal hernias in female children are sliding hernias, and that the most frequently sliding organ is the ovary, followed by the Fallopian tubes [16]. Drawbacks associated with the reproductive system are a hidden but not a negligible problem. Fallopian tube obstruction or displacement of the ovary and Fallopian tube in the retroperitoneal space in a woman with a history of childhood inguinal herniorrhaphy has been reported as the cause of infertility [17 – 19]. We had an episode of injury to the Fallopian tube during OH for ovarian sliding hernia. OH requires the traction of the round ligament from the outside so as to obtain a good visual field and achieve high ligation [20], resulting in the remainder of the U – turned Fallopian tube in the hernial sac as acting a sliding component after reducing the ovary. Careless handling of the neck of the hernial sac can induce cutting or ligation of the Fallopian tube. Especially in female infant S/IH, the round ligament is shortened and the ovarian suspensory ligament is ventrally dislocated, facilitating the inducing of tubal occlusion as a postoperative complication [21].

Strangulation of irreducible ovaries has been reported with an incidence of 2% to 33% [22]. The incidence in our series was 28.3%. The laparoscopic findings suggested that the ovaries went into the inguinal canal through narrow IIR, twisting themselves. Uterus – containing inguinal hernia is an extremely rare condition, with 0.23% incidence [23]. The uterus may be free within the sac, adherent to the wall by adhesions or a true sliding component. [23]. In the treatment of ovary/adnexa I/SH including uterine sliding by LH, after reducing the prolapsing organs, the IIR was encircled by a suture proximal to the IIR level, placing all the surrounding viscera out of the IIR, without any special resources like OH.

In the international literature, a small number of studies have been published on laparoscopic treatment of incarcerated or sliding inguinal hernia, in particular a comparative study between laparoscopy and open surgery. Nah et al. [4] emphasized the superiority of LH in his comparative study from the viewpoint of operative complication, stating that LH presented a lower complication rate (4%) compared to OH (14%). Difficulties in identifying the correct relation of the anatomic structures, occasionally encountered in open procedures, practically almost never occur with the laparoscopic approach [6]. The advantages of the laparoscopic approach have been reported as follows: a lower incidence of complications, technically easy, all edematous tissue surgically bypassed, the cord structures not touched, reduction under direct visual control, inspection of the incarcerated organ at the end of procedure, simultaneous repair of cPPV if present [4, 5].

In our series, all the procedures with LH were completed without conversions, without serious complication and without recurrence, although all the procedures were successful also in OH, except for one Fallopian tube accident. The fact that mean operation time in the OH group exceeded the time of bilateral OH in the WC, while the time of the LH group was equal to the WC and shorter than for the OH group, indicates the technical easiness of LH. In traditional

open repair of I/SH, preoperative diagnostic imaging such as ultrasound and computed tomography have been recommended for differentiating the hernial content [14, 24, 25]. The laparoscopic approach could free patients from these preoperative examinations, because intraperitoneal inspection resolved every ambiguousness around the IIR and in the hernial sac.

## 6. Conclusion

The advantages of laparoscopic approach are that it is technically simple with short operation time, and that there is the possibility for direct inspection of incarcerated/sliding viscera before and after resolution, as well as closure of internal inguinal rings, avoiding injury to the reproductive systems. This comparative study has validated the feasibility of the laparoscopic approach, suggesting that this approach should be allowed to take the place of the gold standard in treatment of children with incarcerated/sliding indirect inguinal hernia.

## Author details

Masao Endo\*, Michinobu Ohno, Fumiko Yoshida, Miwako Nakano, Toshihiko Watanabe and Etsuji Ukiyama

\*Address all correspondence to: [emta@mxr.mesh.ne.jp](mailto:emta@mxr.mesh.ne.jp)

Department of Pediatric Surgery, Saitama City Hospital, Mimuro, Midori – ku, Saitama – shi, Japan

## References

- [1] Erdogan D, Karaman I, Aslan MK, Karaman A, Cavusoglu YH. Analysis of 3, 776 Pediatric Inguinal Hernia and Hydrocele Cases in a Tertiary Center. *J Pediatr Surg* 2013; 48(8) 1767 – 1772.
- [2] Niedzielski J, KrlR, Gawlowska A. Could Incarceration of Inguinal Hernia in Children be Prevented? *Med Sci Monit* 2003; 9(1) CR16 – 18.
- [3] Stylianos S, Jacir NN, Harris BH. Incarceration of Inguinal Hernia in Infants prior to Elective Repair. *J Pediatr Surg* 1993;28(4) 582 – 583.
- [4] Nah SA, Giacomello L, Eaton S, de Coppi P, Curry JI, Drake DP, Kiely EM, Pierro A. Surgical Repair of Incarcerated Inguinal Hernia in Children: Laparoscopic or Open? *Eur J Pediatr Surg* 2011; 21(1) 8 – 11.



- [5] Esposito C, Turial S, Alicchio F, Enders J, Castagnetti M, Krause K, Settini A, Schier F. Laparoscopic Repair of Incarcerated Inguinal Hernia. A Safe and Effective Procedure to Adopt in Children. *Hernia* 2013;17(2) 235 – 239.
- [6] Kaya M, Huckstedt T, Schier F. Laparoscopic Approach to Incarcerated Inguinal Hernia in Children. *J Pediatr Surg* 2006;41(3) 567 – 569.
- [7] Endo M, Watanabe T, Nakano M, Yoshida F, Ukiyama E. Laparoscopic Completely Extraperitoneal Repair of Inguinal Hernia in Children: A Single Institute Experience with 1, 257 Repairs Compared with Cut – down Herniorrhaphy. *Surg Endosc* 2009;23(8) 1706 – 1712.
- [8] Endo M, Ukiyama E. Laparoscopic Closure of Patent Processus Vaginalis in Girls with Inguinal Hernia Using a Specially Devised Suture Needle. *Ped Endosurg Innov Techn* 2001; 5:187 – 191.
- [9] Rowe MI, Lloyd DA. Inguinal Hernia. In: Welch KJ, Randolph JG, Ravitch MM, O'Neil JA Jr, Rowe MI. (eds.) *Pediatric Surgery 4thED*. Chicago, London: Year Book Medical Publishers; 1986. p779 – 793.
- [10] Woolley MM. Inguinal hernia. In: *Pediatric Surgery 3rdED*. Chicago: Year Book Medical Publishers; 1979. p815.
- [11] Rowe MI, Clatworthy HW. Incarcerated and Strangulated Hernias in Children. A Statistical Study of High – risk Factors. *Arch Surg* 1970;101: 136 – 139.
- [12] Lombardo V, Pavone G. Intraoperative Finding of Amyand's Hernia in a Recurrent Inguinal Hernia. Report of a Case. *Ann Ital Chir* 2013; 84: 583 – 584.
- [13] Okur MH, Karacay S, Uygun I, Topcu K, Ozturk H. Amyand's Hernias in Childhood (a Report on 21 Patients): a Single – center Experience. *Pediatr Surg Int* 2013; 29(6) 571 – 574.
- [14] Michalinos A, Moris D, Vernadakis S. Amyand's Hernia: a Review. *Am J Surg* 2013, pii: S0002 – 9610(13)00646 – 6. Doi: 10.1016/j.amjsurg.2013.07043. [Epub ahead of print]
- [15] Kapisiz A, Karabulut R, Turkyilmaz Z, Sonmez K, Basaklar AC. Omental Incarceration may Cause Hydrocele and this Hydrocele Confused Simple or Scrotal Hydrocele. *Hernia* 2011; 15(1) 43 – 45.
- [16] Turk E, Fescekoglu OR, Acari C, Karaca F, Bilen CM, Edirne Y, Karakaya E. Sliding Hernia in Female Children. *Acta Chir Belg* 2013; 113(4) 281 – 284.
- [17] Swanson JA, Chapler FK. Infertility as a Consequence of Bilateral Inguinal Herniorrhaphies. *Fertil Steril* 1977; 28(10) 1118 – 1120.
- [18] Cam C, Celik C, Sancak A, Iskender C, Karateke A. Inguinal Herniorrhaphy in Childhood may Result in Tubal Damage and Future Infertility. *Arch Gynecol Obstet* 2009; 279(2) 175 – 176.

- [19] Gueth U, Renner R, Egelhof T, Singer G, Holzgreve W, Mayr J. Retroperitoneal Displacement of Ovary and Fallopian Tube: a Complication of Surgical Management of Incarcerated Inguinal Hernia in Female Infants. *J Pediatr Surg*; 2007; 42(5) E33 – 35.
- [20] Endo M, Ohno M, Yoshida F, Nakano M, Watanabe T, Ukiyama E. Laparoscopic Hernia Repair and its Validation by Second – look Inspection to Internal Inguinal Rings in Children with Patent Processus Vaginalis. In: Meinhold – Heerlein I. (ed.) *Laparoscopy – An Interdisciplinary Approach*. Rijeka: InTech; 2011. p133 – 146. Available from <http://www.intechopen.com>
- [21] Hirabayashi T, Sakoda A, Kawano T. Ventrally Dislocated Attachment of the Ovarian Suspensory Ligament, a Risk Factor for Tubal Occlusion as a Postoperative Complication of Inguinal Hernia Repair: Efficacy of Laparoscopic Inguinal Hernia Repair for Preventing Tubal Damage. *Pediatr Surg Int* 2012; 28(11) 1089 – 1094.
- [22] Boley SJ, Cahn D, Lauer T, Weinberg G, Kleinhaus S. The Irreducible Ovary: a True Emergency. *J Pediatr Surg* 1991; 26(9) 1035 – 1038.
- [23] Akillioglu L, Kaymakci A, Akkoyun I, Guven S, Yucesan S, Hicsonmez A. Inguinal Hernias Containing the Uterus; a Case Series of 7 Female Children. *J Pediatr Surg* 2013; 48(10) 2157 – 2159.
- [24] Narci A, Korkmaz M, Albyrak R, Sozubir S, Guvenc BH, Koken R, Demir T, Dogru O. Preoperative Sonography of Nonreducible Inguinal Masses in Girls. *J Clin Ultrasound* 2008; 36(7) 409 – 412.
- [25] Akfirat M, Kazez A, Serhatilioglu S. Preoperative Sonographic Diagnosis of Sliding Appendicular Inguinal Hernia. *J Clin Ultrasound* 1999; 27(3) 156 – 158.

