

We are IntechOpen, the world's leading publisher of Open Access books Built by scientists, for scientists

4,800

Open access books available

122,000

International authors and editors

135M

Downloads

Our authors are among the

154

Countries delivered to

TOP 1%

most cited scientists

12.2%

Contributors from top 500 universities



WEB OF SCIENCE™

Selection of our books indexed in the Book Citation Index
in Web of Science™ Core Collection (BKCI)

Interested in publishing with us?
Contact book.department@intechopen.com

Numbers displayed above are based on latest data collected.

For more information visit www.intechopen.com



Traumatic Cloaca

Constantine P. Spanos

Additional information is available at the end of the chapter

1. Introduction

Traumatic cloacal deformities are a result of major obstetric injury; these usually occur after a fourth-degree perineal laceration. They occur in one in 5000 vaginal deliveries. [1] This deformity is characterized by three anatomic lesions: complete disruption of the perineal body, anterior defect of the internal and external anal sphincter, and loss of the distal rectovaginal and/or anovaginal septum. [2-4] Thus, a common genitourinary and gastrointestinal outlet ensues, as in congenital cloaca. This is the cause of symptoms and disorders related to this condition.

Resulting disorders are mostly functional. These patients suffer from severe incontinence to flatus, liquid and solid stool. Recurrent urinary tract and vaginal infection may also result. Sexual dysfunction is significant; patients often complain of dyspareunia [4] or refrain from sexual activity altogether. Partners are also affected. All these disorders may lead to psychological disorders and social distress associated with incapacitating incontinence as well as a sense of shame from the “deformity”. [3-6] A nihilistic approach from both the patient and physicians may lead to delay in treatment, thus burdening the patient with years of suffering and diminished quality of life.

There are several reports and series in the literature describing techniques for repairing traumatic cloacal deformities. There is considerable variety regarding the use or not of flaps, the use or not of fecal diversion. In any case, repair of these deformities can be challenging and complex, and patients may present years after the initial injury. Some may have had a previous repair, thus adding difficulty to definitive correction.

2. Etiology

Traumatic cloaca is usually the result of obstetric injury. The most common injuries involved are third and fourth-degree perineal lacerations. Third-degree lacerations are characterized by disruption of the internal and external anal sphincter. In fourth-degree lacerations, disruption of the anal and/or rectal epithelium is included in addition to sphincter injury. Surgical correction of these types of injuries involves precise, layered approximation of damaged structures and tissues. Failure of repair may be a result of hematoma, infection or technical mishaps. Partial failure may result in a rectovaginal fistula; complete failure leads to a cloacal deformity. [8] Traumatic cloaca may occur if these obstetric injuries of this nature are not repaired, or after failure of surgical repair. This may be secondary to poor surgical technique or a complication such as infection and disruption of the layered repair.

The resulting deformity is three-dimensional absence of the perineal body, disruption of the sphincter complex and loss of the anovaginal/anorectal septum of varying length.

3. Signs and symptoms

Most, if not all, women with traumatic cloacae have severe incontinence to flatus, liquid and solid stool. These patients also suffer from sequelae of the communication of the gastrointestinal and genitourinary tract; namely, severe perineal skin irritation, as well as recurrent urinary tract and vaginal infections. Sexual function is seriously affected. Many patients complain of dyspareunia, and abstinence from sexual activity is not uncommon. Thus, spouses and sexual partners are also affected by this disorder.

Traumatic cloaca may lead to psychological disorders and social distress associated with incapacitating incontinence as well as a sense of shame from the "deformity". Many patients with this disorder isolate themselves socially and suffer from anxiety and depression. [3-6] A nihilistic approach from both the patient and physicians may lead to delay in treatment, thus burdening the patient with years of suffering and diminished quality of life.

4. Diagnosis

A careful obstetric history and detailed physical exam of the perineal area is enough to make the diagnosis of traumatic cloaca. Inspection reveals the diminution or absence of the perineal body and the common genitourinary-gastrointestinal outlet. (Fig1, 2) A digital exam will reveal the length of the remaining anovaginal/rectovaginal septum as well as the relationship of the cervix with the rectum. This will aid in planning the appropriate surgical repair. The examining physician will also note a significant decrease in resting anal sphincter tone as well as a marked loss of voluntary squeeze pressure.

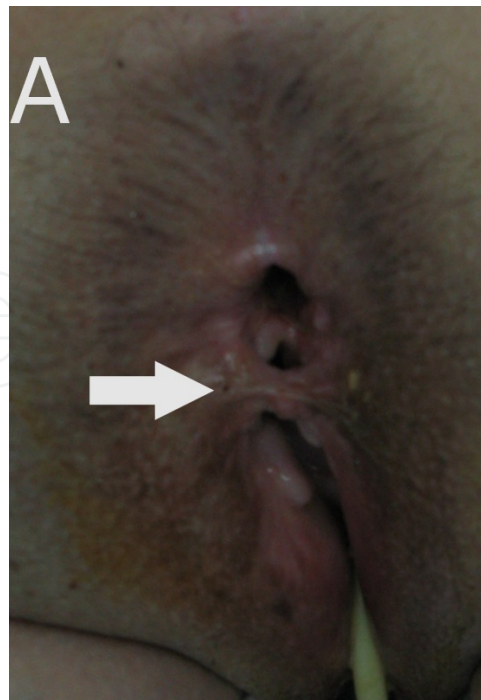


Figure 1. Traumatic cloaca with small bridge of skin between anus and vagina.

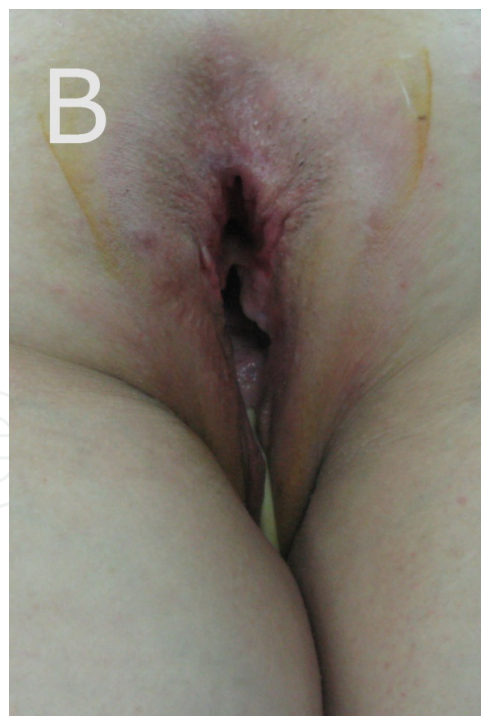

Figure 2. Traumatic cloaca. Note the incomplete anovaginal septum.

Additional diagnostic tests can be performed but are not mandatory. Endoanal ultrasound can be utilized to define the degree of the external and internal anal sphincter defect. In most cases,

a significant defect of the anterior portion of both sphincters is present. Anal physiologic testing such as manometry documents the decrease in resting tone and squeeze pressure. Improvement in these parameters can be assessed after surgical repair of traumatic cloaca. Finally, transanal pudendal nerve stimulation provides evaluation of the neuromuscular integrity of the pelvic floor. [11] Pudendal nerve terminal motor latency can be used to predict the success of sphincteroplasty in incontinent patients with anterior sphincter defects. [12] Assessment of fecal incontinence can be performed with any number of validated tests such as the Cleveland Clinic Florida-Wexner Score or the St. Marks' incontinence score. [1, 13]

5. Treatment

Women with a traumatic cloaca defect are incapacitated in many aspects. Severe incontinence may lead to social isolation. Sexual dysfunction may result in depression and other psychological disorders. Both the patient and the obstetrician may be unaware that such defects can be repaired; therefore, traumatic cloaca may go untreated for many years.

The mainstay of conservative treatment is manipulation of stool consistency and frequency. This is done with fiber bulking and constipating medication such as loperamide. While this type of therapy is valid, results are not satisfactory. The anatomic defects that are associated with traumatic cloaca are such that severe incontinence persists despite conservative therapy. Surgical correction is usually necessary.

6. Surgical treatment

A variety of surgical techniques have been utilized to repair traumatic cloaca.

Surgical correction of these defects invariably involves the following steps:

1. Separation of the anorectum from the vagina by dissecting the rectovaginal septum.
2. Performance of an overlapping sphincteroplasty using both the external and internal anal sphincter, thus repairing the anterior defect.
3. Reconstruction of the perineal body by plicating the puborectalis muscle to the midline and skin closure.

6.1. Perineoplasty with X-flaps

This surgical technique was originally described by Corman [6] and was used both for traumatic cloaca repair as well as rectovaginal fistula repair. It is the technique most commonly used at our institution.

Preoperatively, all patients are given a full bowel preparation. Intravenous broad-spectrum antibiotics are administered preoperatively and continued for 24 hours post-surgery. The

procedure is performed under general anaesthesia and the patient is placed in the prone-jackknife position with the buttocks taped apart and a urinary catheter in place.

The planned incisions are marked on the skin, where an "X" is outlined across the perineum, intersecting at the point of the anovaginal septum. (Fig 3)

The skin incision is performed, and flaps are developed to the ischioanal fossae bi-laterally. Dissection is then carried out in the ischioanal fossa cephalad up to the level of the levator muscles. (Fig 4)

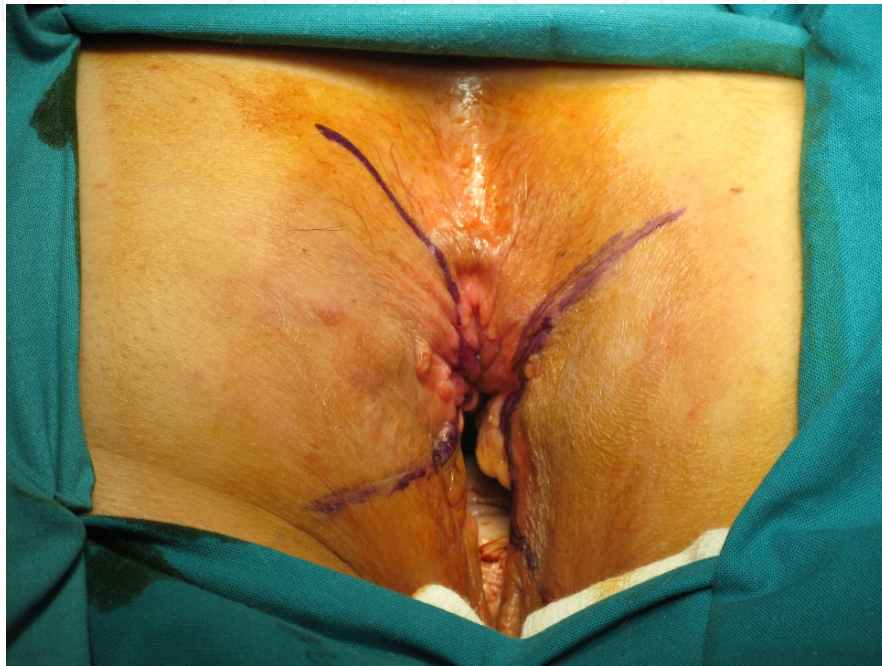

Figure 3. Outline of "X" incision on perineum.

The next step is division of the ano-vaginal/rectovaginal septum. Initially, traction sutures are placed in the anal and vaginal mucosa. Then, the septum is divided with electrocautery, and dissection is carried out cephalad up to the level of the puborectalis muscle. (Fig 5) This division allows for mobilization of both the rectal and vaginal "tubes". During the following step, both edges of the sphincter complex are identified. Mobilization of the sphincter complex is performed lateral to medial. An overlapping sphincteroplasty was then done with interrupted sutures. At all times, a small retractor is placed in the anal canal, in order to prevent stenosis after repair. Midline approximation of the levators is performed with interrupted 2-0 polypropylene sutures, thus filling the space between the anal and vaginal tubes and re-creating a perineal "body". Overlapping of the "X" flaps is then undertaken. The anterior wall of the anus and the posterior wall of the vagina are sutured to the skin of the newly constructed perineum. Layered closure with absorbable sutures is performed. (Fig 6) No drains are placed, and we do not routinely create a diverting stoma.

Postoperatively, betadine ointment is applied to the wounds daily. Metronidazole is given orally for 7 days. Patients are allowed moderate ambulation immediately; however, sitting is

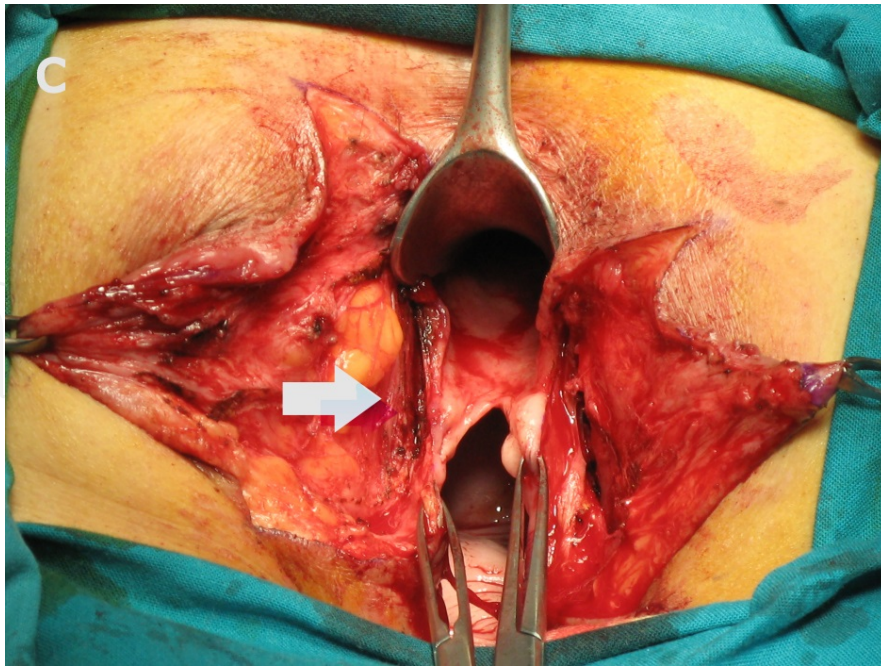


Figure 4. Flaps have been developed, and dissection up to the level of the puborectalis (arrow) is performed.

discouraged. Pharmacological bowel confinement is achieved by administering loperamide thrice daily for 5 days. A soft diet is started on the second postoperative day. Fiber supplements are given after discontinuation of loperamide.

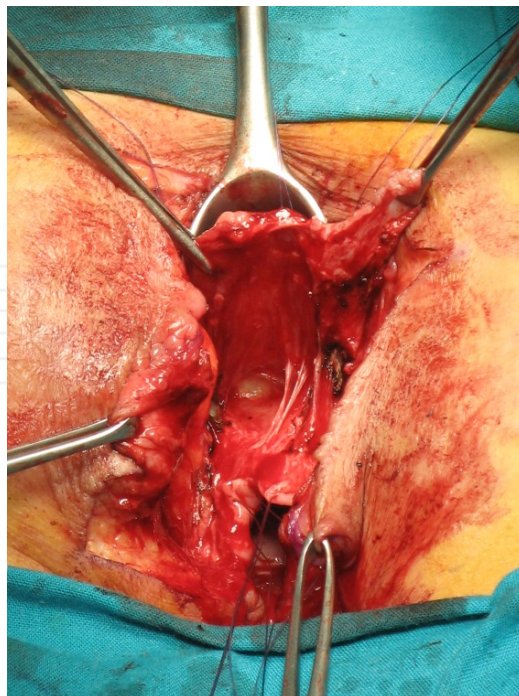


Figure 5. Divided anovaginal septum, with posterior vaginal wall superiorly.

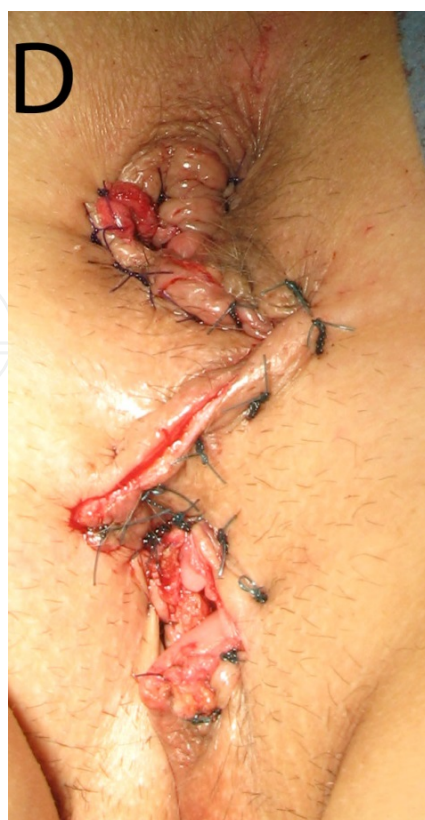

Figure 6. Completed repair, with separation of anus and vagina and restoration of perineal body.

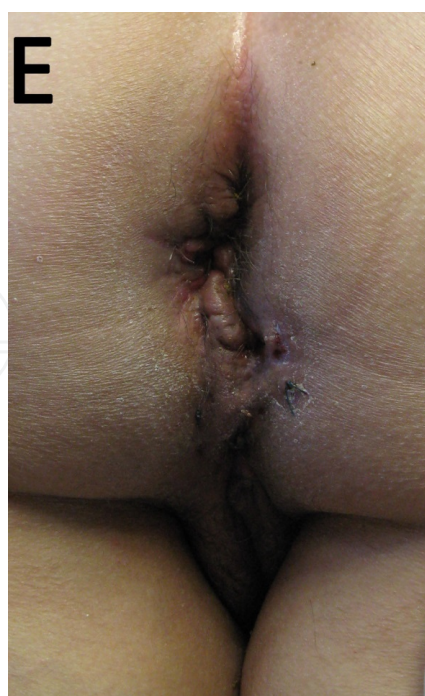

Figure 7. Repair at one month after surgical correction.

6.2. Transverse to vertical incision

An alternative technique, especially in patients with a low-profile perineum, (Fig 8) utilizes a transverse incision, made between the anus and vagina. This incision may also be curvilinear. Dissection of the ischiorectal fossae, division of the anovaginal septum, levatoroplasty and overlapping sphincteroplasty are performed in a fashion similar to the patients with the “X” flaps. The transverse incision is closed in a vertical fashion, thus creating a high-profile perineum. (Fig 9)

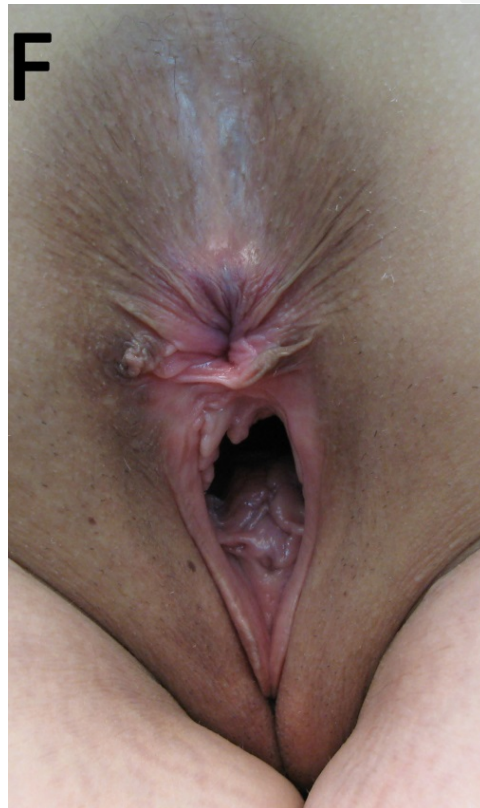

Figure 8. Patient with a low-profile perineum after obstetric injury. This patient underwent surgical correction utilizing a transverse-to vertical perineal incision.

6.3. Island flaps

Instead of primary closure of the skin, which is used in the techniques mentioned previously, perineal closure can be achieved by using island skin flaps.

Draganic and Solomon have reported their experience with island flap perineoplasty and concluded that wound dehiscence was significantly lower when skin flaps rather than simple wound approximation was used for perineal closure. [7] In their series, they performed a faecal diversion in 75% of their patients.

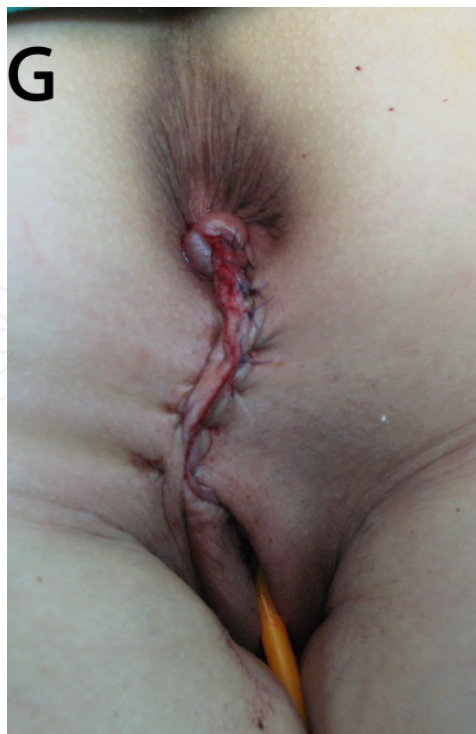

Figure 9. Postoperative photo of patient in previous figure. Result after vertical closure of incision, with restoration of perineal body.

7. Results of surgical correction

Despite the variety of techniques used in the correction of traumatic cloacal deformities, data on the outcome of these procedures is limited. Most reports are based on small series of patients; meta-analyses regarding results have not been performed.

The largest series of patients utilizing X-flaps for traumatic cloaca correction has been reported by Kaiser [4]. Twelve patients underwent this procedure in a 5-year period. No prophylactic diverting stomas were constructed. Three patients experienced postoperative rectovaginal fistula, and in one of these patients a stoma was necessary. Minor wound complications were observed in 8 patients. After surgical follow-up of 9.83 ± 2.8 months and long-term follow-up of 38.9 ± 6.9 months, all the patients were satisfied with regards to overall function, continence and cosmetic result.

In our own small series of 4 patients, mean hospital length stay was 5 ± 0.8 days (range 4-6). All patients were followed in the outpatient clinic weekly for the first month, then monthly for the next 3 months. Median follow-up was 27 months (range 10 – 52 months). One patient developed a small, superficial separation of the corner of the X-flap. This was resolved by placing sutures. One patient experienced significant constipation at 2 weeks postoperatively. This was treated with manual disimpaction and subsequent small-volume enemas. There were no wound infections, separation of the sphincter repair, or rectovaginal fistulas. At 1 month post-repair there was excellent healing of all wounds. (Fig 7)

At the latest follow-up visit, all patients reported significant improvement in fecal continence. The mean Cleveland Clinic Florida/Wexner score decreased from a mean preoperative value of 18.25 ± 0.95 to a postoperative value of 1.25 ± 1.5 . All patients required fibre supplement to maintain stool consistency. None of the patients required use of pads, and major incontinence episodes were ameliorated.

Regarding sexual activity, all patients were empirically advised to resume vaginal intercourse 3 months after repair. All patients resumed activity; one patient complained of dyspareunia at the end of the follow-up period.

Venkatesh and Ramanujam [3] reported surgical correction of traumatic cloaca in 44 patients over a 14-year period. The technique involved approximation of the internal and external sphincters together with the transverse perineal muscles in a vest-over-pants manner. The transverse perineal incision was closed vertically. The authors reported excellent functional results with minimal morbidity. A diverting stoma was not performed. Dyspareunia was reported in 27% of patients.

Excellent functional results have been also reported by Abcarian et al. [2] Their group performed surgical correction in 43 patients. Anal physiological testing was done preoperatively and postoperatively; most parameters (resting tone and voluntary squeeze pressures) return to normal after surgery.

Hollingshead et al reported on their experience in repairing traumatic cloacal deformities. [1] Twenty-nine patients underwent surgical repair over a 14-year period. The technique employed a curvilinear incision, division of the anovaginal septum, identification and mobilization of the cut sphincter edges. Then the anorectal defect was closed, a sphincteroplasty performed and the vagina repaired. In this series, the puborectalis or levator muscles were not plicated, and the initial incision was closed longitudinally. A stoma was constructed in 13 patients. Two out of 12 patients in whom a stoma was not fashioned at the time of repair developed a rectovaginal fistula and required subsequent bowel defunctioning. In most patients, improvement in incontinence scores, anophysiologic testing and sexual function.

8. Discussion

Traumatic cloacal deformities are rare post-obstetric injuries characterized by diminution or disruption of the perineal body, anterior division and lateral retraction of the anal sphincters, and loss of the distal ano/rectovaginal septum of varying length. [1-6]

These deformities may be a result of a third or fourth degree perineal laceration, which may or may not have been repaired. Failure of repair may be a result of hematoma, infection or technical mishaps. Partial failure may result in a rectovaginal fistula; complete failure leads to a cloacal deformity. [8]

Most, if not all patients have complete loss of defecatory control. This leads to skin irritation, genitourinary infections and a significant degree of sexual dysfunction.

The effect on the quality of life of these patients is profound. Patients feel "deformed", and may isolate themselves. Medical advice may be deferred for years. On the other hand,

physicians may be unaware of the possibility of repair of such lesions and fail to refer to a specialist.

Conservative measures and/or pharmacologic manipulation of bowel movements do not improve quality of life and is not a sustainable treatment modality for this condition. Surgical treatment is required.

As in our small series, other authors have reported prior attempts to repair either a perineal laceration or a cloacal deformity before definitive correction. [2, 4] The timing of this definitive repair is extremely important. Early surgical repair may lead to failure as a result of active inflammation and absence of dissection planes. Therefore, most experts advise a waiting time of at least 3 months after index injury or previous repair before correction is undertaken. [2, 6]

Even though these lesions are rare, a variety of surgical techniques for correction have been described. [2-7] Most employ overlapping sphincteroplasty and division of the rectovaginal septum. Perineal body construction is performed in several ways. Closure at right angles to the original incision is one of the most common modes of perineal reconstruction. Others use island flaps or lotus petal flaps. [7, 10] Some authors advise partial closure of the wound, as to avoid wound infection, which is the most serious complication of cloacal repair. [2, 9]

Anovaginal and perineal reconstruction utilizing X flaps was initially described by Corman. [6] Kaiser reported a series of 12 patients in which improvement in fecal continence and sexual function was significant. [4] Possible downsides of this technique in comparison with others are the intrinsic complexity of the operation and potential problems with wound healing, specifically ischemia of the flaps. On the other hand, partial closure of a perineal wound may take time to heal, and may require multiple dressing changes and visits to clinic.

We believe the most important technical point in correction of cloacal deformities is the division of the anovaginal/rectovaginal septum, with mobilization of the anorectal and vaginal tubes. Herein lays the potential for failure of the repair. Several points regarding this division are important.

Firstly, meticulous hemostasis is mandatory. The vagina is an extremely vascular anatomical structure; large vessels (especially veins) surround it. A fair amount of bleeding may be encountered during anovaginal separation if an incorrect plane is entered. Hematoma formation with potential infection and abscess formation may lead to catastrophic results. Second, care should be taken not to "buttonhole" either the anorectum or vagina during this dissection. Unrepaired perforations in either structure may also lead to septic collections and failure of the operation. Third, interposition of tissue in the space created by the division must be utilized. This constructs a perineal body and supports the sphincteroplasty. It also fills dead space and eliminates the possibility of fluid collections, which, as mentioned before, may lead to failure. Plication of the puborectalis muscle seems to be the easiest choice of tissue for this interposition, since it is in immediate anatomical proximity. Other potential techniques should the puborectalis prove to be inadequate, are utilization of a bulbocavernosus (Martius) flap, or a gracilis muscle flap. This could add significant complexity to the repair, however.

Some authors advocate construction of a temporary stoma. [1, 10] Proponents of fecal diversion maintain that this allows accelerated perineal healing and avoidance of infection and failure of the repair. The mechanics of defecation in the immediate perioperative period may also

potentially lead to disruption of the puborectalis plication or other tissue interposition. Stomas are associated with significant morbidity (skin irritation, prolapse, hernia), and need a second operation for closure. [8, 9] In addition, they do not seem to improve outcomes. Some experts reserve diversion for major failure of the perineal repair. [3, 4]

The most common complications reported after correction of traumatic cloacal deformities are minor wound infection, rectovaginal fistula and breakdown of the perineal wound. These may occur in up to 40% of cases [1]. Expectant therapy and revision of repair are utilized in these instances [1, 4]

After definitive correction of traumatic cloacal deformities, sexual activity and subsequent pregnancies should be deferred; however, the exact "safe" time period remains to be determined. Some authors advise sexual abstinence for at least 6 weeks post repair. [8] Caesarean section after complex perineal repairs seems reasonable.

Finally, improvement in fecal incontinence is significant following cloacal repair in most series even after long-term follow-up. [1, 3, 4].

9. Conclusion – Summary

Traumatic cloacal deformities are the least frequent complications of obstetric injuries to the anorectum. Repair and reconstruction of all anatomical structures involved is feasible with satisfactory cosmetic and functional results. Correction of these deformities can be performed using a variety of techniques. Careful dissection and division of the anovaginal/rectovaginal septum is a crucial step in the creation of a new perineal body. Referral to a specialist colorectal surgeon familiar with repair of traumatic cloacal deformities may improve the quality of life of patients. Fecal diversion is not mandatory.

Author details

Constantine P. Spanos*

Address all correspondence to: costasspanos@hotmail.com

Department of Surgery, Aristotelian University, Thessaloniki, Greece

References

- [1] Hollingshead JRF, Warusavitarne J, Vaizey CJ, Northover JMA. Outcomes following repair of traumatic cloacal deformities. *Br J Surg* 2009;96:1082-1085

- [2] Abcarian H, Orsay CP, Pearl RK, et al. Traumatic cloaca. *Dis Colon Rectum* 1989;32:783-787
- [3] Venkatesh KS, Ramanujam P. Surgical treatment of traumatic cloaca. *Dis Colon Rectum* 1996;39:811-816
- [4] Kaiser AM. Cloaca-like deformity with fecal incontinence after severe obstetric injury-technique and functional outcome of ano-vaginal and perineal reconstruction with X-flaps and sphincteroplasty. *Colorectal Dis* 2008;10:827-832
- [5] Mercês RL, Pisi PH, Balestrim Fo A, et al. Surgical treatment of traumatic cloaca. *Acta Cir Bras* 2008; 23 Suppl 1, 1:105-107
- [6] Corman, ML. Anal incontinence following obstetrical injury. *Dis Colon Rectum* 1985;28 :86-89
- [7] Draganic B, Solomon MJ. Island flap perineoplasty for coverage of perineal skin defects after repair of cloacal deformity. *ANZ J Surg* 2001;71:487-490
- [8] Spanos CP, Mikos T, Kastanias E, et al. Surgical treatment of traumatic cloaca. *Arch Gynecol Obstet* 2012;286:815-818
- [9] Valente MA, Khanduja KS. Layered surgical repair of traumatic cloacal deformities: technical details and functional outcomes. *Tech Coloproctol* 2012; 16:153-156
- [10] Altomare DF, Rinaldi M, Bucaria V, et al. Overlapping sphincteroplasty and modified lotus petal flap for delayed repair of traumatic cloaca. *Tech Coloproctol* 2007; 11:268-270
- [11] Kiff ES, Swash M. Slowed conduction in the pudendal nerves in idiopathic (neurogenic) fecal incontinence. *Br J Surg* 1984; 71:614-16
- [12] Wexner SD, Marchetti F, Jagelman DG. The role of sphincteroplasty for fecal incontinence reevaluated: prospective physiologic and functional review. *Dis Colon Rectum* 1996; 39:1164-70
- [13] Jorge JM, Wexner SD. Etiology and management of fecal incontinence. *Dis Colon Rectum* 1993; 36:77-97

