

We are IntechOpen, the world's leading publisher of Open Access books Built by scientists, for scientists

4,800

Open access books available

122,000

International authors and editors

135M

Downloads

Our authors are among the

154

Countries delivered to

TOP 1%

most cited scientists

12.2%

Contributors from top 500 universities



WEB OF SCIENCE™

Selection of our books indexed in the Book Citation Index
in Web of Science™ Core Collection (BKCI)

Interested in publishing with us?
Contact book.department@intechopen.com

Numbers displayed above are based on latest data collected.
For more information visit www.intechopen.com



Paraplegia as a Complication of Thoracic and Thoracoabdominal Aortic Interventions

Anisha H. Perera and Richard G.J. Gibbs

Additional information is available at the end of the chapter

<http://dx.doi.org/10.5772/57528>

1. Introduction

1.1. The thoracic aorta, its conditions and their management

The thoracic aorta The thoracic aorta comprises the ascending aorta, transverse aortic arch and descending thoracic aorta (Figure 1). The aortic arch is the segment from where the carotid and subclavian vessels arise. The descending thoracic aorta begins immediately distal to the left subclavian artery and extends up to the diaphragm. A thoracic aortic aneurysm (TAA) is defined as dilatation of the thoracic aorta to a diameter at least 1.5 times greater than is normal at a given aortic level (Figure 2). Thoracoabdominal aortic aneurysms (TAAA) involve the thoracic aorta and extend into the abdominal aorta. They are classified according to the Crawford classification as types I to IV. Due to their extent and frequent involvement of the visceral vessels, management is invariably complex. TAAs often result from cystic medial degeneration weakening of the aortic wall, though the majority are associated with atherosclerosis and risk factors such as hypertension, hypercholesterolemia and smoking. These aneurysms occur most frequently in the 6th and 7th decade of life. In younger patients TAA is commonly associated with connective tissue disorders such as Marfan, Ehlers-Danlos and Loeys-Dietz syndromes. Acute aortic syndrome comprises a spectrum of emergency conditions caused by disruption of the medial layer of the aortic wall, which includes aortic dissection, intramural haematoma and penetrating atherosclerotic ulcers. Thoracic aortic dissection (TAD) is defined as separation of the aortic media, with the presence of extraluminal blood within the layers of the aortic wall (Figure 3).

Asymptomatic and small TAAs are initially managed medically, whilst symptomatic (usually pain or compression symptoms) or rapidly expanding aneurysms as well as those greater than 6cm in diameter necessitate surgical intervention to prevent rupture. TADs many also be

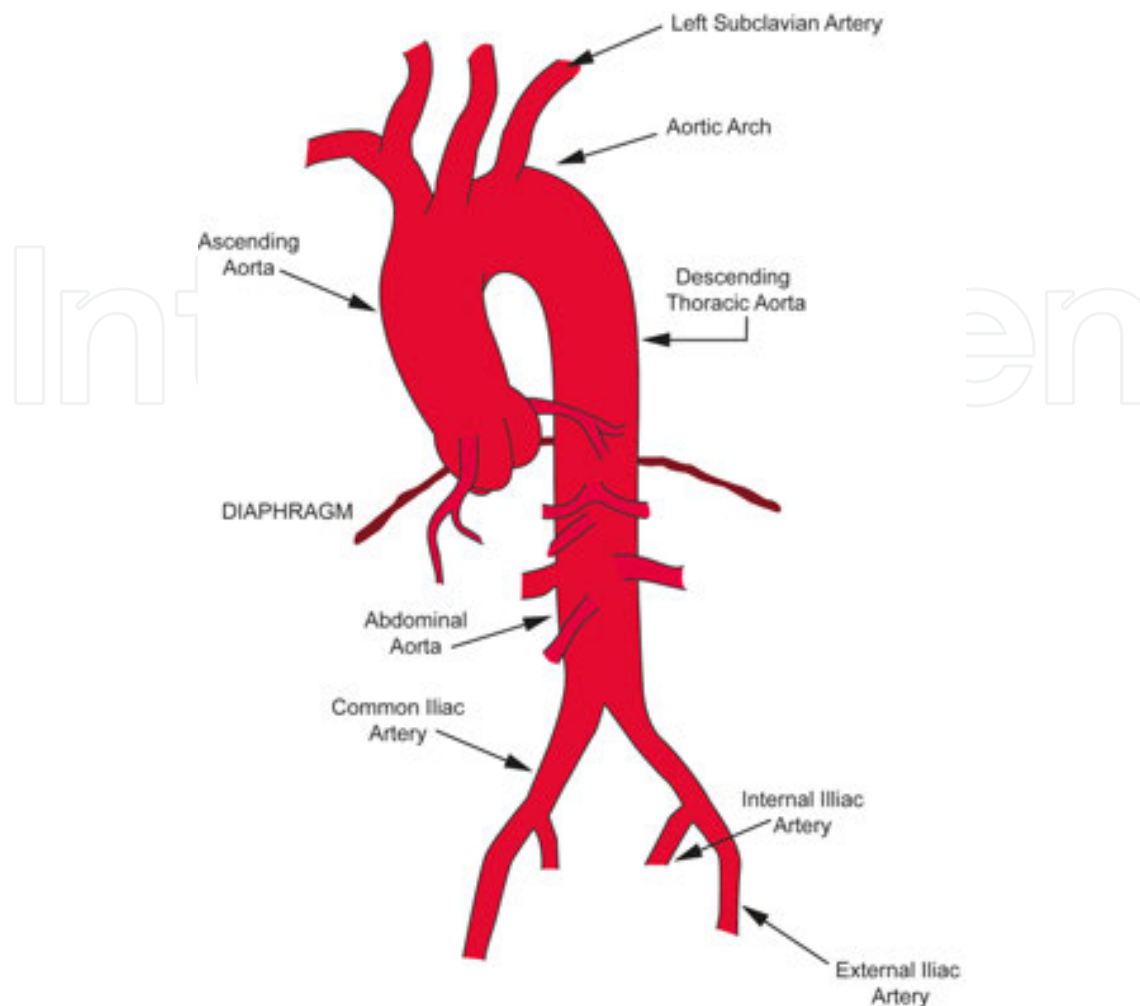


Figure 1. The aorta (Image by Miss S. M. Perera)

initially managed medically with the focus on blood pressure control, although immediate surgical intervention is required in patients with visceral, renal or limb malperfusion or for complications such as secondary dilatation and aneurysm formation. Historically, open surgical repair was the treatment for both TAA and TAD. In recent years, the advent of the endovascular stent-graft has resulted in minimally invasive treatment options. Thoracic endovascular aortic repair (TEVAR) is the placement of an endovascular stent to treat pathology of the thoracic aorta (Figure 4), and there has been a dramatic increase in the number of thoracic endografts placed in the recent years. TEVAR has now been adopted as the surgical approach of choice (particularly in the developed world), and in many countries it exceeds the number of open procedures performed for thoracic aortic pathologies.

Open surgical repair (Figure 5) Open surgery of TAA involves a left thoracotomy or thoracoabdominal incision, and the choice of specific surgical technique is dependent on aneurysm morphology, aortic anatomy and surgeon preference. The aorta is cross-clamped and minimizing ischemia time is vital to ensure adequate perfusion of the bowel, kidneys and lower limbs. The two most commonly applied approaches include a clamp-and-sew technique or the

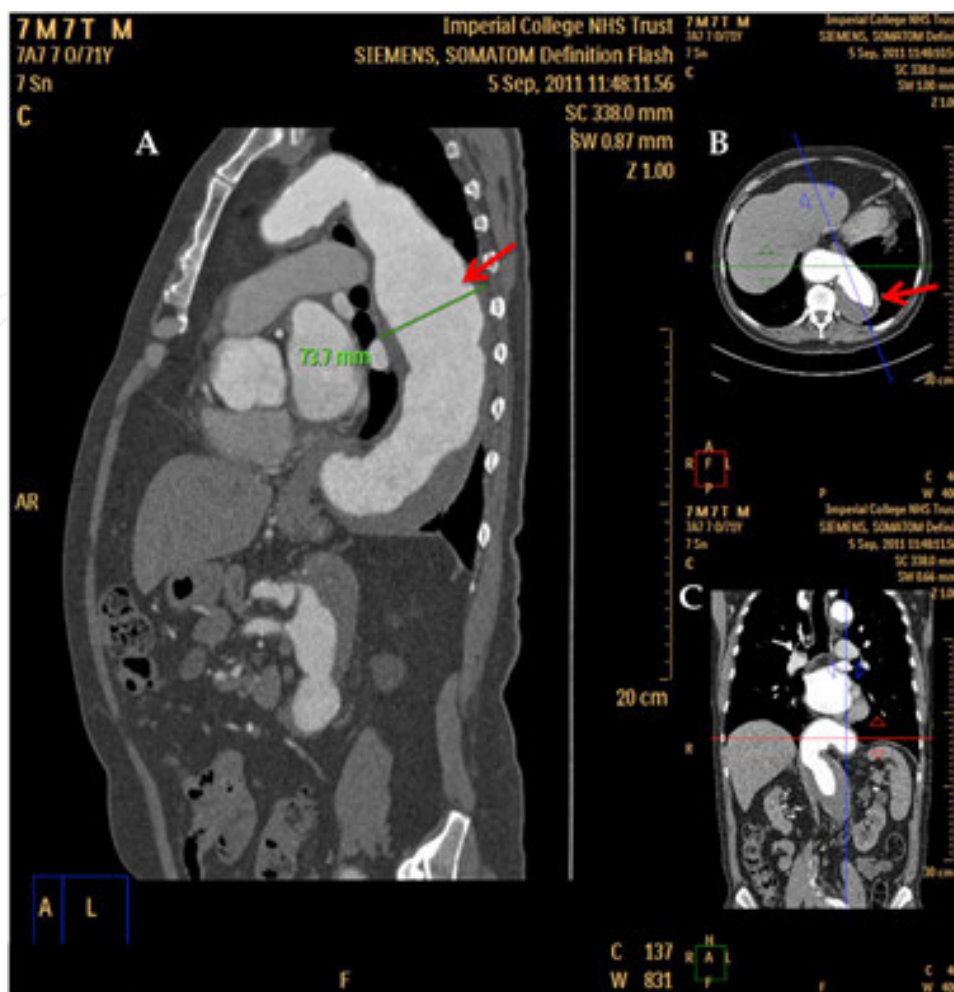


Figure 2. Thoracic aortic aneurysm CT angiogram of 7cm thoracic aortic aneurysm (arrow) in A) sagittal B) axial and C) coronal planes

use of distal aortic perfusion usually provided with an atrio-femoral bypass circuit, although total cardiopulmonary bypass with deep hypothermic circulatory arrest can also be utilized [1]. The aneurysmal aorta is replaced with a Dacron graft using a hand-sewn anastomosis, and vessels (visceral or head and neck) involved in the aneurysm are revascularized. Complications include mortality, cardiovascular and respiratory compromise, bleeding, acute renal failure, stroke and paraplegia. For thoracic and thoracoabdominal aneurysm repair, operative mortality is significant and varies from 2.7 to 8.8% and 7.6 to 14 respectively [2-5]. Paraplegia/paraparesis occurs in 2.7 to 12% in thoracic and 3.6 to 16% in thoracoabdominal open surgical procedures [2, 3, 5, 6].

Thoracic endovascular aortic repair TEVAR allows aneurysm exclusion without the need for thoracotomy and aortic cross-clamping. A pre-sized covered stent-graft is inserted through the common femoral artery via a surgical groin incision and deployed under fluoroscopic guidance (Figure 4). Additional percutaneous access via the contralateral femoral or left brachial artery is obtained for placement of an imaging catheter. Similar to open techniques, any vessels involved in the aneurysm or dissection, both visceral and head and neck, are

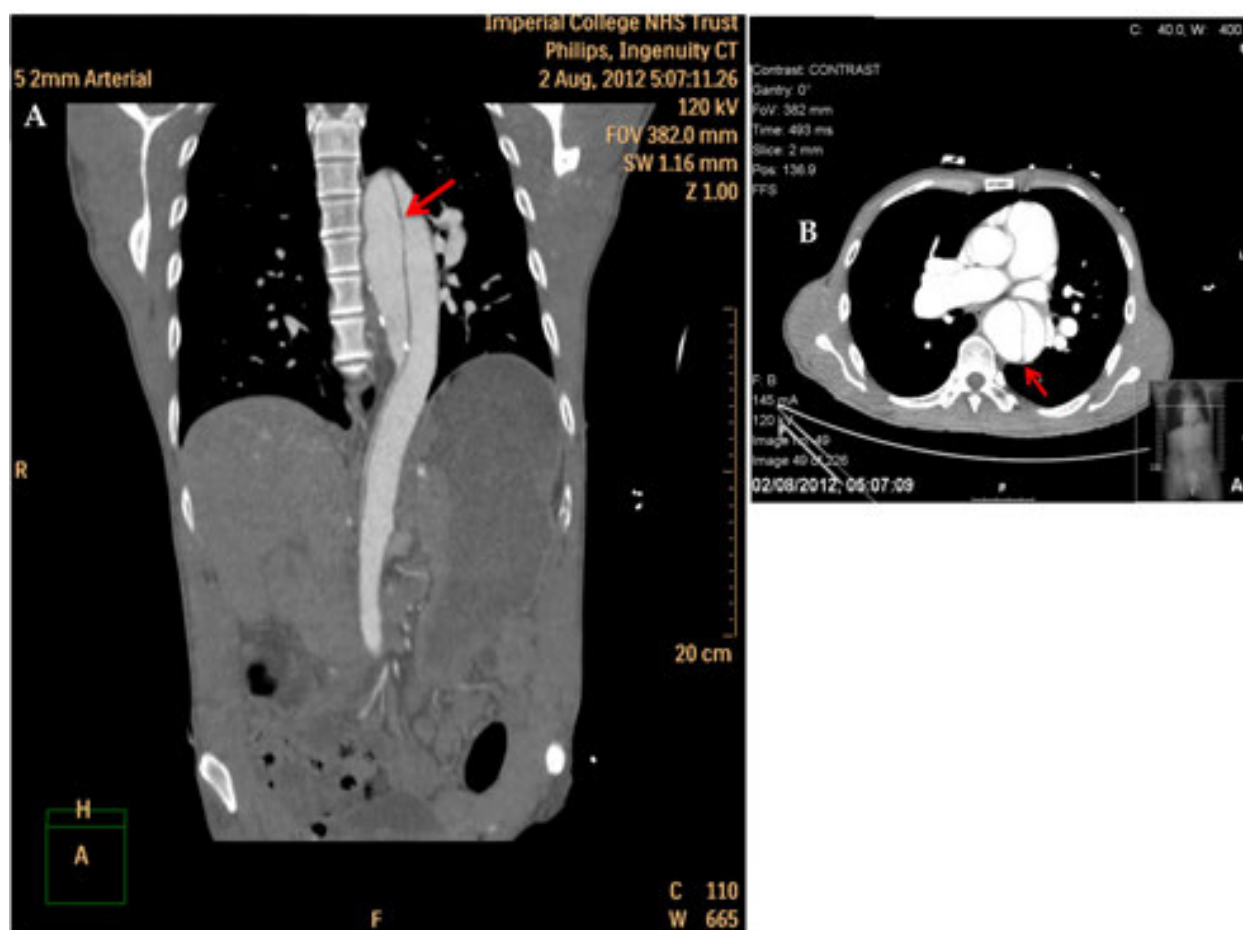


Figure 3. Aortic dissection CT angiogram of type B aortic dissection in A) coronal and B) axial planes. Arrow indicates dissection flap caused by separation of the layers of the aortic wall, with blood within the layers forming a true and false lumen

revascularized prior to stent-graft deployment. In instances of extensive arch or visceral open revascularization prior to stenting, the procedure is termed a hybrid procedure, denoting the combined open and endovascular approach. Recent advances in stent-graft technology have now allowed options for scalloped, fenestrated and branched grafts, mitigating the need for open surgical revascularization in suitable cases. Several challenges remain with TEVAR however, including narrow iliac diameter, vessel tortuosity, aortic arch angulation and the need for adequate sealing zones to ensure stable stent fixation. Complications include stroke, paraplegia, endoleak (persistent blood flow outside the lumen of the stent-graft and within the aneurysm sac due to incomplete sealing or exclusion of aneurysm sac, usually requiring further intervention), the need for re-intervention and less frequently mortality and conversion to open procedure. The global incidence for paraplegia post thoracic stenting varies from 0 to 9.8%, with a permanent paraplegia risk of 5.5%. The paraplegia risk for isolated descending thoracic stents is 0.9%, with poorer outcomes for more complex procedures involving fenestrated and branched stents (7.1%) and visceral hybrid procedures (11.3%) [7]. Both immediate and delayed onset paraplegia have been observed following TEVAR, with cases of delayed neurological deficit occurring from twelve hours up to one month postoperatively [8].

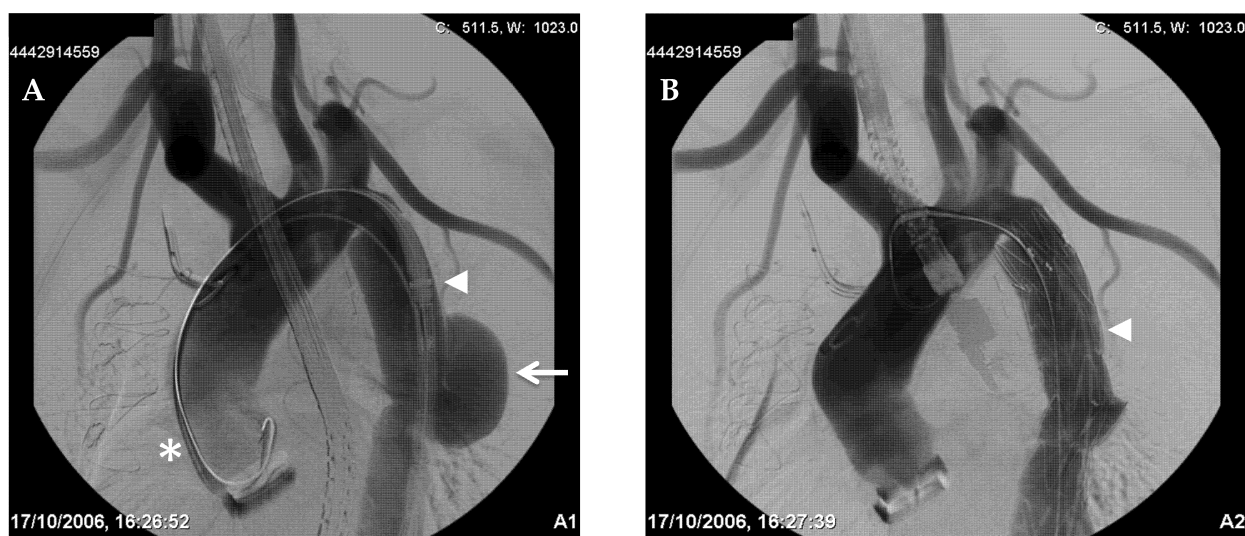

Figure 4. Thoracic endovascular aortic repair (TEVAR) Angiogram images outlining procedural steps A) Guidewire and catheter in aortic arch (star). Stent-graft ensheathed within delivery device advanced up descending thoracic aorta (arrow head). Placed under fluoroscopic guidance and contrast angiogram performed. Arrow indicates thoracic aortic aneurysm B) Stent-graft deployed (arrow head). Contrast angiogram performed to confirm exclusion of aneurysm, correct position of stent and patency of all arch vessels

Epidemiology Between 1999 and 2010, hospital admissions for total (ascending and descending) thoracic aortic disease in the UK rose steadily from 7.2 to 8.8 per 100,000 of population ($p=0.0001$) for TAD, and from 4.4 to 9.0 ($p<0.0001$) for TAA [9]. Since separate coding for open repair and TEVAR was initiated in 2006, the rate of repairs for descending TAAs have more than doubled from 0.7 in 2005 to 1.9 per 100,000 population in 2010. The rates for open repair have been steady, and the observed increase is entirely attributable to the increased rate of TEVAR. The changes for type B aortic dissection are even more remarkable, where overall repair rates have increased from 0.1 per 100,000 in 2000 to 0.5 per 100,000 population ($p=0.0001$) in 2010. Data is from Hospital Episodes Statistics (HES) (England) and Health Solutions Wales PEDW Statistics (Wales). The changing trends indicate a likely increase in thoracic vascular workload in the future. Therefore recognizing, managing and reducing the incidence of spinal cord ischemia (SCI) as a complication of thoracic and thoracoabdominal aortic intervention is essential.

1.2. The spinal cord

Anatomy The blood supply to the thoracic spinal cord comes from a single anterior spinal artery (formed by the union of two branches from the vertebral arteries) and two paired posterior spinal arteries (also derived from the vertebral arteries), which run the length of the spinal cord [10]. The vascular anatomy is variable however, and these arteries may not be continuous along their course. Both the anterior and posterior spinal arteries are supplemented by segmental radicular arteries, which are small branches of the cervical, thoracic and lumbar vessels. The largest of the radicular arteries is the artery of Adamkiewicz, often given off at the level of T10 but it can vary in position from T7 to L4 [11]. This artery supplies the conus, but has a poor connection with the superior portion of the spinal cord. It is given off by the left

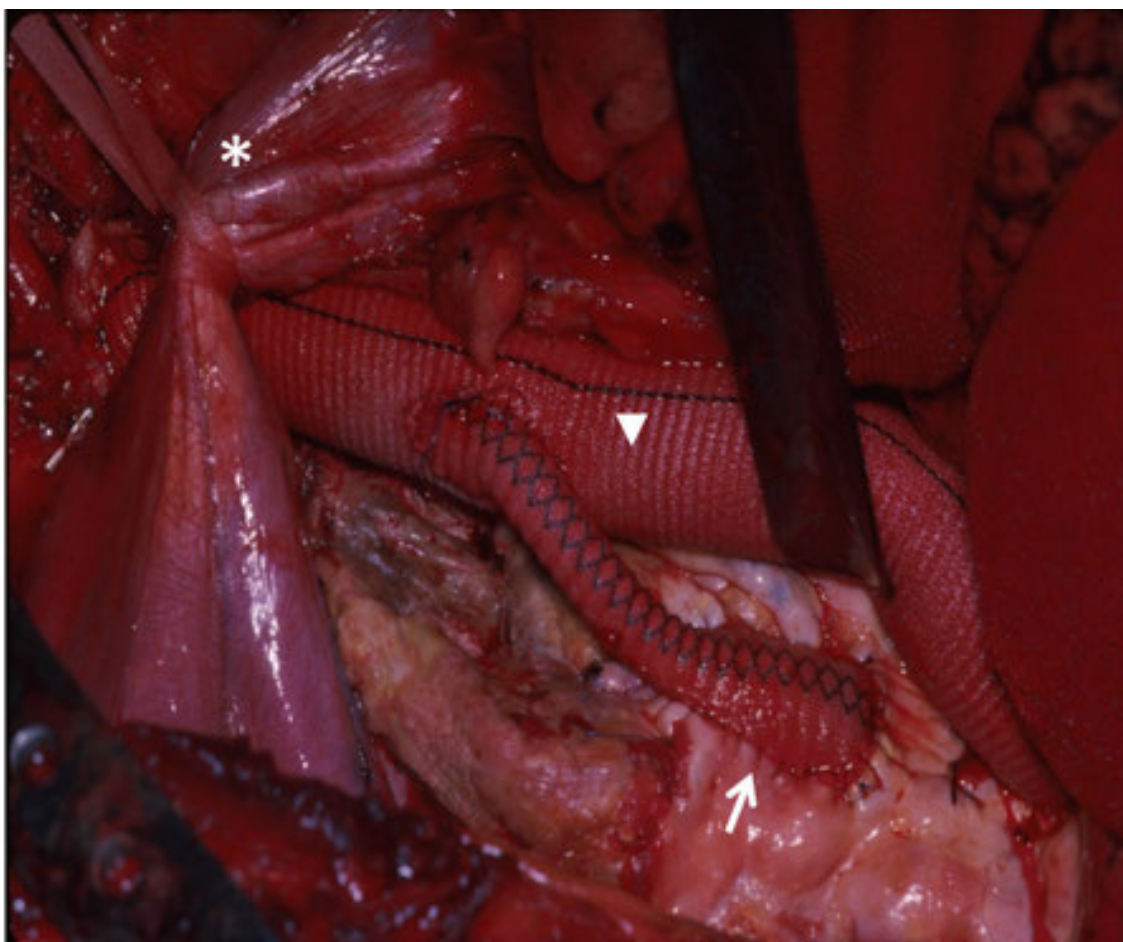


Figure 5. Open repair Retraction of the diaphragm (star) with open repair of thoracoabdominal aortic aneurysm with Dacron graft (arrow head) and reimplantation of an intercostal artery (arrow) (Image courtesy of Mr J. H. Wolfe)

intercostal or lumbar artery in over 75% of patients and is recognized by its characteristic hairpin bend. Another important radicular artery is the mid-thoracic radicular branch, which arises from the T7 posterior intercostal artery and supplements the blood supply of the fourth to eighth segments of the thoracic spinal cord.

Previous consensus has been that identification and reimplantation of the artery of Adamkiewicz during TAAA repair is the best strategy for preserving spinal cord blood supply and thereby preventing paraplegia. SCI remains a problem however and re-anastomosis of arteries, a difficult enough undertaking in the context of an open repair, is not possible with current endovascular techniques. Anatomic studies have been undertaken to establish the presence of an extensive collateral network that supports spinal cord perfusion and explains preservation of spinal cord perfusion when segmental vessels are interrupted [12]. It is reported that the thoracic and lumbar segmental arteries give rise to three major vessel groups which anastomose with one another and with the nutrient arteries of the spinal cord: 1) the intrathecal vessels; the anterior spinal artery and the longitudinal chain of epidural arcades lying between the spinal cord and the vertebral bodies, 2) the interconnecting vessels lying outside the spinal canal along the dorsal processes of the vertebral bodies and paravertebral tissues, 3) a large

collection of interconnecting vessels supplying the paraspinous muscles including the iliopsoas anteriorly and erector spinae posteriorly (Figure 6). The configuration of the arterial network includes inputs not only from the intercostal and lumbar segmental vessels, but also from the subclavian and hypogastric arteries. The presence of this extensive network implies a considerable reserve to ensure spinal cord perfusion when some inputs are compromised. It also highlights the threat of steal phenomenon, as a significant finding of the study was how dramatically the muscular arterial component dominates the anatomy of the network when compared with the small arteries that feed the spinal cord directly. The studies reinforce the idea that the spinal cord circulation is a longitudinally continuous and flexible system, so that input from any single segmental artery along its length is unlikely to be critical. Various studies have already demonstrated that the total loss of segmental arteries sacrificed during TAAA repair is a more powerful predictor of the risk of paraplegia than loss of any individual segmental artery.

Physiology Cerebrospinal fluid (CSF) is secreted by the central nervous system and fills the ventricles and subarachnoid space of the brain and the spinal column. It protects the brain from physical impact, circulates nutrients and has a role in waste management. Spinal cord perfusion pressure is a balance between the inflow and outflow pressures within the closed confines of the spinal canal, calculated as mean arterial pressure (MAP) minus CSF pressure. The inflow depends principally on arterial pressure, which is largely determined by cardiac output, blood volume, and the competing demands of viscera and muscle tissue connected to the same collateral network. Theoretically therefore, decreasing the CSF pressure or increasing the blood pressure/MAP will improve spinal cord perfusion pressure. CSF pressure can be decreased by insertion of a lumbar CSF drain and allowing free drainage by gravity (Figure 7). The drain is transduced to obtain pressure measurements and the rate of CSF drainage is altered by adjusting the height of the drip chamber from the ground until the desired drainage rate and pressure is achieved. MAP is increased and maintained with the use of vasopressors, which induce vasoconstriction and thereby increase the MAP. The MAP is monitored with an arterial line to provide invasive blood pressure readings.

1.3. Risk factors for spinal cord ischemia

Blood supply Given that spinal cord blood supply is often segmental and dependent upon contribution from collateral arteries, the need for more extensive aortic replacement requires interruption of an increasing number of intercostal arteries providing spinal cord perfusion, thereby posing a higher risk of SCI [13]. Type II TAAAs have been reported to have a greater negative neurological outcome compared to less extensive type IV TAAAs. The increased risk of paraplegia with type I and type II TAAAs may also be due to interruption of intercostal arteries in the area of T9–L2 where the anterior spinal artery may be discontinuous and the spinal cord may be more dependent on collateral supply. Dissection and acute presentation have also been identified as variables associated with paralysis risk [14].

Perfusion pressure With open repair the placement of a proximal aortic clamp interferes with the autoregulatory response controlling cerebral perfusion with resulting fluctuations in cerebral blood flow [13]. Control of proximal hypertension following placement of an aortic

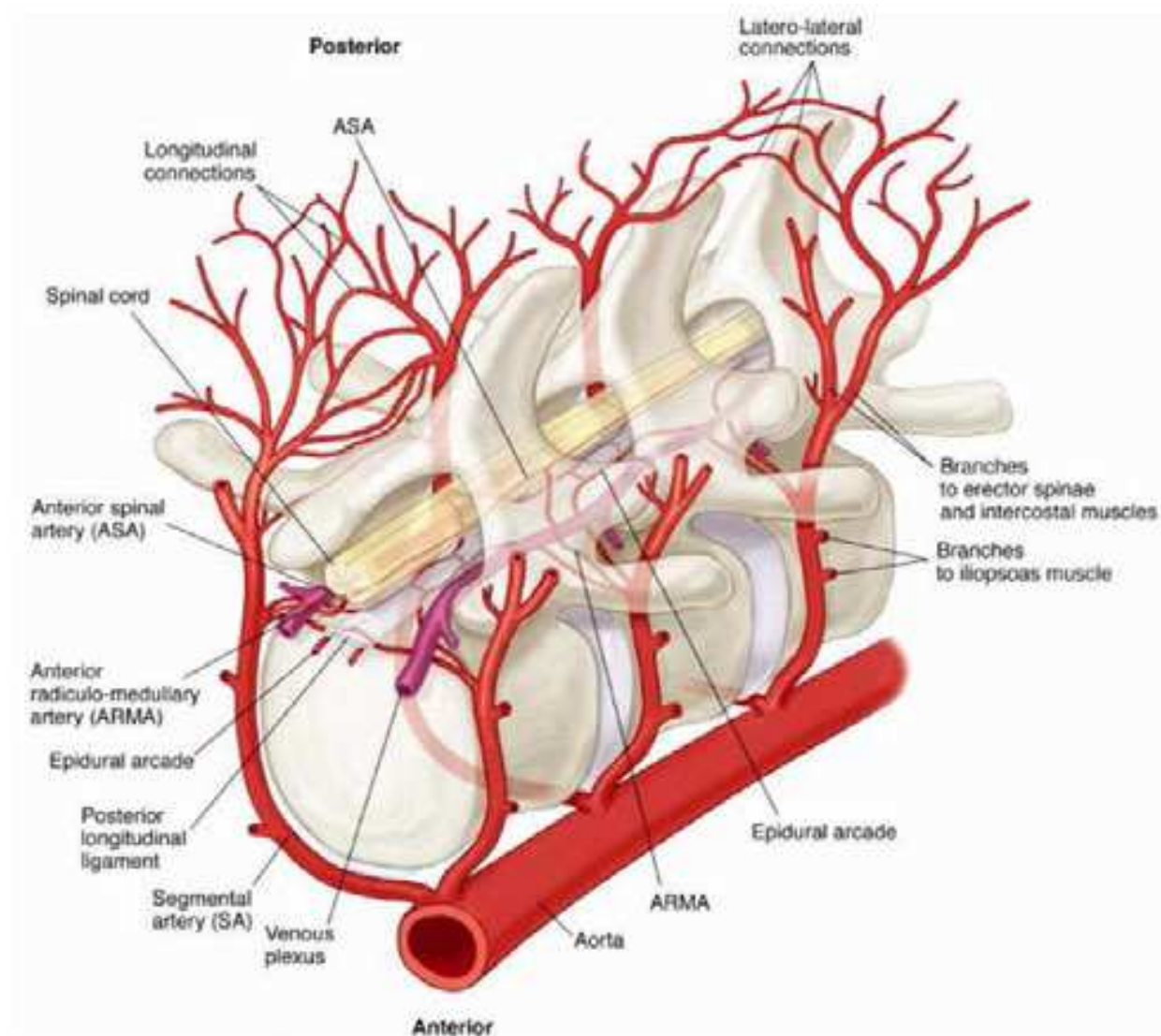


Figure 6. Blood supply to the spinal cord Schematic diagram demonstrating the relationships, relative sizes and interconnections among the segmental arteries (SA), the anterior radiculomedullary arteries (ARMA), the epidural arcades and the anterior spinal artery (ASA). Longitudinal anastomoses along the dorsal processes of the spine as well as dorsal communications (interstitial connections) between right and left branches of the segmental arteries are also shown. (From Etz CD, Kari FA, Mueller CS, Silovitz D, Brenner RM, Lin HM, Griep RB. *The collateral network concept: a reassessment of the anatomy of spinal cord perfusion.* *J Thorac Cardiovasc Surg.* 2011 Apr;141(4):1020-8. Reproduced with permission from Elsevier)

cross-clamp maintains autoregulation in the coronary and cerebral circulation, often at the expense of adequate distal cord perfusion. Lowering proximal pressure decreases distal mean arterial pressure, which in the presence of an unchanged or possibly increased CSF pressure, results in decreased perfusion pressure of the distal cord. Thus, CSF drainage through insertion of a spinal drain (usually controlled to maintain a CSF pressure of less than 10-12mmHg) can reduce CSF pressure, thereby improving spinal cord perfusion.

Reperfusion injury Ischemia and reperfusion initiate neurochemical cellular responses that can exacerbate ischemia, which may in turn progress to infarction [14]. Restoration of blood

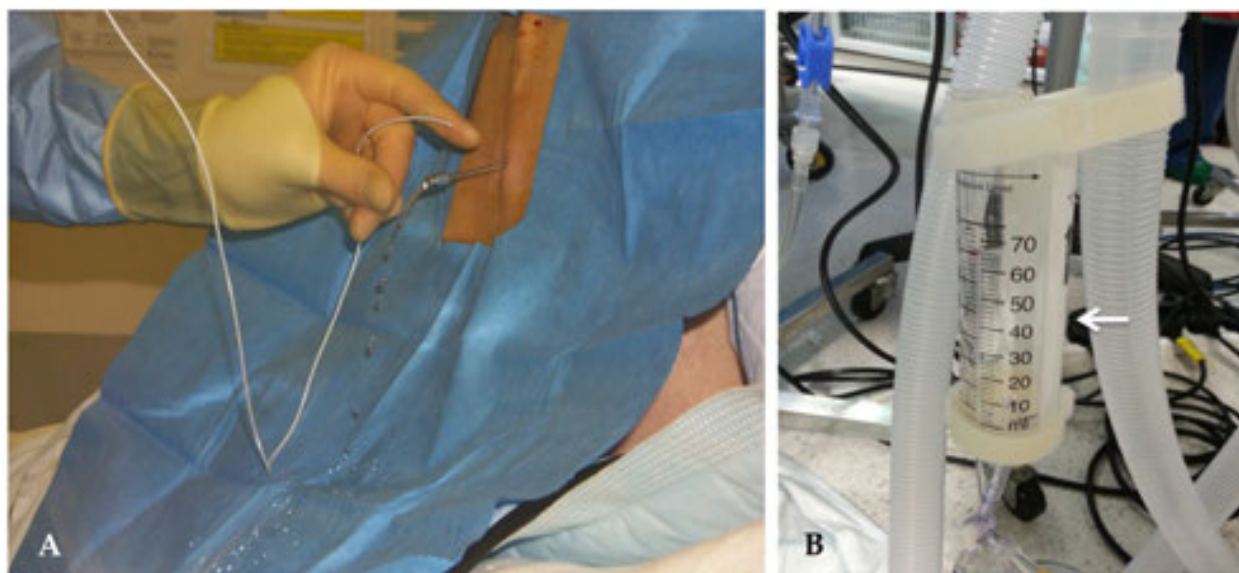


Figure 7. Insertion of lumbar cerebrospinal fluid (CSF) drain A) Performed by anesthetist under aseptic conditions. Spinal needle inserted at or below L3/4 intervertebral space. Position confirmed by free drainage of CSF. Flexible catheter inserted through needle, needle withdrawn and catheter connected to drip chamber, sterile drainage bag and pressure transducer. B) CSF drained passively by gravity by adjusting height of drip chamber (arrow) off the ground

flow to an already ischemic spinal cord introduces oxygen, which is rapidly metabolized to form oxygen radicals [13]. Through lipid peroxidation with cell membrane destruction, there is release of excitatory amino acids known to have a role in spinal cord ischemia. Reperfusion also introduces inflammatory cells including leukocytes, which adhere to the microvasculature and release cytotoxic mediators. The cellular damage induced by this reperfusion process functions as debris in further occluding the microvasculature and propagating the ischemic insult. Inflammatory cytokines derived from visceral ischemia, when introduced to the spinal cord following reperfusion, may compound this effect.

Critical intercostal artery coverage In contrast to open repair, cross-clamping of the aorta is not undertaken in endovascular repair, leaving blood pressure as a major determinant of spinal cord perfusion. With TEVAR, it is thought that stent-graft coverage of the critical thoracic intercostal arteries results in reduced perfusion of the thoracic spinal cord and watershed infarction. The mid-thoracic branch may also be more critical given that the artery of Adamkiewicz can originate below the area involved in graft coverage. Loss of the artery of Adamkiewicz in prior abdominal aortic repairs may explain why patients with prior repair are at higher risk of SCI during subsequent TAA repair. With the loss of thoracic radicular arteries due to occlusion, increased pressure is required through the anterior and posterior spinal arteries along with other collaterals to maintain adequate perfusion pressure of the spinal cord [10]. Given patients undergoing TEVAR are less susceptible to bleeding complications in comparison with open repair, they are able to tolerate higher intraoperative and postoperative systemic pressures.

Collateral circulation SCI following stent-graft deployment can also be dependent upon the extent of existing collateral circulation. Other collaterals to the spinal cord include the hypo-

gastric artery, internal iliac arteries, internal thoracic artery and branches of the subclavian artery. Therefore where possible these should be revascularized or preserved, particularly in high-risk individuals. Where there is adequate collateral preservation following stent deployment, one would not expect to see clinical evidence of ischemia [13]. If collaterals are absent and critical intercostal arteries are covered, an ischemic event is more likely to occur. If the existing intercostal or lumbar artery collateral supply is marginal, tenuous cord perfusion results, which is more vulnerable to any postoperative hemodynamic insult. Incomplete or intermediate cord ischemia may exist in the regional distribution of the excluded intercostal arteries secondary to marginal collateralization. This may present as a delayed onset neurological deficit as the vulnerable cord is more sensitive to decreases in spinal artery perfusion pressure. These decreases may be the result of postoperative hemodynamic compromise or delayed thrombosis of previously patent yet now covered intercostal arteries.

Hypotension It has been demonstrated that hypotension that precipitates spinal cord injury within the first 48 hours after open surgical intervention is quite subtle and depends on interpreting postoperative blood pressure with preoperative values in mind [15]. The findings of this study support a policy of maintaining blood pressures at high levels not only intraoperatively, which has become practice with endovascular repair, but for at least 48 hours postoperatively. This should especially be emphasized in patients with antecedent hypertension, and this finding is likely to be valid following both open and endovascular repair. Following TEVAR, MAP should be maintained at greater than 80mmHg with the use of vasopressors when required. As a rule, at our unit following TEVAR, patients are monitored on a high dependency unit (HDU) environment for 24-48 hours, and maintained on a norepinephrine infusion of 0.01mcg/kg/minute. If the MAP drops below 80mmHg the infusion rate is increased and titrated in order to maintain an adequate MAP. Instigating timely management is crucial, and having a very low background infusion rate prevents common delays associated with initiating new treatment, particularly out of hours.

Delayed onset spinal cord ischemia The extent of neurological deficits attributed to SCI after TEVAR can range from mild paraparesis to flaccid paralysis [16]. At the most severe end of this clinico-pathologic spectrum, patients with complete paralysis are those who have suffered irreversible SCI due to spinal cord infarction. Patients at the opposite end of the spectrum represent a mild form of cord ischemia with the potential for reversibility and full neurological recovery. Delayed-onset SCI, which can occur up to several weeks after TEVAR, is also typically due to ischemia as opposed to infarction of the spinal cord, with the potential for recovery. Whereas a deficit noted immediately upon emergence from anesthesia would be attributed to an intraoperative cause, a delayed neurological deficit observed after a period of normal neurological function is secondary to a postoperative event. Indeed several postoperative events have been linked to the development of delayed-onset SCI, including hypotension, thrombosis, hematoma, embolization and elevated CSF pressures.

Length of aortic coverage The authors conducted a study to determine the incidence and risk factors for SCI following thoracic and thoracoabdominal aortic intervention using a prospective database of all interventions between 2001 and 2009, including both elective and emergency cases [7]. Logistic regression was used to investigate the factors associated with SCI. The

results revealed 235 patients underwent thoracic aortic stent-grafting; 111 (47%) thoracic aortic stent-grafts alone, with an additional 14 (6%) branched or fenestrated thoracic grafts, 30 (13%) arch hybrids and 80 (34%) visceral hybrids. The global incidence of SCI for all procedures was 23/235 (9.8%), which included emergency indications (ruptured TAAA and complex acute dissections). The incidence varied considerably between types of procedures. Of the twenty-three cases of SCI, death occurred in four patients, recovery of function was seen in six and permanent paraplegia occurred in 13/235 patients (5.5%). Of the nine pre-specified factors investigated for association with SCI (age, sex, indication, urgency, type of procedure, duration of procedure, percentage of aorta covered, spinal drain usage and left subclavian artery coverage), only percentage of aortic coverage was significantly associated with the incidence of SCI on logistic regression; adjusted odds ratio per 10% increase in aorta covered=1.78[95% CI 1.18-2.71], $p=0.007$. In patients who developed SCI the operative time was increased (463.5 versus 307.2 minutes) and more stents were utilized (4 versus 2). Therefore the study concluded that SCI following thoracic and thoracoabdominal aortic endovascular intervention is significantly associated with the proportion of aorta covered. The degree of risk varies between different types of procedures, and visceral hybrids appeared to carry the highest risk of SCI. The study however included a heterogeneous group of conditions (atherosclerotic degenerative aneurysms, chronic type B dissections and acute aortic syndromes) with differences in the complexity of procedures performed (endovascular, arch and visceral hybrid solutions). No patient developed SCI with less than 54% coverage of the aorta. This work demonstrated a significant rise in the risk of SCI with increasing magnitude of procedure type; TEVAR (stent-graft confined to the thoracic aorta) was associated with the least risk at 1.8% SCI and 0.9% permanent paraplegia, arch hybrid 10% and 6.7%, fenestrated or branched graft 14.3% and 7.1% and visceral hybrid 20% and 11.3%.

Chronic renal insufficiency Ullery et al [16] also reported similar findings with an SCI rate of 2.8% with TEVAR (12 of 424), 14% with arch hybrid (6 of 43) and 17% with visceral hybrid (1 of 6), and a global incidence of 4% (9 of 473). The twelve patients experiencing SCI within the TEVAR cohort all underwent stent coverage from the origin of the left subclavian artery to the diaphragm ($p<0.001$), and multivariate regression analysis demonstrated chronic renal insufficiency to be independently associated with SCI ($p=0.029$). At SCI onset, therapeutic interventions increased blood pressure from mean MAP 77mmHg to 99mmHg, and decreased mean lumbar CSF pressure from 10mmHg to 7mmHg, both at time of neurological recovery. There was one mortality within 30 days (1/12, 8%), and 9 of 11 patients experienced complete neurological recovery as a result of the interventions.

Simultaneous closure of two vascular territories A risk model was developed using a prospective 63-patient single-centre cohort [17]. This was then applied to data extracted from the multi-centre European Registry on Endovascular Aortic Repair Complications (EuREC), where 38 of 2235 patients (1.7%) developed SCI (data from 19 centres). In the single-centre cohort direct correlation was seen between the occurrence of symptomatic SCI and both prolonged intraoperative hypotension ($p=0.04$) and simultaneous closure of at least two independent spinal cord vascular territories ($p=0.005$), whilst previous closure of a single vascular territory was not associated with an increased risk of symptomatic spinal cord

ischemia ($p=0.56$). The combination of prolonged hypotension and simultaneous closure of at least two territories exhibited the strongest association ($p<0.0001$). Applying the model to the entire EuREC cohort demonstrated a good correlation between the predicted and observed risk factors (kappa 0.77, 95% CI 0.65-0.90). As a result the study concluded that simultaneous closure of at least two vascular territories supplying the spinal cord is highly relevant, especially in combination with prolonged intraoperative hypotension.

Previous or concomitant abdominal aortic repair Although the putative mechanism of loss of lumbar collateral perfusion in those who had prior aortic repairs appears reasonable, occurrence of SCI in this subset of patients has not been consistent. The outcomes of twenty-eight patients who underwent staged TEVAR following previous or concomitant abdominal aortic repair were reported, of whom twenty-seven had cerebrospinal fluid drainage during and following thoracic repair. SCI developed in four of twenty-eight patients (14.3%); symptoms manifested twelve hours postoperatively in one patient, with delayed onset in the remaining three patients ranging from three days to seven weeks postoperatively [18]. Irreversible cord ischemia occurred in three patients, with full recovery in one patient. This was in comparison to only one of 97 patients (1.0%) who developed SCI following TEVAR only, with no intervention to the abdominal aorta. The study showed that SCI occurred at a markedly higher rate in patients with previous or concomitant abdominal aortic repair, and this risk continued beyond the immediate postoperative period. Another study analysed a case series of 406 patients undergoing thoracic stent-grafting for various aortic pathology [19]. Prophylactic cerebrospinal fluid drainage (CSFD) was used selectively in only four cases. The incidence of paraplegia was 2.7% ($n=11$), with six patients having major permanent deficit. When analysing conditions influencing SCI, statistical correlation was found for previous conventional or endovascular abdominal aortic aneurysm repair (odds ratio [OR], 4.8) in addition to coverage of the entire descending thoracic aorta (OR, 3.6) and implantation of thoracoabdominal branched and fenestrated stent-grafts (OR, 9.5). Individual analyses revealed other conditions that might have played a role, such as embolization into the segmental arteries, severe visceral ischemia, profound hemorrhagic shock and heparin-induced thrombocytopenia. At our unit we routinely perform CSFD on patients undergoing TEVAR following previous or concomitant abdominal aortic intervention.

1.4. Adjuncts for the prevention of paraplegia

Intercostal artery re-implantation (Figure 5) Acher et al demonstrated an 80% reduction in paraplegia risk using hypothermia, naloxone, steroids, spinal fluid drainage, intercostal ligation and optimizing hemodynamic parameters. The group then demonstrated that intercostal revascularization (either reimplantation or preservation where possible) further reduced their paraplegia risk index by 75% when evaluated using a highly accurate ($R^2 > 0.88$) paraplegia risk index [20]. Intercostal arteries were reimplanted based on magnetic resonance angiography identification of intercostal arteries that supplied radicular arteries feeding the anterior spinal artery, or by patency and location at surgery. The incidence of paralysis after TAAA repair decreased from 4.83% to 0.88% and the paralysis risk index decreased from 0.26 to 0.05 when intercostal artery reimplantation was added to neuroprotective strategies that

had already substantially reduced paralysis risk. These findings suggest that factors that affect collateral blood flow and metabolism account for approximately 80% of paraplegia risk and intercostal blood flow accounts for 20% of risk. These figures imply there is a limit in being able to reduce paraplegia risk in patients undergoing endograft treatment for TAAAs.

In the era of endovascular repair, where intercostal artery re-implantation is not possible, physiological factors that affect spinal cord perfusion (MAP, CSFD), metabolism and ischemic tolerance (steroids, naloxone, hypothermia) and oxygen delivery (haemoglobin, MAP, oxygen saturations, temperature, cardiac function) are key tools to prevent paraplegia [14]. There is a range of effectiveness of the applied strategies amongst treatment centres, which tells us that treatment protocols to optimize contributing factors must be established and followed consistently to achieve the best results [14].

Internal iliac revascularization [11] In addition to revascularization of the intercostal vessels, one must also consider the superior and inferior supply to the spinal cord via the subclavian arteries and internal iliac network. Revascularization of the internal iliac arteries should not only be considered in the context of buttock ischemia, but also in an attempt to maintain adequate spinal perfusion. Internal iliac flow should be preserved on at least one side and careful consideration must be given in the context of common and internal iliac aneurysms as well as when a uni-iliac stent-graft is placed.

Left subclavian artery revascularization The left subclavian artery (LSCA) has achieved prominence in discussions regarding case planning for stent-graft insertion. Up to one third of patients undergoing TEVAR require coverage of the LSCA in order to achieve an adequate landing zone and proximal seal [21]. In these situations the stent-graft is placed across the origin of the artery and endovascular embolization of the vessel with percutaneous access via the brachial artery is required to prevent development of a type 2 endoleak (persistent blood flow into the aneurysm sac from collateral vessels). In selected cases LSCA revascularization is undertaken prior to endovascular stent deployment. This can be performed as a single or staged procedure. At our unit this is routinely performed as a single-stage procedure in a hybrid operating suite (surgical operating theatre equipped with advanced medical imaging devices required for endovascular procedures). An open left common carotid to left subclavian artery bypass is performed, commonly with a Dacron graft, prior to endovascular stenting across the origin of the LSCA (Figure 8). The LSCA provides important circulation to the spinal cord, brain, and arm, and therefore coverage is not without clinical consequences. Stroke, SCI and coronary ischemia in the setting of a left internal mammary artery bypass, as well as arm ischemia, have all been described. The left vertebral artery serves as the dominant vessel to the hindbrain in 60% of individuals, and as a result LSCA coverage can lead to a posterior circulation stroke. LSCA coverage can also compromise spinal blood flow with resultant SCI. It contributes to spinal cord perfusion by providing branches to the cephalad portions of the anterior and posterior spinal arteries [22]. Management of patients in whom the LSCA is sacrificed remains a source of considerable debate and controversy. Proponents of routine revascularization cite the increased risk of arm ischemia, stroke and SCI associated with LSCA coverage. Several other studies have shown that intentional coverage of the LSCA without revascularization is not associated with increased morbidity and lend support to those who

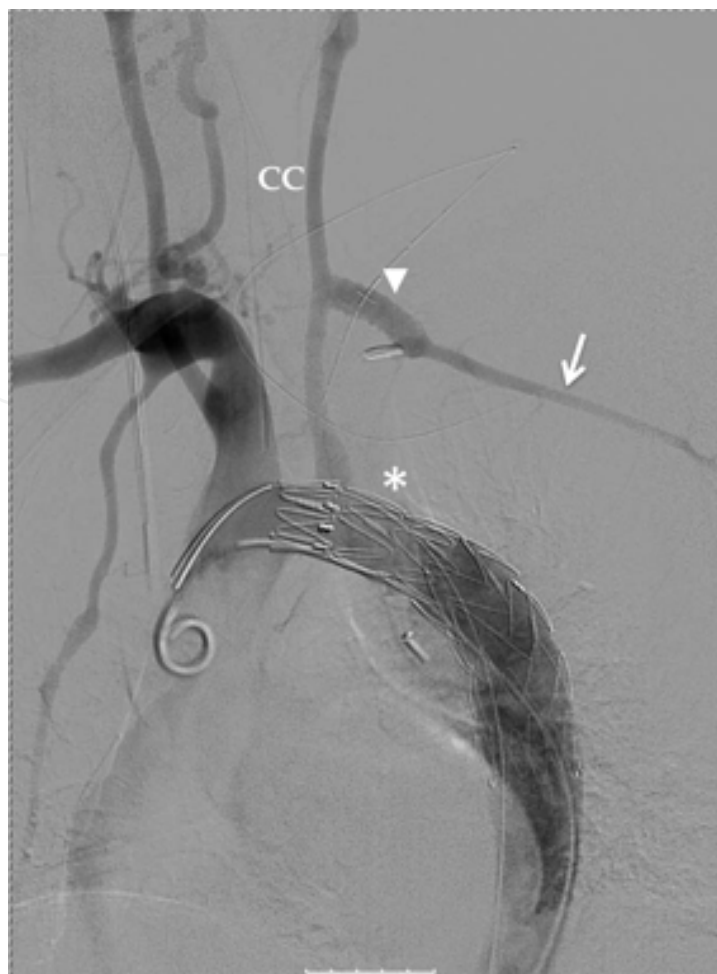


Figure 8. Left subclavian artery revascularization Left common carotid (CC) to left subclavian artery (LSCA, arrow) bypass with Dacron graft (arrow head) performed prior to endovascular stenting across origin of LSCA (star) to create adequate landing zone for exclusion of thoracic aortic aneurysm while maintaining flow to LSCA. Patent LSCA seen (arrow).

advocate more selective revascularization. Despite contributing to critical vascular beds, LSCA coverage is well tolerated in most patients due to collateral blood flow primarily from the right vertebral artery, basilar artery and circle of Willis arcade [22]. In addition, they argue that LSCA bypass and/or transposition is not entirely without risk, and should therefore be stratified according to the individual. Complications include left recurrent laryngeal nerve palsy, left phrenic nerve palsy and neck haematoma necessitating re-exploration. Absolute indications for LSCA revascularization include patent left internal mammary artery coronary bypass graft, dominant left vertebral artery, diminutive or absent right vertebral artery, left arm arteriovenous fistula for dialysis access and patent left axillo-femoral bypass graft. Relative indications include long aortic coverage, previous abdominal aortic surgery and occlusion of the internal iliac or hypogastric arteries.

Two meta-analyses on the subject both reported an increase in SCI when the LSCA is covered. One observed an SCI rate of 2.3 vs. 2.8, $p=0.005$ for LSCA not covered vs. covered. However there was no protective effect from preoperative revascularization; SCI for the uncovered

group 2.7% vs. 0.8% in the revascularized group, $p=0.35$ [23]. In an effort to establish clinical practice guidelines for management of the LSCA with TEVAR, the Society of Vascular Surgery (SVS) selected a committee of experts within the field and commissioned a systematic review and meta-analysis of the literature. They employed the GRADE method (grading of recommendations assessment, development and evaluation) to develop and present their recommendations. The second study, commissioned by the SVS, demonstrated that coverage of the LSCA is associated with a trend towards increase in paraplegia and anterior circulation stroke and a significant increase in risk of arm ischemia and vertebrobasilar stroke [24]. However there was no association with death, myocardial infarction or transient ischaemic attack. All recommendations listed were made based on level C (low-quality) data, but nonetheless, the proposed SVS guidelines suggest routine preoperative revascularization of the LSA for elective cases requiring coverage of the origin of the vessel [25]. Recommendations include: 1) In patients undergoing elective TEVAR where achievement of a proximal seal necessitates coverage of the LSA, they suggest routine preoperative revascularization (despite the low-quality evidence); 2) In selected patients who have an anatomy that compromises perfusion to critical organs, routine preoperative LSA revascularization is strongly recommended (despite the low-quality evidence); and 3) In patients who need urgent TEVAR for life-threatening acute aortic syndromes where achievement of a proximal seal necessitates coverage of the LSA, they suggest that revascularization should be individualized and addressed expectantly on the basis of anatomy, urgency and availability of surgical expertise.

However, other large single-institution studies with protocols for selective revascularization saw no differences in the rates of SCI. A recent large retrospective multi-centre review was performed on 1189 patients undergoing TEVAR [65]. Subgroup analysis was performed for non-covered LSCA (group A), covered LSCA (group B) and covered and revascularized LSCA (group C) which showed no significant difference between groups B and C (SCI 6.3% vs. 6.1%) and LSCA revascularization was not protective for SCI (7.5% vs. 4.1%, $p=0.3$). The study concluded that LSCA coverage does not appear to result in an increased incidence of SCI or stroke when a strategy of selective revascularization is adopted, and selective LSCA revascularization results in similar outcomes among the three cohorts studied. Complications from revascularization, understated in most studies, are worth considering. The key to favourable outcomes likely involves careful patient selection when selective revascularization is employed.

Elective sac perfusion via temporary controlled endoleak With endovascular repair, in contrast to open surgical repair, identification and/or direct revascularization of important segmental vessels is not currently possible. SCI therefore remains a major challenge with endovascular repair, and innovations to reduce the occurrence of this complication are necessary. Early experience with a technique for maintaining perfusion of segmental vessels (intercostal and lumbar arteries) in the early postoperative period after endovascular repair of a TAAA with “sac perfusion branches” added to custom-made stent-grafts has been described [27]. The branched stent-graft and bridging stents to the branches are inserted under general anesthesia. The perfusion branches are left open in order to perfuse segmental vessels. The risk of SCI is greatest in the first few days following repair, and so the perfusion branches are

left open during this time. Five to ten days postoperatively the branches are then closed with Amplatzer plugs to complete exclusion of the aneurysm. This is performed via a single percutaneous groin puncture under local anesthesia, which allows continuous monitoring of neurological function. Test balloon occlusions of the branches are performed and there is clinical evaluation of the patient's neurological symptoms for approximately 30 minutes. If no symptoms are experienced, the branch is then closed. The choice of five to ten days for closure of the perfusion branch is empiric, as most delayed SCI occurs in the first 72 hours postoperatively. This technique was used in ten patients with type II (the most extensive) TAAAs. One developed monoparesis of the right leg during a period of hypotension secondary to a cardiac event and died within 30 days. Two patients developed lower limb weakness after closure of the perfusion branches, but subsequently recovered full recovery. The concept behind the technique described is that perfusion of the sac by a controlled endoleak may protect spinal cord perfusion in the immediate postoperative period when the risk of hemodynamic instability is greatest. Extensive segmental artery sacrifice can be delayed until the patient has recovered from the first stage of the procedure and some remodeling of the collateral network may have occurred. Two patients in this series developed neurological symptoms after closure of the perfusion branches, thus supporting the hypothesis that perfusion of the sac in the postoperative period does have a protective effect. If any symptoms are experienced the procedure can be abandoned and attempted at a later date when further remodeling of the collateral network is likely to have occurred. This small case series indicates that controlled perfusion of segmental vessels with a temporary controlled endoleak is feasible, and may be a useful adjunct to prevent SCI, providing protection to spinal cord perfusion during the immediate postoperative period when risk of SCI is greatest.

Cerebrospinal fluid drainage (Figure 7) Use of prophylactic cerebrospinal fluid drainage in open surgery has been the subject of two meta-analyses [28, 29]. Although based on a small number of cases, both concluded that prophylactic drainage significantly reduces the risk of perioperative paraplegia or paraparesis. A Cochrane review undertaken to determine the effect of CSFD during thoracic and TAAA surgery on the risk of developing spinal cord injury concluded CSFD may increase the perfusion pressure to the spinal cord and hence reduce the risk of ischemic spinal cord injury [29]. To date, three randomized controlled trials have examined the benefits of lumbar CSFD in open TAAA repairs, which were the three trials included in the Cochrane review with a total of 287 participants operated on for type I or II TAAA. In the first trial of 98 participants (46 patients with CSFD and 52 controls), neurological deficits in the lower extremities occurred in 14 (30%) of the CSFD group and 17 (33%) of the controls [30]. The deficit was observed within 24 hours of the operation in 21 (68%), and from three to 22 days in 10 (32%) participants. CSFD did not have a statistically significant benefit in preventing paraplegia ($p=0.8$), and the only significant predictor of delayed deficits was postoperative hypotension ($p=0.006$). The second trial of 33 participants used a combination of CSFD and intrathecal papaverine (IP, a vasodilator and smooth muscle relaxant); 17 patients randomised to CSFD+IP and 16 to control group [31]. They showed the combined treatment had statistically significant reduction in the rate of postoperative neurological deficit (2/17 developed neurological injury) compared to controls (7/16, $p=0.0392$). Control patients also

had lower postoperative motor strength scores ($p=0.0340$). Multivariate analysis of risk factors for neurological injury included ($p<0.05$) longer cross-clamp time, failure to actively cool with bypass and postoperative hypotension, whereas CSFD+IP were found to be protective. Logistic regression showed that CSFD+IP and active cooling significantly reduced the risk of injury and that the two combined modalities had a cumulative protective effect. In the third trial, which is the largest and most recent, TAAA repair was performed on 145 participants; 76 with CSFD and 69 without [32]. CSFD was initiated during the operation and continued for 48 hours after surgery. Paraplegia or paraparesis occurred in 9/74 patients (12.2%) in the control group vs. 2/82 (2.7%) receiving CSFD ($p=0.03$). Overall, CSFD resulted in an 80% reduction in the relative risk of postoperative deficits. The Cochrane meta-analysis showed an odds ratio (OR) of 0.48 (95 % confidence interval (CI) 0.25 to 0.92). For CSFD-only trials, OR was 0.57 (95% CI 0.28 to 1.17) and for intention-to-treat analysis in CSFD-only studies, the OR remained unchanged. The review therefore concluded that there is limited evidence that perioperative CSFD appears to reduce the rate of paraplegia after repair of type I and type II TAAA. CSFD is recommended as a component of the multimodal approach for the prevention of neurological injury, and use of CSFD alone as protection was not established from the available evidence.

The role of prophylactic CSFD in endovascular procedures is more contentious, and level 1 evidence supporting its role is currently lacking. Wong et al undertook a systematic review to determine if preoperative CSFD reduces SCI with TEVAR [33]. Study quality was generally poor to moderate (median Downs and Black score, 9). The systematic review identified 46 eligible studies comprising 4936 patients; overall, SCI affected 3.89% (95% confidence interval, 2.95.05% to 4.95%). Series reporting routine prophylactic drain placement or no prophylactic drain placement reported pooled SCI rates of 3.2% and 3.47% respectively. The pooled SCI rate from 24 series stating that prophylactic drainage was used selectively was 5.6%. However, in all of these series prophylactic CSFDs were placed only in patients deemed at high risk of perioperative SCI. Thus, there is an inherent bias in the analysis in that the CSFD group was at increased risk of SCI. The study concluded that the role of prophylactic CSFD is difficult to establish from the available literature, and high-quality studies are required to determine the role of prophylactic CSF drainage in TEVAR. A single-institution experience of TEVAR using the same proactive spinal cord ischemia protection protocol used in open repair reported proactive spinal cord protective protocols appear to reduce the incidence of spinal ischemia after TEVAR compared with previous series [34]. The spinal cord ischemia protection included routine spinal drainage (spinal fluid pressure <10 mm Hg), endorphin receptor blockade (naloxone infusion), moderate intraoperative hypothermia (<35°C), hypotension avoidance (MAP>90 mmHg) and optimizing cardiac function. From 2005 to 2012, 94 consecutive TEVARs were studied, including 48 for TAA. Mean length of aortic coverage was 161mm, correlating to 59.4% aortic coverage. One patient had delayed paralysis (1.1%) and recovered enough to ambulate easily without assistance. This study recommends that active, as opposed to reactive approaches to spinal ischemia provide a better long-term outcome, and multimodal protection is essential, especially in cases of long segment coverage.

1.5. Adjuncts for the detection of paraplegia

Spinal cord monitoring The priority with thoracic and TAAA repair is the prevention of spinal cord ischemia, followed by the detection and treatment of its occurrence as early as possible to limit injury [35]. These repairs generally require the use of general anesthesia and this is routine practice at our unit. As a result neurological injury is impossible to detect intraoperatively through clinical examination. Neurophysiologic monitoring can therefore be employed in this setting to detect intraoperative injury so that timely interventions can be instigated to improve spinal cord perfusion. In certain institutions TEVAR is performed under loco-regional anaesthesia and if this is the case, routine neuromonitoring or spinal cord protection with CSFD is not required as management such as CSFD can be implemented when clinically required based on examination of the conscious patient.

The two types of intraoperative monitoring used regularly, either alone or in combination, are transcortical motor evoked potentials (MEP) and somatosensory evoked potentials (SSEP) [35]. MEPs are recorded from muscles in the extremities by delivering multi-pulse electrical stimulation to the scalp overlying the motor cortex. The evoked potentials elicited from this stimulation travel from the motor cortex through cortical spinal tracts, anterior horn cell, peripheral nerve, and finally to muscle. An interruption in this pathway will result in loss of the motor evoked potential [36]. Somatosensory evoked potential involves repetitive stimulation of peripheral nerves such as the posterior tibial nerve at the ankle or median nerve at the wrist, followed by the recording of the averaged electrical response in the peripheral nerve, spine, and the cerebral sensory cortex [35]. Most experts in the field believe that intraoperative neuromonitoring is critical in these procedures, although this is largely based on personal clinical experience. These decisions are not based on randomized controlled trials nor do they take into account potential complications and consequences that false positives can have on outcomes in these patients. For example a study examined 97 cases of open (40) and thoracic endovascular stent repairs (57), which were performed with MEP and SSEP monitoring [37]. They used a 50% reduction in amplitude of both cortical SSEPs and transcranial MEP compound motor action potentials as their criteria for potential signs of spinal ischemia. Results included; 63 event-free patients with normal potentials, fourteen patients with accurate correlation between elicited potentials and corresponding neurological outcomes (initial drop and subsequent regeneration in ten patients, six with normal neurological outcomes, four with transient neurological deficit postoperatively and four who suffered paraplegia with no intraoperative evoked potential), three false-positives, one false-negative and sixteen cases with associated with medication (halogenated anesthetic) interaction or technical issues. They observed a sensitivity of 93% and a specificity of 96% for the neurophysiological monitoring.

The choice of whether to use neuromonitoring remains unclear as there still remain difficulties in the successful use of MEPs from the standpoint of safety, technology and experience [35]. In these particular operations there is a significant downside in falsely identifying spinal cord ischemia with MEPs. The maneuvers utilized to treat spinal ischemia such as induced hypertension and arterial reimplantation have potential complications themselves including an increased risk of bleeding, increased length of surgery and even increased mortality [37]. SSEPs may fail to reliably predict all presentations of paralysis and cannot provide evidence

as to whether ischemic events are coincidental or isolated peripheral vascular events (clots and emboli causing distal damage) or secondary to a reduction in spinal cord perfusion. Lower extremity perfusion disturbances may occur for a variety of reasons during these procedures and the raw SSEP signals provide ambiguous quantitative correlation to intraoperative events [35]. The use of MEP requires specialized anesthetic protocols such as the use of short-acting paralytics during intubation only and eliminating the use of halogenated agents, which can make the procedure more challenging for the anesthetic team. However, the availability of intravenous anesthetics such as propofol and remifentanyl make MEP monitoring during TAAA repairs feasible when indicated. Patients undergoing these procedures are often sedated in the postoperative period making clinical assessment difficult, and they do not routinely undergo continued neurophysiologic monitoring during this time. The postoperative period is one of great hemodynamic instability and it is quite possible that a number of patients develop SCI at this time. For this reason it is suggested that patients continue to undergo monitoring until they arouse from anesthesia. MEPS cannot be monitored on extubated patients due to the pain involved in delivering the stimulus, but SSEP can be continued postoperatively. Another disadvantage of such neuromonitoring techniques is the need for neurophysiology expertise to interpret the complex waveforms, which is not always available or practical, particularly in the emergency setting. The authors are currently conducting a feasibility study for a technique of physician-interpreted (i.e. anesthetic and surgical teams) MEP monitoring, without the requirement of neurophysiology input.

Monitoring of spinal cord integrity remains challenging and difficult to interpret and further tests for the timely diagnosis of SCI are required. A recent study evaluated the feasibility of non-invasive monitoring of the paraspinal collateral network oxygenation using near-infrared spectroscopy (NIRS) prior to, during and after TAAA repair in a small clinical series [38]. NIRS optrodes were positioned bilaterally over the thoracic and lumbar paraspinal muscles (and thereby the paraspinal vasculature collateral network) to transcutaneously monitor muscle oxygenation in the collateral network to provide real-time non-invasive monitoring potentially indicating pending SCI in 20 patients undergoing repair of type I, II and III TAAAs. Lumbar oxygenation dropped significantly during open repair (n=15) after proximal aortic cross-clamping, but fully recovered after restoration of pulsatile flow to 98.5% of baseline. During TEVAR (n=3), stent-graft deployment did not significantly affect lumbar oxygenation. Three patients developed SCI, and in these patients lumbar oxygenation reduction after aortic cross-clamping was significantly lower compared to those with no neurological deficit ($p=0.041$). The study demonstrated this technique is feasible, and lumbar collateral network oxygenation levels directly respond to compromise of aortic circulation. Further studies are needed to corroborate these findings.

Biomarkers Although ischemia-related damage with thoracic aortic repair usually occurs intraoperatively, confirmation of neurological injury often does not occur until the postoperative period when anesthetic effects have resolved and the patients can be evaluated clinically [39]. Often patients remain sedated for prolonged periods following their procedure and therefore methods to detect the onset of acute SCI during the intraoperative and immediate postoperative period would be extremely valuable. Biomarkers for the

real-time detection of ongoing SCI or prediction of an increased risk for paralysis would potentially provide time to intervene and would be of great benefit in preventing SCI. Tissue ischemia caused by decreased spinal cord or brain perfusion is a potent and powerful stressor that triggers many metabolic and inflammatory pathways [36]. CSF is produced continuously and the total CSF compartment volume is replaced three times a day under normal conditions. The composition of CSF is dependent on metabolite production from the brain, and as CSF bathes the neural tissues of the brain and spinal cord, it should allow detection of the biochemical products of acute central nervous system ischemia more rapidly than in serum, particularly if the blood brain barrier is intact. Specific biochemical markers that have been examined to date include lactate, pCO₂, neuron-specific enolase (NSE), glucose, pH and S100 β . Existing molecular markers for neurological injury such as S100 β have low sensitivity and specificity making them unsuitable for routine clinical use. These markers also increase in serum at other times including during surgical procedures unrelated to acute brain injury, are often slow to increase and hence not useful for rapid 'on-table' detection. The biochemical signs of cerebrospinal injury have been shown to occur in patients without any clinically detectable neurological deficits and it is often difficult to establish a pattern of proportionality between the degree of ischemia and biomarker parameter increases. In addition, the markers can be confounded by conditions such as hemolysis, extra-cerebral sources and resuscitation, thereby not providing a sensitive prognostic tool [39]. As a result, none of the putative markers of injury in blood or CSF reliably detect early brain or spinal cord ischemia or validated surrogate endpoint measures as yet.

Heat shock proteins Heat shock proteins (HSPs) are members of highly conserved families of molecular chaperones that have multiple roles in vivo, and they are rapidly induced by severe stress. The inducible members of the HSP70 and HSP27 families are associated with cellular protection and recovery after a near lethal stress and have also been used as markers for tissues or organs that have been exposed to near-lethal stress [41]. The levels of HSPs in CSF from patients undergoing thoracic aneurysm repair have been analyzed. Blood and CSF samples were collected at regular intervals, and CSF was analyzed by enzyme-linked immunosorbent assay for HSP70 and HSP27. These results were correlated with intraoperative somatosensory-evoked potentials measurements and postoperative paralysis. They found the levels of these proteins in many of these patients are elevated and that the degree of elevation correlates with the risk of permanent paralysis. They hypothesized that sequential intraoperative measurements of heat shock proteins HSP70 and HSP27 levels in CSF could predict those patients who are at greatest risk for paralysis during thoracic aneurysm repair. Further work is in progress by the group to develop these markers to prevent or attenuate this severe complication.

Metabonomics An individual's phenome describes the biochemical expression of genomic and environmental disease risk and is based on the analysis of small molecules and metabolites. Metabonomics is the quantitative measurement of the dynamic multiparametric metabolic response of living systems to pathophysiological stimuli used in patient phenotyping [42]. Emerging techniques enable rapid measurement of large arrays of metabolites, which could greatly enhance the 'on table' decision-making process during surgery. Spectroscopic methods

have been applied to generate multivariate profiles of metabolites, mainly using nuclear magnetic resonance (NMR) spectroscopy and mass spectrometry (MS) methods that can measure a wide range of metabolites simultaneously. The data are then analyzed using multivariate statistics [43]. Rapid evaporative ionization mass spectrometry is an emerging technique that allows near real-time characterization of human tissue *in vivo* by analysis of aerosol smoke released during electrosurgical dissection, and this technique has shown that near real-time spectro-profiling in the clinical environment is a possibility [44]. CSF provides an ideal medium for analysis of biomarkers indicating neurological injury since metabolites of anaesthetic agents and other drugs are restricted by the blood-brain barrier. Patients undergoing TAA and TAAA at our unit routinely have a spinal drain inserted preoperatively if clinically indicated, and this spinal drain remains *in situ* for approximately 48 to 72 hours postoperatively. This provides a constant source of CSF available for study, and the authors are currently conducting a study to analyse CSF using a metabolic phenotyping approach to identify novel biomarkers for neurological ischemia, with a view to developing a platform for near real-time intraoperative diagnostics.

1.6. Outcomes of paraplegia

In order to define the outcome of patients experiencing SCI after TEVAR and determine the differences in the evolution of long-term functional recovery and the effect on survival, 607 TEVARs performed between 2000 and 2011 were analysed [45]. Fifty-seven patients (9.4%) were noted to have postoperative SCI. SCI developed immediately in twelve patients, had delayed onset in forty and was indeterminate in five patients due to postoperative sedation. Three patients (25%) with immediate SCI had measurable functional improvement based on ambulatory status, whereas twenty-eight (70%) of the delayed-onset patients experienced some degree of neurological recovery ($p=0.04$). Of the thirty-four patients with complete data available, twenty-six (76%) reported quantifiable functional improvement, but only thirteen (38%) experienced return to their preoperative baseline. Estimated mean survival for patients with and without SCI was 37.2 and 71.6 months respectively ($p<0.0006$). Patients with functional improvement had a mean survival of 53.9 months compared with 9.6 months for those without improvement ($p<0.0001$). The study concluded that only a minority of patients experience complete return to baseline function after SCI with TEVAR, and outcomes in patients without early functional recovery are particularly poor. Patients experiencing delayed SCI are more likely to have functional improvement and following neurological recovery may anticipate similar life expectancy compared to patients without SCI.

In addition to the personal consequences to the patient, family and carers, paraplegia is associated with a significant economic burden. Recurring annual costs of caring for patients with chronic spinal cord injury is a large economic burden on health care systems, but information on costs of spinal cord injury care beyond the acute and initial post-acute phase is minimal [46]. The annual direct medical costs associated with healthcare for a sample of 675 patients with chronic spinal cord injury greater than two years after injury were investigated. The total (inpatient and outpatient) annual direct medical cost was \$21,450 per patient. Average inpatient cost per patient for complete and incomplete thoracic spinal cord injury was

\$30,612 and \$24,883 respectively, which included laboratory, nursing, pharmacy, radiology, surgery and inpatient stay costs. Average outpatient costs were \$9954 and \$8925 respectively. However, community care costs such as nursing home or respite stays, occupational therapy and home adaptations, as well as indirect costs such as carers and sickness benefits also need to be considered. To our knowledge there are no studies to date quantifying the economic burden of paraplegia as a complication of aortic intervention.

1.7. Spinal cord imaging

At our unit magnetic resonance (MR) imaging of the spine is performed if SCI is suspected to confirm the diagnosis and exclude any other cause of myelopathy such as extrinsic compression. MRI is the most sensitive method for verifying cord ischemia or infarction, and current techniques of diffusion-weighted images can be particularly sensitive and diagnostic. Mawad et al conducted a study where magnetic resonance (MR) imaging was obtained on 25 patients developing symptoms of spinal cord ischemia following resection and graft replacement of thoracoabdominal aortic aneurysms [47]. MR studies were abnormal in 17 patients, which correlated well with the somatosensory evoked potential studies, which were abnormal in all 17 patients. All the MRI signal abnormalities were found in the low thoracic cord and conus medullaris, regardless of the severity of the clinical findings. Four patients with mid thoracic aneurysms experienced transient SCI with good clinical outcome where patients were ambulatory following recovery; MR abnormality was in the low thoracic region in one patient and low thoracic region and conus in three, with focal abnormal MR signals limited to grey matter. Twelve patients with mid thoracic and thoracoabdominal aneurysms experienced complete SCI where patients were not ambulatory with 0/5 motor function assessed on the muscle strength scale 0-5; MR abnormality was in the conus in five patients, mid to low thoracic region and conus in five patients, low thoracic region in one and low thoracic region and conus in one, with diffuse abnormal MR signals involving both grey and white matter. Significant advances in MRI modalities and techniques have taken place since the study was published in 1990, but identification of the most common sites for spinal cord ischemia following aneurysm repair remains an important finding.

Abbreviations

TAA-Thoracic aortic aneurysm

TAAA-Thoracoabdominal aortic aneurysm

TAD-Thoracic aortic dissection

TEVAR-Thoracic Endovascular Aortic Repair

MAP-Mean arterial pressure

CSF-Cerebrospinal fluid

SCI-Spinal cord ischemia

CSFD-Cerebrospinal fluid drainage

LSCA-Left subclavian artery

OR-Odds ratio

MEP-Motor evoked potentials

SSEP-Somatosensory evoked potentials

Author details

Anisha H. Perera* and Richard G.J. Gibbs

*Address all correspondence to: r.gibbs@imperial.ac.uk

Department of Vascular Surgery, St Mary's Hospital, Imperial College Healthcare NHS Trust, London, UK

References

- [1] Conrad MF, Cambria RP. Contemporary management of descending thoracic and thoracoabdominal aortic aneurysms: endovascular versus open. *Circulation*. 2008;117(6) 841-52.
- [2] Yamauchi T, Takano H, Nishimura M, Matsumiya G, Sawa Y. Paraplegia and paraparesis after descending thoracic aortic aneurysm repair: a risk factor analysis. *Ann Thorac Cardiovasc Surg*. 2006;12(3) 179-83.
- [3] Estrera AL, Rubenstein FS, Miller CC 3rd, Huynh TT, Letsou GV, Safi HJ. Descending thoracic aortic aneurysm: surgical approach and treatment using the adjuncts cerebrospinal fluid drainage and distal aortic perfusion. *Ann Thorac Surg*. 2001;72(2) 481-6.
- [4] Coselli JS, Lemaire SA, Koksoy C, Schmittling ZC, Curling PE. Cerebrospinal fluid drainage reduces paraplegia after thoracoabdominal aortic aneurysm repair: results of a randomized clinical trial. *J Vasc Surg*. 2002;35(4) 631-9.
- [5] Safi HJ, Miller CC 3rd, Huynh TT, Estrera AL, Porat EE, Winnerkvist AN, Allen BS, Hassoun HT, Moore FA. Distal aortic perfusion and cerebrospinal fluid drainage for thoracoabdominal and descending thoracic aortic repair: ten years of organ protection. *Ann Surg*. 2003;238(3) 372-80.
- [6] Svensson LG, Crawford ES, Hess KR, Coselli JS, Safi HJ. Experience with 1509 patients undergoing thoracoabdominal aortic operations. *J Vasc Surg*. 1993;17(2) 357-70.

- [7] Drinkwater SL, Goebells A, Haydar A, Bourke P, Brown L, Hamady M, Gibbs RG; Regional Vascular Unit, St Mary's Hospital, Imperial College NHS Trust. The incidence of spinal cord ischaemia following thoracic and thoracoabdominal aortic endovascular intervention. *Eur J Vasc Endovasc Surg.* 2010;40(6) 729-35.
- [8] Gravereaux EC, Faries PL, Burks JA, Latessa V, Spielvogel D, Hollier LH, Marin ML. Risk of spinal cord ischemia after endograft repair of thoracic aortic aneurysms. *J Vasc Surg.* 2001;34(6) 997-1003.
- [9] von Allmen RS, Anjum A, Powell JT. Incidence of descending aortic pathology and evaluation of the impact of thoracic endovascular aortic repair: a population-based study in England and Wales from 1999 to 2010. *Eur J Vasc Endovasc Surg.* 2013;45(2): 154-9.
- [10] McGarvey ML, Mullen MT, Woo EY, Bavaria JE, Augoustides YG, Messé SR, Cheung AT. The treatment of spinal cord ischemia following thoracic endovascular aortic repair. *Neurocrit Care.* 2007;6(1) 35-9.
- [11] Bicknell CD, Riga CV, Wolfe JH. Prevention of paraplegia during thoracoabdominal aortic aneurysm repair. *Eur J Vasc Endovasc Surg.* 2009 Jun;37(6) 654-60.
- [12] Etz CD, Kari FA, Mueller CS, Silovitz D, Brenner RM, Lin HM, Griep RB. The collateral network concept: a reassessment of the anatomy of spinal cord perfusion. *J Thorac Cardiovasc Surg.* 2011;141(4) 1020-8.
- [13] Carroccio A, Marin ML, Ellozy S, Hollier LH. Pathophysiology of paraplegia following endovascular thoracic aortic aneurysm repair. *J Card Surg.* 2003;18(4) 359-66.
- [14] Acher C, Wynn M. Paraplegia after thoracoabdominal aortic surgery: not just assisted circulation, hypothermic arrest, clamp and sew, or TEVAR. *Ann Cardiothorac Surg.* 2012;1(3) 365-72.
- [15] Etz CD, Luehr M, Kari FA, Bodian CA, Smego D, Plestis KA, Griep RB. Paraplegia after extensive thoracic and thoracoabdominal aortic aneurysm repair: does critical spinal cord ischemia occur postoperatively? *J Thorac Cardiovasc Surg.* 2008;135(2) 324-30.
- [16] Ullery BW, Cheung AT, Fairman RM, Jackson BM, Woo EY, Bavaria J, Pochettino A, Wang GJ. Risk factors, outcomes, and clinical manifestations of spinal cord ischemia following thoracic endovascular aortic repair. *J Vasc Surg.* 2011;54(3) 677-84.
- [17] Czerny M, Eggebrecht H, Sodeck G, Verzini F, Cao P, Maritati G, Rimbau V, Beyersdorf F, Rylski B, Funovics M, Loewe C, Schmidli J, Tozzi P, Weigang E, Kuratani T, Livi U, Esposito G, Trimarchi S, van den Berg JC, Fu W, Chiesa R, Melissano G, Bertoglio L, Lonn L, Schuster I, Grimm M. Mechanisms of symptomatic spinal cord ischemia after TEVAR: insights from the European Registry of Endovascular Aortic Repair Complications (EuREC). *J Endovasc Ther.* 2012;19(1) 37-43.
- [18] Baril DT, Carroccio A, Ellozy SH, Palchik E, Addis MD, Jacobs TS, Teodorescu V, Marin ML. Endovascular thoracic aortic repair and previous or concomitant abdomi-

- nal aortic repair: is the increased risk of spinal cord ischemia real? *Ann Vasc Surg.* 2006;20(2) 188-94.
- [19] Zipfel B, Buz S, Redlin M, Hullmeine D, Hammerschmidt R, Hetzer R. Spinal cord ischemia after thoracic stent-grafting: causes apart from intercostal artery coverage. *Ann Thorac Surg.* 2013;96(1) 31-8.
- [20] Acher CW, Wynn MM, Mell MW, Tefera G, Hoch JR. A quantitative assessment of the impact of intercostal artery reimplantation on paralysis risk in thoracoabdominal aortic aneurysm repair. *Ann Surg.* 2008 Oct;248(4):529-40.
- [21] Peterson BG, Eskandari MK, Gleason TG, Morasch MD. Utility of left subclavian artery revascularization in association with endoluminal repair of acute and chronic thoracic aortic pathology. *J Vasc Surg.* 2006;43(3) 433-9.
- [22] Lee TC, Andersen ND, Williams JB, Bhattacharya SD, McCann RL, Hughes GC. Results with a selective revascularization strategy for left subclavian artery coverage during thoracic endovascular aortic repair. *Ann Thorac Surg.* 2011;92(1) 97-103.
- [23] Cooper DG, Walsh SR, Sadat U, Noorani A, Hayes PD, Boyle JR. Neurological complications after left subclavian artery coverage during thoracic endovascular aortic repair: a systematic review and meta-analysis. *J Vasc Surg.* 2009;49(6) 1594-601.
- [24] Rizvi AZ, Murad MH, Fairman RM, Erwin PJ, Montori VM. The effect of left subclavian artery coverage on morbidity and mortality in patients undergoing endovascular thoracic aortic interventions: a systematic review and meta-analysis. *J Vasc Surg.* 2009;50(5) 1159-69.
- [25] Matsumura JS, Lee WA, Mitchell RS, Farber MA, Murad MH, Lumsden AB, Greenberg RK, Safi HJ, Fairman RM; Society for Vascular Surgery. The Society for Vascular Surgery Practice Guidelines: management of the left subclavian artery with thoracic endovascular aortic repair. *J Vasc Surg.* 2009;50(5) 1155-8.
- [26] Maldonado TS, Dexter D, Rockman CB, Veith FJ, Garg K, Arko F, Bertoni H, Ellozy S, Jordan W, Woo E. Left subclavian artery coverage during thoracic endovascular aortic aneurysm repair does not mandate revascularization. *J Vasc Surg.* 2013;57(1) 116-24.
- [27] Harrison SC, Agu O, Harris PL, Ivancev K. Elective sac perfusion to reduce the risk of neurologic events following endovascular repair of thoracoabdominal aneurysms. *J Vasc Surg.* 2012;55(4) 1202-5.
- [28] Cinà CS, Abouzahr L, Arena GO, Laganà A, Devereaux PJ, Farrokhyar F. Cerebrospinal fluid drainage to prevent paraplegia during thoracic and thoracoabdominal aortic aneurysm surgery: a systematic review and meta-analysis. *J Vasc Surg.* 2004;40 36-44.
- [29] Khan SN, Stansby G. Cerebrospinal fluid drainage for thoracic and thoracoabdominal aortic aneurysm surgery. *Cochrane Database Syst Rev.* 2012;(10) CD003635.

- [30] Crawford ES, Svensson LG, Hess KR, Shenaq SS, Coselli JS, Safi HJ, Mohindra PK, Rivera V. A prospective randomized study of cerebrospinal fluid drainage to prevent paraplegia after high-risk surgery on the thoracoabdominal aorta. *J Vasc Surg.* 1991;13(1) 36-45.
- [31] Svensson LG, Hess KR, D'Agostino RS, Entrup MH, Hreib K, Kimmel WA, Nadolny E, Shahian DM. Reduction of neurologic injury after high-risk thoracoabdominal aortic operation. *Ann Thorac Surg.* 1998;66(1) 132-8.
- [32] Coselli JS, Lemaire SA, Koksoy C, Schmittling ZC, Curling PE. Cerebrospinal fluid drainage reduces paraplegia after thoracoabdominal aortic aneurysm repair: results of a randomized clinical trial. *J Vasc Surg.* 2002;35(4) 631-9.
- [33] Wong CS, Healy D, Canning C, Coffey JC, Boyle JR, Walsh SR. A systematic review of spinal cord injury and cerebrospinal fluid drainage after thoracic aortic endografting. *J Vasc Surg.* 2012;56(5) 1438-47.
- [34] Bobadilla JL, Wynn M, Tefera G, Acher CW. Low incidence of paraplegia after thoracic endovascular aneurysm repair with proactive spinal cord protective protocols. *J Vasc Surg.* 2013;57(6) 1537-42.
- [35] McGarvey ML. Effective tool or necessary evil: intraoperative monitoring during thoracic aneurysm repairs. *J Clin Neurophysiol.* 2012;29(2) 154-6.
- [36] Hecker JG, McGarvey M. Heat shock proteins as biomarkers for the rapid detection of brain and spinal cord ischemia: a review and comparison to other methods of detection in thoracic aneurysm repair. *Cell Stress Chaperones.* 2011;16(2) 119-31.
- [37] ter Wolbeek C, Hartert M, Conzelmann LO, Peivandi AA, Czerny M, Gottardi R, Beyersdorf F, Weigang E. Value and pitfalls of neurophysiological monitoring in thoracic and thoracoabdominal aortic replacement and endovascular repair. *Thorac Cardiovasc Surg.* 2010;58(5) 260-4.
- [38] Coselli JS, Tsai PI. Motor evoked potentials in thoracoabdominal aortic surgery: CON. *Cardiol Clin.* 2010;28(2) 361-8.
- [39] Etz CD, von Aspern K, Gudehus S, Luehr M, Girrbach FF, Ender J, Borger M, Mohr FW. Near-infrared Spectroscopy Monitoring of the Collateral Network Prior to, During, and After Thoracoabdominal Aortic Repair: A Pilot Study. *Eur J Vasc Endovasc Surg.* 2013;46 (6) 651-6.
- [40] Anderson RE, Winnerkvist A, Hansson LO, Nilsson O, Rosengren L, Settergren G, Vaage J. Biochemical markers of cerebrospinal ischemia after repair of aneurysms of the descending and thoracoabdominal aorta. *J Cardiothorac Vasc Anesth.* 2003;17(5) 598-603.
- [41] Hecker JG, Sundram H, Zou S, Praestgaard A, Bavaria JE, Ramchandren S, McGarvey M. Heat shock proteins HSP70 and HSP27 in the cerebral spinal fluid of patients

undergoing thoracic aneurysm repair correlate with the probability of postoperative paralysis. *Cell Stress Chaperones*. 2008;13(4) 435-46.

- [42] Nicholson JK, Lindon JC, Holmes E. 'Metabonomics': understanding the metabolic responses of living systems to pathophysiological stimuli via multivariate statistical analysis of biological NMR spectroscopic data. *Xenobiotica*. 1999;29(11) 1181-9.
- [43] Nicholson JK, Holmes E, Kinross JM, Darzi AW, Takats Z, Lindon JC. Metabolic phenotyping in clinical and surgical environments. *Nature*. 2012;491(7424) 384-92.
- [44] Balog J, Sasi-Szabó L, Kinross J, Lewis MR, Muirhead LJ, Veselkov K, Mirnezami R, Dezső B, Damjanovich L, Darzi A, Nicholson JK, Takáts Z. Intraoperative tissue identification using rapid evaporative ionization mass spectrometry. *Sci Transl Med*. 2013;5(194) 194ra93.
- [45] Desart K, Scali ST, Feezor RJ, Hong M, Hess PJ Jr, Beaver TM, Huber TS, Beck AW. Fate of patients with spinal cord ischemia complicating thoracic endovascular aortic repair. *J Vasc Surg*. 2013;58(3) 635-42.
- [46] French DD, Campbell RR, Sabharwal S, Nelson AL, Palacios PA, Gavin-Dreschnack D. Health care costs for patients with chronic spinal cord injury in the Veterans Health Administration. *J Spinal Cord Med*. 2007;30(5) 477-81.
- [47] Mawad ME, Rivera V, Crawford S, Ramirez A, Breitbach W. Spinal cord ischemia after resection of thoracoabdominal aortic aneurysms: MR findings in 24 patients. *AJR Am J Roentgenol*. 1990;155(6) 1303-7.

