

We are IntechOpen, the world's leading publisher of Open Access books Built by scientists, for scientists

4,800

Open access books available

122,000

International authors and editors

135M

Downloads

Our authors are among the

154

Countries delivered to

TOP 1%

most cited scientists

12.2%

Contributors from top 500 universities



WEB OF SCIENCE™

Selection of our books indexed in the Book Citation Index
in Web of Science™ Core Collection (BKCI)

Interested in publishing with us?
Contact book.department@intechopen.com

Numbers displayed above are based on latest data collected.

For more information visit www.intechopen.com



Mechanical Complications of Acute Myocardial Infarction

Luís Augusto Palma Dallan,
Luiz Roberto Palma Dallan,
Luiz Augusto Ferreira Lisboa and
Luís Alberto Oliveira Dallan

Additional information is available at the end of the chapter

<http://dx.doi.org/10.5772/57110>

1. Introduction

Patients with acute myocardial infarction (AMI) may have hemodynamic, electrical or mechanical complications. The acute mechanical complications are serious events with worse prognosis. When the AMI evolves into a mechanical complication, surgical therapy is mandatory, in order to decrease the high mortality in this group of patients [4].

The main mechanical complications of acute myocardial infarction correspond to: 1 - Ventricular free wall rupture, 2 - Ventricular septal rupture, 3 - Mitral regurgitation with or without ischemic papillary muscle rupture and 4 - Left ventricular aneurysm (a 2, 7).

The mechanical complications of AMI are responsible for approximately 25,000 deaths per year in the United States [8]. The ISIS-2 study showed an increased occurrence of ventricular rupture associated with thrombolytic therapy, especially in the first 24 hours of AMI and when thrombolysis had a late administration. This is due to transformation of ischemic to hemorrhagic infarction and therefore easier to rupture. [19]

However, with the advent of early thrombolytic therapy and primary coronary angioplasty, which reduced ischemia and the size of the myocardial infarction, it is estimated that this incidence has decreased in the last two decades. [7] The incidence of these diseases can be seen in Table 1.

	Ventricular free wall rupture	Ventricular Septum Rupture	Ischemic Papillary Muscle Rupture	Left Ventricular Aneurysm
Prevalence	1-3% without reperfusion therapy, 3,9% in cardiogenic shock	0,8 - 6,2%	1%, greater incidence in the post-medial papillary muscle rupture	5 a 38%, greater incidence in anterior AMI
Reduction with early reperfusion	Yes	Yes	Yes	Yes

Table 1. Incidence of major mechanical complications of acute myocardial infarction [1, 2, 3, 6, 19]

In table 2 are shown the most frequent sites of rupture in fatal cases of mechanical complications after AMI.

Site	Rupture Incidence (%)
Free Ventricular wall	85
Ventricular Septum	10
Pappilary muscle	5

Table 2. Most frequent sites of rupture in fatal cases of mechanical complications after AMI. [7]

Mechanical defects usually occur in the first two weeks after AMI, with bimodal incidence, especially in the first 24 hours of AMI and after 3-5 days of its inception.

The diagnosis should be suspected whenever a patient shows signs and symptoms of hemodynamic instability, and can be established with precision from the transthoracic or transeosophageal echocardiography. Pulmonary artery catheterization and monitoring of hemodynamic parameters can also be useful for detecting the defect and to guide their approach. [1, 3]

Surgical evaluation should be performed early whenever there is suspicion of a mechanical complication. Surgical treatment of emergency / urgency is indicated in most cases because the clinical treatment alone is related to high mortality rates [1, 3].

2. Diagnosis

The early diagnosis and intervention are important in trying to alter the course of an adverse outcome of patients with mechanical complications after AMI.

For the diagnosis of mechanical complications, it is necessary high degree of clinical suspicion. Besides the physical examination, imaging tests such as two-dimensional echocardiog-

raphy and color Doppler are useful and practical, since they have high specificity and can be performed at bedside. Transesophageal echocardiography may improve the diagnostic accuracy in these cases [7].

Diagnosis can also be confirmed by passing a Swan-Ganz catheter, which can result in an increase in the venous blood oxygenation in the case of ventricular septal defect, as shown in Table 3:

	Ventricularfreewallrupture	Ventricular Septum Rupture	IschemicPapillaryMuscle Rupture
Main findings in central catheterization	Clinical signs of cardiac tamponade may be seen (equalization of diastolic pressures between the heart chambers)	"Oximetric jump": Increase in oxygen saturation between the right atrium and the pulmonary artery, forming "Ventricular Shunt" Large "V" waves	No oximetric jump in the right ventricle; Presence of significant large "V" waves; high values of pulmonary capillary pressure

Table 3. Main findings in Swan-Ganz catheterization [2, 3]

More than half of the patients with ventricular rupture or papillary muscle have coronary artery disease in other arteries besides the charge of the infarcted area. Therefore, whenever possible, there should be performed coronary angiography to identify other lesions that requires surgical repair, avoiding further episodes of occlusion that would increase mortality [3, 7].

3. Clinical treatment

Clinical treatment should be instituted early in all cases of mechanical complications after AMI, and ideally should be carried out intensively in specific units such as Intensive Care Unit or Coronary Care Units. Inotropes and vasodilators should be used to ensure hemodynamic stabilization for subsequent surgical treatment [1].

The Swan-Ganz catheter brings important hemodynamic information, guiding the hydration and the administration of vasoactive drugs. In cases of ventricular rupture and cardiogenic shock originating from the right ventricle infarction, aggressive volume replacement is essential for the survival of the patient.

The use of ventricular assist with the insertion of intra-aortic balloon, particularly in patients with acute mitral regurgitation or ventricular septal rupture, helps stabilize the patient, preparing him for surgery.

4. Main mechanical complications

4.1. Ventricular free wall rupture (VFWR)

4.1.1. Incidence and evolution

The incidence of ventricular free wall rupture (VFWR) in AMIs varies between 0.8-6.2%. It occurs in about 10-24% of patients who die due to AMI and represents 85% of deaths from myocardial rupture. Thus, it is the third leading cause of death, surpassed only by cardiogenic shock and the ventricular arrhythmias. [2, 9, 10]

About 30% of cardiac ruptures occur within the first 24 hours after infarction. VFWR is also observed more frequently in women, elderly, during the first episode of AMI, and in patients with previous heart attacks.

It is seven times more frequent in the left ventricle than the right ventricle, and in most cases is associated with extensive transmural infarction, with involvement of the anterior or lateral territory irrigation of left anterior descending artery. [2, 11, 17]

Other factors that increase the incidence of heart failure are hypertension during the acute phase of infarction, lack of collateral circulation, absence of chest pain, associated mitral regurgitation, Q waves on ECG, the use of corticosteroids or non-steroidal anti-inflammatory and the use of fibrinolytic agents after more than 14 hours of symptom onset or when fibrinolytic therapy is ineffective. [3, 12]

4.1.2. Symptoms

The rupture can be complete, leading to severe hemopericardium and its consequences that usually result in death due to cardiac tamponade. It may also be incomplete, which occurs when a thrombus or a hematoma, together with the pericardium, seal the ventricular free wall lesion, avoiding hemopericardium and forming a pseudoaneurysm. [2]

The main clinical findings may be manifested by characteristic chest pain of angina, pericardial or pleuritic pain, syncope, hypotension, arrhythmias, nausea, fatigue, or sudden death. Physical examination may reveal jugular stasis [29%), paradoxical pulse (47%), electromechanical dissociation and cardiogenic shock. [3]

The main clinical manifestations of rupture of ventricular free wall, according to their type, are shown in table 4:

Acute	Massive hemorrhage, electromechanical dissociation; sudden death
Subacute	Moderate hemorrhage, cardiac tamponade, cardiogenic shock
Cronic	Minor hemorrhage, false aneurysm formation, heart failure

Table 4. The main clinical manifestations of rupture of ventricular free wall [4]

4.1.3. *Diagnosis*

The main electrocardiographic signs that can be observed are the preservation and increase of ST segment elevation in more than one derivation and sudden variations of the T wave, or the presence of ST segment elevation in aVL, prior to rupture, with rapid progression to collapse hemodynamic and electro-mechanical dissociation. It may be further evidenced sinus tachycardia and / or ST segment elevation in V5 and may be predictive of inferior wall myocardial infarction. [2]

The Swan-Ganz catheter data may show classic signs of cardiac tamponade (equalization of diastolic pressures between the heart chambers).

Echocardiography can demonstrate pericardial effusion greater than 5 mm, increased echotexture of the pericardial contents (blood clot), direct visualization of the lesion or signs of cardiac tamponade. [3]. In subacute or chronic cases, in addition to echocardiography, magnetic resonance imaging of the heart may help both to confirm the diagnosis and the orientation of the best surgical approach.

4.1.4. *Surgical treatment*

In most cases, surgical treatment is an emergency. Pericardial drainage can be performed for relief of cardiac tamponade before surgical correction. In this case, the patient should be prepared for cannulation and extracorporeal circulation, to prevent hemodynamic collapse. [12, 13]

The mortality of complete ventricular rupture is approximately 100%, and that surgical treatment reduces this ratio to values around 60%. [1, 2, 3]. Surgical treatment involves ventricular suture directly or with a patch to cover the ventricular perforation, always associated with revascularization when possible. The use of biological adhesives such as cyanoacrylate has been made to fix the patch around the necrotic tissue. [1, 12, 13]

Among the surgical techniques are: [1, 2, 12, 13]

- Infarctectomy and suturing the edges anchored in Teflon patch;
- Sutures of a large patch covering the infarcted area to fix the break;
- Use of a Teflon patch covering the infarcted area with use of biological glue.

In cases of subacute rupture with thrombus formation and spontaneous control of hemorrhage, there is an opportunity of the initial clinical treatment with stabilization and control of cardiogenic shock. In this situation the patient will be operated in better clinical conditions and consequently will improve surgical outcomes. However, the surgical indication must be to prevent premature rupture of the ventricle. [1]

The incomplete rupture of ventricular free wall, or also called "pseudo breaks" with false aneurysm formation, are more benign forms of presentation of this serious disease. In these cases, intensive medical therapy with hemodynamic control shows good initial results. The indication for surgery is delayed for 15 to 30 days after the acute phase of infarction, a period that has already begun to form myocardial fibrosis facilitating the surgical approach.

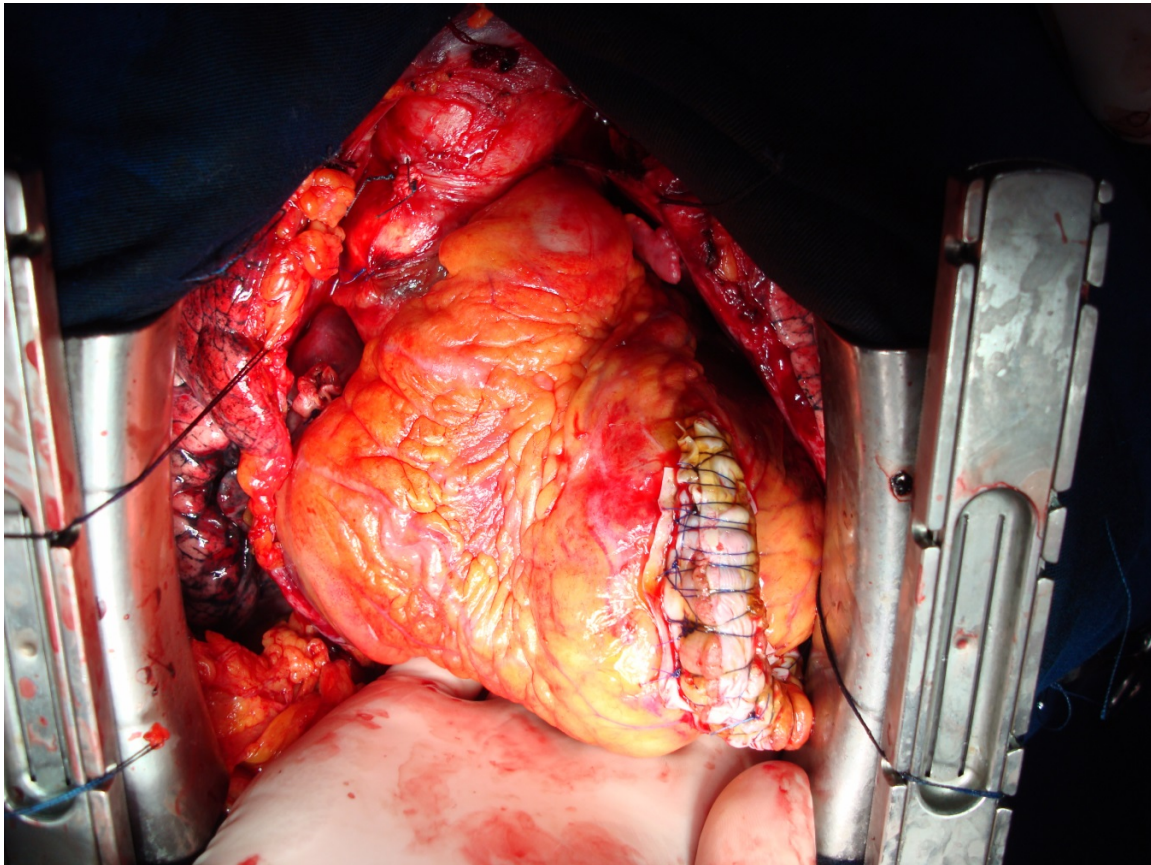


Figure 1. Surgical repair of acute left ventricular rupture

4.2. Ventricular septum rupture (VSR)

4.2.1. Incidence and evolution

The incidence of ventricular septal rupture (VSR) has declined since the beginning of fibrinolytic era, and reduced from 1-3% to 0.2%-0.3% with coronary reperfusion, as evidenced by the large GUSTO-I study.

Although there is an increased risk of ventricular rupture with the use of fibrinolytics, the early reperfusion and the decrease of the extension of the necrotic area are responsible for reducing the incidence of mechanical complications in such cases. [15]

It occurs most frequently between 3-7 days after AMI when recanalization therapy has not being done. [16] The mortality of VSR stays around 94%, while that in patients who underwent surgical treatment it is around 20-60% [1, 2, 3]

4.2.2. Symptoms

The main clinical findings may be manifested by rough holosystolic murmur in the region of the left lower sternal border, usually associated with clinical worsening of the patient, accentuated second heart sound, pulmonary edema, signs of right or left ventricular failure and cardiogenic shock. [2]

4.2.3. Diagnosis

The electrocardiogram is not specific. Echocardiography may show ventricular septal defect, left-right shunt on color Doppler through the septum, signs of right ventricular overload. Coronary angiography and cardiac catheterization confirmed the VSD and the coronary lesions. [2, 3] The data of the Swan-Ganz catheter may show an "oximetric jump", characterized by an increase in oxygen saturation between the right atrium and the pulmonary artery, forming the "Ventricular Shunt." In addition, waves can be observed "V" large.

4.2.4. Surgical treatment

Before surgery some essential cares should be performed, such as invasive monitoring, treatment with anti-arrhythmic drugs, inotropes, vasodilators and the passage of intra-aortic balloon in unstable patients.

The hemodynamic treatment of ventricular septal defect has been studied through the VSD closure with devices installed percutaneously. However, surgery remains the treatment of choice so far, mainly due to the small number of patients studied and lack of data that provides meaningful results and secure the new technique.

The urgent surgical treatment should be instituted in all patients, even those with preserved ventricular function, who do not have pulmonary edema or cardiogenic shock. Hemodynamic collapse even sudden death may happen, because the ventricular impaired location can suddenly expand the tissue stress and rupture [1, 3]

The earlier the surgery is performed, the better is the evolution of the patient. The techniques for surgical correction of this complication include: [1, 2, 7]

- Use of biological tissue preserved, with or without infarctectomy and aneurysmectomy;
- Apical amputation technique to correct the defect in this portion of the ventricle;
- Plication to repair the rupture in the anterior-septal;
- Use of Dacron or bovine pericardium endocardial and epicardial suture to support;
- Correction of posterior septal rupture using the pericardium in a "sandwich", including the septal defect and ventriculotomy;
- Use of biological glue such as cyanoacrylate.

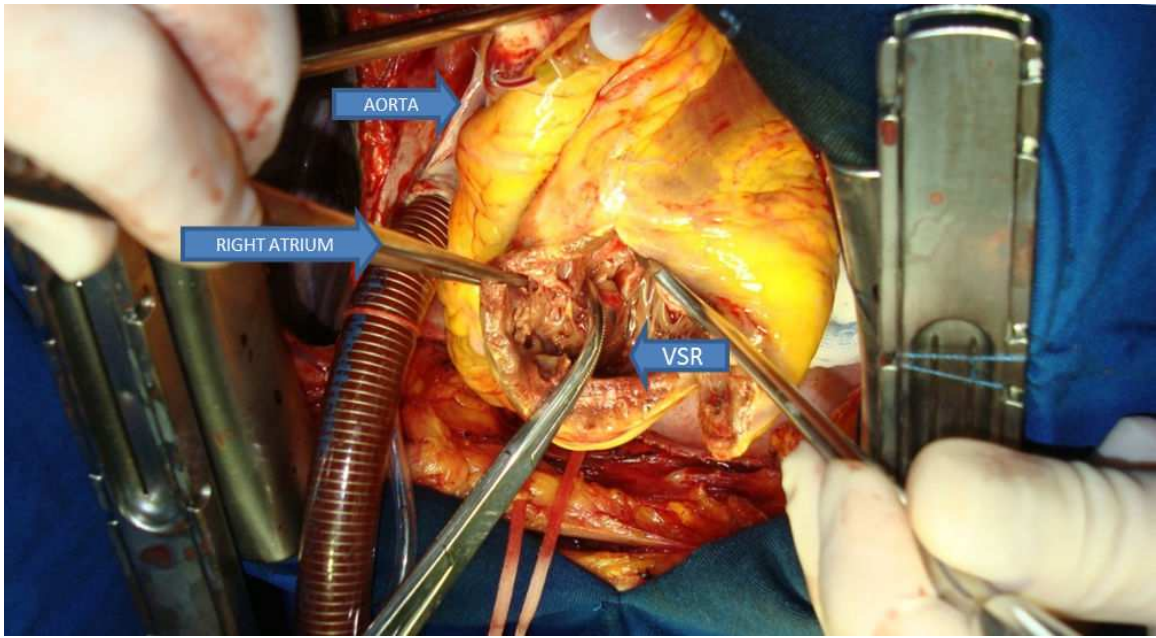


Figure 2. Ventricular septal rupture (VSR) accessed through anterior ventricular infarcted free wall

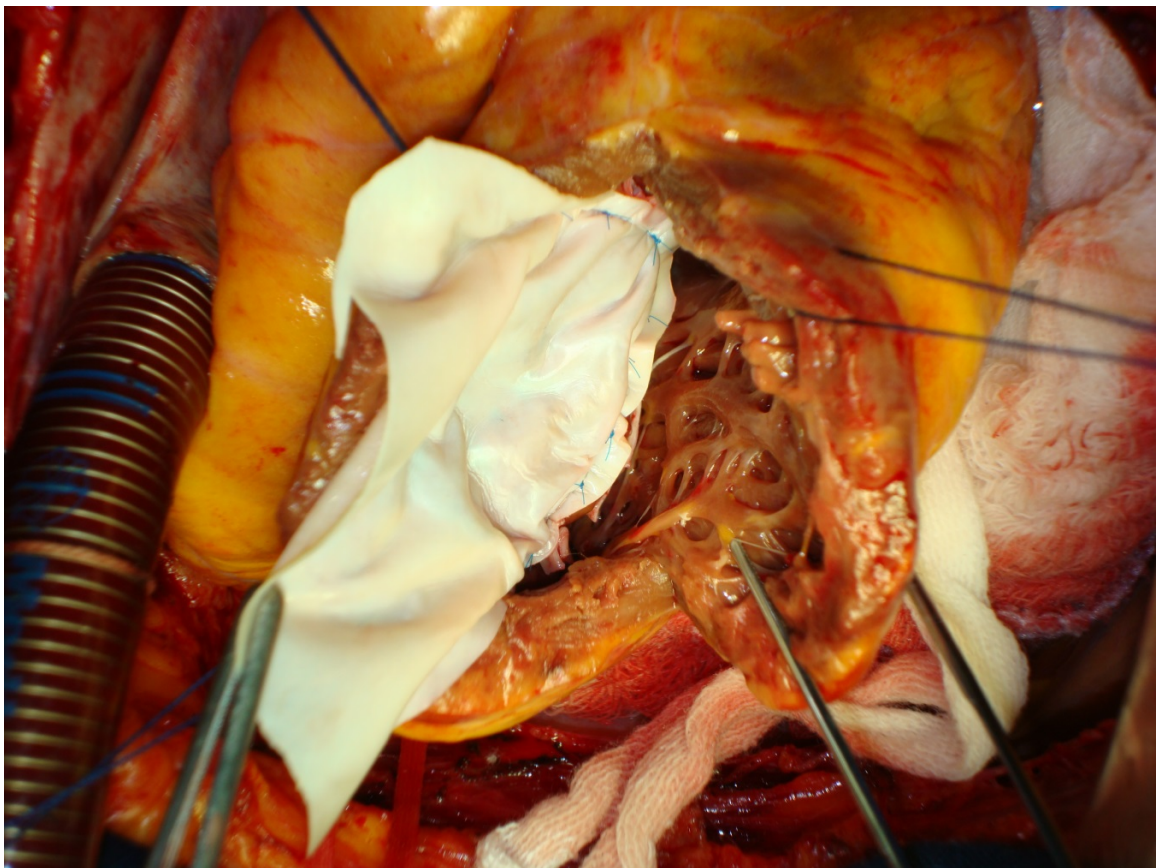


Figure 3. Ventricular septal rupture repair with the use of bovine pericardium

4.3. Mitral valve regurgitation with or without papillary muscle rupture (MVR)

4.3.1. Incidence and Evolution

Mitral valve regurgitation (MVR) occurs mainly in patients with inferior AMI, leading to extreme instability when associated with papillary muscle rupture, even in patients with moderate coronary heart disease.

The most frequently affected papillary muscle is the postero-medial, since the posterior interventricular artery or the circumflex artery are the only responsables for it's irrigation. [1, 2, 14]

The MVR typically occurs in the first two weeks after AMI, with bimodal incidence, especially in the first 24 hours of AMI and after 3-5 days of its inception.

MVR associated with cardiogenic shock carries a poor prognosis. In the SHOCK study, approximately 10% of CABG patients had severe shock, and had a mortality rate of 55%. In the SAVE study, in which patients were treated with inhibitors of angiotensin-converting enzyme after AMI, even patients with mild mitral insufficiency had worse prognosis compared to those without valvular dysfunction. [3, 16]

When complete papillary muscle rupture happens, even with surgical intervention, the mortality rate is high [30-70%), and some factors such as extent of infarction, cardiogenic shock, patient's age and delayed operatory indication increase this index. [4]

4.3.2. Symptoms

Mitral regurgitation may have different degrees of importance, from mild and even asymptomatic, which are usually incidental findings of tests such as echocardiography and catheterization, to severe, with hemodynamic instability evident.

The clinical picture may be manifested by abrupt establishment of dyspnea and pulmonary edema associated with hypotension. The physical examination may show systolic murmur in the mitral regurgitation, and signs of right ventricular hypertrophy, severe pulmonary edema and cardiogenic shock. [3]

4.3.3. Diagnosis

The electrocardiogram is not characteristic. The echocardiogram may show left ventricular dyskinesia, papillary muscle or injury of the chordae tendineae and severe mitral valve regurgitation by Doppler color. Moreover, it can quantify the degree of valvular insufficiency. [2, 3]

Swan-Ganz parameters shows the presence of "V" wave and significant pulmonary capillary wedge pressure, but not an increase variation on oxygen saturation at the right ventricle, confirming the mitral regurgitation and excluding the presence of ventricular septal defect.

Coronary angiography and ventriculography shows clearly the mitral regurgitation.

4.3.4. *Surgical treatment*

Treatment will be established according to patient's hemodynamic stability. Treated clinically, only 25% of patients survive the first 24 hours after rupture of the papillary muscle. The median survival without surgical treatment is three days, and several authors consider the complete rupture of the papillary muscle of the body as incompatible with life. [1] On the other hand, discrete mitral regurgitation is generally treated with oral medications at first.

Invasive monitoring and the use of inotropic and vasodilators should be considered in severe cases, in order to reduce left ventricle's afterload and to reduce mitral regurgitation.

Intra-aortic balloon is required in the most unstable patients. The high mortality rate is related to significant hemodynamic compromise with cardiogenic shock preoperatively. [2, 3]

It is observed lower mortality in mitral valve repair (13%) compared to its replacement (47.4%). [1, 14]

In cases of valve replacement, mortality is related to resection of the papillary muscle, with reported benefits of its preservation. The intraoperative transesophageal echocardiography has improved the surgical results by avoiding residual defects. [2]

Another often surgical procedure mitral valve annuloplasty, and it should be performed concomitantly with CABG when possible. In such cases, the distal anastomosis of the grafts to the coronary arteries should be performed before valve replacement. [1, 14]

4.4. **Left ventricular aneurysm (LVA)**

4.4.1. *Incidence and evolution*

Left ventricular aneurysm is a serious complication of AMI, and its incidence ranges from 5 to 38%. The LVA usually occurs in the left anterior ventricle wall, associated with complete occlusion of the left anterior descending artery, and it is four times more frequent than in inferior wall infarction. [2]

AMI patients undergoing fibrinolytic therapy with early recanalization have a significant reduction in the incidence of ventricular aneurysm (7.2%) compared to those not receiving fibrinolytics (18.8%). [3]

Several factors are involved in the formation of AV, as the extent of necrotic area, absence of collateral circulation and pathophysiology of ventricular remodeling. The AV is found in approximately 10-15% of survivors of AMI, with the rate six times higher in patients with AV than in those without aneurysm. [2]

These aneurysms are more prevalent among males, in the proportion of 2.2 to 1. Its incidence ranges from 45 to 74 years old, corresponding to the highest incidence of AMI.

The mortality is approximately 49% corresponding to 65-80% in those formed in the earlier stages and 23% formed in the later stages of the myocardial infarction.

4.4.2. Symptoms

The symptoms may be manifested as angina pectoris, left ventricular failure, pulmonary thromboembolism, and ventricular arrhythmias. [3]

4.4.3. Diagnosis

The electrocardiogram may show persistence ST segment elevation. Echocardiography can visualize the aneurysm and also, evaluate the presence of intracavitary thrombus. Coronary angiography and hemodynamic studies are indicated for the diagnosis and may guide the surgical procedure. [2]

4.4.4. Surgical treatment

Surgical treatment should be performed only after the healing phase of AMI, which lasts about six weeks, because of the friable tissues surrounding the infarcted area, raising surgical risks. However, it must be urgently done in cases of cardiogenic shock refractory to medical therapy, or in the presence of ventricular arrhythmias, refractory to conventional treatment. [2, 3]

From the hemodynamic point of view, the goals

The main objectives to be achieved with the surgical treatment are to increased ejection fraction, reduce the final diastolic volume and carry out an appropriate coronary graft bypass. [1]

The current mortality rates in the surgical treatment ranges from 3.3 to 7.2%, but in patients with severe ventricular dysfunction it may reach 19%. Patients with successful surgical treatment have a significant improvement in their functional class and have a 5-year survival of 60%. [2, 3]

The sequence for the treatment of ventricular aneurysm is based on: [1, 18]

1. Definition of the aneurysm;
2. Careful intracavitary thrombus removal;
3. Recognition of the area to be resected;
4. Elimination of the septum's paradoxical pulse area;
5. Reconstruction of the ventricle, with or without prosthetic tissue as a patch.

The techniques for surgical correction of this complication include: [1, 2, 7]

- Resection of the aneurysmal area of the left ventricle, with linear suture of the edges;
- Replacement of the ventricular wall by prosthetic material (Dacron);
- Reconstruction of left ventricular geometry, using Dacron or bovine pericardium ;
- Endoaneurysmorrhaphy use of synthetic material sutured inside the ventricular cavity;

- Endoaneurysmorrhaphy using semi-rigid prosthesis of bovine pericardium;
- Ablation of ventricular arrhythmia foci, usually in fibrous areas of the myocardium, identified by intraoperative electrophysiological mapping.

5. Mechanical complications of acute myocardial infarction – Results

The main surgical considerations: [7]

- preoperative coronary angiography to investigate lesions in other coronary arteries also need intervention when possible;
- early intervention to reduce infarct size and rapidly reperfuse the ischemic myocardium;
- femoral cannulation to prevent exsanguination in cases of rupture of the ventricular free wall;
- use of mechanical circulatory support devices such as intra-aortic balloon (IAB) to increase coronary perfusion pressure and reduce afterload;
- approaching the area without viability of the left ventricle, with repair of the interventricular septum followed by infarctectomy;
- myocardial revascularization procedure in the same act, whenever possible, to improve long-term prognosis.

The main determinants of increased mortality are: preoperative hemodynamic instability, the presence of multiple organ failure, and the need for concomitant CABG surgery along with the correction of the defect.

Mortality in clinical and surgical treatment of mechanical complications of acute myocardial infarction can be seen in table 5:

	Ventricularfreewall rupture	Ventricular Septum Rupture	IschemicPapillaryMusc le Rupture	Left Ventricular Aneurysm
Clinical treatment	About 100%	About 94%	About 71%	about 49%, 80% within the first 5 days post AMI
Surgical treatment	About 60%	20 - 60%; 87% in cardiogenic shock	4-13% (mild); 30-70% (severe); medium 20% (30-40% within 5 years)	3,3 - 7,2%, rising to 19% in cardiogenic shock (40% within 5 years)

Table 5. Mortality rates of patients from mechanical complications of acute myocardial infarction [2, 3, 14, 15, 16]

6. Conclusion

Patients with mechanical complications of acute myocardial infarction (ventricular free wall rupture, ventricular septal rupture and mitral regurgitation with hemodynamic, pulmonary congestion and / or cardiogenic shock) should undergo emergency surgery, according to the guidelines of the American Heart Association (Class I, level of evidence B). The coronary artery bypass surgery, whenever possible, should be performed during surgery.

Author details

Luís Augusto Palma Dallan, Luiz Roberto Palma Dallan, Luiz Augusto Ferreira Lisboa and Luís Alberto Oliveira Dallan

Heart Institute, University of São Paulo Medical School, Brazil

References

- [1] Dallan LAO, Lisboa LAF, Almeida SA. Complicações Mecânicas do Infarto Agudo do Miocárdio. In: Porto CC – Doenças do Coração: Prevenção e Terapêutica. Ed Guanabara-Koogan, 2 ed, Rio de Janeiro 2005; pp 691 – 709.
- [2] III Diretriz sobre o tratamento do infarto agudo do miocárdio – Sociedade Brasileira de Cardiologia. Arq Bras Cardiol 2004; 83
- [3] Antman EM, Ambe DT, Armstrong PW et al. – ACC / AHA guidelines for the management of patients with ST-Elevation myocardial infarction: a report of the American College of Cardiology / American Heart Association Task Force on practice guidelines 2004.
- [4] Jatene FB, Monteiro R, Hueb AC. Intervenções Cirúrgicas na Doença Arterial Coronária Aguda. In Nobre F, Serrano Jr CV (eds): Tratado de Cardiologia SOCESP. 1 ed. São Paulo, ed. Manole 2005, p. 719-727.
- [5] Nicolau JC e Marin-Neto JA (eds)– Síndromes isquêmicas miocárdicas instáveis. São Paulo, ed. Atheneu, 2001,
- [6] Abreu Filho CAC, Dallan LAO, Lisboa LAF et al. Tratamento cirúrgico da rotura da parede livre do ventrículo esquerdo após infarto agudo do miocárdio. Rev Bras Cir Cardiovasc 2002; 17:6-13.
- [7] Massad MG, Geha, AS. Surgical repair of mechanical complications of myocardial infarction. World J Surg 2004; 28:847-856

- [8] Buda AJ. The role of echocardiography in the evaluation of mechanical complications of acute myocardial infarction. *Circulation* 1991; 84:109-121.
- [9] Reddy SG, Roberts WC. Frequency of rupture of the left ventricular free wall or ventricular septum among necropsy cases of fatal acute myocardial infarction since introduction of coronary care unit. *Am J Cardiol* 1989; 63:906-11
- [10] Lima RC, Kubrusly LF; Nery AC et al. Diretrizes da cirurgia de revascularização miocárdica. Sociedade Brasileira de Cardiologia. *Arq Bras Cardiol* 2004; 82:1-20.
- [11] Braunwald E. Heart disease a textbook of cardiovascular medicine. 5th ed, Philadelphia, WB Saunders, 1997.
- [12] Dallan LAO, Oliveira SA, Abreu Fo CA et al. Infarto hemorrágico conseqüente à reperfusão miocárdica. Relato de quatro casos. *Arq Bras Cardiol*, 1990; 54:127-132.
- [13] Dallan LAO, Oliveira SA, Abreu Fo CA et al. Rotura cardíaca após infarto agudo do miocárdio: uma complicação passível de correção cirúrgica? *Rev Bras Cir Cardiovasc* 1993; 8[4]:272-281.
- [14] Dallan LAO, Oliveira SA, Atik F et al. Insuficiência valvar mitral isquêmica. Incidência, diagnóstico e tratamento cirúrgico. *Arq Bras Cardiol*, 1994; 62:329-336
- [15] The GUSTO investigators. An international randomized trial comparing four thrombolytic strategies for acute myocardial infarction. *N Engl J Med* 1993; 329:673-82
- [16] Sanborn TA, Bates ER, Jacobs AK et al. Impact of thrombolysis, intra-aortic balloon pump counter-pulsation, and their combination in cardiogenic shock complicating acute myocardial infarction: a report from the SHOCK trial registry. Should we emergently revascularize occluded coronaries for cardiogenic shock? *J Am Coll Cardiol* 2000; 36: 1123-9
- [17] Gutierrez PS, Higushi MI, Moraes CF et al. Diferenças entre homens e mulheres em casos fatais de infarto do miocárdio: estudo de duzentas necropsias. *Arq Bras Cardiol* 1990; 54:189-92.
- [18] Jatene AD. Ventricular Aneurismectomy. Resection or reconstruction. *Torac Cardiovasc Surg* 1985; 89[3]:321. ISIS-2 (Second International Study of Infarct Survival) Collaborative Group. Randomised trial of intravenous streptokinase, oral aspirin, both, or neither among 17,187 cases of suspected acute myocardial infarction: ISIS-2. *Lancet* 1988; ii: 349-360.