

# We are IntechOpen, the world's leading publisher of Open Access books Built by scientists, for scientists

4,800

Open access books available

122,000

International authors and editors

135M

Downloads

Our authors are among the

154

Countries delivered to

TOP 1%

most cited scientists

12.2%

Contributors from top 500 universities



WEB OF SCIENCE™

Selection of our books indexed in the Book Citation Index  
in Web of Science™ Core Collection (BKCI)

Interested in publishing with us?  
Contact [book.department@intechopen.com](mailto:book.department@intechopen.com)

Numbers displayed above are based on latest data collected.  
For more information visit [www.intechopen.com](http://www.intechopen.com)



---

## Groin Hernia Repair in Laparoscopic Era

---

Süleyman Çetinküner, Hasan Erdem,  
B. Çağlar Bilgin, Seyfi Emir, İlhan Bali and  
Selim Sözen

Additional information is available at the end of the chapter

<http://dx.doi.org/10.5772/57250>

---

### 1. Introduction

Inguinal hernias are a common pathology. The use of a non-absorbable mesh placed in the preperitoneal space for the treatment of inguinal hernias was first introduced by Rives in 1966 [1]. Stoppa introduced the use of a large mesh prosthesis via a posterior approach for the repair of bilateral hernias [2]. Open and endoscopic procedures have been described for hernia surgery since Bassini in 1887 [3]. Inguinal hernia treatment offers many possibilities, such as the laparoscopic approach, of which several techniques have been described. Ever since its initial definition in 1990, laparoscopic inguinal hernia repair has gained significant progress [4]. Laparoscopic inguinal hernia repair was first performed using the transabdominal approach, wherein the intra-peritoneal techniques, such as onlay or plug mesh application on the upper ligation of the peritoneum, were employed. Upon observation of early recurrence, the practice of placing the mesh between the peritoneum and the muscle directly led to the emergence of the TAPP and TEP techniques. Only these two laparoscopic repairs have proven to be viable, with early results comparable or superior to the Liechtenstein repair. In brief, the TAPP method involves entering the abdomen with trocars, opening the peritoneum in the hernia zone, covering the potential hernia zones with the mesh and then re-suturing the opened peritoneum. The primary superiority of the TAPP technique versus the TEP technique is that it has an early learning curve. The TEP technique does not involve entering the peritoneal cavity but rather restricts the work to only the Retzius' space. It enables the placement of a large preperitoneal mesh, with the several advantages including the repair of bilateral hernias, minimal dissection, elimination of performing a pneumoperitoneum and addressing its attendant complications, quick return to normal activity after repair, cosmesis and excellent long-term results. In comparison to open surgery methods, endoscopic hernia repair, using either TAPP or TEP procedures, involves less pain and minimal recurrent rates.

## 2. Anatomy

The early 1900s serves as an important period in the development of inguinal hernia surgery. During this period, cadaveric and clinical studies were able to better explain the anatomy of the inguinal canal. Many topics that had not been properly understood and therefore unable to be adequately investigated had begun to be illuminated with the anatomy atlases and new books by Astley Cooper [5], Franz Hasselbach [6], Antonia Scarpa, Jules Germain Cloquet [7] and Morton [8]. The significance of the rear wall of the inguinal canal in etiology and the repair of inguinal hernias was more clearly understood as a result of this new knowledge. It has been revealed that the defect in transverse muscle aponeurosis and transverse fascia plays an important role in the emergence of hernias. The objective in the rectification of this defect is to prevent tension in the transverse fascia [5,8,9].

## 3. Inguinal canal

In an adult, the inguinal canal is an approximately 4 cm - length oblique path at the bottom of the anterior abdominal wall. It is situated between the external (superficial) and internal (profound) inguinal rings at 2-4 cm above the top of the inguinal ligament [10], (Figure 1, 3). Hernia repairs performed using the anterior approach begin with an oblique incision of the external ring and continues to the anteromedial aspect of the cord at the level of the internal ring, proceeding then to the search for an indirect hernia sac at the level of the internal ring at the anteromedial aspect of the cord [13].

**External Ring:** The triangle-shaped aperture of the external oblique aponeurosis created by its base, whose superior and inferior legs are limited by the upper part of the pubic bone. While the superior leg is formed by external oblique aponeurosis itself, the inferior leg is formed by the inguinal ligament [7,14]. The superior leg is attached to the lateral border of rectus sheath and the tendon of rectus abdominis muscle sheath, and the inferior leg is attached to the pubic tubercle.

**Internal Ring:** A U-shaped normal aperture in the transverse fascia. The boundaries of this reverse U is formed by the front and rear transverse fascia. Its lower limit is formed by the iliobac tract of the specialized thickening of the transverse fascia [7,14], (Figure 1). Henri Fruchaud (1894 - 1960) was an anatomist surgeon who gathered all inguinal hernias under a single etiology and ushered in the concept of "Myopectineal Aperture" to hernia anatomy. Fruchaud categorized the hernias according to their clinical presentations and believed that they began from the place himself was responsible for defining as the myopectineal orifice. The boundaries of this space are constituted by the upper internal oblique muscle fibers, the transversus abdominis muscle, the outer iliopsoas muscle, the inner rectus muscle's lateral limit and the bottom pecten pubis. The inguinal ligament passes over this structure and ramifies into two. The spermatic cord and femoral veins pass through this area. It is internally covered by the transverse fascia only [9,10], (Figure-4).

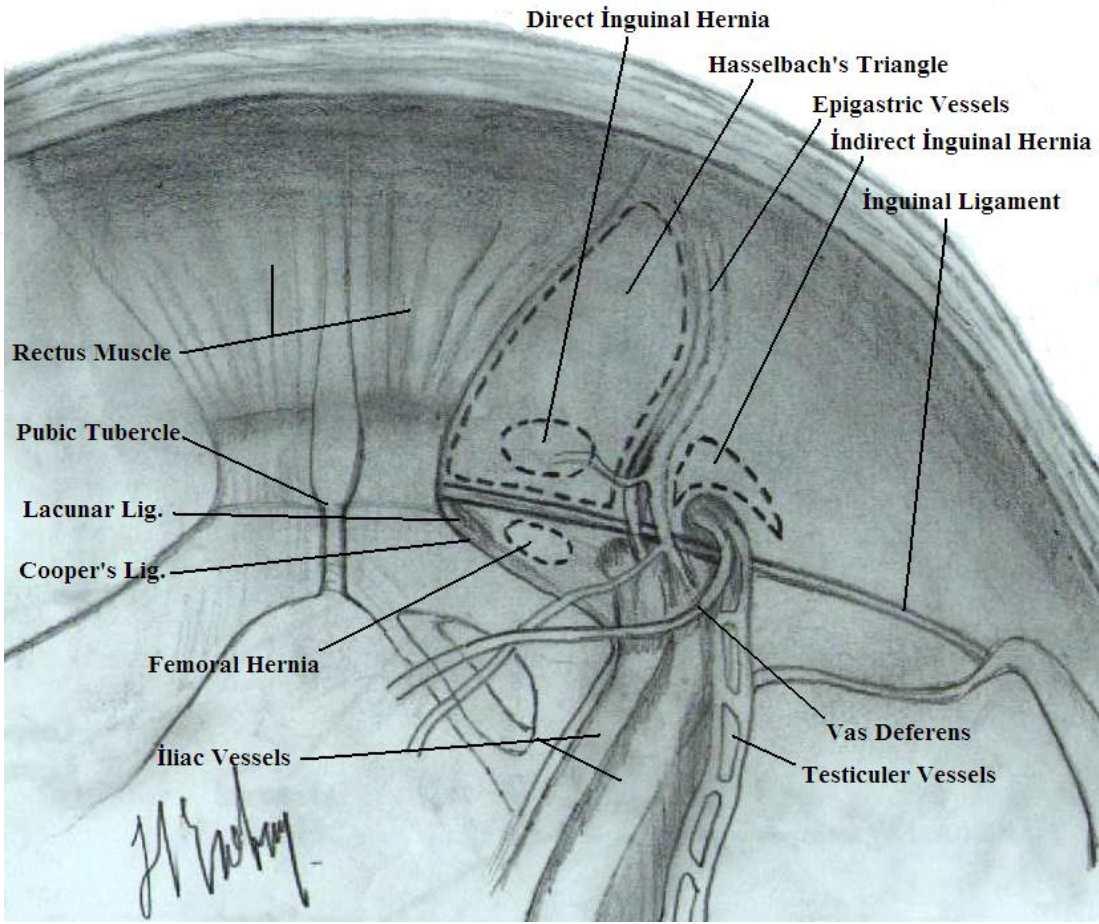


Figure 1. Posterior anatomy of inguinal region

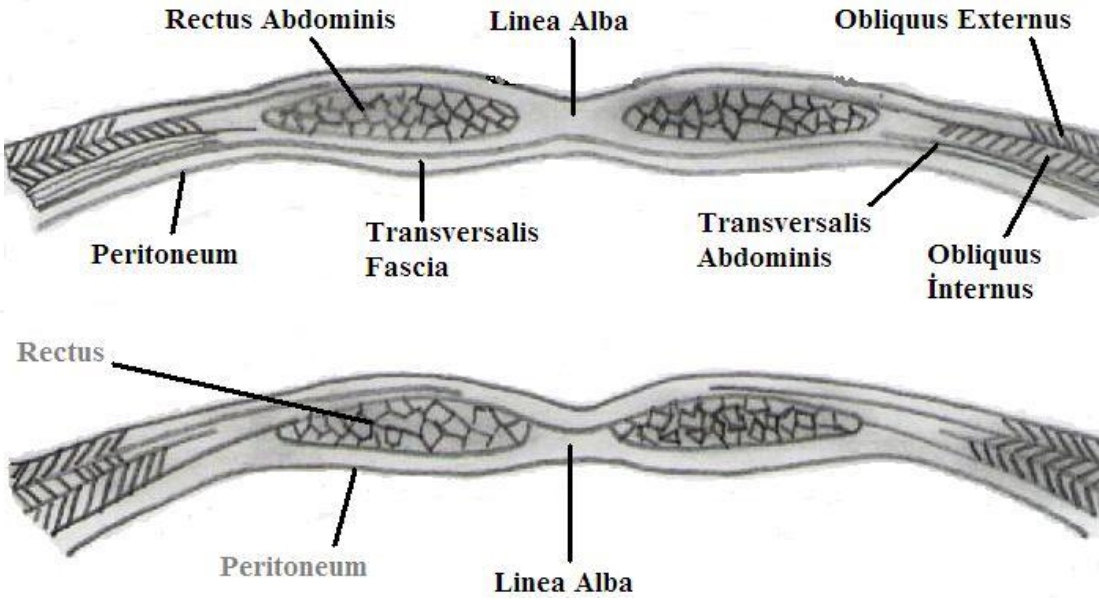
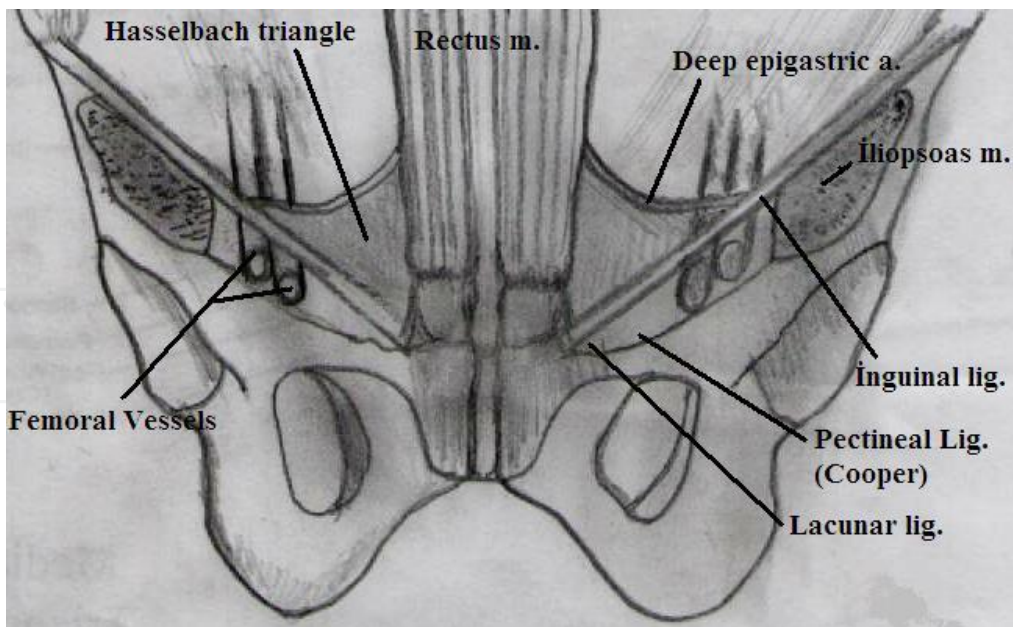
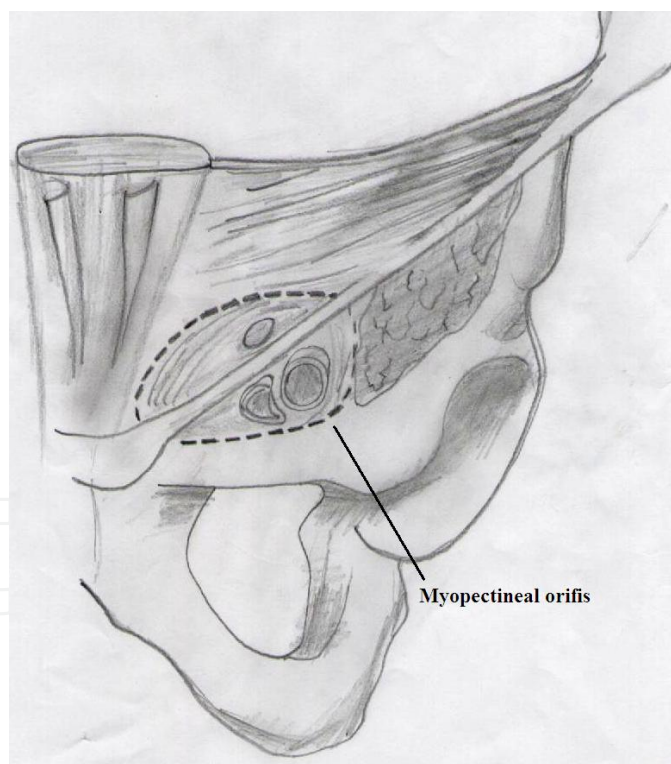


Figure 2. Anterior and lateral abdominal wall layers



**Figure 3.** Ligaments of inguinal region



**Figure 4.** Myopectineal Orifice of Fruchaud

**Hasselbach's Triangle:**

The lateral border of the superior or inferior Hasselbach triangle is formed by the inferior epigastric vessels, the medial border by the lateral rectus abdominis muscle and the inferolat-

eral border by the inguinal ligament. Most of the direct hernias and external supravesicle inguinal hernias emanate from here [10,15], (Figure 2).

### **Cooper Ligament (Ligamentum pectineale):**

This ligament starts from the pubic tubercle and continues along the linea pectinea. It disappears by becoming thinner adjacent to eminentia ilipectinea. It has a 30-degree angular difference with the Poupart ligament and is a strong structure [10,13,15], (Figure 1).

### **Anatomy of the posterior inguinal region:**

When viewed from the abdominal to suprapubic and inguinal area, three peritoneal folds and three shallow fossas extending downward from the omphaloe are seen.

### **Plica Umbilicalis Mediana:**

The part of the urachus that extends from the omphaloe to the bladder. It is located beneath the linea alba and is quite hard to discern (it can be more distinct in some people).

### **Plica Umbilicalis Medialis:**

Remnants of the umbilical artery extending from the omphaloe down to the iliac arteries. They are located in the medial position of the epigastric vessels. Because they serve no function in the human body, incisions made on them do not cause any harm.

### **Plica Umbilicalis Lateralis:**

It is created by the epigastric artery and vein and requires attention when performing dissection.

### **Lateral fossa:**

It is limited by the medial inferior epigastric artery. An internal inguinal ring (indirect inguinal hernia outlet) is present in it.

### **Medial fossa:**

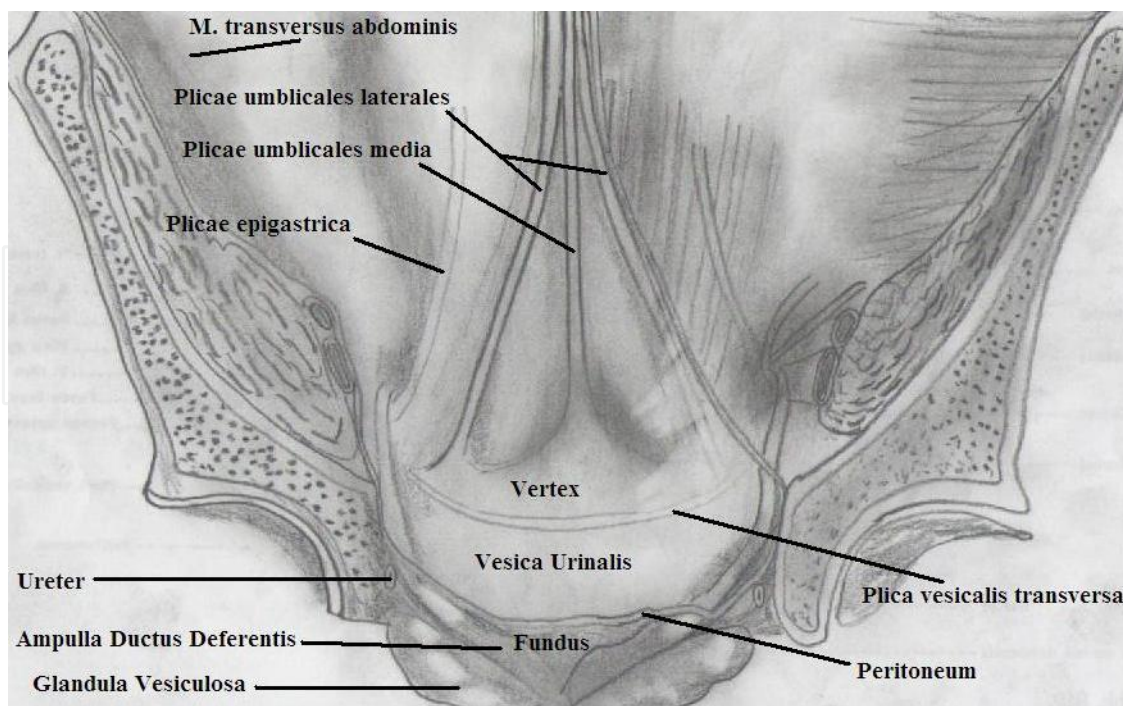
It is found between the inferior epigastric artery and the medial umbilical ligament (remnant of the umbilical artery). Direct inguinal hernias protrude out of it.

### **Supravesical fossa:**

It is situated between medial and the median umbilical ligaments (Median umbilical ligament: Umbilical artery remnants). Supravesicle external hernias protrude from here [10,12], (Figure 5).

### **Arteria Epigastrica inferior:**

It is a branch of A. Iliaca externa. Advancing through rear peritoneal and transverse fascia, it crosses iliopubic tract and reaches the level of medial edge of inner ring and extends inwardly and upwardly. At the level of linea semicircular, it makes an anastomosis with A. Epigastrica superior. It feeds the rectus muscle.



**Figure 5.** Preperitoneal view of lower abdomen

In the endoscopic repair of groin hernia, when the peritoneum is left at posterior and viewed from the anterior abdominal wall, 2 rectus abdominis muscles vertically extend from pubis at the centerline of anterior abdominal wall towards thoracic cage.

Anterior abdominal wall: It is composed of two sections (Figure 2):

Medial Section	Lateral Section
M.Rectus Abdominis	M.Obliquus Externus Abdominis
M.Piramidalis	M. Obliquus Internus Abdominis
	M.Transversus Abdominis
	M.Cremastericus

The medial section of anterior abdominal wall is formed by the rectus abdominis and pyramidal muscles. The rectus muscles on both sides are traversed by three tendinous lines. These traversing points occur at the level of xiphoid projection and omphaloe in such a way so as to stay in the middle of these two. These tendinous bands are tightly attached to the front fold of the rectus sheath (7).

Rectus muscle is firmly closed with the bilaminar aponeuroses formed by three superficial anterior and exterior muscles. It is formed by the exterior sheath, transversus abdominis, transverse posterior fold of internal oblique aponeurosis, of the transversus abdominis aponeurosis and transverse fascia until a distance from the rib border is reached so as to align with the center section of the omphaloe and pubic (linea semicircular). Exterior sheath beneath this point is developed solely by the transverse fascia [7,12]. Lateral abdominal wall consists

of three layers of muscle: External oblique, internal oblique and transversus abdominis muscles.

Each is wrapped with a separate fascia and terminates at the bottom as a flat tendon or aponeurosis returns. The outermost external oblique muscle that starts on the posterior part of the lower eight ribs and descends downward in a wrapping manner around the body. This muscle, which continues up to a line drawn from the anterior superior of the iliac spine to the umbilicus, turns into aponeurosis below this limit and envelops the ilioinguinal region beneath the innominate fascia. The lacunare ligament, inguinal ligament and the inguinal ligament reflexum are structures related to the aponeurosis. The inguinal ligament (Poupart) forms the outer edge of the oblique aponeurosis and extends from the anterior superior iliac spine towards the tubercle pubicum. From the termination point of the Poupart ligament, a band called the Lacunar ligament (Gimbernard ligament) extends towards the pubis. A triangle-shaped formation that is 1.25 cm in length. The fibers of the external oblique aponeurosis just above the inguinal ligament and at the lateral of its bonding location inside the pubic tubercle branches out to construct an aperture, which functions as the exterior (superficial) inguinal ring. The spermatic cord passes through the aperture in males and the round ligament in females [10,12].

The internal oblique muscle begins at the half-way point of the lateral ligament and adjacent iliac fascia and at the 2/3 point of the anterior iliac crest and lower parts of the adjacent lumbar aponeurosis.

The aponeurosis of this muscle extends towards the medial and makes up the anterior rectus sheath uniting with the aponeurosis of the transversus abdominis muscle beneath the semi-circular line. The bottom fibers of the muscle make up the cremasteric muscle adhering to the spermatic cord [12].

The transversus abdominis muscle is the deepest muscle layer in this region. The lateral part of the iliopubic tract of the inner part of the iliac crest starts from the inner surface of lumbo-dorsal fascia and lower six ribs' cartilage. It transversely passes through abdominal side wall towards medial. The muscle fibers then transform into tendinous aponeurosis at the rectus sheath uniting with the internal oblique aponeurosis. The transversus abdominis muscle creates a free edge by twisting over its free bottom part and internal inguinal ring. This is called the aponeurotic arch of the posterior transversus abdominis and generally combines with the internal oblique aponeurosis nearby the spot where it adheres to the pubic tubercle, and it forms the "Joint" (conjoint) tendon. It is seen in only 5% of the humans and is the basic structure utilized in the anatomic repair.

### **3.1. Bogros space**

Fatty and other connective tissues are situated on the left aperture between the peritoneum, also referred to as the Bogros space, and the posterior fold of the transverse fascia. Today, the Bogros space, which was defined by a French surgeon in 1823, does not receive full acceptance in terms of the anatomic structures it contains. However, what matters is that it has become the space where the synthetic prostheses are today placed in modern hernia surgery [11,12,18].



According to Bendavid, the Bogros space is the lateral extension of the retropubic zone of the Retzius' Space. The Bogros space can be exposed by making an incision from the transverse fascia of the inner ring down to the pubic bone. A venous plexus is present at the bottom and anterior sections of the Bogros space. Bendavid's venous circle is found at the subinguinal section of the Bogros space and is comprised of the following structures: Deep inferior epigastric vein, iliopubic vein, rectal veins the retropubic vein and the unifying rectus epigastric vein [18].

### 3.2. Inguinal nerve region

Iliohypogastric, ilioinguinal nerves and the genital branch of the genitofemoral nerve are of primary importance for the surgeon presiding over the operation. The iliohypogastric and ilioinguinal nerves unifying and advancing their routes in approximately 25% of the cases provide the sensory innervation of the skin of the inguinal zone, the base of the penis and the anterior side of the upper abdominal region. The position of these nerves protruding from T12-L1 is variable. Its existence above the spermatic cord, which is the typical localization of the ilioinguinal nerve, is encountered in only 60% of the cases. In addition, it might be found in or behind the the cremaster muscle.

As for the genital nerve, it contains both motor and sensory fibers. It innervates the cremaster muscle, lateral skin of scrotum and the labia, stemming up from L1-2. It is situated across the iliopubic tract inside the inguinal canal [10,16].

### 3.3. Spermatic cord structures

The spermatic cord (funiculus spermaticus) emerges from the preperitoneal space at the level of the anterior ring and comes out of the outer ring after passing through inguinal canal and upper lateral section of pubis and combines with the testicle in the scrotum.

In the spermatic nerve functioning as a branch of the genitofemoral nerve that accommodates the adipose tissue and lymphatics, spermatic artery, plexus pampiniformis and ductus deferens are present. The plexus pampiniformis ensures drainage of spermatic cord veins and forms the testicular vein at the level of the anterior ring. Similarly, a peritoneal fold is present inside the cord. Initially, this structure is in the form of a sac (processus vaginalis), but at a later point closes. The layers making up the cord from inside to outward order: 1 - Internal spermatic fascia: The continuation of transverse fascia encircling the cord up to testicle. 2 - The middle layer (Cremaster muscle): The continuation of internal oblique muscle. It provides roots up to the testicles. 3 - External spermatic fascia: The continuation of aponeurosis of the external oblique fascia (Fascia nominata of Gallaudet fascia) encircling the cord up to testicle [5,9,11].

## 4. Indications

The general indications for laparoscopic inguinal hernia repair, TAPP or TEP are the same as they are for open inguinal hernia repair. For young, active males with primary hernias, it may

offer decreased pain and an earlier return to activity. Laparoscopy may be ideal for bilateral groin hernias and recurrences from open approaches, but is also appropriate with unilateral primary hernias when the surgeon and patient are comfortable with the procedure.

Laparoscopic groin hernia classification is closely related to Nyhus [19], with all the anatomical aspects described according to this procedure

Type 1: Congenital hernias with a narrow internal ring

Type 2 : External oblique inguinal hernias with a dilated internal ring

Type 3:

- a. The posterior wall of the inguinal canal is damaged
- b. External oblique hernias with a dilated internal ring.
- c. Femoral hernias identified in the medial inguinal region below the inguinal ligament

Type 4: Recurrent hernias

The laparoscopic procedure can be considered for all adult patients, regardless of the type of hernia. The best indications according to this classification are;

- Type 3 hernias
- Bilateral hernias
- Type 4 hernias,

Obesity, strenuous activities (strenuous working and sports).

Relative indications:

- Type I or II hernias except when associated with another type of hernia or in cases of bilateral hernias; voluminous sliding hernias;
- strangulated hernias, diagnosed early.

## 5. Contraindications

There are very few contraindications for these procedures. Some of them are listed below;

- contraindication to general anesthesia;
- extensive intra-abdominal adhesions;
- extremely voluminous sliding hernias with the bowel attached to the hernia sac;
- late diagnosis of strangulated hernias with advanced bowel obstruction.

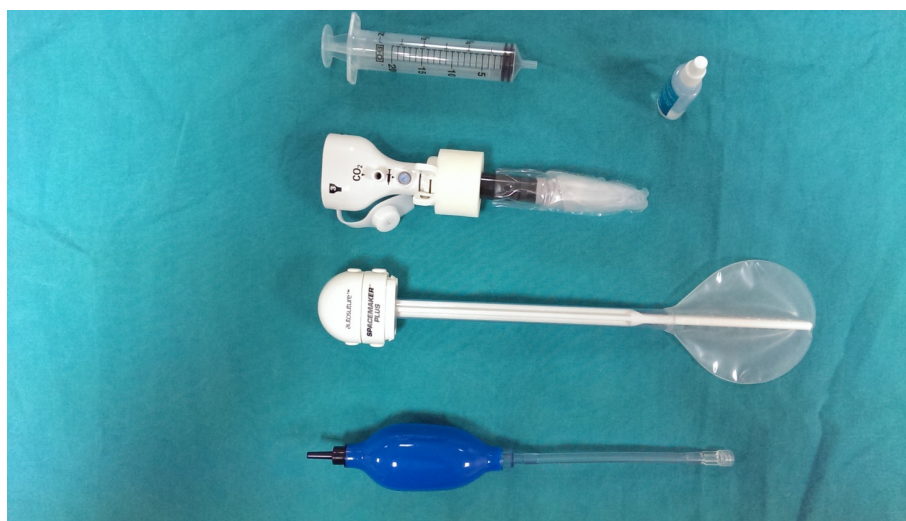Prior lower abdominal surgery or pelvic radiation are strong relative contraindications.

## 6. Surgical technique

### 6.1. Equipment used in laparoscopic repair

Insufflation needle (Veress: Palmer): In the intra-abdominal approaches, it is required for CO<sub>2</sub> insufflation into abdominal cavity. For the intra-abdominal pressure, 12mmHg is adequate. Since entry is made through the use of trocars; there is no need for any insufflation needles, such as Veress, in the total extraperitoneal method. Maintaining the cavity formed by this method at 8 - 10 mmHg with CO<sub>2</sub> pressure is adequate.

Trocars: Generally, three trocar entries are sufficient for laparoscopic repair. In almost all repair techniques, a 10-mm trocar is applied just below the umbilicus for the telescope input and the input for the balloon trocars. Specially designed balloon trocars are used for the TEP technique. By virtue of these trocars, entry into the Retzius' space from the umbilical zone and the creation of a potential cavity inside the preperitoneal area is greatly facilitated (Figure 6).



**Figure 6.** Balloon Trocars (from Çetinküner's archive)

Telescope: While a standard telescope can be employed, the use of a 30-degree angular telescope ensures large-scaled visibility.

#### Manipulation Equipment

1. Grasper and Dissector: Both grasper and dissectors can be used with 5mm trocars.
2. Electrocautery and Scissors: Use of electrocautery in the inguinal region where the great vessels are situated when applying the transabdominal preperitoneal procedure and total extraperitoneal method requires that great care be taken.
3. Aspiration - Irrigation Equipment: These can be used both for stopping hemorrhages which could potentially occur during dissection and for the purpose of cleaning the area as well. However, since frequent aspiration and irrigation might disturb the camera image, use of small buffers is also recommended.

4. Endoclip: For controlling the hemorrhages which might occur, the endoclip must be available among the tools to be used. Particularly, injury to the inferior epigastric veins passing right through the middle of the dissection area may require it to be ligated with the endoclip.
5. Endo-Stitch: An apparatus facilitating placement of suture in closure of peritoneal or hernia sac (TAPP procedure).
6. Endo peanut: Used for the blunt dissection.
7. Mesh stabilizer: Available in absorbable and non-absorbable, anchor and helical types and are effective in the fixed attachment of the prosthesis at appropriate locations. In some selected cases fibrin glue or sealant may be used.

## 6.2. Prostheses


Laparoscopic hernia repair techniques require the use of a prosthesis. The use of a prosthesis provides advantages such as low rates of recurrence and the prevention of tension. The polypropylene mesh produced for this purpose in non-absorbable and monofilament form is currently the most effective and commonly applied prosthesis material. In the repair of hernias, different raw materials and types of mesh can be used, such as anatomically shaped meshes (Figure 7). The properties to look for in meshes are as follows:

- Monofilament, pore size greater than 10  $\mu\text{m}$
- Easy transformability into the shape of the space it is placed
- Resistance to adhesion or erosion of organs
- Anti-allergic and protection against foreign body reaction
- Infection resistance
- Ability to withstand physiological stress for adequate time

Preparing the patient for surgery: Prior to the operation, it is required that patient be informed of the benefits of the laparoscopic repair of inguinal hernia, its potential risks and the availability of the open surgery option. The patient's consent should be obtained in writing. Since the use of mesh will be necessary for skin flora suppression, first-generation cephalosporins are administered parenteral. Patients are asked to urinate on the morning of surgery. For those patients who are unable to do so, a bladder catheter may be applied on the operating table. This is important for not to damage bladder during surgery.

### **Patient position:**

The patient is laid in supine position with arms fastened. Following general anesthesia, the operating table is brought to 20 degrees - Trendelenburg position and the patient is rotated by 25-30 degrees in adverse direction of the side where the hernia repair would be actualized (sided, tilted). Thus, blockage of view by the intraperitoneal organs may be prevented at the



**Figure 7.** Anatomical shaped mesh for TEP (from Çetinküner's archive)

repair area during operation. As for the laparoscopy unit is placed at the toe side on the same side where hernia operation would perform

#### **Surgery Team:**

The surgeon stands on the opposite side of the zone to be repaired. Nurse and the physician stand on the same side and the assistant stands on the opposite side.

#### *6.2.1. TAPP technique*

##### **Insertion of trocars**

After having made up pre-peritoneal with Veress needle, maintaining the intra-abdominal pressure at 12 mmHg is sufficient. A 10mm trocar is inserted - depending on the preference of the surgeon either being open or closed - into abdomen for the camera just beneath the umbilicus upon an incision made. Both pubic areas should be examined for any other possible intra-abdominal pathology after carrying out exploration with the laparoscope. The trocars to be used by the surgeon and the assistant should be inserted from approximately 5 mm distance from the outer edges of rectus abdominuses in a way to be on the transverse line of umbilicus. The diameter of the trocar to be used by the surgeon must be 12 mm. A 5 - mm diameter for the third trocar and to stay on the hernia side is adequate.

**Dissection of Hernia Area:** Before beginning the dissection, centerline (lig.umblicale medianum) and cord elements and residential area of the hernia which can be chosen just behind the peritoneum to lig.umblicale lateral formed by medial umbilical ligament, inferior epigastric artery and vein make up the boundaries required to be recognized. Excluding some of indirect hernias, the hernia sac can be easily reversed in form of a finger of gloves by being gripped from its tip.

The dissection is commenced with a peritoneal incision so as to be approximately 1 cm above the defect extending from umbilical medial ligament up to the anterior superior of iliac spine.

This dissection can be easily done a pair of scissors with cautery or Hook. Entering the preperitoneal region, the flaps are prepared by blunt dissection up and down. The hernia sac stays at the subperitoneal flap. Although this operation is easy with direct hernia, with the cases with indirect hernia exhibiting adhesion to the spermatic cord, partly sharp dissection is required. In blunt dissections carried out from the preperitoneal distance, the anatomic structures like inferior epigastric artery and vein, and the elements of the spermatic cord and iliopubic tract, Cooper's ligament, transverse aponeurotic arch and pubis should be uncovered. When the spermatic cord was dissected together with its elements from the peritoneal flap, first step of the operation is completed. Dissection in Retzius' space is performed primarily by using traction and counter-traction. Dissection is continued until Cooper's ligament and the pubic symphysis are identified and a large space is created. Retzius' space is the prevesical space between the symphysis, the bladder, and the anterior abdominal wall. It contains loose connective tissue and fat.

### **Placement of mesh**

This stage is the selection of a prosthesis which would cover all potential hernia spaces prepared and whose anatomic formations to be used in its repair. After being wound in roller, the prosthesis should be pushed into abdomen through 10 - 12 mm trocar. Rotation of the cord is not required in this technic at all. If the spermatic cord was not rotated, the mesh can be laid on the anatomic structures and fixed.

### **Mesh fixation**

Laparoscopic hernia repair involves the fixation of the prosthetic mesh in the preperitoneal space with staples to avoid displacement leading to recurrence. Fixation of mesh must be made to transverse aponeurotic above and outside, to pubic bone inside and to Cooper's ligament and the iliopubic tract at lower side. The point required to pay attention very much is not to use stapler on the lateral aspect of the external iliac artery and vein and the inferior edge of the lateral pubic tract. These areas are the potential navigation zones of femoral branch of n. genitofemoralis and n. cutaneus lateralis. The last point where the upper edge of prosthesis on lateral would be attached to is the medial of anterior superior of the iliac spine so as to be on top. Use of 6 or 7 staples of staplers is adequate in fixation. One each as per corner and one each to the right and left sides of inferior epigastric vessels above the transversal aponeurotic arc and one each at pubic bone and iliopubic tract at medial should be placed. Especially in femoral and direct hernias, additional fixation also to Cooper ligament is appropriate. Some authors suggest not to fix the mesh with a staple device because of a few complications such as osteitis, chronic groin pain, nerve injury and hematomas. For this reason mesh placement without any suture or stapler seems to be another option in endoscopic hernia repair. But disadvantage of these techniques is migration of the mesh. Just at this point the use of fibrin glue or sealant will be preferable for mesh fixation. Fibrin sealing has recently evolved as a new technique for mesh fixation in endoscopic inguinal hernia repair. Fibrin sealant is a biodegradable adhesive formed by the combination of human-derived fibrinogen and thrombin activated by calcium chloride, leading to the formation of polymerized fibrin chains. After applying the fibrin sealant, it is broken down by fibrinolysis and replaced by a fibrotic layer. The fibrinogen component gives the product its tensile strength and adhesive properties, and the thrombin component pro-

notes fibroblast proliferation [20]. The clinical use of cyanoacrylate synthetic glues as an alternative for mesh fixation in endoscopic hernia repair. [20]

Many studies in the current literature emphasize the advantages of fibrin sealant which can be safely applied in the endoscopic and open hernia surgery. [21,22] As the overall quality of reported studies remains poor, well-designed studies in the future are needed until fibrin sealing can replace mechanical stapling as a new standard for mesh fixation

### **Closure of periton flaps**

By closing the peritoneal flaps opened at the final stage, the contact of mesh with the intra-abdominal organs must be prevented. The upper and lower peritoneal flaps are superposed with the stapler.

### **Endoscopic total extraperitoneal inguinal hernia repair (TEP)**

TEP is different as the peritoneal cavity is not entered and mesh is used to seal the hernia from outside the thin membrane covering the organs in the abdomen. The trocar inlets present property in this method. Following application of local anesthesia to the probable entry locations, entry of first trocar is realized with a 10 - 12 mm transverse skin incision made from the lower edge of umbilicus. If this incision is made closer to the side where the hernia exists particularly with one-sided hernias, exposure becomes better. A 1 cm - incision is made on the anterior sheath of abdominis muscle and lateralizing the rectus muscle, posterior sheath is made visible. Inserting the finger between posterior sheath and the muscle, tunnel is prepared. There are two methods in creating extraperitoneal space. First one is made by advancing a 10 mm trocar placed into such tunnel and making CO<sub>2</sub> insufflation and trocar is pushed into Retzius' space through laparoscopic trocar being a blunt-tipped probe. Second one is the Balloon trocar which is frequently used by inserting the trocar through tunnel rim and guiding it towards symphysis pubis. In single-sided hernias, the trocar cannula should be held towards the hernia side and as for the bilateral ones, it should be held in the midline. If periton is punctured at this stage, the process should be restarted only after removal of cannula and closing the muscle anterior sheath by opening the anterior sheath of opposite rectus abdominis muscle. Arrival of cannula tip at the pubis is easily understood with an external palpation. At this stage, after changing the probe of balloon trocar with the telescope, balloon is started to be inflated. With the aid of 30 - 40 pumping action, it is inflated. Later on, in order to avoid complications and cause anatomy to be clearly exposed, landmarks are determined. The one of these landmarks firstly seen is the symphysis pubis. Until Cooper ligament is seen, balloon dissection is kept on. The balloon inflated should be maintained in place averagely for 3 minutes. This process will ensure the distance formed to be permanent and small hemorrhages to be buffered. Upon having making up the working area, balloon trocar is taken out and while it is possible to enter through same inlet with classic 10 mm trocars as well, structural balloon trocars specifically produced for commercial purpose as to be used in these operations can be used. Then, the extraperitoneal space is being inflated up to an 8 - 12 mmHg pressure. When inserting other two trocars into preperitoneal inguinal cavity, there are two different applications from the aspect of inlet points. Being most - adopted one, in the first application; 5mm trocar is inserted above pubis symphysis 2-3, other 5 cm trocar through center of umbilicus

and pubis line (on the same median line with both trocars). As for the second application preferred by some surgeons, 3 trocars is inserted from one point around the hernia, a little below the umbilicus horizontal line, outer edge of rectus muscle. In some patients, creation of the pneumoperitoneum may well reduce the working space and in exceptional cases lead to a conversion towards a trans-abdominal preperitoneal (TAPP) surgery

### **Dissection of hernia region**

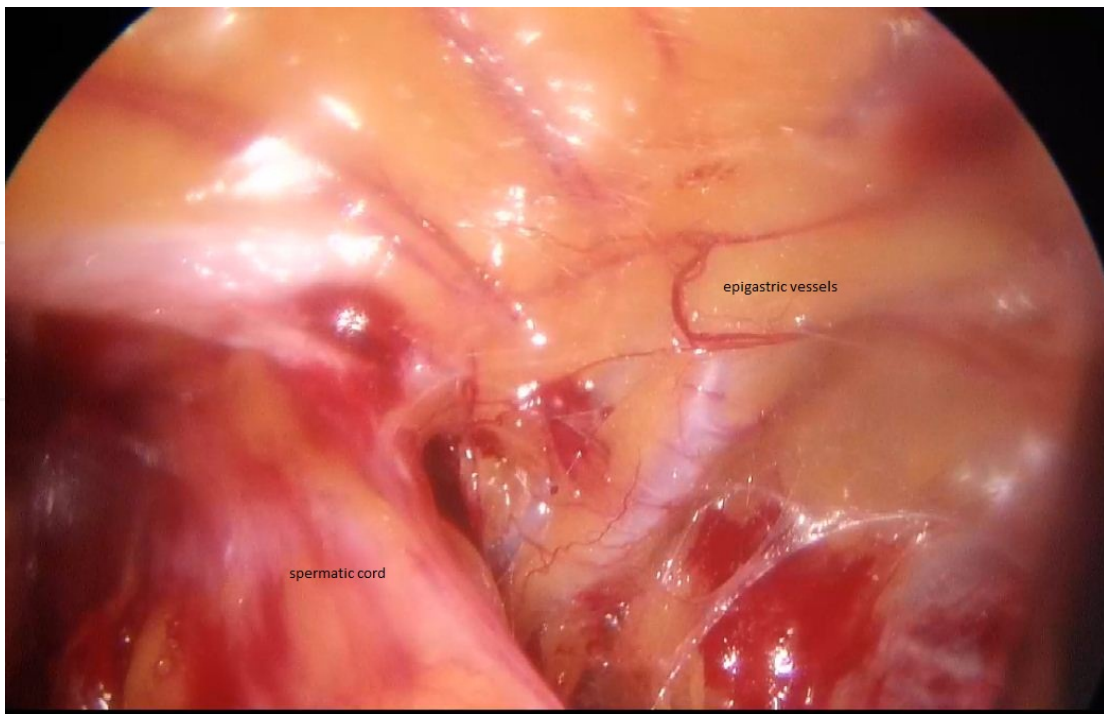
Dissection should be continued to medial and lateral starting from midline. An irrigation-aspiration device with a grasper and blunt tip scissors may be used for dissection. In the extraperitoneal method, anatomical structures necessary for the fixed attachment of mesh should be exposed (Figure 10), reducing the hernia sac consisting of peritoneum. The epigastric artery and vein are exposed as 2nd landmark (Figure 8). After separation with blunt dissection from the iliac vessels behind, the spermatic cord is freed from the tissue behind with the help of a dissector at the level of inguinal annulus profundus. In the case of an indirect hernia sac, it will be located in the anteromedial aspect of the spermatic cord. Testicular vessels progress in the posterolateral aspect, vas deferens (Figure 9) in the medial aspect of the hernia sac. The hernia sac captured with a grasper will be pulled forward and inward perpendicular to the axis of the cord, as testicular veins will be freed as much as possible by pulling them outward with blunt dissection (Figure 10). If the hernia sac is small, it may be left in the preperitoneal position or the distal part may be excised, connecting the endoclip with the help of an endoloop. In the case of large hernia sacs, the excess sac may be cut after being ligated with suture or endoloop. Another option is to cut the sac at the level of the inner ring and to leave the distal part in place after closing the proximal part. Particularly in indirect congenital hernias, this operation will inevitably be performed.

### **Placement of mesh**

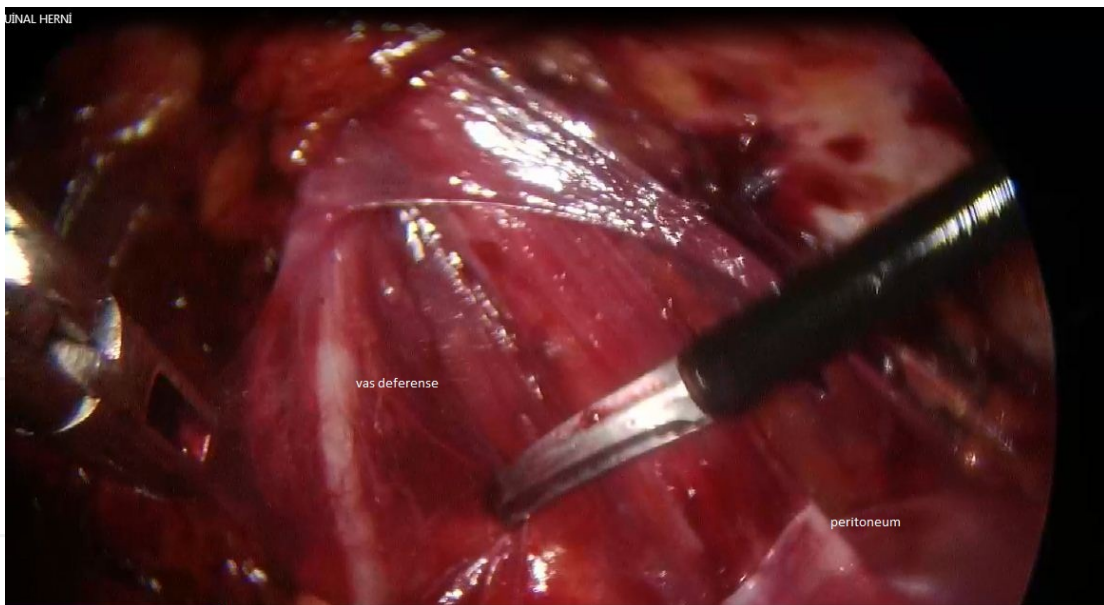The first fixed attachment to be done over the Cooper ligament facilitates the proper placement of the mesh. Occasionally, obturator vessels traversing the Cooper ligament by a curve can be found in only the medial aspect of the iliac vein. Mesh fixators should be used in this area referred to as the Corona Mortis. The space that accommodates the prosthesis should be enlarged towards the anterior superior iliac spine, and the psoas muscle, along with its various nerve rami, can be adequately visualized. These nerve rami must be preserved in order to avoid post-operative neuralgia. This area is called the triangle of pain, and it is absolutely impermissible to place any fixation device in this area as this would increase the risk of stapling a nerve ramus, an error that would lead to immediate and refractory post-operative pain and necessitate a second intervention to remove the staple responsible for the pain. The fibrin glue or sealant usage in this cases may prevent these complications with similar recurrence rates.

The procedure is terminated after the mesh is placed. Withdrawal of the gas should be done slowly under direct supervision. In order to avoid folding of the upper and lower edges that couldn't be fixed, they should be properly overlaid with the help of a grasper during the withdrawal of the gas. Fascia in the 12 mm and 10 mm trocar sites are closed with absorbable suture material.





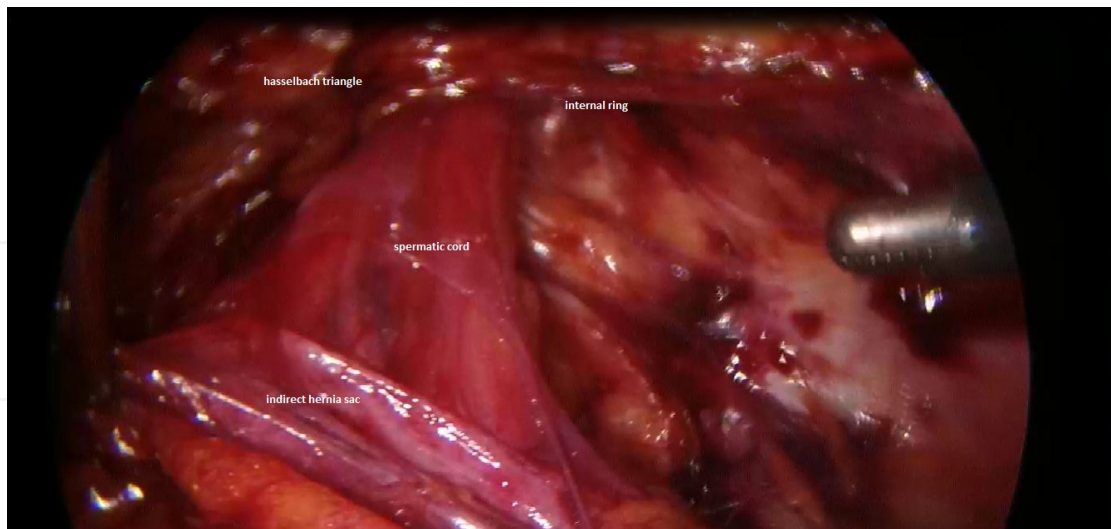**Figure 8.** Inferior epigastric vessels (from Çetinkünar's archive)



**Figure 9.** Vas deferens (from Çetinkünar's archive)

## 7. Post-operative care

On the day of surgery, the anesthetic effect wears off after 6-8 hours and then patients are mobilized and oral food intake is initiated. The patient may be discharged on the same day of surgery. In general, patients who no longer need to take analgesics after the 3rd day may go



**Figure 10.** Hernia sac (peritoneum)dissection (from Çetinkünar's archive)

on with their normal activities. Active employees and athletes may return to full activity after two weeks.

## 8. Complications

The overall incidence of morbidity after laparoscopic groin hernia repair has been quite variable. Unfortunately, it will never be possible to completely eliminate complications after laparoscopic hernioplasty, but it is possible to reduce their incidence. A thorough knowledge of the anatomy and the operative approach, along with advanced laparoscopic skills will reduce the possibility of significant complications. Serious complications specific to the laparoscopic technique, although reduced in parallel with training and experience, seen especially in the early stages of hernia surgery and mostly associated with TAPP, have been reported. Complication rates vary from 3% to 25%. [23,24]. Fortunately, serious complications are uncommon. A summary of possible complications is shown in Table 1. If we take a look at the most common complications;

1. Laparoscopy related complications:
  - a. Vascular injuries:

The most common vascular injuries are epigastric artery vein and spermatic vein injuries. In the literature, external iliac, obturator veins and deep circumflex iliac vessel injuries have been reported. Particularly during mesh fixation, Corona Mortis injuries may also be seen. Dorsal penile vein injury has been reported as well during balloon dissections. The incidence of hemorrhage after TEP surgery is 0.4%. [25]. The rate of major vessel injury must be repaired is 0,08 %.. [26]. These ratios are lower than expected as most of the cases are not reported. Despite low prevalence, hemorrhagic-related mortality rates vary between 8% and 17% [27]. Inexperience, oversight during trocar entry, incorrect cleavage during balloon dissection and

the lack of a full command of anatomy are the major causes of injury. Risk has also increased in patients who underwent abdominal surgery. All vascular structures in the groin, except the external iliac vessels, can be ligated, clipped safely or hemostasis can be achieved through the method of electrocautery sealing. External iliac vessel injuries require urgent repair and laparotomy should be started immediately.

**b. Bladder injury:**

Bladder injury is the most common complication of the urinary system. It especially occurs in the suprapubic area during trocar entry or dissection. In the event that it has been noticed during surgery, the surgeon may repair the injury laparoscopically according to his/her experience. Urinary catheters are used for 7-10 days. In the late period, patient may present with hematuria and lower abdominal pain. In these cases, the diagnosis is confirmed by a retrograde cystogram. Small defects can be treated without the need for repair through drainage of urine.

**c. Bowel injury:**

Bowel injuries can complicate the laparoscopic procedure. These are usually related to a dissection of the small intestine or colon attached to the hernia sac. The sigmoid colon on the left side and the small intestine on the right side are more frequently injured. The incidence rate is about 0.13% [28]. To prevent these injuries, the digestive tract structures should be reintroduced with the peritoneum without dissecting the adhesions between the sac and the organs. Although they can occur more frequently with the TAPP technique they have also been reported for the TEP technique [29]. Other bowel injury mechanisms include direct trocar or Veress needle perforations and secondary necrosis caused by electrocoagulation. The injury can be repaired with suturing or stapling during laparoscopy. Patients with delayed bowel injury may present with peritonitis signs or sepsis one week after surgery. The mortality rate is about 4% [28].

**d. Intestinal obstruction:**

It is a rare complication that can occur as a result of a fascial defect larger than 5 mm which are not closed especially in the TAP procedure. Fascial defects can be easily closed with a number of devices developed by commercial medical companies. When the peritoneal layer sutured over the mesh is not fully closed it causes the migration of the intestinal tract to the preperitoneal area and therefore obstruction is unavoidable. This complication that is much less frequent with TEP technique may develop due to an overlooked peritoneal defect.

**2. Hernioplasty related complications**

**a. Groin pain:**

Each patient's pain threshold level varies, subjective evaluation is in the forefront. If the evaluation of pain is required in terms of the success of an operation, we should be aware of the fact that chronic pain is more important than the pain in the early period. Nerve damage occurs between 2-4% and the femoral branch of genitofemoral nerve and lateral femoral cutaneous nerve are most frequently damaged [30,31]. In the literature, occurrence rate of groin

pain after inguinal hernia surgeries is around 11%. [32]. This problem appears as the most frequent morbidity of hernia surgery. However in the literature, in many studies groin pain is shown to be less in laparoscopic techniques. And even in a study comparing TEP procedure with Lichtenstein technique, TEP procedure is shown to be significantly superior statistically in each of the physical function, physical role, body pain, general health, and spiritual role categories [33]. Also fibrin sealant products for fixation mesh instead of the staples may decrease the groin pain.

#### **b. Recurrence**

In many studies including advanced laparoscopic centers recurrence rates were reported between 0% and 13%. It will be possible to achieve equal proportions of recurrence following impermeable open hernia repairs (tension free hernioplasty) and to obtain even lower recurrence rates with the increase of surgeons' experience and the development of laparoscopic skills. Sometimes it is not clinically evident whether swellings occurred after repair are really recurrent, a cord lipoma, a seroma or a swelling of the internal oblique muscle. In those cases extra imaging technique may be required. It is important to fully demonstrate the diagnosis of recurrence in order to avoid a second surgery in patients readmitted with inguinal pain. After the diagnosis of recurrence, most surgeons prefer open surgical method for recurrence. Nowadays, it is still controversial to consider a repeat endoscopic surgery in recurrences due to TEP or TAPP procedure.

#### **c. Infertility**

During hernia repairs, infertility problems may occur as a result of vas deferens or testicles injuries due to a traction or during dissection. Vas deferens defect may also occur during mesh fixation. Excessive traction or long retention of vas deferens reduce the quality of sperm by disrupting the movement of sperm. Excessive fibrosis that can occur around cord depending on the type of mesh used during the repair predispose to infertility. Incidence of ductus deferens injury is 0.3% in inguinal hernia repair. [34]. To avoid this complication during hernia sac dissection, grasping the ductus deferens and excessive traction should be avoided as much as possible. Care must be taken to the surrounding structures during the placement of the mesh.

#### **d. Orchitis**

Ischemia resulting from the deterioration of testicular blood flow may cause to orchitis and then testicular atrophy. Clinical presentation is enlarged painful testicle presenting with mild fever. scrotal hematoma, seroma, hydrocele, and testicular torsion are considered at the differential diagnosis. Doppler ultrasound scan is helpful in the differential diagnosis. The way to avoid this complication is to avoid full dissection of hernia sacs with very large scrotal component. In this type of patients, hernia sac is divided just in the distal aspect of the internal ring, proximal portion is ligated with the help of Endoloop while the distal is left open. Contrary to the opinion of most surgeons, leaving the distal hernia sac open in the scrotum does not lead to an excessive increase in the formation of non-communicating hydrocele. [35]

**e.** The other complications:

Complications such as wound infection, seroma formation, hydrocele, development of hematoma and testicular ptosis due to the freed cremasteric muscles can be seen after endoscopic hernia repair.

**f.** Mesh contraction:

Mesh contraction that is shown to be responsible for some recurrence cases appears in rates up to 20%. [36]

Related with	Related with Patient	Related with	Related with mesh
Laparoscopy		hernioplasty	
Vascular injury	Ileus	Recurrence	Folding
Bowel injury	Urinary retention	Port site problems	Pai
Bladder injury	DVT	Seroma	Contraction
Gas Embolism	Cardiopulmonary complications	Hematoma	Erosion
Bowel obstruction		Hydrocele	Infection
Shoulder pain		Orchitis	Rejection
Subcutaneous emphysema		Infertility	
Arrhythmias		Groin pain	
		Anesthesia, pareasthesia	
		Dysejaculation	

DVT, deep venos thrombosis

**Table 1.** Complications of TAPP/ TEP procedure

## 9. Comparison of TAPP and TEP techniques; which method is the best

When compared to TAPP procedure, advantages of TEP technique such as absence of abdominal approach, lack of risk of damage in intraperitoneal organs and vascular structures, very little risk of incisional hernia development in the port sites, absence of postoperative adhesion formation immediately come to mind. Most importantly, absence of operations such as re-suturing of the peritoneum opened during TAPP procedure may be considered as an advantage of TEP procedure. In this way, the surgery time is shortened. The main disadvantage of TEP repair is the anatomy of Retzius' space appearing complicated, a learning curve that lasts longer and relatively limited study area. Still, TEP is also contraindicated in patients with a history of prior lower abdominal surgery. However anatomy is more comprehensible and surgical area is larger in TAPP surgery. In endoscopic hernia repair, clear understanding of the anatomy of the posterior muscle is very important. TAPP technique provides greater understanding of the anatomy, as well as encourages the surgeon as initial cases. Despite all these advantages and disadvantages, in many studies comparing TEP and TAPP, obvious superiority of the two techniques to each other have not been demonstrated. [37,38]. What is

accepted throughout the surgical arena is that; the surgeon gets the best results in the technique that he/she develops him/herself best. We must not forget that all the surgeons involved in this domain have to know both techniques very well.

## 10. Conclusion

Although the literature on laparoscopic hernia repair is wide, except selected eligible patients, the benefit of laparoscopic procedures has not yet clearly understood, or generally accepted. However it is necessary to gain experience in laparoscopic techniques before hernia surgery. Studies showed that surgeons need to realize 30-100 operations in order to avoid recurrence and complications. [39] Laparoscopic or endoscopic groin hernia surgery is associated with short-term benefits, in terms of the postoperative pain and more rapid return to normal activities and has the advantage that it is minimal invasive compared to open mesh hernia repair but is usually performed under general anaesthesia. Unlike most surgical procedures, endoscopic groin hernioplasty has been tested in a large number of randomised controlled trials. These provide a reliable evidence base which demonstrates the feasibility and value of trials for assessing the effectiveness of laparoscopic/endoscopic procedures. For the patient to benefit from advantages of minimally invasive surgery, surgeon should either have a good knowledge on laparoscopic procedure or transfer the patient to centers of reference in this regard. Most precisely surgeon must apply the surgical procedure he/she knows the best.

## Author details

Süleyman Çetinküner<sup>1</sup>, Hasan Erdem<sup>1</sup>, B. Çağlar Bilgin<sup>2</sup>, Seyfi Emir<sup>3</sup>, İlhan Bali<sup>3</sup> and Selim Sözen<sup>3</sup>

1 Adana Numune Training and Research Hospital, Department of General Surgery, Adana, Turkey

2 Medical Faculty of Kafkas University, Department of General Surgery, Kars, Turkey

3 Medical Faculty of Namık Kemal University, Department of General Surgery, Tekirdağ, Turkey

## References

- [1] Rives J, Nicaise H. A propos des hernies de l'aîne et de leurs récives. *Semin Hop.* 1966;31:1932-1934

- [2] Stoppa R, Rives JL, Walamount C, Palot JP, Verhaege PJ, Delattre JF. The use of Dacron in the repair of hernias of the groin. *Surg Clin North Am.* 1984;64(2):269-285.
- [3] Bassini E. Nuovo metodo sulla cura radicale dell' ernia inguinale. *Arch Soc Ital Chir.* 1887;4:80
- [4] Ger R, Monroe K, Duviviver R et al: Management of indirect hernias by laparoscopic closure of the neck of the sac. *Am J Surg* 159;370,1990
- [5] Lichtenstein IL, Shulman AG, Amid PK et al. The tension free hernioplasty. *Am J Surg* 1989; 157:188-92
- [6] Glassow WF: A comparison of the Shouldice and cooper ligament repair for adult inguinal hernias. *The American Jurnal of Surgery* 1976; 131: 306-311.
- [7] Skandalakis. L.J. *Modern Hernia Repair.* 1. publ. London. Catagologing Publ. 1992.
- [8] Laparoscopic techniques versus open techniques for inguinal hernia repair. *Cochrane Database Syst Rev.* 2003;(1):CD001785.
- [9] Wantz GE: Abdominal wall hernias, in Schwartz. Ed: Seymour I. Schwartz: *Principles of Surgery* 7. ed Vol. 2, Bölüm 34, McGraw Hill Co, Singapore: 1999, s. 1585-1611.
- [10] Skandalakis PN, Skandalakis JE, Colborn GL, Kingsnorth AN, Weidman TA, Skandalakis LJ: Abdominal wall and hernias, in Skandalakis. Ed: John E Skandalakis: *Surgical Anatomy* 14. ed Vol 1, Bölüm 9, PMP Co, Athens: 2004, s. 395-491.
- [11] Mirilas P, Colborn GL, McClusky DA 3rd, Skandalakis LJ, Skandalakis PN, Skandalakis JE. The history of anatomy and surgery of the preperitoneal space. *Arch Surg.* 2005 Jan;140(1):90-4.
- [12] Devlin HB, Kingsnorth A: Essential anatomy of the abdominal wall, in Devlin. Ed: H Brendan Devlin: *Management of Abdominal Hernias* 2. ed Bölüm 2, Chapman and Hall Co, London: 1998, s. 15-37.
- [13] Milić DJ, Pejić MA. Tension-free procedures in the surgical treatment of groin hernias. *Srp Arh Celok Lek.* 2003 Jan-Feb;131(1-2):82-91.
- [14] Bekoev VD, Kril' VA, Troianov AA, Anisimova VN, Iashchuk IuI, Blakhov NIu. Recurrence of inguinal hernia (problems and ways of treatment. *Khirurgiia (Mosk).* 2003;(2):45-7;
- [15] Agarwal AK, Mukherjee R. Franz kaspar hasselbach (1759-1816). *Indian J Surg.* 2008 Apr;70(2):96-8.
- [16] Chevallier JM, Wind P, Lassau JP. Damage to the inguino-femoral nerves in the treatment of hernias. An anatomical hazard of traditional and laparoscopic techniques. *Ann Chir.* 1996;50(9):767-75.

- [17] Moreno-Egea A, Paredes PG, Perello JM. Vascular injury by tacks during totally extraperitoneal endoscopic inguinal hernioplasty. *Surg Laparosc Endosc Percutan Tech*. 2010 Jun;20(3):e129-31
- [18] Bendavid R. The space of Bogros and the deep inguinal venous circulation. *Surg Gynecol Obstet*. 1992 May;174(5):355-8
- [19] Nyhus LM, Condon RE, Harkins HN. Clinical experience with preperitoneal hernia repair for all types of hernia of the groin. *Am J Surg*. 1960;100:234-244
- [20] Effect of fibrin glues on the mechanical properties of healing wounds. Byrne DJ, Hardy J, Wood RA, McIntosh R, Cuschieri A. *Br J Surg*. 1991 Jul; 78(7):841-3
- [21] Comparing sutures and human fibrin glue for mesh fixation during open inguinal hernioplasty. Sözen S, Cetinküner S, Emir S, Yazar FM. *Ann Ital Chir*. 2012 Oct 2
- [22] Mesh fixation with fibrin sealant during endoscopic totally extraperitoneal inguinal hernia approach: a review of 640 repairs. Berney CR, Yeo AE. *Hernia*. 2013 Jan 24
- [23] Memon MA, Cooper NJ, Memon B, Memon MI, Abrams KR. Meta-analysis of randomized clinical trials comparing open and laparoscopic inguinal hernia repair. *Br J Surg*. 2003 Dec;90(12):1479-92
- [24] Bittner R, Schmedt CG, Schwarz J, Kraft K, Leibl BJ. Laparoscopic transperitoneal procedure for routine repair of groin hernia. *Br J Surg*. 2002 Aug;89(8):1062
- [25] Tamme C, Scheidbach H, Hampe C, Schneider C, Köckerling F. Totally extraperitoneal repair of recurrent inguinal hernia. *Surg Endosc*. 2003 Jul;17(7):1072-6. Epub 2003 May 6.
- [26] Schäfer M, Lauper M, Krähenbühl L. A nation's experience of bleeding complications during laparoscopy. *Am J Surg*. 2000 Jul;180(1):73-7.
- [27] Olsen DO. Laparoscopic cholecystectomy. *Am J Surg*. 1991 Mar;161(3):339-44.
- [28] Van der Voort M, Heijnsdijk EA, Gouma DJ. Bowel injury as a complication of laparoscopy. *Br J Surg*. 2004 Oct;91(10):1253-8.
- [29] Ramshaw BJ, Tucker JG, Conner T, Mason EM, Duncan TD, Lucas GW. A comparison of the approaches to laparoscopic herniorrhaphy. *Surg Endosc* 1996;10:29-32
- [30] Tam KW, Liang HH, Chai CY. Outcomes of staple fixation of mesh versus nonfixation in laparoscopic total extraperitoneal inguinal repair: a meta-analysis of randomized controlled trials. *World J Surg*. 2010 Dec;34(12):3065-74
- [31] Stark E, Oestreich K, Wendl K, Rumstadt B, Hagmüller E. Nerve irritation after laparoscopic hernia repair. *Surg Endosc*. 1999 Sep;13(9):878-81.
- [32] Poobalan AS, Bruce J, Smith WC, King PM, Krukowski ZH, Chambers WA. A review of chronic pain after inguinal herniorrhaphy. *Clin J Pain*. 2003 Jan-Feb;19(1):48-54



- [33] Myers E, Browne KM, Kavanagh DO, Hurley M. Laparoscopic (TEP) versus Lichtenstein inguinal hernia repair: a comparison of quality-of-life outcomes. *World J Surg.* 2010 Dec;34(12):3059-64
- [34] Sheynkin YR, Hendin BN, Schlegel PN, Goldstein M. Microsurgical repair of iatrogenic injury to the vas deferens. *J Urol.* 1998 Jan;159(1):139-41
- [35] Fong Y, Wantz GE. Prevention of ischemic orchitis during inguinal hernioplasty. *Surg Gynecol Obstet.* 1992 May;174(5):399-402.
- [36] Amid PK. How to avoid recurrence in Lichtenstein tension-free hernioplasty. *Am J Surg.* 2002 Sep;184(3):259-60
- [37] Laparoscopic surgery for inguinal hernia repair: Technology appraisal 83, London, UK, 2007, National Institute for Clinical Excellence
- [38] McCormack K, Wake BL, Fraser C, Vale L, Perez J, Grant A. Transabdominal pre-peritoneal (TAPP) versus totally extraperitoneal (TEP) laparoscopic techniques for inguinal hernia repair: a systematic review. *Hernia.* 2005 May;9(2):109-14. Epub 2005 Feb 10.
- [39] Wake BL, McCormack K, Fraser C, Vale L, Perez J, Grant A. Transabdominal pre-peritoneal (TAPP) vs totally extraperitoneal (TEP) laparoscopic techniques for inguinal hernia repair. *Cochrane Database Syst Rev.* 2005;25:CD004703