

We are IntechOpen, the world's leading publisher of Open Access books Built by scientists, for scientists

4,800

Open access books available

122,000

International authors and editors

135M

Downloads

Our authors are among the

154

Countries delivered to

TOP 1%

most cited scientists

12.2%

Contributors from top 500 universities



WEB OF SCIENCE™

Selection of our books indexed in the Book Citation Index
in Web of Science™ Core Collection (BKCI)

Interested in publishing with us?
Contact book.department@intechopen.com

Numbers displayed above are based on latest data collected.
For more information visit www.intechopen.com



The Non Invasive Brain Injury Evaluation, NIBIE – A New Image Technology for Studying the Mechanical Consequences of Traumatic Brain Injury

Hans von Holst and Svein Kleiven

Additional information is available at the end of the chapter

<http://dx.doi.org/10.5772/57344>

1. Introduction

Traumatic brain injury (TBI) is an epidemiologically well-known disorder that ranges from minor to severe conditions (Kleiven, Peloso, von Holst, 2003). The aetiology of TBI is due to external violence and similar all over the world. About 80% is defined as mild and in this category, most patients recover completely after a certain time, ranging from days to months. Another 10% is defined as moderate with a prolonged recovery period, depending on a number of causes such as type and localisation of injury. The final 10% covers severe injuries, where the recovery period usually remains for life. In contrast to most other diseases, TBI has a sudden onset with a substantial impact on the patient's close relatives, as complications are obviously not only of a physiologically handicapped nature but also psychological, due to the presence of personality changes. With an increase in worldwide social standard, TBI may unfortunately increase further. Thus, the World Health Organization has predicted TBI to surpass many diseases as one of the major causes of disability and death during the next decade unless external causes are reduced (World Health Organization, 2003).

As the external causes of TBI in most cases are known, the focus on primary prevention has already reduced the number of TBI successfully. One of the reasons for this reduction is due to the reconstruction of accidents by means of simulation. By using simulation methods and models, it is easier to discover innovations for prevention of the most severe accidents. The use of simulations will be of even greater importance in the future. Of equal importance is secondary prevention at the scene of the accident, in hospital care and the subsequent tertiary prevention during neurological rehabilitation. The overall mechanisms associated with TBI have been extensively investigated during the last decades by focusing on the biochemical and

biomechanical consequences (Narayan, R.K, Wilberger, J.E, Povlishock, J.T, 1995). The introduction of new and advanced image technologies such as computerized tomography (CT) and magnetic resonance tomography (MRI) have, together with the introduction of neurological intensive care units, further improved the knowledge and consequences of TBI (von Holst, 2007). Today the recommended treatment is based on clinical practice and personal experience, with an increased interest in evidenced-based medicine an even more comprehensive and generally accepted treatment of TBI resulting in an expected improved outcome. Utilisation of simulation models and methods in clinical practice will further improve future intensive care treatment after TBI. The same scenario holds true also for tertiary prevention in neurological rehabilitation, as simulation methods and models will be introduced. Thus, the combined increased activities of primary prevention, pre-hospital care, neurosurgical interventions and neurological rehabilitation have certainly improved outcomes following TBI.

In this chapter we present the concept of a new image technology defined as non-invasive brain injury evaluation technology focusing on reconstructive potentials of TBI and how this can be implemented into clinical practice aimed at improvement of outcomes.

2. Biomechanics in TBI

Clinically, brain injuries can be classified into two broad categories: focal injuries and diffuse injuries. The focal brain injury is a lesion causing local damage, which can be seen by the naked eye. The diffuse brain injury is associated with global disruption of brain tissue and is usually invisible. Focal injuries consist of epidural haematomas (EDH), subdural haematomas (SDH), intracerebral haematomas (ICH) and contusions (coup and contrecoup). Diffuse injuries consist of brain swelling, concussion and diffuse axonal injury (DAI) (Melvin, 1993).

The human brain is sensitive to rotational motion (Holbourn, 1943; Gennarelli et al., 1987). In pioneering work, Holbourn (1943) observed shear strain patterns in 2D gel models and claimed that translation is not injurious; on the other hand, rotation could explain the majority of traumatic brain injuries due to the nearly incompressible properties of brain tissue. The bulk modulus of brain tissue is roughly five to six orders of magnitude larger than the shear modulus (McElhaney et al., 1976), so that for a given impact, it tends to deform only in shear. This gives significant sensitivity of the strain in the brain to rotational loading and small sensitivity to linear kinematics (Kleiven, 2006). Therefore, rotational kinematics should be a better indicator of traumatic brain injury risk than linear acceleration. Additionally, it has been shown that the most common severe injuries, such as subdural haemorrhage and diffuse axonal injury are more easily caused by rotational head motion (Gennarelli et al., 1972, 1987). Gurdjian and Gurdjian (1975) suggested that a combination of skull deformation, pressures and inertial brain lag could present a clearer picture of head injury (Gennarelli et al., 1982) stated that all types of brain injury can be produced by angular acceleration. According to Ommaya (1985), rotation can produce both focal and diffuse brain injuries, while translation is limited to focal effects.

2.1. Focal injuries

2.1.1. Epidural haematoma (EDH) and subdural haematoma (SDH)

Epidural haematoma is a relatively infrequently occurring sequel to head trauma (0.2-6%, Cooper, 1982). It occurs as a result of trauma to the skull and the underlying meningeal vessels and is not due to brain injury (Melvin et al., 1993). The mortality rate of SDH in most studies is greater than 30%. Acute subdural haematoma, together with diffuse axonal injury account for more head injury deaths than all other lesions combined (Gennarelli, 1981). SDH is the most common of the severe traumatic brain injuries, accounting for around 50% of the total number of injuries in this category in Sweden (Kleiven et al., 2003). The most common mechanism of subdural haematoma is tearing of the veins that bridge the subdural space as they go from the brain surface to the various dural sinuses (Gennarelli and Thibault, 1982). Based on previous primate experiments, Gennarelli (1983) suggested that SDH was produced by short duration and high amplitude of angular accelerations. Lee and Haut (1989) studied the effects of strain rate on tensile failure properties of human bridging veins and determined the ultimate strain to be about $\epsilon_f=0.5$, which they found to be independent of the strain rate ($=0.1-250 \text{ s}^{-1}$). Earlier research done by Löwenhielm (1974) showed that the failure strain was markedly reduced from about 0.8 to 0.2 as the strain rate was increased. Lee et al. (1987) used a 2D sagittal model and Huang et al. (1999) used a 3D model (Shugar, 1977) to study the mechanisms of SDH. They found that the contribution of angular acceleration to tearing of bridging veins, measured as observed change in distance between a node in the interior of the skull and a node in the brain, was greater than the translational acceleration. Substantially larger relative motions between the skull and the brain, as well as higher strain in the bridging veins have been found when switching from a translational to a rotational mode of motion using a detailed 3D head model including 11 pairs of the largest bridging veins (Kleiven, 2003).

2.1.2. Contusion

Cerebral contusion is one of the most frequently found lesions following head injury. It consists of heterogeneous areas of necrosis, pulping, infarction, haemorrhage and oedema (Melvin et al., 1993). Contusions generally occur at the site of impact (coup contusions) and at remote sites from the impact defined as contrecoup contusions. Contrecoup lesions are more significant than coup lesions. Cerebral contusion at the site of impact in the presence of skull fracture is likely to be induced by the direct impression of the skull against the underlying brain tissue and therefore, in terms of skull fracture, caused by contact force and predicted by linear acceleration. In the absence of skull fracture, cerebral contusion is likely to be induced by shearing and scratching of the brain tissue against edges and sharper ridges in the dura/skull, and therefore caused by excessive head rotational loading (Löwenhielm, 1974). Moreover, Shreiber et al. (1997) derived a threshold of 0.19 in principal logarithmic strain in the cortex for a 50% risk of cerebral contusions. As previously mentioned, this strain is sensitive only to the rotational kinematics and not the translational motion (Ueno, Melvin, 1995; Kleiven, 2007).

2.1.3. Intracerebral haematomas (ICH)

Intracerebral haematomas are well defined homogeneous collections of blood within the cerebral parenchyma. They are most commonly caused by sudden acceleration/deceleration of the head. Other causes are penetrating wounds and blows to the head. Through reconstruction of a motocross accident, it was possible to re-create the injury pattern in the brain of the injured rider using the maximal principal strain (Kleiven, 2007b). The strain levels at maximum for two locations of intra-cerebral haematomas were around 0.4-0.5, which is close to known thresholds for rupture of cerebral veins and arteries (Monson, 2003; Löwenhielm, 1974; Lee, Haut, 1989), indicating that the risk of intra-cerebral haematomas can be predicted by the pattern and magnitude of maximum principal strain.

2.2. Diffuse Injuries

2.2.1. Concussion

The classical cerebral concussion involves immediate loss of consciousness following injury (Melvin et al., 1993). This is the most commonly occurring head injury, accounting for around 70% of total injuries, with more than 99% of patients leaving the hospital within 14 days (Kleiven et al., 2003). Studies on giant squid axons (Thibault, 1993) suggest a maximal principal strain of around 0.10 to cause reversible injury to the axons, which could be used as an approximate axonal strain threshold for concussion. During simulations of concussions in the National Football League (NFL), the strain magnitude in the brain was found to be sensitive to only rotational kinematics and not translational motion (Kleiven, 2007b).

2.2.2. Diffuse axonal injury (DAI)

Diffuse axonal injury is associated with mechanical disruption of many axons in the cerebral hemispheres and subcortical white matter (see Fig. 3). Microscopic examination of the brain discloses axonal tearing throughout the white matter of both cerebral hemispheres. It also involves degeneration of long white matter tracts extending into the brain stem. High-resolution CT scans may show small haemorrhages and axonal swelling (Fig. 3). DAI involves immediate loss of consciousness lasting for days to weeks. Severe memory and motor deficits are present and posttraumatic amnesia may last for weeks. At the end of one month, 55% of patients are likely to have died (Gennarelli, 1982).

The maximum strain that may cause damage to the axons has been estimated in previous publications. Studies have been performed with giant squid axons (Thibault et al., 1990) and a strain of 0.3 was suggested as threshold of diffuse axonal injury. Bain and Meaney (2000) proposed a threshold of 0.2 in maximal principal strain in the brain tissue for the onset of the malfunction of the neurons in the brain, which could be seen as a first stage of DAI. Maximum principal Green Lagrange strain of 0.2 has also been shown to correlate with cell death and neuronal dysfunction associated with DAI (Morrison et al., 2003). Gennarelli et al. (1972) subjected squirrel monkeys to controlled sagittal plane head motions. It was found that in the animals subjected to pure translation of the head, cerebral concussion was not obtainable. In

contrast, the animals who were subjected to head rotations were all concussed. Visible brain lesions were noted in both translated and rotated groups but with a greater frequency and severity after rotation. Ueno and Melvin (1995) found, when applying kinematics to a 2D head model, that rotational acceleration has a dominant effect on shear deformation, while linear acceleration is related to pressure.

3. The concept of NIBIE

NIBIE, Non-Invasive Brain Injury Evaluation, is a technology for measuring and evaluating parameters such as intracranial pressure, strain and stress from CT, MRI and Positron Emission Tomography (PET) scans (Fig. 1). The primary purpose of NIBIE is as a diagnostic tool for screening of patients with TBI and observation of intensive care patients with neurosurgical disorders such as haematoma, oedema or tumours. In addition, stroke patients may benefit from the method. NIBIE was created as a result of an interdisciplinary collaborative research project between engineers at the Royal Institute of Technology and neurosurgeons at the Karolinska University Hospital in Stockholm, Sweden.

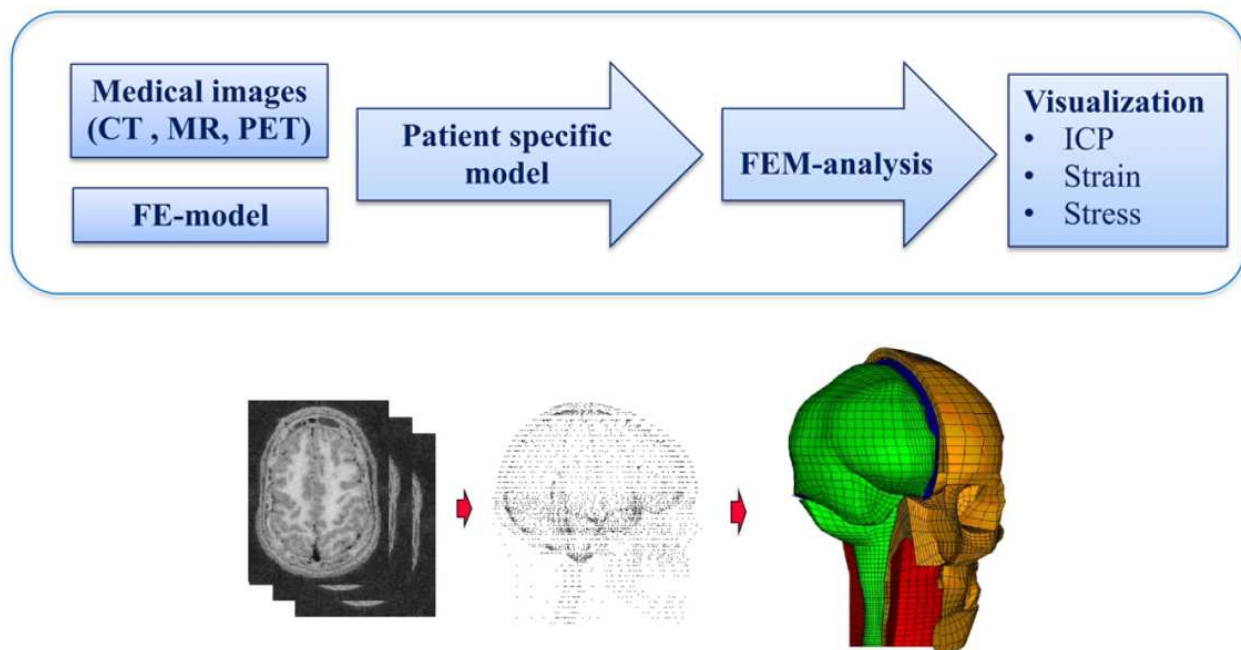


Figure 1. From medical image to FE modelling for visualization of ICP, strain and stress.

Research on numerical modelling of the head, which resulted in one of the most accurate finite-element models of the head available, made possible the use of the numerical model for medical applications in combination with existing medical diagnostic imaging data. The new image technology is well integrated with existing diagnostic tools and adjusted for each individual patient. NIBIE is unique in the sense that it can measure and define intracranial pressure without any neurosurgical procedure. It is the first non-invasive simulation method

that is able to define biomechanic parameters in brain tissue on healthy and diseased people. Additionally, NIBIE has the capacity to define the strain level in the brain in order to evaluate the impact on the fibre tracts and classify what local and regional areas need to be focused on following TBI and stroke. Moreover, in neurosurgical procedures, NIBIE has proven to be safe for calculating the optimal neurosurgical approach into the brain with regard to the skull bone opening. Calculation of the most optimal head position with regard to gravitation is another possibility for reducing the pressure and strain level in the injured area. Further possibilities include the calculation of strain levels in fibre tracts following hydrocephalus and brain tumours to potentially explain gait apraxia, incontinence and cognitive dysfunctions. Thus, it is clear that the NIBIE software program is superior for the identification of biomechanical influence on brain tissue when compared to that found in CT, MRI and PET images.

4. Technology of NIBIE

The introduction of CT, MRI, PET and other images for medical use has substantially improved clinical knowledge and practice. Further improvement is to be expected parallel with developments in computer capacity. The next generation of innovative images supporting clinical neuroscience is the introduction of simulation technology. Among those that should be mentioned is the finite element (FE) method, or modelling, which dates back more than a hundred years. However, the phrase 'finite element' was initiated about 60 years ago when Ray Clough (1980) introduced and published what today is defined as the finite element method. Since then, a number of further improvements have been developed by other researchers worldwide. The advantage of FE modelling is that the numerical method has the capacity to deal and analyse larger and more complex geometrical structures by dividing, or discretizing them into smaller and simple geometrical structures defined as elements (Fig. 2). The elements, which are of one, two or three dimensions, are connected to each other by nodes and the system is usually defined as a mesh. Dividing the human head and neck using the FE technique made it possible for the first time to further study the biomechanical consequences of TBI and stroke.

Depending on the size of the structure to be analysed, the number of elements differ from a few to several hundred thousand. In general, the number of elements and nodes in the mesh is dependent on the accuracy needed for analysing a problem. Depending on the purpose of the analysis, a number of mathematical equations are connected to each of the elements, thereby giving the mesh a relationship between different mechanical loadings of, for instance, forces and displacements in the mesh. Parallel with the introduction of CT, MR and PET images, the FE method was further developed for engineering purposes such as simulations, of which the transportation industry should be mentioned in particular. Of special interest was the introduction of colour graphics in combination with powerful computers, which gave the FE method better understanding and capacity for clinical implementation.

In the last twenty years, an increased interest in the FE method has been highlighted in the health care sector mainly due to its capacity for performing reconstructive biomechanical

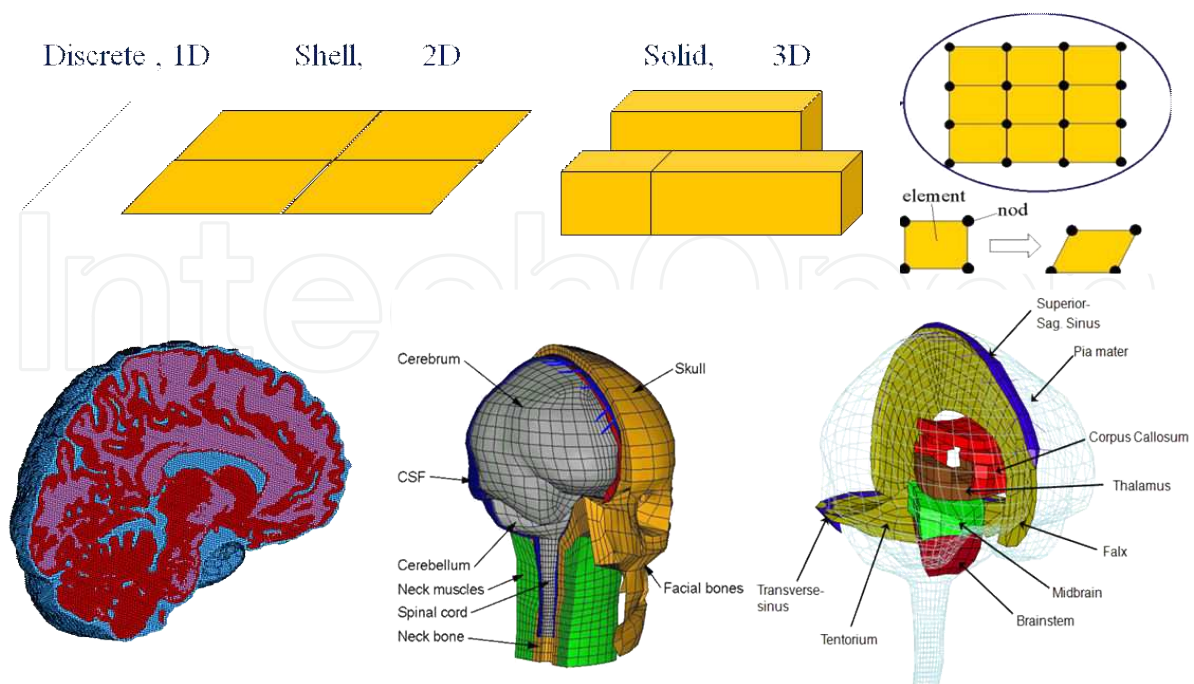


Figure 2. Schematic illustration of FE model development process from 1D, 2D and 3D elements to the construction of human head and neck models.

simulations of accidents (Kleiven, 2007). Although existing image technologies have substantially increased knowledge, there are still areas in need of new innovative image methods. This holds true especially in the field of clinical neuroscience. For instance, there is no image technology today that has the capacity to analyse a number of important biomechanical issues, which in turn will improve clinical assessment and clinical practice. Some of these problems include analysis of intracranial pressure in the brain tissue, the strain level in nerve fibres and stress in bone materials.

4.1. A computational 3D FE model

The development of advanced computational technology that started roughly three decades ago has increased interest in introducing human FE head models today (Ward and Thompson, 1975; Kumarezan, Radhakrishnan and Ganesan, 1995; Zhou, Khalif and King, 1995; Krabbel and Muller, 1996). With increased knowledge and interdisciplinary collaboration, more advanced 3D FE models have seen the light (Kleiven and von Holst, 2002; Johnson, 2008; Li, 2012). The technology has also become more accessible through easy-to-use interfaces, provided by most commercial FE-codes. The latest 3D versions include all anatomical structures of the human brain. As such, today a modern 3D FE head model includes the skin, all three bone layers, meninges, cerebrospinal fluid, brain tissue and aqueduct – including the foramina located in the skull base of the brain tissue. Depending on the purpose and need for analysis, the elements may consist of shell and solid tetrahedral or hexahedral configurations and can be used where they are most appropriate.

A prerequisite for using a modern FE method for TBI in clinical practice is access to a realistic and reliable 3D FE model of the human head. First, a FE model of the human head and brain includes the development of the outer and inner skull bone with the porous bone in between. Second, the model must further include the meninges including the dura, falx and tentorium and pia mater. Third, the construction of cerebrospinal fluid circulation requires the two lateral ventricles, the aqueduct connecting the third and fourth ventricles where it ends in the skull base and where the brain passes into the spinal cord. Fourth, the complete 3D FE model contains the grey and white matter of the brain tissue. Following complete development, it is necessary for the proposed 3D FE model to be validated via a significant amount of patient data before it can be accepted for use as a simulation tool in clinical practice. The 3D FE model can thus be extensively individualized and might tentatively have a substantial impact on clinical practice in the near future.

Increased knowledge from clinicians about the potential of using 3D FE modelling and what the FE method can add to existing knowledge will hasten the method to be implemented into clinical practice. For this purpose, an advanced and validated numerical model of the human brain was developed with the FE method; some of the results from such simulations are presented here, aiming at its introduction to neurosurgical practice of TBI and other neurological disorders. It can be tentatively suggested that the advanced FE model, including geometrically detailed descriptions, will predict injuries with good accuracy (Kumarezan, Radhakrishnan and Ganesan, 1995). It should be stressed that the FE method provides a means for studying how complex structures are affected by external loading and has long been used for applications in civil engineering and in the manufacturing industry. Thus, the method is well-suited for analysis of complex biological structures in the head and neck, as it will likely improve clinical practice in neurosurgery in the future.

5. Applied neuroscience

One of the most important neurological complications of moderate and severe traumatic brain injury (TBI) is the development of brain tissue oedema, which consists of an abnormal accumulation of fluid within the brain parenchyma. Oedema and its associated complications account for approximately 50% of deaths in patients with TBI (Marmarou, 2003). Raised intracranial pressure (ICP) is found in the majority of severe traumatic brain injuries caused by intracranial haematomas and brain swelling, and may be deleterious for the patient unless treated effectively (von Holst, 2007). Vasogenic and cytotoxic oedema are the two major types of oedema after TBI. Vasogenic oedema is due to blood-brain barrier disruption, resulting in increased extracellular water accumulation, while cytotoxic oedema is defined as increased intracellular water collection (Marmarou, 2003). As the aetiology of vasogenic oedema is relatively well understood, the treatment thereof is fairly effective. However, the mechanisms of cytotoxic brain oedema are still unclear, which renders a treatment of choice inadequate. Research has shown that the brain swelling observed in patients with TBI appears to be predominantly cellular, while vasogenic oedema is present at a minor degree (Marmarou,

Singoretti and Fatouros et al., 2006). This makes the clinical treatment of TBI oedema more complicated.

Although improvements in outcome have been made in recent decades, much remains to be done, especially since the recommended treatment is predominately based on clinical practice and personal experience. Clinically, local and minor oedema may be treated conservatively only by observation, while more extensive oedematous areas demand intensive care and where the treatment of choice usually follows evidence-based practice (Rabinstein, 2006; von Holst, 2007). Monitoring the ICP is an integral part of intensive care treatment following moderate and severe TBI. The longer the ICP exceeds 20–25 mm Hg, the poorer the outcome for the patient is expected (von Holst, 2007). On admittance to hospital, the patient with moderate and severe TBI is placed with the head at a 30-degree elevation aimed at optimizing the ICP, the cerebral perfusion pressure, the venous drainage from the head as well as the pulmonary function (Rabinstein, 2006; von Holst, 2007). Anatomically detailed FE models have been developed in an effort to simulate consequences of various impacts to the human head in the same group (Ho and Kleiven, 2009), which gives both researchers as well as clinicians a better understanding of TBI. Poroelasticity has been used to simulate hydrocephalus and brain oedema in early studies (Nagashima, Tamaki and Matsumotu et al., 1987). In more recent studies, simplified geometry, such as cylindrical or spherical geometry, has been adopted to investigate the mechanisms behind hydrocephalus (Kaczmarek, Subramaniam and Neff, 1997; Levine, 1999; Smille, Sobey and Molnar, 2005). Three dimensional (3D) FE models with anatomically detailed brain structures have also been used (Dutta-Roy, Wittek and Miller, 2008; Li, von Holst and Kleiven, 2009). Gravity has been shown to play an important role in brain shift during craniotomy in a series of studies using FE models (Coffey, Garg and Miga et al., 2010; Miga, Roberts and Kennedy et al., 2001). However, to date, there has been no experimental or clinical study evaluating the patient's head position with regard to oedema localization considering the gravity aspects, which could potentially alter both the clinical treatment as well as the outcome following TBI.

Formation of brain oedema involves fluid movement from the vasculature directly into the intracellular space (cytotoxic brain oedema) or extracellular space defined as the vasogenic oedema (Marmarou, 2003). The circulation of CSF tends to be disturbed for oedema patients with high ICP. However, the detailed mechanisms behind oedema and disturbed CSF circulation fall outside the range of this study. We used a fluid source added to the oedema to simulate extra fluid accumulation. In this model, we considered the influence of gravity on a patient with oedema at the posterior part of the brain for the supine and prone positions. The model was based on the normal CSF circulation model with the addition of a focal oedema at the posterior part of the brain. A higher localized interstitial fluid pressure (IFP) at the oedema zone due to extra oedema fluid accumulation is seen for both positions. The average IFP at the oedema zone decreased around 15%, from 3,331 Pa to 2,824 Pa when changing from the supine to prone position. For the supine position, the IFP decreased from the oedema zone the whole way to the frontal part of the brain. For the prone position, the IFP at tissue adjacent to the oedema showed a similar tendency to the supine position; however, IFP started to increase at a certain distance from the oedema zone due to hydrostatic pressure induced by gravity. The

tissue pressure gradient drove the interstitial fluid away from the oedematous zone to other parts of the brain. When IFP increased, the brain tissue swelled due to the pressure gradient acting on the tissue skeleton. Since brain cells and CSF were nearly incompressible (Kaczmarek, Subramaniam and Neff, 1997), the enlarged volume was expected to be filled with extra fluid. The predicted water content increment was about 10% at the centre of the oedema and decreased towards other areas of the brain. The value of water content increment was nearly identical for both positions. This was to be expected, since the swelling of oedematous tissue was caused by the IFP gradient acting on the solid skeleton rather than the IFP. Both IFP and water content increment distribution in the brain was similar to those reported in experiments on cold-injured oedema in cats (Reulen and Kreysch, 1973).

5.1. Epidural, subdural haemorrhages and intracranial pressure

On arrival at the hospital from the scene of an accident it is not always easy to clinically judge the patient's condition with regard to potential injuries in the brain tissue that might be in need of immediate handling by emergency staff. A better clinical evaluation can be done by performing a CT scan, which can be done within a short period of time. Among the most important injuries are the presence of epidural haematomas (EDH) and any signs of increased ICP. As shown in Fig. 3, the EDH is clearly visible. As this EDH will cause a substantial midline shift, the ultimate choice of treatment is an acute neurosurgical evacuation of the haemorrhage, which aims to reduce the expanding volume to avoid further secondary injuries. Additionally, as the ICP is probably increased in this patient, it is important to judge whether it should be monitored continuously or not. These two types of injuries are of great interest when it comes to the application of the NIBIE software image. The CT image is digitized over to NIBIE (Fig. 1) for the evaluation of secondary complications such as potential increased strain and ICP levels, two criteria which may have a dramatic effect on brain tissue with regard to secondary injuries.

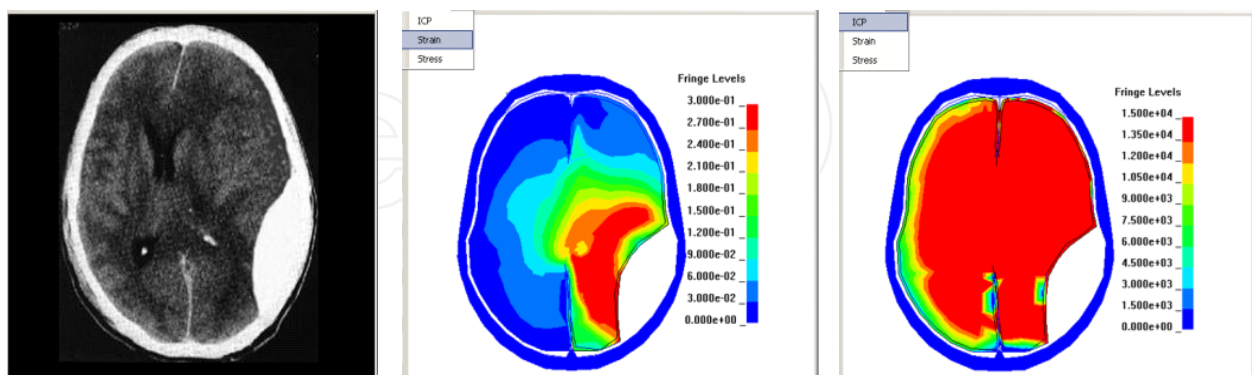


Figure 3. CT-verified epidural haematoma (left) analysed with NIBIE with regard to strain (middle) and ICP (right).

The increased strain level shown in Fig. 3 is highest in the nearest vicinity of the EDH and reduces with distance from the EDH. After the acute evacuation of the EDH, the strain level is simultaneously reduced, thereby preventing further secondary injuries. The strain level

shown in Fig. 3 offers significant support to clinicians in neurological intensive care and for rehabilitation staff. Comparing the CT scan with the degree of strain level, NIBIE may also have the capacity to define the anatomical area of most importance for treatment and observation. This is also beneficial to the rehabilitation staff in terms of what region to focus on when the time is ready for more active neurological rehabilitation.

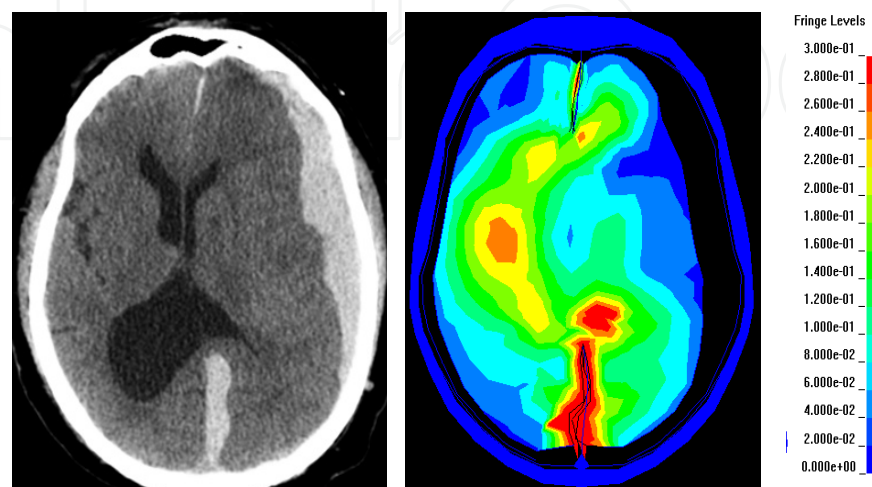


Figure 4. CT verified subdural haematoma (left) evaluated with NIBIE and strain level (right).

In contrast to the strain level, the FE model of NIBIE shows that the ICP is substantially increased throughout the brain. The evacuation of the EDH volume will not only reduce the increased strain level, but also the increased ICP. Usually, monitoring equipment is obligatory for a suspected increased ICP and is implanted right after the evacuation of the EDH during the same neurosurgical procedure. As NIBIE has proven reliable in defining normal or increased ICP levels, an implantation of monitoring equipment is not always necessary. In future, ICP can easily be defined by repeated CT and NIBIE evaluation during the neurological intensive care treatment period.

Not only patients suffering from EDH, but also those admitted with subdural haematomas may also benefit for the same reasons. While EDH is mostly acute and found in about two per cent of all types of injury, SDH is more frequent and divided into acute, sub-acute and chronic injury, depending on the age of the haematoma, which is not always easy to estimate. One possible and more precise age definition of the SDH could be the definition of strain level, which should be reduced when the haematoma has transferred from a clot to fluid (Fig. 4). In this case, NIBIE has the capacity to define the area of potential secondary injury and that may be found in nerve fibres showing an increased strain level.

With the introduction and use of NIBIE for clinical application, new injury criteria may be defined by focusing on strain and ICP levels. It is therefore quite possible that the new criteria will successively increase knowledge among health care staff. By using each slice from the CT and evaluating them in NIBIE, it is possible to gain a holistic view of the severity of the injury and hence better information on potential secondary injuries, and what clinicians should focus

on when it comes to direct and more long term treatment. Of interest are patients with asymptomatic chronic SDH. Here, evaluation with NIBIE may give insight to whether the brain tissue shows any evidence of strain, which will be clinically helpful for clinicians in terms of their decisions for clinical treatment in some of the more questionable patients. This new insight will further encourage better clinical evaluation and treatment, resulting in better clinical outcomes for patients with EDH, SDH and increased ICP. This scenario also holds true for other cerebral injuries after TBI.

5.2. Influence of gravity

In general, gravity is an important factor for consideration in TBI, since it may have a dramatic influence on the pressure around an intracerebral lesion or haemorrhage. In the neurosurgical procedure, gravity is of paramount importance to facilitating an operation. When it comes to clinical treatment, this aspect is, however, not always considered in the intensive care phase. Here, the non-invasive brain injury evaluation, NIBIE, has proven promising in evaluating optimization of the head position. When the head of the patient with a cerebral lesion is positioned in the usual supine position, as is normally the case, the pressure is usually higher compared to if the same patient is instead considered for a more prone position (Fig. 5). Using NIBIE, it has been shown that by switching from the supine to prone position, the pressure in the injured area is reduced by about 15%, depending on the size and localization of the injury. Switching from a supine to a more prone position may thus cause a substantial reduction in secondary injury, thereby promoting shorter in-hospital treatment and a better outcome.

It has been shown that reducing an increased ICP after severe TBI can significantly reduce mortality rate. This is supported in clinical treatment where the patient's head is elevated to about 30 degrees to facilitate cerebral blood flow (Rabinstein, 2006). The pressure gradient in the central nervous system is not always equally distributed inside the cranium following TBI (Miindermann, 1999). Instead, it has been found that pressure gradients also exist between the two hemispheres or even between neighbouring areas of the same hemisphere, especially in the oedema zone, where local tissue pressure increases as a result of a pathological accumulation of extra fluid (Reulen and Kreysch, 1973). Additionally, it can be tentatively suggested that even a slightly increased interstitial fluid pressure IFP might trigger a series of pathological processes to the already injured and vulnerable tissue inside and surrounding the oedema zone (Li, von Holst and Kleiven, 2011). Following the biomechanical cascades of events in moderate and severe TBI, both necrosis and apoptosis was seen to be present, although they differed in some aspects. Necrosis was found as a response to tissue damage due to biomechanical or ischemic influences.

In contrast, neurons undergoing apoptosis are morphologically intact during the immediate post-traumatic period, with adequate biochemistry providing the existence of normal membrane potential (Werner and Engelhard, 2007). When the hydrostatic pressure reaches 30 mmHg the neurochemical cascade of events is initiated, thereby having the potential to trigger both neurodegenerative diseases and apoptosis in the brain tissue (Ju, Liu, Kim and Crowston et al., 2007). From a biomechanical point of view, the consequence of an increased interstitial fluid pressure may result in larger deformation of the cellular membranes, thus altering the

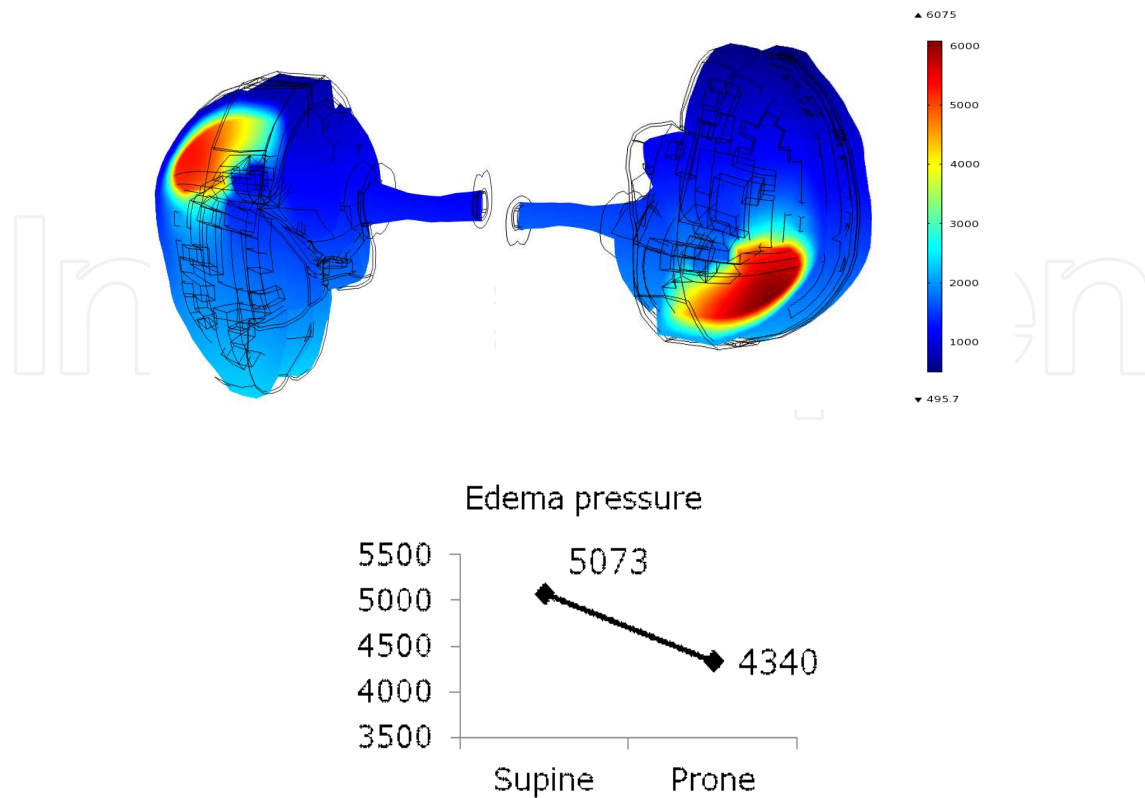


Figure 5. By changing the patient’s head position from supine to a more prone position the pressure in the oedematous tissue is reduced by about 15 %.

pressure between the extracellular and intracellular environment. An elevated interstitial fluid pressure due to oedema compresses the vasculature, the consequence of which is reduced cerebral blood flow, potential ischemia and arteriolar dilatation. This makes the capillary pressure increase, which results in even more interstitial fluid accumulation (Werner and Engelhard, 2007).

Gravity causes a hydrostatic pressure gradient in compartments filled with fluid. The same pressure is present in the centre of gravity in the head and is thus set to zero. As is found in neurosurgical procedures, a postural change of the head position alters the distribution of hydrostatic pressure patterns according to the body’s alignment to the gravity field (Hinghofer-Szalkay, 2011). However, at a certain location – referred to as hydrostatic indifferent point – the pressure remains constant during a given change of body position. When it comes to defining the most optimal head position in clinical practice between supine and prone positions, this remains to be evaluated when the indifferent point is presented. Thus, when positioning the TBI patient in the supine position as a routine, the treatment of choice is suboptimal, as it does not consider the anatomical localization of the injury. The potential verification of changing from supine to a more prone position has been shown by using an anatomically detailed 3D FE model in simulation research (Li, von Holst and Kleiven, 2011), where the effects of gravity on the oedema zone at the posterior part of the brain were

investigated. It is hoped that these results may be implemented into clinical practice and may change the existing best evidence synthesis of intensive care for patients with TBI.

5.3. Decompressive hemicraniectomy

Decompressive procedures in neurosurgery are excellent methods for reducing the ICP in patients suffering from TBI or stroke. The number of such procedures has increased substantially worldwide with good effect on increased ICP. Of specific interest is decompression of the brain tissue by a larger hemicraniectomy. There are no real answers for these results. Thus, the debate on its overall effectiveness remains and complete consensus has not been achieved among clinicians (Cooper, Rosenfeld and Murray et al., 2011; Vashu and Sohail, 2011) From a global perspective, the number of TBI in need of decompressive hemicraniectomy will remain at an unacceptably high level for a long time to come. Presently, there is debate on how to interpret data from the decompressive craniotomy and apply it to clinical practice (Servadei, 2011).

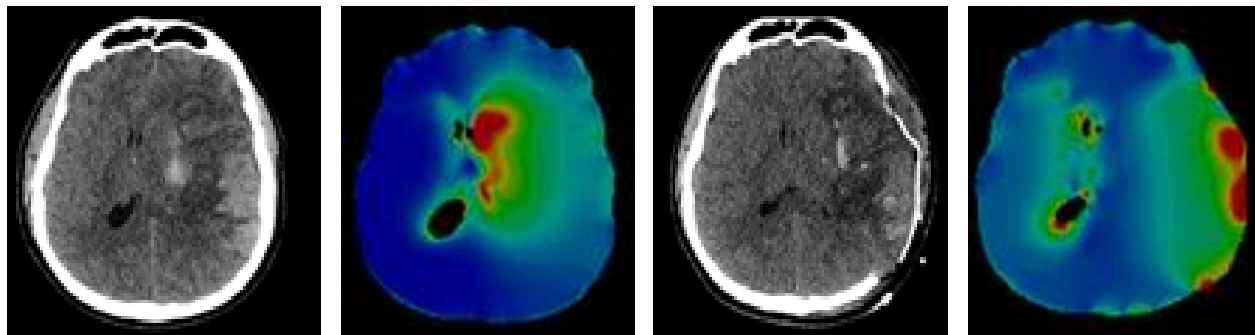


Figure 6. Evaluation of strain level in different anatomical areas in the brain tissue before (left black image with CT, left colour image with NIBIE) and after the decompressive hemicraniectomy (right black image with CT, right colour image with NIBIE).

The purpose of decompressive craniotomy is to reduce the ICP by allowing expansion of the brain tissue outside the skull bone. However, the treatment also results in stretching of the axonal fibres, which has been suggested to contribute to an unfavourable outcome for patients treated with decompressive craniotomy (Cooper, Rosenfeld and Murray et al., 2011; Stiver, 2009). Thus, there is a need for new clinical methods that may have the capacity to better consider the biomechanical consequences of swollen brain tissue after decompressive hemicraniectomy. With the new image technology of NIBIE, it is possible to evaluate the consequences by focusing on strain level before and after the neurosurgical procedure, which may have possibly improve our knowledge in this context. In fact, an increased strain may account for why we don't see more significant improvement in these patients.

Prior to the neurosurgical procedure (Fig. 6, left), the CT showed increased strain levels of various degree in and around the injured brain tissue. When evaluating the consequences of decompressive hemicraniectomy, the strain level of the nervous tissue on the same side was also increased to over 60% and also more widespread (Fig. 6, right), and interfering with the

remote hemisphere. Increased strain level can also be found when evaluating several slices from NIBIE, where the decompressive hemicraniectomy causes the injured brain tissue to expand beyond the skull bone. This results in strain levels well over 60% (Fig. 7).

- Strain level in %

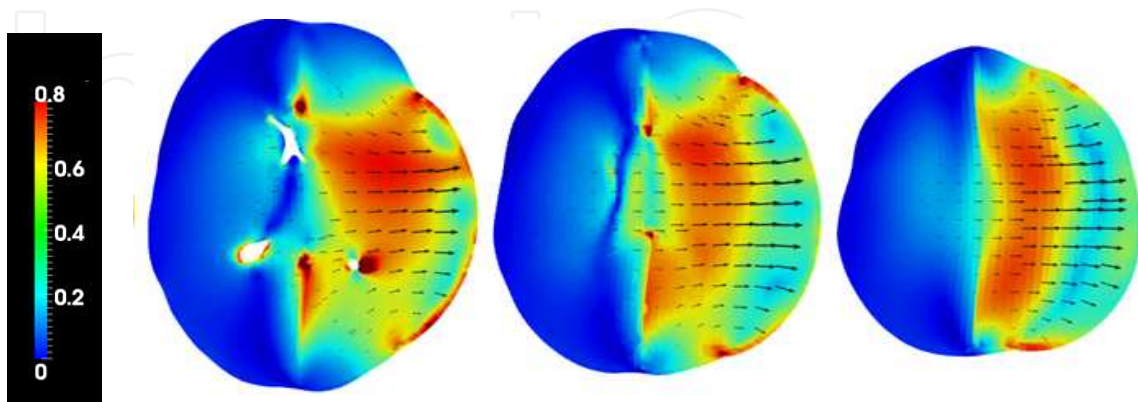


Figure 7. Three image sections from NIBIE showing increased strain levels of over 40% on the injured side (right hemisphere) after decompressive hemicraniectomy.

When biomechanical effects cause the nerve fibres to become stretched abnormally high during the neurosurgical procedure, the normal biochemical metabolism is also altered. Axons transfer electrical-chemical impulses between neurons, including their intact axons. These activities are critical for establishing normal clinical function in the nervous system. When parts of the axonal fibres are stretched, the capacity to transfer physiological impulses is altered and may even result in permanent loss of functional capability when stretched too much (Joseph, 1996). *In vitro* models for studying injury have shown that axonal stretch causes a number of neural derangements including neurofilament structure alterations (Chung, Staal and McCormack, 2005), immediate rise in intracellular calcium level after injury (Staal, Dickson and Gasperini, 2010), mechanical breaking of microtubules during stretch in axons (Tang-Schomer, M.D, Patel, A.R and Baas et al., 2010) and axonal swelling formation (Smith, Wolf and Lusardi et al., 1999).

An increase in strain levels as low as a 5% increase will alter neuronal function, while a strain level higher than 20% induces significant levels of cell injury *in vitro* (Morrison III, Cater, Wang et al., 2003). Bain et al. (2000) demonstrated that a strain level of approximately 21% will initiate electrophysiological changes, while a strain of approximately 34% results in morphological signs in the white matter. Combined, these studies have increased the knowledge in response to biomechanical stretch as found after the neurosurgical procedure. This may explain why decompressive craniotomy not only reduces ICP, but may also contribute to unfavourable outcomes for patients by increasing the strain level. Thus, with NIBIE, it is possible to quantify the axonal stretching to better understand the consequences of the neurosurgical procedure for many of the most severely injured patients, thereby having a better insight into the potential damages to the nervous tissue after TBI and stroke. In general, decompressive craniotomy results in complex axonal deformation; it is difficult to apply these cellular level thresholds to

the tissue level, since the axons within the white matter do not necessarily lie in the same orientation as the stretching direction. Most of the previous axonal injury models use dynamic brain tissue during impact to study strain. This is different to the case of axonal stretch for the post-craniotomy stage, under which the axons are enduring slow dynamic events similar to a quasi-static stretching. The incorporation of fibre tracts in biomechanical simulation models is therefore necessary to obtain stretching along the axons, thus making it comparable with the threshold obtained from laboratory investigations.

The displacement and stretching of injured cerebral tissue after TBI and stroke is usually found for several days. This may further challenge the cerebral metabolism. Using a model of sciatic nerve stretch, it was reported that even minimal tension, if maintained for a significant amount of time, may result in loss of neuronal function (Fowler, Leonetti and Banich, 2001). Hence, it should be expected that the central nervous system will also sustain potential damage under long duration stretch, such as in the post-craniotomy stage, but with a different threshold level. The strain level representing the stretch of brain tissue has been quantified in a previous study (von Holst, Li and Kleiven, 2011). It was shown that following decompressive craniotomy, the strain level, as well as the water content in the brain tissue, was substantially increased. This may influence the axonal fibres in such a way that the neurochemical events are jeopardized. Axonal fibre tracts extracted from diffusion weighted (DW) images have been included in a biomechanical model simulating an impact event in order to study the axonal elongation occurring at the primary injury stage (Chatelin, Deck and Renard et al., 2011). Results from this study showed that stretching of axons correlates closely with diffuse axonal injury (DAI). However, axonal stretching during the post-craniotomy period, which may have prognostic value for the cognitive and neurological sequelae of patients treated with decompressive craniotomy, has not been previously studied.

6. Conclusion

Parallel with an increased theoretical knowledge of TBI, clinical neuroscience practice has witnessed a remarkable improvement with new technological equipment aimed at emergency care at the scene of accident, intensive care, as well as for neurosurgical procedures. Concurrently, the significant development of computer capacity during the last two decades has made it possible to implement various software programs having the capacity to better understand the mechanical consequences following an accident to the central nervous tissue. Thus, the integration of clinical practice with neuroengineering used for applied neurosurgery may further improve the future outcome of patients suffering from moderate and severe TBI. The integrated research between clinical neurosurgery and neuronics engineering has resulted in the development of a method for generating a numerical model based on 3D medical images, from either computer tomography (CT) or magnetic resonance imaging (MRI). We have found that simulation of TBI in numerical models can define the intracranial pressure without neurosurgical procedures. In addition, the strain level, which is related to the stretching of axons, can be used as a new predictive value in diagnoses, e.g., the effect of oedema and haemorrhage. Moreover, it is now possible to analyse the outcome of a treatment in, for

instance, decompressive hemicraniectomy. By using numerical models of the human brain, it is possible to further optimize present treatments of TBI. Finally, using NIBIE in education of health care staff in all categories in the new field of neuroengineering is of significant importance in order to better understand the consequences of diseases in the central nervous system.

Acknowledgements

The present chapter was sponsored by Vinnova, Karolinska University Hospital and the Royal Institute of Technology, Stockholm, Sweden.

Author details

Hans von Holst^{1,2} and Svein Kleiven²

1 Dept. of Neurosurgery, Karolinska University Hospital, Stockholm, Sweden

2 Division of Neuronic Engineering, Royal Institute of Technology, Stockholm, Sweden

References

- [1] Bain, B.C. and Meaney, D.F, (2000) Tissue-Level Thresholds for Axonal Damage in an Experimental Model of Central Nervous System White Matter Injury. *J. Biomech. Engng.*16, pps 615-622.
- [2] Chatelin, S, Deck, C, Renard, F, Kremer, F, Heinrich, C, Armspach, J.P, Willinger, R, (2011). Computation of axonal elongation in head trauma finite element simulation. *Journal of the Mechanical Behavior of Biomedical Materials*, 4(8):1905–1919.
- [3] Chung, R.S, Staal, J.A, McCormack, G.H, Dickson, T.C, Cozens, M.A, Chuckowree, J.A, Quilty, M.C, Vickers, J.C, (2005) Mild axonal stretch injury in vitro induces a progressive series of neurofilament alterations ultimately leading to delayed axotomy. *Journal of neurotrauma*, 22(10):1081–1091.
- [4] Clough, R. W., (1980). The finite element method after twenty-five years: A personal review. *Computers and Structures*, Vol 12 (4), 361-370.
- [5] Coffey A.M, Garg I, Miga M.I, Thompson R.C (2010). An evaluative tool for preoperative planning of brain tumor resection. *Proc SPIE* 7625:762531. doi:10.1117/12.844477
- [6] Cooper, D.J, Rosenfeld, J.V, Murray, L, Arabi, Y.M, Davies, A.R, D'Urso, P, Kossmann, T, Ponsford, J, Seppelt, I, Reilly, P, Wolfe, R (2011). Decompressive craniectomy

- my in diffuse traumatic brain injury. *New England Journal of Medicine*, 364(16): 1493–1502.
- [7] Cooper, P.R, (1982). Post-traumatic intracranial mass lesions, in: *Head injury*, Williams and Wilkins, Baltimore/London. pages 185-232.
- [8] Dutta-Roy T, Wittek A, Miller K (2008) Biomechanical modeling of normal pressure hydrocephalus. *J Biomech* 41:2263–2271.
- [9] Fowler, S.S, Leonetti, J.P, Banich, J.C, Lee, J.M. Wurster, R, Young, M.R.I, (2001) Duration of neuronal stretch correlates with functional loss. *Otolaryngology-Head and Neck Surgery*, 124(6):641–644.
- [10] Gennarelli, T.A, et al., (1972). Pathophysiological Responses to Rotational and Translational Accelerations of the Head, SAE Paper No. 720970, in: 16th Stapp Car Crash Conf., Society of Automotive Engineers, pp. 296-308.
- [11] Gennarelli, T.A, et al., (1982) Diffuse Axonal Injury and Traumatic Coma in the Primate. *Ann. Neurol.* 12, 564-574.
- [12] Gennarelli, T.A, (1983). Head injuries in man and animals: clinical aspects. *Acta neurochir suppl.* 32, 1-13.
- [13] Genarelli T.A, et al., (1987) Directional dependence of axonal injury and traumatic coma in the primate. *Ann. Neurol.* 12, 564-574.
- [14] Gurdjian E.S, Lissner, H.R, (1944) Mechanisms of head injury as studied by the cathode ray oscilloscope: preliminary report. *J Neurol Neurosurg Psychiatry* 1:393-399.
- [15] Hinghofer-Szalkay H, (2011) Gravity, the hydrostatic indifference concept and the cardiovascular system. *Eur J Appl Physiol* 111:163–174.
- [16] Ho, J, (2008) Generation of patient specific finite element head models. Doctoral thesis report:7 ISBN: 978-91-7415-191-6.
- [17] Ho, J, von Holst, H, Kleiven, S, (2009) Automatic generation and validation of patient specific finite element head models suitable for crashworthiness analysis. *International Journal of Crashworthiness*, 14(6): p. 555-563.
- [18] Ho J, Kleiven, S, (2009) Can sulci protect the brain from traumatic injury? *J Biomech* 42: 2074–2080.
- [19] von Holst, H, (2007) Traumatic brain injury. In: Feigin VL, Bennett DA (eds) *Handbook of clinical neuroepidemiology*. Nova Science, New York, pp. 197–232.
- [20] von Holst, H, Li, X.G, Kleiven, S, (2011) Increased strain levels and water content in brain tissue after decompressive craniotomy evaluated with numerical analysis.
- [21] Holburn, A.H.S, (1943) Mechanics of head injury. *Lancet* 2. October 9, 438-441.

- [22] Huang H.M, Lee, M.C, Chiu, W.T, Chen, C.T, Lee, S.Y, (1999) Three-dimensional finite element analysis of subdural hematoma. *The Journal of Trauma, Injury, Infection and Critical Care*. 47 (3) 538-544.
- [23] Joseph, R, (1996) *Neuropsychiatry, neuropsychology, and clinical neuroscience: emotion, evolution, cognition, language, memory, brain damage, and abnormal behavior*. Williams & Wilkins.
- [24] Ju, W.K, Liu, Q, Kim, K.Y, Crowston, J.G, Lindsey, J.D, Agarwal, N, Ellisman, M.H, Perkins, G.A, Weinreb, R.N, (2007) Elevated hydrostatic pressure triggers mitochondrial fission and decreases cellular ATP in differentiated RGC-5 cells. *Invest Ophthalmol Vis Sci* 48:2145–2151.
- [25] Kaczmarek, M, Subramaniam, R.P, Neff, S.R, (1997) The hydromechanics of hydrocephalus: steady-state solutions for cylindrical geometry. *Bull Math Biol* 59:295–323.
- [26] Kleiven, S, von Holst, H, (2002) Consequences of head size following trauma to the human head. *Journal of Biomechanics* 35, 153-160.
- [27] Kleiven, S., Peloso, P.M. von Holst, H, (2003) The epidemiology of head injuries in Sweden from 1987 to 2000. *Inj Control Saf Promot*, 10(3): p. 173-80.
- [28] Kleiven, S, (2006) Evaluation of head injury criteria using an FE model validated against experiments on localized brain motion, intra-cerebral acceleration, and intracranial pressure, *International Journal of Crashworthiness* 11 (1), 65-79.
- [29] Kleiven, S, (2007) Predictors for traumatic brain injuries evaluated through accident reconstructions. *Stapp Car Crash J*. 51: p. 81-114.
- [30] Kleiven, S, (2007) Predictors for traumatic brain injuries evaluated through accident reconstructions. *Stapp Car Crash J* 51:1–35.
- [31] Kumarezan, S, Radhakrishnan, S, Ganesan, N, (1995) Generation of geometry of closed human head and discretization for finite element analysis. *Med. Biol Eng Comput* 33, 349-353.
- [32] Krabbel, G, Muller, R, (1996) Development of a finite element model of the human head using the visible human database. *Abstract of the visible human project conference*, 71-72.
- [33] Lee, M.C, Haut, R.C, (1989). Insensitivity of tensile failure properties of human bridging veins to strain rate: Implications in biomechanics of subdural hematoma. *J. Biomech*. 22 (6/7), 537-542.
- [34] Levine, D.N, (1999) The pathogenesis of normal pressure hydrocephalus: a theoretical analysis. *Bull Math Biol* 61:875–916.
- [35] Li, X.G, (2012) *Finite element and neuroimaging techniques to improve decision making in clinical neuroscience*. Doctoral thesis report 2012:1 ISBN: 978-91-7501-240-7.

- [36] Li, X.G, von Holst, H, Ho, J, Kleiven, S, (2009) Three dimensional poroelastic simulation of brain edema: initial studies on intracranial pressure. Proceedings of World Congress on Medical Physics and Biomedical Engineering, September 7–12, Munich. Springer, Heidelberg, pp. 1478–1481.
- [37] Li, X, von Holst, H, Kleiven, S, (2011) Influence of gravity for optimal head positions in the treatment of head injury patients. *Acta Neurochirurgica*, 153(10): p. 2057-2064.
- [38] Lövenhjem, P, (1974) Dynamic Properties of the Parasagittal Bridging Veins. *Z. Rechtsmedizin* 74, pages 55-62.
- [39] Marmarou, A, (2003) Pathophysiology of traumatic brain edema: current concepts. *Acta Neurochir Suppl* 86:7–10.
- [40] Marmarou, A, Signoretti, S, Fatouros, P.P, Portella, G, Aygok, G.A, Bullock, M.R, (2006) Predominance of cellular edema in traumatic brain swelling in patients with severe head injuries. *J Neurosurg* 104:720–730.
- [41] McElhaney, J, Roberts, V, Hilyard, J, (1976) Handbook of human tolerance, Japan Automobile Research Institute Inc., Tokyo, p. 143.
- [42] Melwin, J.W, (1995). Injury assessment reference values for the CRABI 6-Month Infant Dummy in a Rear-Facing Infant Restraint with Air Bag Deployment. in: SAE International Congress and Exposition. , SAE Paper No. 950872, Society of Automotive Engineers.
- [43] Miga, M.I, Roberts, D.W, Kennedy, F.E, Platenik, L.A, Hartov, A, Lunn, K.E, Paulsen, K.D, (2001) Modeling of retraction and resection for intraoperative updating of images. *Neurosurgery* 49:75–85.
- [44] Morrison III, B.C, Cater, H.L, Wang, C.C-B, Thomas, F.C, Hung, C.T, Ateshian, G.A, Sundström, L.E, (2003) A tissue level tolerance criterion for living brain developed with an in vitro model of traumatic mechanical loading. 47TH Stapp Car Crash Conference Journal.
- [45] Nagashima, T, Shirakuni, T, Rapoport, S.I, (1990) A two dimensional, finite element analysis of vasogenic brain edema. *Neurol Med Chir* 30:1–9.
- [46] Narayab, R.K, Wilberger, J.E, Povlishock, J.T, (Editors) (1995) *Neurotrauma*. McGraw-Hill. ISBN 0-07-045662-3.
- [47] Ommaya, A.K, Hirsch, A.E, (1971) Tolerances for Cerebral Concussion from Head Impact and Whiplash in Primates. *J. Biomech*, 4, 13-21.
- [48] Rabinstein, A.A, (2006) Treatment of cerebral edema. *Neurologist* 12:59–73.
- [49] Reulen, H.J, Kreysch, H.G, (1973) Measurement of brain tissue pressure in cold induced cerebral oedema. *Acta Neurochir (Wein)* 29:29–40.

- [50] Schugar, T.A, (1977) A finite element head model Vol I: Theory, development and results. U.S. Deptat. of Transportation Report No. DOT-HS-289-3-550-IA.
- [51] Servadei, F, (2011) Clinical value of decompressive craniectomy. *New England Journal of Medicine*, 364(16):1558–1559.
- [52] Shreiber, D.I, Bain, A.C, Meaney, D.F, Schreiber, D.I, Bain, A.C, (1997) In vivo thresholds for mechanical injury to the blood-brain barrier. 41st Stapp Car Crash Conf.
- [53] Tang-Schomer, M.D, Patel, A.R, Baas, P.W, Smith, D.H, 2010 Mechanical breaking of microtubules in axons during dynamic stretch injury underlies delayed elasticity, microtubule disassembly, and axon degeneration. *The FASEB Journal*, 24(5):1401–1410.
- [54] Thibault, L.E, (1993) Brain injury from the macro to the micro level and back again: What have we learned to date? in: IRCOBI Conf. 3-25.
- [55] Smillie, A, Sobey, I, Molnar, Z, (2005) A hydroelastic model of hydrocephalus. *J Fluid Mech* 539:417–443.
- [56] Smith, D.H, Wolf, J.A, Lusardi, T.A, Virginia, M.Y.L, Meaney, D.F, (1999) High tolerance and delayed elastic response of cultured axons to dynamic stretch injury. *The Journal of neuroscience*, 19(11):4263–4269.
- [57] Staal, J.A, Dickson, T.C, Gasperini, R, Liu, Y, Foa, L, Vickers, J.C, (2010) Initial calcium release from intracellular stores followed by calcium dysregulation is linked to secondary axotomy following transient axonal stretch injury. *Journal of neurochemistry*, 112(5):1147–1155.
- [58] Stiver, S.I, (2009) Complications of decompressive craniectomy for traumatic brain injury. *Neurosurgical focus*, 26(6):E7.
- [59] Ueno, K, Melvin J.W,(1995) Finite element model study of head impact based on Hybrid III head acceleration; The effect of rotational and translational acceleration. *Journal of Biomechanical Engineering*. 117(3) 319-328.
- [60] Vashu, R, Sohail, A, (2011) Decompressive craniectomy is indispensable in the management of severe traumatic brain injury. *Acta neurochirurgica*, 10:2065–2066.
- [61] Ward, C.C, Thompson, R. B, (1975) The development of a detailed finite element brain model. SAE Paper No. 751163.
- [62] Werner, C, Engelhard, K, (2007) Pathophysiology of traumatic brain injury. *Br J Anaesth* 99:4-9.
- [63] World Health Organization (2003) World Health Report 2003: A vision for global health. Shaping the future. World Health Organization.
- [64] Zhou, C., Khalif, T.B, King, A.I, (1995) New model comparing impact responses of the homogenous and inhomogeneous human brain. *Stapp Car Crash Conference Proceedings*, 121-137.

