

We are IntechOpen, the world's leading publisher of Open Access books Built by scientists, for scientists

4,800

Open access books available

122,000

International authors and editors

135M

Downloads

Our authors are among the

154

Countries delivered to

TOP 1%

most cited scientists

12.2%

Contributors from top 500 universities



WEB OF SCIENCE™

Selection of our books indexed in the Book Citation Index
in Web of Science™ Core Collection (BKCI)

Interested in publishing with us?
Contact book.department@intechopen.com

Numbers displayed above are based on latest data collected.
For more information visit www.intechopen.com



Surgical Strategies for Liver Metastases from Colorectal Cancer

Nikola Kolev, Valentin Ignatov, Anton Tonev,
Tanya Kirilova, Georgi Ivanov,
Alexander Zlatarov and Krassimir Ivanov

Additional information is available at the end of the chapter

<http://dx.doi.org/10.5772/56915>

1. Introduction

Colorectal carcinoma is one of the more common types of cancer around the world. For patients in UICC stage I (i.e., those who have pT1/2 tumors and do not have any lymph node metastases), the probability of surviving 5 years is 90% [2]. The prognosis of patients in stages II (pT3/4 tumors without lymph node metastases) and III (tumors with lymph node metastases) has improved steadily in recent years. At present, the 5-year survival in these two groups is 80% and 60% [1].

Approximately, 1.2 million cases of CRC occur yearly worldwide, with 412, 900 new cases diagnosed in Western Europe alone and 150, 000 in the United States. [1, 2] Resection of colorectal liver metastases (CRLM) is the only treatment offering the possibility of cure and has been shown to provide clear survival benefits. [3] Unfortunately, only 10% to 20% of patients with CRLM are eligible for this procedure upfront. On the other hand, during the last 10 years, major advances in the management of CRLM have taken place involving principally three different fields: oncology (new and more effective chemotherapeutic agents), interventional radiology (portal embolization and radiofrequency), and surgery (better instruments and newer techniques). These advances as part of a multidisciplinary team approach have gradually but effectively increased the resectability rate to 20%-30% of cases with a 5-year survival of 35%-50%. [3]

Nonetheless, distant metastases eventually arise in about 20% of patients who are stage II or III at the time of diagnosis [3]. About 35% of all patients already have distant metastases when the diagnosis is made. Patients with untreated hepatic metastases have a very poor prognosis.

In a prospective, observational study carried out on 484 patients from 1980 to 1990, the median time to death was 6.9 months [4]. Adson and colleagues, in the 1970's, were the first to show that patients could be cured by the resection of hepatic metastases [5]. Since then, resection has become established as a standard treatment. For this review, we selectively searched the literature for articles containing the words "colorectal liver metastases," "chemotherapy," and "surgery," paying special attention to studies carried out on larger groups of patients and to randomized clinical trials. [6]

Most favorable outcomes were observed in patients with pedicle lymph node involvement (5-year survival rate 25% vs 0% for patients with celiac and/ or para-aortic lymph node metastases), and in patients younger than 40 years (5-year survival rate 45% vs 10% for older patients). [7, 8] In relation to our results and those reported by others, we recommend combining hepatectomy with lymphadenectomy only for young CLM patients presenting with pedicle lymph node involvement, in the absence of disease progression after preoperative chemotherapy. On the other hand, patients presenting with celiac or para-aortic lymph node involvement should not be subjected to this oncosurgical treatment strategy. Even concomitant pulmonary metastases should not be considered a contraindication to surgery. Patients with only pulmonary metastases as a site of extrahepatic disease have a particularly good outcome after complete metastasectomy of both liver and lung disease. Five-year survival rates ranged from 22% to 50% in patients with metastases limited to the lungs. [8] Also, selected patients with complex multiorgan metastases have been associated with prolonged survival after a multimodality treatment. Patients with simultaneous hepatic and extrahepatic disease (EHD) do, however, need to be selected for surgery. Elias et al stated that EHD, when resectable, is no longer a contraindication to hepatectomy. [18] More importantly, the total number of metastases, whatever their location, has a strong prognostic effect than the site of the metastases. In addition, a study conducted at our centre demonstrated that patients with concomitant EHD who were resected experienced a lower 5-year survival than those without EHD (28% vs 55%, $P < .001$). Five poor prognostic factors were identified with multivariate analysis: EHD location other than lung metastases, EHD concomitant to colorectal liver metastases recurrence, CEA-level > 10 ng/ml, > 6 colorectal liver metastases and right colon cancer. The five-year survival ranged from 64% (0 factors) to 0% (> 3 factors). [19]

We aim to report the new trends in strategies about surgical treatment of colorectal liver metastases and our experience according to surgical and oncological outcome in patients, operated for IV stage colorectal cancer.

2. Criteria for resectability

Currently available data have led to a change in the indications for resecting hepatic metastases of colorectal carcinoma. Previously, the indication was based on tumor-biological and clinical characteristics. The new criterion is the feasibility of complete resection of both intra- and extrahepatic disease. R0-resectable hepatic metastases, in patients without any extrahepatic metastases, should be resected. [12] As the determination of resectability is becoming ever more complex, all patients with hepatic metastases of colorectal carcinoma should be presented to an experienced hepatobiliary surgeon before the beginning of treatment. Postoperative

hepatic function can be predicted more precisely with the aid of CT volumetry. This technique enables prediction of the remaining volume of hepatic tissue after surgery to within 10% of the actual value. [9, 11]

Metastases are considered resectable when the following criteria are met:

- exclusion of a non-resectable extrahepatic tumor manifestation,
- parenchymal involvement <75%,
- <3 hepatic veins and <7 hepatic segments involved,
- no hepatic insufficiency, no Child B or C cirrhosis,
- no severe accompanying diseases.

Metastases are considered non-resectable or marginally resectable when an R0 resection is not possible. Metastases are also considered marginally resectable in the setting of, for example, extra-hepatic tumor manifestations, technical impediments to surgery, or inadequate expected residual liver mass. For these patients, intensified preoperative chemotherapy can be considered. The feasibility of secondary resection should be evaluated at each re-staging under chemotherapy. [15]

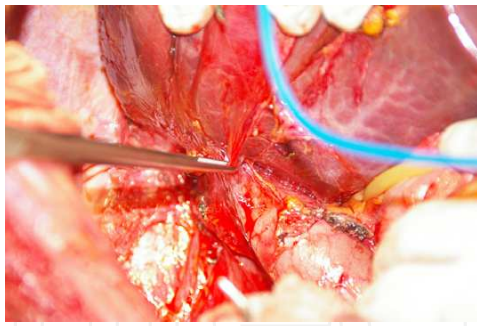
3. New treatment strategies

Today, patients with metastatic CRC should be treated by multidisciplinary teams including surgeons, oncologists and radiologists. Evidence of the benefit of perioperative chemotherapy over surgery alone [22] and the potential benefit of adjuvant chemotherapy (after liver resection) [23] caused a rethink among the experts particularly in terms of the timing of the administration of chemotherapy for CRC patients with initially resectable liver and lung metastases. Poor prognostic factors for patients with liver metastases are multiple metastases, >5 cm in diameter, synchronous presentation, lymph node-positive primary and high tumor marker levels. [17] Thus, even when the metastases are technically resectable (in terms of number, location and size), when facing a patient with more than one of the poor prognostic factors listed above, the current trend is to refer patients for neoadjuvant chemotherapy before surgery. The data from the EORTC study showed quite clearly that nearly all patients were able to tolerate neo-adjuvant chemotherapy. Also, analysis of the PFS curves from the EORTC-EPOC trial shows that the main difference comes after the first 2 months when the curves drop down and then move out in parallel, suggesting that the benefit conferred by perioperative chemotherapy might be a consequence of a reduction in the occurrence of early cancer relapse as a consequence of preoperative chemotherapy. [16] An exception to preoperative chemotherapy is, however, those patients with a single resectable metachronous metastasis who could be directly referred to surgery, [14] with the recognition that this accounts for <10% of patients seen in routine clinical practice. All other patients with resectable metastases should be treated up front with chemotherapy, with the caveats that the patient is able to receive chemotherapy and the position of the lesion is not going to be lost. On the other hand, it has

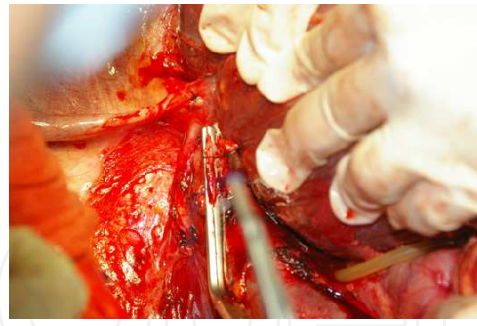
also become a standard strategy to give postoperative adjuvant chemotherapy to all resected patients (if possible) based on the data for the resected patients in the EORTC–EPOC trial. [22] For patients who are non-responders, there are two treatment strategies available: 1) change to a new chemotherapy protocol or 2) liver resection before the metastatic disease becomes unresectable. At this point it is important to mention that, the decision to perform either treatment strategy should always be decided by a multidisciplinary. Currently, it has become mandatory to select the systemic therapy regimen based on biological predictive factors, such as KRAS mutation status. This strategy has had a double impact: first of all, it has helped to optimize the choice of first-line treatment, in turn decreasing the risk of immediate disease progression; secondly, it has also helped to better select the second-line ‘rescue’ treatment strategies with the possibility of resection. [27] However, considering that surgery is still the only treatment that has curative potential per se, in some situations this can be the treatment of choice, even if resistance to medical treatment generally means that the patient has a unfavorable tumor biology. The situation is much simpler for patients whose metastases are initially unresectable, where systemic therapy is administered until an adequate response has been achieved. [24]

4. Primarily resectable hepatic metastases

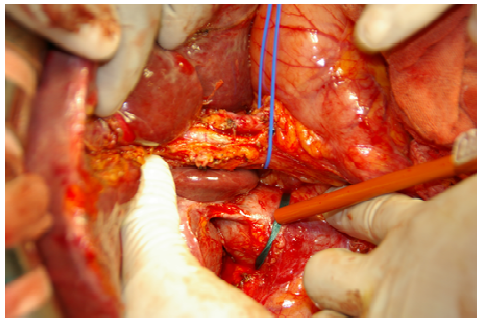
For operable hepatic metastases, hepatic resection is the treatment of choice. The reported 5-year-survival rates that have been achieved after the resection of isolated hepatic metastases with curative intent range from 25% to 50% [1–4, 6–8]. Hepatic metastases, however, are primarily resectable in only about 20% of patients [4]. For the remaining 80%, resection is contraindicated by the presence of diffuse hepatic metastases, non-resectable extra-hepatic disease, or impaired liver function. It is now generally accepted that the contraindications for hepatic resection that were defined in the 1980’s are no longer applicable. At that time, the presence of 4 or more tumor nodules, metastases exceeding 5 cm in size, extra-hepatic disease, or a tumor-free resection margin of less than 1 cm [9] was held to contraindicate hepatic resection. Many subsequent studies have confirmed that these are, indeed, relevant prognostic factors for survival after the resection of hepatic metastases of colorectal carcinoma, yet long-term survival is still possible when hepatic resection is performed despite the presence of these supposed contraindications. There have also been technical improvements in the treatment of hepatic metastases of colorectal carcinoma. Diagnostic assessment has become markedly more sensitive through the use of modern types of CT and MRI scanners and the introduction of PET-CT (5, 10–14]. Furthermore, surgical dissecting techniques and the development of potent systemic chemotherapy protocols have been optimized [15–18]. As a result, 5-year survival rates after the resection of hepatic metastases of colorectal carcinoma have improved markedly. [6] Today, even patients with more than three metastases or with metastases larger than 5 cm in diameter can be cured with appropriate surgical treatment, as found in a recent analysis [7]. One hundred and two patients were tumor-free 10 years after the resection of hepatic metastases of colorectal carcinoma, and only one patient among them developed a recurrent tumor thereafter.



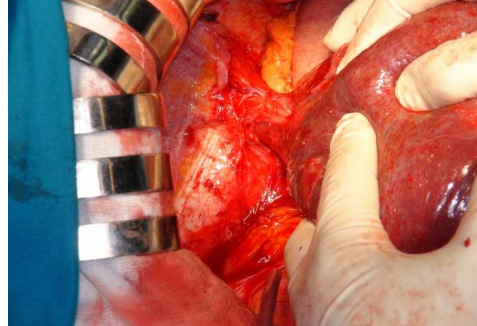
Right and retro-hepatic mobilization



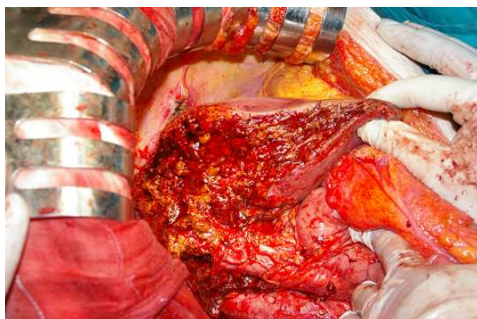
Hepatic vein division



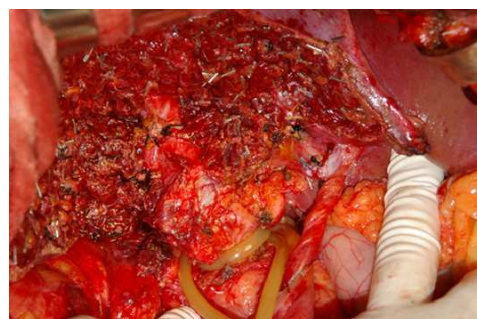
Total vascular exclusion of the liver – infra-hepatic



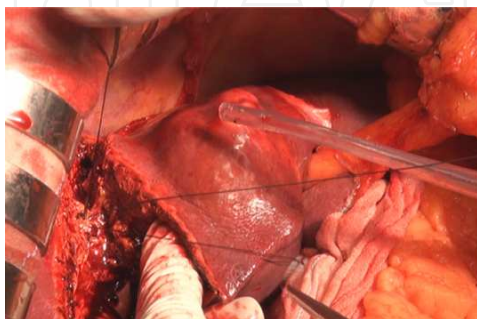
Total vascular exclusion of the liver – supra-hepatic



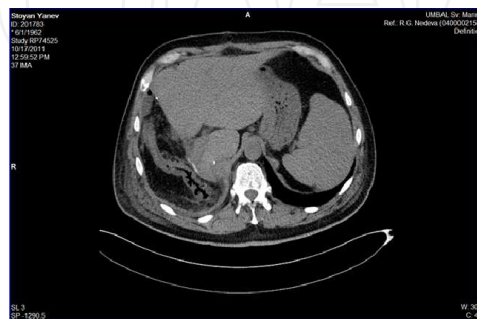Right hepatectomy



Mesohepatectomy



Left hepatectomy



Postoperative CT scan – left lobe hypertrophy

Figure 1. Different types of liver resections

5. Perioperative complications

Hepatic resections can now be performed safely and effectively. The mortality of hepatic resection was about 5% as late as 1990, while recent articles on the subject generally document figures between 1% and 2%. This reduction of mortality has been achieved even though the resections themselves have become ever more extensive. [3]

6. Long-term results after hepatic resection

More than 40% of appropriately selected patients with colorectal carcinoma who undergo the resection of hepatic metastases survive for at least 5 years thereafter [5, 6, 8, 9]. This is particularly true of patients whose surgery was performed more recently. As many as two-thirds of patients later develop a recurrent tumor, and half of them have a recurrent tumor in the liver [23]. In one of the largest studies performed to date, which included 1001 patients, showed that the benefit of surgery extends not just to patients who have undergone an R0 resection (5-year survival: 37%), but also to those who have undergone an R1 resection, i.e., a resection with positive margins, up to 20% of whom are still alive 5 years after surgery. [31]

7. Prognostic parameters

Many different prognostic scores are used to predict the patient's risk of recurrence and chances of long-term survival on the basis of preoperatively measured parameters. The three most commonly used scoring systems in hepatic surgery are those of Nordlinger, Fong, and Iwatsuki [2, 9, 24]. Although these scoring systems differ with respect to certain individual parameters, they share the common feature that a low score (i.e., the presence of no more than a few risk factors) is correlated with a low risk of recurrence, while the chance of long-term survival is less than 10% when all risk factors are present. No preoperatively measurable prognostic parameter can identify with any certainty the patients who will not benefit from surgical treatment. The most important prognostic factor, according to all studies, is a tumor-free resection margin [10, 11, 25, 26].

8. Expanded application of resection for CRLM

Liver resection is the current preferred treatment for CRLM patients and should be undertaken whenever feasible and potentially curative (R0), regardless of prognostic factors and presence of extra hepatic metastases. The main limiting factors to perform curative resection of CRLM are: presence of bilobar or bulky disease and presence of extra hepatic disease. Resection in patients with multiple or bulky lesions may result in insufficient residual hepatic tissue (i.e., less than 30% functional parenchyma). [19]

9. Neoadjuvant chemotherapy in patients with resectable CRLM

Despite major survival improvements achieved with successful primary hepatectomy for CRLM, [7-13, 20] many of these patients experience disease recurrence. Data indicate that pre or post-operative chemotherapy may provide a meaningful benefit, although controlled trials are needed. Tanaka et al [21] reported a retrospective analysis of patients with multiple CRLMs, wherein use of neoadjuvant chemotherapy was an independent predictor of survival by multivariate analysis. In 71 patients undergoing hepatectomy for more than five bilobar liver tumors, 3- and 5-year survival rates were superior ($P < .05$, log-rank) in the neoadjuvant chemotherapy group ($n=48$; 67.0% and 38.9%) than in the hepatectomy-alone group ($n=23$; 51.8% and 20.7%). Furthermore, neoadjuvant treatment reduced the need for extended (>4 segments) hepatectomies (39 of 48 neoadjuvant vs 23 of 23 control patients). Data from the LiverMetSurvey [5] also indicate a survival improvement with neoadjuvant treatment. In 207 patients with more than five metastases resected, 5-year survival was better with neoadjuvant treatment, although not significantly (20% vs 15%) and among 1,045 patients who had only one liver metastasis resected, 5-year survival rates were 49% and 57% with and without neoadjuvant chemotherapy, respectively. Similar results were reported in a meta-analysis by Mitry et al, [22] which showed a strong trend toward better disease-free survival with adjuvant 5-FU treatment (HR 0.76, $P=5.8$), and a trend toward favorable overall survival (HR 0.76, $P=9.8$). In addition, a phase III randomized study (The EORTC Intergroup) examined perioperative FOLFOX4 (5-fluorouracil (5-FU), leucovorin, oxaliplatin) chemotherapy for patients with potentially resectable CRLM. A total of 364 patients with up to four CRLM were randomized between perioperative FOLFOX4 (oxaliplatin 85 mg/m² and LV5FU2), six cycles before and six cycles after surgery (CT), vs surgery alone (S). Eleven of 182 patients were ineligible in each arm, mostly due to more advanced disease; 31 and 30 patients in the CT and S arms, respectively, could not undergo resection. At a median follow-up of 3.9 years, progression-free survival (PFS) was significantly better with CT in the group of resected patients, although the trial was formally not positive in the intention-to-treat (ITT) analysis (HR 0.79, $P=.058$). In terms of postoperative chemotherapy in resectable patients with CRLM data from United States and Europe show better survival in patients receiving adjuvant chemotherapy after resection of CRC liver metastases. [24] Use of adjuvant or neoadjuvant systemic treatment is widely recognized as standard of care in cases of liver resection, and was the focus of single-center studies with XELOX/FOLFOX25 and XELOX plus bevacizumab. [26] So far, only one study has as yet shown a clear benefit. [27] In this randomized trial, 109 patients (75 assessable) with one to three hepatic lesions received hepatic arterial floxuridine plus intravenous 5-FU ($n=30$) or no further therapy ($n=45$) after hepatectomy. The 4-year recurrence-free rates (46% vs 25%) and 4-year liver recurrence-free rates (67% vs 43%) were significantly better in the adjuvant therapy group. Median survival differences were not statistically significant (64% vs 49%), however, the trial was insufficiently powered to evaluate overall survival. [33]

10. Strategies for improving resectability

At present, only 10% to 20% of patients with hepatic metastases of colorectal carcinoma can be considered candidates for resective surgery. Opportunities for resection are often limited

by an unfavorable anatomical site of the metastasis (-es), poor function of the remaining hepatic parenchyma, and/or the patient's poor general condition. Multiple strategies have been developed in order to increase the percentage of patients whose metastases are resectable.

Liver surgery has progressed in parallel to the improvements in chemotherapy and interventional radiology. Bad-located tumors (situated deeply or close to critical vascular or biliary structures) can now be safely resected thanks to the availability of sophisticated instruments such as the ultrasonic dissector, argon gas diathermy and new techniques such as the one of low-central venous pressure anaesthesia that allows an almost bloodless field. With the routine use of intraoperative ultrasound examination precise localization of liver lesions and planning of the resection is done aiming at removing all possible lesions with a clear margin and at the same time preserve the maximum of liver parenchyma. This improvement in surgical planning and techniques has been directly responsible for the low hospital mortality. The risk of liver resection for CRLM has decreased in specialized hepatobiliary centres probably below the figures observed after colorectal surgery. The mortality of elective liver resection on non-cirrhotic livers is estimated to be around 1% [35, 36] at a time when patients' age and disease complexity are increasing, in addition to the associated changes of SOS and CASH often present in chemotherapy patients undergoing surgery. The experience of the centre has a major impact on outcome: the mortality and morbidity of liver resections decreased inversely to the number of cases performed in the institution. [37] It has been shown in US that patients resected at high volume centres (>25 cases/year) for liver cancer have not only a better perioperative outcome, but also a better long-term survival, [38] and similar results concerning the correlation between high volume surgery and specialization and outcome were observed in Europe. [39]

11. Preoperative chemotherapy ("down-staging")

When hepatic metastases of colorectal carcinoma are unresectable, systemic chemotherapy is indicated. About 20% of metastases respond to treatment with 5-fluorouracil (5-FU) and folic acid [4]. When these are used in combination with newer drugs, such as oxaliplatin or irinotecan (CPT-11), the response rate rises as high as 60% [29]. Folprecht et al. reviewed the available studies on the "down-staging" of hepatic metastases of colorectal carcinoma and found that resection rates are correlated with response rates [4]. The first major clinical series of this type was published in 1996 by Bismuth et al. [13] and updated in the years thereafter [14, 30]. The 5-year-survival was 40% (95% confidence interval: 33% to 68%) and was thus comparable to that of patients with primarily resectable hepatic metastases. A major bias in the studies of neoadjuvant chemotherapy published to date arises from patient selection. In the available prospective studies of patients with "isolated" hepatic metastases (i.e., no extrahepatic metastases), the criteria for nonresectability differ from one study to another and are often poorly defined. The hepatotoxicity of all currently used chemotherapeutic drugs argues against their use as neoadjuvant treatment for patients with primarily resectable hepatic metastases. Oxaliplatin can cause sinusoidal obstruction ("blue liver"), while irinotecan can induce fatty liver or steatohepatitis [31–34]. These changes are associated with significantly

more frequent perioperative complications. Vauthey et al. found that steatohepatitis after irinotecan use is associated with a significantly higher 90-day mortality [15].

12. Systemic chemotherapy in patients with non-resectable CRLM

Systemic chemotherapy is currently the main treatment approach for non-resectable CRLM. Incorporation of drugs such as oxaliplatin and irinotecan have led to an improvement of median survival as well as response rates compared with those achieved previously with 5-fluoracil (5-FU)/leucovorin-based regimens. Development of oral fluoropyrimidines has also improved treatment options in these patients. Median survival duration after systemic chemotherapy alone is approximately 20 months, [28, 29] however, only 1% to 2% of such patients remain alive at 5 years. [3, 30] On the other hand, the improved efficacy of newer regimens in down staging tumors is rendering more patients resectable. [14]

13. Accompanying chemotherapy

There is no longer any doubt that patients benefit from hepatic resections that are performed with curative intent. The current discussion concerns the question whether they also benefit from accompanying adjuvant or neo-adjuvant chemotherapy. The first encouraging data on adjuvant chemotherapy after hepatic resection were published by Kemeny et al., who compared local intra-arterial therapy combined with systemic 5-FU chemotherapy to adjuvant treatment with 5-FU alone. A trend was found toward improved progression-free survival in the group that additionally received regional therapy (37.4 versus 17.2 months, $p = 0.06$) [20, 44]. Nonetheless, the overall survival was no better in this group. This finding could not be replicated in a German study of intraarterial chemotherapy administered in the hepatic artery [21]. There are currently two further options for systemic chemotherapy: neo-adjuvant and adjuvant postoperative chemotherapy. For adjuvant chemotherapy, data are only available on 5-FU based treatment. Portier et al., in the AURC 9002 trial, describe an improved 5-year tumor-free survival of 33.5% among patients receiving adjuvant 5-FU bolus therapy, compared to 26.7% treated with resection alone [22]. These 5-FU patients' overall survival was no better than that of their counterparts without 5-FU, but the study size was, in any case, inadequate to detect a moderate benefit. An unplanned subgroup analysis revealed that patients with a greater tumor burden (diameter >5cm, or 3 or more tumor nodules) survived longer if they received adjuvant chemotherapy. Likewise, a pooled analysis of a number of studies, including the FFCD study, found a trend toward a benefit from adjuvant 5-FU treatment, in terms of both progression-free survival and overall survival [23]. These data appear promising, especially because there have been further improvements in chemotherapeutic regimens since they were published. Further evidence that adjuvant 5-FU treatment confers a survival benefit after the resection of hepatic metastases of colorectal carcinoma comes from a cohort study of 792 patients by Parks et al. [24]: The median survival time was 47 months, compared with 36 months without 5-FU. This year (2010), Nordlinger et al. have published the results of the

EORTC 40 983 trial, in which neoadjuvant therapy with FOLFOX (folic acid, 5-FU, and oxaliplatin) before and after hepatic resection was compared with resection alone. There were 182 patients in each of the study's two groups (with and without neoadjuvant therapy). The declared study endpoint of a significantly improved progression-free 3-year survival was not met in the intent-to-treat analysis. Tumor-free survival was 28.1% after surgery alone and 35.4% in the FOLFOX group [25]. The study did, however, show a significantly improved tumor-free 3-year survival when all patients whose data could be completely evaluated were taken into account (as opposed to the intent-to-treat analysis). Data on overall survival are currently unavailable. It should also be mentioned that the chemotherapy group had a higher rate of postoperative complications, but their postoperative mortality was no higher. Thus, in our view, preoperative chemotherapy should remain reserved, at least for now, to patients whose hepatic metastases are marginally resectable. This group includes patients whose tumor burden is high because of multiple hepatic metastases and extrahepatic tumor manifestations. Our view is founded on the documented survival benefit that can be achieved in patients who have a large burden of initially unresectable hepatic metastases by down-staging their tumors with chemotherapy, in order to render them resectable. [29]

14. Portal-vein embolization

In some cases, the resection of one or more hepatic metastases is technically feasible, yet cannot be performed because the amount of liver tissue remaining after resection would be too small. To minimize the risk of postoperative hepatic insufficiency, ipsilateral hepatic atrophy and contralateral hepatic hypertrophy can be induced preoperatively by selective embolization of the hepatic portal vein, or else by ligation of the branch of the portal vein that leads to the hepatic lobe containing the metastasis.

14.1. Definitions

Future liver remnant (FLR) is the liver that will be left in place after surgery and that was not targeted by embolization. The FLR must hypertrophy after portal vein embolization (PVE). Most teams wait 4 weeks before surgery. FLR hypertrophy must be measured by way of computed axial tomography (CAT) examination after injection of iodine with volumetric measurements of the FLR segments, with the results compared with the measurements performed before PVE using the same technique. Hypertrophy can be quantified as FLR hypertrophy, which is defined as the difference between FLR after a waiting period from 3 to 6 weeks after PVE minus FLR before PVE divided by FLR before PVE. The waiting period must be long enough to allow hypertrophy and as short as possible to avoid tumor growth, which precludes surgery. Hypertrophy can also be quantified by increased FLR ratio. The FLR ratio is defined as $(\text{FLR volume} - \text{tumor in the FLR}) / (\text{total liver volume} - \text{total tumor volume})$ [8]. Technical success of PVE is defined by a complete occlusion of portal branches feeding the future resected liver segments. Branches of the FLR must be patent with hepatopetal flow. In the late phase of control portography, parenchymography must be visible only in the FLR. Clinical success is considered to occur when the patient reaches the volumetric criteria for liver

resection. Patients with Tumors that Developed in Normal Underlying Liver Parenchyma PVE is recommended when the FRL-to-total liver ratio is 25 to 30 [7, 10, 11]. The indication of PVE can be extended to a 40% FLR ratio in patients having received chemotherapy or showing abnormal indocyanine green test results (or other abnormal liver function tests) [10, 12, 13]. Portal-vein embolization should always be considered when the residual hepatic volume without it would be less than 30% of the normal size of the liver, and when at least two contiguous hepatic segments are free of metastases. For technical surgical reasons, the left lateral segments 2 and 3 are particularly suitable for this approach. As long as the liver is not cirrhotic, portal-vein embolization results in a 40% to 60% hypertrophy of the contralateral hepatic lobe. It remains unclear at present whether the stimulus to hypertrophy that portal-vein embolization provides might also accelerate the growth of tumor nodules [16, 35]. In any case, the data regarding morbidity, mortality, and long-term survival are comparable to those of standard hepatic resections [16, 36–39].

Patients with Tumors that Develop in Chronic Liver Disease and Cirrhosis States

In such cases, the decision is based either on liver volume or on liver volume plus estimation of overall liver function by indocyanin green retention rate at 15 min. An FRLR of 40% is recommended when the ICCG 15 is between 10% and 20%. When the ICCG 15 is [20%, an FRLR of 50% is recommended [12–14].

Patients with Tumors Invading the Biliary Tree Associated with Cholestasis

Because biliary obstruction has impaired liver regeneration and hypertrophy, the biliary tree of the FRL must be drained first, and PVE can be performed secondarily. The indication is an FRLR\40% [15].

Contraindication for PVE [11]

PVE is contraindicated in the following types of patients:

1. Tumors invading the portal vein
2. Portal hypertension (blocked to free hepatic vein pressure gradient [12 mmHg])
3. Coagulation disorders (PT\60%, platelet count\50 G/l)
4. Even if previous transarterial chemoembolization (TACE) may improve PVE results [16], a minimum of 3-week delay between TACE and PVE is recommended.

Patients should be informed that this procedure is not an antitumoral treatment but a treatment made to increase safety or to enable a surgical procedure. Minor complications are encountered in 20% to 25% of cases and are mainly associated with slight fever and abdominal discomfort and pain. Major complications are infrequent and mainly include infection and subcapsular hematoma, hemobilia, and portal vein thrombosis (9\2% of cases). Mortality due to PVE has not been reported. When tumors (usually small nodules) are present in the nonembolized lobe, it must be explained to the patient that those lesions might increase in size more quickly due to PVE [17]. Patients must also be told that the efficacy of the procedure can be estimated approximately 4 weeks after

PVE by way of CAT with injection of contrast media and liver volumetry.

14.2. Embolization method

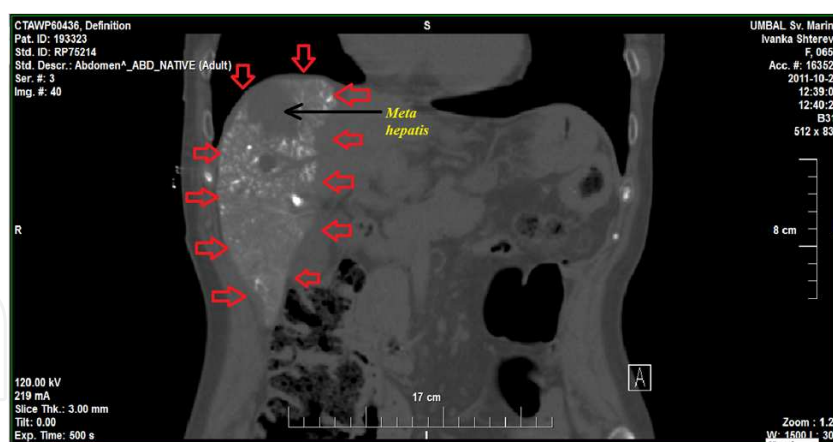
Access to the portal system should be done under ultrasound guidance to puncture a peripheral branch [8]. Access can be obtained by way of contralateral approach (i.e., puncture of the left portal branch and embolization of the right portal branches) or ipsilateral approach (puncture of the right portal branch to embolize right portal branches). The advantage of the contralateral approach is easier catheterization, but there is a risk of damage to the FLR. Five-French materials (catheter or introductory sheath) are usually recommended. The catheter should be placed at the splenomesenteric confluence to perform a portography to visualize portal anatomy, including its variations, and to localize segment IV branches. Measurement of portal pressure is not routinely performed in patients with normal liver. In cirrhotic patients, measuring the portal and central venous pressures is useful to determine whether the patient has a portostemic gradient [12 mmHg in, which case the patient is at major risk of perisurgical complications [18, 19]. These patients are not eligible for PVE. The aim of embolization is complete obstruction of the targeted branches and redistribution of flow to the FLR branches only. Final portography is mandatory to verify this objective. A final pressure measurement should be obtained at the end of the procedure in patients with chronic liver disease to document portal pressure increase, which is usually approximately 3 mmHg. Embolization of segment IV branches is recommended in patients with tumors who are undergoing extended right hepatectomy. However, if embolization of that segment causes risk of reflux into the portal branch of the FRL, such embolization must not be performed because any major reflux into FRL portal branches might preclude surgery.

15. Two-stage hepatic resection

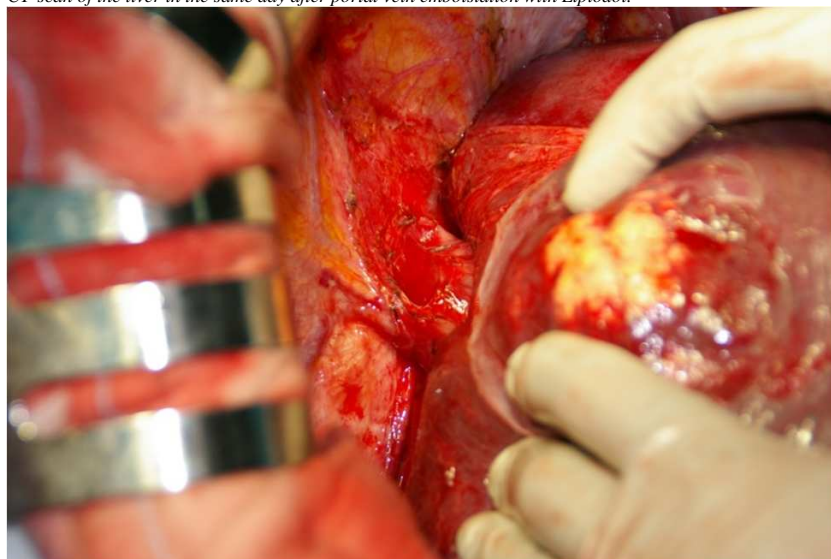
A further way of enabling curative resection of patients with extensive bilobar hepatic metastases of colorectal carcinoma is so-called two-stage hepatic resection [17]. This technique is suitable for patients with bilateral hepatic metastases who can undergo neither complete tumor resection, nor tumor resection combined with a local ablative procedure, because of the risk of postoperative hepatic insufficiency. Most, but not all, of the tumor burden is resected in a first operation, and then the remaining tumor nodules are resected in a second one, after liver tissue has regenerated. The decision whether to operate in one or two stages depends on the quantity and quality of the extratumoral hepatic tissue. The second operation is usually performed three to four weeks after the first, to allow time for the residual liver tissue to become adequately hypertrophic. [40]

16. Extreme liver surgery

Involvement of major vascular structures (vena cava or hepatic veins) by liver metastases has been considered as a contraindication to surgery for colorectal liver metastases. However, at



CT-scan of the liver in the same day after portal vein embolisation with Lipiodol.



The same patient – hypertrophy of the left liver, 8 weeks later

Figure 2. Portal vein embolization and liver hypertrophy.

the present time this clinical situation is no longer considered as contraindication due to the experience gained with total vascular exclusion (TVE) of the liver combined with vascular reconstruction. These techniques have made the surgery possible even for this group of patients, without exposing them to the risk of massive intraoperative blood loss and gas embolism. TVE consists on hepatic inflow and outflow occlusion. [46-48] This can be achieved by clamping the portal vein/ hepatic artery as well as the supra and infra hepatic vena cava. Alternatively, the hepatic veins are isolated and clamped in addition to the vascular portal structures. The latter technique is more advantageous as it can preserve the caval flow, however, in cases of caval infiltration by metastatic lesion/s this technique is not feasible. On the other hand, if hemodynamic instability is encountered while the vena cava is clamped, a veno-venous bypass should be installed to overcome this complication. Although, it is believed that the hepatic blood flow can be interrupted safely up to 60 minutes, when vascular resection/ reconstruction is necessary, a 60 minute duration of ischemia may be not sufficient. [47] Hence, hypothermic perfusion of the liver should be instituted. The combination of TVE with in situ hypothermic perfusion was evaluated in our center. [68] It is found that this combination was

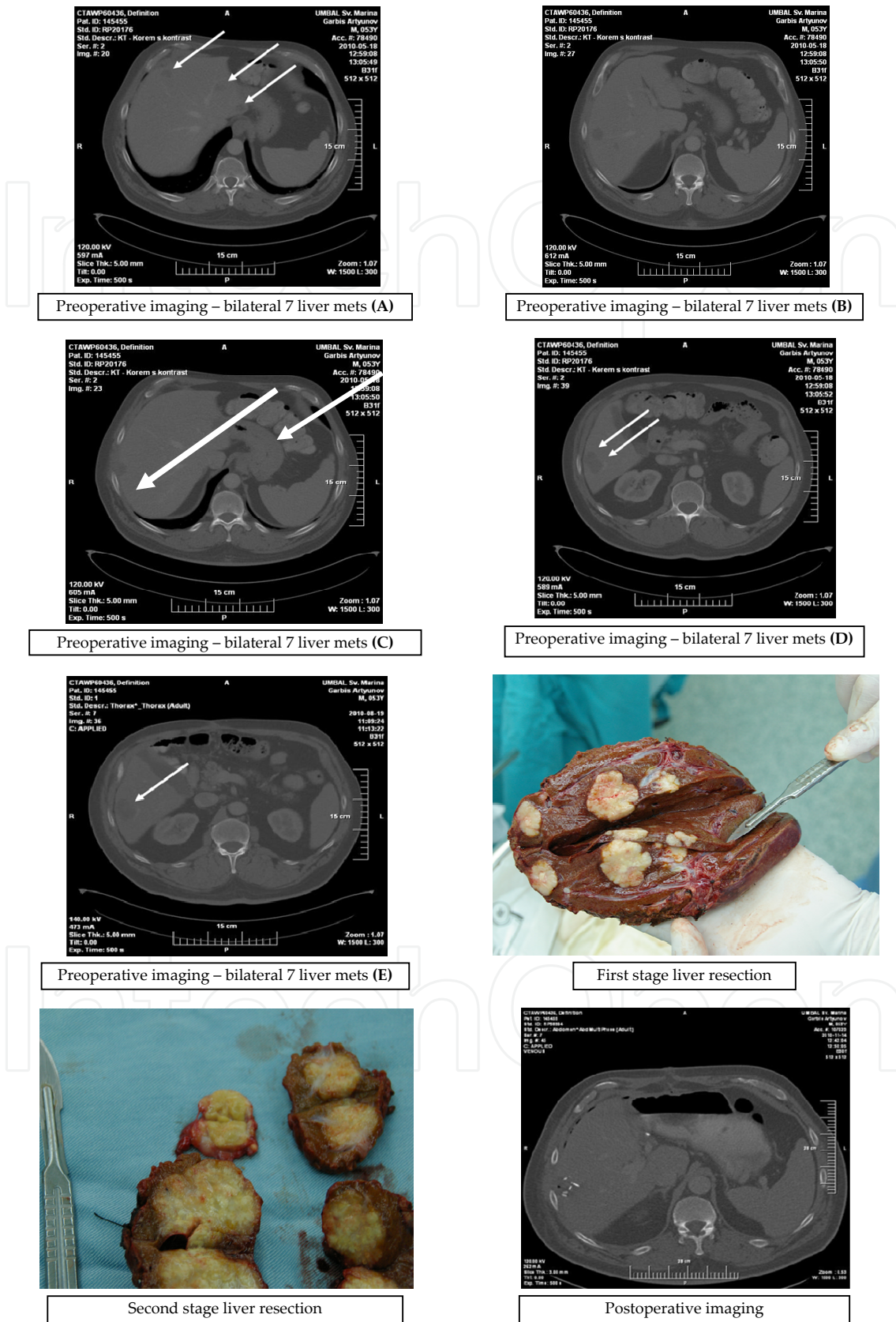


Figure 3. Two stage hepatectomy.

associated with a better liver tolerance to ischemia, a better liver function, and a significantly lower rate of complications compared to standard TVE >60 min. In some cases, a combined liver and vascular resection may be required. An experience with such cases (combined liver and vena cava resection) has shown that a 5-year survival of 38.3% can be obtained even for this group of patients. [49] In conclusion, using TVE and vascular reconstruction techniques, surgery in cases with involvement of the vena cava or hepatic veins is not necessarily contraindicated. However, a very careful evaluation and selection of the cases should be done, making sure that the risks involved do not counterbalance the desired benefits. [42]

17. Timing of surgery

Optimal duration chemotherapy and timing of liver surgery in responding patients have not been definitively established. For patients not considered resectable, in the clinical setting, most surgeons perform liver resection as soon as metastases become operable. Similarly, there is still debate, whether chemotherapy should precede resection when metastases are synchronous, particularly when the primary tumor is in place and the surgery involves the resection of the primary tumor as well as a simultaneous major liver resection. At the present, many surgeons believe that the chemotherapy is a better choice for patients with synchronous liver metastases, although these conclusions come from retrospective or surgical series from a single center. Capussotti and colleagues have published several papers on this topic. [40-43] There is only one randomized study [23] which has evaluated the results of preoperative chemotherapy and demonstrating an absolute difference in favor of chemotherapy. However, this study has a drawback as it was not possible to separate the benefits of preoperative chemotherapy from those of adjuvant postoperative chemotherapy. Another issue is the impact which the disease progression while on chemotherapy has on the timing of surgery. Disease progression during neoadjuvant chemotherapy indicates a poor prognosis. In a cohort of 131 patients undergoing rescue hepatectomy, 5-year survival rates were 8% if disease progressed during preoperative chemotherapy, 30% if disease was stable, and 37% in responders. [14] These findings suggest that hepatectomy for CRC metastases should be undertaken as soon as technically feasible and underscore the importance of collaboration between medical oncologists and surgeons in achieving that goal. Medical oncologists should be referring patients for surgery before tumor progression, and surgeons need to consider tumor evolution in addition to resectability. Thus, patients with biologically aggressive tumors unlikely to benefit from resection may be spared surgery upfront and can instead consult with the medical oncologist for a better regimen likely to induce tumor response or stabilization. [44]

18. Local tumor destruction and hybrid techniques

In recent years, local ablative methods such as cryotherapy and radiofrequency ablation (RFA) have come into more common use for the *in situ* destruction of hepatic metastases. Among these methods, RFA has been studied the best. It can be performed percutaneously, laparos-

copically, or at open surgery and is currently used for tumors up to 5 cm in diameter. Lencioni et al. recently reported a multicenter study of 423 patients with a total of 615 metachronous metastases of colorectal carcinoma who were treated with RFA. The average tumor size was 2.7 cm [18]. In this patient group, 25% had local tumor progression, and the 1-, 3-, and 5-year survival rates were 86%, 47%, and 24%. These figures correspond to those of Abdalla et al., who found that tumor progression is more probable after RFA than after surgical resection [19, 43]. In general, RFA is associated with low morbidity and mortality. As no prospective data are yet available for a comparison of local ablative techniques to hepatic resection with curative intent, the procedure cannot be recommended as an alternative to hepatic resection, though it does play a role as an additional, complementary method of achieving complete tumor destruction in patients whose lesions are not otherwise R0-resectable.

19. Radiofrequency thermal ablation (RFA)

RFA is the most widely used technique for local destruction of CRLM and has gained popularity because of its relative easy usage, and its effectiveness as an adjuvant treatment.⁴⁸ For the treatment of CRLM, RFA can be used as: 1) a definitive treatment per se; 2) a complementary procedure to surgery, or 3) in the treatment of recurrent metastatic disease after surgery. Results so far show that RFA must be restricted to cases in which the size of the dominant lesion is less than 3 cm or when a maximum of three tumours are present.⁴⁹ In a study on percutaneous RFA for CRLM, local control was achieved in 78% of tumours <2.6 cm, but only in 47% of tumours 2.6-4.0 cm and 32% of tumours >4.0 cm.⁴² The anatomic location of a metastasis is an additional limitation of RFA. In the vicinity of a large hepatic vessel, the heat sink effect significantly increases the risk of incomplete ablation. Also, the risk of thermal injury is increased when nodules are close to main biliary structures or to extrahepatic organs. In these cases, new RFA techniques or additional procedures, such as hepatic inflow occlusion or intraductal cooling, have to be considered. [50, 51] Because of the high local recurrence rates, and of the anatomical limitations described above, there is still no place for RFA in patients with resectable colorectal metastases. Surgical RFA for small resectable CRLM could only be acceptable in a randomized trial comparing resection with surgical RFA, [52] and it was shown that hepatic resection is still the treatment of choice for CRLM and that RFA alone provides survival only slightly superior to non-surgical treatment. [53] This is the case also for patients with solitary liver metastases who are treated with RFA (higher LR rate and shorter recurrence free and overall survival). [54] Radiofrequency ablation has been proposed to treat a limited number of small metastases, simultaneously with right PVE. [46, 47] Although this strategy is theoretically appealing because it limits the number of surgical operations, its effectiveness compared to two-step hepatectomies is doubtful. The place of RFA in the treatment of CRM is limited: it is most useful for early recurrences detected as small lesions after resection, because it is not mandatory to stop the chemotherapy, except for the use of bevacizumab, and because RFA allows a “test of time” that helps to select out patients with very aggressive/disseminated disease that would not benefit from repeated surgery.

19.1. Frequency of complications

19.1.1. Mortality

A total of 21 deaths were reported in 11 series, [41] with overall mortality varying from 0% to 5.2%. Four deaths were related to cirrhosis. Eleven occurred in patients undergoing resections, eight of which were major hepatectomies. Eight deaths were related to liver failure, four of which were subsequent to major hepatectomy with IRFA on the remnant liver for bilobar disease. Five deaths were caused by myocardial infarct; one of these related to a carcinoid crisis and another to a haemorrhage. Four deaths resulted from portal thrombosis, three of which occurred in cirrhotic patients. One of these patients had been treated by IRFA alone. Four deaths were related to septic complications; two of these referred to pulmonary infections, one to infection of the ascites and one to multiple deep abscesses. Lastly, three deaths were reported after postoperative haemorrhaging; one was caused by liver failure after an intrahepatic haematoma in a cirrhotic setting, one resulted from myocardial infarction following a haemorrhage in a large metastasis treated by IRFA, and one patient was treated by major hepatectomy and two IRFA sessions and died of cardiac arrest after postoperative bleeding.³¹

19.1.2. Infections

Abdominal infections were reported in 49 patients in 21 series. [41] Diagnosis of infection was delayed by up to 5 months. Seventeen liver abscesses were reported, of which one was fatal and were related to IRFA. Only one case of biliary digestive anastomosis was observed. Ten cases of perihepatic abscesses at resection sites were reported. Twelve were following digestive system-associated procedures. These abscesses were treated by percutaneous drainage and antibiotics. One patient needed re-operation and died from septic shock. Seven cases of wound infection were reported; two were re-operated. Lastly, one case of peritonitis after infection of the ascites was reported and was fatal.

19.1.3. Biliary complications

Twenty-five early (30 postoperative days) and 14 delayed (sometimes for >4 months¹⁸) biliary complications [42] were reported in 10 series. Twelve biliary leakages occurred, 10 of which were early. Six occurred in resection combined with IRFA. One early leakage was caused by a prophylactic cholecystectomy, but two delayed leakages were associated with a biliary stenosis. Fifteen intrahepatic bile collections were described, one of which induced duodenal compression. One article gave details of the treatment of eight biliomas: all eight were drained percutaneously and two recurred after drain clamping. Two were related to biliary stenoses and were treated by intrahepatic stenting; the other six patients underwent endoscopic sphincterotomy. Eleven biliary stenoses associated with jaundice and biliary dilatation were reported, of which five were early. These were complicated by biliomas, biliary leakage and cholangitis. In their prospective study, some authors [43] did not observe a correlation between central or peripheral localization of the tumour and the frequency of biliary complications.

19.1.4. Liver failure

Liver failure was reported in 24 patients in 11 articles [41] and was fatal in eight patients. Fourteen liver failures occurred after IRFA combined with major resection. Six liver failures occurred in cirrhotic patients; three of these failures occurred after IRFA alone. Two liver failures were subsequent to portal thrombosis.

19.1.5. Vascular complications

Different types of vascular complication were described in a total of 22 patients. Associated procedures such as cholecystectomy or colectomy induced six haemorrhages, two of which were fatal and one required re-operation after prophylactic cholecystectomy. Three haemorrhages from the needle track were treated during surgery by compression. In three cirrhotic patients, haemorrhage occurred in the necrosis induced by the IRFA; one patient died as a result. [25]

Treatment of two juxta-portal lesions induced haemorrhages from arterial injuries. 25, 26 In one patient, an arterio-portal fistula appeared in an area of necrosis 6 weeks later and was treated by a transfemoral embolization. [18] Similarly, a false aneurysm occurred in one patient 6 months after IRFA and led to a haemorrhage. Five portal thromboses were reported, [19, 25, 34] four of which were complete and fatal. Three of these occurred in cirrhotic patients treated with Pringle vascular occlusion.

19.1.6. Skin burns

Eight dispersive pad skin burns were reported in four articles. Skin burns occurred when RFA ran for >30 min on high power and within large and multiple skin pads. One skin burn occurred in a patient with bilateral hip prostheses. 30 One third-degree skin burn required surgical treatment. [38]

19.1.7. Visceral damage

Two instances of thermal gastric damage [41] and one of acute cholecystitis near the gallbladder were observed after IRFA during surgery and were treated immediately.

19.1.8. Comparison with hepatectomy

The morbidity of hepatectomy depends on the extent and complexity of the hepatic resection. Intraoperative RFA as a standalone treatment is indicated for unresectable tumours in patients in whom major hepatectomy would leave a low level of functional hepatic reserve. Mortality and morbidity rates in major hepatic resection are 0–5% and 20–50%, respectively. [45] Rates of liver failure after major hepatectomy preceded by portal embolization are 4–10% vs. 2.6% after IRFA [46, 47] combined with hepatic resection. There is reported mortality of 2.3% and morbidity of 19.8% in patients treated by resection and combined IRFA, and estimates their results to be comparable with those of resection alone. [31] Morbidity rates after major hepatic

resection and IRFA combined with hepatic resection are comparable, even if IRFA is indicated in tumours unresectable by hepatectomy alone. [48]

The past 10 years have represented a period of learning for surgeons who deal with liver metastases with the aim of treating more patients by combining IRFA with resection. The benefit: risk ratio is now well known and surgeons have access to the knowledge they need to make more informed choices about whether to resect, ablate or renounce treatment on a lesion-by-lesion basis. Surgeons who are skilled in intraoperative ultrasound diagnosis and guidance are now not only able to choose whether or not to perform surgery, but are also able to perform IRFA and do not need to involve a radiologist. Specific complications related to IRFA are rare, especially if the lesion is <35 mm in diameter and is located far from a main biliary duct and no additional septic procedures are used. The surgeon can decide to ablate a lesion in a more difficult situation, but this carries greater risk. Combining resection with IRFA leads to higher morbidity, especially in difficult patients with numerous bilateral lesions, but this may be necessary to achieve R0 (microscopically negative) resection margins.

20. Hepatic re-resection in case of recurrent tumor

The resection of hepatic metastases of colorectal carcinoma is followed by tumor recurrence in up to two thirds of cases, and about half of these recurrences are found in the liver [12, 23, 27, 28]. In general, whenever there is a chance of a curative resection, resection should be considered for recurrent tumors as well. The operative morbidity and mortality of hepatic re-resection in experienced centers are no greater than those of primary resection. In a study on second operations in 94 patients with recurrent hepatic metastases of colorectal carcinoma, 38% of the patients were alive 5 years after surgery [12]. Thus, whenever complete resection of the tumor is possible, surgery is indicated even for patients with recurrent hepatic metastases.

21. Conclusion

The results of surgical treatment of metastatic colorectal carcinoma have improved markedly in recent years. The reasons for this include developments in medical imaging, in perioperative and surgical treatment, and in chemotherapy, with the introduction of potent new protocols. Clinicopathological factors such as tumor size, number of tumor nodules, and extrahepatic tumor manifestations no longer contraindicate hepatic resection. The main consideration at present is the need to achieve a complete R0 resection. Accompanying chemotherapy should be considered, especially for patients with an unfavorable risk profile. Neoadjuvant chemotherapy is reserved for patients with marginally resectable metastases. The resectability or nonresectability of hepatic metastases is a matter that must be evaluated by a surgeon who is experienced in the treatment of hepatic metastases. Hepatic resection of colorectal liver metastases after downsizing by chemotherapy provides the only chance of long term survival

for patients with initially unresectable colorectal liver metastases. Additional surgical techniques can be combined to chemotherapy to further improve resectability. The only absolute contraindication for resection is the inability to completely resect all metastases, avoiding postoperative liver failure by leaving enough functional liver parenchyma. The presence of poor prognostic factors no longer limits the indications for resection. Neoadjuvant treatment with chemotherapeutic agents such as irinotecan and oxaliplatin, hepatic artery infusion combined with systemic therapy and biologic agents (bevacizumab, cetuximab) play an important role in increasing the number of patients eligible to secondary resection. However, with the progressive use of neoadjuvant chemotherapy further studies are necessary to answer questions such as the risk: benefit ratio in maximizing response rates versus vascular changes in the liver (current opinion still divided concerning their importance). These questions remain challenging and should not be underestimated. The perfecting of surgical techniques together with safer procedures, as well as the improvement in chemotherapy regimens have allowed doctors to offer patients with liver metastasis the possibility of curative treatment or longterm survival. Factors that were previously considered contraindications for the surgery, such as number of metastases, synchronous metastases and even the presence of extrahepatic disease, must be considered only as prognostic factors and must not prevent the patient from having the opportunity of being treated.

Author details

Nikola Kolev¹, Valentin Ignatov¹, Anton Tonev¹, Tanya Kirilova², Georgi Ivanov¹, Alexander Zlatarov¹ and Krassimir Ivanov¹

1 Department of General and Operative Surgery, University Hospital "St. Marina", Varna, Bulgaria

2 Department of Gastroenterology, University Hospital "St. Marina", Varna, Bulgaria

References

- [1] Jemal A, Murray T, Ward E, Hao Y, Xu J, Murray T, et al. Cancer statistics, 2005. *CA Cancer J Clin.* 2005;55:10-30.
- [2] International Agency for research on cancer: GLOBOCAN 2002 data. [Accessed 2006 Nov 16]. Available from: [http:// www-dep.iarc.fr](http://www-dep.iarc.fr)
- [3] Stangl R, Altendorf-Hofmann A, Charnley RM, Scheele J. Factors influencing the natural history of colorectal liver metastases. *Lancet.* 1994;343:1405-10.

- [4] Mentha G, Majno P, Terraz S, Rubbia-Brandt L, Gervaz P, Andres A, et al. Treatment strategies for the management of advanced colorectal liver metastases detected synchronously with the primary tumour. *EJSO*. 2007;33:76-83.
- [5] Livermetsurvey. International registry of liver metastases of colorectal cancer. [Accessed 2010 Mar].
- [6] Choti M, Sitzmann J, Tiburi M, Sumetchotimetha W, Rangsin R, Schulick RD, et al. Trends in long term survival following liver resection for hepatic colorectal metastases. *Ann Surg*. 2002;235:759-66.
- [7] Abdalla EK, Vauthey JN, Ellis LM, Ellis V, Pollock R, Broglio KR, et al. Recurrence and outcomes following hepatic resection, radiofrequency ablation, and combined resection/ablation for colorectal liver metastases. *Ann Surg*. 2004;239:818-27.
- [8] Fong Y, Fortner J, Sun RL, Brennan MF, Blumgart LH. Clinical score for predicting recurrence after hepatic resection for metastatic colorectal cancer: analysis of 1001 consecutive cases. *Ann Surg*. 1999;230:309-18.
- [9] Nordlinger B, Jaeck D, editors. Traitment de metastases hépatiques as cancers colorectaus. Paris: Springer-Verlag; 1992.
- [10] Gayowski TJ, Iwatsuki S, Madariaga JR, Selby R, Todo S, Irish W, et al. Experience in hepatic resection of colorectal cancer – analysis of clinical and pathological risk factors. *Surgery*. 1994;116:703-71.
- [11] Minagawa M, Maltuuchi M, Torzilli G, Takayama T, Kawasaki S, Kosuge T, et al. Extension of the frontiers metastases from colorectal cancer: Long-term results. *Ann Surg*. 2000;231: 487-99.
- [12] Ercolani G, Grazi GL, Ravaioli M, Cescon M, Gardini A, Varotti G, et al. Liver resection for multiple colorectal metastases: influence of parenchymal involvement and total tumor volume versus number or location on long term survival. *Arch Surg*. 2002;137:1187-92.
- [13] Scheele J, Stangl R, Altendorf-Hofmann A. Hepatic metastases from colorectal carcinoma: impact of surgical resection on the natural history. *Br J Surg*. 1990;77:1241-6.
- [14] Adam R, Delvart V, Pascal G, Valeanu A, Castaing D, Azoulay D, et al. Rescue surgery for unresectable colorectal liver metastases downstaged by chemotherapy: a model to predict longterm survival. *Ann Surg*. 2004;240:644-58.
- [15] Rodgers M, Mccall J. Surgery for colorectal liver metastases with hepatic lymph node involvement: A Systematic review. *Br J Surg*. 2000;87:1142-55.
- [16] Adam R, De Haas RJ, Wicherts DA, Aloia TA, Delvart V, Azoulay D, et al. Is hepatic resection justified after chemotherapy in patients with colorectal liver metastases and lymph node involvement? *J Clin Oncol*. 2008;26:3672-80.

- [17] Pfannschmidt J, Dienemann H, Hoffmann H. Surgical resection of pulmonary metastases from colorectal cancer: a systematic review of published series. *Ann Thorac Surg.* 2007;84:324-38.
- [18] Elias D, Liberale G, Vernerey D, Pocard M, Ducreux M, Boige V, et al. Hepatic and extrahepatic colorectal metastases: when resectable, their localization does not matter, but their total number has a prognostic effect. *Ann Surg Oncol.* 2005;12: 900-9.
- [19] Adam R, Haas RJ, Wicherts D, et al. Concomitant extrahepatic in patients with colorectal liver metastases: when is there a place for surgery? *Ann Surg.* 2011. In press.
- [20] Adam R, Pascal G, Azoulay D, Tanaka K, Castaing D, Bismuth H. Liver resection for colorectal metastases: the third hepatectomy. *Ann Surg.* 2003;238:871-83.
- [21] Tanaka K, Adam R, Shimada H, Azoulay D, Lévi F, Bismuth H. Role of neoadjuvant chemotherapy in the treatment of multiple colorectal metastases to the liver. *Br J Surg.* 2003;90:963-9.
- [22] Mitry E, Fields AL, Bleiberg H, Labianca R, Portier G, Tu D, et al. Adjuvant chemotherapy after potentially curative resection of metastases from colorectal cancer: A pooled analysis of two randomized trials. *J Clin Oncol.* 2008;26:4906-11.
- [23] Nordlinger B, Sorbye H, Glimelius B, Poston GJ, Schlag PM, Rougier P, et al. Perioperative chemotherapy with FOLFOX4 and surgery versus surgery alone for resectable liver metastases from colorectal cancer (EORTC Intergroup trial 40983): a randomised controlled trial. *Lancet.* 2008;371: 1007-16.
- [24] Parks R, Gonen M, Kemeny N, Jarnagin W, D'Angelica M, DeMatteo R, et al. Adjuvant chemotherapy improves survival after resection of hepatic colorectal metastases: analysis of data from two continents. *J Am Coll Surg.* 2007;204:753-61.
- [25] Gruenberger B, Scheithauer W, Punzengruber R, Zielinski C, Tamandl D, Gruenberger T. Importance of response to neoadjuvant chemotherapy in potentially curable colorectal cancer metastases. *BMC Cancer.* 2008;8:120.
- [26] Kemeny MM, Adak S, Gray B, Macdonald JS, Smith T, Lipsitz S, et al. Combined-modality treatment for resectable metastatic colorectal carcinoma to the liver: Surgical resection of hepatic metastases in combination with continuous infusion of chemotherapeutic-An Intergroup Study. *J Clin Oncol.* 2002;20:1499-505.
- [27] Thirion P, Wolmark N, Haddad E, Buyse M, Piedbois P. Survival impact of chemotherapy in patients with colorectal metastases confined to the liver: A reanalysis of 1458 non-operable patients randomized in 22 trials and 4 meta-analysis. *Meta-Analysis Group in cancer. Ann Oncol.* 1999;10:1317-20.
- [28] Hobday TJ, Kugler JW, Mahoney MR, Sargent DJ, Sloan JA, Fitch TR, et al. Long-term survivors of metastatic colorectal cancer treated with chemotherapy only: A North central Cancer Treatment group review. *J Clin Oncol.* 2002;20: 4574-80.

- [29] Giacchetti S, Itzhaki M, Gruia G, Adam R, Zidani R, Kunstlinger F, et al. Long-term survival of patient with unresectable colorectal cancer liver metastases following infusional chemotherapy with 5-fluorouracil, leucovorin, oxaliplatin and surgery. *Ann Oncol.* 1999;10:663-9.
- [30] Folprecht G, Grothey A, Alberts S, Raab HR, Kuhne CH. Neoadjuvant treatment of unresectable colorectal liver metastases: Correlation between tumor response and resection rates. *Ann Oncol.* 2005;16:1311-9.
- [31] Ychou M, Viret F, Kramar A, Desseigne F, Mitry E, Guimbaud R, et al. Tritherapy with fluorouracil/leucovorin, irinotecan and oxaliplatin (FOLFIRINOX): a phase II study in colorectal cancer patients with non-resectable liver metastases. *Cancer Chemother Pharmacol.* 2008;62:195-201.
- [32] Van Cutsem E, Kihne CH, Hitre E, Zaluski J, Chang Chien CR, Makhson A, et al. Cetuximab and chemotherapy as initial treatment for metastatic colorectal cancer. *N Engl J Med.* 2009;360:1408-17.
- [33] Bokemeyer C, Bondarenko I, Makhson A, Hartmann JT, Aparicio J, De Braud F, et al. Fluorouracil, leucovorin, and oxaliplatin with and without cetuximab in the first-line treatment of metastatic colorectal cancer. *J Clin Oncol.* 2009;27:663-71.
- [34] Ocvirk J, Brodowicz T, Wrba F, Ciuleanu TE, Kurteva G, et al. Cetuximab plus FOLF-FOX6 or FOLFIRI in metastatic colorectal cancer: CECOG trial. *World J Gastroenterol.* 2010;16:3133-43.
- [35] Folprecht G, Gruenberger T, Bechstein WO, Raab HR, Lordick F, Hartmann JT, et al. Tumour response and secondary respectability of colorectal liver metastases following neoadjuvant chemotherapy with cetuximab: the CELIM randomized phase 2 trial. *The Lancet Oncol.* 2010;11:38-47.
- [36] Adam R, Aloia T, Levi F, Wicherts DA, De Haas RJ, Paule B, et al. Hepatic resection after rescue cetuximab treatment for colorectal liver metastases previously refractory to conventional systemic therapy. *J Clin Oncol.* 2007;25: 4593-602.
- [37] De Baere T, Roche A, Elias D, Lasser P, Lagrange C, Bousson V. Preoperative portal vein embolization for extension of hepatectomy indications. *Hepatology.* 1996;200:559-63.
- [38] Madoff DC, Abdalla EK, Gupta S, Wu TT, Morris JS, Denys A, et al. Transhepatic ipsilateral rightportal vein embolization extended to segment IV: improving hypertrophy and resection outcomes with spherical particles and coils. *J Vasc Interv Radiol.* 2005;16:215-25.
- [39] Abdalla EK, Barnett CC, Doherty D, Curley SA, Vauthey JN. Extended hepatectomy in patients with hepatobiliary malignancies with and without preoperative portal vein embolization. *Arch Surg.* 2002;137:675-80.

- [40] Razafindratsira T, Isambert M, Evrard S Complications of intraoperative radiofrequency ablation of liver metastases. *HPB (Oxford)*. 2011 Jan;13 (1):15-23.
- [41] Vauthey JN, Chaoui A, Do KA, Bilimoria MM, Fenstermacher MJ, Charnsangavej C, et al. Standardized measurement of the future liver remnant prior to extended liver resection: methodology and clinical associations. *Surgery*. 2000;127: 512-9.
- [42] Azoulay D, Castaing D, Smail A, Adam R, Cailliez V, Laurent A, et al. Resection of nonresectable liver metastases from colorectal cancer after percutaneous portal vein embolization. *Ann Surg*. 2000;231:480-6.
- [43] Madoff DC, Abdalla EK, Vauthey JN. Portal vein embolization in preparation for major hepatic resection: evolution of a new standard of care. *J Vasc Interv Radiol*. 2005;16:779-90.
- [44] Elias D, De Baere T, Roche A, Ducreux M, Leclere J, Lasser P. During liver regeneration following right portal embolization the growth rate of liver metastases is more rapid than that of the liver parenchyma. *Br J Surg*. 1999;86:784-8.
- [45] Kokudo N, Tada K, Seki M, Ohta H, Azekura K, Ueno M, et al. Proliferative activity of intrahepatic colorectal metastases after preoperative hemihepatic portal vein embolization. *Hepatology*. 2001;34:267-72.
- [46] Elias D, Santoro R, Ouellet JF, Osmak L, De Baere T, Roche A. Simultaneous percutaneous right portal vein embolization and left liver tumour radiofrequency ablation prior to a major right hepatic resection for bilateral colorectal metastases. *Hepatogastroenterology*. 2004;51:1788-91.
- [47] Terraz S, Constantin C, Majno P, Spahr L, Mentha G, Becker CD. Image-guided multipolar radiofrequency ablation of liver tumours: initial clinical results. *Eur Radiol*. 2007;17:2253-61.
- [48] Lencioni R, Cioni D, Crocetti L, Franchini C, Pina CD, Lera J, et al. Early-stage hepatocellular carcinoma in patients with cirrhosis: long-term results of percutaneous image-guided radiofrequency ablation. *Radiology*. 2005;234:961-7.
- [49] Berber E, Pelley R, Siperstein AE. Predictors of survival after radiofrequency thermal ablation of colorectal cancer metastases to the liver: a prospective study. *J Clin Oncol*. 2005;23:1358-64.
- [50] Solbiati L, Livraghi T, Goldberg SN, Ierace T, Meloni F, Dellanoce M, et al. Percutaneous radiofrequency ablation of hepatic metastases from colorectal cancer: long-term results in 117 patients. *Radiology*. 2001;221:159-66.
- [51] De Baere T, Bessoud B, Dromain C, Ducreux M, Boige V, Lassau N, et al. Percutaneous radiofrequency ablation of hepatic tumors during temporary venous occlusion. *Am J Roentgenol*. 2002;178:53-9.

- [52] Elias D, Sideris L, Pocard M, Dromain C, De Baere T. Intraductal cooling of the main bile ducts during radiofrequency ablation prevents biliary stenosis. *J Am Coll Surg.* 2004;198:717-21.
- [53] Mulier S, Ni Y, Jamart J, Ruers T, Marchal G, Michel L. Local recurrence after hepatic radiofrequency coagulation. Multivariate meta-analysis and review of contributing factors. *Ann Surg.* 2005;242:158-71.
- [54] Aloia TA, Vauthey JN, Loyer EM, Ribero D, Pawlik TM, Wei SH, et al. Solitary colorectal liver metastases: resection determines outcome. *Arch Surg.* 2006;141:460-7.
- [55] Wicherts DA, Miller R, de Haas RJ, Bitsakou G, Vibert E, Veihan LA et al. Long-term results of two-stage hepatectomy for irresectable colorectal cancer liver metastases. *Ann Surg.* 2008;248:994-1005.
- [56] Martin R, Paty P, Fong Y, Grace A, Cohen A, De Matteo R et al. Simultaneous liver and colorectal resections are safe for synchronous colorectal liver metastasis. *J Am Coll Surg.* 2003;197:233-41; discussion 41-2.
- [57] Reddy SK, Pawlik TM, Zorzi D, Gleisner AL, Ribeiro D, Assumpção L et al. Simultaneous resections of colorectal cancer and synchronous liver metastases: a multi-institutional analysis. *Ann Surg Oncol.* 2007;14:3481-91.
- [58] Brouquet A, Mortenson MM, Vauthey JN, Abdalla EK. Surgical strategies for synchronous colorectal liver metastases in 156 consecutive patients: classic, combined or reverse strategy? *J Am Coll Surg.* 2010;210:934-41.
- [59] Mentha G, Majno PE, Andres A, Rubbia-Brandt L, Morel P, Roth AD. Neoadjuvant chemotherapy and resection of advanced synchronous liver metastases before treatment of the colorectal primary. *Br J Surg.* 2006;93:872-8.
- [60] Poultsides GA, Servais EL, Saltz LB, Patil S, Kameny NE, Guillem JG et al. Outcome of primary tumor in patients with synchronous stage IV colorectal cancer receiving combination chemotherapy without surgery as initial treatment. *J Clin Oncol.* 2009;27:3379-84.
- [61] Tebbutt NC, Norman AR, Cunningham D, Andreyev J. Intestinal complications after chemotherapy for patients with unresected primary colorectal cancer and synchronous metastases. *Gut.* 2003;52:568-73.
- [62] Adam R, Pascal G, Castaing D, Azoulay D, Delvart V, Paule B et al. Tumor progression while on chemotherapy: a contraindication to liver resection for multiple colorectal metastases? *Ann Surg.* 2004;240:1052-61; discussion 61-4.
- [63] Herman P, Machado MAC, Diniz AL, Coimbra FJF, Sallum RA, Montagnini AL. Surgical treatment of colorectal cancer hepatic metastases; experience of A. C. Camargo Cancer Hospital - São Paulo. *Appl Cancer Res.* 2006;26:88-93.

