

We are IntechOpen, the world's leading publisher of Open Access books Built by scientists, for scientists

4,800

Open access books available

122,000

International authors and editors

135M

Downloads

Our authors are among the

154

Countries delivered to

TOP 1%

most cited scientists

12.2%

Contributors from top 500 universities



WEB OF SCIENCE™

Selection of our books indexed in the Book Citation Index
in Web of Science™ Core Collection (BKCI)

Interested in publishing with us?
Contact book.department@intechopen.com

Numbers displayed above are based on latest data collected.

For more information visit www.intechopen.com



The Holistic Scarless Rejuvenation of the Face

M. B. Des Fernandes

Additional information is available at the end of the chapter

<http://dx.doi.org/10.5772/56203>

1. Introduction

This chapter will concentrate on the holistic approach to harmonious facial rejuvenation by concentrating on the procedures that should accompany every face-lift procedure. In particular I will concentrate on facial rejuvenation in younger adults or those who do not need a full facelift with excision of skin. However, the principles of holistic rejuvenation of the face remain the same.

Rejuvenation of the face is commonly asked for yet, sadly, often not delivered. A Face-lift is not automatically facial rejuvenation. Surgeons who concentrate on surgery only fail to recognize that the very best surgery done without any attention to the skin will deliver only a semblance of rejuvenation and very often a disharmony between structure and surface appearance. For real rejuvenation, one needs to pay attention to the skin in particular and restore *naturally young*, and not just *smoother* skin. As aesthetic surgeons we have to be sure that our patients get the best advice for rejuvenation. This is my experience and when a patient comes for facial surgery I explain that there are three important steps that we should always attend to:

1. First of all we need to make sure that our patients use skin care that can actually rejuvenate skin. The only molecule so far described in the history of skin care that actually rejuvenates skin physiologically as well as in appearance is vitamin A. We do not need to use retinoic acid to get these effects because we can use the pre-cursors of retinoic acid e.g. like retinyl palmitate to get exactly the same end-result without the irritation normally encountered when using retinoic acid. However, there are very few products available that contain effective quantities of vitamin A. One way to ensure that you are recommending a product with sufficient vitamin A is to choose a product that presents vitamin A in gradually increasing doses till the maximum dose is reached. We have at the same time to remember that skin care alone cannot make photodamaged skin return to younger skin. This is where we need to add regeneration of youthful skin through skin needling.

2. The second step for the most convincing, scarless rejuvenation of the facial skin is Collagen Induction Therapy (CIT) by skin needling to generate platelet-derived growth factors and regenerate skin (P-CIT). [1] This is the only process yet described in the medical literature that causes regeneration of skin and the normal latticework matrix.
3. Finally, a simple face-lift without attention to the mid-face will not produce a convincingly younger face. The mid-face is the key to a youthful appearance because it not only addresses the naso-labial folds, but also rejuvenates the lower eyelids and lifts up the corner of the mouth. In fact the mid-face-lift addresses most of the concerns of many people seeking a face-lift. The ideal situation is where the intervention occurs at an earlier rather than a later time and the facial tissues can be lifted by sutures or threads and repositioned in their youthful position. [2]

2. Restoring the skin surface through scientific skin care

Vitamin A is a normal component found in our skin and is absolutely essential for healthy skin. [3] However, vitamin A is rapidly destroyed by exposure to light because it is in fact a natural sunscreen and absorbs UVA and UVB rays [4]. As a result our skin develops a chronic, progressive and unrelenting deficiency of vitamin A that manifests as pigmented blotches, wrinkles, thin skin, and pre-cancerous lesions that eventually develop into skin cancer. This is exactly the sort of person who may present to you for a face-lift. Fortunately, by restoring normal levels of vitamin A we can reverse these effects and create healthier skin. The earlier the patient starts to use Vitamin A topically, the better. Do not waste time thinking about Alpha hydroxyacids except to enhance the effects of vitamin A products. Only vitamin A has this power to rejuvenate the skin cells and restore more normal function.

While sunscreens can give protection, the safety of the skin depends to a large extent on the quantity of vitamin A and other antioxidants in the skin. Keep the skin rich in Retinyl palmitate (RP) because it is the major form of cellular vitamin A. RP is relatively non-irritating and is converted into every possible metabolite of vitamin A. As a result, when used topically at adequate dosage, it affords us the most acceptable method of vitamin A replacement. Research shows us that Retinyl palmitate plays a role in preventing skin cancer [5] and squamous skin cancer cells have an impaired ability to esterify retinol [6]

Doctors generally think retinoic acid is the only effective vitamin A but retinyl palmitate, as described above, is the major form of vitamin A in the human body and skin [3]. Retinyl esters are de-esterified to retinol, which is then oxidised by alcohol dehydrogenases to retinal and finally retinoic acid [7]. There seems to be a feedback mechanism whereby retinoic acid production is controlled by increasing or decreasing the esterification of retinol to retinyl palmitate. [8] The ratio is tightly controlled with the retinyl esters being 91% and retinol, retinal and retinoic acid each at 3%. By increasing the RP one automatically increases the quantity of retinoic acid that is the molecule that interacts with the DNA.

Guide your patients to healthier, lovelier skin by using products containing vitamin A, especially RP. [9] [10] [11]. Make sure that the creams are adequately supported by

antioxidant vitamins at the same time. Pay particular attention that they contain vitamin C (preferable in its ester form and particularly ascorbyl tetra-isopalmitate. Vitamin C and E are the dominant antioxidant vitamins of the skin [12].

Figure 1 shows the degree of photo-damage often seen in “sun-worshipping” people who may come to you for surgery and Figure 2 shows the changes that can be expected from using topical vitamin A as retinyl palmitate in doses that I recommend. The skin is clearly healthier.

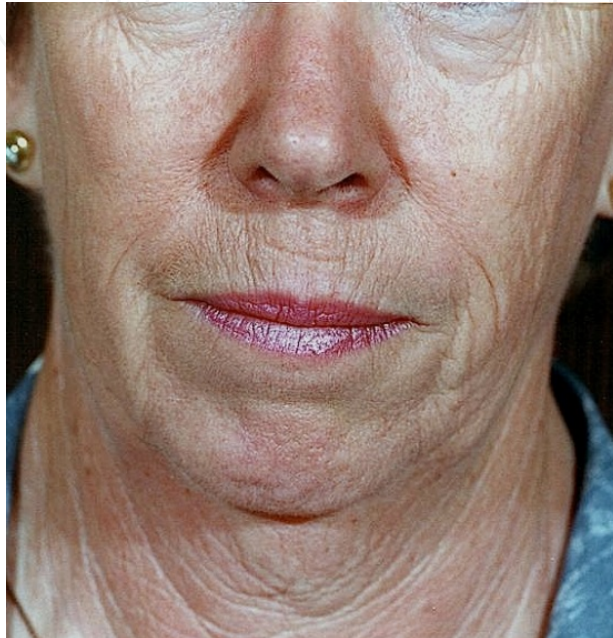

Figure 1. Before using vitamin A, C and antioxidant skin care.

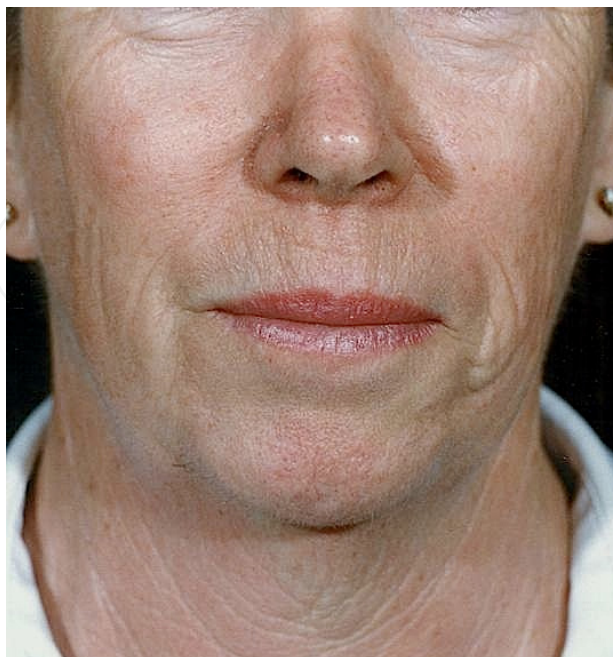


Figure 2. Six months after using vitamin A, C and antioxidant skin care.

Clinical effects of topical retinyl palmitate

- It affects the genes of the stem cells so that the keratinocytes grow and look more normal. It increases the growth of the basal layer (growth layer) of skin cells that causes thickening of the epidermis. Not only does the skin get thicker; it also heals faster because the cells are growing faster.
- Vitamin A improves the horny layer, so it makes the skin more resistant to environmental pollution. [13]
- Melanin in keratinocytes becomes more evenly distributed. [14]
- The production of melanin by melanocytes is generally reduced to the normal constitutional colour of the skin.
- The production of sebum is decreased in oily skin. [15]
- Vitamin A supports and potentiates the Langerhans cells of the skin. [16]
- It affects the fibroblast cells, the most important cell in the dermis, particularly the genes for the production of collagen. Healthier collagen is formed and unhealthy collagen is removed by enzyme activity. [17]
- It increases the secretion of natural moisturising factors by the fibroblast cells of the dermis into the space between the cells, allowing the skin to retain more water with some puffing out of the wrinkles. These natural moisturising factors filter up into the epidermis between the cells. Glycosaminoglycans are some of the chemicals created by the fibroblast to help retain moisture. [18]
- The blood supply to the deeper layers of the skin is improved, which means that nutrition of the skin is improved. The skin also assumes a healthier colour.

Vitamin A should be used twice daily and if used during daylight hours it should be accompanied with anti oxidant vitamins like vitamin C, E and beta carotene, so that it is better protected from ultra violet light. Vitamin A metabolism is strongly tied to vitamin C, and vitamin C is essential for the proper function of vitamin E. The concept of the balanced use of these vitamins as the main way of maintaining skin health is becoming more and more certain with current research work. Our skin is constantly exposed to light and light destroys certain essential chemicals in our skin. We can never escape this fact. A reliable UVA and UVB sunscreen with sun protection factor SPF 15 – 20 should be used at the same time in preference to high SPF products over 30. Vitamin A should also be replaced every evening as a topical application to the skin to try and address the loss of vitamin A from being in light. Because we cannot prevent the damage to the vitamin A in the skin, it is essential to replace the vitamin A each day so that we minimise the signs of photoaging that are really also the signs of accumulative vitamin A and antioxidant deficiency of the skin.

Recommended skin care regime:

Select a skin care regime that offers vitamin A as retinyl palmitate especially, or retinyl acetate, retinol or even retinaldehyde. I prefer a heavy bias towards retinyl palmitate and the vitamin A should be offered in a series of creams that increase from low levels right up to 50,000 i.u. per g., which is the maximum permitted dose for vitamin A in cosmetics in the European Union. You cannot start at high doses because that would induce a retinoid

reaction that would dissuade the patient from using the product. Start on the lowest and even that levels will still give excellent changes [19]. Then for maximum results gradually build up to the strongest permitted concentration. The simultaneous use of stable versions of vitamin C and other antioxidants is essential. Peptides such as Matrixyl are particularly valuable in giving tighter smoother skin. The patient ideally should start this skin care regime before surgery and continue forever afterwards to maintain the best, healthiest skin.

The effects of topical vitamin A and C and antioxidants and even peptides can be enhanced by using a device that punctures only the stratum corneum¹ Even greater tightening of the skin may be obtained as witnessed by Figures 3 and 4 which show skin before being treated with vitamin A and antioxidants² and the Skin-Roller and then the appearance after one year. This demonstrates tightening that is normally only achieved after heavy peels or intensive treatments with fractional laser or radio-heating devices. However, this was done by the patient herself with a simple device that caused absolutely no pain or discomfort.

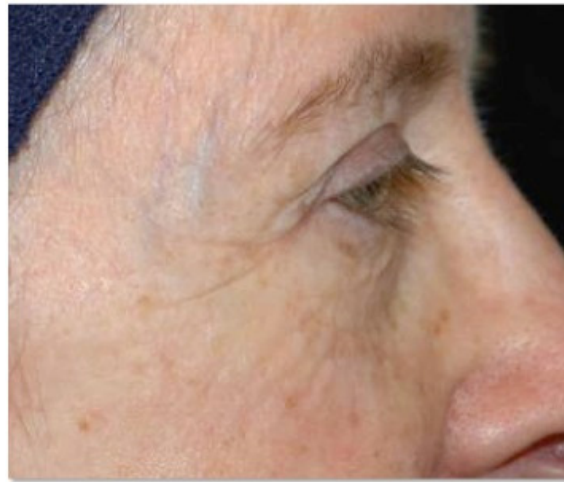


Figure 3. photo-damaged skin before starting vitamins A, C and antioxidants.

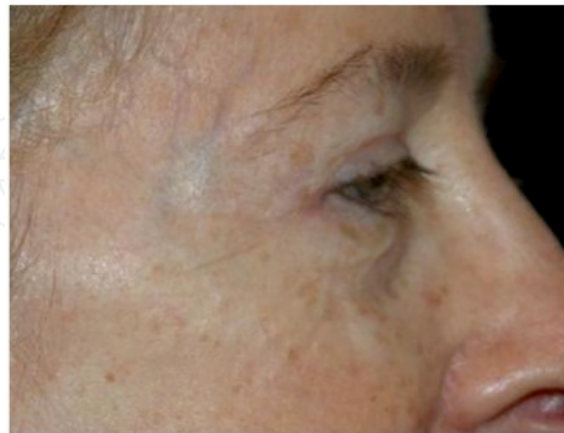

Figure 4. One year later with no surgery peeling or anything else except daily skin care enhanced by using the Cosmetic Skin Roller

¹ The Environ Cosmetic Skin-Roller

² Environ Skin Care

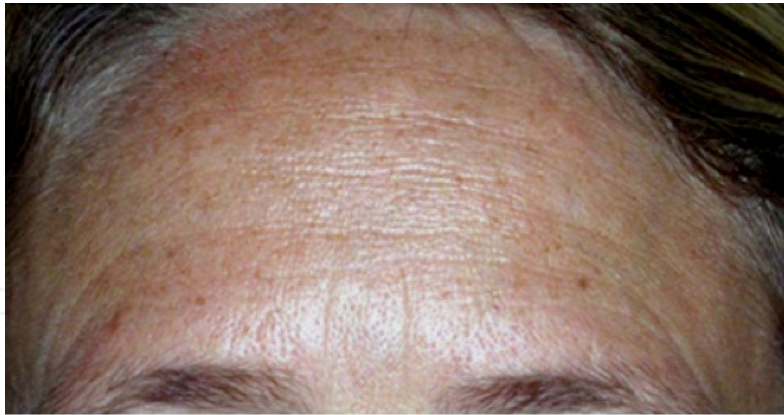

Figure 5. Lower face before needling with 3 mm Roll-CIT

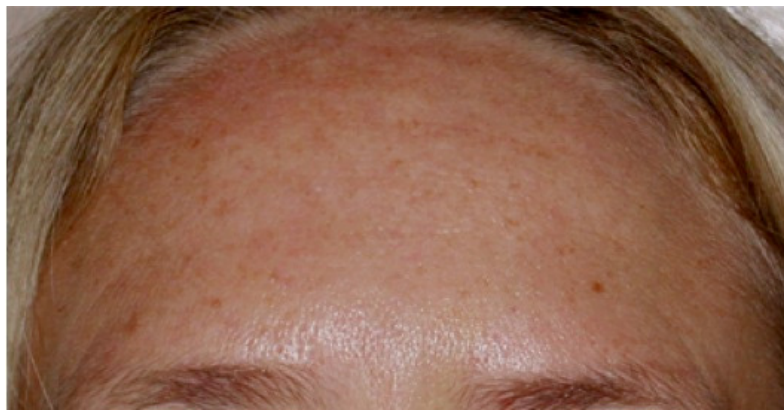

Figure 6. After Roll-CIT and skin care.

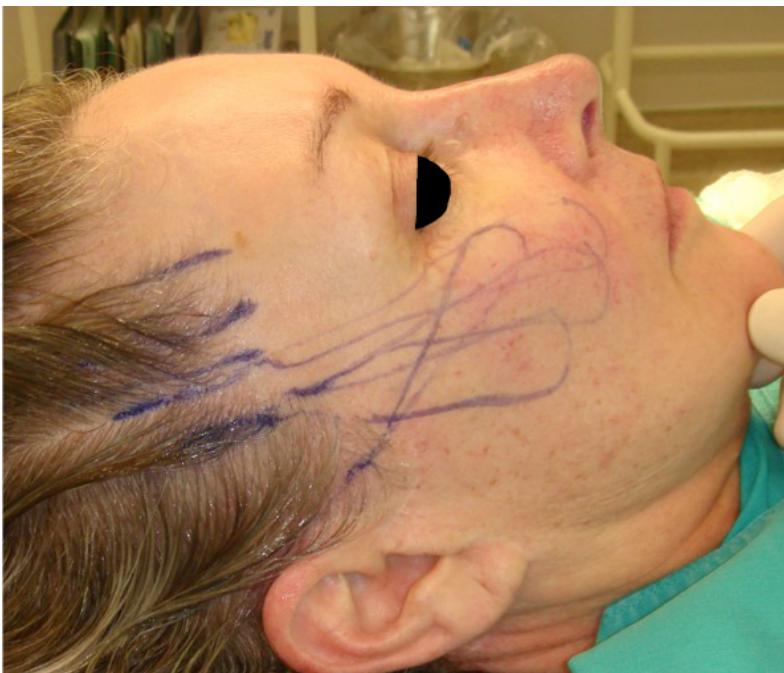

Figure 7. Markings for suture loops of the cheeks. In this case a number of loops have been marked in case they will be needed to get full tightening of the facial tissues. Generally by adding the Silhouette sutures, one can avoid adding extra loops.

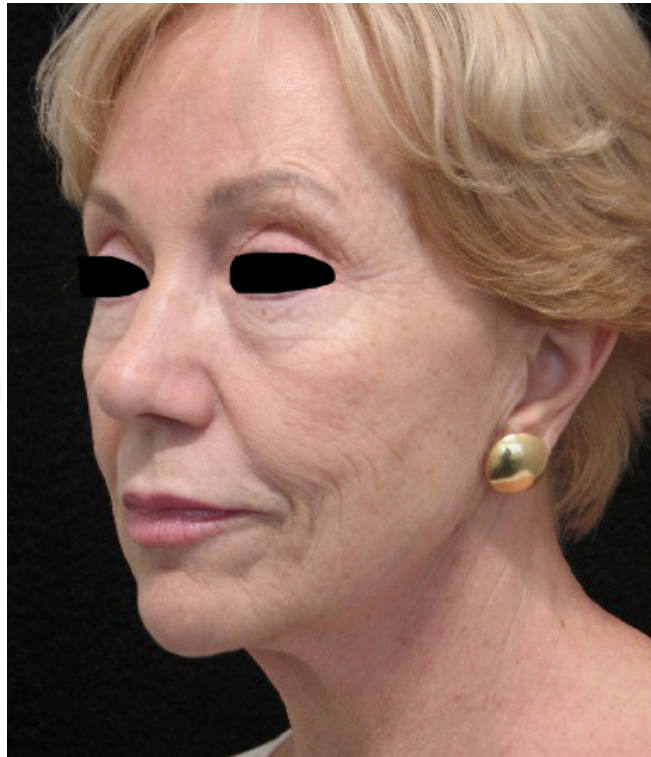

Figure 8. This patient has had a face-lift but was not given a mid-face-lift and is unhappy with the result. One can understand this because the corners of her mouth turn down and she still has a heavy naso-labial fold.

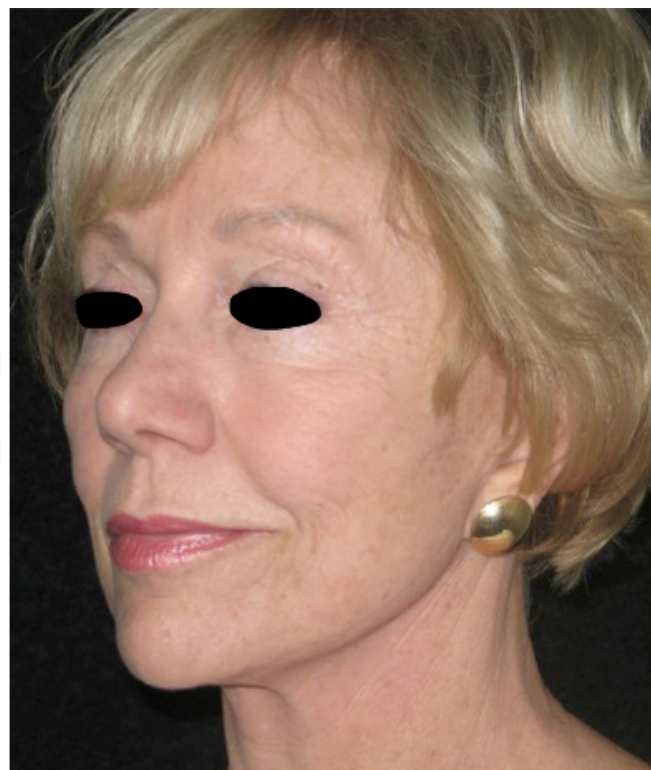

Figure 9. One year after a scarless suture suspension mid-facelift only and skin care with vitamins A, C and antioxidants enhanced by the use of the Cosmetic Skin Roller.

Summary of Skin Care

Vitamin A, particularly as retinyl palmitate, is probably the safest way to protect skin from solar irradiation and may also be used for protracted periods to rejuvenate skin. The ideal treatment would be to apply topical vitamin A to the skin starting at an early age, soon after our first exposure to light, and continuing the daily replenishment of vitamin A into old age. Not only would this maintain healthy young looking skin, but most likely would also protect against cancer.

While skin care can make a big difference and when used under ideal conditions, may hold back the clock of photoaging, most patients present to us with well established damage and skin care needs to be supplemented with a more radical and new technique that actually regenerates younger skin.

3. Regenerating skin through percutaneous Collagen Induction Therapy (p-CIT)

Needling skin is rapidly becoming an established method to rejuvenate skin and refine scars that is competing with ablative and minimally ablative procedures. [1] While the technique may seem new, we actually have centuries of experience of needling skin because tattooing has been practiced in both “civilized” and “primitive” cultures all around the world. Needling stands above all other currently used treatments because it has been shown to be the first method described, as far as we can determine, that conclusively regenerates tissue and restores the natural lattice-distribution of collagen of the dermis. Neither fractionated laser or any other treatments induce regeneration of tissue. To date it is the only described skin treatment that regenerates elastin [20]. It has a wide list of indications and can be used on all ages and all different coloured skins with safety.

To achieve results one has to cause bleeding of the skin because it is the release of platelets that stimulates the regeneration of tissue, and the degree of improvement is directly related to the amount of bleeding. Since I first started needling in 1994 I have been searching how to get the best out of needling.

Here are my guidelines:

I always insist that the patient should use topical vitamin A and C and antioxidants for at least three weeks before the procedure. I persuade my patients to use a device with needles protruding only 0.2 mm as a “rolling massage” system so that only the stratum corneum is punctured and this allows better action of the applied vitamin A etc. See figure 3 and 4

I first started experimenting with needling of the skin in the early 1990”s and by 1996 started the micro-needling of skin in the way that we now do it.

I called the process Collagen Induction Therapy and that term is used around the world and usually abbreviated to CIT. [21] [22]

Then I recommend **The Medical Roll-CIT** that has needles that protrude 1.0 – 1.5 mm so that the needles will penetrate right down into the dermis and rupture the tiny arcade

capillaries in the dermal papillae (rete pegs). Bleeding releases platelets and the platelets in turn release growth factors and particularly TGF-Beta-1, 2 and 3. TGF-beta-1 and 2 soon disappear after needling in direct contrast to the levels seen after a surgical incision. TGF-beta-3 disappears within 24 hours after a surgical incision whereas with needling it is raised for more than two weeks and that seems to be responsible for regeneration [23] of tissue and natural lattice arranged collagen fibres and elastin.

Generally I recommend that the patient should have six sessions of needling done once a week under topical anaesthesia, or if they prefer, then they could have one intensive session done with nerve block and local anaesthetic infiltration. The difference is that with the lighter sessions under topical anaesthesia, they can return to work the very next day whereas after an intensive needling, they will be swollen and bruised for about four days.

I use a unique cream-form of low concentration TCA cream³ that I apply for 20 minutes before and then for only four minutes after the needling session. I believe this gives me better results. I do this to clean the skin and reduce the chance of an infection in people with acne spots. The second reason for doing this is that I deduce that lower pH levels induce the release of growth factors from the keratinocytes.

The technique for needling is simple and has been well described. [21] Basically one keeps rolling until one has made as many holes as one can either physically or when topical anaesthesia is used, until the patient finds it uncomfortable.

By doing skin care and then skin needling I can offer my patients a safe way to get smooth clear healthy younger-looking skin without any risks. The results, according to many observers, outrank the results achieved with fractionated lasers and radio-frequency devices etc.

I have used iontophoresis and sonophoresis of vitamin A and C immediately after the needling treatment to maximize the induction of healthy collagen. Iontophoresis also tends to reduce the swelling of the skin and I also recommend it after all facial surgery. Low Frequency Sonophoresis can be used to enhance penetration of peptides to induce more collagen and elastin production.

In summary, Skin needling

1. Tightens skin laxity and restores normal skin tension in the early stages of ageing. Some patients who are worried about face-lift surgery may be satisfied with simple Percutaneous CIT. The arms, hands, abdomen, thighs, and buttocks can also be treated to give total rejuvenation. In fact this has become the only “anti-ageing full body treatment that we have.
2. Treats fine wrinkles. The interesting feature about skin needling is that it sets up a metabolic mechanism that replaces photo-damaged fibres and re-invigorates cells to regenerate skin. As one would expect, this cannot happen overnight, so it is not

³ Environ Acid Cream Mask

surprising that the regeneration phase is prolonged and there is continual improvement over many months. I believe the best time to judge the final result is about one year after the needling sessions. Our photographs show that the three-month picture is not as good as the six-month picture and the photograph at the end of the year is the best. This is quite different from the commonly used soft lasers etc. where the best time to take the post-intervention picture is within three months after the treatment otherwise the results become more difficult to see.

3. Reduces Acne scarring and it is gratifying to see that previously scarred skin is slowly replaced by normal looking skin. Interestingly enough, histology shows reduction of scarring and restoration of the normal architecture of the skin.
4. Stretch marks respond well to skin needling even when they have become “silvery” after a long time. This however, is not a problem with facial work except in rare cases where there are stretch marks on the neck.
5. Scars are always improved - even if they are white, old scars they can become more skin coloured.
6. Burn scars – both flat and hypertrophic scars can be treated with success and depigmented areas are restored to even normal coloured skin.

Advantages of PCI

1. PCI does not damage the skin. The epidermis remains intact. Histology done at 24 hours, a week, and several months after needling fail to show any signs of damage.
2. Any part of the body may be treated. It is excellent for rejuvenating hands so that younger looking hands can accompany facial rejuvenation.
3. Skin becomes thicker as has been repeatedly demonstrated in histological studies. The epidermis is thickened by vitamin A and antioxidant creams but the restoration of a healthy lattice of collagen and elastin results from skin needling. We have never seen excessive deposition of collagen or any sign of scar collagen after skin needling.
4. The healing phase is short. With milder needling under topical anaesthesia, the patients can normally return to work the next day. Most patients select this form of needling but some people choose intensive needling because of time constraints and even do needling at the same time as the scarless minimally invasive face-lift. That way their healing period from needling over-laps with the healing of the facial lifting.
5. Not as expensive as laser resurfacing.
6. The skin does not become sun sensitive so this can be done any time of the year.
7. Can be done on people who have previously had laser resurfacing, or those with very thin skin. The skin always thickens up so the ugly complication of translucent skin following CO2 laser re-surfacing can be treated. I like these patients to use topical vitamin A for a minimum of three months prior to needling.
8. I have never seen hyper-pigmentation in patients with darker skins e.g. African, Indian, Malaysian, Chinese and Mediterranean skins.
9. Telangiectasia may disappear totally. I think the explanation for this may lie in the fact that the tiny vessels are repeatedly fractured and cannot be easily re-constituted.

10. Does not really have to be done by a doctor but should be done under their supervision. In my office the skin-care therapists and nurses, do the needling and that makes it more affordable for the patient.
11. The technique of Medical Roll-CIT is easy to master and is easily taught by a demo DVD. Medical Focus-CIT is also useful for smaller areas and makes the treatment more affordable.
12. Can even be done with topical anaesthesia.

Disadvantages of PCI:

1. Exposure to blood. If the procedure is done properly there will be exposure to blood so the proper precautions have to be followed
2. While we cannot achieve as intense a deposition of collagen as in laser resurfacing, we can repeat the treatment and get even better results that will last even longer. The scar collagen following laser resurfacing is dense and often reflects white through the skin. These scar collagen fibres, as with any other scar, are resorbed over time. It seems that the normal collagen latticework is not affected in the same way and is only damaged by light.
3. Local anaesthetics limit the area that may be treated and in some cases a general anaesthetic is required e.g. when extensive areas or virtually the whole body is needed.

This is a simple technique and with the right tool it is easy and fast to puncture any skin thoroughly. While one treatment may not give the smoothening seen with ablative laser resurfacing, the epidermis is normalised and if the result is not sufficiently improved it can safely be repeated as often as necessary. The technique can be used on areas that are not suitable for peeling or laser re-surfacing.

Some Pitfalls to avoid.

1. Never use retinoic acid after needling. It irritates the skin and the patient is also less likely to use it properly.
2. Never use Ascorbic acid preparations immediately after needling. Experience has shown me that the ascorbic acid can cause a deep, destructive peel.
3. Never use any strong peeling agents immediately after a peel. The peel will be very much deeper than expected and may cause scars.
4. Needling is painful for about 20 minutes after the operation so, if the procedure has been done with general anaesthesia and without local anaesthetic infiltration, do make sure that the patient is given adequate analgesia before waking up.

Skin Needling induces collagen and elastin induction by employing the body's natural mechanisms that for the first time, as far as we know, produces regeneration of the skin and its matrix. There is no scar formation and the procedure can safely be repeated until the desired effect is achieved. This can be repeated as often as necessary after face-lift surgery.

4. Lifting the most important component of the face with the scarless Mid-face-lift

Younger patients in their thirties and early forties are presenting to the plastic surgeon because they want to

- Reduce the early tear-trough shadows that run obliquely across their cheeks, and
- Early naso-labial grooves that make them looked tired and jaded. This results from the medio-inferior descent of malar fat and Sub Orbicularis Oculi Fat. There is a loss of the “ogee” curve of the face and in order to restore a youthful appearance to the face the surgeon has to reposition these two essential “padding” structures. However, this is not achieved even with the standard full face-lift, which tends to address the lower face and hardly deals with the mid-face. Improvement of the sagging mid-face can only be achieved by re-positioning of the malar and SOOF pads. We cannot approach this area without causing noticeable scars and because we are aesthetic surgeons we have to try and do this with virtually no scars.

I believe the solution is to anchor the tissues of the cheek with loops of non-absorbable sutures, to the temporal fascia on the side of the head and avoid making visible scars. I call this “Suture Suspension Loops” which I started doing in 1994. Alternatively, or in combination one can use specially designed anchoring threads to lift the midface tissues. After using various types of these threads I prefer Silhouette threads [24] either alone or in combination with suture suspension loops.

Suture suspension Loops

By using a number of 4/0 non-absorbable suspensory suture-loops, positioned in the malar fat pads with a spinal needle, one can easily lift the malar and sub-orbicularis oculi fat to create a youthful lower eyelid and ogee curve to the face. The principle is surprisingly simple and will be described in more detail [2]. However, there are many small tips and I found a rather steep “learning curve” in developing this procedure.

These threads are anchored by using 4-6 stab-incisions in a special pattern behind the temporal and side-burn hairline. Then I define the tissues of the malar fat pads and one easily can see that traction on these tissues will eliminate the jowls and improve the corner of the mouth. This creates the classical “ogee” cheek contour [25]. One of the major advantages of this procedure is that the anchoring area can be marked with silicon or even metallic rings and then at a later date, when the tissues start to sag again, they can be tightened up with a small operation in the temporal area without any signs of surgical intervention in the face. This is a unique feature of the technique and stands out as an important difference from virtually all other facelift operations. This novel idea is derived from the anchoring system for the Silhouette suture-lift.

In some cases it is useful to use the described suture loop to lift heavier tissues of the cheek, but in other cases with very little malar fat, I prefer to use “Silhouette” threads with absorbable cones to lift the cheek. These threads are also anchored onto the same anchoring system as the suture loops. I often use both sutures and threads.

Markings

You must mark the patient in the upright position and draw the guidelines that will give you the most appropriate lift. Some people only need moderate lifting of the actual mid-face

whereas many require lifting of the tissues pushing down the corners of the mouth. In these people an extra loop is required.

The first loop should be designed (see figure 7) about 1.5 cms from the naso-labial groove at about the level of the nostril curving on its upper line over the malar arch, infero-laterally to the orbital margin, towards the temple about 2 cms behind the hairline. This point on the temple will be the anchor point. Mark the area where this line reaches the hairline. We will need to make a small stab incision at this point. The inferior part of the loop curves sufficiently to catch a good volume of malar fat and then goes straight up to the temple anchor point. Plan to anchor the Silhouette threads, if they will be used, in the same place.

If there is heaviness of the lower midface, then a similar loop is designed catching tissue more inferiorly but anchored to the same temporal area. If necessary other loops can be added. I prefer often to add another loop in a different horizontal vector just below the lateral canthus as shown in figure 7.

5. Methods and instruments

The following instruments and materials are required:

1. 11 or 15 blade scalpel
2. A 22 (yellow) gauge spinal needle.
3. Sharp pointed fine scissors
4. Fine dissector
5. Toothed "Adson's" forceps.
6. Fine needle-holder to tie the knot.
7. Skin hook to free the skin from the buried thread
8. 4/0 non-absorbable suture. I use a "Provein" polypropylene suture but this could be an elasticised suture as described by Serdev.
9. A Mayo style thick curved suture needle

Surgical technique.

The reason why this technique is called a scarless mid-face-lift is because no incisions or scars are made on the face at all. Only a needle prick is necessary on the facial skin. A stab incision is made on the hairline where the guidelines transect on their way to the temporal anchoring point as shown in figure 7. A slightly larger incision is made at the anchor point so that an anchoring silicon ring marker can be inserted into the depths. These incisions are carefully dissected away from the surrounding tissue so that the skin is totally free.

Push the needle into the skin in the cheek on the most medial part of the upper loop. The needle should be directed perpendicularly into the substance of the cheek fat, then upward towards the orbital margin to catch the greatest volume of cheek fat and finally directed to the upper incision at the hairline. The needle tip is "fished" out with the 'Adson's forceps and then the non-absorbable suture is passed through the barrel of the needle till it emerges from the hub. Then the needle and the contained suture are withdrawn until the needle

reaches the starting point in the depths of the cheek tissue. The needle is then re-directed in the opposite direction and then towards the lower incision at the temporal hairline. The needle is once again “fished” out and the thread inside the needle is pulled out. The needle can be totally withdrawn and the loop of the suture remains and can be checked to make sure that it pulls the tissues upwards without any retraction of skin. If necessary the suture should be replaced if it is not perfect.

WE now have a suture loop that can be anchored on the temporal fascia by taking each end respectively and then threading it through the mayo needle which is passed from the stab incision through the temporal fascia to the anchoring incision. The loop is tightened carefully with only mild over-correction and knotted. Once it has been knotted a silicon ring is used to mark the knot and the loop is tied onto the ring. I use six throws at least. At a later date if the face tissues become a little loose, one can open the incision again, find the silicon ring and tug it further backwards to restore the tightness.

Any other loops are similarly made and connected to the silicon ring.

I believe that it is necessary to change the vector of pull and introduce horizontal traction at the level of the lower orbital margin. For that reason I place a horizontal loop as shown in figure 7 after the malar lift. This restores a natural curve to the malar area.

Then if necessary, the upper silhouette threads are positioned and tied and also attached to the silicon ring. One needs to bury the silicon ring carefully and without any tension. If necessary I use a deep suture to close the skin as well as a skin suture. The stab wounds do not need to be sutured.

Once you have finished the one side you can easily see the difference between the tightened and the untreated side. I have learned to be sure not to have any traction areas or bumps because I have found that small irregularities do not always disappear. Often these irregularities can be pulled out with the skin hook.

I use this easy and safe procedure for younger patients as well as when I do a full face-lift with skin excision. The recovery can be rapid but some people swell rather more than one expects.

This can be a rather painful operation for about 50% cases in the initial 24 hours. The pain does not seem to be related to the tension of the loops. I tend to prescribe a special program of two unrelated analgesics to be taken alternately at 4-hour intervals. I usually use oral diclofenac as the one and a standard analgesic for moderate to severe pain as the other. That keeps the total daily dose down to minimal levels of each of these agents and also gives great pain relief.

PRE-OPERATIVE CARE – notes I give to the patient

1. To reduce bruising, avoid products that contain ASPIRIN, high doses of Vitamin E, high level Omega Oils and Evening Primrose oil for a period of 4 weeks before surgery. Avoid strong alcoholic drinks prior to surgery. I recommend that you use Vitamin C

- 1000 mg daily prior to surgery to reduce bruising and facilitate healing. You may use antioxidants, as usual. The use of bovine colostrum is also recommended.
2. It is also my impression that iontophoresis treatment with vitamin A and C by your beauty therapist may promote rapid healing if it is done a day or two before your operation. This may promote lymphatic drainage.
 3. Do not smoke before or for a few days after surgery. Smoking interferes with the circulation of your skin. For people who cannot stop smoking, I will still operate because there is no threat of skin necrosis.
 4. Wash your hair the night or the morning before surgery. We supply a medicated shampoo.
 5. If you develop any signs of infection, pustules or boils on the face or body before surgery, please notify my office. We will be able to stop the infection rapidly.
 6. Do not wear any make-up to surgery: this includes mascara and nail polish. If you tint, dye or bleach your hair then this should be done about one week prior to surgery.
 7. Wear comfortable loose clothes that you don't have to pull over your head.
 8. I always recommend a skin care with vitamin A and C and antioxidants for as long as possible before the operation and then continue post-operatively indefinitely to keep your skin as healthy and young-looking as possible.
 9. I recommend Medical Roll-CIT skin needling to maximise the rejuvenation of your skin. Generally a course of six treatments should be done prior to surgery but can be done after surgery and repeated as often as necessary to achieve eradication of fine wrinkles.
 10. I have designed a special pillow to remove the distorting pressure on your face that is partially responsible for the aged appearance and the development of the naso-labial grooves and upper lip lines. This pillow will also be essential to help you sleep comfortably after the operation.

POST-OPERATIVELY

1. It is important to remember that even though this delicate, extensive operation has been done under local anaesthetic, you must treat yourself as if it had been done under a general anaesthetic. Do not laugh, talk much, or run about. You have had a very large operation and you must rest properly. The fine suturing of the deep muscle layer and the re-positioning of the facial fat must be protected from rupturing in the first 2 weeks. Failure to take care may compromise the long-term result.
2. If you have had an intensive medical Roll-CIT at the same time then apply your topical skin products as normal.
3. Blood may stain the bandages. You may remove the bandages the morning after surgery. Do not remove any facial support that I have placed on the skin. You can have a shampoo one day after surgery.
4. You will be given a special mask to use post-operatively that will prevent distortion of your facial tissues no matter what pillow you chose to use. This also allows you to sleep on your side immediately after the operation. As soon as I have removed the support tapes, then you should use the "facial support mask" to protect the repair.

5. Do not turn your head from side to side but turn your body as a unit. Keep your chin in an elevated position and your head above shoulder level at all times. I prefer that you do not sleep flat. The head of the bed should be elevated with bricks if necessary so that you may sleep comfortably and still have your head elevated.
6. Use the special Pillow to support the face without placing stress on the repair while sleeping.
7. If eyelid surgery has been done at the same time as your face-lift, apply cold eye pads as frequently as possible for the first 48 hours.
8. Swelling and discoloration, and uneven swelling (more on one side than the other) are expected. Bruising and discoloration may rarely persist for 2-3 weeks after surgery. There might also be some lumpiness of the neck or cheeks and this may persist for 6-8 weeks, but it will disappear. In unusual cases it may be necessary to anaesthetise areas and tug on the skin.
9. Swelling may be improved by having Lymphatic drainage by a qualified skin-care therapist. A Facial treatment involving pulsed iontophoresis and low-frequency-sonophoresis is recommended a few days after surgery to reduce swelling and promote a tighter skin.
10. Avoid strenuous activity, getting overheated and sunbathing for 2-3 weeks.
11. Excessive swelling or pain should be reported as soon as it is noted.
12. If you have pets then please be particularly careful not to allow them close to you during the early stages of healing. Their hairs etc. can contaminate your scars and cause an infection.
13. Generally you may use topical vitamin A and C products again within a day or two of the operation.
14. You will have had a major operation so please remember to be gentle with yourself. Many people laugh in the initial phases after the operation and are euphoric but then become depressed as they realize the gravity of the operation, and the local anaesthetic. You should not be surprised to feel a little depressed about a week after the operation. Slowly, as the swelling in your eyes disappears, you will regain your confidence, and feel much happier.
15. You may drive as soon as you feel comfortable and safe to do so.
16. Usually, after a scarless facelift with or without intensive Roll-CIT needling, the patients feel comfortable to be out socially by about 5-7 days.
17. If the forehead has been lifted, you may have bruised eyes for 10-14 days.

6. Conclusion

It is easier to achieve impressive results when one ensures that the patient who wants a face-lift for rejuvenation, first treats their skin with vitamin A and C to get the youngest skin possible and reverse as much of their photoaging as possible. By adding six sessions of Roll-CIT done with topical anaesthesia one can make the skin actively more vital and convincingly younger. Finally, one can do a scarless mid-face-lift or total scarless face-lift with or without upper blepharoplasty or forehead lift and achieve a holistic and truly scarless rejuvenation of the face.

Author details

M. B. Des Fernandes

*Renaissance Surgical Clinic, Cape Town, The Renaissance Body Science Institute, South Africa
Department of Plastic Surgery, Grootte Schuur Hospital, University of Cape Town, Cape Town,
South Africa*

7. References

- [1] Fernandes, D., Percutaneous collagen induction: an alternative to laser resurfacing. *Aesthet Surg J*, 2002. 22(3): p. 307-9.
- [2] Hudson, D.A. and D.B. Fernandes, Caveats for the use of suspension sutures. *Aesthetic plastic surgery*, 2004. 28(3): p. 170-3.
- [3] Randolph, R.K. and M. Simon, All-trans-retinoic acid regulates retinol and 3,4-didehydroretinol metabolism in cultured human epidermal keratinocytes. *J Invest Dermatol*, 1996. 106(1): p. 168-75.
- [4] Antille, C., et al., Vitamin A exerts a photoprotective action in skin by absorbing ultraviolet B radiation. *J Invest Dermatol*, 2003. 121(5): p. 1163-7.
- [5] Moon, T.E., et al., Effect of retinol in preventing squamous cell skin cancer in moderate-risk subjects: a randomized, double-blind, controlled trial. Southwest Skin Cancer Prevention Study Group. *Cancer Epidemiology, Biomarkers and Prevention*, 1997. 6(11): p. 949-56.
- [6] Guo, X. and L.J. Gudas, Metabolism of all-trans-retinol in normal human cell strains and squamous cell carcinoma (SCC) lines from the oral cavity and skin: reduced esterification of retinol in SCC lines. *Cancer Res*, 1998. 58(1): p. 166-76.
- [7] Bailly, J., et al., In vitro metabolism by human skin and fibroblasts of retinol, retinal and retinoic acid. *Exp Dermatol*, 1998. 7(1): p. 27-34.
- [8] Kurlandsky, S.B., et al., Auto-regulation of retinoic acid biosynthesis through regulation of retinol esterification in human keratinocytes. *J Biol Chem*, 1996. 271(26): p. 15346-52.
- [9] Idson, B., Vitamins in cosmetics, an update: 1. Overview and vitamin A. *Drug Cos Ind*, 1990. May, 1990.
- [10] Counts, D.F., F. Skreko, and J. McBee, The effect of retinyl palmitate on skin composition and morphometry *J Soc Cosmet Chem*, 1988. 39(44): p. 235-240.
- [11] Hill, D.L. and C.J. Grubbs, Retinoids and cancer prevention. *Annu Rev Nutr*, 1992. 12: p. 161-81.
- [12] Lin, J.Y., et al., UV photoprotection by combination topical antioxidants vitamin C and vitamin E. *J Am Acad Dermatol*, 2003. 48(6): p. 866-74.
- [13] Goffin, V., et al., Topical retinol and the stratum corneum response to an environmental threat. *Skin Pharmacol*, 1997. 10(2): p. 85-9.
- [14] Ortonne, J.P., Retinoid therapy of pigmentary disorders. *Dermatol Ther*, 2006. 19(5): p. 280-8.
- [15] Shalita, A., The integral role of topical and oral retinoids in the early treatment of acne. *J Eur Acad Dermatol Venereol*, 2001. 15 Suppl 3: p. 43-9.

- [16] Murphy, G.F., S. Katz, and A.M. Kligman, Topical tretinoin replenishes CD1a-positive epidermal Langerhans cells in chronically photodamaged human skin. *J Cutan Pathol*, 1998. 25(1): p. 30-4.
- [17] Varani, J., et al., Vitamin A antagonizes decreased cell growth and elevated collagen-degrading matrix metalloproteinases and stimulates collagen accumulation in naturally aged human skin. *J Invest Dermatol*, 2000. 114(3): p. 480-6.
- [18] Edward, M., Effects of retinoids on glycosaminoglycan synthesis by human skin fibroblasts grown as monolayers and within contracted collagen lattices. *Br J Dermatol*, 1995. 133(2): p. 223-30.
- [19] Watson, R.E., et al., Repair of photoaged dermal matrix by topical application of a cosmetic 'antiageing' product. *Br J Dermatol*, 2008. 158(3): p. 472-7.
- [20] Aust, M.C., et al., Percutaneous collagen induction-Regeneration in place of cicatrization? *J Plast Reconstr Aesthet Surg*.
- [21] Fernandes, D., Minimally invasive percutaneous collagen induction. *Oral Maxillofac Surg Clin North Am*, 2005. 17(1): p. 51-63.
- [22] Fernandes, D. and M. Signorini, Combating photoaging with percutaneous collagen induction. *Clin Dermatol*, 2008. 26(2): p. 192-9.
- [23] Aust, M.C., et al., Percutaneous collagen induction-regeneration in place of cicatrization? *J Plast Reconstr Aesthet Surg*, 2010.
- [24] de Benito, J., et al., Facial rejuvenation and improvement of malar projection using sutures with absorbable cones: surgical technique and case series. *Aesthetic plastic surgery*, 2011. 35(2): p. 248-53.
- [25] Little, J.W., Volumetric perceptions in midfacial aging with altered priorities for rejuvenation. *Plastic and reconstructive surgery*, 2000. 105(1): p. 252-66; discussion 286-9.