

We are IntechOpen, the world's leading publisher of Open Access books Built by scientists, for scientists

4,800

Open access books available

122,000

International authors and editors

135M

Downloads

Our authors are among the

154

Countries delivered to

TOP 1%

most cited scientists

12.2%

Contributors from top 500 universities



WEB OF SCIENCE™

Selection of our books indexed in the Book Citation Index
in Web of Science™ Core Collection (BKCI)

Interested in publishing with us?
Contact book.department@intechopen.com

Numbers displayed above are based on latest data collected.
For more information visit www.intechopen.com



Serdev Technique for Cervicoal Flaccidity and Mandibular Definition Utilizing “Serdev Sutures”

Roberto Tulli

Additional information is available at the end of the chapter

<http://dx.doi.org/10.5772/56202>

1. Introduction

Working with cosmetic surgery, in 25 years I performed several techniques for facial flaccidity beyond the plastic surgery that were presented in congresses and workshops with the goal of minimizing scars leading to a pos-op with less trauma, less edemas, aiming good results in medium average time.

Since I met Doctor Nikolay Serdev in 2001 during the International Congress of Esthetic Medicine in Brazil I became very interested in a new technique for facial flaccidity, developed by him, which lifts and fix mobile fascias to immobile fascias/periosteum, with semi-elastic threads from Bulgaria. That procedure was baptized as “Serdev Sutures”.

After analyzing for years the follow up and results of “Serdev Sutures” procedures for cervical flaccidity, I decided to combine two techniques that would give an excellent retraction of lower SMAS – platysma, sunken skin aspect especially in the submandibular zone improving the jaw line.

I started to perform this technique on selected patients, observing their complaints carefully and thinking if I could give them long lasting results and what anatomic structures I should handle to obtain an harmonical retraction of platysma and surrounding tissues, as dermis and epidermis, always respecting the natural look of the patient.

2. Aim

The aim of modern aesthetic surgery is to create aesthetic forms and proportions for the face and body with the purpose of beautification. In the Aesthetic Cosmetic Surgery rejuvenation which means the same of beautification, by giving the right proportions and angles, typical for young people. In the last decade surgery was renovated, based on the experience of many specialties, increased technology and computer devices.

Lower face lifting techniques to repair the laxity and ptosis of tissues were submitted to invasive procedures with visible scars pre and retro auricular. Recently these techniques were replaced by more simple procedures. One of these is the scarless "Serdev Suture" liftings used in this case to restructure and reposition the "subdermal facial mask". The idea of lower SMAS-platysma face-lift using semi-elastic long term absorbable sutures is to tighten and elevate the lower face and neck, together with facial soft tissues without unnecessary incisions. As we know that soft tissues and skin are attached to the SMAS and platysma, lifting and fixing them in better position, aims repositioning of other facial structures as well. In young patients where no real ptosis exist, heavy faces, not well-expressed cheekbones, mandible arch, bad proportions, angles and sad look should be corrected.

One cannot expect the same results from this technique as from other excision surgery. However the suggestion for carrying out this technique under local anesthesia and that patient leave the clinic at the end of the procedure and rapidly recover their normal life is encouraging.

Results and duration vary from person to person according to each case, state of skin and subcutaneous tissue. There is no unique procedure in aesthetic cosmetic surgery for perfection of beauty. Other mini-invasive techniques as peelings, PRP, liposowing and fillers can be an addition to "Serdev Suture" techniques to keep significant results and satisfaction.

3. Anatomy

With age, loosening of SMAS and facial fascias, atrophy of ligaments due to the gravity, causes sagging of the neck and results in an aged face. Jawing is caused by displacement of the SMAS and aging of the skin. (Figs. 1 and 2)

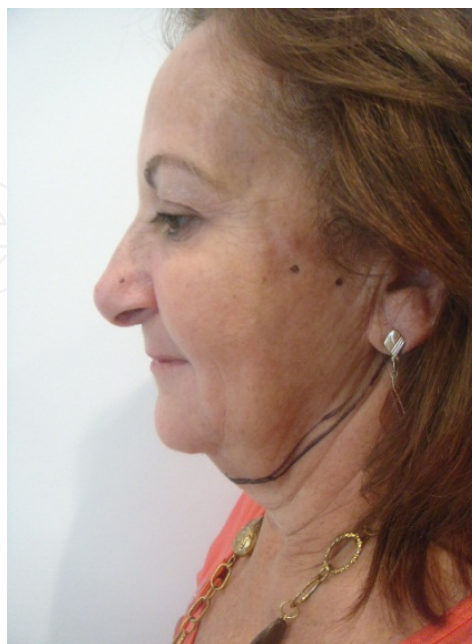

Figure 1. Example of jawing caused by displacement of the SMAS and aging of the skin

subdermal plexus of vessels and superficial to the motor nerves of the facial musculature. It provides a suspensory sheet, which distributes forces of facial expression, mimetic and overlying skin. The idea that suspending this layer leads to a better long-term suspension has become common. (Fig. 4)

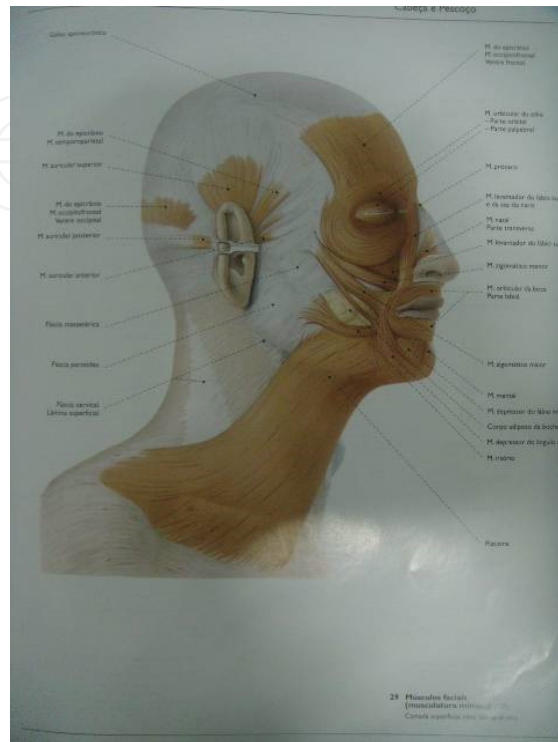


Figure 4. Side view of SMAS

SMAS overlies the parotid gland in mandibular angle and tends to be substantial and easy to handle, because the parotid gland, zygomatic major and minor muscles protect underlying facial nerve branches. With regard to protecting the facial nerve structures, we can accept that Serdev lower SMAS-platysma face-lift “by sutures only” or “with retrolobular incision” is done in a fairly secure area.

4. First technique for cervical flaccidity procedures

The first proposed by Serdev technique was done with a 1cm retro auricular incision, careful dissection of subcutaneous tissue reaching platysma, clamping it and traction it with a mosquito. Its fixation to mastoid periosteum was done with a 3-0 thread. After a time the same technique was performed with Serdev needle and semi elastic thread, without incisions, using only a tiny perforation at the retro auricular zone and some centimeters in front of the sternocleidomastoid muscle. Results depend on the flaccidity status of the skin, fat tissue amount and not too much hanging skin in the submandibular zone.

From this point, desiring to develop a technique that could give patients a good result, despite of high level of flaccidity in the submandibular zone, and aiming also a better definition of jaw line, I increased some alterations on classic techniques.

5. Surgical technique

The skin perforation points as well as fixation to colli fascia, mastoid or occipital periosteum should be planned previously, while the patient is sited or standing up in the surgical room, after photographing the face in standard protocol, the patient is asked to lay down marking the points where the needle will pass with a special surgical pen. The main points are marked over mastoid, 4cm from the sternocleidomastoid muscle, over the platysmal bands if they are visible and at the same places on the other side. Lidocain 2% with adrenaline is used to numb the region. (Fig. 5)

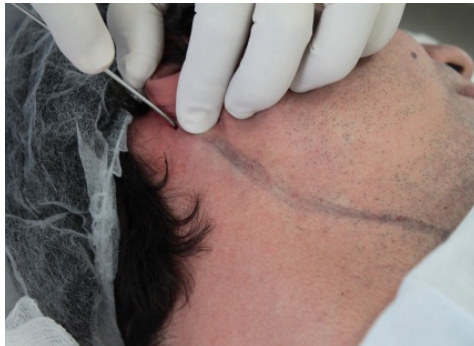

Figure 5. Administering the Lidocain 2% in order to numb the region

I start with a tiny incision using a scalpel blade number 11 from where a Serdev needle number 60 is introduced to reach the mastoid periosteum. Having a good tangential fixation to mastoid I move the needle towards subcutaneous tissue superficial to sternocleidomastoid muscle. Attention should be paid to superficial vessels as well as to the internal jugular vein and artery, passing above the sternocleidomastoid muscle avoiding any nerve and vessel damage (Fig. 6).

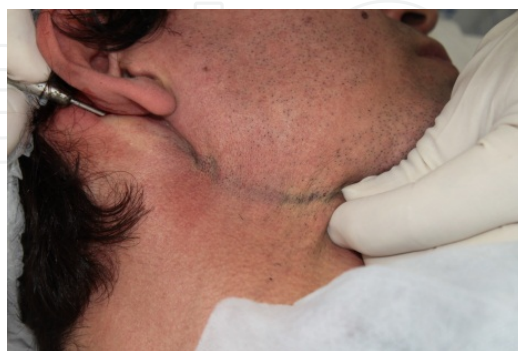

Figure 6. Incision using scalpel blade number 11

With a twisting movement I continue moving, pointing the tip of the needle down to reach platysma that is punctured in a zigzag way and getting out through the skin marks in a 90 degree angle avoiding dermal damage. (Fig. 7)

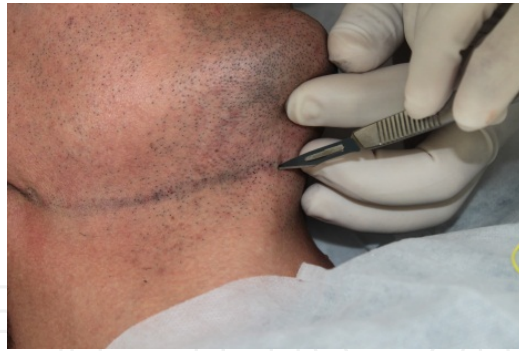

Figure 7. Reaching platysma

The needle is loaded with a number 2 semi-elastic thread and the needle is pulled through the first entry point. This thread has to be long enough to reach both sides twice. (Fig. 8)

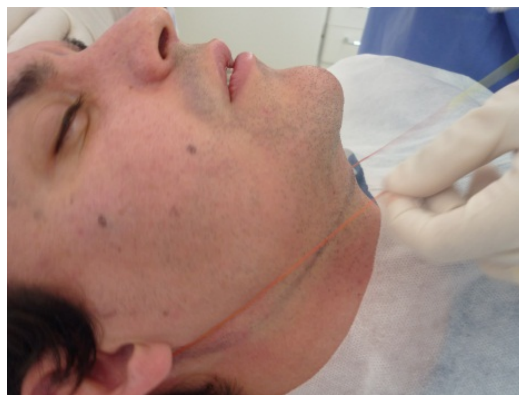

Figure 8. Placing a number 2 semi-elastic thread

The procedure goes along the same way using a Serdev needle 140 zigzag through platysma and additional skin perforations, until it reaches mastoid periosteum of the opposite side where the other thread's end will be exteriorized (Fig. 9).

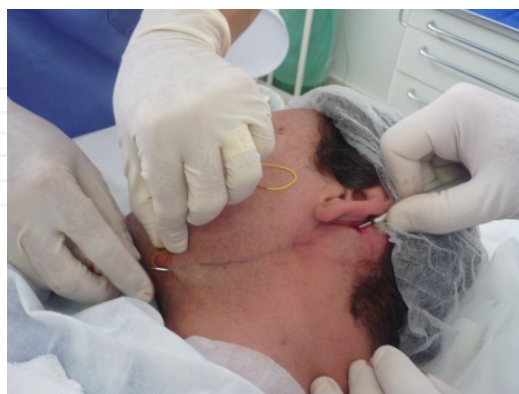
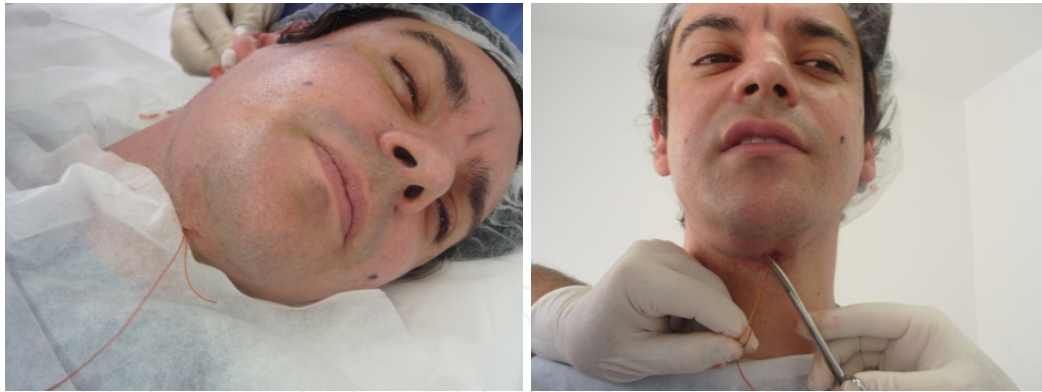

Figure 9. Reaching mastoid periosteum on the opposite side

Enough thread should be present to return until the submental mark is reached, where both thread ends will be tied with three knots which are made while the patient is sited, with medium elastic tension. (Figs. 10a and 10b)

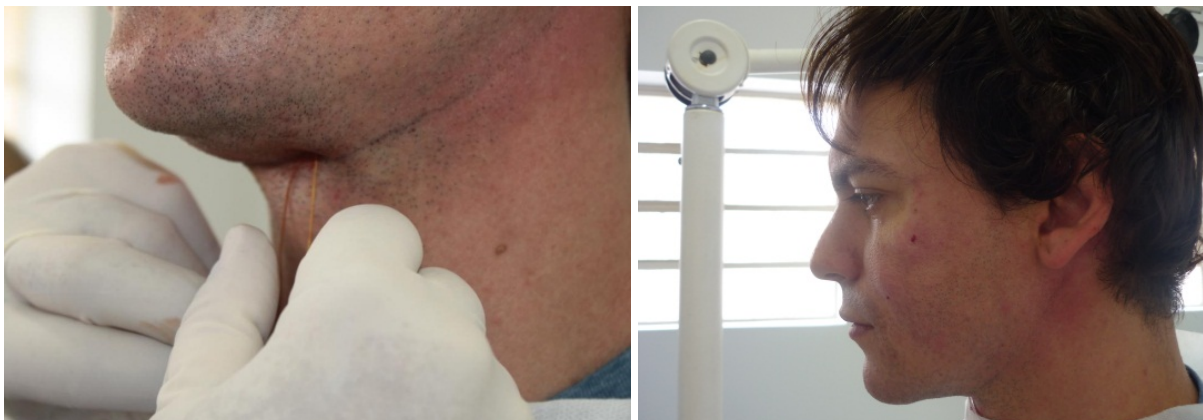

(a)

(b)

Figure 10. Tying the knots

This will direct the skin flaccidity upwards improving the anatomical mandibulo-cervical angle, the mandibular line, and the sagging neck as well. (Figs. 11a and 11b)



(a)

(b)

Figure 11. Placing the patient in a sitting position will direct the skin flaccidity upwards

Possible skin dimples can be managed by pulling the skin laterally and away from the suture using a "mosquito" instrument. (Fig. 12.)

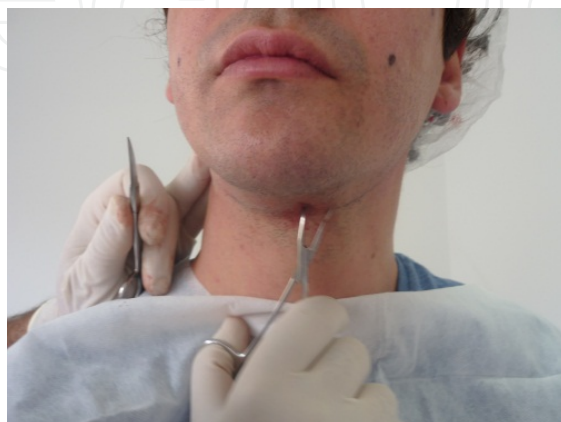


Figure 12. Using "mosquito" instrument

6. Results

The Serdev Suture for platysma generally shows excellent results. There are no visible scars, no sign of any operative intervention and no “operated” appearance at all. The patients are submitted to local anesthesia and the method is minimally invasive, that means, without severe surgical cuts or incisions. The day after the procedure the patient is back to normal life. (Figs. 13. and 14.)

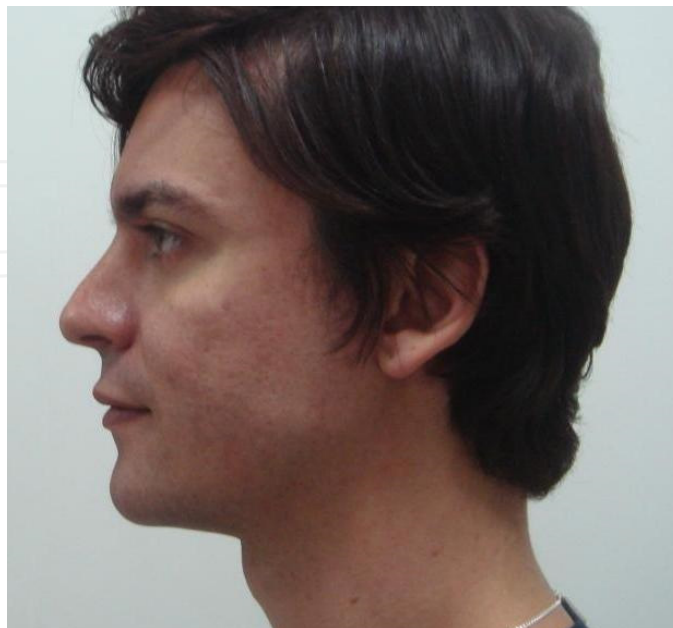
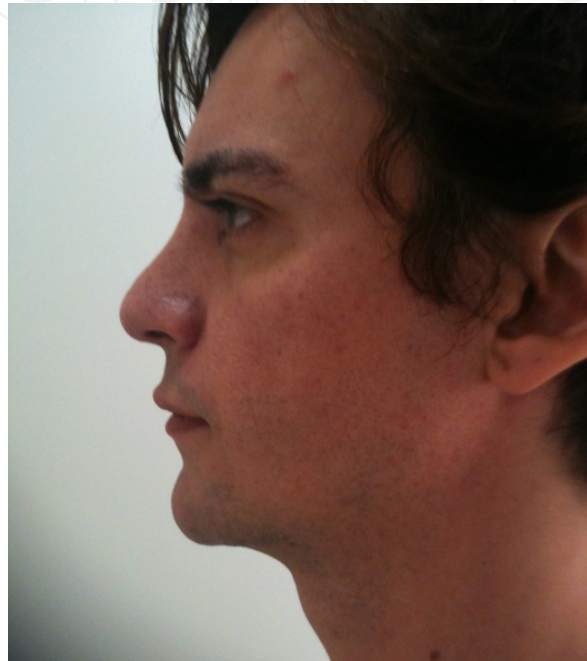
Figure 13. Example of before and after the procedure

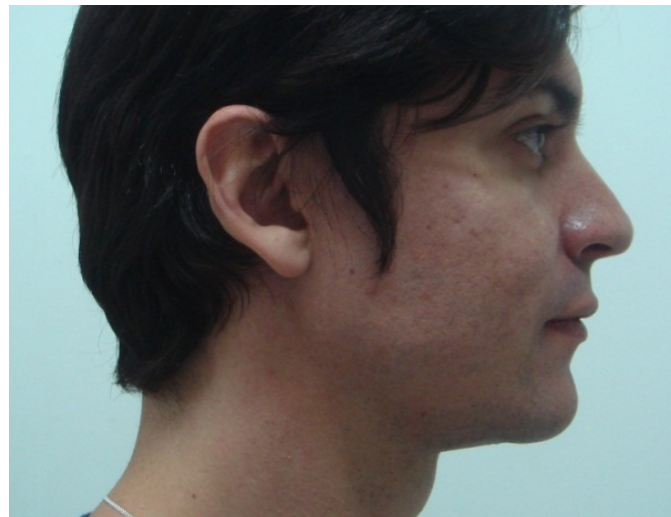

Figure 14. Example of before and after the procedure

Having performed seventeen patients with an indication of the modified technique over the past two years, some complications were observed, such as: two patients had pain in the first two days in front of the sternocleidomastoid, one of which also showed shrinkage the skin in this area. Detachment of the dermis with 18 gripped needle has been successful in improving the pain the day after. The other patient, from outside São Paulo, visited a plastic surgeon on her town who removed the thread.

Other four patients complained of discomfort in the mastoid region. Infiltration of 0,2ml of Dexametazone plus 0,2ml of 1% Lidocaine with epinephrine symptoms improved significantly after two days. One patient reported inflammation and infection at the place of the knot. Antibiotics and drainage of localized collection solved the problem without having to remove the thread. The degree of patient's satisfaction is high due to the simplicity of the technique and immediate results. Weekly follow up helps to solve complications.

7. Discussion

Beautification and immediate social activity are the first and most important patient's requirements. Classic rhytidectomy, in the past years were replaced by minimal invasive procedures with hidden incisions within the hair, extending around the earlobe and retroauricular area. Subperiosteal endoscopic surgeries have also been proposed. In recent years, with increasing demand of patients due to modern lifestyle, requiring less invasive surgical procedures with no visible scars, the Serdev's Sutures were developed, which give patients an optimal solution for face and neck beautification while preserving the natural appearance at the same.

In the case of medium flaccidity in the lower region of the SMAS and platysma, the first Serdev technique is recommended. In cases of excess sagging of the neck and laxity in the submental area, the extended modified technique (Serdev - Tullii), is a valid alternative to stretch the neck, the lower SMAS and platysma, anchoring them to the retroauricularly positioned mastoid. Also, the laxity of the submental area is affected by the suture elevating the hole area.

When the facial skin is also very flaccid, dermal rejuvenation techniques are employed (PRP, Peelings), to improve skin tonus prolonging the results.

If there is excess fat located in the submental region, first we should perform an ultrasonic liposuction with local anesthesia. The skin will retract sticking largely to the deep plane, avoiding extended surgeries. After months it could be necessary to add the first Serdev suture technique as a complement. Also, an submental incision would be performed with plications of the platysmal bands fixating one above the other with two folds.

8. Conclusions

The "Scarless submental platysmal suture band" using skin needle perforations only, or in combination with the Serdev suture lift techniques in lower face and neck "by hidden retrolobular incisions" provide a safe and effective method for beautification of flaccid neck and submental area, as an independent procedure or combining with other techniques of rejuvenation in order to solve face and neck ptosis and aging appearance.

The platysmal Serdev – Tullii suture band in the submental area achieves a bidirectional lower face and neck lift, correction of submental area laxity. It is a safe and effective procedure that gives a pleasant result, the patient obtains a younger appearance maintaining a natural and harmonic expression without plastic surgical incisions. After the surgery there is minimal swelling and business people can work normally.

This much desirable effect of the method is immediate, without visible scars and fulfills patient's desires.

In cases of localized submental fat, the ultrasonic assisted liposuction in combination with our method is helpful to give the good definition of the cervicomandibular angle.

Author details

Roberto Tullii

Clínica Valian, Sao Paolo, Brazil

9. References

- [1] Mitz V, peyronie M. The superficial musculo-aponeurotic system (SMAS) in the parotid and cheek area. *Plast Reconstr Surg* 58: 80-88, 1976
- [2] Brennan HG. Rhytidectomy: Mandibular and submandibular contouring. *Facial Plastic Surgery Clinics of North America* 1(2): 181-96, 1993.
- [3] Baker DC, Conley J. Avoiding facial nerve injuries in rhytidectomy. Anatomical variations and pitfalls. *Plast Reconstr Surg* 6: 781-95, 1979
- [4] Owsley JQ. SMAS-platysma facelift. A bidirectional cervicofacial rhytidectomy. *Clin Plast Surg* 3: 429-401, 1983
- [5] Serdev, N.P. Forehead Subperiosteal Masklift in Combination with McIndoe Facelift Technique and Profile correction. The 7th IPRAS Congress European Section, Berlin, Germany, June 2-5, 1993
- [6] Serdev, N.P. Temporal SMAS lift without skin excision in: Lip Augmentation During Mask and SMAS Lift Procedure, AAARS Annual Meeting, New Orleans, USA, October 5-9, 1994
- [7] Serdev, N.P. Temporal SMAS Lifting of the Face. Life Surgery Workshop. Unidad Medica Clinica Del Country, Bogota D. C., Colombia, November 8-10, 1999
- [8] Serdev, N.P. SMAS Lifting of the Face by Minimal Incisions – the Serdev Tecnique. Life Surgery Workshop sponsored by International Academy of Cosmetic surgery and the Balkan Academy of Cosmethic Surgery, held at the Krilig Clinic in Caracas, Venezuela, November 12-18, 1999.
- [9] Serdev, N.P. Principles of Face Beautification, Ier Congresso International de Cirurgia Cosmetica, Buenos Aires, Argentina, 31 Octubre – 1 de Noviembre 1999
- [10] Serdev, N. P. Temporal SMAS lift, Lecture and Life Demonstration, 1st World Congress of Cosmethic Surgery with Life Demonstrations, Edsa Shangri-La Manilla and Quezon City Medical Center, Febuary 25-27, 2000
- [11] Serdev, N. P. Temporal SMAS Lifting of the Face, Combined with Liposuction and Chin Augmentation Using Suture. Life Surgery Workshop, Tel Aviv, Israel, April 20-24, 2000
- [12] Serdev, N. P. Principlless of face beautification, The 3-rd World Congress of ISAS, Tokyo, April 8-10, 2000, 9W58
- [13] Serdev, N. P. Lifting del SMAS con Una Pequenna Incision Temporal, VIIIas Journadas Mediterraneas de Confrontaciones Terapeuticasen Medicina y cirurgia Cosmetica, Sitges, Barcelona, March 16-19, 2000
- [14] Serdev, N. P. Facial Rejuvenation by Minimal Skin Incisions, International Congress "Refiinments in Aesthetic Surgery" Oradea, Romania, June 22-24
- [15] Gasparotti M. Superficial liposuction: a new application of the technique for aged and flaccid skin. *Aesthetic Plast Surg* 1992, Spring;16(2):141-53

- [16] Gasperoni C, Salgarello M. MALL liposuction: the natural evolution of subdermal superfiction liposuction. *Aesthetic Plast Surg* 1994, Summer, 18(3): 253-7
- [17] Perssonelle, J. G. *Cosmiatria A Ciência da Beleza*, 2004
- [18] Kopf Maier, P, Wolf Heidegger *Atlas na Anatomia Humana*, Volume 2, Ed: 5, 28-36
- [19] Rees and LaTrenta, *Aesthetic Plastic Surgery*, Cap. 28 “Composite Rhytidectomy” (Sam, T. Hamara, M.D.) 1994
- [20] Rees and LaTrenta, *Aesthetic Plastic Surgery*, Cap. 26 “The Classic Operation” (Thomas D. Rees, M.D) 1994
- [21] Serdev, N. P. Year 1994, Sutures suspension for lifting or volume augmentation in face and body (English version), *Int.J.Cosm.Surg.* 2001, Volume 1, Number 1, 2561-2568.