

We are IntechOpen, the world's leading publisher of Open Access books Built by scientists, for scientists

4,800

Open access books available

122,000

International authors and editors

135M

Downloads

Our authors are among the

154

Countries delivered to

TOP 1%

most cited scientists

12.2%

Contributors from top 500 universities



WEB OF SCIENCE™

Selection of our books indexed in the Book Citation Index
in Web of Science™ Core Collection (BKCI)

Interested in publishing with us?
Contact book.department@intechopen.com

Numbers displayed above are based on latest data collected.

For more information visit www.intechopen.com



New Method of Face Elastic Thread Lift

M. Sulamanidze, G. Sulamanidze, I. Vozdvizhenskiy,
K. Sulamanidze and A. Kadzhaya

Additional information is available at the end of the chapter

<http://dx.doi.org/10.5772/56316>

1. Introduction

Within the last few decades the priorities for the treatment of facial ageing and sagging, especially in the paraoral area, have changed dramatically. Patients demand this interference to be performed with minimum risk to their health, minor injury, short postoperative rehabilitation period, and, above all, long-term aesthetic effect.

However, during the process of lifting operation on the mentioned facial zone mobilization and hypodermic soft tissues transfer (subcutaneous tissue, SMAS, muscles) into a new higher position and applying interrupted sutures through the soft tissues are regarded as key points of the long-term effect, that is impossible to achieve without a considerable operational trauma. Besides, the strongly pronounced mobility of this facial area brings the results of the interference to the relapse of the aesthetic deformation.

2. Classical methods of face lift and their disadvantages

It is known that traditional face lift methods are not effective enough to eliminate aesthetic age manifestations in the paraoral area, as these zones are at the maximum distance from the section and face lift line. That is why during face lift operations some surgeons make a wide separation of face skin up to the nasolabial folds and mouth corners, and then raise the skin fold upwards and laterally to the maximum possible extent, removing considerable skin surplus. Performance of such surgeries quite often leads to unnaturally stretched faces, alopecia in the temple area and hypertrophy of postoperative cicatrices, appearing deceitfully under auricula lobes and stretching them down (picture 1). Even deep plane lift methods (so called SMAS- and intraperiosteal lifts) do not always eliminate the aging face signs in its medial parts.

In picture 2 we can see a skin area with marking, in picture 2(b) – the same area after mobilization in the course of rhytidoplasty. It is clearly seen that the skin area that had been

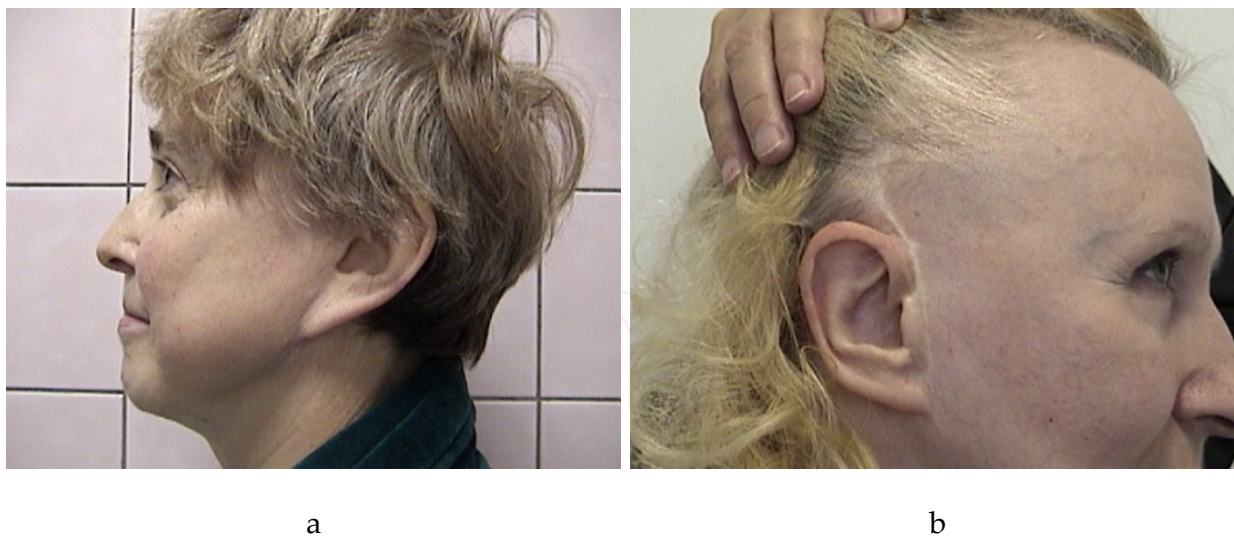

Figure 1.

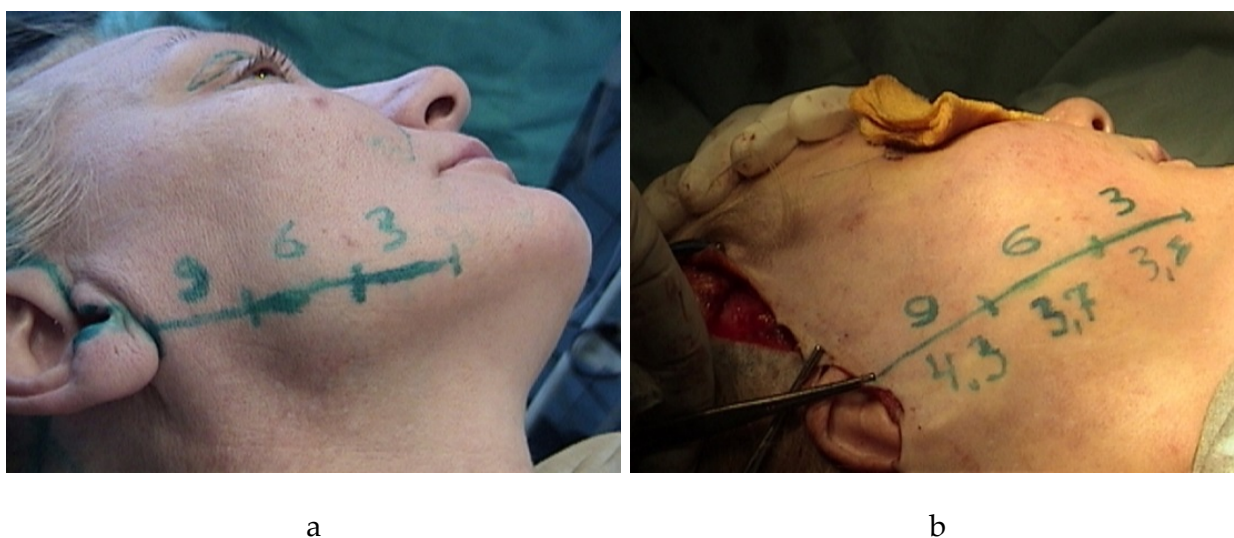


Figure 2.

the furthest from the place of the force application stretched out insignificantly – only to 0.4 cm, while the nearest skin graft stretched considerably – it became 1.5 cm longer.

Furthermore, paraoral facial areas are in the zone of active influence of masticatory and mimic muscles, and in the nearest postoperative period the areas around the mouth corners, smoothed out as the result of the surgery, become sagged again. This factor also interferes with the stabilization of the face lift result [1].

In the last few years, despite the anatomic and functional features of the paraoral area, different methods of hard thread lifting have been used quite often for mouth corner soft tissue lift. Such an approach cannot give consistent long-term effect, as in this case the presence of highly developed and active masticatory and mimic muscles, which quickly destroy the achieved result (in 2-3 months a relapse is expected), is underrated.

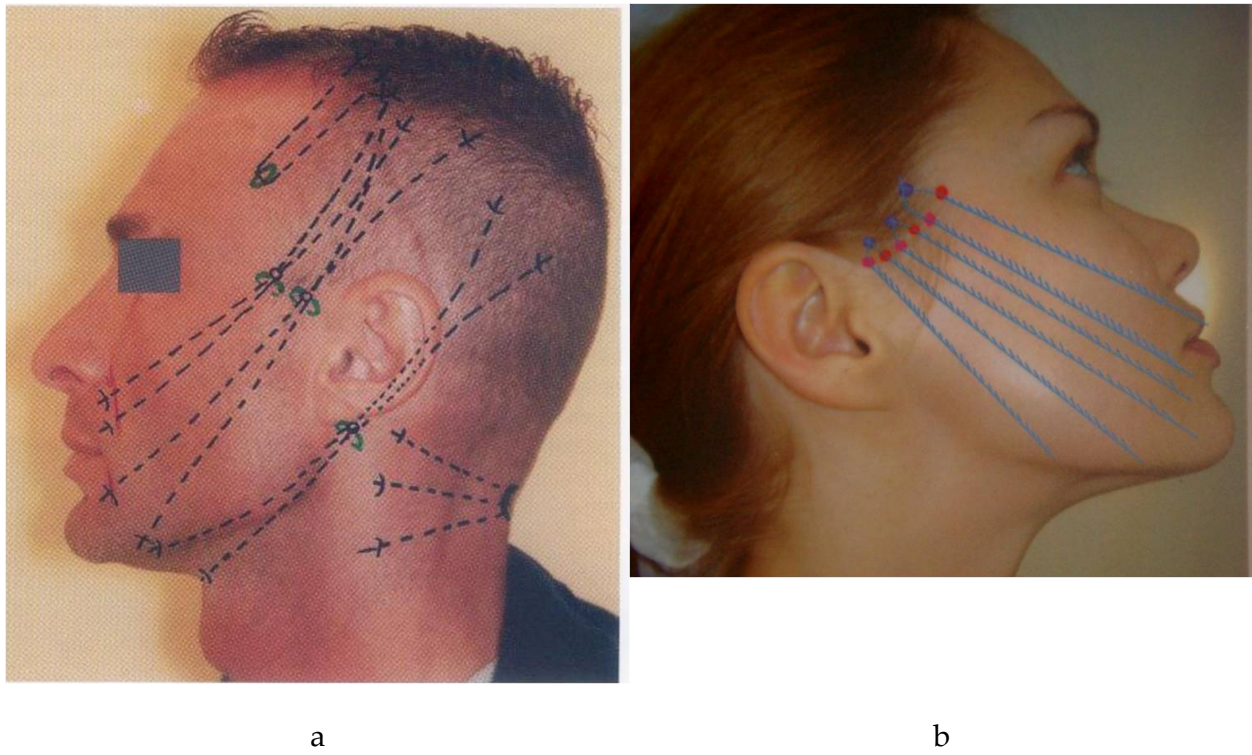


Figure 3.

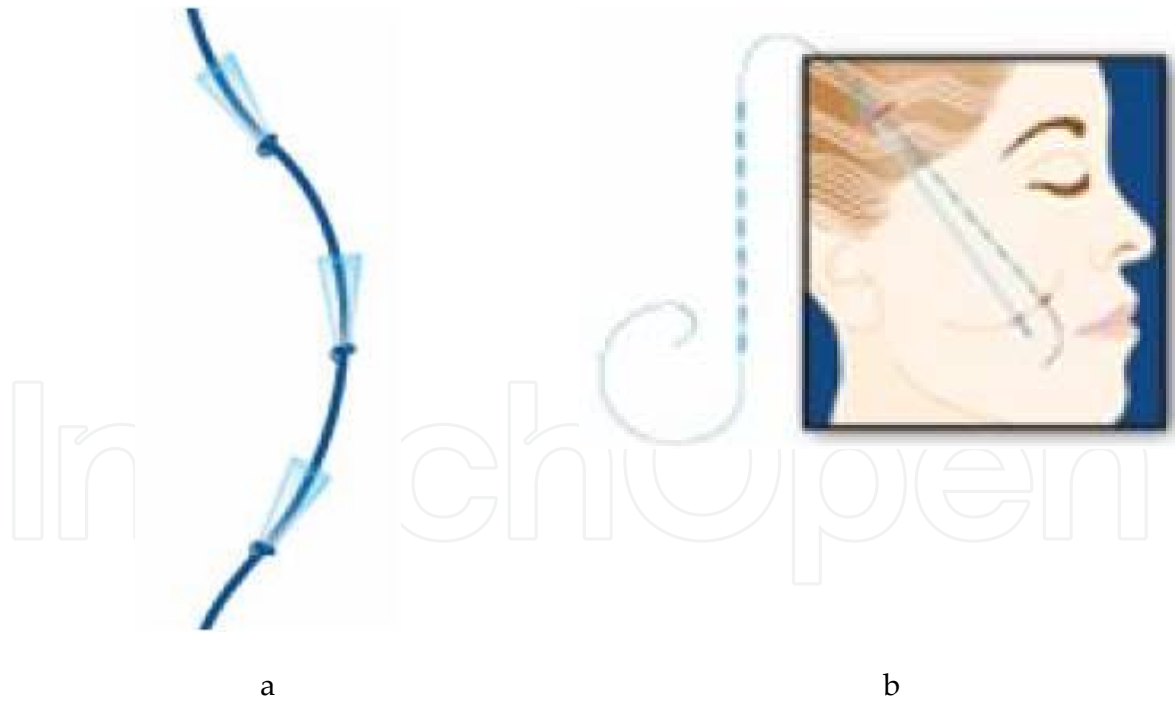


Figure 4.

Even such powerful lift constructions as Silhouette Sutures, as they can seem at first glance, cannot resist kinetics of these muscles and cannot save lift results in such areas for a long period of time (picture 4), as the direction of threads' position resists muscle contraction and relaxation.

3. Elastic thread lift of the paraoral area. Aptos Springs Method

In 2004 elastic thread lift of the paraoral area – Aptos Springs Method – was developed in our clinic. Both the method and the threads developed for using in this technique have Russian and international patents [6, 7].

Aptos Springs thread is a special twisted in form of a spring polypropylene (non-absorbable) thread 2/0, which has a “memory”. In the course of production this thread undergoes a special processing which provides it with spring type characteristics. A spring in a compressed position is wound around an injection needle of 1.1x100 or 0.9x90 mm (picture 5). There are two Aptos Springs threads of each size in one package, and one package usually is enough for one procedure.




Figure 5.

The manufacture produces Aptos Springs threads made from polypropylene (non-absorbable) as well as from absorbable Kaprolac threads (Light Lift), which gets fully absorbed in the tissues within a year, and the fibrosis, which appears in this place, keeps on “working”.

In the clinical practice Aptos Springs threads are used for:

- labiomental fold elimination (Marionette Line) (variant I);
- mouth corners lift (variant II).

During the consultation the patient is informed about the method possibilities, details of the surgery performance, its duration, rehabilitation period special characteristics, and the duration of the lift effect. The patient decides on his/her own with the use of which product (absorbable or non-absorbable threads) the surgery is to be performed.

4. Variants of the surgery performance

4.1. Labiomenal fold elimination (surgery technique, variant I)

The “marionette line” is marked and two parallel lines, 1 cm distant from each other, are drawn perpendicularly to the wrinkle (picture 6). The Aptos Springs thread of the bigger thickness is usually fixed above, and the one of the smaller size is fixed below.

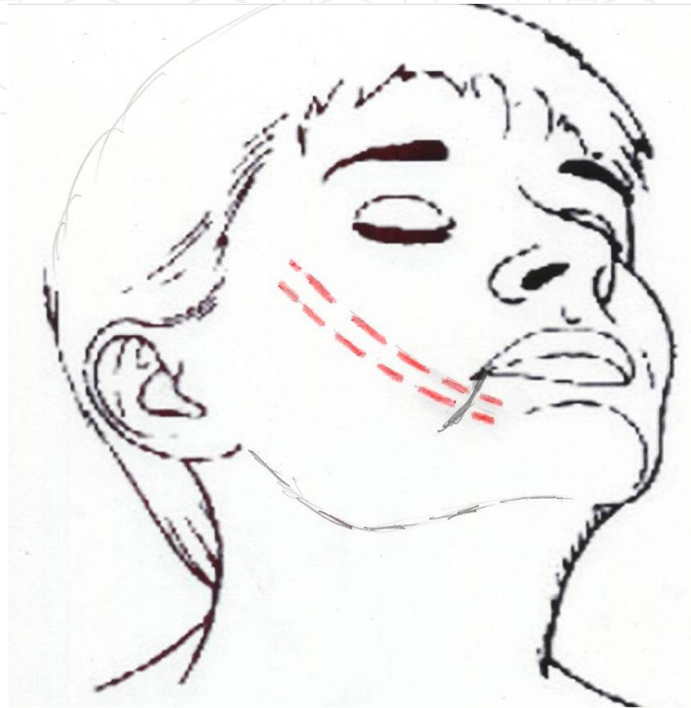
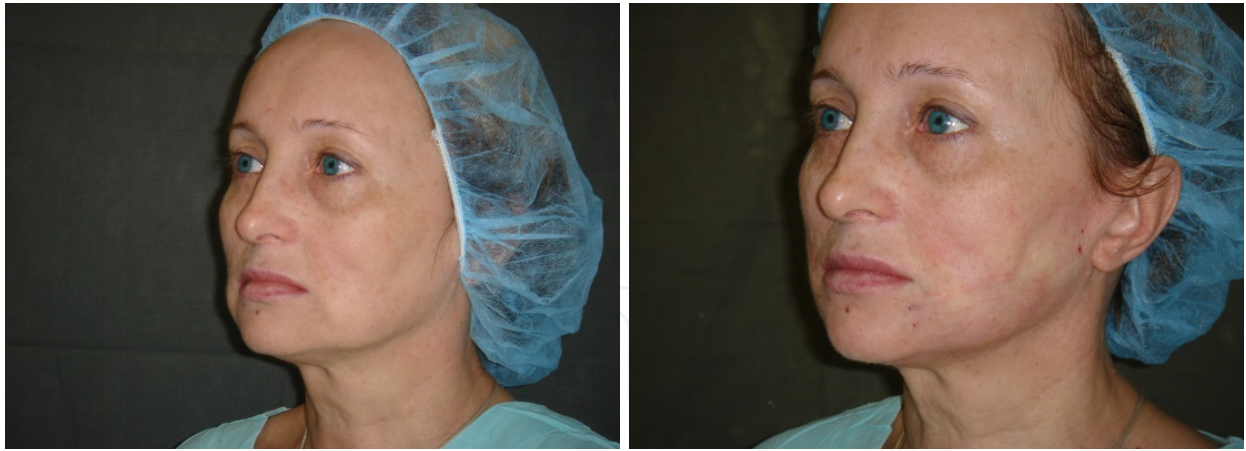
Figure 6.

Before it is fixed the spring is stretched along the length of the needle and is inserted subcutaneously in this position. The needle is inserted at the upper point and pushed towards the wrinkle; in the first half of the way it is deepened to the SMAS limits, in the second half it is shifted closer to the skin and crosses the fold at this depth. The needle is taken out from the skin 1.5 cm past the Marionette line, while the spring is left subcutaneously. After a slight lifting of the spring thread from the both sides, its surplus is cut off and the ends are buried under the derma. In this case there is no need to use any special thread ends' fixing as it is evenly and rigidly fixed in the tissues with the help of its coils.

Right after the fixation, on the operating table, you can see a lift effect and elimination of the labiomenal folds and the soft tissue folds over them. By compressing Aptos Springs threads lift sagging soft tissues, and stretch and shrink in synchrony with facial muscles in the process of mimic, masticatory or other facial movements (picture 7).

Subsequently fibrous tissue appears around the thread, which in its turn provides strengthening of the lifting and spring type effect with a long-term consistent result (picture 8,9,10).



a

b

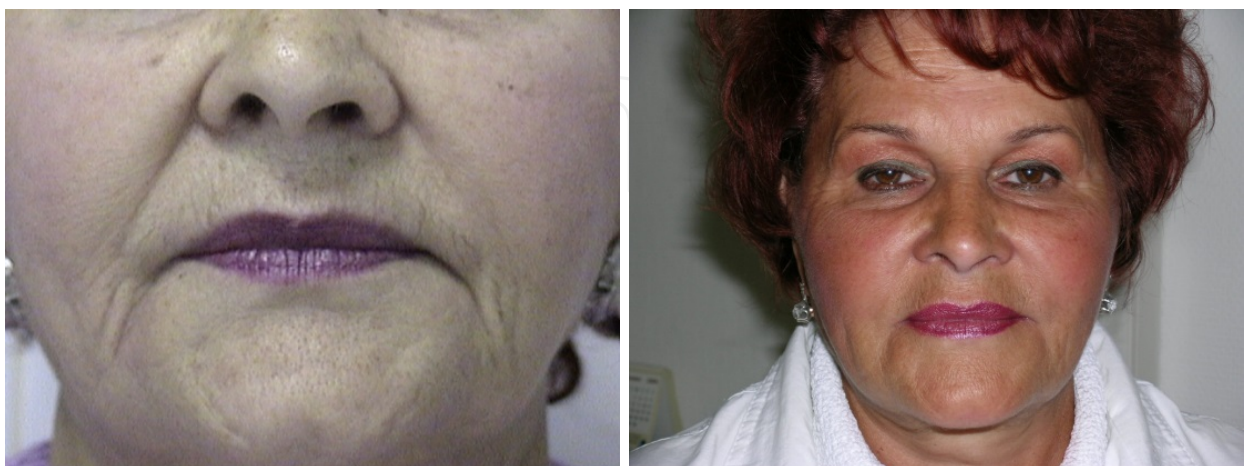Figure 7.



a

b

Figure 8.



a

b

Figure 9.

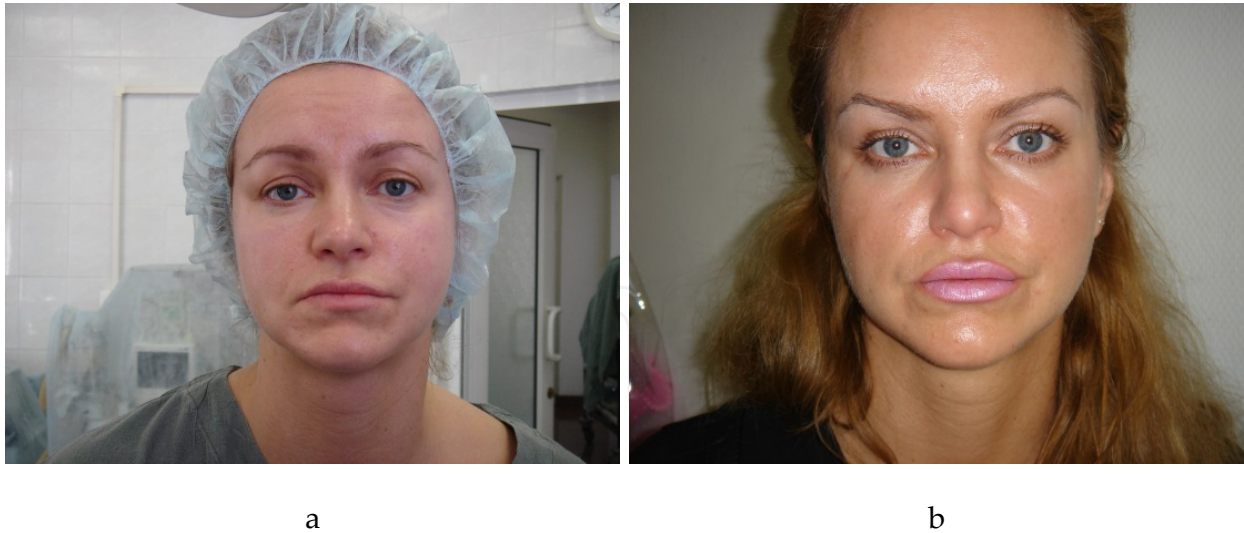

Figure 10.

4.2. Mouth corners lift (surgery technique, variant II)

The marking used for the mouth corners lift surgery is made in the following way: one line is drawn perpendicularly to the “marionette line”, just like in Variant I, while the second line is drawn parallelly up to the mouth corner, and then up and angle-wise, sideward the red border of the upper lip at a distance of 1.5-2.0 cm (picture 11).

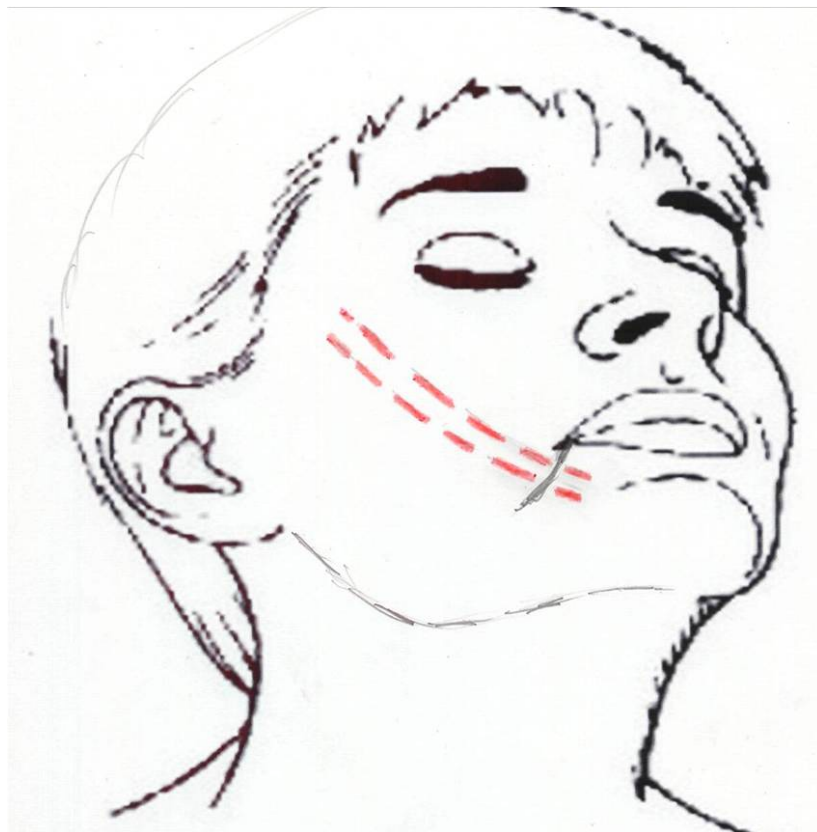

Figure 11.

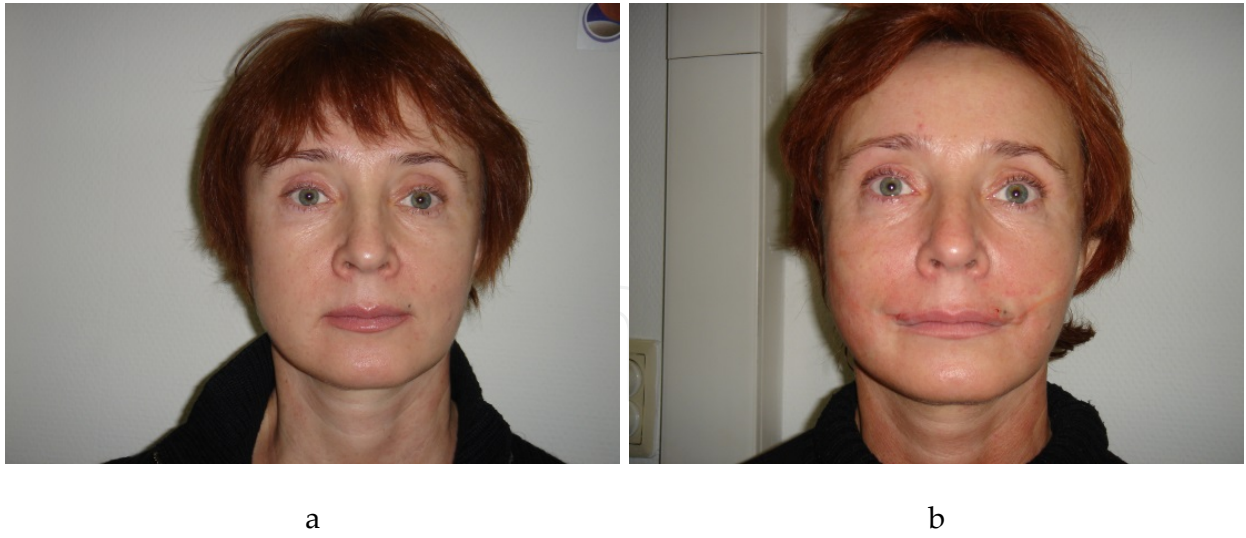

Figure 12.

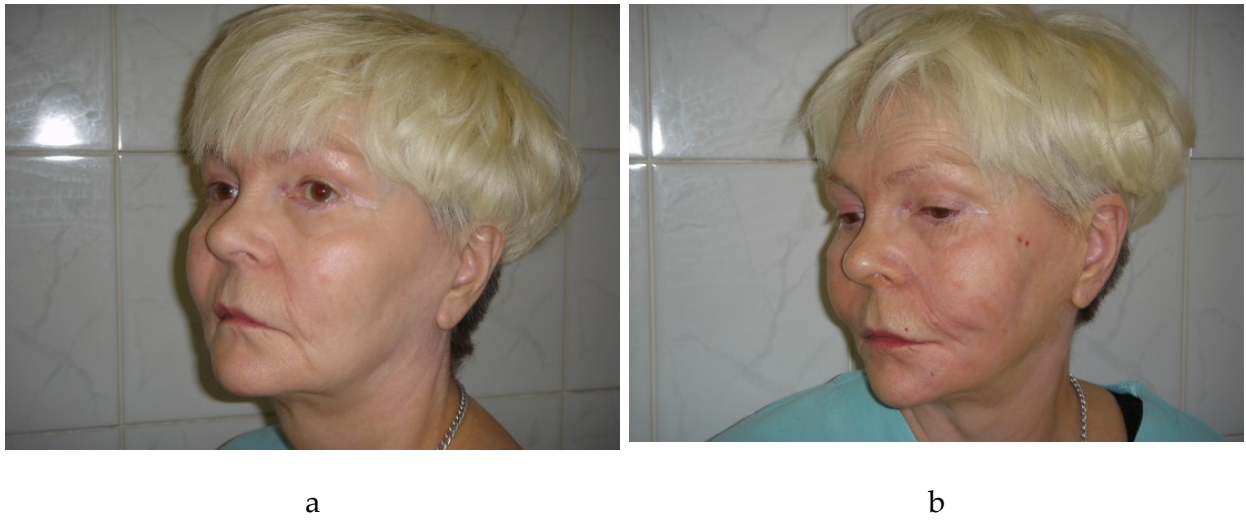

Figure 13.

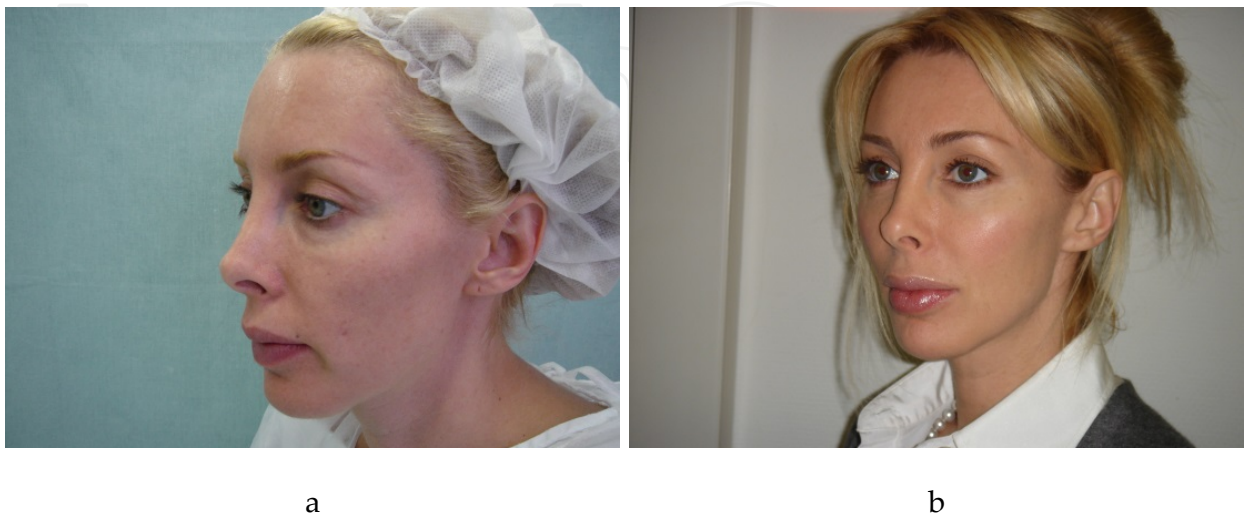

Figure 14.

The Aptos Springs thread of the bigger thickness is fixed sideward the “marionette line”, the thread of the smaller thickness is brought to the mouth corner and then inserted under the skin of the red lip border.

Right after the threads fixation (as early as on the operating table) we can see the mouth corner lift effect (“constant smile” effect), slight eversion of the lateral areas of the upper lip and labiomental folds elimination of slight expressiveness (picture 12, 13, 14).

5. Conclusions

Operations by Aptos Springs method are performed under local infiltration anaesthesia quickly, easily, without discissions, with a slight surgical trauma, little postoperative pains, and a short rehabilitation period. Since 2003 more than 2000 similar operations have been carried out in our clinic both in the form of monotherapy and simultaneously with other rejuvenation interference and always with good long-term results.

Author details

M. Sulamanidze, G. Sulamanidze, I. Vozdvizhenskiy,
K. Sulamanidze and A. Kadzhaya
*Clinic of Plastic, Aesthetic Surgery and Dermatocosmetology, Total Charm,
Moscow, Russia*

6. References

- [1] Mendelson B.C., Muzaffar A.R., Adams W.P. Surgical Anatomy of the Midcheek and Malar Mounds // *Plastic. And Reconstruct. Surgery.* – 2002, September. – Vol. 110, №3. – P. 885-896.
- [2] Guillo D. Fils Aptos implantation en X. *Surginevs* 2005, 8, 10-13.
- [3] Matarasso A., Pfaifer T.M., The Use of Modified Sutures in Plastic Surgery. *Plastic and Reconstructive Surgery*, 2008; 122 (issue 2):652-658.
- [4] Sasaki G.H., Komorovska-Timek E., Bennet D.C., Cabriel A. An Objective Comparison of Holding, Slippage and Pull-Out Tensions for Eight Suspension Sutures in the Malar Pads of Frech-Frosen Human Cadavers. *Aesthetic Surgery Journal*, 2008; 28 (4): 387-396.
- [5] Sulamanidze M.A., Sulamanidze G.M., Sulamanidze C.M., Vozdvizhensky I.S. Lifting of Soft Tissues With Barbed Threads. Side Effects, Complications. // 11-th ESPRAS Congress Plastic, Restorative and Aesthetic Surgery, 20-26 September 2009, Rhodes, Greece. – Book of Abstracts. – P.25
- [6] Sulamanidze M.A., Sulamanidze G.M. Aptos Springs – a new concept of lifting. *Journal of the Japan Society of Aesthetic Surgery*, 2005; 42(5):183.

- [7] Sulamanidze M.A., Sulamanidze G.M. Surgical Thread and Cosmetic Surgery Method. WO, 2005/087283.

IntechOpen

IntechOpen