

We are IntechOpen, the world's leading publisher of Open Access books Built by scientists, for scientists

4,800

Open access books available

122,000

International authors and editors

135M

Downloads

Our authors are among the

154

Countries delivered to

TOP 1%

most cited scientists

12.2%

Contributors from top 500 universities



WEB OF SCIENCE™

Selection of our books indexed in the Book Citation Index
in Web of Science™ Core Collection (BKCI)

Interested in publishing with us?
Contact book.department@intechopen.com

Numbers displayed above are based on latest data collected.
For more information visit www.intechopen.com



Serdev Sutures® in Upper Face: Brow and Temporal Lift; Glabella Muscle Ligation

Nikolay Serdev

Additional information is available at the end of the chapter

<http://dx.doi.org/10.5772/55673>

1. Introduction

Closed approach transcutaneous Serdev Suture® lifts encompass the principle concept of stable suturing and fixation of mobile fascias to immobile periosteum, tendons and fascias, resulting in suture suspension and/or volume augmentation and/or repositioning.

21 techniques and individual modifications are used on face and in body areas, even where open surgical techniques cannot be directly applied. Serdev Sutures® are scarless and uncomplicated in the post-operative period. These techniques use curved semi-blunt semi-elastic needles and smooth surgical sutures to elevate and fixate mobile fascial tissue. Polycon surgical sutures are preferred for these techniques. They are characterized by short elasticity to prevent mobilized tissue from rupture and are characterized by delayed resorption (in 2-3 years, after the fibrosis is finalized). This enables stable fibrotic fixation before suture degradation.

Fixed mobile facial tissue using Serdev Sutures® is SMAS in all face areas: upper facial SMAS (galea aponeurotica), zygomatic SMAS extension, cheek SMAS, platysma and others. It is fixed by suture to stable, immobile tissues, such as periosteum, temporal fascia, zygoma, coli fascia, mastoid, occipital bone etc.

In addition to the possibility of lifting, Serdev Sutures® follow aesthetic principles of beautification: adaptation of aesthetic proportions, volumes and angles. In art and theatre, face masks called “mask of tragedy” and “mask of comedy” are well known and used to express age, status and emotions. The concept of scarless suture lift in face is to convert the “mask of tragedy” into a “mask of comedy”, i.e. to uplift the subcutaneous facial mask – the SMAS. As soft tissue and skin are attached to the SMAS by a trabecular system, an intrinsic consequence of SMAS lifting is reflected in the lifting of the face and its most important elements in the same direction.

The structuring and positioning of different face elements is not limited to facial ptosis and elderly cases. Unaesthetic face angles, volumes and proportions are responsible for lack of beauty in young patients as well. Beautification is most important in youth and rejuvenation incl. beautification in elderly. Changing SMAS position by sutures can restore aesthetic angles, shape, volume and proportions as a basis for beautification and rejuvenation, imparting a happy, youthful appearance and a smiling expression.

1.1. History

Scarless closed approach Serdev Suture® lifts present skeletal fixation using skin punctures, without incisions and excisions, as a first alternative to classic excision lifts. Sutures are the same as in open surgery, but with much more variations and even in areas not reachable in open surgery. The anatomy study, instrument creation and surgical suture selection commenced in 1990 and the entire understanding of local topographic anatomy, instrumentarium and technique of this new method was ready in 1993. Needle preparation and selection of surgical sutures was experimental. For sutures stretch, elasticity and cut through tests were performed. The long term absorption of the sutures is crucial in the author's method. In 1994, at the Second annual meeting of the National Bulgarian Society of Aesthetic Surgery and Aesthetic Medicine, most of the scarless suture techniques for correction of early ptosis and flabbiness in areas of face and body were presented, as well as the initial results with 54 patients, operated during the period from 1993 to 1994. The author's contribution is that the transcutaneous closed approach suture techniques lift the SMAS and the facial skin attached to it, without traditional incisions. Operations were ambulatory with excellent results, reported by the patients. The trauma is minimal and the follow-up period is no longer than 3 days with fast and mostly immediate return to work and social life. There are no visible scars and the needle perforations on the skin are no longer visible after days.

1.2. Technique and anatomical fixations

Operations are ambulatory, without hospital stay. Trauma is minimal. The techniques consist of passing closed sutures, by needle perforations only, to lift mobile fascias supporting the skin and fix them to immobile skeletal structures (such as periosteum) in several facial and body areas.

The author has invented and performs the following scarless transcutaneous closed approach **suture lifts**:

1. **In face areas: Temporal lift** (upper SMAS to upper temporal line and temporal fascia) and **supra-temporal lifting** (upper SMAS to upper temporal line), **Brow lift** (orbito-cutaneous brow fascia, discovered by the author, to upper temporal line periosteum 1.5 cm above the upper orbital rim or at the hair line), **Lateral canthus lift** (to orbital rim or to upper temporal line and temporal fascia), **Mid-face lift** (SMAS zygomatic extension to temporo-parietal tendon and to upper temporal line periosteum), **Cheekbone lift** (fascial tube of Bichat fat pad, SMAS and zygomatic SMAS extension to zygoma

periosteum, to upper temporal line and temporal fascia, to temporo-parietal tendon etc.) **as well as Augmentation** using patient's own tissue, **Smiling dimple formation**, **Lower SMAS-platysma face and neck lift** (platysma fixation to mastoid), **Chin enhancement, form and position correction** with or without fixation to the menton periosteum, **Chin dimple formation**, **Sutures in rhinoplasty for tip rotation** (medial crura of greater alar cartilages to nasal bone periosteum), **tip refinement** (suturing together all 4 crura of both greater alar cartilages at the dom), **alar base narrowing** (suturing the alar base incl. accessory alar cartilages), **Otoplasty** (perihondrium suture to obtain the antihelix fold) etc.

2. **In body areas: Breast lift** (fixation of breast fascia and upper glandular tissue to clavicle and/or to pectoralis major tendon), **suture technique for Simmastia, or implant position correction**, **Buttocks lift** (fixation of the fibrous soft tissue to the sacro-cutaneous fascia, found by the author), **Abdominal flaccidity tightening** (linea alba shortening, superficial fascia to costal line, spina iliaca superior anterior), **Inner thigh lift** etc.

1.3. Results

The suture methods became possible after creating specific curved, semi-elastic, semi-blunt needles. Best results were obtained with the Bulgarian polycaproamide sutures Polycon, which ensure semi-elastic fixation of mobile to immobile tissue (unlike other available non elastic and non-absorbable surgical sutures). The author has experimentally evaluated that they do not cut through the tissues.

Preferred **surgical suture** qualities are – short elasticity, absorbable within two-three years - after final fibrosis formation, and anti-microbial action. The author's tests have shown that only Polycon surgical sutures ensure these qualities. - <http://medicaldevices-bg.com/MDI/Threads.html>.

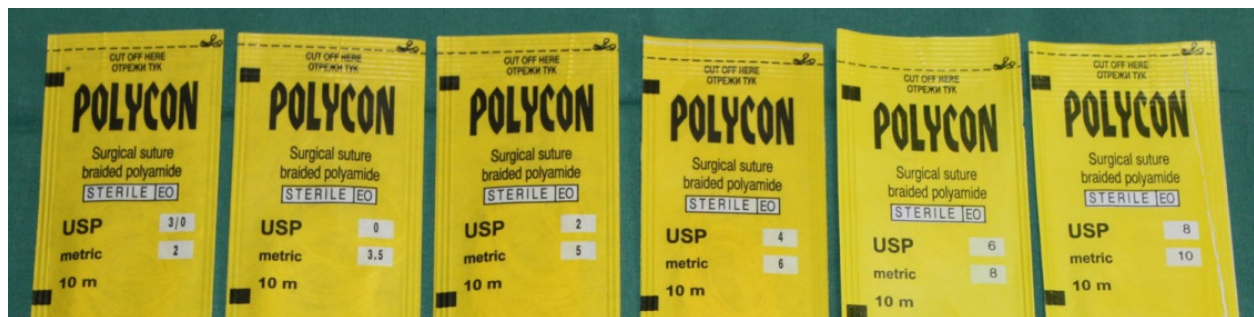

Figure 1. Polycon surgical sutures (3/0, 0, 2, 4, 6, 8) are semi-elastic (short elasticity), braided polycaproamide sutures of different thickness and have anti-microbial qualities.

USP depends on application. **6 different USPs** are suitable for different procedures and body areas:

- **USP 3/0** - for ear and nose: tip & base
- **USP 0** - for chin & brow lift
- **USP 2** - for facial, inner thigh, abdomen lifts

- **USP 4** - for temporal, mid-face lifts, buttocks & breast lifts
- **USP 6** - for bigger buttocks & large breast lifts
- **USP 8** - for bigger buttocks lifts (mostly used in Latin America)

Polycon surgical sutures are absorbed in the human body within 2-3 years, i.e. after the final fibrosis. According to the author, these are the best surgical sutures for lifting methods, because they permit semi-elastic movement of the sutured tissues.

1.4. Contributions

Serdev Suture® lifts, suspensions and volumizing present the first lifting method to replace scarring classic excision lifts as a complete method for scarless transcutaneous closed approach in total face and body lifts, where mobile fascias (holding skin by trabecular system) can be lifted and fixed to immobile periosteum, tendons and fascias.

1.4.1. Author suture techniques present

- A new method for closed approach face and body liftings – a new alternative to classic excision lifts;
- Scarless lifting, using skin punctures only (no incisions or excisions);
- Mini-invasive, no downtime procedures;
- Beautification and rejuvenation methods;
- Volumizing method without implants and transplants. When needed, tissue augmentation is performed using patient's own tissue – a new alternative without implants;
- Can be used in cosmetic, aesthetic and plastic-reconstructive surgery;
- Downtime is shortened from weeks into some days;
- No danger of hematoma formation, no nerve damage, no scars.

Serdev® Needles are specially designed and developed for best use and have the following qualities:

- Elastic curve (the curve cannot be deformed when applying pressure in patients tissue);
- Smooth surface (does not cut periosteum);
- Conical semi-blunt tip (trauma is minimized);
- Thickness depends on length (from 50 mm to 250 mm) and application - http://medicaldevices-bg.com/MDI/Serdev_Needles.html.

11 different needle lengths were developed specifically for one or more face & body lifting techniques:

- Mini Mini 50 - for ear and nose: tip and alar base
- Mini Mini 50 (bended) - for fine chin subperiosteal fixations
- Mini 60 - for brow, chin, temporal, mid-face, cheekbone etc. lifts
- Mini 60 (bended) - for fine mid-face subperiosteal fixations

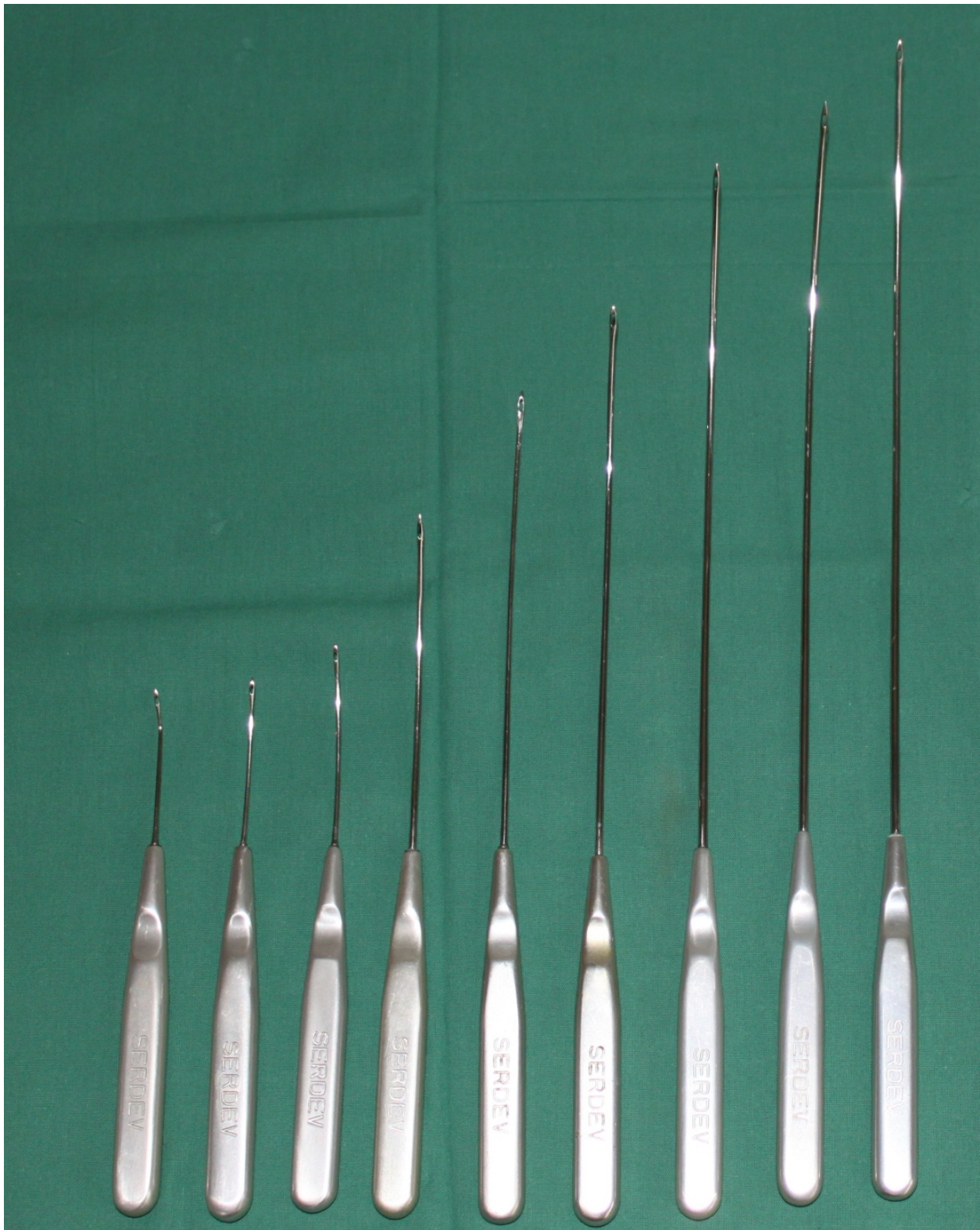


Figure 2. Serdev® needles (from left to right): Mini Mini 50 mm (bended), Mini Mini 50 mm, Mini 60 mm, Small 100 mm, Medium 140 mm, Long 170 mm, Super Long 210 & 230, and Super Super Long 250 mm (mostly used in Latin America).

- Small 80 - for neck lifts
- Small 100 - for facial, inner thigh, abdomen lifts
- Medium 140 - for mid-face, breast, abdomen lifts
- Long 170 - for buttock and breast lifts
- Super Long 210 - for buttock lifts *
- Super Long 230 - for buttock lifts *
- Super Super Long 250 - for buttock lifts *

*The choice of length depends on patient's physical characteristics

The needles are similar in shape to the currently used surgical needles with a handle to ease manipulation, with an eye at the needle tip (example Reverdin needles). However, Serdev® Needles are different in surface, elasticity, shape, size, thickness and have a curved elastic section (that retains structural curve memory regardless of the applied pressure). The elasticity and smooth polished surface allows the needles to safeguard bone-periosteal structures against cutting, regardless of the length and change of direction of the moving needle. The semi-blunt tip and elastic needle characteristics combine to avoid tissue trauma. The needle curve is specifically designed to provide ease of skin ingress, fluid movement through different soft tissue levels and periosteum, and the capture of fascial tissue. The semi-blunt tip exhibits variable penetrative qualities adapting to the application of the respective methods. The handle is flat and has a concavity mark for secure handling and display of needle tip position in the tissue.

1.5. Discussion

Scarless Serdev Suture® liftings use closed approach fixation of specific mobile fascial tissue to immobile skeleton periosteum without incisions. In Brazil they are known as “fio elastico” or “fio bulgaro”. The Serdev Suture® techniques are used to correct early ptosis and flaccidity in areas of face and body, without traditional incisions. They are used also for tissue augmentation.

Observing Dr. Serdev's videos without proper training and understanding of anatomy led to “modified” techniques using non-original or straight needles, performing superficial barbed threads that are neither sutured, nor fixed, free floating in subdermal fat tissue or fixed only superiorly. Superficial threads and sutures fixed solely to the trabecular system in the subdermal fat cannot guarantee outcome longevity. Using straight needles is an oversimplification that fails to secure deep fixation of mobile to immobile tissues that is essential for stable fixation. These are easy procedures for non-surgeons and this is the reason that this oversimplification became popular. However, outcomes are insecure. As little as a 1 or 2 mm change is enough to miss the topography of the important anatomical fixations such as bony rim, level of fascias and tendons. Therefore it is essential that doctors have a critical perception about the differences between suture lifts of mobile to immobile stable tissues and superficial thread lifts in subdermal fat.

2. Brow lift

Multiple invasive techniques have been described for fixation of the scalp and upper face. However, these methods do not allow the direct positioning of the brow as in the suture method described by the author. Within the past decade the demand for minimally invasive surgery, fast recovery and immediate beautification outcomes have revised the trend toward extensive surgical procedures and radically changed surgery in face-forehead beautification and rejuvenation. Even minimal incision approaches to brow lifting, using endoscopic methods or excisions of supra-brow skin, are associated with longer down time and have become undesirable options for beautification in younger patients. Improved understanding of eyebrow anatomy, pathophysiology of the aging face and advances in small - and non-incision surgery, have contributed to the new approach in correction of the eyebrow position for beautification and rejuvenation. The Serdev Suture® method with needle skin perforations between the eyebrow hairs has been reported and introduced internationally since 1994. The concept is to capture mobile but stable tissue (the orbito-superciliar fascia, discovered by the author) and attach it to firm, immobile upper temporal line bone and periosteum.

The eye-eyebrow is the most influential region in determining facial expressions. There is only a narrow range of eyebrow positions that are perceived as attractive. Artistic location of the eyebrow is a guide line for eyebrow repositioning. The author has reviewed the young position of the eyebrow in models and also the artistic experience and aesthetic criteria for ideal female eyebrow height and shape in both international fashion models and movie stars. The preferred distance from the upper orbital rim to the eyebrow tail is on average 1.5 cm. Eyebrow shape should have a lateral apex slant. In male patients a lesser rise of the eyebrow tail has to be considered. The importance of aesthetic anatomy, aesthetic assessment and treatment planning in evaluation of the face must take into account considerations of patient selection, indications, and contraindications.

The author performs brow lift by suture in cases of ptosis, asymmetry, or in patients who desire a non-scarring and non-invasive procedure. Indications are beautification, rejuvenation, correction of proportions and angles.

2.1. Procedure

The brow lift suture is done by needle punctures only between the eyebrow hairs to prevent scarring. It presents a stable fixation of the orbito-superciliar fascia to the periosteum of the rim of the upper temporal line, 1.5 cm above the orbital rim or at the hair line. The subperiosteal bite line (1.5 cm above the orbital rim) defines the eyebrow design. An important instrument that facilitates performing this technique is the curved, semielastic, semiblunt mini-mini Serdev® needle with length of 50 mm that can be turned down and up in order to enter through the skin, capture periosteum or fascias and exit through another skin perforation point (Fig. 5). It is most important that we have at our disposal the 0 polycapraamide surgical sutures with marked elasticity that are biodegradable in the longer term (in 2-3 years), antimicrobial and braided (Fig. 1, 4). The semielastic, braided, USP 0 suture permits movements of face and muscles, fixation under elastic tension and does not

traumatise or cut the sutured tissue. The extended period of resorption quality allows time for a stable fibrosis formation and does not leave foreign bodies in the tissue after the fibrotic fixation formation process and suture absorption is complete.

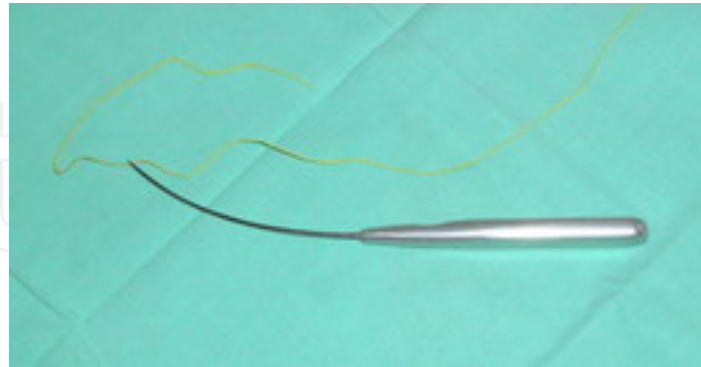


Figure 3. Curved, elastic, semi-blunt 50 mm or 60 mm Serdev® needle.

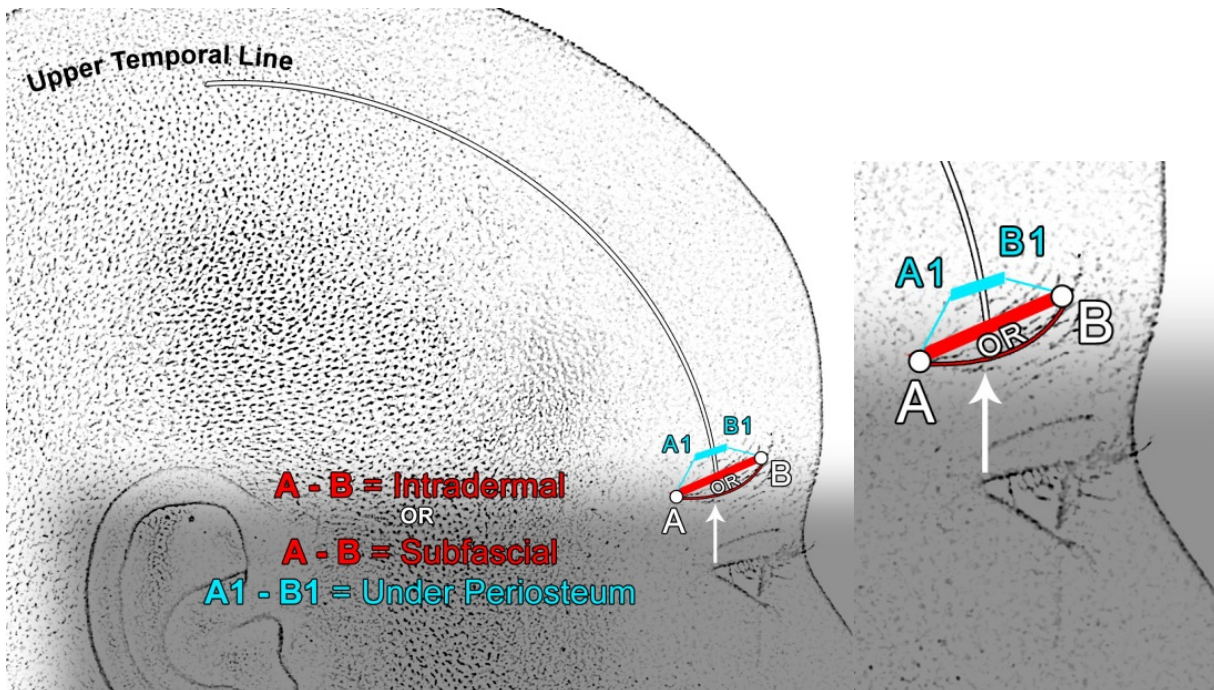


Figure 4. Semi-elastic, absorbable, braided, anti-microbial, polycaprocamide surgical sutures USP 0 are preferable and give best results.

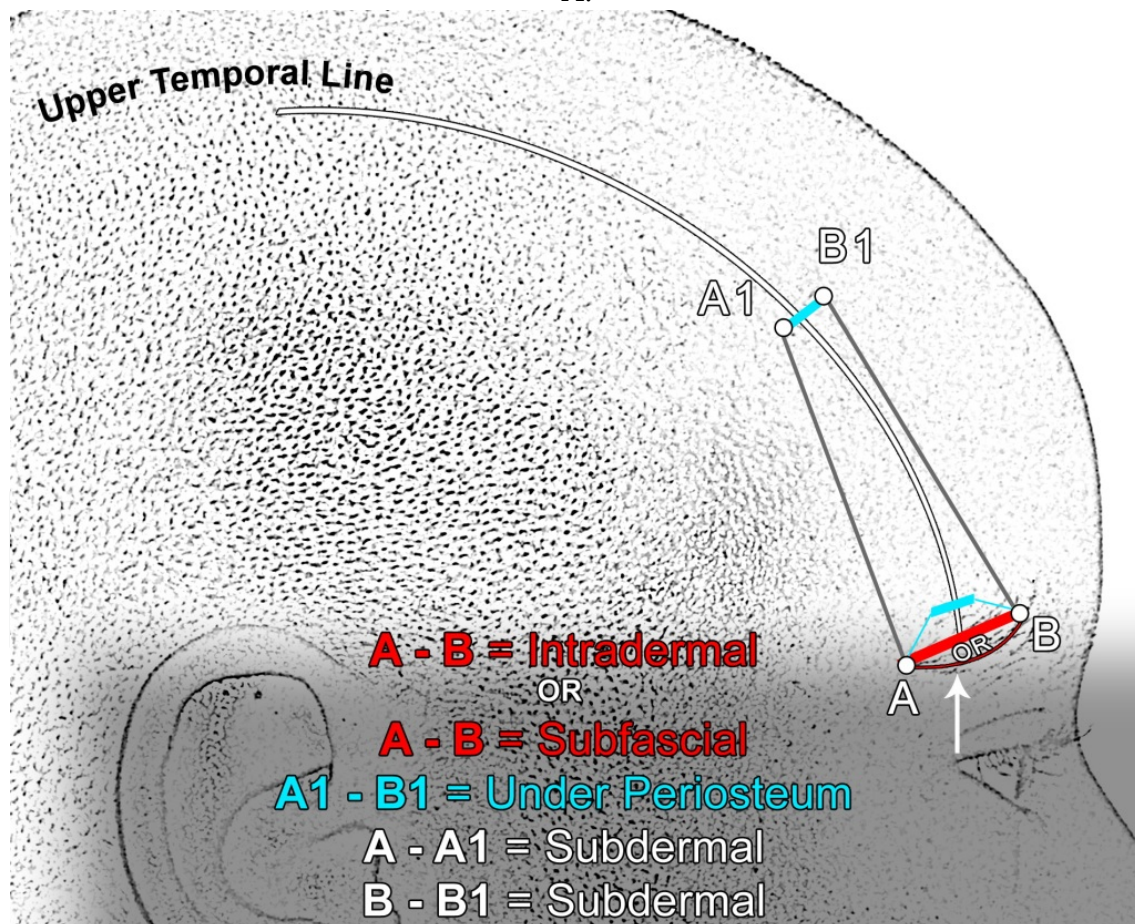
2.2. Method for scarless brow lift by suture

1. Fixation of the orbito-superciliar fascia to the periosteum of the upper temporal line, 1.5 cm above the orbital rim

To perform and accomplish the brow lift suture, the author uses 2 perforation points between the hairs of the brow, using the tip of a No. 11 scalpel blade. The perforation points are located on both sides of the intersection of the lateral canthus line and the eyebrow (Fig. 5A, B). The lateral canthus line is very important as the upper temporal line rim is located along this line, above the upper orbital rim. To position the eyebrow for artistic fixation, the forehead skin is pulled with a thumb placed 1 cm higher than the eyebrow, at the lateral canthus line. The maximum pull positions the eyebrow tail at the desired level of 1.5 cm over the upper orbital rim, without exception. **NB!** Do not pull the eyebrow itself, which is looser and more mobile - it will result in a wrong brow tail position. After local anesthesia, while holding the eyebrow lifted, a 50 mm Serdev® needle is introduced through the lateral skin perforation point A with the tip pointing down, slides down on the rough surface of the upper temporal line rim, taking its periosteum, and becomes fixed. **NB!** If the needle is not



A.



B.

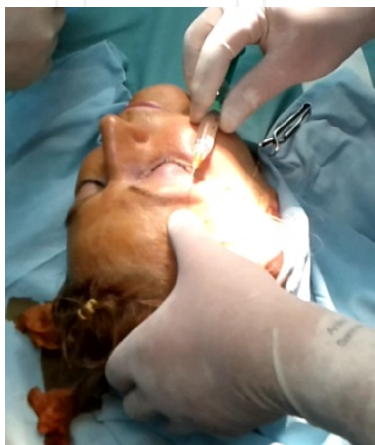
Figure 5. A. Eyebrow lifting by suture to the upper temporal line, 1.5 cm above the superior orbital rim.
B. Eyebrow lifting by suture to the upper temporal line at the hair line.

fixed and can be moved laterally, it is wrongly located in a superficial tissue plane and its position should be changed deeper subperiosteal. Turning the tip up, the needle exits through the medial skin perforation - point B. **NB!** Prevent dermis fixation. The needle should not feel any resistance when passing through the skin perforation points. This could be facilitated twisting the needle gently forward and backward. Do not push or pull. After threading the needle eye, the surgical suture is introduced and positioned through the first needle pass – stable immobile subperiosteal fixation. The second needle pass is done through the lower dermis layer between the points A and B at the lower eyebrow line. After exiting through point B and re-threading the needle, the second end of the surgical suture is pulled out through the second needle pass that presents fixation of the mobile orbito-superciliar fascia, found by the author to hold the eyebrow to the upper orbital rim. The knot of the suture is done under medium elastic tension. A symmetry check follows. Equal lift of the skin on both sides gives us symmetry in all cases. If even a slight asymmetry is noted, an additional suture is performed to solve it. Then, pressure is used to flatten the brow over the suture and stop any bleeding. Still using pressure, skin at perforation points A and B is pulled away from the suture with a mosquito clamp, in order to remove any dimpling. No bandages are necessary. A skin color tape is placed on the upper eyelid that stays on overnight to reduce (suck) swelling by the hypertensive quality of the glue.

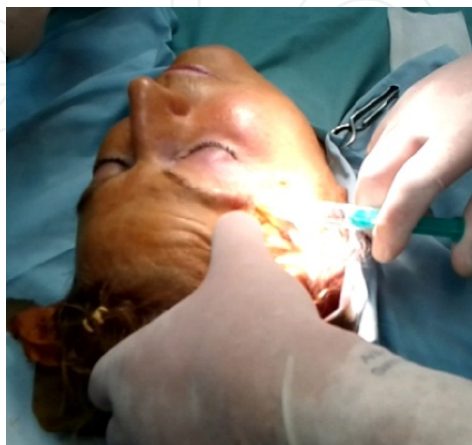Additionally, through a 3-mm medial brow incision, glabellar muscles can be excised or ligated.

Post-op care: Next day, tapes are removed from upper lids. Face washing is obligatory to remove residual blood. Swelling in the suture area and the upper lid is nearly invisible for observers. No bruising appears in 99% of the cases. Patients can return to social life. Wound disinfection should be performed several times in the next 2-3 days.

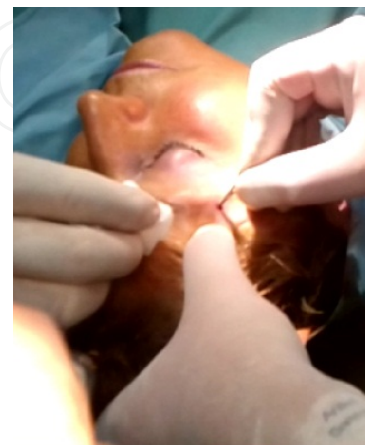
Video <http://www.youtube.com/watch?v=cLUf6-OrMPg>



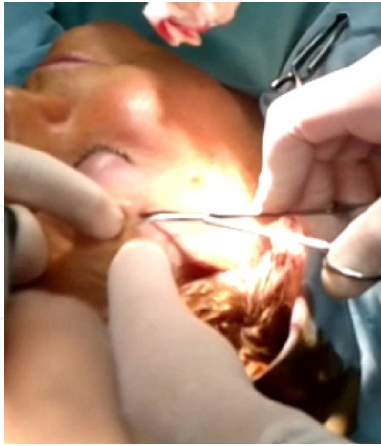A.



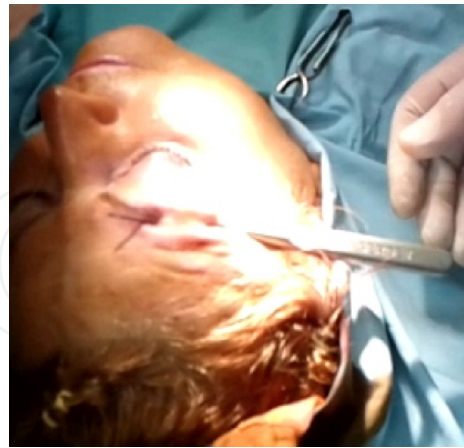B.



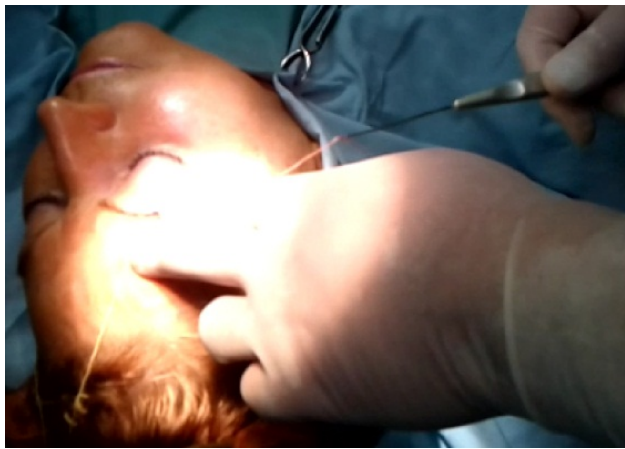C.



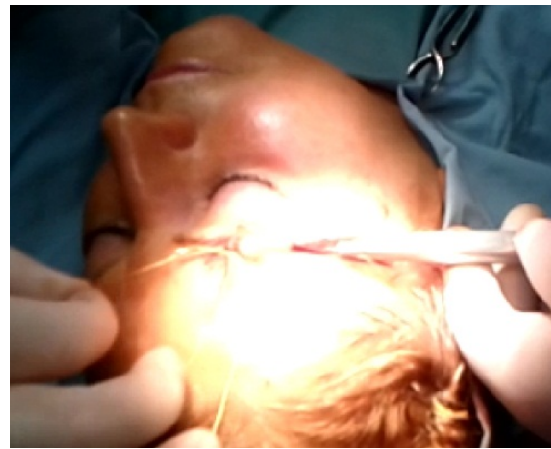D.



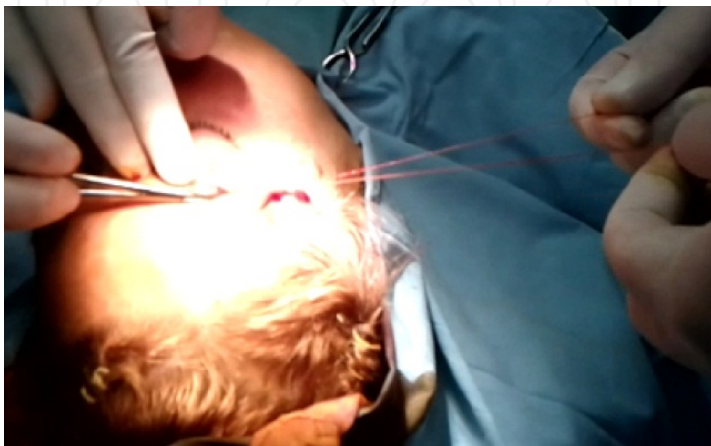E.



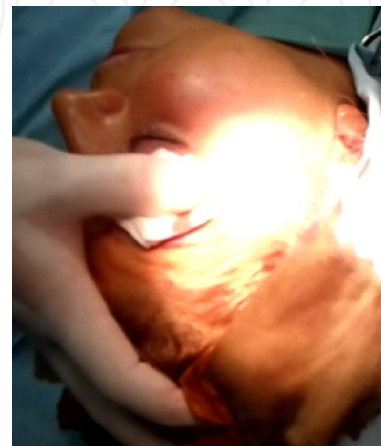F.



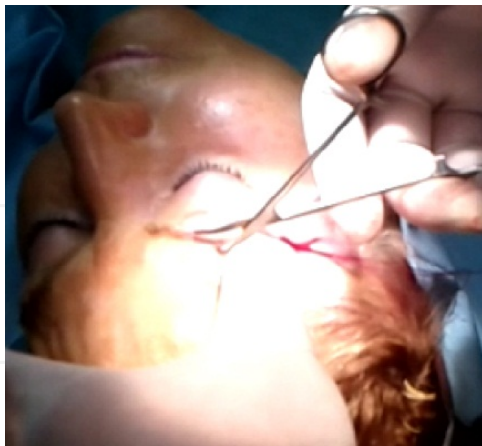G.



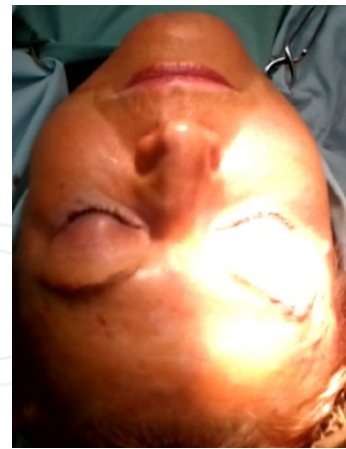
H.



I.



J.



K.

Figure 6. Steps of eyebrow lift by suture. **A.** The needle shows where the lateral canthus line is crossing the brow. Skin perforation points A and B are located on both sides of this intersection point. Higher, on the lateral canthus line, the upper temporal line (rim) can be palpated with the thumb. Locate your thumb on the rim, 1 cm higher than the eyebrow; **B.** Lift the eyebrow with the thumb maximally and hold the brow in this position. Infiltrate point A and B, then the periosteum between, and also intradermally. Use a small amount of local anesthesia, injecting a few drops per line, to prevent swelling; **C.** Still holding the thumb in the same position, perforate points A and B with a No. 11 blade; **D.** Perforate the subdermal fascia at points A and B with the tip of a thin mosquito clamp; **E.** Still holding the brow in maximum lifted position, introduce the Serdev® needle 50mm subperiosteally between A and B. To test for proper placement, release your hand from the skin and the needle. If the needle stays in the proper subperiosteal position without moving, it is properly fixed. If needle moves, repeat this pass subperiosteally; **F.** Load the needle tip and introduce the USP 0 surgical suture subperiosteally in the line B-A; **G.** Second A-B needle pass is just subdermal, just below the brow line i.e. below the Serdev orbito-superciliar fascia. Load the needle and introduce the second end of the surgical suture into the subcutaneous line B-A; **H.** The suture circle is finalized; **I.** Press for a minute and a half to stop any bleeding; **J.** Remove dimples at points A or B; **K.** The brow lift result is immediate. Perform the same steps the other side, holding the skin maximally lifted at the upper temporal line (rim), 1 cm higher than the brow. If the traction with the thumb is equal on both sides, the eyebrows will be lifted equally. Flex the head to check for equality.

2. Fixation of the orbito-superciliar fascia to the periosteum of the upper temporal line at the hairline

Rarely, the author performs eyebrow fixation to the upper temporal line at the hair line (Fig .5B) – Video: <http://www.youtube.com/watch?v=71n9oveGapc>.

It is more traumatic and the author uses it only if higher lifting of the eyebrows is requested and only if the particular face permits aesthetic proportions with higher eyebrow position.

This technique consists on: Subdermal suture pass A-B (just below the line of the eyebrow), in order to attach the mobile Serdev orbito-superciliar fascia; two Connecting subdermal passes – A-A1 and B-B1; and Subperiosteal pass A1-B1: immobile subperiosteal attachment to the upper temporal line

2.3. Clinical cases




Figure 7. A., B. Before and after brow lift by suture. A skin color tape is placed on the upper lid below the eyebrow to reduce swelling.

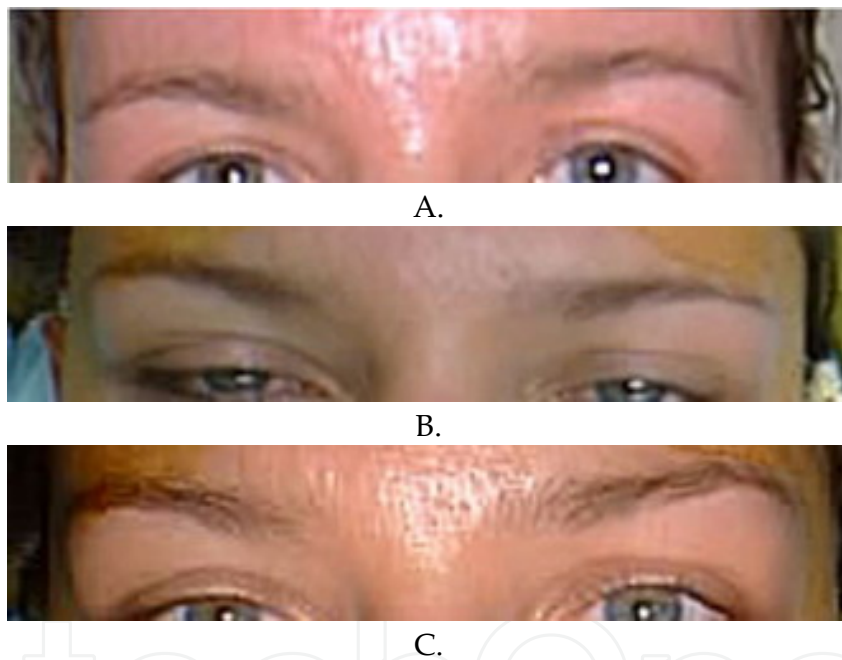

Figure 8. A. Before, B. Intraop: right eyebrow is lifted without visible scars. Visible lift of the lateral canthus of the right eye, C. After: both eyebrows are lifted at the end of the operation. No visible scars. No operated-on appearance. No down time.

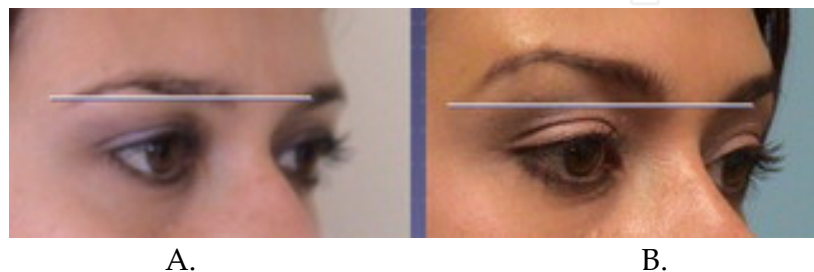


Figure 9. A. Before and after Brow lift by Serdev Suture®. Artistic lifting and positioning of the eyebrow in a young lady.

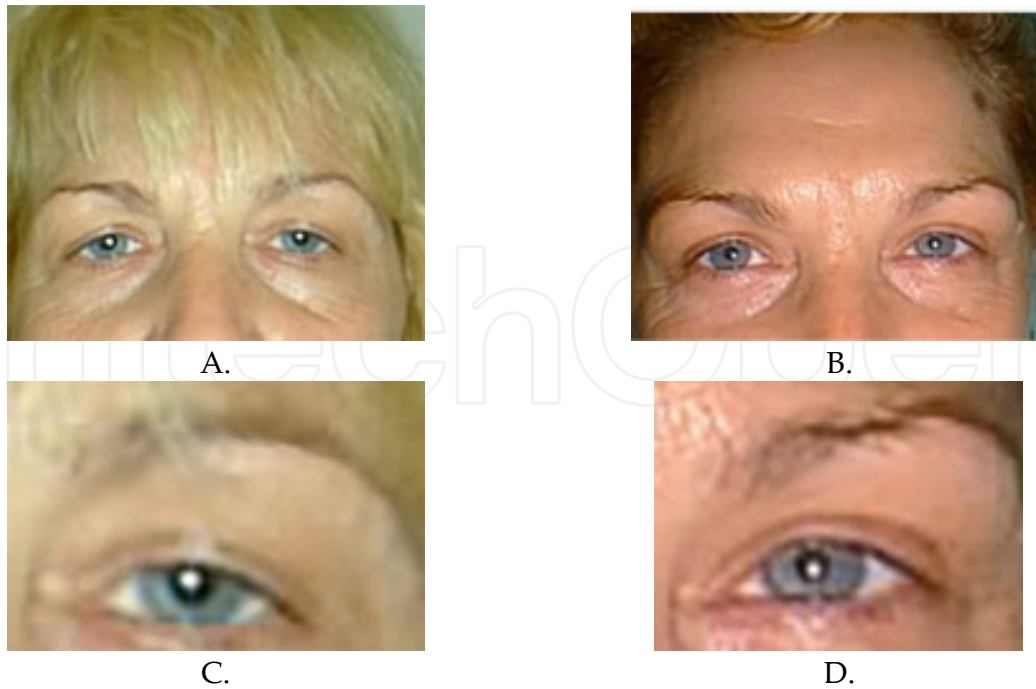

Figure 10. A., C. Before and B., D. 3 years after brow lift by suture. Visible lift of the eyebrow and lateral eye canthus.

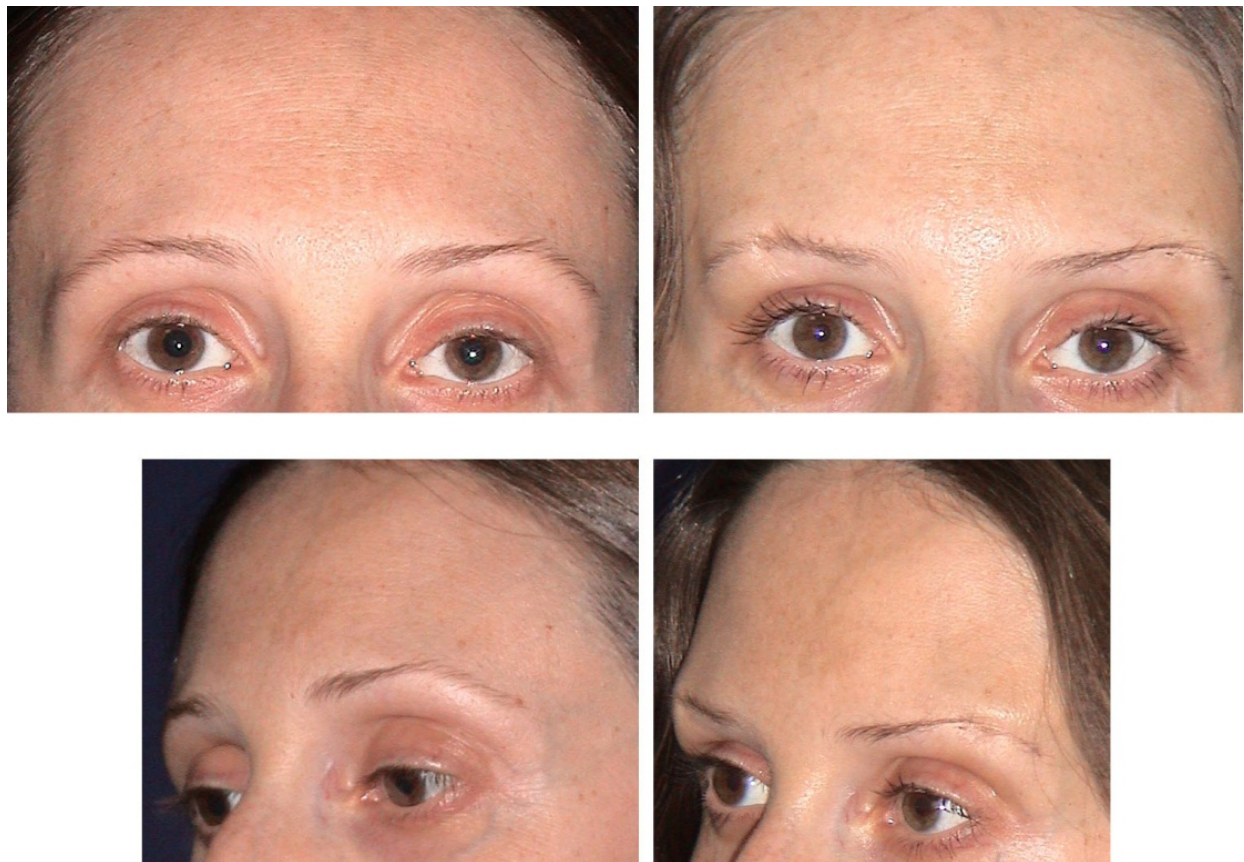

Figure 11. Eyebrow lift enhances appearance of the eyes.

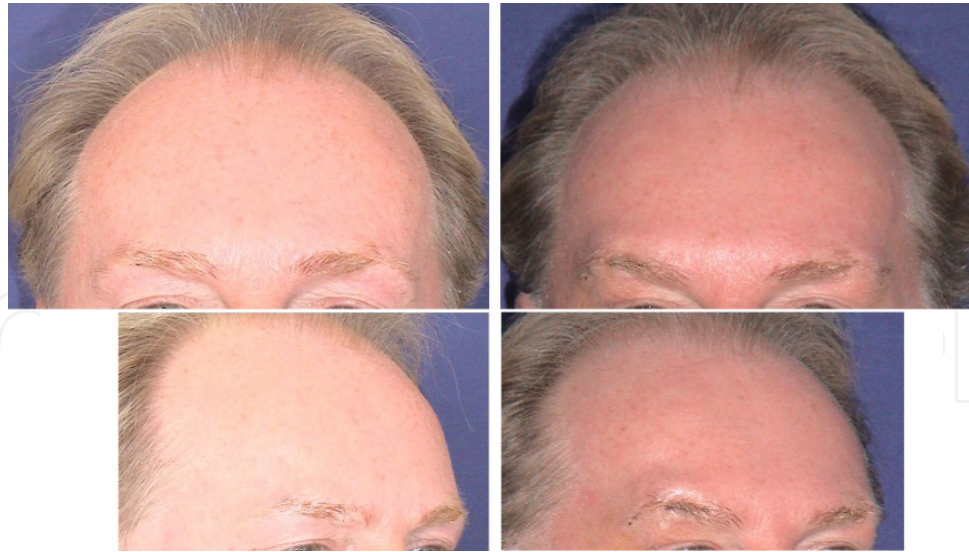

Figure 12. Lifted eyebrows solve the problem with proportions in high fronts and baldness.



Figure 13. Total face beautification in the above 22 years young female obtained by a combination of operations: Brow lift + Nasal tip and allar base narrowing by suture + Chin enhancement + Cheekbone lift – all done by sutures + nasal hump removal. Result 4 days after surgery.

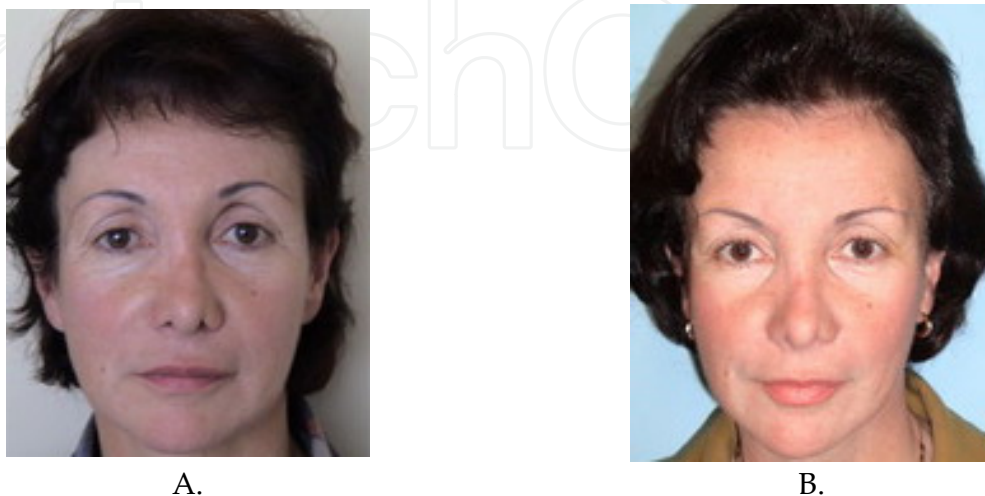

Figure 14. A. Before and B. After Brow lift and Temporal SMAS lift by suture



Figure 15. Beautification is mostly obtained by a combination of multiple operations – in this case: Brow lift + Chin enhancement + Chin dimple – all done by suture +secondary Rhinoplasty + Lip wy-plasty augmentation – immediate result

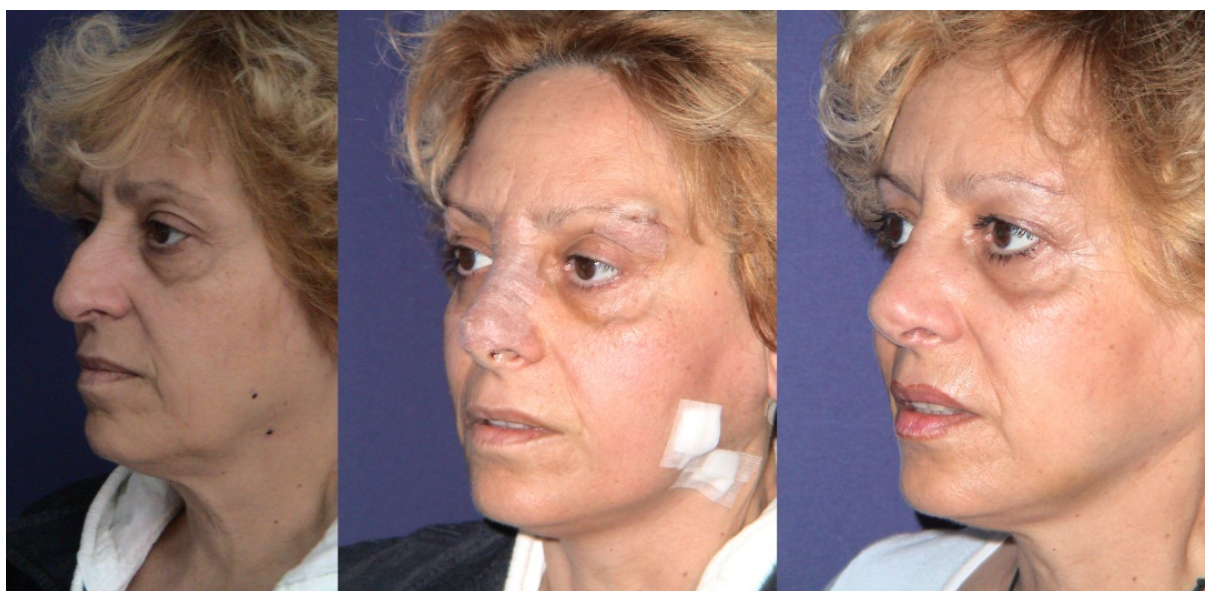

Figure 16. Beautification and rejuvenation obtained by a combination of operations: Brow + Temporal + Lower SMAS lifts by sutures + Rhinoplasty – Immediate and late result.




Figure 17. Total face beautification in a young male: Brow lift + Chin enhancement by sutures + Rhinoplasty. Brow lift in male patients has to be a bit lower than in female patients.

2.4. Results

During the period from 1994 to 2012, brow elevations using sutures were carried out in 982 patients. The follow up period varies from one month to 15 years. 96% of the patients reported excellent results, while 4% experienced good results. 68 % of the patients were followed during the first 5 years after surgery with very good rates of satisfaction. Only one 59 years old patient experienced aesthetic lack of satisfaction due to differences in appreciation of aesthetic proportions and angles in her age group. Complications were minimal – only 2 cases of infection in the lateral skin punctures which were treated by wound cleaning and disinfection for 2-3 days.

There were no instances of scarring, skin problems, or hair loss. The post operative period is characterized by a small percentage of swelling, no bleeding or bruising, no nerve injury, no scars, near to zero complications, immediate return to social life, preservation of facial expressive function.

In the patients with more than one year of follow up, the author has observed stable results and no ptosis was discovered with the years during follow up.

2.5. Complications

Two complications, infection in the lateral perforation point, 2 and 3 weeks after surgery, were treated by wound cleaning and disinfection and healed in 2 to 3 days. There were no cases of suture removal. No nerve damage has been noted in any patient.

2.6. Discussion

The purpose of this section is to present new trends in brow lifting philosophy and techniques.

There are a lot of procedures for brow lift that can have some negative effects for patients in modern society life: scars on the face that are only partially acceptable or non acceptable, asymmetries, increased tension across the healing wound, tension-related trophic skin changes, alopecia, paresis, ptosis etc. We can divide the proposed methods into invasive and mini-invasive surgeries. This chapter aims to describe an innovation in scarless brow lifting without any incision, without undermining but through suturing in situ the brow subdermal fibrous tissue and the orbito-superciliar fascia higher to stable periosteum, using special needles and skin punctures only between the hairs of the brow. The method was introduced in 1994, with protocol description and was presented around the world as a part of author's "fashion art" face beautification in young patients and for correction of ptotic eyebrow and rejuvenation. In his hands it has the following advantages compared to incision and excision methods: short intervention time (about 5 minutes per side), no visible scars, minimal trauma, immediate result, a short and easy post-operative period with immediate return to social life. The suture absorbs over the longer term – in 2-3 years, so that it remains until the fibrosis is finally completed in 6 to 18 month after surgery and disappears later. The results are long lasting and pleasing.

The brow lift by suture without scars is an effective and safe technique for beautification of the eye region and rejuvenation of the upper face, producing a natural result with minimal complications and high level of longevity. It is a beautification method, ambulatory, under local anesthesia and i.v. sedation, with immediate results and near to 0 complications. It is done without visible scars, preserves the expression, the movement of the brow, and also preserves the natural look. A combination of local anesthesia and intravenous sedation provides excellent patient tolerance and comfort, both intraoperatively and postoperatively. Postoperative recovery is uneventful. Complications are very rarely encountered.

The eye-eyebrow region is the center for facial expression. The position of the eyebrows expresses emotion and even a minor change in brow position can be important for the understanding and contact between individuals. Lifting the eyebrows can change the expression into a more pleasant, young and natural one. We believe that this technique provides a more permanent and stable result. This brow lift method can be one of the most beneficial surgical procedures in cosmetic surgery. This very simple procedure allows lifting in any degree and elevation of any brow point. It supports the upper lid with lateral face improvement. It may be utilized for eyebrow ptosis alone or for fashion beauty, whether unilateral or bilateral; in conjunction with other suture techniques for equalizing asymmetrical eyebrows and for further support of markedly ptotic upper lids. It has been used by the author in instances of facial paresis or paralysis in conjunction with other procedures in the face to accomplish better symmetry. The stable duration of results with this procedure depends on the tissue quality and healing, the non-traumatic surgical technique, care given to the area during healing by the patient, amount of frowning and vigorous facial muscle use by the patient, and aging. It is a useful adjunct, especially when used with temporal SMAS lift, other suture methods on the face, beautification rhinoplasty etc. to adjust proportions, volumes and angles for beautification and rejuvenation of the individual's face.

The author's experience indicates that this specific method of scarless brow lift by suture adds a great deal to appearance and satisfaction. The procedure has taken its place as an integral part of facial beautification and rejuvenation.

3. Temporal SMAS lift

Since Mitz and Peyronie described the superficial muscle-aponeurotic system, or SMAS, in 1976, the SMAS facelift has become common and has risen into an operation to which others are compared. The author's concept to lift the whole SMAS in temporal direction is realised using the scarless Serdev Suture® method for changing the "mask of tragedy" into the "mask of comedy" in cases of beautification, soft tissue laxity, early facial ptosis and revision facelifts.

The temporal SMAS lift by suture was started in 1990 using traditional surgical instrumentarium. The author's needles and semi-elastic surgical sutures were introduced in 1993. In 1994 the author firstly reported his concept of a scarless ambulatory temporal SMAS lift by sutures, as lifting of the suprazygomatic SMAS with effect on the infrazygomatic SMAS, i.e. the whole SMAS. It became a routine ambulatory procedure for beautification and rejuvenation, presented and demonstrated around the world.

Since soft tissue and skin are attached to the SMAS in the temporal region, the lifting of the SMAS in temporal direction reflects in lifting of the face and its most important elements in the same direction (Fig. 18). It affects the lower face as well.

Anatomic landmarks for this method are: 1. The upper temporal line; and 2. The crosspoint (intersection) of the upper temporal line and the coronal line.

The aim of this method is to obtain beautification in patients of any age and rejuvenation in elderly, using minimally invasive cosmetic surgery procedures. It is performed in the ambulatory setting under local anesthesia with i.v. sedation. It is scarless with immediate results and near to 0% complications.



Figure 18. Mechanism of temporal SMAS lift – lifting of facial fascial mask (upper SMAS). Effect on facial structures. Transforming the old appearance into a young one. In ancient theater these masks are known as “Mask of tragedy” and “Mask of comedy”.

Same idea of a temporal lift is easily created in any lady’s mind, beautiful or not (Fig.19).




Figure 19. Ladies with no exception are thinking about temporal lift of the face.

With age, cranium volume shrinks and ptosis is reflected in the SMAS, which we can name Loose SMAS, and skin laxity changes expression into a sad and tired one. On the other hand, re-positioning of face elements could be used without restriction in face ptosis of the elderly. Aesthetically wrong face angles make young people look sad. Fixing the SMAS in a

higher position allows repositioning of other soft tissue facial structures, fixed to SMAS. In young patients, the aim of the temporal SMAS lift is beautification, based on facial aesthetics.

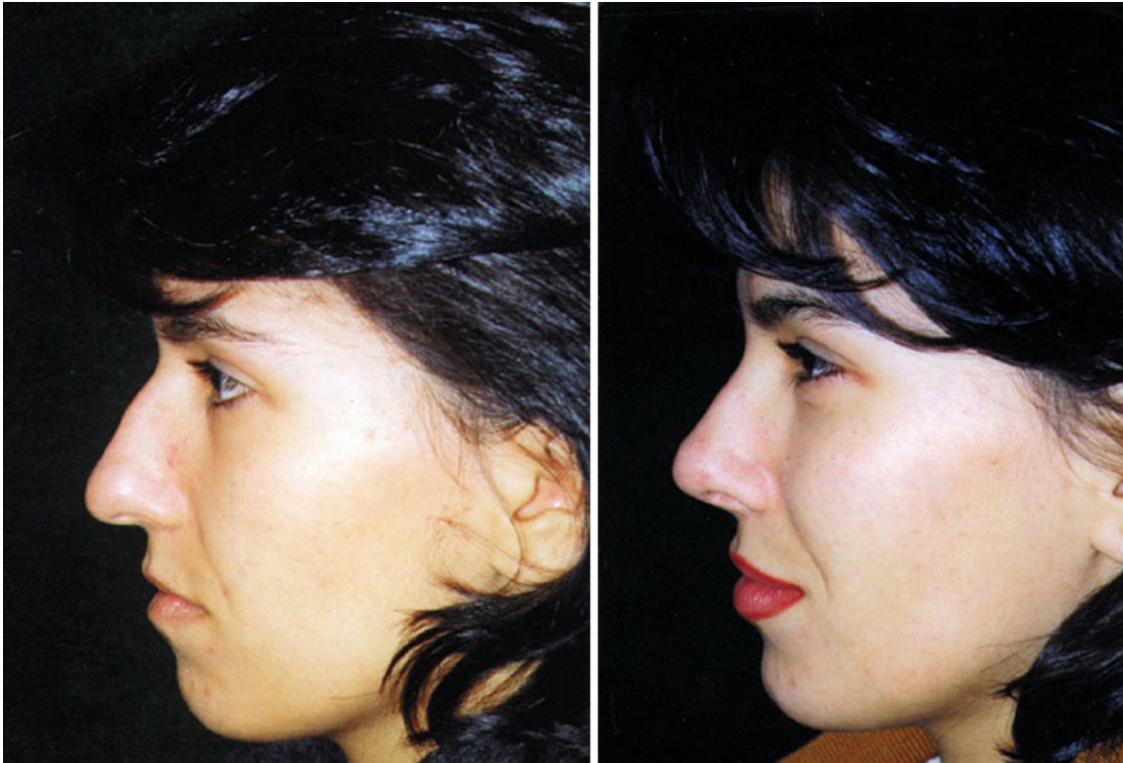

Figure 20. Before and after surgery. Temporal SMAS lift changes hanging eyebrow tail, lateral canthus angle of the eye and oral commissure. After: Better expression of cheek-bone prominence, due to the lifting of the skin and the fat pad. Additional rhinoplasty is made to correct the “golden section rule” of facial proportions in 3 equal parts; Lip augmentation to equalize lip and eye volume; Chin augmentation to obtain the “beauty triangle” and the straight line of the profile. Embellishment of the face is obtained and “smiling” expression is present (“mask of comedy” = fresh and young look).

3.1. Anatomic description of the temporal area and the SMAS

The SMAS is spread from the vertex to the platysma. It lies superficially to facial nerves. The SMAS acts as a suspension for the overlying facial skin and distributes forces of facial expression.

The Galea aponeurotica, as the upper part of the SMAS, is a muscle-aponeurotic tissue and extends from the vertex to the brow and the zygoma. It is named “superficial temporal fascia” as well, but it does not cover the temporal area solely. The temporal region, or “temporal pocket”, is located over the temporal muscle, bordered by the superior temporal line above, by the lateral orbital rim in front, and by the zygomatic arch below. The layer, covering the temporalis muscle, is a bright and thick aponeurosis, the Temporalis Fascia, named also (wrongly) “deep temporal fascia”. Both galea and temporal fascia are described with different names that causes confusion. At the level of the superior orbital rim, the temporal fascia (or “deep temporal fascia”) splits in two layers: Superficial and Deep layer of the temporalis fascia (or /wrongly/ “deep temporal fascia”). These two fascial layers:

Superficial and Deep layer of the temporalis fascia enclose intermediate fat, including nerve and vessels. An important landmark in the temporal region is the superficial temporal artery that can be easily palpated along the hairline. The vein follows the same pattern. The frontal branch of the facial nerve, which innervates the frontalis muscle, the orbicularis oculi and corrugator supercilii lies in the intermediate fat interposed between the deep and the superficial layer of the temporalis fascia (or /wrongly/ “deep temporalis fascia”). It is considered to travel along a line connecting the base of the tragus to a point 1.5cm above the eyebrow.

3.2. The procedure

The concept of the scarless closed approach transcutaneous temporal face lift by sutures is to lift loose mobile galea and to fix it to stable immobile upper temporalis line periosteum and temporalis fascia. Skin fixed to the galea follows this repositioning in temporal direction that reflects in face lifting. To obtain such lifting, special curved semi-blunt, semi-elastic Serdev® needles with different lengths of 50 mm, 60 mm and 100 mm are used to introduce long-term absorbable, semi-elastic, braided, antimicrobial Bulgarian polycapromide (Polycon) surgical sutures USP 2 or 4. Other surgical sutures could be used, but the short elasticity quality of the Bulgarian suture reduces trauma to the fixated mobilised tissues. Rigid thin USP 2/0 threads work as a scalpels to mobile tissue, when under tension.

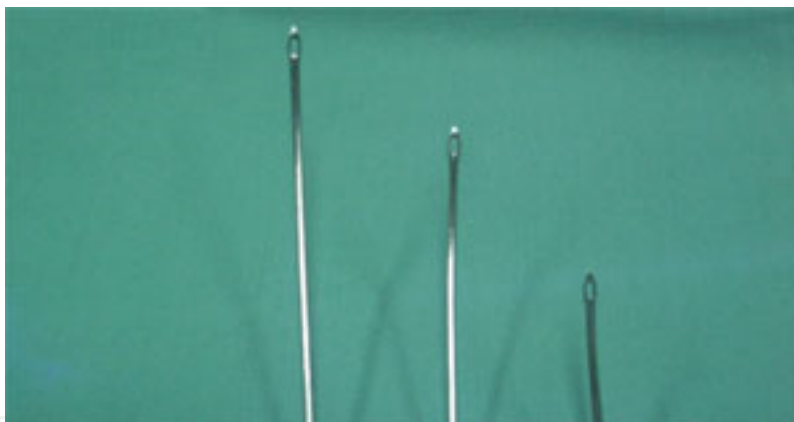

Figure 21. Curved semi-blunt and semi-elastic needles 50 mm, 60 mm and 100 mm

3.3. Surgical method

Video: <http://www.youtube.com/watch?v=qFF3lr9jHqs>

1. Using needle perforation only - without skin incisions

1a. First Temporal SMAS Lift Suture

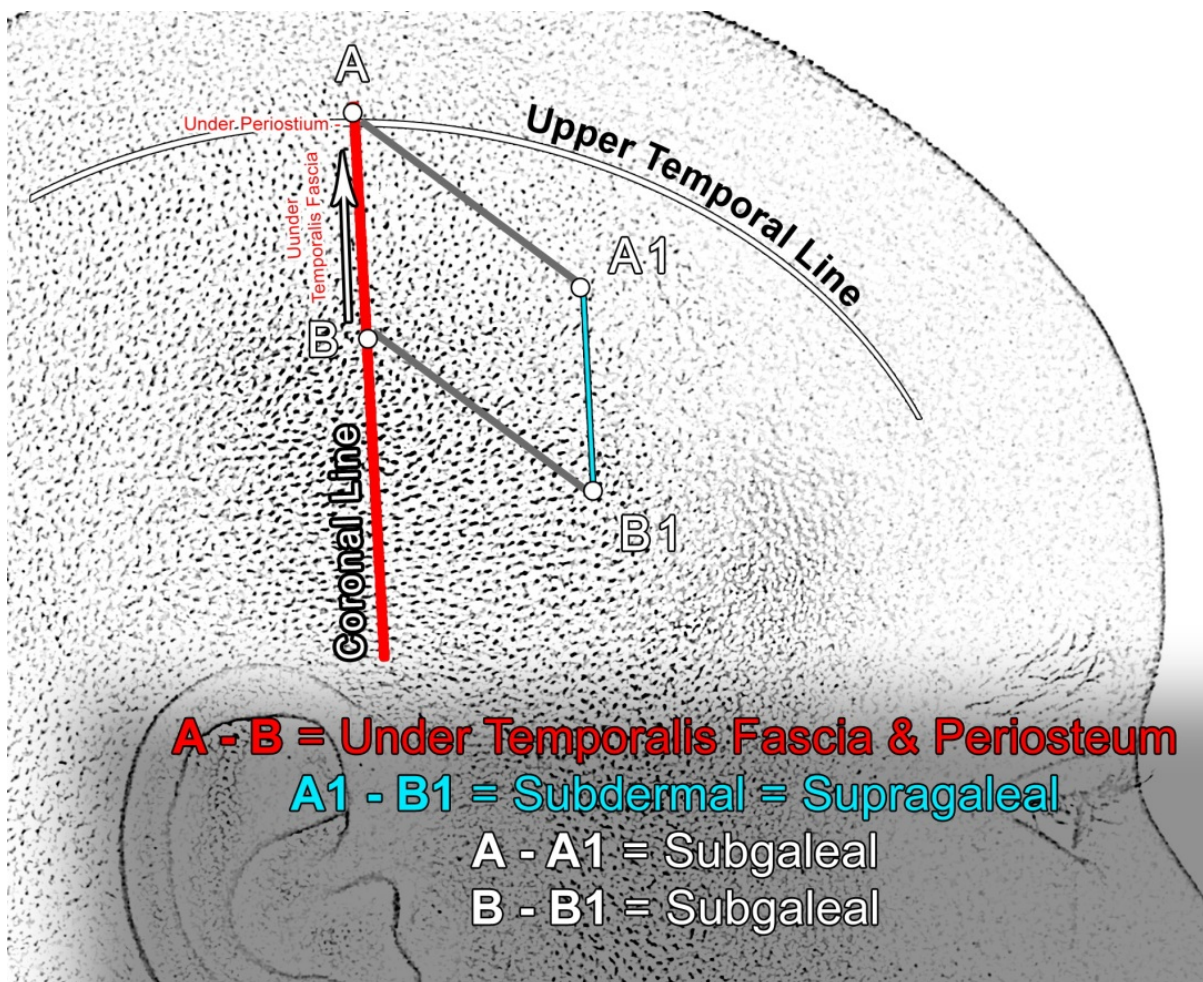
Two lines A-B and A1-B1 are marked as parts of a rhombus inside the temporal area (Fig. 22 A). Line A-B represents the subperiosteal (upper temporal line) and subtemporal pass of the suture. Point A is located above the intersection point of the upper temporal line and the coronal line and point B is marked about 3-4 cm below at the coronal line. Starting from A, a

line A-A1 is marked in 45 degrees angle to the line A-B in direction to the eyebrow tail. Point A1 is located at the end of that line in a distance from A, depending on the laxity, usually at 3-5 cm away from A. Line A1-B1 is the line of supragaleal fixation of SMAS. Lines A-A1 and B-B1 are subgaleal passes of the suture, connecting the two fixation lines. They mark the direction of movement of the galea to temporalis fascia. In cases of a very loose SMAS, mostly in elderly, it is advisable to perform a second suture, lower than the first one, to lift the medial and lower facial SMAS and soft tissue.

The wide spread temporal fixation (to temporal fascia) is not advisable, because temporalis fascia fibers are perpendicular and cannot hold a suture fixation with tension in distal direction. The suture will slide down and the lift will lose on longevity (Fig. 23).

1b. Second (Lower) Suture for Temporal Lift

A second line of galea fixation A2-B2 (below A1-B1) is marked (Fig. 22B) and a second suture is performed. in cases when laxity in the lower face is still presented after the first suture, mostly in elderly. The needle and surgical suture are introduced as follows: A-B – subperiosteally/subtemporally at the upper temporal line; A2-B2 – supragaleally; A-A2 and B-B2 – subgaleally.



A.

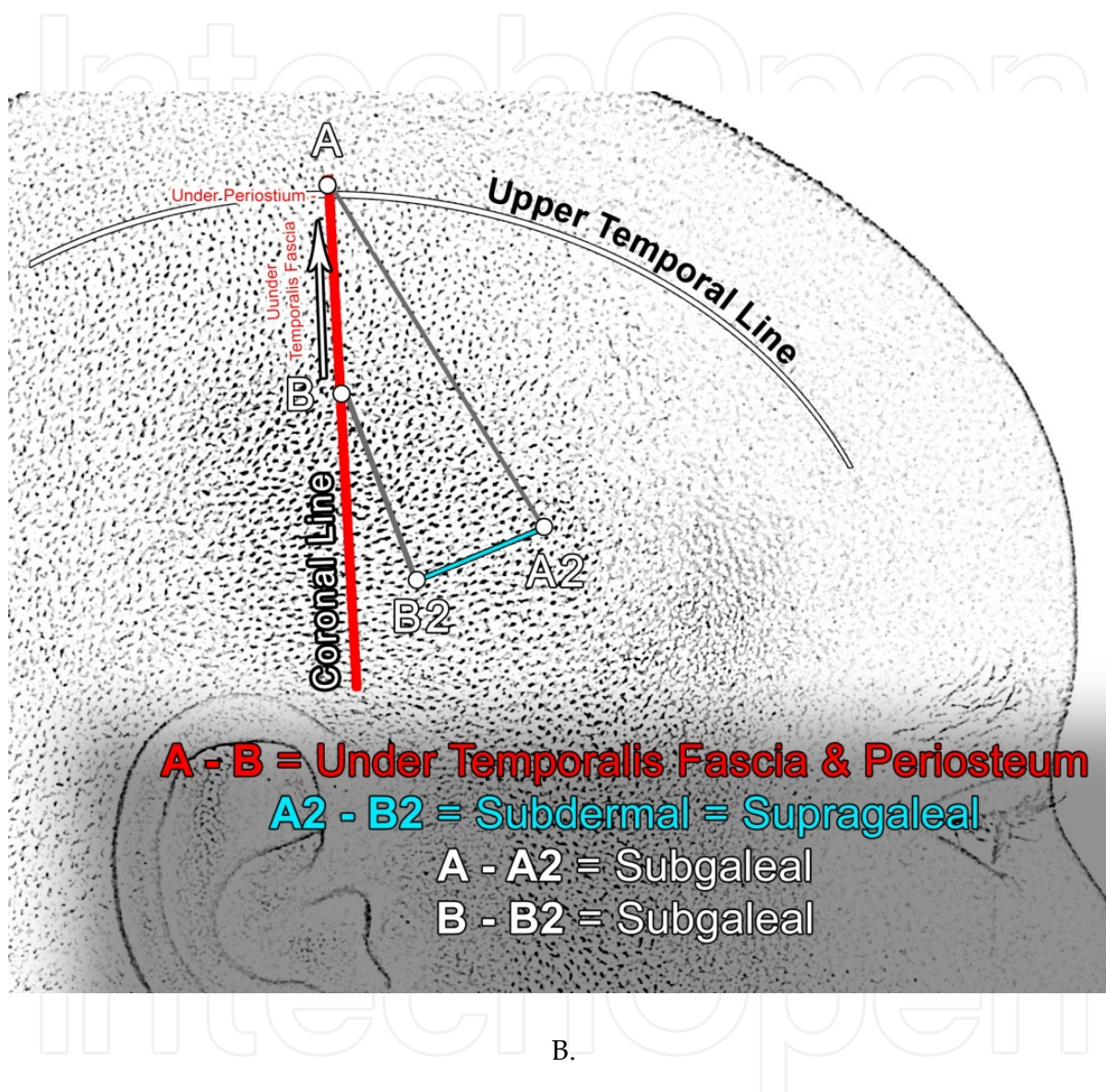


Figure 22. A. Upper temporal line and coronal line are marked. The upper immobile fixation - subperiosteal (upper temporal line) and subtemporal pass of the suture (3-5 cm in the coronal line) is marked in red color. Line A1-B1 of supragaleal SMAS fixation will be lifted and fixed to A-B line of subperiosteal and subtemporal fixation. **B.** Same with the second lower suture in elderly: line A2-B2 of supragaleal fixation will be lifted and fixed by the suture to A-B line of subperiosteal and subtemporal fixation. Line A-A1 in direction to eyebrow and line B-B1 in direction to the cheekbone are subgaleal passes only. Lines A-A2 and B-B2 in direction to the lower face are subgaleal passes as well.

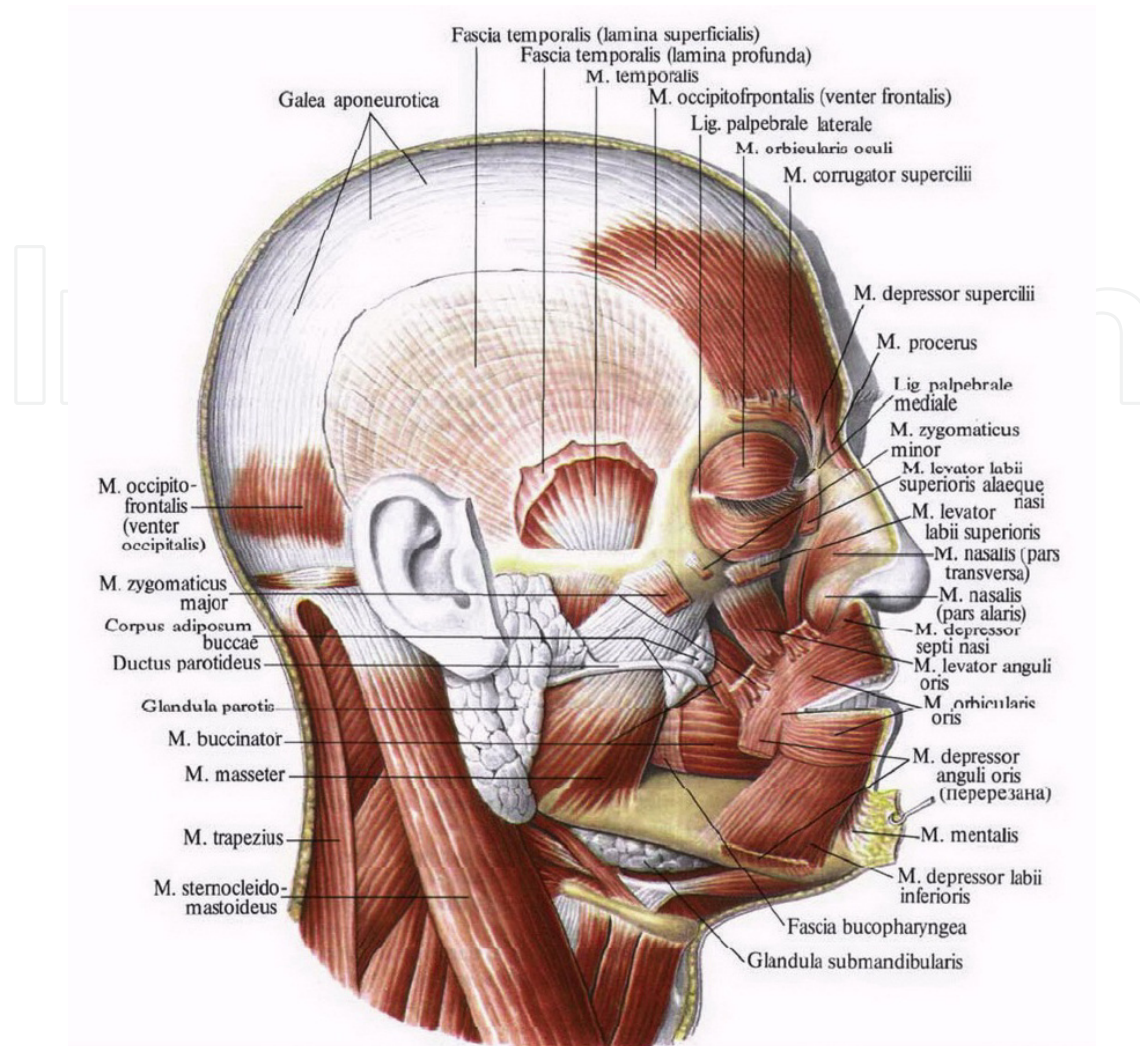


Figure 23. Temporal fascia fibers* are in distal direction and cannot hold the suture if the fixation is not attached to upper temporal line bone and periosteum. *Anatomy figures from Sinelnikov - Atlas Of Human Anatomy, GIML, Moscow, 1963

After local anesthesia, a No. 11 scalpel blade is used to make skin perforations at points A, B, A1 and B1. The order of needle entries should be convenient to right or left handed surgeons and could be as follows: the needle is introduced supragaleally in line A1-B1, just under the skin (between skin and galea, where a thin layer of subdermal fat allows to pass without any resistance). After threading the needle, the surgical suture is introduced in the A1-B1 supragaleal plane. The next subgaleal passes are directed from A to A1 and from B to B1 to take the suture ends. The final A-B pass is through the bone of the upper temporal line, subperiosteally and subtemporally. So, we have 3 levels of needle passes i.e. 3 levels of positioning of the surgical suture in the tissue: A1-B1 is supragaleal/subdermal (mobile fixation), A-A1 and B-B1 are subgaleal, and A-B – subperiosteal and subtemporal (immobile fixation). The location of the needle in each level has its characteristics. In the subdermal plane, the needle is not fixed by stable tissue – it is movable laterally and is covered only by a thin layer of skin. In the subgaleal plane, the needle is introduced deeper (in the tunnel of the lifted skin and galea, fixed together), and is mobile laterally again (Galea is mobile), and is covered

by a thicker layer that includes skin, subdermal fat and galea. As galea is fixed to skin in that region, pulling of skin like a tunnel pulls galea as well and subgaleal entry in that tunnel is made easy. In this plane, one has to avoid taking temporalis fascia that is located below the needle. If temporalis fascia is captured with the needle, movement of the needle is impossible without movement of the entire head. Such fixation is incorrect and the needle has to be repositioned. **NB!** The needle should pass through all 4 skin perforations, in and out (or vice versa), without biting any dermal tissue, so as to prevent dimpling. The suture should not invert hair into the subdermal plane, in order to prevent foreign body reaction. When tightening, the suture dives in the subdermal tissue. Skin should not be engaged in the suture. When the circle of the suture is finished, a knot is made under medium elastic tension. The idea is to prevent trauma of the tissue. After the knot is tightened, a mosquito clamp is used to pull the skin perforations away from the suture, in order to free the skin and reduce dimpling at the perforation points. Some bulging effect (due to suture and edema) will disappear in a month, but is not visible in the temporal area, which is covered by hair.

2. Using a minimal, hidden skin incision in the coronal line:

In the very beginning, the author was using a 3 cm temporal incision in the coronal line A-B, which, working under visual control, is more comfortable for beginners to perform the subperiosteal and subtemporal fixation. In this technique we start with anesthesia and make a 2-3 cm long A-B incision along the coronal line. The skin and subdermal fat are opened and the red vascularised galea below becomes visible. After the galea is opened with a mosquito instrument, the white shiny temporal fascia is presented (Fig. 24).

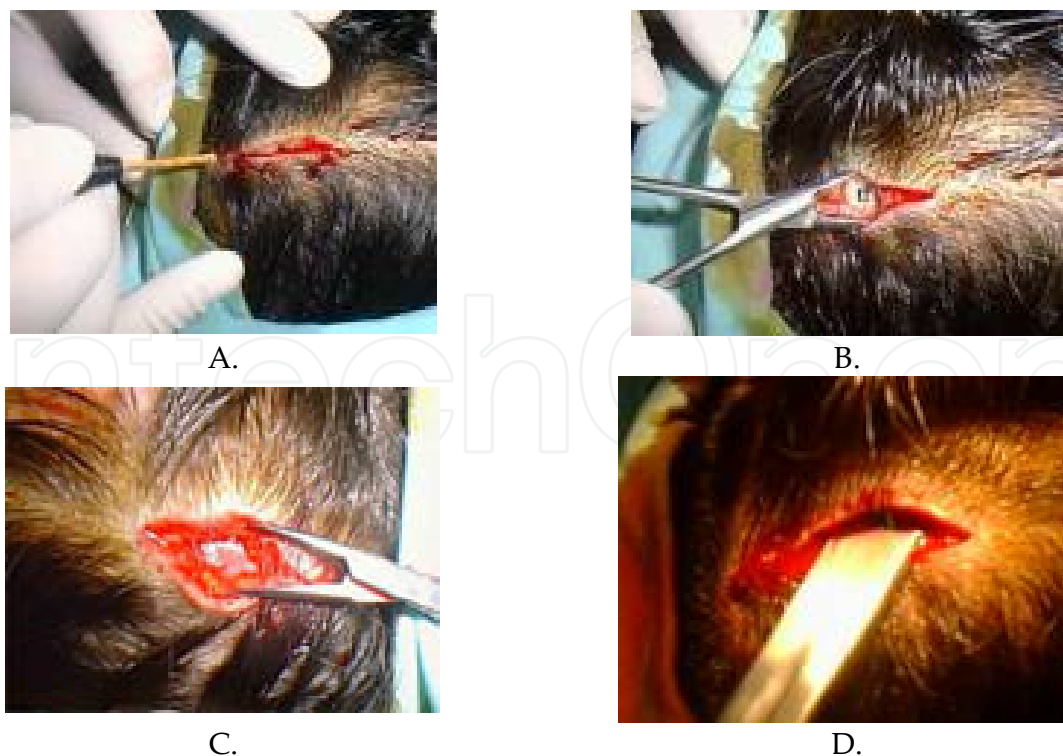
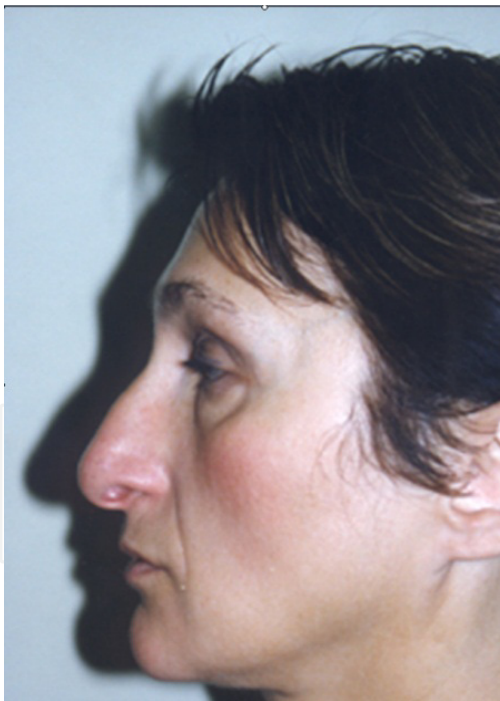

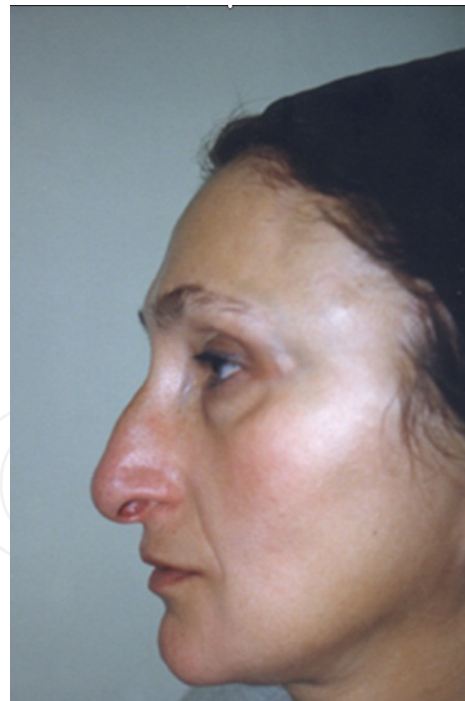Figure 24. A. Skin incision, B., C. blunt opening of skin and red galea; then white, shiny temporal fascia is visible, D. Blunt dissection between galea and temporal fascia.

A blunt subgaleal dissection follows till the hairline. It should be very easy because there is no stable fixation between these two fascias – galea and temporal fascia. Further, the same surgical technique is done as described above. Lines A-A1 and B-B1 are subgaleal passes of the suture, done under visual control, A1-B1 is a supragaleal i.e. subdermal pass, and A-B is a subperiosteal and subtemporal pass under visual control as well. A very important part of the technique is prevention of hair insertion with the suture loop into the subdermal plane that will lead to granuloma formation and local infection. Deep biting of the temporal muscle instead of a subfascial pass should be avoided to prevent pain, which is described by patients as headache. The galea, presenting the SMAS, is pulled up and fixed higher to the upper temporal line with one or two sutures on each side, under elastic tension. Thus, the whole SMAS is pulled up in temporo-occipital direction. Following this, the skin is closed with single stitches and no dressing is necessary. A hair wash is recommended on the next day to remove any residual blood. Wound stitches are removed after 7 days.

3.4. Clinical cases

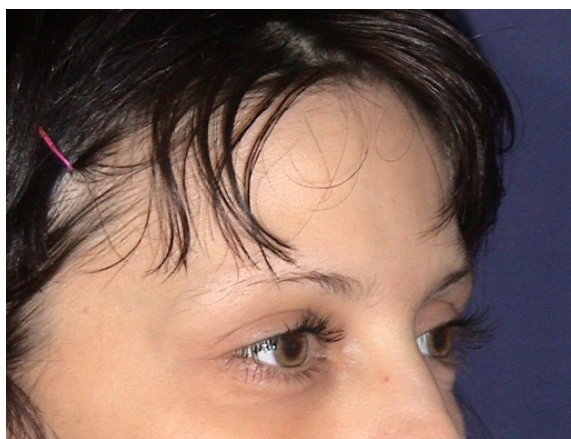

A.

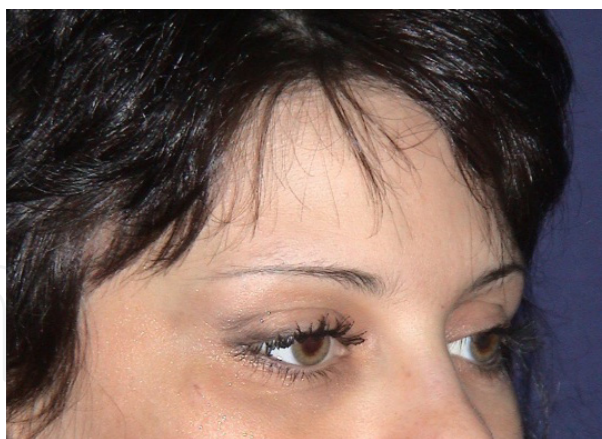

B.

Figure 25. A, B. Before and after a temporal SMAS lift. Visible elevation of the eyebrow tail and the lateral canthus of the eye, reduction of the crows-feet wrinkles, elevation of the cheeks' fat pad into a better cheekbone prominence; tightening, better texture and beautification of the skin.

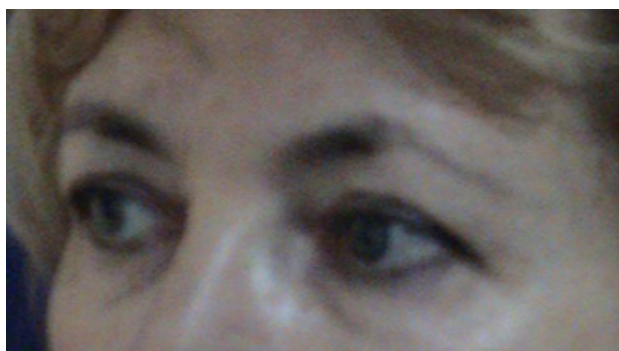


A.

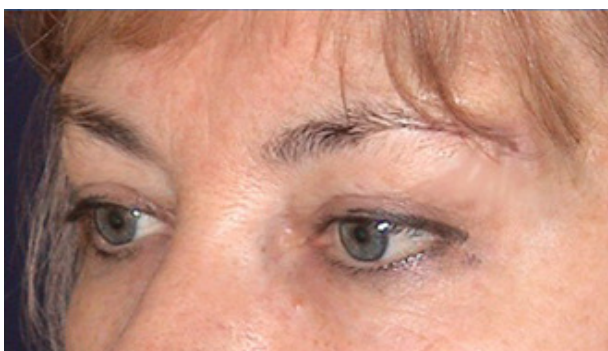

B.

Figure 26. A. before, B. after a temporal face lift in a young patient using Serdev Suture®. Angles of the eyes and eyebrows are changed, resulting in beautification.



A.

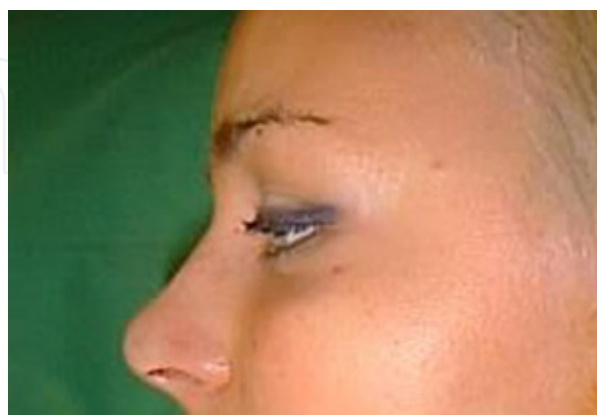

B.

Figure 27. A. before, B. after a temporal face lift using Serdev Suture® in an elderly patient. Angles of the eyes and eyebrows are changed resulting in rejuvenation and beautification.



A.



B.

Figure 28. A, B. Before and immediately after a temporal SMAS lift and tip rotation rhinoplasty. The absence of visible signs of operation permits immediate return to social life. Rhinoplasty in the author's technique does not need tampons and plaster fixation. No bruising when tip rotation only.

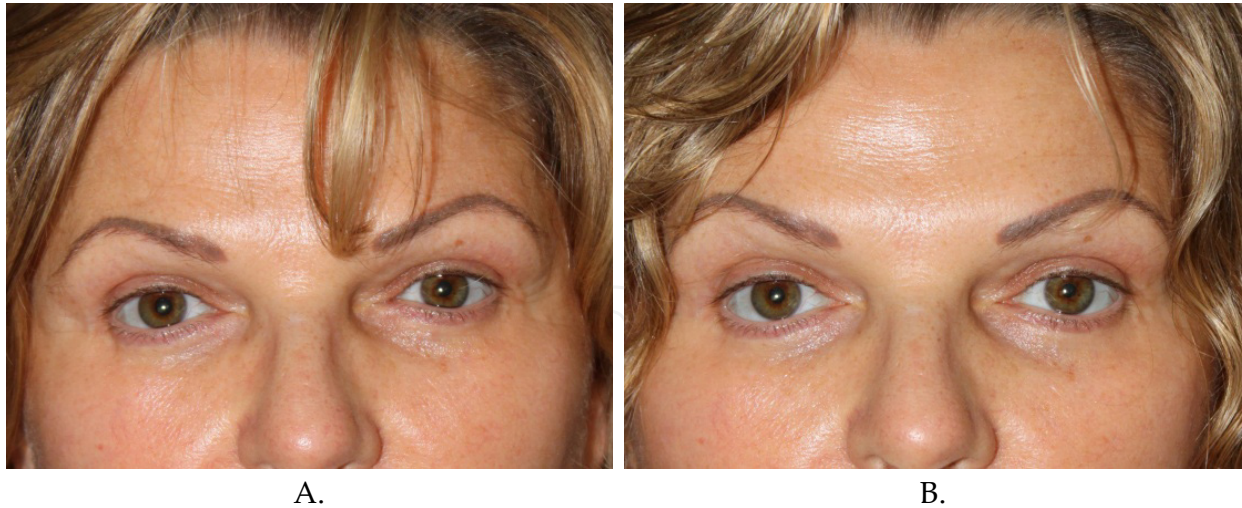


Figure 29. **A.** Before. Asymmetric ptosis of the face with aging, **B.** After a temporal face lift using Serdev Suture®. The whole face is lifted resulting in beautification and rejuvenation, solving the different flabbiness on both sides. The face symmetry is equalized.

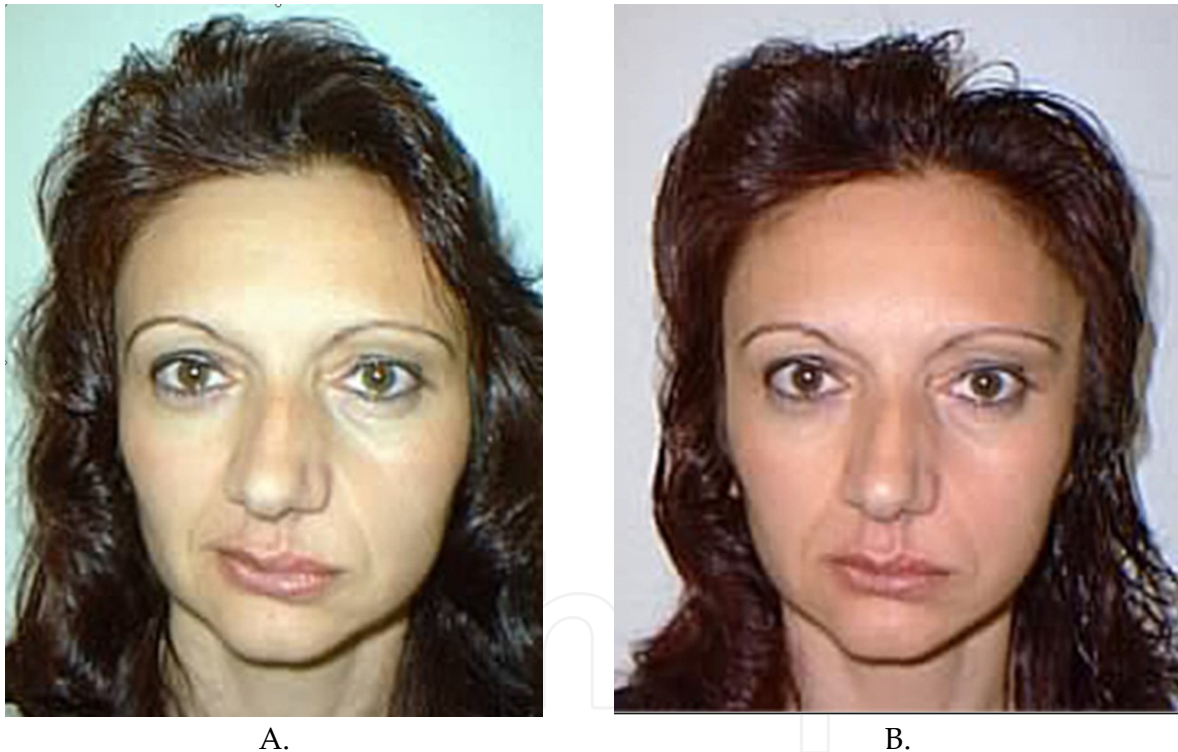

Figure 30. **A, B.** Before and after unilateral temporal SMAS lift in facial paralysis. A 4-years result. The whole left side is elevated and the nose is repositioned in the middle by the temporal SMAS lift. Further equalization is possible using mid-face and cheekbone lifts, as well as chin movement to the left (see mid face and lower face chapters).

3.5. Results

1427 patients were followed up for more than 3 years, operated from 1993 to 2001, using the Temporal lift suture method, firstly with a minimal incision in the coronal line and later

with needle perforations only. Patients' age ranges from 19 to 68 years. The operation was performed in ambulatory settings. After washing and styling the hair, patients could return to their social life next day, if necessary on the same day.

The temporal SMAS lift has effects on the suprazygomatic area: it reduces the lateral and forehead wrinkles; raises the eyebrow tails and the lateral canthus of the eyes; reduces the crow's-foot wrinkles, raises the cheekbone prominence and tightens the skin. The effects on the lower face are collateral. The SMAS elevates the lateral canthus of the eyes, and the oral commissure. It improves the skin texture, reducing cheek flaccidity; gives a clearer outline of the jaw. Generally, the method gives excellent results in younger and middle aged patients whose lower face flaccidity is minimal to medium. The facial tissues are repositioned to the desired higher youthful location. The temporal hair is preserved. There are no visible scars, no signs of operative intervention, and no "operated-on" appearance. A moderate feeling of tension in the face could be present for hours or days. The feeling is mostly pleasing. Only 7 patients described the tension as uncomfortable for one or two days. During the first week 12 patients reported headache. Lower eyelid swelling could appear on day 3 after surgery due to gravity and should be prevented by resting in supine position during the first two days. Five patients had lower lid bruising on the 3rd day on one side and four other patients – on both sides. Seven patients reported a crust formation with liquid under the crust. The reason was subdermal position of hair by the suture sling. After hair removal, the wounds healed in approximately two to four days. One patient had the same problem in another country and the surgeon removed the suture. Due to the fibrosis formation, no ptosis appeared after removal of the suture. No other infections, no hematomas or damage on the facial nerve were observed. Some palpable bulging in the temporal area could be present for some weeks. Most important in face lifting is its longevity. Numerous factors act against face stability, such as gravity and facial movements. The longevity of the result is improved due to the SMAS fixation to periosteum. This is best seen years after surgery in cases of a unilateral temporal SMAS lift in facial paralysis, post traumatic and postoperative canthal abnormalities etc. (Fig. 30). Two patients could not see the difference, despite the photograph demonstrations, contesting the aesthetic result. The effect of lifting angles was not satisfactory with 5 patients. With 3 of them the operation was repeated after 3 to 5 years.

3.6. Discussion

Currently, there are plenty of techniques used for face-lifts: conventional rhytidectomy, composite face-lifting, deep layer rhytidectomy, sub-SMAS, extended face-lifting, subcutaneous temporofacial lift combined with SMAS suspension, medial SMAS lift with aggressive temporal skin removal, temporal lift via blepharoplasty approach. Stretching the skin solely is obsolete. New techniques were proposed, such as endoscopic, subperiosteal, extended face lifts etc. There is no general agreement and no definitive answer as to which operative technique is most effective or preferable for each specific case. This is due to the subjective nature of aesthetics, aspirations and to the variability of skills and anatomy.

In the last years, an increasing number of patients ask for non-invasive or minimally invasive surgery for beautification or rejuvenation with minimal trauma and short recovery downtime, corresponding to the modern lifestyle. The suture method for temporal SMAS lift is the most preferred option by author's patients as an optimal solution for upper (and total) face beautification and rejuvenation, which preserves the natural look.

The temporal SMAS lift is a nice, weekend ambulatory procedure that gives a pleasing rejuvenation and beautification of the skin, eyes, brows, cheekbones, and most importantly - changes the expression. Complications rate is very low and the methods to solve the complications are easily performed. In young ladies, only one suture per side is usually enough to lift the lateral canthus of the eye, the eyebrow and to pull the ptotic malar fat into place, which restores and forms a nice malar eminence. It is also possible to combine the temporal lift by suture with other suture procedures: the author uses additional suture methods for brow, mid-face, cheekbone, and lower SMAS lift, simultaneous rhinoplasty, chin and lip augmentation, fat reduction and/or augmentation, skin resurfacing or blepharoplasty to obtain facial beautification and or rejuvenation. The closed approach Serdev Suture® method for temporal SMAS lift provides a safe and effective beautification, as well as rejuvenation in early laxity and face ptosis, and in some revision facelifts.

4. Supra-temporal lift

Supra-temporal lift presents fixation of the mobile galea aponeurotica at the hairline to the upper temporal line periosteum.

5. Glabella muscle ligation for permanent glabella relaxation

Video: <http://www.youtube.com/watch?v=F7r-W7-kK20>

5.1. Directions

1. Mark the glabella muscles: 1. Corrugator supercillii muscle; 2. Procerus muscle; 3. Depressor supercillii muscle. The glabella muscles are V-shaped. Select and mark A, B and C skin perforation points to tie and ligate that muscles in 3 lines: A-B line to ligate the Procerus muscle and Depressor supercillii muscle, A-C and B-C lines to ligate the Corrugator and Depressor supercillii muscles (Fig. 31).

2. Local anesthesia in points A, B and C intradermal and in direction A-B, A-C and B-C at periosteum and subdermally. Note: Inject local anesthesia sparingly, drop by drop as necessary, to prevent from visible swelling.

3. Perforate points A, B and C using a No. 11 scalpel blade. Using a mosquito clamp, perforate bluntly the subdermal fascia in the points A, B and C. **NB!** If not previously perforated, superficial fascias will be engaged in the suture, forming a dimpling effect on the skin surface.

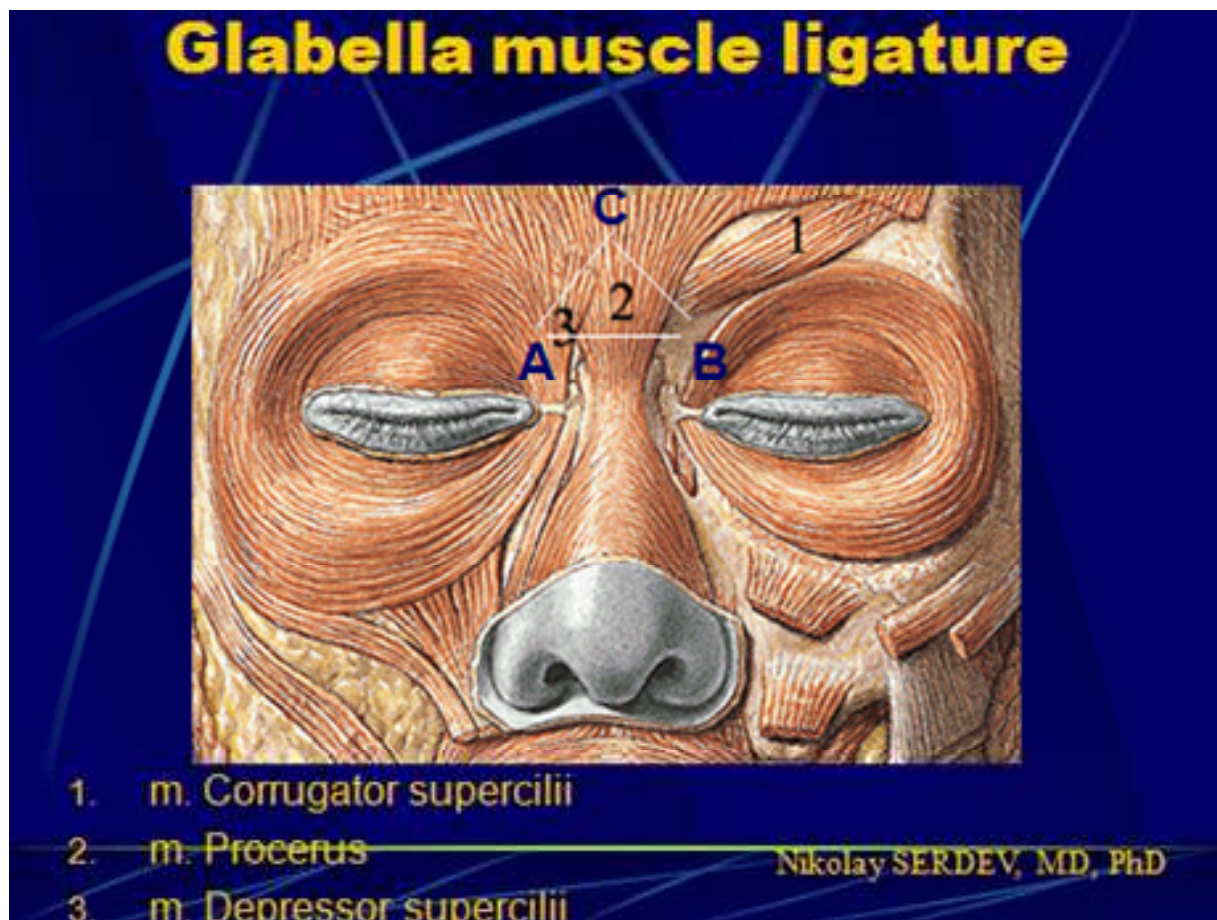


Figure 31. Suture lines A-B, B-C and A-C to ligate glabella muscles

5.2. A-B Suture - procerus & depressor supercilii muscle ligation

A. Introduce an unloaded “mini mini” Serdev® 50 mm needle from point A to point B, below the Procerus muscle, touching the periosteum. Load the needle with a surgical suture USP 3/0 and introduce it on the way of the needle pass A-B. **NB!** In skin perforation points, pass the needle perpendicularly to the skin surface, without resistance in front (to prevent engagement of dermal and fibrotic tissue), by smoothly twisting the needle. Do not push to bite dermis as this will result in a dimple. Do not push, do not pull – twist the needle smoothly forward and backward.

B. Introduce the unloaded needle from point A to point B subdermally, above the muscles. Feed the second suture end into the Serdev® needle at point B and introduce it toward A to finalize the circle of the suture. **NB!** The needle tip is always in direction to the suture end - to reach and load it.

C. Tie strongly at point A to ligate the muscles and obtain muscle necrosis at that place. After securing the knot, release any dimpling with a hemostat at point A and B.
NB! Serdev Sutures® should not engage skin.

5.3. A-C suture - corrugator supercilii & depressor supercilii muscle ligation

A. Introduce an unloaded “mini mini” Serdev® needle from point C to A, below the muscles Corrugator supercilii and Depressor supercilii, touching periosteum. Load the needle with suture USP 3/0 and introduce it on the way of the needle pass A-C.

B. Introduce the unloaded Serdev® needle from point C to A subdermally, above the muscles. Feed the second suture end into the Serdev® needle at point A and introduce it from A to C to finalize the circle of the suture.

C. Tie strongly at point C to ligate the muscles and to obtain muscle necrosis at that place. After securing the knot, release any dimpling with a hemostat at point A and C.

5.4. B-C suture - corrugator supercilii & depressor supercilii muscle ligation

A. Introduce an unloaded “mini mini” Serdev® needle from point B to C, below the muscles Corrugator supercilii and Depressor supercilii, touching periosteum. Load the needle with surgical suture USP 3/0 and introduce it on the way of the needle pass C-B.

B. Introduce the unloaded Serdev® needle from point B to C subdermally, above the muscles. Feed the second suture end into the Serdev® needle at point C and introduce it at B to finalize the circle of the suture.

C. Tie strongly at point B to ligate the muscles and to obtain muscle necrosis at that place. After securing the knot, release any dimpling with a hemostat at point B and C.

5.5. Results

20 patients were followed up to 3 years after operation with the suture ligation method to block glabella muscles. 3 years results show 80-95% relaxation of the glabella muscle function that is permanent.

Serdev Sutures® glabella muscle ligation provides a minimally invasive, scarless glabella muscle ligation, necrosis and relaxation with no downtime and near to zero complications. Longevity is very satisfactory. Aesthetic results often exceed patient expectations.

6. Lateral canthus lifting

There are 2 methods for lateral canthus lifting:

1. Fixation to the lateral orbital rim. Using 2 skin perforation points, the needle passes once below the lateral canthus and perforates orbital rim periosteum, and second time it passes above the orbital rim, subcutaneously. The suture fixes the lateral canthus to the lateral orbital rim periosteum.

2. Fixation to the upper temporal rim and temporal fascia.

First pass: Two skin perforation points are necessary on both sides of the lateral canthus to pass below or through the lateral canthus (using the 50 mm “mini mini” Serdev® needle), and introduce the surgical suture through that sub- or trans-canthal line.

Second pass: Then, a small (100 mm) or medium (140 mm) Serdev® needle is introduced through a third skin perforation point in the temporal line area to perforate the periosteum of the upper temporal line and the temporal fascia, take one of the suture ends and introduce it subtemporally and subperiosteally.

Third pass: This pass is subdermal, in order to take the second end of the suture, pull it through subdermally and fulfill the suture.

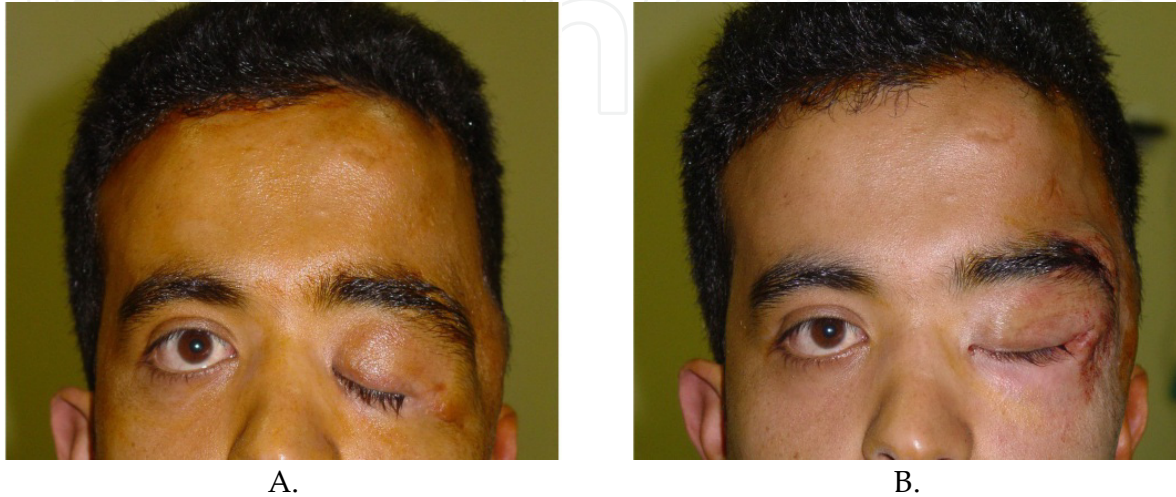

Figure 32. A. After eye tumor enucleation, B. After lateral canthus fixation to upper temporal line and temporal fascia.

Lateral canthus repositioning is performed mostly in reconstructive surgery. Serdev Suture® lift permits beautification as well. Another possibility for lateral canthus lifting is the Serdev Suture® brow lift, which also reflects in a lateral canthus lifting.

Author details

Nikolay Serdev

New Bulgarian University, Sofia, Bulgaria

7. References

- [1] Serdev, N.P. Year 1994, Suture Suspensions For Lifting Or Volume Augmentation In Face And Body (English version), presented at the 2nd Annual Meeting of the National Bulgarian Society for Aesthetic Surgery and Aesthetic Medicine, Sofia, 18 March 1994, *Int J Aesth Cosm*, 2001,1:1, 2561-2568
- [2] Serdev, N.P. Eyebrow lifting by suture (from "Serdev Sutures. Scarless face and body liftings"), *Int J Aesth Cosm*, 2011,11:3, 1-2
- [3] Serdev, N.P. Brow lifting to the upper temporal line 1.5 cm, *Int J Aesth Cosm*, 2012,12:1, 1-62
- [4] Serdev, N.P. Brow lifting with fixation to the upper temporal line at the hairline, *Int J Aesth Cosm*, 2012,12:1, 3-6

- [5] Paul MD. The evolution in aesthetic cosmetic surgery. *Plast Reconstr Surg* 2001 Oct;108(5):1409-24
- [6] Wang TD. Rhytidectomy for treatment of the aging face. *Mayo Clin Proc* 1989 Jul;64(7):780-90
- [7] Cook TA, Musgrave-Zwetsch J. Adjuncts to face lifting procedures. *Otolaryngol Clin North Am* 1980 May;13(2):321-35
- [8] Forrest CR, Phillips JH, Bell TA, Gruss JS. The biomechanical effects of deep tissue support as related to brow and facelift procedures. *Plast Reconstr Surg* 1991 Sep;88(3):427-32
- [9] Rafaty FM. Elimination of glabellar frown lines. *Arch Otolaryngol* 1981 Jul;107(7):428-30
- [10] Liebman EP, Webster RC, Berger AS, DellaVecchia M. The frontalis nerve in the temporal brow lift. *Arch Otolaryngol* 1982 Apr;108(4):232-5
- [11] Webster RC, Gaunt JM, Hamdan US, Fuleihan NS, Giandello PR, Smith RC. Supraorbital and supratrochlear notches and foramina: anatomical variations and surgical relevance. *Laryngoscope* 1986 Mar;96(3):311-5
- [12] Whitaker LA, Bartlett SP. Skeletal alterations as a basis for facial rejuvenation. *Clin Plast Surg* 1991 Jan;18(1):197-203
- [13] Fogli A. Orbicularis oculi muscle and crow's feet. Pathogenesis and surgical approach. *Ann Chir Plast Esthet* 1992 Oct;37(5):510-8
- [14] Yeatts RP. Current concepts in brow lift surgery. *Curr Opin Ophthalmol* 1997 Oct;8(5):46-50
- [15] Bruck JC, Baker TJ, Gordon H. Facial mimics and the coronal brow lift. *Aesthetic Plast Surg* 1987;11(4):199-201
- [16] Bruck JC, Baker TJ, Gordon H. Facial mimics and the coronal brow lift. *Aesthetic Plast Surg* 1987;11(4):199-201
- [17] Freund RM, Nolan WB 3rd. Correlation between brow lift outcomes and aesthetic ideals for eyebrow height and shape in females. *Plast Reconstr Surg* 1996 Jun;97(7):1343-8
- [18] Arteaga DM, Taylor CO. Esthetic evaluation and treatment of the upper one third of the face. *J Oral Maxillofac Surg* 1991 Jan;49(1):27-32/
- [19] Quantitative analysis of facial motion components: anatomic and nonanatomic motion in normal persons and in patients with complete facial paralysis. *Plast Reconstr Surg* 1997 Jun;99(7):1894-902; discussion 1903-4/
- [20] Elkwood A, Matarasso A, Rankin M, Elkowitz M, Godek CP. National plastic surgery survey: brow lifting techniques and complications. *Plast Reconstr Surg* 2001 Dec;108(7):2143-50; discussion 2151-2
- [21] Matarasso A, Elkwood A, Rankin M, Elkowitz M. National plastic surgery survey: face lift techniques and complications. *Plast Reconstr Surg* 2000 Oct;106(5):1185-95; discussion 1196
- [22] Forrest CR, Phillips JH, Bell TA, Gruss JS. The biomechanical effects of deep tissue support as related to brow and facelift procedures. *Plast Reconstr Surg* 1991 Sep;88(3):427-32

- [23] Webster RC, Fanous N, Smith RC. Blepharoplasty: when to combine it with brow, temple, or coronal lift. *J Otolaryngol* 1979 Aug;8(4):339-43
- [24] Adamson PA, Cormier R, McGraw BL. The coronal forehead lift -modifications and results. *J Otolaryngol* 1992 Feb;21(1):25-9
- [25] McKinney P, Mossie RD, Zukowski ML. Criteria for the forehead lift. *Aesthetic Plast Surg* 1991 Spring;15(2):141-7
- [26] Rafaty FM, Goode RL, Fee WE Jr. The brow-lift operation. *Arch Otolaryngol*. 1975 Aug;101(8):467-8.
- [27] Ortiz-Monasterio F, Barrera G, Olmedo A. The coronal incision in rhytidectomy--the brow lift. *Clin Plast Surg*. 1978 Jan;5(1):167-79.
- [28] Ellenbogen R. Transcoronal eyebrow lift with concomitant upper blepharoplasty. *Plast Reconstr Surg*. 1983 Apr;71(4):490-9.
- [29] Fett DR, Sutcliffe RT, Baylis HI. The coronal brow lift. *Am J Ophthalmol* 1983 Dec;96(6):751-4
- [30] Riefkohl R. The forehead-brow lift. *Ann Plast Surg* 1982 Jan;8(1):55-63
- [31] Nassif PS, Kokoska MS, Homan S, Cooper MH, Thomas JR. Comparison of subperiosteal vs subgaleal elevation techniques used in forehead lifts. *Arch Otolaryngol Head Neck Surg* 1998 Nov;124(11):1209-15
- [32] Troilius C. A comparison between subgaleal and subperiosteal brow lifts. *Plast Reconstr Surg* 1999 Sep;104(4):1079-90; discussion 1091-2
- [33] Dempsey PD, Oneal RM, Izenberg PH. Subperiosteal brow and midface lifts. *Aesthetic Plast Surg* 1995 Jan-Feb;19(1):59-68
- [34] Riefkohl R, Kosanin R, Georgiade GS. Complications of the forehead-brow lift. *Aesthetic Plast Surg* 1983;7(3):135-8
- [35] Gasperoni C, Salgarello M, Bajaj-Luthra A, Mueller T, Johnson PC, Karabulut AB, Tumerdem B. Forehead lift: a combined approach using subperiosteal and subgaleal dissection planes. *Aesthetic Plast Surg* 2001 Sep-Oct;25(5):378-81
- [36] Camirand A, Doucet J. A comparison between parallel hairline incisions and perpendicular incisions when performing a face lift. *Plast Reconstr Surg* 1997 Jan;99(1):10-5
- [37] Holcomb JD, McCollough EG. Trichophytic incisional approaches to upper facial rejuvenation. *Arch Facial Plast Surg* 2001 Jan-Mar;3(1):48-53
- [38] Johnson CM Jr, Waldman SR. Midforehead lift. *Arch Otolaryngol* 1983 Mar;109(3):155-9
- [39] Johnson CM Jr, Anderson JR, Katz RB. The brow-lift 1978. *Arch Otolaryngol* 1979 Mar;105(3):124-6 The We discuss the surgical technique in detail.
- [40] Lewis JR Jr. A method of direct eyebrow lift. *Ann Plast Surg* 1983 Feb;10(2):115-9
- [41] Byrd HS, Andochick SE. The deep temporal lift: a multiplanar, lateral brow, temporal, and upper face lift. *Plast Reconstr Surg* 1996 Apr;97(5):928-37
- [42] Miller TA, Rudkin G, Honig M, Elahi M, Adams J. Lateral subcutaneous brow lift and interbrow muscle resection: clinical experience and anatomic studies. *Plast Reconstr Surg* 2000 Mar;105(3):1120-7; discussion 1128
- [43] Gasperoni C, Salgarello M, Gargani G. Subperiosteal lateral browlift and its relationship to upper blepharoplasty. *Aesthetic Plast Surg* 1993 Summer;17(3):243-6

- [44] Gargani G. Subperiosteal lateral browlift and its relationship to upper blepharoplasty. *Aesthetic Plast Surg* 1993 Summer;17(3):243-6
- [45] Ramirez OM. Transblepharoplasty forehead lift and upper face rejuvenation. *Ann Plast Surg* 1996 Dec;37(6):577-84
- [46] Ramirez OM. Endoscopically assisted biplanar forehead lift. *Plast Reconstr Surg* 1995 Aug;96(2):323-33
- [47] Dayan SH, Perkins SW, Vartanian AJ, Wiesman IM. The forehead lift: endoscopic versus coronal approaches. *Aesthetic Plast Surg* 2001 Jan-Feb;25(1):35-9
- [48] Pakkanen M, Salisbury AV, Ersek RA. Biodegradable positive fixation for the endoscopic brow lift. *Plast Reconstr Surg* 1996 Nov;98(6):1087-91
- [49] McKinney P, Celetti S, Sweis I. An accurate technique for fixation in endoscopic brow lift. *Plast Reconstr Surg* 1996 Apr;97(4):824-7
- [50] Namazie AR, Keller GS. Current practices in endoscopic brow and temporal lifting. *Facial Plast Surg Clin North Am* 2001 Aug;9(3):439-51
- [51] Byrd HS. The extended browlift. *Clin Plast Surg* 1997 Apr;24(2):233-46
- [52] Putterman AM. Intraoperatively controlled small-incision forehead and brow lift. *Plast Reconstr Surg* 1997 Jul;100(1):262-6
- [53] Kikkawa DO, Miller SR, Batra MK, Lee AC. Small incision nonendoscopic browlift. *Ophthal Plast Reconstr Surg* 2000 Jan;16(1):28-33
- [54] Graziosi AC, Beer SMC. pp Browlifting with thread: the technique without undermining using minimum incisions. *Aesthetic Plast Surg* 1998 Mar-Apr;22(2):120-5
- [55] Ahn MS, Catten M, Maas CS. Temporal brow lift using botulinum toxin A. *Plast Reconstr Surg* 2000 Mar;105(3):1129-35; discussion 1136-9
- [56] Serdev, N. Accessories to Face Lifting. II International Symposium of Updating on Skin Aesthetic, Sao Paulo, Brazil, 6-8 May, 1994
- [57] Serdev N. Live Surgery Workshop, SMAS Lifting of the face by minimal incision – Brow, Temporal, Medial, Lower - the Serdev Technique. The International Academy of Aesthetic Surgery and Aesthetic Medicine, The Krulig Clinic, Caracas, Venezuela, Nov. 1999
- [58] Serdev, N. Scarless Brow Lift Using A Special Suture. Presentations – 3rd World Congress of Cosmetic Surgery with Live Surgical Demonstrations. *Int. J. Cosm. Surg.* 2002, Volume 2, Number 4
- [59] Serdev, N. P. Forehead Subperiosteal Masklift in Combination with McIndoe Facelift Technique and Profile Correction. The 7th IPRAS Congress European Section, Berlin, Germany, June 2-5, 1993.
- [60] Serdev N. P. Temporal SMAS lift without skin excision In: Lip Augmentation During Mask and SMAS Lift Procedure, AAARS Annual Meeting, New Orleans, USA, October 5-9, 1994
- [61] Serdev, N.P. Temporal SMAS Lifting of the Face. Life Surgery Workshop. Unidad Medica Clinica Del Country, Bogota D.C., Colombia, November 8-10, 1999
- [62] Serdev, N. P. SMAS Lifting of the Face by Minimal Incisions – the Serdev Technique. Life Surgery Workshop sponsored by International Academy of Cosmetic surgery and

- the Balkan Academy of Cosmetic Surgery, held at the Krilig Clinic in Caracas, Venezuela, November 12-18, 1999.
- [63] Serdev, N. P. Principles of Face Beautification, Ier Congresso Internacional de Cirurgia Cosmetica, Buenos Ares Argentina, 31 Octubre – 1 de Noviembre 1999
 - [64] Serdev, N.P. Temporal SMAS lift, Lecture and Life Demonstration, 1st World Congress of Cosmetic Surgery with Life Demonstrations, Edsa Shangri-La Manila and Quezon City Medical Center, February 25-27, 2000.
 - [65] (<http://www.mpint.co.jp/apacs/Congress2000/con007.htm>).
 - [66] Serdev, N.P. Temporal SMAS Lifting of the Face, Combined with Liposuction and Chin Augmentation Using Suture. Life Surgery Workshop, Tel Aviv, Israel, April 20-24, 2000.
 - [67] Serdev, N. P. Principles of face beautification, The 3-rd World Congress of ISAS, Tokyo, April 8-10, 2000 , 9W58
 - [68] Serdev, N.P. Lifting del SMAS con Una Pequenna Incision Temporal, VIIIas Journadas Mediterraneas de Confrontaciones Terapeuticasen Medicina y Cirurgia Cosmetica, Sitges, Barcelona, March 16-19, 2000
 - [69] Serdev, N.P. Facial Rejuvenation by Minimal Skin Incisions, International Congress “Refinements in Aesthetic Surgery” Oradea, Romania, June 22-24
 - [70] Mitz, V, Peyronie M. The superficial musculoaponeurotic system (SMAS) in the parotid and cheek area. *Plast. Reconstr. Surg.* 1976; 58: 80.
 - [71] Miura Y, Moura PD, Ramasastry S, Hochberg J. Can we simplify the nomenclature of the fascial lyers of the temporo parietal region? *OnLine J Plast Reconstr Surg*, Nov 1997;1: 1.
 - [72] Stuzin, J. M., Baker, T. J., Gordon, H. L., and Baker, T. M. Extended SMAS dissection as an approach to midface rejuvenation. *Clin. Plast. Surg.* 1995; 22: 295.
 - [73] Connell, B. F., and Marten, T. J. The male foreheadplasty: Recognizing and treating aging in the upper face. *Clin. Plast. Surg.* 1991; 18: 653.
 - [74] Aston, S. J. Platysma-SMAS cervicofacial rhytidoplasty. *Clin. Plast. Surg.* 1983;10: 507.
 - [75] Barton, F. E., Jr. The SMAS and the nasolabial fold. *Plast. Reconstr. Surg.* 1992; 89: 1054.
 - [76] Bosse, J. P., and Papillon, J. Surgical Anatomy of the SMAS at the Malar Region. In *Transactions of the 9th International Congress of Plastic and Reconstructive Surgery*. New York: McGraw-Hill, 1987: 348.
 - [77] Cardoso de Castro, C. The role of the superficial musculoaponeurotic system in face lift. *Ann. Plast. Surg.* 1986; 16: 276.
 - [78] Stuzin JM, Wagstrom L, Kawamoto HK, Wolfe SA. Anatomy of the frontal branch of the facial nerve: The Significance of the Temporal Fat Pad. *Plast Reconstr Surg* 1989; 83: 265-71.
 - [79] Ramirez OM, Maillard GF, Musolas A. The extended Subperiosteal Face lift: A definitive Soft-tissue Remodeling for Facial Rejuvenation. *Plast Reconstr Surg* 1991; 88:227-36.
 - [80] Tolhurst DE, Carstens MH, Greco RJ, Hurwitz DJ. The Surgical Anatomy of The Scalp. *Plast Reconstr Surg* 1991; 87: 603-12.
 - [81] Larrabee Jr., W.F., Makielski, K.H. *Surgical Anatomy of the face*. New York: Raven Press, 1993: 41-48.

- [82] Hochberg J, Kaufman H, Ardenghy M. Saving The Frontal Branch during a Low Fronto-orbital Approach. *Aesth Plast Surg* 1995; 19: 161-163.
- [83] Core GB, Vasconez LO, Graham III, HD Endoscopic Browlift. *Clin. Plast. Surg.* 1995; 22: 619-31.
- [84] Bostwick III, J., Eaves, F.F., Nahai, F. Endoscopic Plastic Surgery. Quality Medical Publishing, Inc. St. Louis, MO, 1995: 86-129. S.E. The Deep Temporal Lift: A multiplanar, lateral Brow, Temporal, and Upper face Lift. *Plast. Reconstr Surg* 1996; 5: 928-37.
- [85] Bostwick III, J., Eaves, F.F., Nahai, F. Endoscopic Plastic Surgery. Quality Medical Publishing, Inc. St. Louis, MO, 1995: 86-129.
- [86] De la Fuente A, Santamaria AB Endoscopic subcutaneous and SMAS facelift without preauricular scars. *Aesthetic Plast Surg* 1999 Mar-Apr; 23: 119-24.
- [87] Kamer FM, Frankel SMAS rhytidectomy versus deep plane rhytidectomy: an objective comparison. *ASPlast Reconstr Surg* 1998 Sep; 102 (3): 878-81
- [88] Hagerty RC, Scioscia PJ The medial SMAS lift with aggressive temporal skin takeout. *Plast Reconstr Surg* 1998 May; 101 (6):1650-6.
- [89] Gray H, Goss CM. Anatomy of The Human Body. Philadelphia: Lea and Febiger, 1966: 375-99.
- [90] Hamra ST. The tri-plane face lift dissection. *Ann Plast Surg* 1984 Mar; 12 (3): 268-74.
- [91] Casanova R, Cavalcante D, Grotting JC, Vasconez LO, Psillakis JM. Anatomic basis for Vascularized Outer-Table Calvarial Bone flaps. *Plast. Reconstr Surg* 1986; 78: 300-8.
- [92] Abul-Hassan, HS, Ascher, GD, Acland, RD. Surgical Anatomy and Blood Supply of the Fascial Layers of the Temporal Region. *Plast Reconstr Surg* 1986; 77: 17-24.
- [93] Hamra ST. The deep-plane rhytidectomy. *Plast Reconstr Surg* 1990 Jul; 86 (1):53-61.
- [94] Mitz V, Use of deep planes in surgery of rejuvenation of the face *Chirurgie* 1991; 117 (4): 278-86.
- [95] De La Plaza R, Valiente E, Arroyo JM, Supraperiosteal lifting of the upper two-thirds of the face. *Br J Plast Surg* 1991 Jul; 325 :32- 44.
- [96] Caix P, Goin JL, Modschiedler T. "Total SMAS lift" or deep facial lift by temporal approach. Initial report. *Ann Chir Plast Esthet* 1992 Jan; 37 (1): 67-74.
- [97] Bonnefon A Deep "en bloc" facial lift" *Ann Chir Plast Esthet* 1992 Jan; 37 (1), 85-94
- [98] Hamra ST, Composite rhytidectomy. *Plast Reconstr Surg*, 1992 Jul; 90 (1): 1-13.
- [99] Teimourian B, Delia S, Wahrman A, The multiplane face lift. *Plast Reconstr Surg* 1994 Jan 93; 1: 78-85.
- [100] Campiglio GL, Candiani P. Anatomical study on the temporal fascial layers and their relationships with the facial nerve. *Aesthetic Plast Surg* 1997 Mar-Apr; 21 (2): 69-74.
- [101] Byrd HS The extended browlift. *Clin Plast Surg*, 1997 Apr; 24 (2): 233-46.
- [102] Honig JF Concepts in face lifts. State of the art *Mund Kiefer Gesichtschir* 1997 May; 1(Suppl): 1S21-6.
- [103] Bonnefon A. Deep vertical lift and its development regarding the central facial area and lower two-thirds of the neck. Our technique, *Ann Chir Plast Esthet*, 1999 Dec: 609-16.

- [104] Quatela VC, Sabini P. Techniques in deep plane face lifting. *Facial Plast Surg* 2000 May; 2: 193-209.
- [105] Mittelman H, Newman J. Smasectomy and imbrication in face lift surgery. *Facial Plast Surg* 2000 May; 2: 173-82.
- [106] Maloney BP, Schiebelhoffer J. Minimal-incision endoscopic face-lift. *Arch Facial Plast Surg* 2000 Oct-Dec; 4: 274-8.
- [107] Achauer BM, Adair SR, VanderKam VM, Combined rhytidectomy and full-face laser resurfacing. *Plast Reconstr Surg*, Dec 2000; 106: 1608-11.
- [108] Serdev, N. Glabella muscles ligature using Serdev Suture technique, <http://www.youtube.com/watch?v=F7r-W7-kK20>
- [109] Edgerton, M., Wolford, F. Technique of Value in the Surgical Treatment of Facial Palsy, *Plastic & Reconstructive Surgery*: January 1969 - Volume 43 - Issue 1 - ppg 42-52
- [110] Montadon, D. A Modification of the Dermal-Flap Canthal Lift for Correction of the Paralyzed Lower Eyelid, *Plastic & Reconstructive Surgery*: April 1978 - Volume 61 - Issue 4 - ppg 555-557
- [111] Yip C-Chew, McCann J. D., Goldberg R. A. The Role of Midface Lift and Lateral Canthal Repositioning in the Management of Euryblepharon, *Arch Ophthalmol*. 2004;122(7):1075-1077.