

We are IntechOpen, the world's leading publisher of Open Access books Built by scientists, for scientists

4,800

Open access books available

122,000

International authors and editors

135M

Downloads

Our authors are among the

154

Countries delivered to

TOP 1%

most cited scientists

12.2%

Contributors from top 500 universities



WEB OF SCIENCE™

Selection of our books indexed in the Book Citation Index
in Web of Science™ Core Collection (BKCI)

Interested in publishing with us?
Contact book.department@intechopen.com

Numbers displayed above are based on latest data collected.

For more information visit www.intechopen.com



Role of Magnetic Resonance Imaging in Locally Advanced Rectal Cancer

Roberta Fusco, Mario Sansone, Mario Petrillo,
Antonio Avallone, Paolo Delrio,
Fabiana Tatangelo and Antonella Petrillo

Additional information is available at the end of the chapter

<http://dx.doi.org/10.5772/56831>

1. Introduction

This chapter will give an overview of the magnetic resonance imaging (MRI) modalities used in locally advanced rectal cancer (LARC) staging with an emphasis on the role of MRI and its significance for planning an effective therapeutic strategy for the individual patient.

Specifically, the aim of this chapter is to present a brief review about:

- 1. Methodologies of Magnetic Resonance Imaging in LARC staging**
 - a. Morphologic MRI**
 - b. Functional MRI**
 - i. Dynamic Contrast Enhanced MRI (DCE-MRI)**
 - ii. Diffusion Weighted MRI (DW-MRI)**
- 2. The role of MRI in diagnosis, staging, evaluation of response of neoadjuvant treatment, follow-up post surgery.**

This chapter will be organised in the following sections. First, in order to better define the role of MRI in LARC management, we will briefly describe the epidemiological scenario and therapeutic options, with an emphasis on issues in which MRI is relevant. Second, we will describe morphologic and functional MRI including DCE-MRI and DW-MRI. Finally, a systematic review of the literature concerning MRI, CT and PET for LARC management will be presented.

2. Epidemiology

Colorectal cancer is the third most common cancer worldwide [1], which includes cancers of the colon, rectum, rectosigmoid junction and anus. Specifically, in men it represents the third commonest neoplasm after prostate and lung cancers while in women it is the second major cause of morbidity and mortality, following breast cancer.

In recent years, mortality rates have decreased due to several factors, including less exposure risk factors, more possibility of prevention and “early diagnosis” followed by an effective management of the disease. In particular, major changes in therapeutic management are given by the standardization of operative procedures and the introduction of adjuvant and neoadjuvant therapy [2-7], able to reduce recurrence risk and tumor size.

Cancers are characterized by profound spatial and temporal heterogeneity in their biologic characteristics. Most invasive cancers typically have alterations in cell physiology that promote malignant growth [2-7]. Rectal cancer is the result of a complex interaction between genetic and environmental factors and it is defined as a tumor whose aboral margin measured with the rigid rectoscope is 16 cm or less from the anocutaneous line. This distance serves to classify rectal cancer into tumours of the upper third (12–16 cm), the middle third (6–12 cm), and the lower third (<6 cm) [26] according to the Union for International Cancer Control (UICC).

The mesorectal fascia is an important anatomic landmark for the diagnostic evaluation of local tumor extent [26]. It is a connective tissue sheath that surrounds the rectum and the perirectal fatty tissue and acts as a natural barrier for tumor spread.

A locally advanced tumor often describes a tumor extending beyond the rectal wall with infiltration to surrounding organs or structures, and/or perforation of the visceral peritoneum. It includes bulky T3 tumors with threatened circumferential margins or T4 tumors, tumors with growth onto the peritoneal surface. A radiological T4 tumor is considered when detected growing outside the mesorectal fascia, while a T3 tumor refers to a tumor invading through muscularis propria [26].

These tumors have traditionally been looked upon as “unresectable”, although previous staging, due to the wide tumor extension. However, when it is possible, these tumors cannot be resected without leaving microscopic or gross residual disease at the local site because of tumor adherence or fixation to that site.

3. Therapeutic options

In LARC accurate and detailed anatomic information in tumor extent is essential not only for the selection of the patients for neoadjuvant chemotherapy and radiation therapy to achieve tumor shrinkage but also for the optimal surgical procedure planning. Moreover, the treatment for patients with locally advanced and recurrent rectal cancer differs significantly from patients with rectal cancer restricted to the mesorectum.

Adequate preoperative imaging of the pelvis is therefore important to identify those patients who are candidates for multimodality treatment, including preoperative chemoradiation protocols, intraoperative radiotherapy, and extended surgical resections. Much effort should be made to select patients with these advanced tumors for treatment in specialized referral centers. This has been shown to reduce morbidity and mortality and improve long-term survival rates.

Two main therapeutic options can be considered according to different pathological stages presented [13-35]:

1. Total mesorectal excision (TME): using this surgical technique, the rectum is resected together with all surrounding lymphatic pathways, lymph nodes, mesorectal fatty tissue, and the mesorectal fascia while the parietal pelvis fascia and the pelvic splanchnic nerves are spared. This surgical technique minimizes the chance of tumor being left inside;
2. Adjuvant/neoadjuvant therapy: the aims of adjuvant or neoadjuvant therapy are to enable or facilitate total tumor resection even in advanced disease, to prevent local tumor recurrence, and to minimize the risk of distant metastases.

The majority of patients with primary rectal cancer have a tumor located within the mesorectal fascia, which is generally treated with total mesorectal excision (TME). Results of TME surgery are excellent with a significant reduction in local recurrences when preoperative short-term radiotherapy (5 x 5 Gy) is delivered one week prior to surgery [27]. In ≈10% of all rectal cancer patients the tumor extends into or beyond the enveloping fascia of the mesorectal compartment.

Often these tumors infiltrate adjacent structures and therefore have a higher risk to develop a local recurrence [28].

Patients with these primary locally advanced or recurrent rectal cancer are difficult to treat with surgery alone, but outcome has significantly improved using multimodality treatment. Although preoperative and adjuvant therapy is important in these patients, the mainstay of treatment in rectal cancer is complete surgical removal of the tumor. In both locally advanced and recurrent rectal cancers, this involves not only the removal of the total mesorectum, but en bloc resection of involved structures is often needed.

Although postoperative chemoradiotherapy (CRT) has long been recommended for locally advanced and node positive rectal cancer patients, preoperative treatment is now widely used worldwide. In many European centers, radiotherapy only was used as neoadjuvant treatment for locally advanced rectal cancer, but the addition of chemotherapy has recently demonstrated to improve local control in two large randomized trials [30,31]. Addition of 5-FU and leucovorin to preoperative radiation slightly increased the amount of acute toxicity in T3 to T4 resectable rectal cancer patients [32]. However, it increased the number of complete responses and decreased the local recurrence rate after 5 years.

Not only new chemotherapeutic drugs, but also a vascular endothelial cell growth factor-(VEGF-) specific monoclonal antibody in combination with chemoradiation was recently reported by Willet et al [32] to lead to considerable downstaging of the tumor. Other modalities

such as the use of intensity-modulated radiotherapy (IMRT), which has the potential of more accurate delivery of higher radiotherapy dosages, thus avoiding the damage of critical structures surrounding the tumor, are being tested in rectal cancer.

Total pelvic exenteration (TPE) is a widely used technique for resection of locally advanced or recurrent rectal tumors invading the bladder and/or prostate. Longterm survival with excellent local control is possible after TPE for primary locally advanced rectal cancer [33-35]. The majority of resections in primary cancer are without microscopic or macroscopic residual tumor mass, which clearly justifies the use of TPE in selected patients with primary disease. Although current guidelines for colorectal cancer surgery advocate TPE, only one third of the patients in a recent study based on SEER (survival, epidemiology and end results) data underwent the appropriate surgical resection.

These patients had a clinically significant overall survival benefit with no increase in short-term mortality compared with similar patients who did not receive a multi-visceral resection. Local control in rectal cancer patients is related to the dose of irradiation, but because of toxicity to radiosensitive organs (such as small bowels), the external radiation dose should not exceed 60 Gy. A combination of external radiation and intraoperative radiation therapy (IORT) allows the safe delivery of higher effective doses of irradiation than can be delivered with external-beam only techniques. IORT is used when resection margins are narrow or involved with tumor cells and can be applied very specifically to an area at risk, under direct visual control, and with the ability to shield the surrounding structures from radiation. The biological effectiveness of single-dose IORT is considered to be as effective as 2 to 3 times the equivalent dose of fractionated radiotherapy.

3. Role of MRI vs other modalities

3.1. Generalities

Imaging techniques play a pivotal role in the strategies for management of locally advanced rectal cancer patients. The role of diagnostic imaging is to perform a loco-regional staging as accurate as possible in both evaluation of infiltration and extension degrees of disease. Image features also enable preoperative assessment of important prognostic outlines, which may guide patient selection for neoadjuvant therapies. Moreover, imaging plays an important role in therapeutic assessment, surveillance after surgery, and evaluation of suspected disease fall-out. To date, imaging innovations have led to improvements in spatial and contrast resolution, increased data acquisition speeds, and enabled complex image to achieve excellence in anatomic resolution.

There are many different imaging modalities suitable for rectal cancer staging, tumour location and restaging but not all of them have the same accuracy for each indication. An optimal visualization of tumor volume and of its surrounding anatomical structures is necessary for any local cancer treatment. This issue is particularly important for radiotherapy treatment planning in order that a geographical miss can be avoided and the tumor adequately treated.

Among the imaging methods available Magnetic Resonance Imaging (MRI) is currently the modality of choice because of its capacity to perform local staging, since it enables evaluation of anatomic aspects and prognostic factors that are key to choosing the appropriate surgical approach and determining the need for neoadjuvant treatment.

3.2. MRI physical basics

MRI is an imaging technique based on the different magnetic properties of tissues in the body. The exposure to a high intensity magnetic field determines the alignment of the hydrogen nuclei (protons) along the magnetic field axis itself. The emission of radio frequency pulses causes a shift from this alignment, which tends to reconstitute as soon as the impulse is interrupted. This phenomenon leads to a variation in energy level of the charges, which can be translated into a signal whose decoding is the basis of the generation of magnetic resonance images. All this is based on specific parameters that describe these steps of energy levels (including the so-called "relaxation times T1 and T2"), as well as on the concentration of protons within a given tissue.

Pulses sequences are used to obtain the different MR images, sequences consisting of radio frequency pulses with different characteristics in terms of duration, frequency and type of sampling of the resulting signal.

In the various biological tissues, the characteristics of the magnetic resonance signal are influenced mainly by the content of hydrogen atoms (whose nuclei are composed of only one proton). Since water is the most abundant molecule in the body and contains hydrogen atoms, it can be reasonably stated that the increase or the decrease of water in a given tissue is almost always at the basis of changes in signal intensity when using sequences of magnetic resonance imaging.

Where tissue contrast depends primarily on electron density, the tissue contrast obtained by MRI can be extensively varied by imaging the intrinsic tissue properties, as spin-lattice and spin-spin relaxation times, protons density, magnetization transfer, separately or in combination, using a number of pulse sequences, which in turn can be altered by an essentially infinite number of different experimental conditions. These MR parameters can be exploited and tailored to facilitate optimal tumor visualization and evaluation. Another feature of MRI is that cortical bone does not give rise to an MR signal and therefore appears hypointense. This is because cortical bone contains calcium and there are few hydrogen protons to provide an MR signal. Furthermore, MRI can obtain detailed anatomical images in any desired plane, also acquiring 3D or volumetric image sets. Therefore, the superior soft tissue definition provided by MRI, together with its unrestricted multiplanar, volumetric, vascular and functional information has benefits for 3D treatment planning.

3.3. Comparison of MRI and CT

Computed Tomography (CT) scanning is an imaging technique able to reproduce a 3D image of internal organs by irradiating X-ray. In LARC treatment CT shows the effective tumor size and its possible dissemination to internal organs. Although CT imaging provides excellent

definition between structures with different electron density or X-ray attenuation characteristics, it distinguishes poorly between structures with similar electron density such as different soft tissue structures, including tumors, unless there is an obvious fat or air interface [60]. The major advantage of MRI compared with CT is in its superior ability to demonstrate and characterize soft tissues that have similar electron densities. In this manner, MRI may provide better delineation not only of the tumor extent, but also of the adjacent critical soft tissue organs. This will allow conformal planning to enhance its therapeutic ratio by more accurately targeting the tumor, avoiding the organs at risk and subsequently improving local control.

3.4. Comparison of MRI and PET/CT

In LARC patient management detection of tumor sites throughout the body is needed with high sensitivity and specificity in order to have accurate information about the local extent. As discussed in the previous section, an accurate tumour visualization can be performing using MRI techniques. An additional value should be given to consider the combination of Positron Emission Tomography (PET) and CT [61]. PET/CT is a diagnostic procedure that allows to obtain morphological images of the human body provided by CT and images of the tissue metabolic processes provided by PET by means of a co-registration system.

Tissues appear differently on PET and on CT images. CT displays anatomy with high spatial resolution, but with low contrast resolution for soft tissues, while PET visualizes pathological sites with high contrast resolution but a limited spatial resolution and surrounding normal anatomical structures are hardly visualized. The combination of metabolic activity with anatomic localization achievable with PET/CT improve accuracy over that of PET or CT alone [62].

4. Role of MRI in LARC

In the recent years MRI has undergone significant transformations resulting from technological innovation that have taken place as the introduction of high-field magnets, powerful gradients, multi-channel phased array coils and endorectal coils improvement. These technological developments have certainly allowed the executing of high quality diagnostic studies due to the high spatial resolution and contrast obtained, to the possibility of identification and distinction of rectal wall layers, and to the possibility of assessing perirectal and sphincteric structures. Mainly, superficial endorectal coils are currently able to identify various layers of lower rectum wall. MRI is thus the ideal technique for rectal cancer staging, combining the capabilities of an accurate loco-regional staging to the outlook and multi-planar properties.

In conclusion, MRI can currently stage with high accuracy the T parameter (related to the degree of tumor infiltration) due to the possibility offered by the endorectal coil to recognize the wall layers, resulting also extremely useful in planning surgery and in prognostic stratification, owing to the ability to accurately identify mesorectum and the distance between mesorectal fascia and neoplasia. Furthermore the high temporal resolution of last generation devices allows to perform perfusion and dynamic studies after gadolinium administration that

allow to detection of the residual tumor after neoadjuvant therapy and to diagnose recurrences, distinguishing them from fibrosis.

4.1. Morphological MRI

As regards the topographic relationship of the tumor with the mesorectal fascia can be adequately established with morphologic MRI [26]. The advent of powerful gradient systems and, above all, the development of high-resolution phased array surface coil systems in recent years brought the breakthrough in the staging of rectal cancer by MRI. The use of these phased-array surface coils combines a very high spatial resolution with a large FOV that allows not only detailed evaluation of the intestinal wall but also depicts surrounding anatomy including the mesorectal fascia.

A standard phased-array morphologic MRI protocol for LARC staging (including T-N stage and CRM evaluation) consists of T2-weighted coronal, transversal and sagittal turbo spin-echo MR sequences with high spatial resolution (Fig. 1) [26].

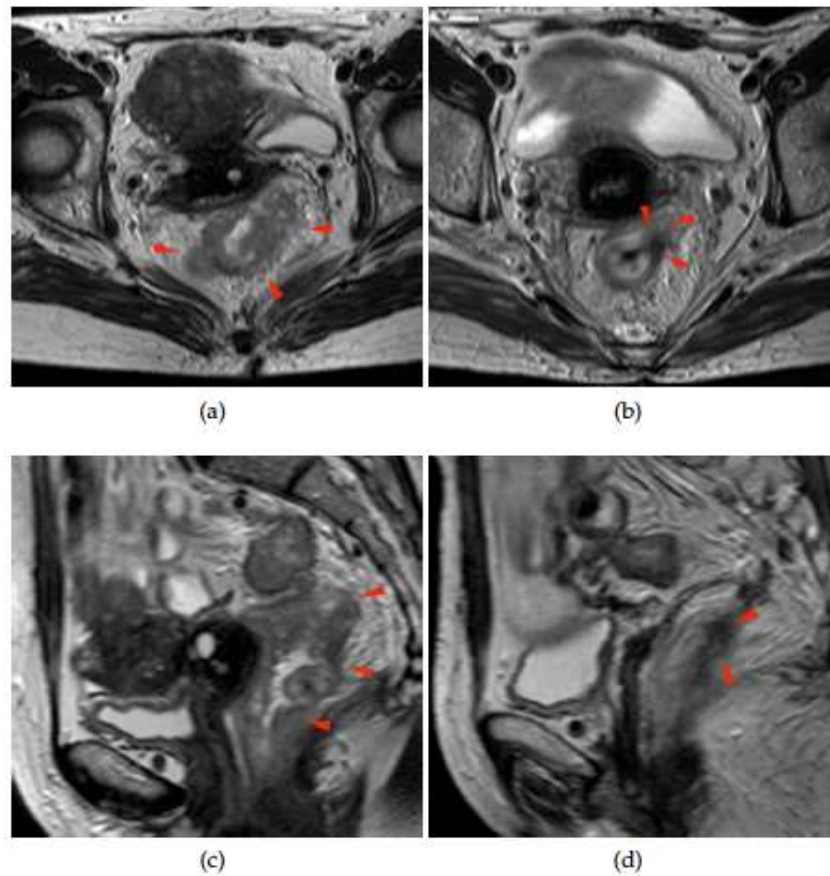


Figure 1. (a) A heterogeneous irregular thickening along the entire rectal wall is well shown on T2w axial pre-pCRT scan (arrowheads). (b) After pCRT, a hypo-intense spiculated area with thin digitations into peri-rectal fat is visible on T2w axial scan (arrowheads). (c) In the same patient, multiple irregular rectal wall thickenings are shown on T2w sagittal pre-pCRT scan (arrowheads). (d) A single hypo-intense area, showed also in (b) is pointed by arrowheads, suspecting for a residual post-pCRT tumor focus (arrowheads).

An adequate, state-of-the-art MRI staging classification is capable to predict whether a tumor-free CRM is likely to be achieved or not [26]. In this way one would be able to differentiate patients with minimal mesorectal infiltration in whom neoadjuvant therapy is not mandatory from patients who would definitely benefit from neoadjuvant therapy because the mesorectal fascia is infiltrated or at risk.

The common use of total mesorectal excision (TME) and the shift from a postoperative to a preoperative chemo-radiotherapy (pre-CRT) approach have substantially reduced the risk of local recurrences, increasing curative resection and the rate of anal sphincter preservation and improving local control and overall survival rates [13-18].

4.2. Functional MRI

Although morphological tumour assessment performed by MRI has been repeatedly shown to be the most accurate modality in evaluating the presence of a positive circumferential resection margin (CRM), MRI is considered not to be conclusive in pre-CRT tumor response evaluation since histopathological downstage is not always associated with tumour effective reduction [17]. The main difficulty regarding post-chemoradiation MRI includes discrimination of active tumour and post-treatment fibrosis, particularly when differentiating stage T2 and stage T3 carcinomas, according to different recurrence and overall survival rates between Low Risk (T1/T2N0) and Intermediate Risk (T3/N0) as reported by Gunderson et al. [23-24].

Several studies have shown the potential of functional [diffusion- or perfusion] weighted imaging to predict the response to adjuvant or neoadjuvant therapy [5-7,19].

In fact, it has long been known that the pathophysiology and aggressiveness of a tumor are determined not only by the macroscopic tumor extent but also by other factors such as tumor microcirculation and angiogenesis.

4.2.1. DCE-MRI

Previous considerations support a Dynamic Contrast Enhanced-Magnetic Resonance Imaging (DCE-MRI) approach that could gain a renewed role to MRI adding functional data to the morphological examination. DCE-MRI has been reported by many authors as a tool potentially able to permit an evaluation of pre-CRT effectiveness basing on the strict relationship between tumor growth and angiogenesis [6-7,24-25].

DCE-MRI is gaining a large consensus as a technique for diagnosis, staging and assessment of therapy response for different types of tumours, due to its capability to detect highly active angiogenesis. It is well known that angiogenesis is a key factor in the growth and dissemination of cancer; characterization of the angiogenic status of the tumour on an individual patient basis could allow for a more targeted approach to treatment of rectal cancer [24].

More specifically, in the case of rectal cancer, previous trials have provided the proof of principle that inhibition of angiogenesis has the potential to enhance the effectiveness of the treatment for this disease. In vivo imaging techniques capable to assess tumour perfusion have

the potential to improve the management of treatment for patients with rectal cancer [6-7,24-25].

Angiogenesis is a key factor for the growth and dissemination of solid tumors and is a prognostic marker in CRC. Neovascularization arises early in the adenoma–carcinoma sequence via upregulation of vascular endothelial growth factor. Tumor angiogenesis is characterized by structurally abnormal blood vessels that are thin, fragile, tortuous, and hyperpermeable. They have a chaotic, heterogeneous intratumoral distribution. Abnormal vascularity often extends beyond the tumor boundaries into surrounding tissues.

DCE-MRI techniques inform on tissue perfusion and vascular leakage (Fig. 2). T1- or relaxivity-based MR sequences are sensitive to the presence of dilute contrast medium in the extravascular– extracellular space. In most tumors, low-molecular-weight contrast media readily diffuse from the blood into the extravascular– extracellular space at a rate determined by perfusion and the capillary permeability and surface area.

The most commonly used model for analyzing DCE-MRI data uses two compartments where the contrast agent resides (blood plasma and extravascular– extracellular space). K^{trans} (volume transfer constant between the blood plasma and the extravascular–extracellular space, the washin rate, measured in minutes⁻¹) and k_{ep} (rate constant between the extravascular–extracellular space back to the blood plasma, the washout rate, measured in minutes⁻¹) determine the transport between these two compartments.

Physiologically, K^{trans} indicates a variable combination of the flow and permeability properties. For blood vessels where leakage is rapid (that is, when the extraction fraction during the first pass of the contrast agent is high, as typically is found in tumors), perfusion will determine contrast agent distribution and K^{trans} approximates to tissue blood flow per unit volume. There are circumstances in which transport out of the vasculature does not significantly deplete intravascular contrast medium concentration (that is, tissues with lower first-pass extraction fraction). This is typically found after treatment with chemotherapy or late after radiotherapy and in fibrotic lesions, and in these situations, K^{trans} approximates to the product of permeability and the surface area (permeability surface area product).

4.2.2. Diffusion-weighted imaging DWI-MRI

At present, the use of diffusion-weighted imaging (DWI) incorporated into a standard MR protocol is gradually increasing because of its proven benefit not only for tumor detection/ characterization but also for monitoring treatment response (8–12). Diffusion-weighted imaging measures water diffusion characteristics, which are dependent on multiple factors such as cell density, vascularity, viscosity of extracellular fluid, and cell membrane integrity (12). By quantifying these properties and expressing them as an apparent diffusion coefficient (ADC), DWI could potentially be used as an imaging biomarker to better select patients with poor prognosis who will truly benefit from a more aggressive neoadjuvant treatment (8-12). In literature it was demonstrated that ADC values of rectal cancers significantly correlate with prognostic factors including the MRF status, the nodal stage and the histological differentiation grade.

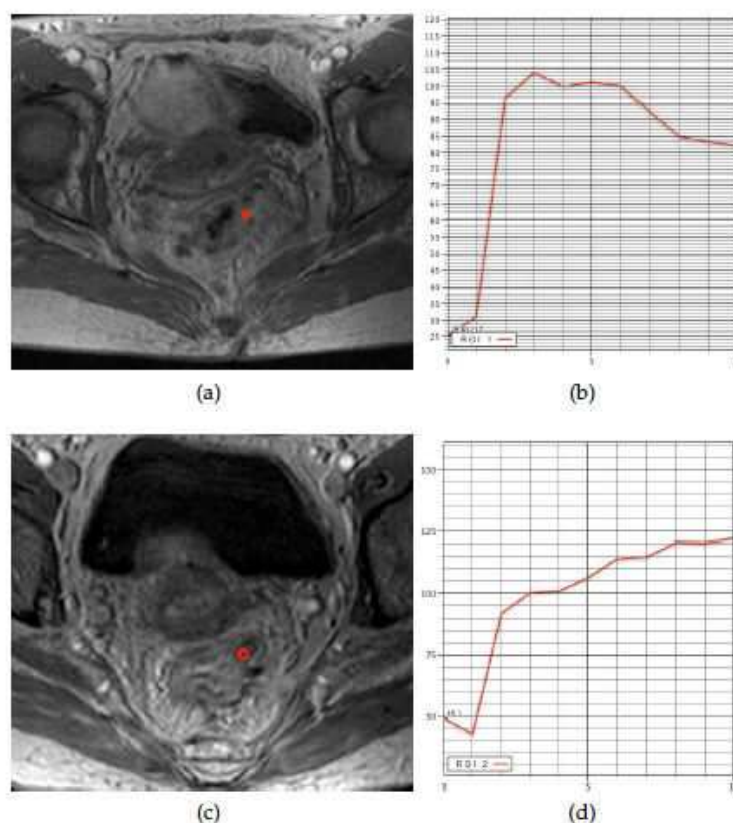


Figure 2. T1w post-contrast scan obtained on the same patient in fig. 8, before (a)-(b) and after (c)-(d) pre-CRT. The analysis of TIC calculated on a ROI, drawn outside the rectal wall where on T2w scans (fig. 8) tumor clearly spreads into peri-rectal fat pad, confirm this suspect showing a rapid CA intake and a fast discharge (b). After pre-CRT, on the same areas showed on T2w scans (fig. 8) no pathological CA uptake is present confirming that hypo-intense tissue visible on T2w scans are tumor nests but only residual inflammation due to pre-CRT. This patient was considered as a Responder. Histopathology showed a TRG 1.

The movement of water molecules in biologic tissues is restricted because their motion is modified and limited by interactions with cell membranes and macromolecules. Water-molecule motion in tissues can be assessed by applying diffusion-weighting gradients to T2-weighted sequences. This process entails the application of two balanced gradients placed symmetrically about a focusing 180° pulse. Water molecules that have not moved during the time taken to apply the first gradient will have acquired phase shifts that are exactly cancelled out by the proceeding second gradient; thus, there is no net additional signal loss induced by the application of the paired diffusion gradients. For water molecules that have moved during the application of the first gradient, however, the acquired phase shifts will not be cancelled out by the second gradient; residual phase incoherence will result in net losses of signal. Hence, the motion of water molecules is detected as attenuation of the measured signal intensity on DWI (Fig. 3).

The sensitivity of the DWI sequence to water motion can be varied by changing the parameter known as the b value (measured in s/mm^2), which is proportional to the gradient amplitude, duration of the applied gradient, and time interval between the paired gradients. DWI can be

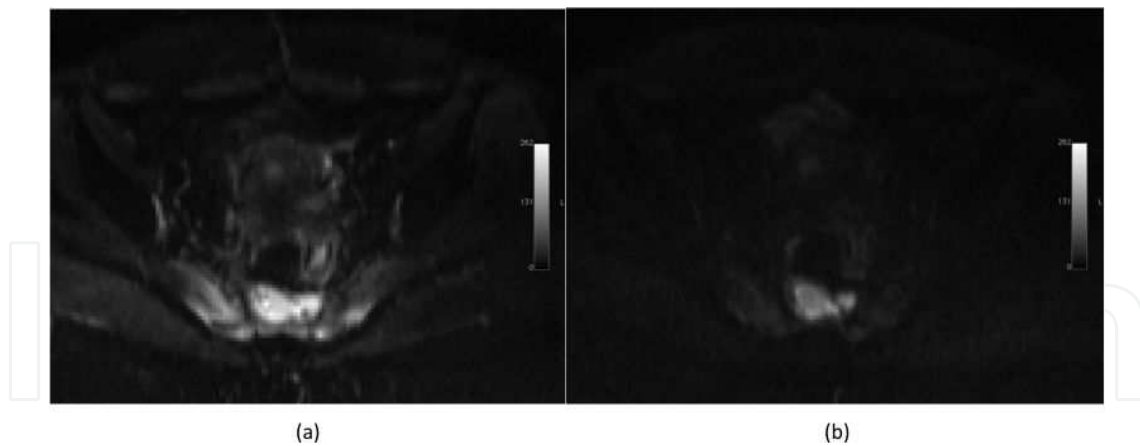


Figure 3. (a) Axial diffusion weighted imaging $b=0$, (b) Axial diffusion weighted imaging $b=800$. Hyperintensity diffusion weighted imaging is consistent with the diagnosis of tumor.

exploited in clinical practice to provide indirect assessments of tissue properties such as cellularity, gland formation, perfusion, and cell death. In general, the greater the cell density per high power field, the more impeded will be tissue water diffusion. Diffusion-weighted signal is derived from the motion of water molecules within the extravascular–extracellular space and intravascular space with some component from intracellular space water. The relative contribution of each space to the derived signal varies from tissue to tissue. In highly vascular tumors, intravascular water diffusion will account for a significant proportion of the diffusion-weighted signal. In highly glandular tissues, such as the pancreas and salivary glands, significant signal contributions arise from glandular water.

By performing DWI using different b values, quantitative analysis is possible with the calculation of the apparent diffusion coefficient (ADC, measured in $\mu\text{m}^2/\text{s}$). Areas of restricted diffusion show low ADC values. ADC values are inversely correlated with tumor cellularity and reductions in ADC correlate with response to cytotoxic therapy.

Areas retaining high signal intensity on high- b -value images usually (but not always) indicate highly cellular tissues such as tumors. Normal tissues including lymph nodes, spleen, nervous tissues, adrenal glands, bowel mucosa, and endometrium may show the same findings. Lower-signal-intensity regions are seen in most organized normal tissues, cystic spaces, and vessels. However, high signal intensities on high- b -value images are not always reliable indicators of increased cellularity on their own. Occasionally, fluid, edema, or mucinous materials remain of high signal intensity because of high proton density. This observation is called T2-shine through, but this effect can be detected easily by noting corresponding high signal on ADC maps.

There is growing interest in the application of DWI for the evaluation of CRC. DWI aids in detection of lesions, particularly when lesions are small. High- b -value DWI may be a useful tool for detecting and defining tumor extent.

DWI has been shown to be feasible as an early marker of treatment response because cell death and vascular alterations typically occur before size changes. Increases in ADC values with

treatment reflect decreases in cellularity and thus provide indirect assessment of chemotherapy induced cell death. It has been reported that transient decreases in ADC may occur early in treatment related to cellular swelling, reduction in blood flow, or reduction in the extravascular– extracellular space due to dehydration. However, early decreases in ADC values are not consistently seen, and it has recently been reported that increases in ADC value with therapy response occur within 3–7 days in responding CRC patients treated with chemotherapy.

Responders had a lower ADC at presentation than non responders. Higher pretreatment ADC values in nonresponders may reflect necrotic tumors that are more resistant to therapy because of concomitant hypoxia. Similarly, for CRC liver metastases, a higher pretreatment ADC is also predictive of poor response.

5. A systematic review

5.1. Methodologies

A systematic literature search was performed to identify English-language studies and articles concerning different diagnostic imaging methodologies available in locally advanced rectal cancer disease after radiation therapy. Data were identified using PubMed database with the following keywords: “locally advanced rectal cancer, magnetic resonance imaging, CT planning, PET imaging”. This yielded 309 titles. Articles, reviews and studies that did not present data about specificity and sensibility of tests treated were excluded. Due to the small number of studies for each imaging modality, there was not set a minimum number of patients as an inclusion criteria. For this reason, a total number of 12 titles were considered as studies included in the research.

Details regarding the number of patients, imaging modality investigated, the accuracy values and parameters examined of the studies were recorded. Cascini et al. [41] evaluated ^{18}F -FDG PET to assess the effect of chemoradiation therapy in thirty-three patients with LARC proved disease. They correlate the change in tumor ^{18}F -FDG standardized uptake value (SUV) during and after preoperative radiotherapy with the pathologic response achieved.

The accuracy of CT and MRI in restaging rectal cancer after preoperative chemoradiation in order to plan optimal therapy was performed in Martellucci et al. [42] study, in which thirty-seven consecutive patients undergoing neoadjuvant therapy were evaluated. Considering the depth of invasion after treatment only in neoplasia with stage T3 they found CT agree with histopathology in 19 cases and MRI in 10/12 cases.

Denecke et al. [46] compare CT, MRI and FDG-PET examining a total of twenty-three patients with T3/4 rectal cancer. Response criteria were a change in T category and tumour volume for CT and MRI and a change in glucose uptake for FDG-PET. Their results in sensitivity and specificity suggest that PET is superior to CT and MRI in predicting response to preoperative multimodal treatment of LARC.

A prospective analysis to evaluate tumor response with ^{18}F -FDG PET in twenty-seven patients with biopsy-proven rectal adenocarcinoma was conducted by Leibold et al. [47]. They found

of the total 27 patients, 11 (41%) had pathologic complete response; 16 (59%) had suboptimal response. They evaluate the ability of change in 4 specific PET parameters to predict pathologic response: the maximum SUV in the region of interest, SUV_{max} ; the average SUV throughout the entire region of interest, SUV_{avg} ; the summed metabolic rate of the tumor, TLG; the virtual graded global assessment of response, VRS.

Chien-Chih Chen et al. [37] evaluated the correlation between pathological verified tumor stage and clinical stage predicted by MRI. The overall predictive accuracy in T stage was 52%, whereas overstaging and understaging occurred in 38% and 10% of patients, respectively. Another study regard the MRI accuracy was conducted by Dresen et al. [45] using T2- weighted MR images obtained before and after radiation therapy and correlating findings with histopathology results.

Kristiansen et al. [39] investigated the possibility of using PET/CT to predict the histopathologic response in 30 patients with LARC treated with a combination of radiotherapy and concurrent Uftoral[®] and leucovorine. PET/CT correctly identified six of eight patients, specificity 75%, with complete pathologic response.

To evaluate the correlation between the change of SUV_{max} and of apparent diffusion coefficient (ADC) before and after neoadjuvant therapy, thirty patients with locally advanced rectal cancer were recruited in Ippolito et al. [40] analysis, in which all the patients underwent a whole body ¹⁸F-FDG PET/CT scan and a pelvic MR examination including DW imaging for staging therapy.

Table 1 summarizes the main characteristics of the examined methodologies in locally advanced rectal cancer studies.

Study	Modality	No.Patients	Parameters
C. C. Chen et al. [37]	MRI	50	TNM
T. Denecke et al. [46]	MRI	23	TNM
	CT	23	TNM
	PET	23	SUV
G. L. Cascini et al. [41]	PET	33	SUV
C. Capirci et al. [38]	PET/CT	45	SUV
C. Kristiansen et al. [39]	PET/CT	30	TRG,SUV
R. Rosenberg et al. [44]	PET/CT	30	SUV
A. Suppiah et al. [36]	MRI	49	TNM
R. C. Dresen et al. [45]	MRI	67	TNM
T. Leibold et al. [47]	PET	27	SUV,TLG,VRS
D. Ippolito et al. [40]	MRI	30	ADC
	PET/CT	30	SUV
J. Martellucci et al. [42]	MRI	20	TNM
	CT	37	TNM
M. J. M. Duréndez et al. [43]	PET/CT	41	SUV

Table 1. Summary of the main characteristics of includes studies about different methodologies used in LARC diseases. Per each study the table reports: imaging modality used; number of patients examined; parameters examined; sensitivity and specificity methodology values.

5.2. Summary ROC curves and Forest Plots

In order to assess individual methodology in LARC treatment, Summary Receiver Operating Characteristic (SROC) curves have been realized, Fig. 4. ROC curves is a statistic technique for displaying, organizing and selecting classifiers based on their performance.

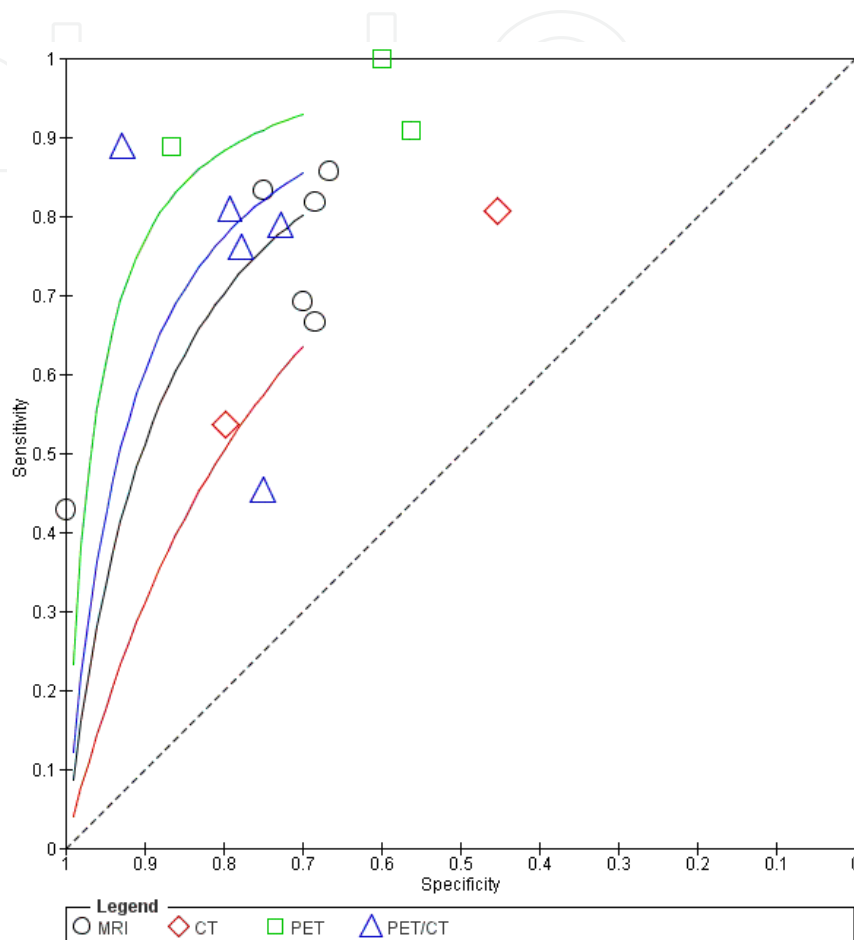


Figure 4. Estimated Summary ROC curves and original data points for four imaging techniques. MRI= magnetic resonance imaging, CT= computed tomography, PET= Positron emission tomography, PET/CT= positron emission tomography and computed tomography.

ROC analysis was performed through the study of the function that links the probability to obtain a true-positive result in the disease like class, i.e. the sensitivity, to the probability to obtain a false-positive result in the non-diseased class, linked to the specificity. In this way a graphical 2D representation that shows the false-positive proportion in x-axis and true-positive proportion in y-axis, relatively to values obtained from each test applied.

For each modality, a model was obtained that was adjusted for significant variables that were set to 1, indicating the ideal design versus 0, as appropriate, Fig. 4. The position of the summary ROC curve indicates the difference in diagnostic performance among the imaging modalities. A summary ROC curve located near the upper left corner indicate the better diagnostic

modality, while a summary ROC curve for a worthless modality is represented by the bisector, also named change line.

Another additional graphical representation realized is the Forest Plot, Fig. 5, which shows the sensitivity and specificity estimates of the results for each study. It is composed of a plot of the measure of effect for each of these studies incorporating confidence intervals represented by horizontal bars. The confidence interval expresses the precision level associated with the parameter estimation: the more is small, the more indicates that the prediction is accurate. In this analysis confidence intervals are computed with a probability of containing the true effect size equal to 95%. The blue square represents the point estimate, i.e. the sensitivity or specificity.

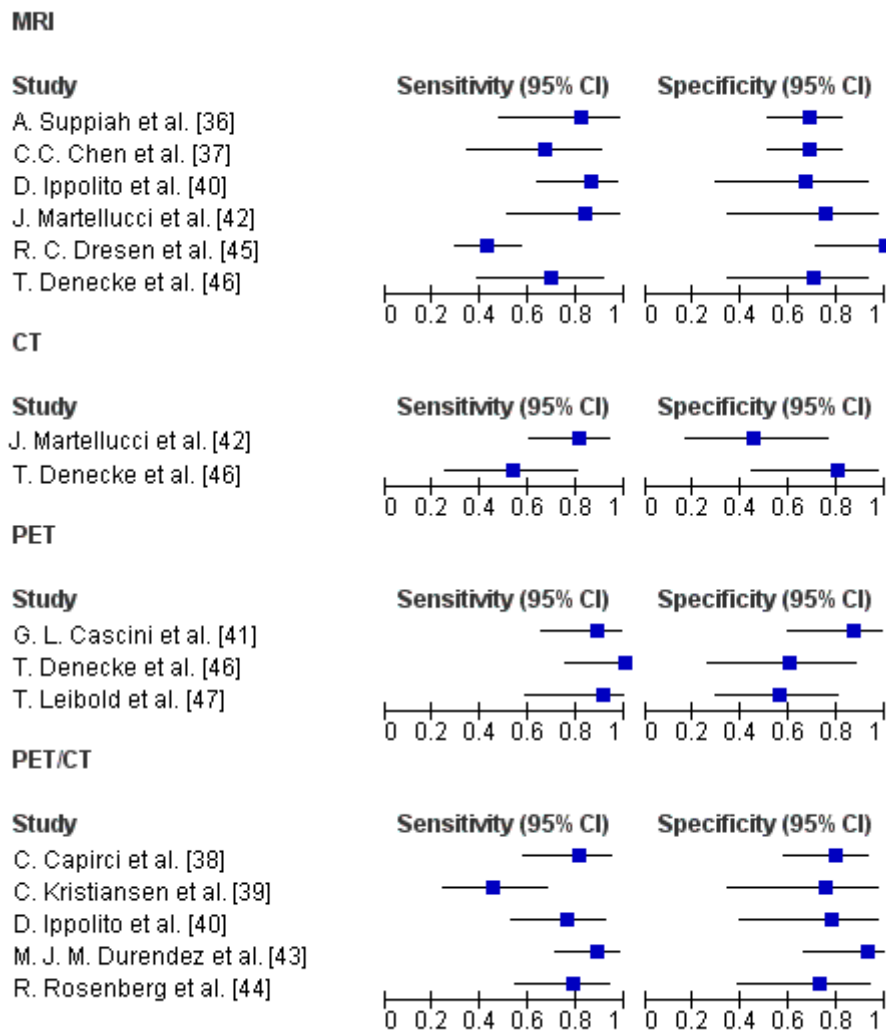


Figure 5. Forest Plot of MRI, CT, PET and PET/CT sensitivity and specificity estimates and their confidence intervals (95%).

5.3. Discussion

The objective of this statistical analysis was to evaluate the diverse methodologies (MRI, PET, PET/CT, CT) in LARC management. In particular, in our analysis we considered the accuracy in assessing the therapy response.

Although, the ROC curves analysis showed that PET has the best accuracy in term of sensitivity and specificity it should be noticed that only three studies have been retrieved from the literature.

However, in agreement with the intuitive considerations MRI and PET/ CT showed a high diagnostic accuracy and their results are also more reliable than PET because the statistical analysis has been carried out on a larger number of studies (6 studies for MRI with a total of 239 patients and 5 studies for PET/CT with a total of 176 patients).

The number of studies for CT is very small to draw detailed conclusions.

In conclusion we could state that a greater number of studies should be performed in the future for each modalities to improve the reliability of any conclusion.

Author details

Roberta Fusco^{1,3}, Mario Sansone², Mario Petrillo³, Antonio Avallone⁴, Paolo Delrio³, Fabiana Tatangelo³ and Antonella Petrillo¹

1 Department of Diagnostic Imaging, Radiant and Metabolic Therapy, "Istituto Nazionale dei Tumori Fondazione G. Pascale" – IRCCS, Naples, Italy

2 Department of Electrical Engineering and Information Technologies University 'Federico II' of Naples, Italy

3 Department of Radiology, Second University of Naples, Italy

4 Gastrointestinal Medical Oncology, "Istituto Nazionale dei Tumori Fondazione G. Pascale" – IRCCS, Naples, Italy

References

- [1] Jemal A, Siegel R, Xu J, Ward E. Cancer statistics, 2010. *CA Cancer J Clin* 2010;60(5): 277–300.
- [2] Folkman J Tumor angiogenesis: therapeutic implications. *N Engl J Med* 1971;285:1182–1186.

- [3] Choi HJ, Hyun MS, Jung GJ, Kim SS, Hong SH. Tumor angiogenesis as a prognostic predictor in colorectal carcinoma with special reference to mode of metastasis and recurrence. *Oncology* 1998; 55:575–581.
- [4] Dvorak HF, Brown LF, Detmar M, Dvorak AM. Vascular permeability factor/vascular endothelial growth factor, microvascular hyperpermeability, and angiogenesis. *Am J Pathol* 1995;146:1029–1039.
- [5] Dzik-Jurasz A, Domenig C, George M et al (2002) Diffusion MRI for prediction of response of rectal cancer to chemoradiation. *Lancet* 360 (9329):307–308
- [6] DeVries AF, Griebel J, Kremser C et al (2001) Tumor microcirculation evaluated by dynamic magnetic resonance imaging predicts therapy outcome for primary rectal carcinoma. *Cancer Res* 61(6):2513–2516
- [7] DeVries AF, Kremser C, Hein PA et al (2003) Tumor microcirculation and diffusion predict therapy outcome for primary rectal carcinoma. *Int J Radiat Oncol Biol Phys* 56(4):958–96
- [8] Koh DM, Padhani AR. Diffusion-weighted MRI: a new functional clinical technique for tumor imaging. *Br J Radiol* 2006;79: 633–635.
- [9] Koh DM, Collins DJ. Diffusion-weighted MRI in the body: applications and challenges in oncology. *AJR Am J Roentgenol* 2007; 188:1622–1635.
- [10] Patterson DM, Padhani AR, Collins DJ. Technology insight: water diffusion MRI-a potential new biomarker of response to cancer therapy. *Nat Clin Pract Oncol* 2008;5:220–233.
- [11] Padhani AR, Liu G, Koh DM, et al. Diffusion-weighted magnetic resonance imaging as a cancer biomarker: consensus and recommendations. *Neoplasia* 2009;11:102–125.
- [12] deSouza NM, Riches SF, Vanas NJ, et al. Diffusion-weighted magnetic resonance imaging: a potential non-invasive marker of tumour aggressiveness in localized prostate cancer. *Clin Radiol* 2008;63:774–782.
- [13] Avallone A, Delrio P, Guida C, Tatangelo F, Petrillo A, Marone P, Cascini LG, Morrica B, Lastoria S, Parisi V, Budillon A, Comella P. (2006). Biweekly oxaliplatin, raltitrexed, 5-fluorouracil and folinic acid combination chemotherapy during preoperative radiation therapy for locally advanced rectal cancer: a phase I-II study, *Brit J Cancer* 94(12): 1809–1815.
- [14] Avallone A, Delrio P, Pecori B, Tatangelo F, Petrillo A, Scott N, Marone P, Aloï L, Sandomenico C, Lastoria S, Iaffaioli VR, Scala D, Iodice G, Budillon A., Comella P. (2011). Oxaliplatin plus dual inhibition of thymidilate synthase during preoperative pelvic radiotherapy for locally advanced rectal carcinoma: long-term outcome, *Int J Radiat Oncol* 79(3): 670–676.
- [15] Delrio P, Avallone A, Guida C, Lastoria S, Tatangelo F, Cascini GM, Marone P, Petrillo, A, Budillon A, Marzo MD, Palaia R, Albino V, Rosa VD, Parisi V. (2005). Multidis-

ciplinary approach to locally advanced rectal cancer: results of a single institution trial, *Suppl Tumori* 4(3): S8.

- [16] Delrio P, Lastoria S, Avallone A, Ravo V, Guida C, Cremona F, Izzo F, Palaia R, Ruffolo F, Puppio B, Guidetti GM, Cascini GL, Casaretti R, Tatangelo F, Marone P, Rossi GB, Budillon A, Petrillo A, Rosa VD, Comella G, Morrica B, Tempesta A, Botti G, Parisi V. (2003). Early evaluation using PET-FDG of the efficiency of neoadjuvant radiochemotherapy treatment in locally advanced neoplasia of the lower rectum, *Tumori* 89(4 Suppl): 50–53.
- [17] Petrillo A, Catalano O, Delrio P, Avallone A, Guida C, Filice S, Siani A. (2007). Post-treatment fistulas in patients with rectal cancer: MRI with rectal superparamagnetic contrast agent, *Abdom Imaging* 32(3): 328–331.
- [18] Petrillo A, Filice S, Avallone A, Delrio P, Guida C, Tatangelo F, Marone P, Nunziata A, Siani A. (2006). Staging of locally advanced rectal cancer (LARC): proposal of 96 Rectal Cancer – A Multidisciplinary Approach to Management Dynamic Contrast Enhanced Magnetic Resonance Imaging in Rectal Cancer 23 a one-stop magnetic resonance (MR) imaging-based protocol, *Eur Radiol Supplements* 16: 321–494.
- [19] Sansone M, Fusco R, Petrillo A, Petrillo M, Bracale M. (2011). An expectation-maximisation approach for simultaneous pixel classification and tracer kinetic modelling in dynamic contrast enhanced-magnetic resonance imaging, *Med Biol Eng Comput* 49(4): 485–495.
- [20] Fusco R, Sansone M, Petrillo M, Antonella Petrillo. Influence of parameterization on tracer kinetic modeling in DCE-MRI. *Journal of Medical and Biological Engineering*, Uncorrected Proof Available online 7 Sep 2012, doi: 10.5405/jmbe.1097
- [21] Fusco R, Sansone M, Maffei S, Petrillo.A. Dynamic Contrast-Enhanced MRI in Breast Cancer: A Comparison between Distributed and Compartmental Tracer Kinetic Models. *Journal of Biomedical Graphics and Computing*, *Journal of Biomedical Graphics and Computing*, vol. 2, no. 2, p. p23, Aug. 2012.
- [22] Gunderson LL, Sargent DJ, Tepper JE, O'Connell MJ, Allmer C, Smalley SR, Martenson JA, Haller D. G., Mayer, R. J., Rich, T. A., Ajani, J. A., Macdonald, J. S. & Goldberg, R.M. (2002). Impact of T and Nsubstage on survival and disease relapse in adjuvant rectal cancer: a pooled analysis, *Int J Radiat Oncol* 54(2): 386–396.
- [23] Gunderson LL, Sargent DJ, Tepper JE, Wolmark N, O'Connell MJ, Begovic M, Allmer C, Colangelo L, Smalley SR, Haller DG, Martenson JA, Mayer RJ, Rich TA, Ajani JA, MacDonald JS, Willett CG, Goldberg RM. Impact of T and N stage and treatment on survival and relapse in adjuvant rectal cancer: a pooled analysis, *J Clin Oncol* 2004; 22(10): 1785–1796.
- [24] Goh V, Padhani AR, Rasheed S. Functional imaging of colorectal cancer angiogenesis, *Lancet Oncol* 2007; 8(3): 245–255.

- [25] Kremser C, Trieb T, Rudisch A, Judmaier W, de Vries A. Dynamic t(1) mapping predicts outcome of chemoradiation therapy in primary rectal carcinoma: sequence implementation and data analysis, *J Magn Reson Imaging* 2007; 26(3): 662–671.
- [26] Beets-Tan RG, Beets GL. Rectal cancer: review with emphasis on MR imaging. *Radiology*. 2004 Aug;232(2):335-46.
- [27] Kapiteijn E, Marijnen CA, Nagtegaal ID, et al. Preoperative radiotherapy combined with total mesorectal excision for resectable rectal cancer. *N Engl J Med* 2001;345:638–646
- [28] Vermaas M, Ferenschild FT, Nuyttens JJ, et al. Preoperative radiotherapy improves outcome in recurrent rectal cancer. *Dis Colon Rectum* 2005;48:918–928
- [29] Gerard JP, Conroy T, Bonnetain F, et al. Preoperative radiotherapy with or without concurrent fluorouracil and leucovorin in T3–4 rectal cancers: results of FFC0 9203. *J Clin Oncol* 2006;24:4620–4625
- [30] Bosset JF, Collette L, Calais G, et al. Chemotherapy with preoperative radiotherapy in rectal cancer. *N Engl J Med* 2006;355:1114–1123
- [31] Bosset JF, Calais G, Daban A, et al. Preoperative chemoradiotherapy versus preoperative radiotherapy in rectal cancer patients: assessment of acute toxicity and treatment compliance. Report of the 22921 randomised trial conducted by the EORTC Radiotherapy Group. *Eur J Cancer* 2004;40:219–224
- [32] Willett CG, Boucher Y, di Tomaso E, et al. Direct evidence that the VEGF-specific antibody bevacizumab has antivascular effects in human rectal cancer. *Nat Med* 2004;10:145–147
- [33] Vermaas M, Ferenschild FT, Verhoef C, et al. Total pelvic exenteration for primary locally advanced and locally recurrent rectal cancer. *Eur J Surg Oncol* 2007;33(4):452–458
- [34] Wiig JN, Poulsen JP, Larsen S, Braendengen M, Waehre H, Giercksky KE. Total pelvic exenteration with preoperative irradiation for advanced primary and recurrent rectal cancer. *Eur J Surg* 2002;168:42–48
- [35] Luna-Perez P, Delgado S, Labastida S, Ortiz N, Rodriguez D, Herrera L. Patterns of recurrence following pelvic exenteration and external radiotherapy for locally advanced primary rectal adenocarcinoma. *Ann Surg Oncol* 1996;3:526–533
- [36] Suppiah A, Hunter IA, Cowley J, Garimella V, Cast J, Hartley JE, Monson JRT. Magnetic resonance imaging accuracy in assessing tumour down-staging following chemoradiation in rectal cancer. *Colorectal Disease* 22 April 2008;11:249-253.
- [37] Chen CC, Lee RC, Lin JK, Wang LW, Yang SH. How Accurate is Magnetic Resonance Imaging in Restaging Rectal Cancer in Patients Receiving Preoperative Combined Chemoradiotherapy? *Disease of the Colon & Rectum* 17 February 2005;48:722-728.

- [38] Capirci C, Rampin L, Erba PA, Galeotti, Crepaldi G, Banti E, Gava M, Fanti S, Mariani G, Muzzio PC, Rubello D. Sequential FDG-PET/CT reliably predicts response of locally advanced rectal cancer to neo-adjuvant chemo-radiation therapy. *Nucl Med Mol Imaging* 2007;34:1583-1593.
- [39] Kristiansen C, Loft A, Berthelsen AK, Graff J, Lindebjerg J, Bisgaard C, Jakobsen A. PET/CT and Histopathologic Response to Preoperative Chemoradiation Therapy in Locally Advanced Rectal Cancer. *Disease of the Colon & Rectum* 2008;51:21-25.
- [40] Ippolito D, Monguzzi L, Guerra L, Deponti E, Gardani G, Messa C, Sironi S. Response to neoadjuvant therapy in locally advanced rectal cancer: assessment with diffusion-weighted MR imaging and 18FDG PET/CT. *Abdominal Imaging* 20 January 2012.
- [41] Cascini GL, Avallone A, Delrio P, Guida C, Tatangelo F, Marone P, Aloj L, De Martinis F, Comella P, Parisi V, Lastoria S. 18F-FDG PET Is an Early Predictor of Pathologic Tumor Response to Preoperative Radiochemotherapy in Locally Advanced Rectal Cancer. *The journal of nuclear medicine* August 2006;47(8):1241-1248.
- [42] Martellucci J, Scheiterle M, Lorenzi B, Roviello F, Cetta F, Pinto E, Tanzini G. Accuracy of transrectal ultrasound after preoperative radiochemotherapy compared to computed tomography and magnetic resonance in locally advanced rectal cancer. *Journal of Colorectal Diseases* 3 February 2012;27:967-973.
- [43] Murcia MJ, Duréndez L, Frutos Esteban J, Luján MD, Frutos G, Valero JL, Navarro Fernández L, Mohamed Salem G, Ruiz Merino MA, Claver Valderas. The value of 18F-FDG PET/CT for assessing the response to neoadjuvant therapy in locally advanced rectal cancer. *Nucl Med Mol Imaging* 19 October 2012;40:91-97.
- [44] Rosenberg R, Herrmann K, Gertler R, Künzli B, Essler M, Lordick F, Becker K, Schuster T, Geinitz H, Maak M, Schwaiger M, Siewert JR, Krause B. The predictive value of metabolic response to preoperative radiochemotherapy in locally advanced rectal cancer measured by PET/CT. *Colorectal Disease* 3 December 2008;24:191-200.
- [45] Dresen RC, Beets GL, Rutten HJT, Engelen SME, Lahaye MJ, Vliegen RFA, de Bruïne AP, Kessels AGH, Lammering G, Beets-Tan RGH. Locally Advanced Rectal Cancer: MR Imaging for Restaging after Neoadjuvant Radiation Therapy with Concomitant Chemotherapy Part I. Are We Able to Predict Tumor Confined to the Rectal Wall? *Radiology* July 2009;252(1):71-80.
- [46] T. Denecke, B. Rau, K.-T. Hoffmann, B. Hildebrandt, J. Ruf, M. Gutberlet, M. Hünerbein, R. Felix, P. Wust, H. Amthauer. Comparison of CT, MRI and FDG-PET in response prediction of patients with locally advanced rectal cancer after multimodal preoperative therapy: Is there a benefit in using functional imaging? *European Journal of Radiology* 2 April 2005;15:1658-1666.
- [47] Leibold T, Akhurst TJ, Chessin DB, Yeung HW, Macapinlac H, Shia J, Minsky BD, Saltz LB, Riedel E, Mazumdar M, Paty PB, Weiser MR, Douglas WW, Larson SM,

- Guillem JG. Evaluation of 18F-FDG-PET for Early Detection of Suboptimal Response of Rectal Cancer to Preoperative Chemoradiotherapy: A Prospective Analysis. *Official Journal of the society of surgical oncology* 2011;18:2783-2789.
- [48] Chau I, Allen M, Cunningham D, Tait D, Brown G, Hill M, Sumpter K, Rhodes A, Wotherspoon A, Norman AR, Hill A, Massey A, Prior Y. Neoadjuvant systemic fluorouracil and mitomycin C prior to synchronous chemoradiation is an effective strategy in locally advanced rectal cancer. *British Journal of Cancer* 2003;88:1017-1024.
- [49] Corner C, Khimji F, Tsang Y, Harrison M, Glynne-Jones R, Hughes R. Comparison of conventional and three-dimensional conformal CT planning techniques for preoperative chemoradiotherapy for locally advanced rectal cancer. *The British Journal of Radiology* 4 December 2009;84:173-178.
- [50] Ruby JA, Leibold T, Akhurst TJ, Shia J, Saltz LB, Mazumdar M, Riedel ER, Larson SM, Guillem JG. FDG-PET Assessment of Rectal Cancer Response to Neoadjuvant Chemoradiotherapy Is Not Associated With Long-Term Prognosis: A Prospective Evaluation. *Diseases of the colon and rectum* 2012;55(4):378-386.
- [51] Kuo LJ, Chern MC, Tsou MH, Liu MC, Jian JJM, Chen CM, Chung YL, Fang WT. Interpretation of Magnetic Resonance Imaging for Locally Advanced Rectal Carcinoma After Preoperative Chemoradiation Therapy. *Disease of the Colon & Rectum* 7 December 2004;48(23-28).
- [52] Yeung JMC, Kalff V, Hicks RJ, Drummond E, Link E, Phil D, Taouk Y, Michael M, Ngan S, Lynch AC, Heriot AG. Metabolic Response of Rectal Cancer Assessed by 18-FDG PET Following Chemoradiotherapy is Prognostic for Patient Outcome. *Diseases of the colon & rectum* 2011;54:518-525.
- [53] Mezzi G, Arcidiacono PG, Carrara S, Perri F, Petrone MC, De Cobelli F, Gusmini S, Staudacher C, Del Maschio A, Testoni PA. Endoscopic ultrasound and magnetic resonance imaging for re-staging rectal cancer after radiotherapy. *World Journal of Gastroenterology* 28 November 2009;44:5563-5567.
- [54] Patel UB, Taylor F, Blomqvist L, George C, Evans H, Tekkis P, Quirke P, Sebag-Montefiore D, Moran B, Heald R, Guthrie A, Bees N, Swift I, Pennert K, Brown G. Magnetic Resonance Imaging-Detected Tumor Response for Locally Advanced Rectal Cancer Predicts Survival Outcomes: MERCURY Experience. *Journal of Clinical Oncology* 2011;1-11.
- [55] Johnston DF, Lawrence KM, Sizer BF, Arulampalam THA, Motson RW, Dove E, Lacey N. Locally advanced rectal cancer: histopathological correlation and predictive accuracy of serial MRI after neoadjuvant chemotherapy. *The british journal of radiology* 2009;82:332-336.
- [56] Shanmugan S, Arrangoiz R, Nitzkorski JR, Yu JQ, Li T, Cooper H, Konski A, Farma JM, Sigurdson ER. Predicting Pathological Response to Neoadjuvant Chemoradio-

therapy in Locally Advanced Rectal Cancer Using¹⁸F-FDG-PET/CT. *Society of Surgical Oncology* 7 March 2012;19:2178-2185.

- [57] Itatani Y, Akiyoshi T, Kuroyanagi H, Yamakawa K, Noaki R, Konishi T, Fujimoto Y, Ueno M, Oya M, Suenaga M, Yamaguchi T. Total mesorectal excision of initially unresectable locally advanced rectal cancer infiltrating the pelvic wall after treatment with FOLFOX4 plus bevacizumab and preoperative chemoradiation: report of a case. *Surg Today* 12 November 2011;42(75-79).
- [58] O'Neill BDP, Brown G, Heald RJ, Cunningham D, Tait DM. Non-operative treatment after neoadjuvant chemoradiotherapy for rectal cancer. *The lancet oncology* July 2007;8:625-633.
- [59] Fusco R, Sansone M, Petrillo M, Avallone A, Delrio P, Antonella Petrillo (2011). *Dynamic Contrast Enhanced Magnetic Resonance Imaging in Rectal Cancer, Rectal Cancer - A Multidisciplinary Approach to Management*, Giulio Aniello Santoro (Ed.), ISBN: 978-953-307-758-1, InTech, Available from: <http://www.intechopen.com/books/rectal-cancer-a-multidisciplinary-approach-to-management/dynamic-contrast-enhanced-magnetic-resonance-imaging-in-rectal-cancer>.
- [60] Beets-Tan RG, Beets GL, Borstlap SC, Oei Tk, Teune TM, von Meyenfeldt MF, et al. Preoperative assessment of local tumour extent in advanced rectal cancer: CT or high-resolution MRI? *Abdominal Imaging* 2000;25(5):533-41.
- [61] Wiering B, Ruers TJ, Oyen WJ. Role of FDG-PET in the diagnosis and treatment of colorectal liver metastases. *Expert Rev Anticancer Ther* 2004; 4: 607-13.
- [62] Park IJ, Kim HC, Yu CS, et al. Efficacy of PET/CT in the accurate evaluation of primary colorectal carcinoma. *Eur J Surg Oncol* 2006; 32:941-947.