

We are IntechOpen, the world's leading publisher of Open Access books Built by scientists, for scientists

4,800

Open access books available

122,000

International authors and editors

135M

Downloads

Our authors are among the

154

Countries delivered to

TOP 1%

most cited scientists

12.2%

Contributors from top 500 universities



WEB OF SCIENCE™

Selection of our books indexed in the Book Citation Index
in Web of Science™ Core Collection (BKCI)

Interested in publishing with us?
Contact book.department@intechopen.com

Numbers displayed above are based on latest data collected.

For more information visit www.intechopen.com



Pemphigus Vulgaris and Pemphigus Foliaceus

Suran L. Fernando, Jamma Li and Mark Schifter

Additional information is available at the end of the chapter

<http://dx.doi.org/10.5772/56423>

1. Introduction

The word “pemphigus” is derived from the Greek term “pemphix” meaning bubble or blister. Pemphigus is a group of autoimmune diseases (see Table 4) characterized by intra-epithelial blistering, resulting in superficial vesicles or bullae that easily rupture, resulting in ulceration of mucosal and/or cutaneous sites. Although rare, pemphigus causes significant morbidity and potential mortality for patients. The two main subtypes are pemphigus vulgaris (PV), and pemphigus foliaceus (PF), of which PV is the most common and clinically, the most aggressive variant, being associated with significant morbidity and mortality, composing 70% of all reported cases of pemphigus: Less common forms and variants include paraneoplastic pemphigus, drug induced pemphigus, and IgA pemphigus. This book chapter focuses on the diagnosis and treatment of PV and PF.

2. Epidemiology

The estimated incidence of pemphigus is 1-16 cases per year per million people [1],[2]. PV is the most common type of pemphigus found in the USA and Europe. In the USA, PV is 5 times as prevalent as PF [3]. In contrast, PF is more common in certain countries such as Finland and South Africa [4] and the endemic variety, Fogo Salvegem, affects up to 3% of the population, in affected rural regions in Brazil, Columbia, and Tunisia [5]-[7].

3. Pathogenesis

The pathogenesis of pemphigus involves the targeting of inter-keratinocyte adhesion molecules by autoantibodies, leading to acantholysis and subsequent blister formation. There are

four subtypes of desmoglein, which are glycoproteins that belong to a superfamily of cadherin molecules and are essential components of desmosomal intracellular adhesive junctions [8]. The molecular target in PF is desmoglein-1, which is found predominantly in the upper layers of the epidermis of the skin [9] [10]. Two subtypes of PV are described. In mucosal-dominant PV, the molecular target is restricted to desmoglein-3, whereas in mucocutaneous PV, the target is desmoglein-3 and desmoglein-1.[8] Desmoglein-3 is found in mucous membranes and predominantly in the lower layers of the epidermis of the skin and hence explains the absence of mucous membrane involvement in PF. Current evidence suggests that autoantibodies to desmogleins cause the loss of this desmosome from the surface of the keratinocyte and rearrangement of the actin cytoskeleton. This results in an unidentified cascade of signalling events resulting in apoptotic cell death and acantholysis [11]. Autoantibodies to desmoglein-3 and desmoglein-1 are paramount in the pathogenesis of PV and PF. In PV, this is demonstrated by the fact that passive transfer of serum IgG to desmoglein-3 into newborn mice induces blister formation [12].

Interaction between antigen specific T cells and B cells is postulated for the production of antibodies to desmoglein-3 and desmoglein-1. Autoantibody production has been shown, in vitro, to be dependent on mononuclear cells [13]. Further, aberrant T cell recognition of desmoglein-3 and desmoglein-1 is likely involved in the initiation and perpetuation of the B cell response.

Additionally, in PV, HLA Class 2 alleles including HLA DR β 1*0402, β 1*1401, β 1*0503 may be involved in the presentation of desmoglein-3 peptides to autoreactive T cells. However, similar associations are not observed in PF [14]. Further it has been observed that autoantibodies of the Th2-dependent IgG4 subtype are present in active disease but are not detectable in inactive disease or healthy individuals [15]. In active disease, IgG1 and IgG4 recognises epitopes in EC1 (amino acids 50-79, Bos 1) and EC2 (amino acids 200-29, Bos 2) of desmoglein-3. In inactive disease, only autoantibodies of the Th1-dependent IgG1 subtype to EC1 are detectable [15]. These observations suggest that IgG4 against EC2 is the main antibody responsible for acantholysis, but that this process may be facilitated or enhanced by IgG4 against EC1 [14].

A Th2 response predominates in PV. This suggests that Th2 cells are needed to activate B cells to initiate antibody production [16]. Further, in PV and PF, imbalance between Th2 and Th1 cytokines in terms of the elevation of the former against the suppression of the latter is postulated to contribute to pathogenesis [16],[17]. It is possible that Th17 and Treg pathways may also be integral. However, the association between Th cell subsets and disease activity is not well understood.

PV autoantibodies also bind large portions of keratinocytes outside desmosomal structures. Autoantibodies against other keratinocyte surface antigens such as desmoglein-4, desmocollins, acetylcholine receptors, pemphaxin and α -9 acetylcholine receptors, of which some or maybe all, may be involved in the pathogenesis of PV [8]. It is not clear whether blister formation is a direct result of these antibodies or occurs indirectly through immune mediated pathways which involve inflammatory cells and cytokines [14]. For instance, TNF- α is observed to be raised in PV compared to healthy controls, and may also increase with disease activity [16],[18].

Genetic susceptibility by individuals that increases their risk for developing pemphigus is suggested by studies describing associations between certain HLA polymorphisms and subtypes of disease. For instance, HLA-DRB*0102, 0404, 1402, and 1406 have been associated with endemic PF [5]. In 87 Italian patients, 61 with PV and 26 with PF, it was found that pemphigus vulgaris and pemphigus foliaceus share HLA-DRB1*1401 and DQB1*0503, are both associated with both PV and PF, whereas DRB1*0402 is only prevalent in patients with PV [19]. In a group of 20 French patients [20] the HLA alleles DRB1*0404 and DRB1*0102 were found to be associated with PF. It remains to be determined, whether these HLA-polymorphisms are true disease susceptibility genes given their role in antigen presentation. Alternatively, they may be markers of disease susceptibility through strong linkage disequilibrium with the causative gene. An environmental trigger may ultimately result in expression of disease in genetically susceptible individuals as is suspected to occur in endemic PF in Brazil[21]. Recently, it has been postulated that the inciting antigen in Brazil is a salivary protein from a haematophagous black fly, *Simulium nigricornum* [22].

Disease and Subtype(s) (alternate terms)		Clinical Presentation		Natural History/ Prognosis/ Outcome	Target Antigens
Oral	Cutaneous				
Pemphigus vulgaris (PV)		Common. Usually the first site involved	Commonest and most aggressive form of pemphigus: oral mucosal involvement common and often first site of presentation leading to extensive skin involvement.	Fatal if untreated Good with treatment	Desmoglein 3 (Dsg 3 is more common in oral epithelium)
Pemphigus vegetans		Rare (in all 3 forms of pemphigus vegetans)	Uncommon and less aggressive clinical variant of PV: presents with large verrucous confluent plaques and pustules localized to flexural areas (axilla/groin).	Often progresses to pemphigus vulgaris	(& Desmoglein 1 (Dsg-1 & 3 are both found in skin))
Pemphigus vegetans of Neumann			Often begins and ends as typical PV. Needs more intense immune-suppression than seen with PV, with patients troubled by chronic relapses (and remissions).	Frequent relapses (even with treatment)	
Pemphigus vegetans of Hallopeau			Relatively benign, usually very well localised disease.	Prolonged remission (with treatment)	
Pemphigus foliaceus (PF)		Rare	All forms of PF are characterised clinically by superficial cutaneous blisters and erosions seen on histology as subcorneal acantholysis.	More benign course than PV, with prolonged remission.	Desmoglein 1
Pemphigus erythematous ("Senear-Usher syndrome")			Very rare condition with the combined features of pemphigus foliaceus and SLE		

Disease and Subtype(s) <i>(alternate terms)</i>	Clinical Presentation	Natural History/ Prognosis/ Outcome	Target Antigens
Endemic pemphigus ("Brazilian pemphigus" or "Fogo Sevagem" (FS))	Common (endemic form)	PF and FS are identical clinically, histologically, and serologically but differ significantly, <i>epidemiologically</i> , with marked geographic clustering in Brazil, being a diseases of people resident in/or near the rainforests. The autoimmune response in FS is thought to be triggered by a putative environmental factor.	
IgA pemphigus	Rare (all 3 forms of IgA pemphigus)	Rare, characterised by pruritic, flaccid vesicles and/or pustules in annular pattern with central crusting, sometimes hypopyon* of the eye. Pathogenesis: related to the neutrophilic infiltrate in the epidermis rather than solely to the binding of IgA to target epidermal antigens. DIF: IgA (cf IgG seen in all other forms of pemphigus) deposits in lower epithelium or entire epidermal cell surfaces	Recalcitrant to treatment with corticosteroids
Subcorneal pustular dermatosis <i>("Sneddon-Wilkinson disease")</i>		Subcorneal (beneath the stratum corneum) blister containing neutrophils with epidermal acanthosis and spongiosis, results in superficial fragile blistering.	
Intraepidermal neutrophilic IgA dermatosis		Deeper, intra-epidermal blister containing neutrophils with epidermal acanthosis and spongiosis, results in more marked blistering and consequent ulceration.	
Paraneoplastic pemphigus	Common & very severe	Polymorphous skin eruption, consisting of blisters, erosions, and targetoid lesions; severe mucous membrane involvement. DIF: IgG deposits on entire epidermal cell surfaces +/- granular-linear complement auto-antibodies to rat bladder epithelium in 75% of cases.	Fatal Desmoglein 3, Desmoplakin 1, Desmoplakin 2, BP 230, evoplakin, periplakin, others
Familial benign chronic pemphigus <i>("Hailey-Hailey disease")</i>	Rare	Not a true form of pemphigus, as it is not antibody mediated. It presents a chronic recurrent bullous and vesicular dermatitis of intertriginous areas that is characterized histologically by suprabasilar acantholysis.	chronic, relapsing– remitting course Desmocollin 1

Disease and Subtype(s) (alternate terms)	Clinical Presentation	Natural History/ Prognosis/ Outcome	Target Antigens
		<p>Pathogenesis: heterozygous mutations of the ATP2C1 gene leads to a malfunction of the encoded protein hPMR1 - hPMR1 being a high-affinity calcium transport ATPase pump of the Golgi complex. A low level of intracellular Ca²⁺ induces premature keratinocyte proliferation, which leads to dysfunctional desmosomal proteins and thus abnormal keratinocyte adhesion.</p>	

PV = pemphigus vulgaris; PF = pemphigus foliaceus, SLE = systemic lupus erythematosus, FS = Fogo Sevagem, DIF = direct immune-fluorescence,

cf = in contrast, BP = bullous pemphigoid, AD = autosomal dominant inheritance, Ca²⁺ = calcium ion

*hypopyon= sterile leukocytic exudate, seen in the anterior chamber of the eye

Table 1. Clinical and Immunohistochemical Variants of Pemphigus

4. Clinical features

4.1. Pemphigus vulgaris

Patients with PV usually present, in the initial stage, with highly painful erosions of the oral mucosa (Figures 1, 2) [23], but other mucous membranes such as the nasal, laryngo-esophageal, genital, anal and conjunctival mucosae can be involved. Some patients have mucosal dominant disease whereas in others cutaneous lesions develop and manifest as flaccid blisters followed by denuding and ulceration (Figure 3). A direct Nikolsky's sign can be elicited where tangential pressure on the on perilesional skin causes the epidermis to separate from the dermis. Skin lesions have a predilection for the trunk, groins, axillae, scalp, face, and pressure points. Secondary infection and dehydration are frequent cause of morbidity and mortality. Studies that differentiate PV according to clinical phenotype have shown a lower mortality in patients with predominantly mucosal PV (1–17%) compared with those with mucocutaneous PV (34–42%)[24].

4.2. Pemphigus foliaceus

Non-endemic PF usually presents in middle age or older adults whereas endemic PF is more common in children and young adults. FS in Tunisian affect women 4 times as often as men [7]. In both non-endemic and endemic PF, patients usually report the eruption of blisters on the scalp, face and upper trunk but they are fragile and some patients present instead with multiple painful crusted erosions (Figure 4). There is no history of mucosal involvement.

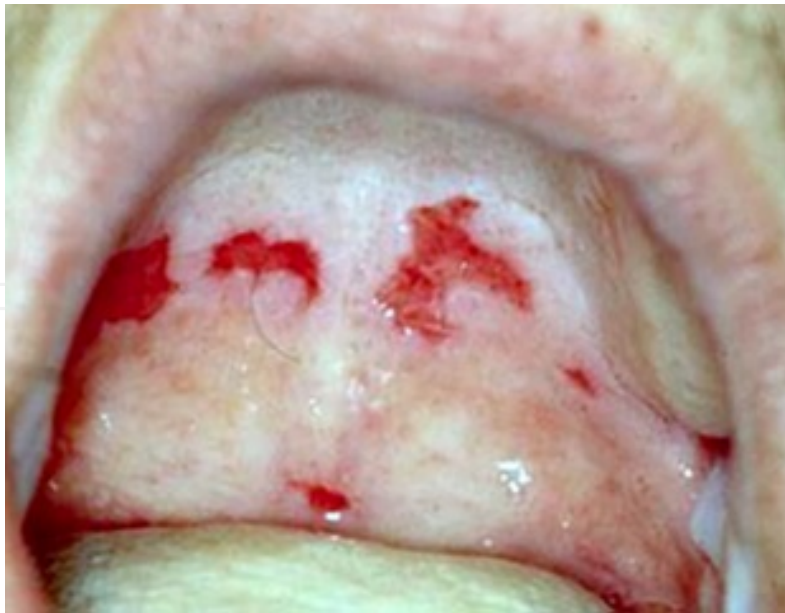

Figure 1. Pemphigus vulgaris with palatal ulceration and bleeding

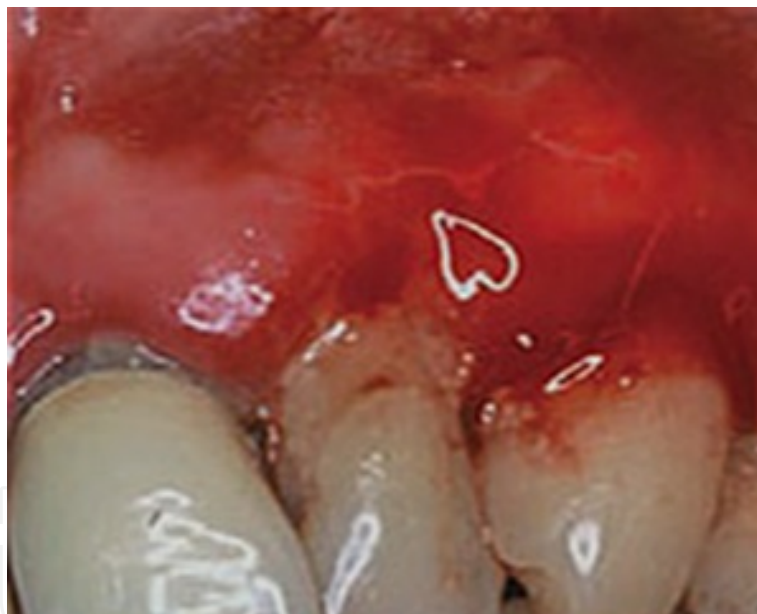


Figure 2. Pemphigus vulgaris with desquamative gingivitis

Pemphigus erythematosus is considered to be combination of PF and systemic lupus erythematosus typified by the presence of erosions in a malar distribution. Drug-associated cases may implicate angiotensin-converting enzyme inhibitors [25], penicillamine [26] or rifampicin [27]. There may be an intercurrent medical history of bullous pemphigoid [28], myasthenia gravis [29] or other autoimmune diseases [30]. PF has been associated with various malignancies such as non-Hodgkin's lymphoma [31], prostate cancer [32], and cutaneous squamous cell cancer [33].

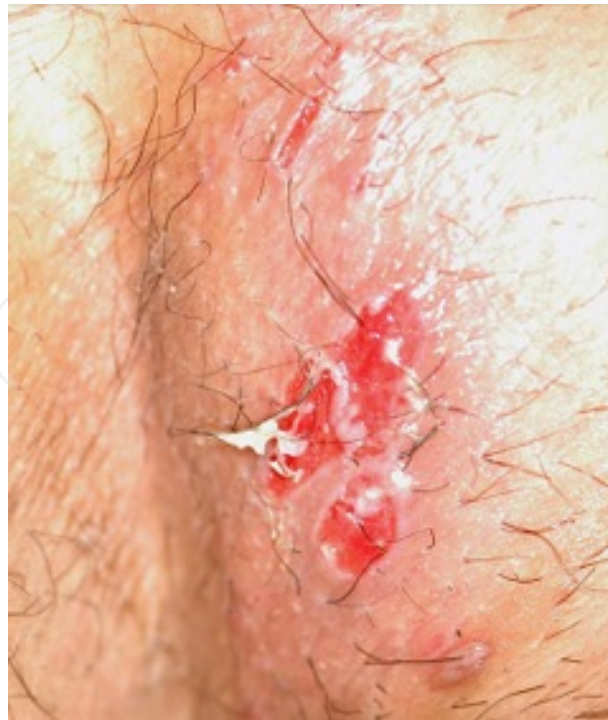

Figure 3. Pemphigus vulgaris characterised by multiple ulcers over the lower back

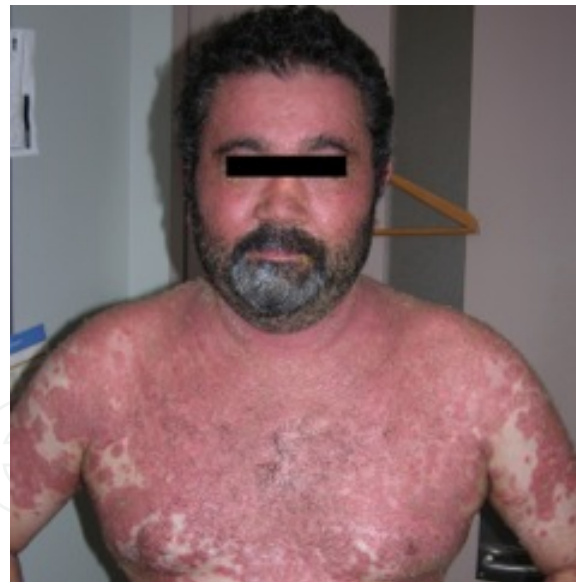

Figure 4. Pemphigus foliaceus characterised by exfoliative erythroderma

In both non-endemic and endemic PF, superficial flaccid vesicles and bullae may be evident and a positive Nikolsky sign is commonly elicited. However, the fragility of these lesions result in the formation of scaled erosions reflecting detachment of the stratum corneum from the stratum granulosum described as a 'corn flakes' appearance (Figure 5). At the severe end of the spectrum, PF can result in an exfoliative erythroderma.

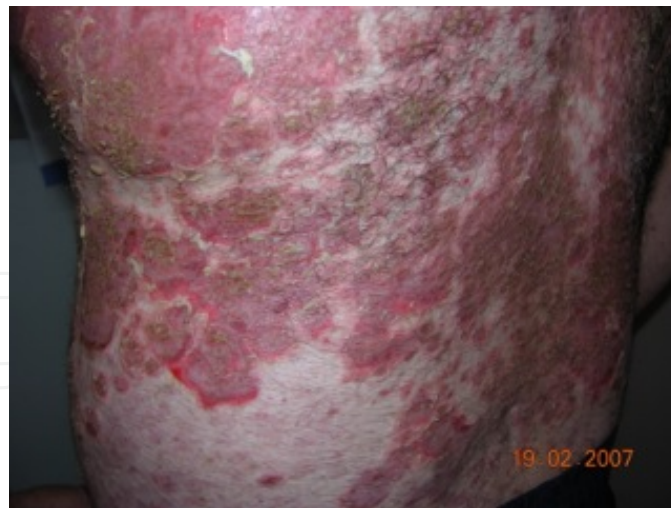

Figure 5. Pemphigus foliaceus with large scaly and crusted erosions over the trunk giving a 'corn flakes' appearance

PF causes significant morbidity as the lesions are painful and patients are prone to secondary infection, dehydration and metabolic disturbances with fatalities reported for those cases involving exfoliative erythroderma.

4.3. Differential diagnosis

Clinically, the differential diagnosis for mucosal lesions of PV (before the development of cutaneous disease) includes herpes simplex virus, lichen planus, mucous membrane (cicatricial) pemphigoid, erythema multiforme, and paraneoplastic pemphigus. The differential diagnosis for cutaneous involvement include other autoimmune blistering skin conditions, such as pemphigus foliaceus, pemphigus vegetans, IgA pemphigus, paraneoplastic pemphigus, bullous pemphigoid, linear IgA disease, erythema multiforme, Grover's disease, and Hailey-Hailey disease.

The differential diagnosis of endemic and nonendemic PF includes bullous impetigo, IgA pemphigus, pemphigus herpetiformis, drug eruptions, subcorneal pustular dermatosis, and systemic lupus erythematosus. If lesions are localized to the face or scalp with abundant scaling and yellow crusting, seborrheic dermatitis needs to be considered. The differential diagnosis of exfoliative erythroderma as the manifestation of PF includes papulosquamous diseases such as psoriasis, pityriasis rubra pilaris, and Drug Reaction with Eosinophilia and Systemic Symptoms.

5. Diagnosis

5.1. Histopathology

In PV, biopsy of lesional skin demonstrates intraepidermal splitting that occurs suprabasally forming an intraepidermal blister [34]. A single layer of basal keratinocytes remains attached

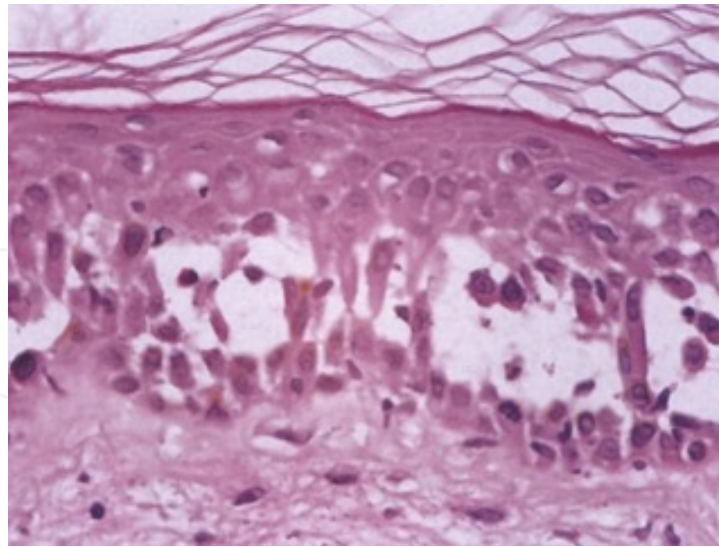


Figure 6. Medium power view of a skin biopsy from a patient with pemphigus vulgaris showing acantholysis of the suprabasal keratinocytes leaving a single layer of basal keratinocytes attached to the basement membrane (tombstone pattern), which forms the floor of an intraepidermal blister. The roof of the blister comprises relatively intact superficial epidermal layers with the stratum corneum. A sparse perivascular lymphocytic and eosinophilic inflammatory infiltrate is found within the upper dermis.

to the basement membrane (tombstone pattern), which forms the floor of the blister. The roof of the blister comprises relatively intact superficial epidermal layers with the stratum corneum showing a basketweave pattern. Hematoxylin and eosin staining demonstrates suprabasilar acantholysis and infiltration with predominantly neutrophils and eosinophils. A sparse perivascular lymphocytic and eosinophilic inflammatory infiltrate is found in the upper dermis [35] (Figure 6). In contrast, intraepidermal splitting is found subcorneally in PF with the initial formation of vacuoles within the intercellular spaces of the granular and/or upper spinous layers of the epidermis. [34] The vacuoles become larger and eventually lead to subcorneal blister formation within the upper epidermis (Figure 7). Hematoxylin and eosin staining show variable amounts of acantholytic keratinocytes, neutrophils, and fibrin within the blisters (Figure 8). Chronic PF lesions may show evidence of papillomatosis, acanthosis, hyperkeratosis, parakeratosis, and follicular plugging. The papillary dermis contains an inflammatory infiltrate composed of small numbers of neutrophils, eosinophils, and lymphocytes.

5.2. Direct immunofluorescence

Biopsy for direct immunofluorescence should be taken from perilesional mucosa and/or skin [36]. Biopsy of lesional tissue is not useful as immunoreactants are rapidly degraded by inflammatory activity [37]. To prevent the destruction of immunoreactants, specimens must be snap frozen and stored at temperatures below -70°C or placed in special transport media (such as Michel's medium) [36]. In direct immunofluorescence, specimens are incubated with fluorescein isothiocyanate-labelled antibodies against immunoglobulins, complement or fibrinogen, and examined with a fluorescent microscope [36]. In PV, direct immunofluores-

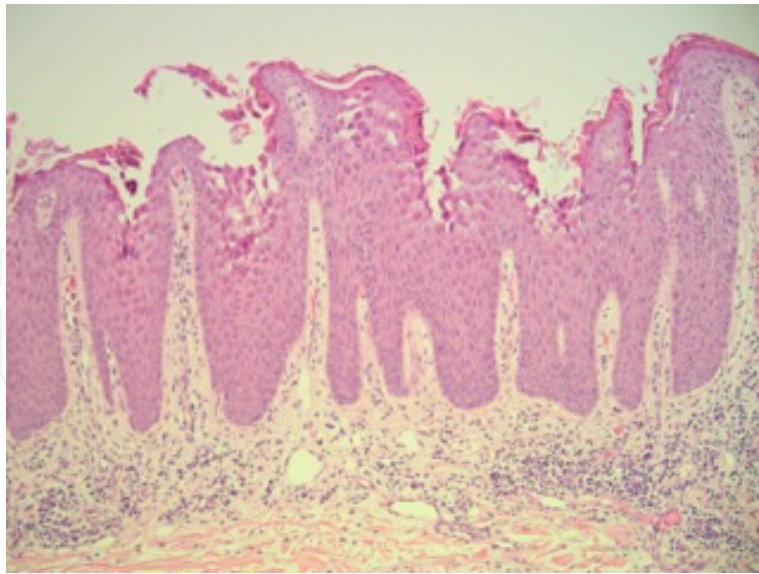


Figure 7. Medium power view of a skin biopsy from a patient with pemphigus foliaceus showing vacuoles within the intercellular spaces of the stratum granulosum and the upper stratum spinosum of the epidermis. The papillary dermis contains an inflammatory infiltrate comprising neutrophils, eosinophils, and lymphocytes (hematoxylin and eosin staining).

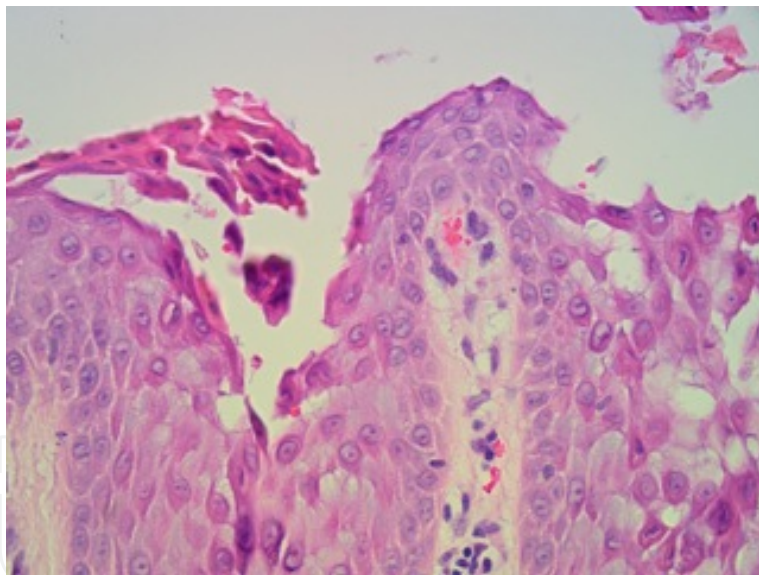


Figure 8. High power view of a skin biopsy from a patient with pemphigus foliaceus showing clefting with acantholysis and spongiosis (hematoxylin and eosin staining).

cence shows intercellular immunoglobulin G (IgG) throughout the epidermis as a result of deposition of both anti-desmoglein-1 and -3 antibodies (Figure 9). Approximately 50% of biopsies may display complement 3 (C3) [36]. In contrast, PF is characterized by both intercellular IgG and C3 predominantly in the upper half of the epidermis due to the increased density of desmoglein-1 and subsequent antibody deposition in the superficial epidermis. The diagnostic sensitivity of direct immunofluorescence in pemphigus disease is 80-95% [38].

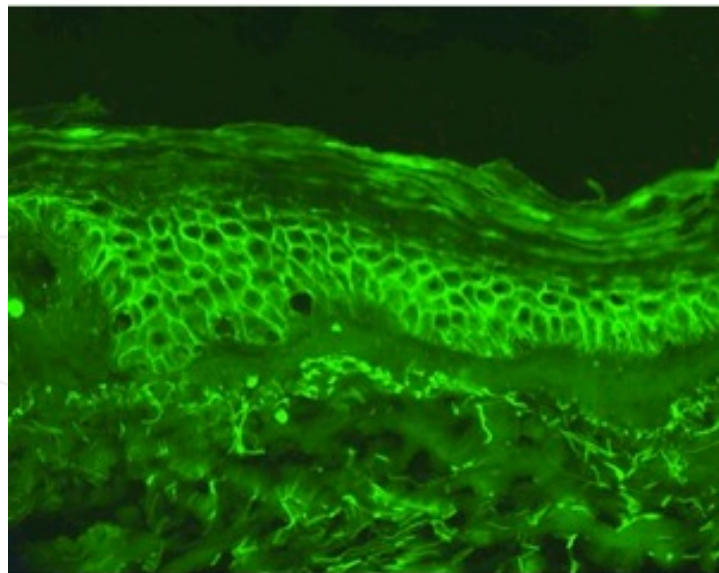


Figure 9. Direct immunofluorescence of a skin biopsy from a patient with pemphigus vulgaris revealing deposition of IgG throughout the epidermis resulting in a chicken wire appearance.

5.3. Indirect immunofluorescence

The target of pemphigus is desmoglein. Desmoglein-1 and -3 are restricted to stratified squamous epithelium, whereas desmoglein-2 is expressed in all desmosome possessing tissues [8]. In indirect immunofluorescence, patient serum is incubated with epithelial substrates containing the target antigen. In pemphigus, the most frequently used substrates are monkey esophagus, which is more sensitive for the detection of PV autoantibodies, and guinea pig esophagus and rabbit lip mucosa, which are more sensitive for the diagnosis of PF [39]. In PV, indirect immunofluorescence produces a characteristic chicken-wire pattern predominantly on the lowermost epithelial layers. The result is invariably positive in active disease. PF autoantibodies produce a chicken wire pattern in the superficial epithelial layers (Figure 10). The positivity rate is approximately 79-90% [38]. False positives can result from patient serum containing antibodies to cell surface antigens[39]; antibodies can be found in patients with staphylococcal scalded skin, penicillin adverse drug reactions, toxic epidermolysis necrosis, and burns. Importantly, patients with blood group O who have antibodies to blood groups A and B may give low false positives on indirect immunofluorescence testing, which is avoided by preabsorbing their sera with these blood group antigens. Indirect immunofluorescence titers can be used as a marker of disease activity in patients[38],[40].

6. Enzyme-Linked Immunosorbent Assay (ELISA)

Indirect immunofluorescence is not reactive with all pemphigus sera and does not differentiate between desmoglein-3 and desmoglein-1[41]. In response, ELISAs have been developed using the recombinant ectodomains of desmoglein-1 and -3 [42]. In commercially available assays,

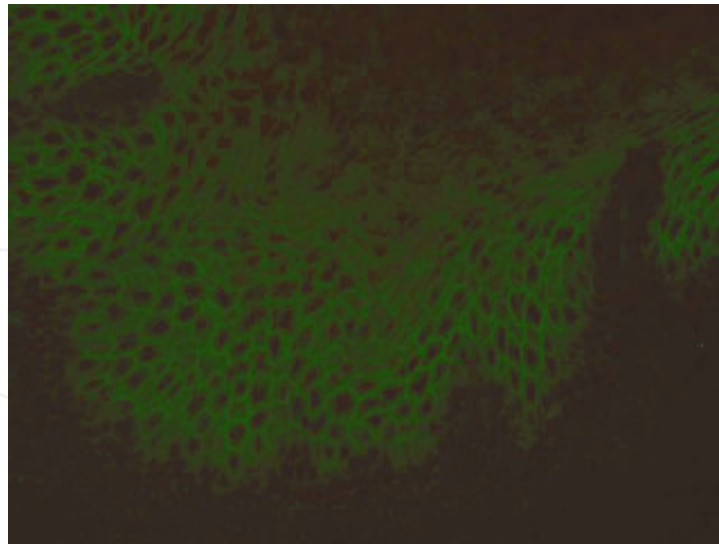


Figure 10. Indirect immunofluorescence with the serum of a patient with pemphigus foliaceus and monkey oesophagus substrate reveals deposition of specific IgG in the intercellular cement space substance of the epidermis resulting in a chicken wire appearance. There is an increased deposition in the upper layers of the epidermis.

these desmoglein ectodomains have been expressed in insect cells (MBL, Nagoya, Japan), or in human HEK293 cells (Euroimmun, Lubeck, Germany) [43]. Meta-analyses suggest that available ELISAs are highly sensitive and specific, and has a higher diagnostic accuracy than indirect immunofluorescence [44]. The quantification of these autoantibodies is useful in monitoring disease activity because the titre of circulating autoantibodies has been observed to correlate with disease activity. Specifically, the level of desmoglein-1 antibodies matches the severity of skin disease, and the level of desmoglein-3 reflects the severity of mucosal disease [45],[46].

7. Treatment

Therapy has resulted in a drastic decline of the mortality from pemphigus rate to below 7% [24],[47]; however, mortality still occurs, predominantly iatrogenic, caused by complications of the immunosuppressive therapy [24],[47]. PF tends to have a relatively benign course compared with PV. However, mortality rates of untreated endemic PF are still very high, ranging from 40 to 60% [48],[49]. With appropriate treatment endemic PF has a mortality rate of less than 10% [48]. The mortality of PV was 75% before the introduction of corticosteroids in the early 1950s [47]. Studies that differentiate PV according to clinical phenotype have shown a lower mortality in patients with predominantly mucosal PV (1–17%) compared with those with mucocutaneous PV (34–42%)[24]. Hence, the goal of managing patients with pemphigus is inducing and maintaining remission using those evidenced-based treatments that have a favourable side effect profile.

Pemphigus is a rare disease and therefore it is not surprising that only a few blinded randomized controlled trials have been performed to guide treatment decisions. A 2009 Cochrane

review [50] assessed interventions for PV and PF and concluded that there is inadequate information available to ascertain optimal therapy for pemphigus. They ascertained that the quality of most studies was not high and the majority examine patients with newly diagnosed or active disease. Another consideration in the evaluation of data is lack of generally accepted definitions and measurements for the clinical evaluation of patients with pemphigus and the definitions of disease control and remission. A recent consensus statement has been released to assist with future trials enabling improved comparisons to be made [51].

As high-dose systemic corticosteroids, followed by alternate immune-suppressive agents, serves as the mainstay of initial therapy for PV, there is the need to exclude underlying latent infectious diseases that can be reactivated by the corticosteroids (e.g.: HIV, Hepatitis B and C, and tuberculosis). In addition, screening for the diseases initiated or exacerbated by high-dose 'steroids, such as hypertension, diabetes mellitus and osteoporosis is prudent.

8. Systemic corticosteroids

Systemic corticosteroids are currently the mainstay of treatment as they have a rapid onset of action and are effective in controlling disease and improving prognosis [52]. However significant side effects such as diabetes, osteoporosis, adrenal suppression, peptic ulceration, weight gain, increased susceptibility to infection, mood changes, proximal myopathy, Cushing's syndrome, and cataracts limit their usefulness. Adjuvant treatments have therefore been introduced as steroid sparing agents. Various corticosteroid regimens are used to treat pemphigus, the most common of which is a gradual reduction of an oral formulation [47]. In newly diagnosed patients, an initial daily dose of 0.5 mg/kg of prednisone/prednisolone, (or equivalent) appears preferable to 1 mg/kg. A randomized trial compared these two regimens in 19 patients with PV and 3 with PF followed for 5 years, with remission defined as less than 15 mg of corticosteroids per day to maintain disease control [53]. No difference was observed in remission or the incidence of complications between the high and low dose regimens. In a randomized trial that included only patients with newly diagnosed PV, pulsed oral dexamethasone provided no additional benefit to the combination of oral prednisone and azathioprine with remission defined as cessation of systemic treatment [54]. Furthermore, there were an increased number of adverse events in those participants receiving pulsed dexamethasone. However, the possible benefit of high dose pulsed intravenous corticosteroids in achieving disease control and maintaining remission was suggested in a small case-controlled retrospective study of patients with PV initially unresponsive to low dose of prednisone (less than 40 mg daily) [55] and an open study of new diagnosed PV patients [56]. There have no studies to date examining the effects of high dose pulsed intravenous corticosteroids in PF.

Currently no optimal regimen for corticosteroid therapy has been defined for the treatment of pemphigus despite its proven benefits. Hence in routine practice, a tailored regime is recommended. A starting dose of prednisolone 0.5 mg/kg daily is prudent that may need to be increased, until no new blister formation is observed. Such higher doses of corticosteroids including pulsed therapy may be warranted in newly diagnosed severe disease and recalcitrant disease but this remains to be substantiated in randomized studies.

9. Adjuvant treatment of pemphigus

Immunosuppressive therapy for pemphigus includes azathioprine, mycophenolate mofetil, methotrexate, cyclophosphamide, cyclosporin and dapsone. Adjuvant agents with immunomodulatory activity that have also been used in pemphigus include calcineurin inhibitors, epidermal derived growth factor and tetracycline antibiotics. The main role of these immunosuppressive medications is to function as a steroid-sparing agent. As they generally have a slow mode of onset, approximately 4-6 weeks, they are used in maintenance therapy rather than in the initiation of disease control. However, their role needs to be further elucidated as there has been only limited number of randomized controlled trials with most of the literature derived from case series reports.

9.1. Azathioprine

Azathioprine is a purine antimetabolite that is cleaved to 6-mercaptopurine, which in turn is converted to additional metabolites that inhibit *de novo* purine synthesis. Cell proliferation is inhibited and as a consequence a variety of lymphocyte functions are impaired. Azathioprine is commonly used to treat pemphigus; a survey of dermatologists in 2003 showed it was the most commonly prescribed adjuvant agent used to treat PV [57]. It has even been used as monotherapy in mild cases [58]. In a recent randomized trial conducted by Chams-Davatchi et al, 120 new patients with PV were treated for over one year with one of four regimens. These regimes were prednisolone alone, prednisolone plus azathioprine, prednisolone plus intravenous cyclophosphamide and prednisolone plus mycophenolate mofetil [59]. Azathioprine reduced the cumulative dose of prednisolone compared with prednisolone alone however remission rates were similar. Side effects were similar between the two groups. Thus in this trial, which included only patients with PV, azathioprine reduced the cumulative corticosteroid dose but not the rate of remission. More recently, a non-randomized study compared high dose oral prednisone daily (1.5 mg/kg/daily) versus low dose oral prednisone (40 mg on alternate days) plus azathioprine (100 mg/daily) in 36 patients with oral PV [60]. Both treatments resulted in high rates of clinical remission; the monotherapy group showed a reduced mean time to remission but this group was associated with an increased rate of treatment-associated adverse events. Other non-randomized trials using azathioprine have generally shown favourable outcomes in PV [61],[62].

9.2. Mycophenolate mofetil

Mycophenolate mofetil is a prodrug and its active drug, mycophenolic acid, inhibits inosine monophosphate dehydrogenase, an important enzyme in guanine nucleotide synthesis. Lymphocytes are highly dependent on this pathway and are selectively inhibited by mycophenolate mofetil [63]. In the randomized trial by Chams-Davatchi et al, no difference in remission was observed for mycophenolate mofetil when compared to prednisolone alone [59]. In this same study no difference in remission was demonstrated between azathioprine and mycophenolate mofetil. The steroid sparing effect of mycophenolate mofetil was inferior to azathioprine. Beissert et al. compared oral methylprednisolone plus azathioprine with

mycophenolate mofetil in 33 patients with PV and 7 patients with PF [64]. The primary outcome was complete healing of all lesions. This study concluded that mycophenolate mofetil and azathioprine demonstrated similar efficacy. Safety profiles were similar as was corticosteroid-sparing effects. There were less severe side effects observed in the mycophenolate group but this was not statistically significant. Many non-randomized trials have supported the use of mycophenolate mofetil in the treatment of pemphigus [65]-[69]. The majority of patients in these trials had PV. Mycophenolate mofetil is generally well tolerated; lymphopenia, gastrointestinal symptoms and infections are the most common side effects. Currently it is a relatively expensive medication, often precluding its off-label use. The drug is usually commenced at dose of 1 g per day in adult patients, and if required, increased in 500-mg increments up to doses of 2-3 g per day [70].

9.3. Cyclophosphamide

Cyclophosphamide is an alkylating agent that disturbs DNA synthesis and cell division. Cyclophosphamide interferes with DNA integrity and function inducing cell death in rapidly proliferating tissues including lymphocytes. This provides the basis for their therapeutic and toxic properties. Several randomized trials have assessed cyclophosphamide in treatment of pemphigus. Chrysomallis et al. used oral cyclophosphamide in patients with PV whose disease was limited to oral involvement [71]. Twenty-eight patients were divided into 3 groups and given corticosteroids alone, corticosteroids with cyclophosphamide or cyclosporine. No difference in remission was seen when cyclophosphamide was compared with corticosteroids alone, and at 5 years, all patients had their disease controlled with a low dose corticosteroid regimen. The more recent study by Chams-Davatchi et al. described above and comprising entirely of patients with PV concluded that there was no difference in remission rates following pulsed intravenous cyclophosphamide therapy [59]. A randomized control trial that included 6 patients with PF as well as 16 with PV compared pulsed cyclophosphamide with dexamethasone and daily cyclophosphamide with methylprednisolone plus azathioprine [72]. No difference in disease control was observed for the cyclophosphamide group compared to the azathioprine group after 2 years. Several non-randomized case series have utilized pulse cyclophosphamide with variable outcomes [73]-[75].

Given the lack of superiority of cyclophosphamide over other regimes in randomized trials and its well-described serious side effect profile, the authors recommend that its use be restricted for the treatment of severe or refractory cases of PF, where alternative agents such as rituximab or IVIg are not available.

9.4. Cyclosporin

Cyclosporin is a calcineurin inhibitor that prevents dephosphorylation of nuclear factor of activated T cells (NFAT) preventing its translocation into nucleus and as a consequence the T cells fail to respond to specific antigenic stimulation. Cyclosporin also increases expression of TGF- β , a potent inhibitor of IL-2-stimulated T-cell proliferation. A randomized trial compared oral methylprednisolone alone with oral methylprednisolone plus cyclosporin in 33 newly diagnosed patients, 29 with PV and 4 with PF [76]. The patients were followed for

4-6 years and the investigators concluded that the combination regimen of corticosteroids and cyclosporin provided no additional benefit over corticosteroids alone. Side effects, including hypertrichosis, hypertension and renal dysfunction, were more common in the cyclosporin group. The randomized controlled study by Chrysomallis et al. in newly diagnosed PV limited to oral involvement found no difference in remission or relapse rates between the cyclophosphamide and cyclosporine (5 mg/kg) groups [71]. Again, adverse events were more common in the cyclosporin group and included hypertrichosis and renal impairment. A case series reported successful the successful treatment of 6 patients with recalcitrant PV [77].

The randomized trials have not supported the use of cyclosporine at a dose of 5 mg/kg for the treatment of new onset pemphigus and side effects are relatively common. Further randomized controlled trials are required to determine its benefit in recalcitrant disease.

9.5. Dapsone

Dapsone has anti-inflammatory and antimicrobial actions. Its immunomodulatory action is incompletely understood but several actions have been described including prevention of the respiratory burst from myeloperoxidase, suppression of neutrophil migration by blocking integrin-mediated adherence, inhibition of adherence of antibodies to neutrophils, and reduction of eicosanoid release. Most studies utilising dapsone have been performed in patients with PV. A randomized controlled trial performed in 19 patients, all with PV, compared dapsone with placebo [78]. Patients were in the maintenance phase after glucocorticoids and/or cytotoxic agents (azathioprine, mycophenolate or methotrexate) were used to achieve remission. Doses of dapsone were increased to 150 mg per day and then to a further 200 mg per day if tolerated. The trial was performed over 1 year, and the main outcome measured was reduction of prednisolone to doses of 7.5mg/day or less. Five of the 9 patients in the placebo group achieved the main outcome compared with 3 out of 10 in the placebo group. The difference was not statistically significant although there was a trend favouring dapsone as a steroid sparing agent. A retrospective study in 9 patients with PV suggested that dapsone reduced steroid dependence in these patients [79]. Another study reported improvement in 5 of 9 cases of superficial pemphigus treated with dapsone [80]. A recent meta-analysis comprising 55 patients with pemphigus revealed that 32 patients with PV and 14 patients with PF responded to dapsone [81].

The side effects of dapsone observed in these studies include methaemoglobinaemia, haemolysis and agranulocytosis. [81],[82] Patients should be tested for glucose-6-phosphate dehydrogenase deficiency prior to commencing this agent. Dapsone at best may have a role as a steroid sparing agent in the maintaining remission in pemphigus but cannot be recommended in treatment of acute disease.

9.6. Methotrexate

The antimetabolite methotrexate is a folic acid analogue that competitively inhibits dihydrofolate reductase and has multiple immunosuppressive actions including suppressing lymphocytes in the skin [83],[84]. A small number of non-randomized trials have investigated the

role of methotrexate in treatment of pemphigus. The most recent study [83] treated 9 patients with chronic active PV, who were unable to successfully wean their prednisolone dose. They were treated with a mean dose of 12.5 mg per week of methotrexate. Prednisolone was discontinued in 6 of the 9 patients within 6 months of commencing methotrexate. There were minimal adverse effects reported in the study. A recent review of the English literature revealed that 111 (82%) of 136 pemphigus patients responded to methotrexate [85]. However, meaningful conclusions are limited by the lack of randomized trials, varying doses and schedules of treatment, and insufficient information on clinical progress including the lack of consistency of the length of follow up.

Thus methotrexate may be useful as a steroid sparing agent but further trials are required before recommending methotrexate as an initial steroid-sparing agent.

Medication	Dose	Contra-indications	Pre-Therapeutic Investigations	Monitoring	Adverse Reactions
Corticosteroids ("steroids")	prednisolone: (1) ½-1 mg per kg/ bodyweight of the patient for 4 days (or longer in pemphigus) with rapid taper until clinical remission occurs (2) < 7.5 mg/daily	<ul style="list-style-type: none"> Active infectious diseases: Tb, HIV, HBV, HCV 	<ul style="list-style-type: none"> Tb, HIV, HBV, HCV 	Systemic: <ul style="list-style-type: none"> hypertension, psychosis, diabetes mellitus, weight gain, cataracts Oral Mucosa: <ul style="list-style-type: none"> candidiasis, mucosal atrophy 	hypertension, psychosis, diabetes mellitus, weight gain, cataracts Oral Mucosa: candidiasis, mucosal atrophy
Calcineurin-Inhibitors: pimecrolimus (Elidel®)	<u>Topical Application Only:</u> thin layer to affected mucosa twice daily	A <i>causal</i> relationship has <u>not</u> been established with malignancy. Skin cancer and lymphoma have been reported in patients treated with topical calcineurin inhibitors, including pimecrolimus 1% cream.			irritation, pruritis and erythema on application
Lysosomotropic Amines: hydroxyl-chloroquine (Plaquenil®)	200-400 mg (once daily)	<ul style="list-style-type: none"> pre-existing retinopathy psoriasis porphyria G6PD deficiency 	<ul style="list-style-type: none"> baseline visual acuity testing (for macular degeneration) by an Ophthalmologist FBC; G6DP levels; LFT's 	<ul style="list-style-type: none"> annual baseline visual acuity testing FBC and LFT's weekly for first 4 weeks; thereafter, only if indicated 	UV (sun) light-initiated lichenoid cutaneous reactions Note: slow onset of action of up to 3 months
azathioprine (Imuran®)	1.0-2.0 mg per kg bodyweight/daily (once daily)	<ul style="list-style-type: none"> recent use of live vaccines pregnancy (Category D) (including partner of male patient) concomitant allopurinol 	<ul style="list-style-type: none"> thiopurine methyl-transferase (TPMT) assay (determines risk of bone marrow aplasia) FBC; LFT's; E/U/C 	<ul style="list-style-type: none"> FBC weekly for first 8 weeks; thereafter monthly 	severe adverse reaction with xanthine oxidase inhibitors of which the most potent is allopurinol (Progout® Zyloprim®)

mycophenolate (CellCept®, Myfortic®)	max 2 g/day (once daily or divided dose)	• pregnancy (Category D)	• HIV, HBV, HCV	• FBC and LFT's weekly for first 4 weeks; thereafter, only if indicated	malignancy risk eg skin cancer, lymphoma; infection; progressive multifocal leuco-encephalopathy; bone marrow depression
dapsone (Dapsone®)	maintenance dose: 50-100 mg daily (≥ 300 mg daily)		• FBC, G6DP levels, LFT's • HIV, HBV, HCV	• FBC, LFT's weekly for the first month, monthly for six months and semi-annually thereafter	dose related haemolysis, especially in G6DP deficient patients; agranulocytosis; toxic hepatitis and cholestatic jaundice
methotrexate (Methoblastin®)	10 to 25 mg/ WEEKLY ONLY until adequate response is achieved	• pregnancy (Category D) • liver/renal impairment • HIV, HBV, HCV • immune-deficiency; • concomitant retinoids	FBC, LFT's, E/U/C HIV, HBV, HCV	• FBC weekly for first 8 weeks, thereafter monthly	hepato/ nephrotoxicity; ulcerative stomatitis; bone marrow depression; immune-suppression
Rituximab (Mabthera®)	375 mg/m ² (body surface area) once weekly for 4 weeks or 2x 1.0g -500 mg ivi infusions over two weeks	• Murine(mouse) protein hypersensitivity	• Tb, HIV, HBV, HCV	• infection	progressive multifocal leucoencephalopathy (PML)

(A)

Medication	Actions
corticosteroids ("steroids)	<p>Profound, generalised inhibitory effects on inflammatory processes and cells achieved by the control of protein synthesis by reacting with certain corticosteroid responsive genes of sensitive cells in many tissues:</p> <ul style="list-style-type: none"> ↘ production of acute inflammatory mediators, especially eicosonoids, postaglandins and leukotrienes. (corticosteroids increase the production of a polypeptide – <i>lipocortin</i>, that in turn inhibits phospholipase A₂ the enzyme responsible for the mobilising arachnidonic acid from cell membranes) ↘ production and numbers of circulating immune-competent cells: e.g.: neutrophils, macrophages, T and B lymphocytes ↘ Complement activation ↘ activity of macrophages and fibroblasts involved in the chronic stages of inflammation – leading to decreased inflammation and healing
cyclosporine tacrolimus	Calcineurin inhibitors:

pimecrolimus	<ul style="list-style-type: none"> • binds to the cytosolic protein cyclophilin of T-lymphocytes and the complex of cyclosporin (or other calcineurin-inhibitor) and cyclophilin inhibits calcineurin, which normally induces the transcription of interleukin-2. ↓ lymphokine production and interleukin release (further reducing the function of effector T-cells)
hydroxyl-chloroquine (Plaquenil®)	<p>Lipophilic weak base that passes easily through plasma membranes to accumulate in acidic vesicles, such as the lysosomes of the inflammatory cells and acts by:</p> <ul style="list-style-type: none"> ↓ antigen presentation by the antigen-presenting cells (APC's) ↓ cytokine production (e.g.: Tumour Necrosis Factor-alpha (TNF-α), Interleukin-6 (IL-6), Interferon-gamma (IFN-γ)) ↓ stimulation of the toll-like receptors • prostaglandin antagonist
azathioprine (Imuran®)	<p>Azathioprine is an imidazole derivative of 6-mercaptopurine (6-MP) into which is rapidly broken down (in vivo).</p> <ul style="list-style-type: none"> • 6-MP readily crosses cell membranes and is converted intracellularly into a number of purine thioanalogues, including the main active nucleotide: thioinosinic acid. • thioinosinic acid inhibits many pathways in nucleic acid biosynthesis causing damage to deoxyribonucleic acid (DNA), through incorporation of this "false" purine thio-analogue. • this action is restricted to the cells involved in determination and amplification of immune response; the B and T lymphocytes as they are unable to source alternate or extrinsic nucleotides being entirely dependent for their proliferation on de novo synthesis of purines, whereas other cell types can utilise salvage pathways.
mycophenolate (CellCept®, Myfortic®)	<p>Mycophenolic acid (MPA) is a potent, selective, uncompetitive and reversible inhibitor of inosine monophosphate dehydrogenase (IMPDH) which inhibits the de novo pathway of guanosine nucleotide synthesis but without incorporation into the cell's DNA:</p> <ul style="list-style-type: none"> • MPA has more potent cytostatic effects on T and B lymphocytes than on other cells because these cells are entirely dependent for their proliferation on their <i>de novo</i> synthesis of purines, whereas other cell types can utilise salvage pathways • depletion of guanosine nucleotides also leads to the inhibition of glycosylation of the adhesion molecules on lymphocytes further interfering in their immune functions
dapsone (Dapsone®)	<p>Dapsone is effective in dermatoses with abnormal neutrophil accumulation</p> <ul style="list-style-type: none"> • Dapsone interferes in chemotactic-mediated migration of neutrophils and neutrophil function by: (1) inactivating the function of the G-protein (Gi type) that initiates the signal transduction cascade common to chemotactic stimuli; (2) the cytokine mediated adherence of neutrophils to the vascular endothelial cells; and (3) inhibits neutrophil MPO-mediated iodination and cytotoxicity and eosinophil peroxidase, thereby, dapsone suppresses neutrophil recruitment and protects cells from neutrophil- and eosinophil-mediated injury by directly inhibiting the generation of toxic, oxygen-derived radicals. • in antibody mediated diseases, dapsone appears to interfere in the adherence of neutrophils to the auto-antigenic antibodies (IgA and IgG) bound to the various target sites in the basement membrane zone, so protecting the epithelial cells from neutrophil-derived cytolytic agents ↓ release of prostaglandins and leukotrienes and so blocks their inflammatory effects
methotrexate (Methoblastin®)	<p>Antimetabolite cytotoxin. Methotrexate (MTX) competitively inhibits the enzyme <i>dihydrofolate reductase</i> and so prevents the regeneration of intermediates (such as tetrahydrofolate) essential for the synthesis of purines and thymidylate so preventing DNA synthesis:</p> <ul style="list-style-type: none"> • actively proliferating tissues such as the bone marrow stem cells, dermal epithelium, and lymphocytes (as well as the oral mucosal cells) are in general more sensitive to the effects of MTX • MTX has more potent cytostatic effects on T and B lymphocytes than on other cells because these cells are entirely dependent for their proliferation on their <i>de novo</i> synthesis of purines, whereas other cell types can utilise salvage pathways

Rituximab (Mabthera®)	Rituximab is a genetically engineered chimeric murine/human monoclonal antibody that binds specifically to the antigen CD20, a transmembrane molecule located on pre-B and mature B-lymphocytes, only. This non-glycosylated phosphoprotein is found on both normal (and malignant B cells), <i>but</i> not on haemopoietic stem cells, pro-B cells, normal plasma cells or other normal tissues: <ul style="list-style-type: none"> • inhibits CD20 which regulates the early steps in the activation process for B-cell cycle initiation and differentiation • the depletion of circulating autoreactive B cells (for up to 12 months) and , presumably specific downregulation of dsq3-specific CD4(+ve) T-lymphocytes and the associated release of proinflammatory cytokines mayre-establish immune homeostasis and tolerance
--------------------------	--

(B)

A: Tb = tuberculosis, HIV = human immune-deficiency virus, HBV = hepatitis B virus, HCV = hepatitis C virus, G6DP = glucose-6-phosphate dehydrogenase, FBC – full blood count, LFT's = liver function tests, UV = ultraviolet light, E/U/C = electrolytes/urea/creatinine

B: ↓ = decreased or reduced

Table 2. (A) Therapeutic Agents Useful in the treatment of Pemphigus, (B) Therapeutic Agents Useful in Treating of Pemphigus

9.7. Gold

Awad [86] performed a blinded placebo-controlled randomized trial on the utility of auranofin in 30 patients with PF. Nearly one third of the patients withdrew from the active treatment arm due to side effects. In the placebo group, a reduction in the mean corticosteroid steroid dose was evident. Other case series comprising patients with PV and/or PF have described similar findings [87]-[89]. The most recent study published showed that 62% of patients with PV achieved remission or halve their dose of prednisone during a period of 10 years of intramuscular gold therapy [90]. However, the mean time to halve the dose of prednisone was 3 months and 42% developed side effects blood dyscrasia, proteinuria and nephrotic syndrome, cutaneous reactions and dizziness. These adverse effects in addition to the relatively long time to take effect as a steroid-sparing agent preclude its use in favour of other steroid-sparing agents in the treatment of treatment of pemphigus.

9.8. Tetracycline antibiotics and nicotinamide

Tetracycline antibiotics with and without nicotinamide have been combined with other adjuvant agents as treatment for pemphigus. Several small non-randomized trials have shown varying results [91]-[93]. Minocycline given at a dose of 100 mg per day allowed the reduction of prednisolone in 6 out of 10 patients with pemphigus [91]. Tetracycline at a dose of 2 g per day for 1 month reducing to 1 g per day for 4 weeks enabled more rapid tapering of corticosteroids in 13 patients with PV [93]. However the study by Alsپoy found that a combination of tetracycline (2 g/d) and nicotinamide (1.5 g/d) for 2 months was not an effective alternative to the classic forms of therapy in 14 patients with pemphigus [92]. Further trials are needed before recommending these agents.

9.9. Topical agents

9.9.1. Epidermal growth factor

A double-blind randomized controlled study investigated the use of epidermal growth factor (EGF) on skin lesions of 20 patients with PV [94]. Topical epidermal growth factor 10 ug/g in 0.1% silver sulfadiazine cream was applied to skin lesions daily until lesions had healed and compared to the effect of applying 0.1% silver sulfadiazine (SSD) cream alone. Topical EGF appeared to hasten lesion healing by a median of 6 days compared to SSD.

9.9.2. Topical corticosteroids (Clobetasol)

A small study comprised of 4 patients with mild PF and 3 with mild PV were treated with the very potent topical corticosteroid, Clobetasol propionate 0.05%, as a sole agent [95]. The cream was applied to mucosal lesions and involved skin twice a day for at least 15 days, then progressively tapered. Control of disease was defined as healing of lesions was obtained, with a 75% decrease in the number of new lesions per week without the addition of systemic treatment. Disease control was achieved in all 7 patients, with cutaneous remission attained in 15 days, although mucosal regression occurring more slowly. In 4 patients, remission was maintained with topical corticosteroid alone for a mean 19-month follow up. In 3 patients, relapse occurred after 2-11 months, requiring systemic treatment. Another study is in progress comparing the effect of Clobetasol with placebo in pemphigus vulgaris.

9.9.3. Topical calcineurin inhibitors

Tacrolimus and Pimecrolimus are non-steroidal immunomodulatory macrobactams that inhibit the enzyme, calcineurin, impairing the production and IL-2 and subsequent T-cell activation and proliferation [96]. A small number of case reports and case series suggest a useful role for Tacrolimus in mild PV and PF but further randomized controlled trials are required to clarify its role in this setting [97]-[99]. A recent double blind study of 11 patients with PV refractory to azathioprine and corticosteroids showed a marked response to pimecrolimus 1% by day 15 when compared to placebo using the epithelialization index [100].

10. Novel therapies and strategies

10.1. Biological agents

10.1.1. Rituximab

Rituximab is a chimeric (human/murine) monoclonal antibody directed against CD20, a cell surface molecule specific to B cells. Although it was initially approved for use in B-cell non-Hodgkin's lymphoma, a growing number of reports have described the efficacy of rituximab for B-cell depletion in the treatment of autoimmune diseases [101]. The mode of action of rituximab in autoimmune diseases includes the removal of precursors of autoantibody-

producing plasma cells, and impairment of autoantigen presentation to CD4 cells [102]. In PV, Eming et al, show that rituximab not also causes marked reduction of anti-desmoglein 3 antibodies but also depletion of desmoglein-specific CD4 cells. In contrast, tetanus toxoid-specific CD4 cells were not affected nor were the overall number of CD4 cells [103]. Tetanus toxoid has been used in as an antigen in the assessment of memory CD4 cell responses [104]. Eming et al, speculate that this specific effect of rituximab on autoreactive rather than pathogen-specific T cells is that the latter do not require CD20 B cells as antigen-presenting cells. A number of case reports and series have demonstrated the benefit on the use of rituximab in over 40 patients with either PV or PF [40][105]-[115]. The largest case series to date comprising 42 patients, 37 with PV and 5 with PF, utilized the rheumatoid arthritis protocol where two 1g infusions of rituximab are administered 15 days apart [116]. Patients were followed for up to 5 years and 36 of the 42 patients achieved a complete response and were able to cease corticosteroids within 6 months from induction therapy. Twenty patients experienced relapses with the time to relapse ranging from 8 to 64 months. Relapses were treated with rituximab (500 mg) without corticosteroids resulting in a new complete response. Importantly, no serious adverse events were observed.

The largest case series to date using the lymphoma protocol where rituximab is administered weekly (375 mg/m²) for 4 weeks induced remission in 12 of 14 patients with PV and 6 of 7 patients with PF within 3 months [117]. These patients had previously not responded to first-line immunosuppressive agents or had contraindications to corticosteroid therapy. The treatment was generally well tolerated; however, two cases were complicated by severe infection, one resulting in death. Similarly, Canchini et al, showed that the administration of rituximab, 375 mg/m² once weekly for 4 weeks, induced remission in all 10 patients with PV and both patients with PF [118]. Another study comprising 11 patients with refractory PV, evaluated the effect of combination therapy consisting of 10 infusions of rituximab (375 mg/m²) and 6 infusions of intravenous immunoglobulin (IVIg) (2 g/kg body weight) administered over a 6-month period [119]. Remission was induced in 9 patients for a period of 22 to 37 months following treatment and there were no reports of serious adverse events.

More recently, Kasperkiewicz et al reported use of rituximab in combination with immunoadsorption, pulsed dexamethasone and azathioprine or mycophenolate mofetil in 23 patients. [120] IA was performed at initially 3- and later 4-week intervals until lesions healed by 90%; 1 g rituximab was given at weeks 1 and 3, and intravenous dexamethasone pulses were administered at first every 3 weeks and then at increasing intervals in addition to daily azathioprine or mycophenolate mofetil. All patients demonstrated clinical improvement within the first few weeks of therapy accompanied by a concomitant rapid fall in anti-desmoglein antibody levels. However, two patients had non-fatal severe adverse events; one developed *Staphylococcus aureus* sepsis from a central intravenous line followed by spinal haemorrhage and transient paraplegia, and another developed extensive herpes simplex infection.

The high frequency of treatment failure with corticosteroids and first line immunosuppressive therapies has raised the issue of whether rituximab should be implemented earlier in the treatment of PV. Horvath et al conducted a study comprising 15 patients (12 with PV, 3 with

PF) who were treated with two infusions of rituximab (500 mg each) at an interval of 2 weeks [121]. All 15 patients responded to therapy. Eight patients achieved complete remission in a median period of 5 weeks. Seven patients achieved partial remission in a median period of 34.5 weeks. Relapses (40%) were seen between 53 and 103 weeks after start of therapy.

In the majority of these studies, abrogation of peripheral B cells and concomitant reduction in the level of circulating antipemphigus autoantibodies for 6 to 12 months occurs with only two to four infusions of rituximab. Interestingly, clinical remission in both PV and PF is often sustained beyond B cell recovery. The reason as provided Mouquet et al, is that the phenotype of restored B cells following rituximab treatment is that of a naïve B cell with a diverse repertoire rather than a primed autoreactive B cell [122].

Accumulation of the data from case reports and series reveals that 16% of patients with PV developed the serious complications of bacterial sepsis, fatal *Pneumocystis jirovecii* pneumonia, persistent hypogammaglobulinemia or pulmonary embolism [123]. Concerns have also been raised regarding the role of rituximab and other biological agents used in patients with other immune-mediated diseases such as rheumatoid arthritis developing Progressive Multifocal Leukoencephalopathy (PML) [124]. PML is an inevitably fatal demyelinating disease of the central nervous system, that occurs almost exclusively in immunosuppressed individuals due to reactivation of the polyomavirus JC (JCV) [125]. This is in contrast to rarity of adverse events observed in patients treated for non-Hodgkin's lymphoma [126]. Although, the question has been raised of the use of rituximab as a first line agent due to the impressive rates of remission [127], the incidence of serious side effects may at present preclude its role in initial therapy. Ongoing surveillance of patients treated with rituximab for pemphigus and other autoimmune diseases is required to monitor for long-term complications.

There is enough evidence to suggest that rituximab should be the therapy of choice for patients with pemphigus who have refractory disease or contraindications to first-line immunosuppressive therapy although randomized controlled trials have not been performed and as such, there is no uniform protocol on its administration. The value of adjunctive therapies such as IVIg and IA in patients treated with rituximab for pemphigus needs to be also further elucidated. However, one of the most important questions to address is whether it is cost effective and safe to administer rituximab for PV and severe PF as a first line agent.

10.1.2. TNF-antagonists

Studies have demonstrated that TNF released by keratinocytes plays a role in acantholysis in PV. Human keratinocytes pretreated with anti-TNF antibodies, are resistant to the acantholytic effect of anti-desmoglein 3 antibodies [128],[129]. Furthermore, TNF-deficient mice are more susceptible to blister formation after injection with anti-desmoglein 3 antibodies [128]. The role of TNF in PF has not been as extensively studied. Etanercept [130]-[133], infliximab [134],[135], and adalimumab [136], have all demonstrated benefit in a small number of patients with refractory PV. Randomized controlled trials of infliximab and etanercept in refractory PV are currently in progress. However, the effect of these agents in refractory PF has not been reported to date.

10.2. Intravenous immunoglobulin

IVIg is a fractionated and purified blood product derived from the pooled plasma of up to 15,000 healthy donors. Hence it has a high concentration of IgG with a broad range of specificities against various antigens [137]. The mode of action of IVIg in autoimmune disease has not been clearly defined but is probably multifactorial and includes provision of anti-idiotypic antibodies, modulation of expression and function of Fc receptors thereby neutralizing the effect of pathogenic antibodies, blocking of complement activation, reduced secretion of pro-inflammatory cytokines through modulation of dendritic, T and B-cell activation [138],[139]. IVIg upregulates endogenous caspase inhibitors protecting keratinocytes from proapoptotic molecules and thereby inhibits acantholysis [140]. In PV, IVIg causes a selective and rapid decline in serum levels of pathogenic antibodies, specifically IgG1 and IgG4 anti-desmoglein-1 and anti-desmoglein-3 antibodies without affecting total serum IgG levels [141],[142]. A reduction in anti-desmoglein-1 antibodies also occurs in PF [143]. FcRn receptors, which normally function to protect serum IgG from degradation, are saturated following IVIg resulting in catabolism of all IgG molecules including autoreactive antibodies [144]. However, pathogenic autoantibodies are selectively reduced because catabolized normal antibodies are replaced by those present in the IVIg preparation [141].

Three case series and 1 retrospective analysis comprising 54 patients with refractory PV documented the induction of clinical remission following IVIg in all but 2 patients [145]-[148]. Two case series involving a total of 15 patients with refractory PF all responded to IVIg [149], [150]. One of these studies featuring 7 patients revealed a prolonged mean remission time of 18.6 months following discontinuation of IVIg [150]. Two retrospective analyses that included 17 patients with refractory PV and 2 patients with refractory PF, however, demonstrated a much less favourable response with the majority of patients harbouring active disease following IVIg [151],[152]. Recently, a double blind randomized study investigated the effect of a 5 day course of IVIg at varying doses (400, 200 or 0 mg/kg/day) in 40 patients with PV and 21 patients with PF resistant to doses of steroids greater than 20 mg daily [153]. The study did not specify whether these patients had previously been treated with or were currently receiving corticosteroid-sparing immunosuppressive agents. The patients were maintained on their study entry dose of corticosteroids for the duration of the trial. The primary end point was the time to escape from the protocol, which was defined as the length of period that the patient remained on the protocol, without any additional treatment. Patients that showed no improvement after 2 weeks or developed fresh lesions necessitating an increase in corticosteroids or additional immunosuppression were considered as having escaped from the protocol. The study demonstrated a significantly longer time to escape the protocol, and a lower disease activity index accompanied by a fall in anti-desmoglein antibody levels in the 400 mg/kg/day group at days 43 and 85 for both PV and PF patients. There were no significant differences in the side effects observed between the groups. Adverse events that were reported in a minority of patients included fever, headache, palpitations, hypertension, gastrointestinal bleeding, increased creatinine, abnormal liver function tests, and anemia. One patient in the 200 mg/kg/day died as a result of liver failure from exacerbation of pre-existing chronic hepatitis C. Hence, this study does provide useful evidence for the efficacy of IVIg in both PV and PF. Cessation

of IVIg may result in new synthesis of autoantibodies exceeding that initially present [154] and this rebound in antibody levels may be minimized by concurrent cytotoxic therapy.

Comparative trials in refractory disease with other modalities such as biological agents and extracorporeal treatments still need to be performed. The considerable expense of IVIg warrants clarification of the optimal dose, frequency and duration of therapy. Further studies are required to determine whether IVIg can be ceased once remission is achieved, and the patient maintained on conventional first line immunosuppressive agents to minimize rebound synthesis of pathogenic antibodies.

10.3. Extracorporeal treatments

10.3.1. Plasmapheresis

Plasmapheresis results in the potential removal of pathogenic antibodies from the patient's plasma. Forty patients with pemphigus were recruited in a multicentre study and randomized to receive prednisone alone or prednisone and plasma exchange, which consisted of 10 treatments over 4 weeks [155]. No adjuvant immunosuppressive therapy was used for any of the patients. No difference was observed between the 2 groups. Four patients in each group did not achieve disease control. Four patients in the plasmapheresis group died from either sepsis or thromboembolism. The lack of response is surprising as Nagasaka et al, demonstrated in 15 patients with PV and 1 patient with PF that one centrifugal plasmapheresis treatment eliminates 15% of the IgG autoantibodies as measured in the effluents and this is reflected in serum measurements performed one day later [156]. Numerous case series have demonstrated benefit in severe or recalcitrant pemphigus when plasmapheresis is combined not only with corticosteroids but other immunosuppressive agents as well [157]-[161]. Many of these patients experienced side effects including thrombocytopenia, hypocalcemia, urticaria, fever, hypotension, acute hepatitis, nausea, dizziness and leg cramps. The beneficial response observed in these case series studies in contrast to the randomized controlled study of Guillaume et al, may therefore be explained by the concurrent use of immunosuppressive agents in order to prevent the rebound production of autoantibodies. Hence further randomized control studies are needed to clarify the value of plasmapheresis combined with immunosuppressive therapy.

10.3.2. Immunoabsorption

Immunoabsorption (IA) is an extracorporeal treatment for the selective removal of antibodies and circulating immune complexes from plasma. This differs from plasmapheresis, which nonspecifically removes plasma proteins including clotting factors, hormones and albumin, thus requiring substitution of fresh frozen plasma or albumin. The Food and Drug Administration approved IA for the treatment of rheumatoid arthritis, idiopathic thrombocytopenic purpura and hemophilia with inhibitors. It has also been used off label for the treatment of various autoimmune mediated conditions including dilated cardiomyopathy, systemic lupus erythematosus, myasthenia gravis and autoimmune bullous disorders [162].

Initially, 4 case series and 2 case reports totalling 31 patients with PV and 5 patients with PF reported efficacy for IA in combination with immunosuppressive therapies in the treatment of recalcitrant disease [163]-[167]. The treatment schedule generally consisted of 3 initial cycles on consecutive days, a fourth cycle on day 8, followed by 19 cycles in incrementally prolonged intervals of 1 to 4 weeks. However, relapses are common once IA is discontinued and concurrent immunosuppressive therapy tapered [167]. More recently, a small case series comprising 7 patients with refractory PV demonstrated that 23 cycles of IA administered 40 weeks, as described above, in combination with rituximab (375 mg/m² weekly for 4 weeks) and concomitant conventional therapy resulted in complete remission in 3 patients for a period of between 13 and 30 months with minimal or no maintenance immunosuppression [168]. One patient attained partial remission but required significantly less dose of corticosteroids than prior to IA and rituximab. The remaining 3 patients relapsed following the completion of treatment. Two of these patients achieved remission when IVIg (2 g/kg body weight every 4 weeks) was administered and the other only partially responded to IVIg. A retrospective study on refractory PV compared the efficacy of IA in 6 patients with rituximab in 5 patients and showed remission in all patients at 6 months [169]. This remission was sustained in all patients who had received rituximab compared to half of those that received IA. Randomized trials are required to compare the efficacy of rituximab or IVIg with IA and determine any additional benefit from a combination of these modalities.

The treatment is generally well tolerated. Rare adverse events that have been reported include catheter related sepsis, *Pneumocystis jirovecii* pneumonia, mild hypotension, bradycardia and in relation to anticoagulant use, hypocalcemia and paraesthesia. The trials by Schmidt et al, and Shiminovich et al, showed that the combination of IA and immunosuppression resulted in anemia in 30% of patients [164],[167].

10.3.3. Extracorporeal Photochemotherapy (ECP)

In ECP, a patient's leukocytes are collected, exposed to 8-methoxypsoralen, irradiated with ultraviolet-A light and reinfused into the patient. The principle of ECP is to induce apoptosis of leukocytes with ultraviolet-A radiation after their presentation by psoralens [170]. Early apoptotic cells produce anti-inflammatory cytokines such as IL-10 and TGF-beta, which stimulates their engulfment by macrophages and immature dendritic cells. The further production of IL-10 and TGF-beta by these antigen presenting cells with subsequent down regulation of proinflammatory cytokines such as TNF, IL-1 and IL-12 results in immunosuppression and absence of co-stimulation of effector T cells [171]. A deficiency of apoptotic cell clearance may contribute to the pathogenesis of autoimmune diseases including pemphigus and therefore ECP may enhance clearance of autoreactive cells and the reduce formation of pathogenic autoantibodies by B cells [172],[173]. Collectively, 9 patients, 8 with PV and 1 with PF, originating from a small number of case studies and series, received ECP for refractory disease in conjunction with their baseline immunosuppressive agents. [174]-[177]. In contrast to the patients with PV, the lone patient with PF achieved only partial remission and long term immunosuppression was unable to be weaned successfully [177]. ECP was well tolerated in these patients with no adverse effects reported.

10.4. Cholinergic agonists

Studies have suggested that acetylcholine and its receptors are involved in the acantholysis of pemphigus. Approximately 85% of patients with pemphigus have antibodies against acetylcholine receptors on keratinocytes [178]. Cholinergic antagonists mediate similar acantholytic effects on keratinocytes as PV IgG [179]. Acantholytic antibodies can recognize the alpha-9 acetylcholine receptor [180] and pemphaxin [181], which can function as an acetylcholine receptor. Finally, cholinergic agonists can prevent acantholysis *in vivo* [182] and reverse the process *in vitro* [179].

Grando demonstrated a response in 3 of 6 patients with PV treated with pyridostigmine bromide and conventional immunosuppression with 2 responders ultimately able to control their disease with pyridostigmine bromide alone [183]. A recent double blind placebo controlled study comprising 3 PV patients showed a superior epithelialisation effect from 4% pilocarpine gel compared with placebo [184]. The use of these agents in PF has not been reported.

10.5. Peptide immunotherapy

Immunization with intravenous desmoglein-3 peptides was developed to suppress production of anti-desmoglein-3 antibodies through inactivation of disease specific CD4 cells. A phase I clinical trial in PV patients found no significant change in anti-desmoglein-3 antibodies following administration of intravenous desmoglein-3 peptides [185]. Additional studies utilizing higher doses and longer treatment are in progress. It remains to be determined whether peptide immunotherapy with desmoglein-1 peptides will have a beneficial effect in PF.

10.5.1. Inhibitors of intracellular signalling and apoptosis

Studies performed by Berkowitz's group have demonstrated the role of p38 mitogen-activated protein kinase (p38MAPK) in the pathogenesis of pemphigus. Human keratinocytes treated with PV IgG show a time and dose dependent increase in levels of p38MAPK and heat shock protein 27 (HSP27) proteins involved in regulating cytoskeletal components such as keratin intermediate filaments [186]. Inhibitors of MAPK signalling blocked phosphorylation of HSP27 following PV IgG stimulation of human keratinocytes and importantly prevented keratin filament retraction, an early change evident in acantholysis [186]. Inhibition of p38MAPK in murine and cell culture models of pemphigus vulgaris also prevented blister formation [187],[188]. The same group also recently demonstrated p38MAPK inhibition and prevention of blister formation in a murine model of PF [189]. An open labelled uncontrolled study is currently in progress to determine the safety and efficacy of the oral allosteric p38MAPK inhibitor, KC706 (Kémia, Inc), in refractory PV.

Activation of protein kinase C (PKC) followed by plakoglobin dislocation and subsequent dissociation of desmogleins from desmosomes also appear important in the pathogenesis of pemphigus [190]-[194]. Inhibitors of PKC and plakoglobin/c-myc proto-oncogene axis have been shown to inhibit PV IgG induced blister formation in the neonatal passive

transfer murine model of pemphigus vulgaris [195]. It has been demonstrated that p53 knockout mice are protected from PV IgG induced disease [196]. Neonatal mice pretreated with p53 inhibitor pifithrin-alpha were resistant to both PV and PF IgG mediated blister formation [197].

As shown by the studies of Waschke et al, PV autoantibodies directly block desmoglein-3 transinteraction in contrast to anti-desmoglein antibodies found in PF, which disrupt desmoglein-1 transinteraction via cellular signalling events rather than by direct inhibition [198]-[200]. Hence targeting these signalling proteins in PF may provide a more specific target of therapy as compared to immunosuppressive or biological agents. It remains to be determined whether targeting these signalling proteins results in mediating disease remission in humans. Although they target specific areas of pemphigus pathogenesis, these proteins mediate numerous cellular functions and hence the outcome of early safety studies is eagerly awaited.

11. Elimination of triggering antigens

The elimination or avoidance of an antigen in a genetically susceptible individual may prevent the onset of disease or reduce disease activity. Cessation of offending medications such as penicillamine or captopril results in remission of drug-induced PF [25], [201], [202]. Similarly, patients with endemic pemphigus, who relocate from their native rural endemic environment to a more industrialized area experience clinical and immunologic disease regression [203]. Hence, the clear identification of a triggering environmental antigen such as arthropod protein, microorganism or otherwise, will not only enhance our understanding of disease pathogenesis but also significantly enhance therapies in endemic pemphigus and possibly non-endemic PF [5].

12. Conclusion

PV and PF are debilitating and potentially life-threatening conditions that are therefore important to promptly recognize clinically and then confirm through their characteristic features on histology and direct immunofluorescence. The detection of serum autoantibodies by indirect immunofluorescence or ELISA does not obviate the need for a tissue diagnosis but might be useful in assessing disease severity and activity.

Although, corticosteroids remain the cornerstone of therapy for pemphigus, the morbidity associated with its use restricts its value as a long term treatment option. This is complicated by the fact that steroid-sparing agents are also associated with serious adverse events and there are only few randomized controlled trials demonstrating a beneficial response from the use of these agents. This has been further compounded, until very recently, by the inconsistent parameters of disease activity used in different studies. Azathioprine and mycophenolate mofetil appear to be the most feasible first line adjunctive agents in terms of inducing and

maintaining remission and having a comparatively favourable side effect profile. An enhanced understanding of the pathogenesis of pemphigus has resulted in the implementation of a number of novel agents. These therapies have also been mainly studied through case series reports, are expensive and difficult to access in some centres, and are associated with a number of deleterious side effects. Rituximab, has emerged as the therapy of choice in severe refractory disease and is now being explored as a first line agent. We eagerly await further studies on the effects and safety profiles of more specific agents, especially those targeting signalling molecules involved in the pathogenesis of pemphigus.

We have formulated guidelines on the treatment of pemphigus as suggested by the current level of evidence [204]. Corticosteroids remain the mainstay of treatment and should be initiated at a dose of 0.5 mg /kg of oral prednisone per day and continued at this dose until disease control is obtained. This is defined as the time at which new lesions cease to form and existing lesions begin to heal and in responsive patients, this usually occurs within weeks. At the end of the consolidation phase defined as the point in time where no new lesions have occurred after 2 weeks and 80% of established lesions have healed, the corticosteroid dose is tapered. Unless disease is mild we would recommend adding an adjuvant agent. Either mycophenolate mofetil or azathioprine could be utilized at this stage. For severe or recalcitrant disease rituximab is recommended given the current level of evidence. Other biologic agents, extracorporeal therapies or cytotoxic agents can be considered if rituximab is unavailable or contraindicated.

Author details

Suran L. Fernando^{1,2}, Jamma Li¹ and Mark Schifter^{3,4}

1 Department of Clinical Immunology and Allergy, Royal North Shore Hospital, Sydney, Australia

2 Sydney Medical School – Northern, Sydney University, Sydney, Australia

3 Department of Oral Medicine, Oral Pathology and Special Care Dentistry, Westmead Hospital, (Western) Sydney, Australia

4 Faculty of Dentistry, University of Sydney, Sydney, Australia

References

- [1] Chams-Davatchi C, Valikhani M, Daneshpazhooh M, et al. Pemphigus: analysis of 1209 cases. *Int J Dermatol* 2005;44:470-6.

- [2] Uzun S, Durdu M, Akman A, et al. Pemphigus in the Mediterranean region of Turkey: a study of 148 cases. *Int J Dermatol* 2006;45:523-8.
- [3] Krain LS. Pemphigus. Epidemiologic and survival characteristics of 59 patients, 1955-1973. *Arch Dermatol* 1974;110:862-5.
- [4] Aboobaker J, Morar N, Ramdial PK, Hammond MG. Pemphigus in South Africa. *Int J Dermatol* 2001;40:115-9.
- [5] Culton DA, Qian Y, Li N, et al. Advances in pemphigus and its endemic pemphigus foliaceus (Fogo Selvagem) phenotype: a paradigm of human autoimmunity. *J Autoimmun* 2008;31:311-24.
- [6] Abreu-Velez AM, Hashimoto T, Bollag WB, et al. A unique form of endemic pemphigus in northern Colombia. *J Am Acad Dermatol* 2003;49:599-608.
- [7] Bastuji-Garin S, Souissi R, Blum L, et al. Comparative epidemiology of pemphigus in Tunisia and France: unusual incidence of pemphigus foliaceus in young Tunisian women. *J Invest Dermatol* 1995;104:302-5.
- [8] Amagai M, Tsunoda K, Zillikens D, Nagai T, Nishikawa T. The clinical phenotype of pemphigus is defined by the anti-desmoglein autoantibody profile. *J Am Acad Dermatol* 1999;40:167-70.
- [9] Stanley JR, Koulu L, Thivolet C. Distinction between epidermal antigens binding pemphigus vulgaris and pemphigus foliaceus autoantibodies. *J Clin Invest* 1984;74:313-20.
- [10] Koulu L, Kusumi A, Steinberg MS, Klaus-Kovtun V, Stanley JR. Human autoantibodies against a desmosomal core protein in pemphigus foliaceus. *J Exp Med* 1984;160:1509-18.
- [11] Gniadecki R. Desmoglein autoimmunity in the pathogenesis of pemphigus. *Autoimmunity* 2006;39:541-7.
- [12] Anhalt G, Labib K, Vorhees J, Beals T, Diaz L. Induction of pemphigus in neonatal mice by passive transfer of IgG from patients with the disease. *N Engl J Med* 1982;306:1189-92.
- [13] Nishifuji K, Amagai M, Kuwana M, Iwasaki T, Nishikawa T. Detection of antigen-specific B cells in patients with pemphigus vulgaris by enzyme-linked immunospot assay: Requirement of T cell collaboration for autoantibody production. *J Invest Dermatol* 2000;114:88-94.
- [14] Hertl M. Humoral and Cellular Autoimmunity in Autoimmune Bullous Skin Disorders. *Int Arch Allergy Immunol* 2000;122:91-100.
- [15] Bhol K, Ahmed A, Aoki V, Mohimen A, Nagarwalla N, Natarajan K. Correlation of peptide specificity and IgG subclass with pathogenic and non pathogenic autoanti-

bodies in pemphigus vulgaris: A model for autoimmunity. *Proc Natl Acad Sci USA* 1995;92:5239-43.

- [16] Giordano C, Sinha A. Cytokine networks in Pemphigus vulgaris: An integrated viewpoint. *Autoimmunity* 2012;45:427-39.
- [17] Satyam A, Khandpur S, Sharma V, Sharma A. Involvement of Th1/Th2 cytokines in the pathogenesis of autoimmune skin disease - Pemphigus vulgaris. *Immunol Invest* 2009;38:498-509.
- [18] D'Auria L, Bonifati C, Mussi A, et al. Cytokines in the sera of patients with pemphigus vulgaris: interleukin-6 and tumour necrosis factor-alpha levels are significantly increased as compared to healthy subjects and correlate with disease activity. *Eur Cytokine Netw* 1997;8:383-7.
- [19] Lombardi ML, Mercurio O, Ruocco V, et al. Common human leukocyte antigen alleles in pemphigus vulgaris and pemphigus foliaceus Italian patients. *J Invest Dermatol* 1999;113:107-10.
- [20] Loiseau P, Lecleach L, Prost C, et al. HLA class II polymorphism contributes to specify desmoglein derived peptides in pemphigus vulgaris and pemphigus foliaceus. *J Autoimmun* 2000;15:67-73.
- [21] Aoki V, Millikan RC, Rivitti EA, et al. Environmental risk factors in endemic pemphigus foliaceus (fogo selvagem). *J Investig Dermatol Symp Proc* 2004;9:34-40.
- [22] Ribeiro JM, Valenzuela JG, Pham VM, et al. An insight into the sialotranscriptome of *Simulium nigrimanum*, a black fly associated with fogo selvagem in South America. *The American journal of tropical medicine and hygiene* 2010;82:1060-75.
- [23] Sirois DA, Fatahzadeh M, Roth R, Ettl D. Diagnostic patterns and delays in pemphigus vulgaris: experience with 99 patients. *Arch Dermatol* 2000;136:1569-70.
- [24] Mourellou O, Chaidemenos GC, Koussidou T, Kapetis E. The treatment of pemphigus vulgaris. Experience with 48 patients seen over an 11-year period. *Br J Dermatol* 1995;133:83-7.
- [25] Kaplan RP, Potter TS, Fox JN. Drug-induced pemphigus related to angiotensin-converting enzyme inhibitors. *J Am Acad Dermatol* 1992;26:364-6.
- [26] Penas PF, Buezo GF, Carvajal I, Dauden E, Lopez A, Diaz LA. D-penicillamine-induced pemphigus foliaceus with autoantibodies to desmoglein-1 in a patient with mixed connective tissue disease. *Journal of the American Academy of Dermatology* 1997;37:121-3.
- [27] Lee CW, Lim JH, Kang HJ. Pemphigus foliaceus induced by rifampicin. *The British journal of dermatology* 1984;111:619-22.

- [28] Ishiko A, Hashimoto T, Shimizu H, et al. Combined features of pemphigus foliaceus and bullous pemphigoid: immunoblot and immunoelectron microscopic studies. *Archives of dermatology* 1995;131:732-4.
- [29] Imamura S, Takigawa M, Ikai K, Yoshinaga H, Yamada M. Pemphigus foliaceus, myasthenia gravis, thymoma and red cell aplasia. A case report and indirect immunofluorescence study on 38 patients with myasthenia gravis. *Clinical and experimental dermatology* 1978;3:285-91.
- [30] Ng PP, Ng SK, Chng HH. Pemphigus foliaceus and oral lichen planus in a patient with systemic lupus erythematosus and thymoma. *Clinical and experimental dermatology* 1998;23:181-4.
- [31] Cowley NC, Neill SM, Staughton RC. Pemphigus foliaceus and non-Hodgkin's lymphoma. *International journal of dermatology* 1994;33:510-1.
- [32] Ota M, Sato-Matsumura KC, Matsumura T, Tsuji Y, Ohkawara A. Pemphigus foliaceus and figurate erythema in a patient with prostate cancer. *The British journal of dermatology* 2000;142:816-8.
- [33] Inaoki M, Kaji K, Furuse S, et al. Pemphigus foliaceus developing after metastasis of cutaneous squamous cell carcinoma to regional lymph nodes. *Journal of the American Academy of Dermatology* 2001;45:767-70.
- [34] Mihai S, Sitaru C. Immunopathology and molecular diagnosis of autoimmune bullous diseases. *J Cell Mol Med* 2007;11:462-81.
- [35] Kneisel A, Hertl M. Autoimmune bullous skin diseases. Part 2: diagnosis and therapy. *J Dtsch Dermatol Ges* 2011;9:927-47.
- [36] Morrison L. Direct immunofluorescence microscopy in the diagnosis of autoimmune bullous dermatoses. *Clinics in Dermatology* 2001;19:607-13.
- [37] Kirtschig G, Wojnarowska F. Autoimmune blistering diseases: an up-date of diagnostic methods and investigations. *Clinical and Experimental Dermatology* 1994;19:97-112.
- [38] Harrist TJ, Mihm MC. Cutaneous immunopathology. The diagnostic use of direct and indirect immunofluorescence techniques in dermatologic disease. *Human pathology* 1979;10:625-53.
- [39] Kanitakis J. Indirect Immunofluorescence Microscopy for the Serological Diagnosis of Autoimmune Blistering Skin Diseases: A Review. *Clinics in Dermatology* 2001;19:614-21.
- [40] Fernando SL, O'Connor KS. Treatment of severe pemphigus foliaceus with rituximab. *Med J Aust* 2008;189:289-90.

- [41] Schmidt E, Dahnrich C, Rosemann A, et al. Novel ELISA systems for antibodies to desmoglein 1 and 3: correlation of disease activity with serum autoantibody levels in individual pemphigus patients. *Experimental Dermatology* 2010;19:458-63.
- [42] Ishii K, Amagal M, Hall R, et al. Characterization of autoantibodies in pemphigus using antigen-specific enzyme linked immunosorbent assays with baculovirus-expressed recombinant desmogleins. *J Immunol* 1997;159:2010-7.
- [43] Schmidt E, Zillikens D. Modern diagnosis of autoimmune blistering skin diseases. *Autoimmunity Reviews* 2010;10:84-9.
- [44] Tampoia M, Giavarina D, Di Giorgio C, Bizzaro N. Diagnostic accuracy of enzyme-linked immunosorbent assays (ELISA) to detect anti-skin autoantibodies in autoimmune blistering skin diseases: A systematic review and meta-analysis. *Autoimmunity Reviews* 2012;12:121-6.
- [45] Harman K, Seed P, Gratian M, Bhogal B, Challacombe S, Black M. The severity of cutaneous and oral pemphigus is related to desmoglein 1 and 3 antibody levels. *British Journal of Dermatology* 2001;144:775-80.
- [46] Hallaji Z, Mortazavi H, Lajevardi V, et al. Serum and salivary desmoglein 1 and 3 enzyme-linked immunosorbent assay in pemphigus vulgaris: correlation with phenotype and severity. *J Eur Acad Dermatol Venereol* 2010;24:275-80.
- [47] Bystryn JC, Steinman NM. The adjuvant therapy of pemphigus. An update. *Arch Dermatol* 1996;132:203-12.
- [48] Castro RM, Roscoe JT, Sampaio SA. Brazilian pemphigus foliaceus. *Clin Dermatol* 1983;1:22-41.
- [49] Diaz LA, Sampaio SA, Rivitti EA, et al. Endemic pemphigus foliaceus (fogo selvagem). I. Clinical features and immunopathology. *J Am Acad Dermatol* 1989;20:657-69.
- [50] Martin LK, Werth V, Villanueva E, Segall J, Murrell DF. Interventions for pemphigus vulgaris and pemphigus foliaceus. *Cochrane Database Syst Rev* 2009:CD006263.
- [51] Murrell DF, Dick S, Ahmed AR, et al. Consensus statement on definitions of disease, end points, and therapeutic response for pemphigus. *J Am Acad Dermatol* 2008;58:1043-6.
- [52] Bystryn JC. Adjuvant therapy of pemphigus. *Arch Dermatol* 1984;120:941-51.
- [53] Ratnam KV, Phay KL, Tan CK. Pemphigus therapy with oral prednisolone regimens. A 5-year study. *Int J Dermatol* 1990;29:363-7.
- [54] Mentink LF, Mackenzie MW, Toth GG, et al. Randomized controlled trial of adjuvant oral dexamethasone pulse therapy in pemphigus vulgaris: PEMPULS trial. *Arch Dermatol* 2006;142:570-6.

- [55] Werth VP. Treatment of pemphigus vulgaris with brief, high-dose intravenous glucocorticoids. *Arch Dermatol* 1996;132:1435-9.
- [56] Femiano F, Gombos F, Scully C. Pemphigus vulgaris with oral involvement: evaluation of two different systemic corticosteroid therapeutic protocols. *J Eur Acad Dermatol Venereol* 2002;16:353-6.
- [57] Mimouni D, Nousari CH, Cummins DL, Kouba DJ, David M, Anhalt GJ. Differences and similarities among expert opinions on the diagnosis and treatment of pemphigus vulgaris. *J Am Acad Dermatol* 2003;49:1059-62.
- [58] Roenigk HH, Jr., Deodhar S. Pemphigus treatment with azathioprine. Clinical and immunologic correlation. *Arch Dermatol* 1973;107:353-7.
- [59] Chams-Davatchi C, Esmaili N, Daneshpazhooh M, et al. Randomized controlled open-label trial of four treatment regimens for pemphigus vulgaris. *J Am Acad Dermatol* 2007;57:622-8.
- [60] Chaidemenos G, Apalla Z, Koussidou T, Papagarifallou I, Ioannides D. High dose oral prednisone vs. prednisone plus azathioprine for the treatment of oral pemphigus: a retrospective, bi-centre, comparative study. *J Eur Acad Dermatol Venereol* 2011;25:206-10.
- [61] Aberer W, Wolff-Schreiner EC, Stingl G, Wolff K. Azathioprine in the treatment of pemphigus vulgaris. A long-term follow-up. *J Am Acad Dermatol* 1987;16:527-33.
- [62] Benoit Corven C, Carvalho P, Prost C, et al. [Treatment of pemphigus vulgaris by azathioprine and low doses of prednisone (Lever scheme)]. *Ann Dermatol Venereol* 2003;130:13-5.
- [63] Krensky AM. Immunosuppressants, Tolerogens, and Immunostimulants. In: Brunton LL, ed. *Goodman & Gilman's The Pharmacological Basis of Therapeutics*, 11th Edition. 11th ed: McGraw-Hill; 2006.
- [64] Beissert S, Werfel T, Frieling U, et al. A comparison of oral methylprednisolone plus azathioprine or mycophenolate mofetil for the treatment of pemphigus. *Arch Dermatol* 2006;142:1447-54.
- [65] Enk AH, Knop J. Mycophenolate is effective in the treatment of pemphigus vulgaris. *Arch Dermatol* 1999;135:54-6.
- [66] Mimouni D, Anhalt GJ, Cummins DL, Kouba DJ, Thorne JE, Nousari HC. Treatment of pemphigus vulgaris and pemphigus foliaceus with mycophenolate mofetil. *Arch Dermatol* 2003;139:739-42.
- [67] Esmaili N, Chams-Davatchi C, Valikhani M, Farshidfar F, Parvaneh N, Tamizifar B. Treatment of pemphigus vulgaris with mycophenolate mofetil as a steroid-sparing agent. *Eur J Dermatol* 2008;18:159-64.

- [68] Enk AH, Knop J. Treatment of pemphigus vulgaris with mycophenolate mofetil. *Lancet* 1997;350:494.
- [69] Powell AM, Albert S, Al Fares S, et al. An evaluation of the usefulness of mycophenolate mofetil in pemphigus. *Br J Dermatol* 2003;149:138-45.
- [70] Orvis AK, Wesson SK, Breza TS, Jr., Church AA, Mitchell CL, Watkins SW. Mycophenolate mofetil in dermatology. *J Am Acad Dermatol* 2009;60:183-99; quiz 200-2.
- [71] Chrysomallis F, Ioannides D, Teknetzis A, Panagiotidou D, Minas A. Treatment of oral pemphigus vulgaris. *Int J Dermatol* 1994;33:803-7.
- [72] Rose E, Wever S, Zilliken D, Linse R, Haustein UF, Brocker EB. Intravenous dexamethasone-cyclophosphamide pulse therapy in comparison with oral methylprednisolone-azathioprine therapy in patients with pemphigus: results of a multicenter prospectively randomized study. *J Dtsch Dermatol Ges* 2005;3:200-6.
- [73] Kaur S, Kanwar AJ. Dexamethasone-cyclophosphamide pulse therapy in pemphigus. *Int J Dermatol* 1990;29:371-4.
- [74] Pasricha JS, Khaitan BK, Raman RS, Chandra M. Dexamethasone-cyclophosphamide pulse therapy for pemphigus. *Int J Dermatol* 1995;34:875-82.
- [75] Fleischli ME, Valek RH, Pandya AG. Pulse intravenous cyclophosphamide therapy in pemphigus. *Arch Dermatol* 1999;135:57-61.
- [76] Ioannides D, Chrysomallis F, Bystryn JC. Ineffectiveness of cyclosporine as an adjuvant to corticosteroids in the treatment of pemphigus. *Arch Dermatol* 2000;136:868-72.
- [77] Mobini N, Padilla T, Jr., Ahmed AR. Long-term remission in selected patients with pemphigus vulgaris treated with cyclosporine. *J Am Acad Dermatol* 1997;36:264-6.
- [78] Werth VP, Fivenson D, Pandya AG, et al. Multicenter randomized, double-blind, placebo-controlled, clinical trial of dapsone as a glucocorticoid-sparing agent in maintenance-phase pemphigus vulgaris. *Arch Dermatol* 2008;144:25-32.
- [79] Heaphy MR, Albrecht J, Werth VP. Dapsone as a glucocorticoid-sparing agent in maintenance-phase pemphigus vulgaris. *Arch Dermatol* 2005;141:699-702.
- [80] Basset N, Guillot B, Michel B, Meynadier J, Guilhou JJ. Dapsone as initial treatment in superficial pemphigus. Report of nine cases. *Arch Dermatol* 1987;123:783-5.
- [81] Gurcan HM, Ahmed AR. Efficacy of dapsone in the treatment of pemphigus and pemphigoid: analysis of current data. *Am J Clin Dermatol* 2009;10:383-96.
- [82] Pfeiffer C, Wozel G. Dapsone and sulfones in dermatology: overview and update. *J Am Acad Dermatol* 2003;48:308-9.
- [83] Smith TJ, Bystryn JC. Methotrexate as an adjuvant treatment for pemphigus vulgaris. *Arch Dermatol* 1999;135:1275-6.

- [84] Mashkilleysen N, Mashkilleysen AL. Mucous membrane manifestations of pemphigus vulgaris. A 25-year survey of 185 patients treated with corticosteroids or with combination of corticosteroids with methotrexate or heparin. *Acta Derm Venereol* 1988;68:413-21.
- [85] Gurcan HM, Ahmed AR. Analysis of current data on the use of methotrexate in the treatment of pemphigus and pemphigoid. *Br J Dermatol* 2009;161:723-31.
- [86] Auad A, Auad T, Auad. A., P. A. Coadjuvant therapy for the treatment of South American pemphigus foliaceus with aurofin, A double-blind study.. *Anais Brasileiros de Dermatologia* 1986;61:131-4.
- [87] Penneys NS, Eaglstein WH, Frost P. Management of pemphigus with gold compounds: a long-term follow-up report. *Arch Dermatol* 1976;112:185-7.
- [88] Poulin Y, Perry HO, Muller SA. Pemphigus vulgaris: results of treatment with gold as a steroid-sparing agent in a series of thirteen patients. *J Am Acad Dermatol* 1984;11:851-7.
- [89] Pandya AG, Dyke C. Treatment of pemphigus with gold. *Arch Dermatol* 1998;134:1104-7.
- [90] Lange D, Meiss F, Fiedler E, Treiber K, Marsch WC, Fischer M. [Gold. Effective therapy for mucosal lesions of pemphigus vulgaris]. *Der Hautarzt; Zeitschrift fur Dermatologie, Venerologie, und verwandte Gebiete* 2007;58:142-5.
- [91] Gaspar ZS, Walkden V, Wojnarowska F. Minocycline is a useful adjuvant therapy for pemphigus. *Australas J Dermatol* 1996;37:93-5.
- [92] Alpsyoy E, Yilmaz E, Basaran E, Yazar S, Cetin L. Is the combination of tetracycline and nicotinamide therapy alone effective in pemphigus? *Arch Dermatol* 1995;131:1339-40.
- [93] Calebotta A, Saenz AM, Gonzalez F, Carvalho M, Castillo R. Pemphigus vulgaris: benefits of tetracycline as adjuvant therapy in a series of thirteen patients. *Int J Dermatol* 1999;38:217-21.
- [94] Tabrizi MN, Chams-Davatchi C, Esmaeeli N, et al. Accelerating effects of epidermal growth factor on skin lesions of pemphigus vulgaris: a double-blind, randomized, controlled trial. *J Eur Acad Dermatol Venereol* 2007;21:79-84.
- [95] Dumas V, Roujeau JC, Wolkenstein P, Revuz J, Cosnes A. The treatment of mild pemphigus vulgaris and pemphigus foliaceus with a topical corticosteroid. *Br J Dermatol* 1999;140:1127-9.
- [96] Nghiem P, Pearson G, Langley RG. Tacrolimus and pimecrolimus: from clever prokaryotes to inhibiting calcineurin and treating atopic dermatitis. *J Am Acad Dermatol* 2002;46:228-41.

- [97] Hall VC, Liesegang TJ, Kostick DA, Lookingbill DP. Ocular mucous membrane pemphigoid and ocular pemphigus vulgaris treated topically with tacrolimus ointment. *Arch Dermatol* 2003;139:1083-4.
- [98] Termeer CC, Technau K, Augustin M, Simon JC. Topical tacrolimus (protopic) for the treatment of a localized pemphigus foliaceus. *J Eur Acad Dermatol Venereol* 2004;18:636-7.
- [99] Cassano N, Coviello C, Scoppio BM, Miracapillo A, Vena GA. Recalcitrant lesions of pemphigus foliaceus at a surgical site: successful treatment with tacrolimus 0.1% ointment. *Eur J Dermatol* 2006;16:443-4.
- [100] Irajii F, Asilian A, Siadat AH. Pimecrolimus 1% cream in the treatment of cutaneous lesions of pemphigus vulgaris: a double-blind, placebo-controlled clinical trial. *Journal of drugs in dermatology : JDD* 2010;9:684-6.
- [101] Browning JL. B cells move to centre stage: novel opportunities for autoimmune disease treatment. *Nat Rev Drug Discov* 2006;5:564-76.
- [102] Edwards JC, Cambridge G. Prospects for B-cell-targeted therapy in autoimmune disease. *Rheumatology (Oxford)* 2005;44:151-6.
- [103] Eming R, Nagel A, Wolff-Franke S, Podstawa E, Debus D, Hertl M. Rituximab exerts a dual effect in pemphigus vulgaris. *J Invest Dermatol* 2008;128:2850-8.
- [104] Cellerai C, Harari A, Vallelian F, Boyman O, Pantaleo G. Functional and phenotypic characterization of tetanus toxoid-specific human CD4+ T cells following re-immunization. *Eur J Immunol* 2007;37:1129-38.
- [105] Herrmann G, Hunzelmann N, Engert A. Treatment of pemphigus vulgaris with anti-CD20 monoclonal antibody (rituximab). *Br J Dermatol* 2003;148:602-3.
- [106] Goebeler M, Herzog S, Brocker EB, Zillikens D. Rapid response of treatment-resistant pemphigus foliaceus to the anti-CD20 antibody rituximab. *Br J Dermatol* 2003;149:899-901.
- [107] Dupuy A, Viguier M, Bedane C, et al. Treatment of refractory pemphigus vulgaris with rituximab (anti-CD20 monoclonal antibody). *Arch Dermatol* 2004;140:91-6.
- [108] Espana A, Fernandez-Galar M, Lloret P, Sanchez-Ibarrola A, Panizo C. Long-term complete remission of severe pemphigus vulgaris with monoclonal anti-CD20 antibody therapy and immunophenotype correlations. *J Am Acad Dermatol* 2004;50:974-6.
- [109] Morrison LH. Therapy of refractory pemphigus vulgaris with monoclonal anti-CD20 antibody (rituximab). *J Am Acad Dermatol* 2004;51:817-9.
- [110] Wenzel J, Bauer R, Bieber T, Tuting T. Successful rituximab treatment of severe pemphigus vulgaris resistant to multiple immunosuppressants. *Acta Derm Venereol* 2005;85:185-6.

- [111] Schmidt E, Herzog S, Brocker EB, Zillikens D, Goebeler M. Long-standing remission of recalcitrant juvenile pemphigus vulgaris after adjuvant therapy with rituximab. *Br J Dermatol* 2005;153:449-51.
- [112] Arin MJ, Engert A, Krieg T, Hunzelmann N. Anti-CD20 monoclonal antibody (rituximab) in the treatment of pemphigus. *Br J Dermatol* 2005;153:620-5.
- [113] Kong HH, Prose NS, Ware RE, Hall RP, 3rd. Successful treatment of refractory childhood pemphigus vulgaris with anti-CD20 monoclonal antibody (rituximab). *Pediatr Dermatol* 2005;22:461-4.
- [114] El Tal AK, Posner MR, Spigelman Z, Ahmed AR. Rituximab: a monoclonal antibody to CD20 used in the treatment of pemphigus vulgaris. *J Am Acad Dermatol* 2006;55:449-59.
- [115] Serrao VV, Martins A, Paris FR, Lopes MP. Successful treatment of recalcitrant pemphigus foliaceus with rituximab. *J Eur Acad Dermatol Venereol* 2008;22:768-70.
- [116] Cianchini G, Lupi F, Masini C, Corona R, Puddu P, De Pita O. Therapy with rituximab for autoimmune pemphigus: results from a single-center observational study on 42 cases with long-term follow-up. *Journal of the American Academy of Dermatology* 2012;67:617-22.
- [117] Joly P, Mouquet H, Roujeau JC, et al. A single cycle of rituximab for the treatment of severe pemphigus. *N Engl J Med* 2007;357:545-52.
- [118] Cianchini G, Corona R, Frezzolini A, Ruffelli M, Didona B, Puddu P. Treatment of severe pemphigus with rituximab: report of 12 cases and a review of the literature. *Arch Dermatol* 2007;143:1033-8.
- [119] Ahmed AR, Spigelman Z, Cavacini LA, Posner MR. Treatment of pemphigus vulgaris with rituximab and intravenous immune globulin. *N Engl J Med* 2006;355:1772-9.
- [120] Kasperkiewicz M, Shimanovich I, Meier M, et al. Treatment of severe pemphigus with a combination of immunoadsorption, rituximab, pulsed dexamethasone and azathioprine/mycophenolate mofetil: a pilot study of 23 patients. *The British journal of dermatology* 2012;166:154-60.
- [121] Horvath B, Huizinga J, Pas HH, Mulder AB, Jonkman MF. Low-dose rituximab is effective in pemphigus. *The British journal of dermatology* 2012;166:405-12.
- [122] Mouquet H, Musette P, Gougeon ML, et al. B-cell depletion immunotherapy in pemphigus: effects on cellular and humoral immune responses. *J Invest Dermatol* 2008;128:2859-69.
- [123] Schmidt E, Brocker EB, Goebeler M. Rituximab in treatment-resistant autoimmune blistering skin disorders. *Clin Rev Allergy Immunol* 2008;34:56-64.

- [124] Molloy ES, Calabrese LH. Progressive multifocal leukoencephalopathy associated with immunosuppressive therapy in rheumatic diseases: evolving role of biologic therapies. *Arthritis and rheumatism* 2012;64:3043-51.
- [125] Padgett BL, Walker DL, ZuRhein GM, Eckroade RJ, Dessel BH. Cultivation of papova-like virus from human brain with progressive multifocal leukoencephalopathy. *Lancet* 1971;1:1257-60.
- [126] Cohen Y, Solal-Celigny P, Polliack A. Rituximab therapy for follicular lymphoma: a comprehensive review of its efficacy as primary treatment, treatment for relapsed disease, re-treatment and maintenance. *Haematologica* 2003;88:811-23.
- [127] Hertl M, Eming R, Borradori L. Rituximab (anti-CD20 monoclonal antibody)--ultimate or first choice in pemphigus? *Dermatology* 2007;214:275-7.
- [128] Feliciani C, Toto P, Amerio P, et al. In vitro and in vivo expression of interleukin-1 α and tumor necrosis factor- α mRNA in pemphigus vulgaris: interleukin-1 α and tumor necrosis factor- α are involved in acantholysis. *J Invest Dermatol* 2000;114:71-7.
- [129] Lopez-Robles E, Avalos-Diaz E, Vega-Memije E, et al. TNF α and IL-6 are mediators in the blistering process of pemphigus. *Int J Dermatol* 2001;40:185-8.
- [130] Berookhim B, Fischer HD, Weinberg JM. Treatment of recalcitrant pemphigus vulgaris with the tumor necrosis factor alpha antagonist etanercept. *Cutis* 2004;74:245-7.
- [131] Lin MH, Hsu CK, Lee JY. Successful treatment of recalcitrant pemphigus vulgaris and pemphigus vegetans with etanercept and carbon dioxide laser. *Arch Dermatol* 2005;141:680-2.
- [132] Gubinelli E, Bergamo F, Didona B, Annessi G, Atzori F, Raskovic D. Pemphigus foliaceus treated with etanercept. *J Am Acad Dermatol* 2006;55:1107-8.
- [133] Shetty A, Marcum CB, Glass LF, Carter JD. Successful treatment of pemphigus vulgaris with etanercept in four patients. *Journal of drugs in dermatology : JDD* 2009;8:940-3.
- [134] Jacobi A, Shuler G, Hertl M. Rapid control of therapy-refractory pemphigus vulgaris by treatment with the tumour necrosis factor- α inhibitor infliximab. *Br J Dermatol* 2005;153:448-9.
- [135] Pardo J, Mercader P, Mahiques L, Sanchez-Carazo JL, Oliver V, Fortea JM. Infliximab in the management of severe pemphigus vulgaris. *Br J Dermatol* 2005;153:222-3.
- [136] Howell SM, Bessinger GT, Altman CE, Belnap CM. Rapid response of IgA pemphigus of the subcorneal pustular dermatosis subtype to treatment with adalimumab and mycophenolate mofetil. *J Am Acad Dermatol* 2005;53:541-3.
- [137] Jolles S, Sewell WA, Misbah SA. Clinical uses of intravenous immunoglobulin. *Clin Exp Immunol* 2005;142:1-11.

- [138] Kazatchkine MD, Kaveri SV. Immunomodulation of autoimmune and inflammatory diseases with intravenous immune globulin. *N Engl J Med* 2001;345:747-55.
- [139] Zhu KY, Feferman T, Maiti PK, Souroujon MC, Fuchs S. Intravenous immunoglobulin suppresses experimental myasthenia gravis: immunological mechanisms. *J Neuroimmunol* 2006;176:187-97.
- [140] Arredondo J, Chernyavsky AI, Karaouni A, Grando SA. Novel mechanisms of target cell death and survival and of therapeutic action of IVIg in Pemphigus. *Am J Pathol* 2005;167:1531-44.
- [141] Bystryń JC, Jiao D. IVIg selectively and rapidly decreases circulating pathogenic autoantibodies in pemphigus vulgaris. *Autoimmunity* 2006;39:601-7.
- [142] Green MG, Bystryń JC. Effect of intravenous immunoglobulin therapy on serum levels of IgG1 and IgG4 antidesmoglein 1 and antidesmoglein 3 antibodies in pemphigus vulgaris. *Arch Dermatol* 2008;144:1621-4.
- [143] Sami N, Bhol KC, Ahmed AR. Influence of IVIg therapy on autoantibody titers to desmoglein 1 in patients with pemphigus foliaceus. *Clin Immunol* 2002;105:192-8.
- [144] Li N, Zhao M, Hilario-Vargas J, et al. Complete FcRn dependence for intravenous Ig therapy in autoimmune skin blistering diseases. *J Clin Invest* 2005;115:3440-50.
- [145] Ahmed AR. Intravenous immunoglobulin therapy in the treatment of patients with pemphigus vulgaris unresponsive to conventional immunosuppressive treatment. *J Am Acad Dermatol* 2001;45:679-90.
- [146] Bystryń JC, Jiao D, Natow S. Treatment of pemphigus with intravenous immunoglobulin. *J Am Acad Dermatol* 2002;47:358-63.
- [147] Sami N, Qureshi A, Ruocco E, Ahmed AR. Corticosteroid-sparing effect of intravenous immunoglobulin therapy in patients with pemphigus vulgaris. *Arch Dermatol* 2002;138:1158-62.
- [148] Baum S, Scope A, Barzilai A, Azizi E, Trau H. The role of IVIg treatment in severe pemphigus vulgaris. *J Eur Acad Dermatol Venereol* 2006;20:548-52.
- [149] Sami N, Qureshi A, Ahmed AR. Steroid sparing effect of intravenous immunoglobulin therapy in patients with pemphigus foliaceus. *Eur J Dermatol* 2002;12:174-8.
- [150] Ahmed AR, Sami N. Intravenous immunoglobulin therapy for patients with pemphigus foliaceus unresponsive to conventional therapy. *J Am Acad Dermatol* 2002;46:42-9.
- [151] Wetter DA, Davis MD, Yiannias JA, et al. Effectiveness of intravenous immunoglobulin therapy for skin disease other than toxic epidermal necrolysis: a retrospective review of Mayo Clinic experience. *Mayo Clin Proc* 2005;80:41-7.

- [152] Segura S, Iranzo P, Martinez-de Pablo I, et al. High-dose intravenous immunoglobulins for the treatment of autoimmune mucocutaneous blistering diseases: evaluation of its use in 19 cases. *J Am Acad Dermatol* 2007;56:960-7.
- [153] Amagai M, Ikeda S, Shimizu H, et al. A randomized double-blind trial of intravenous immunoglobulin for pemphigus. *J Am Acad Dermatol* 2009;60:595-603.
- [154] Bystryn JC, Schenkein I, Uhr JW. A model for regulation of antibody synthesis by serum antibody. *Prog Immunol* 1971;1:627-36.
- [155] Guillaume JC, Roujeau JC, Morel P, et al. Controlled study of plasma exchange in pemphigus. *Arch Dermatol* 1988;124:1659-63.
- [156] Nagasaka T, Fujii Y, Ishida A, et al. Evaluating efficacy of plasmapheresis for patients with pemphigus using desmoglein enzyme-linked immunosorbent assay. *Br J Dermatol* 2008;158:685-90.
- [157] Roujeau JC, Andre C, Joneau Fabre M, et al. Plasma exchange in pemphigus. Uncontrolled study of ten patients. *Arch Dermatol* 1983;119:215-21.
- [158] Ruocco V, Astarita C, Pisani M. Plasmapheresis as an alternative or adjunctive therapy in problem cases of pemphigus. *Dermatologica* 1984;168:219-23.
- [159] Blaszczyk M, Chorzelski TP, Jablonska S, Daszynski J, Beutner EH. Indications for future studies on the treatment of pemphigus with plasmapheresis. *Arch Dermatol* 1989;125:843-4.
- [160] Tan-Lim R, Bystryn JC. Effect of plasmapheresis therapy on circulating levels of pemphigus antibodies. *J Am Acad Dermatol* 1990;22:35-40.
- [161] Sondergaard K, Carstens J, Zachariae H. The steroid-sparing effect of long-term plasmapheresis in pemphigus: An update. *Ther Apher* 1997;1:155-8.
- [162] Eming R, Hertl M. Immunoabsorption in pemphigus. *Autoimmunity* 2006;39:609-16.
- [163] Ogata K, Yasuda K, Matsushita M, Kodama H. Successful treatment of adolescent pemphigus vulgaris by immunoabsorption method. *J Dermatol* 1999;26:236-9.
- [164] Schmidt E, Klinker E, Opitz A, et al. Protein A immunoabsorption: a novel and effective adjuvant treatment of severe pemphigus. *Br J Dermatol* 2003;148:1222-9.
- [165] Luftl M, Stauber A, Mainka A, Klingel R, Schuler G, Hertl M. Successful removal of pathogenic autoantibodies in pemphigus by immunoabsorption with a tryptophan-linked polyvinylalcohol adsorber. *Br J Dermatol* 2003;149:598-605.
- [166] Frost N, Messer G, Fierlbeck G, Risler T, Lytton SD. Treatment of pemphigus vulgaris with protein A immunoabsorption: case report of long-term history showing favorable outcome. *Ann N Y Acad Sci* 2005;1051:591-6.

- [167] Shimanovich I, Herzog S, Schmidt E, et al. Improved protocol for treatment of pemphigus vulgaris with protein A immunoabsorption. *Clin Exp Dermatol* 2006;31:768-74.
- [168] Shimanovich I, Nitschke M, Rose C, Grabbe J, Zillikens D. Treatment of severe pemphigus with protein A immunoabsorption, rituximab and intravenous immunoglobulins. *Br J Dermatol* 2008;158:382-8.
- [169] Pfütze M, Eming R, Kneisel A, Kuhlmann U, Hoyer J, Hertl M. Clinical and immunological follow-up of pemphigus patients on adjuvant treatment with immunoabsorption or rituximab. *Dermatology* 2009;218:237-45.
- [170] Hivelin M, Siemionow M, Grimbert P, Lantieri L. Extracorporeal photopheresis: From solid organs to face transplantation. *Transpl Immunol* 2009.
- [171] Voll RE, Herrmann M, Roth EA, Stach C, Kalden JR, Girkontaite I. Immunosuppressive effects of apoptotic cells. *Nature* 1997;390:350-1.
- [172] Wolf R, Matz H, Ruocco E, Ruocco V. The putative role of apoptosis in the induction of pemphigus. *Med Hypotheses* 2005;64:44-5.
- [173] Yeh SW, Sami N, Ahmed RA. Treatment of pemphigus vulgaris: current and emerging options. *Am J Clin Dermatol* 2005;6:327-42.
- [174] Rook AH, Jegasothy BV, Heald P, et al. Extracorporeal photochemotherapy for drug-resistant pemphigus vulgaris. *Ann Intern Med* 1990;112:303-5.
- [175] Liang G, Nahass G, Kerdel FA. Pemphigus vulgaris treated with photopheresis. *J Am Acad Dermatol* 1992;26:779-80.
- [176] Gollnick HP, Owsianowski M, Taube KM, Orfanos CE. Unresponsive severe generalized pemphigus vulgaris successfully controlled by extracorporeal photopheresis. *J Am Acad Dermatol* 1993;28:122-4.
- [177] Wollina U, Lange D, Looks A. Short-time extracorporeal photochemotherapy in the treatment of drug-resistant autoimmune bullous diseases. *Dermatology* 1999;198:140-4.
- [178] Nguyen VT, Arredondo J, Chernyavsky AI, Pittelkow MR, Kitajima Y, Grando SA. Pemphigus vulgaris acantholysis ameliorated by cholinergic agonists. *Arch Dermatol* 2004;140:327-34.
- [179] Grando SA, Dahl, M.V. Activation of keratinocyte muscarinic acetylcholine receptors reverses pemphigus acantholysis. *J Eur Acad Dermatol Venereol* 1993;2:72-86.
- [180] Nguyen VT, Ndoye A, Grando SA. Novel human alpha9 acetylcholine receptor regulating keratinocyte adhesion is targeted by Pemphigus vulgaris autoimmunity. *Am J Pathol* 2000;157:1377-91.

- [181] Nguyen VT, Ndoye A, Grando SA. Pemphigus vulgaris antibody identifies pemphaxin. A novel keratinocyte annexin-like molecule binding acetylcholine. *J Biol Chem* 2000;275:29466-76.
- [182] Nguyen VT, Ndoye A, Shultz LD, Pittelkow MR, Grando SA. Antibodies against keratinocyte antigens other than desmogleins 1 and 3 can induce pemphigus vulgaris-like lesions. *J Clin Invest* 2000;106:1467-79.
- [183] Grando SA. New approaches to the treatment of pemphigus. *J Investig Dermatol Symp Proc* 2004;9:84-91.
- [184] Irajil F, Yoosefi A. Healing effect of Pilocarpine gel 4% on skin lesions of pemphigus vulgaris. *Int J Dermatol* 2006;45:743-6.
- [185] Anhalt GJ, Werth VP, Strober B. An open-label phase I clinical study to assess the safety of PI-0824 in patients with pemphigus vulgaris. *J Invest Dermatol* 2005;125:1088.
- [186] Berkowitz P, Hu P, Liu Z, et al. Desmosome signaling. Inhibition of p38MAPK prevents pemphigus vulgaris IgG-induced cytoskeleton reorganization. *J Biol Chem* 2005;280:23778-84.
- [187] Berkowitz P, Hu P, Warren S, Liu Z, Diaz LA, Rubenstein DS. p38MAPK inhibition prevents disease in pemphigus vulgaris mice. *Proc Natl Acad Sci U S A* 2006;103:12855-60.
- [188] Berkowitz P, Diaz LA, Hall RP, Rubenstein DS. Induction of p38MAPK and HSP27 phosphorylation in pemphigus patient skin. *J Invest Dermatol* 2008;128:738-40.
- [189] Berkowitz P, Chua M, Liu Z, Diaz LA, Rubenstein DS. Autoantibodies in the autoimmune disease pemphigus foliaceus induce blistering via p38 mitogen-activated protein kinase-dependent signaling in the skin. *Am J Pathol* 2008;173:1628-36.
- [190] Kitajima Y, Aoyama Y, Seishima M. Transmembrane signaling for adhesive regulation of desmosomes and hemidesmosomes, and for cell-cell detachment induced by pemphigus IgG in cultured keratinocytes: involvement of protein kinase C. *J Investig Dermatol Symp Proc* 1999;4:137-44.
- [191] Aoyama Y, Kitajima Y. Pemphigus vulgaris-IgG causes a rapid depletion of desmoglein 3 (Dsg3) from the Triton X-100 soluble pools, leading to the formation of Dsg3-depleted desmosomes in a human squamous carcinoma cell line, DJM-1 cells. *J Invest Dermatol* 1999;112:67-71.
- [192] Aoyama Y, Owada MK, Kitajima Y. A pathogenic autoantibody, pemphigus vulgaris-IgG, induces phosphorylation of desmoglein 3, and its dissociation from plakoglobin in cultured keratinocytes. *Eur J Immunol* 1999;29:2233-40.

- [193] Caldelari R, de Bruin A, Baumann D, et al. A central role for the armadillo protein plakoglobin in the autoimmune disease pemphigus vulgaris. *J Cell Biol* 2001;153:823-34.
- [194] Lo Muzio L, Pannone G, Staibano S, et al. A possible role of catenin dyslocalization in pemphigus vulgaris pathogenesis. *J Cutan Pathol* 2001;28:460-9.
- [195] Williamson L, Raess NA, Caldelari R, et al. Pemphigus vulgaris identifies plakoglobin as key suppressor of c-Myc in the skin. *EMBO J* 2006;25:3298-309.
- [196] Li N, Liu, Z., Park, M., Diaz, L.A. p53-knockout mice are resistant to the induction of skin blisters and acantholysis by pemphigus autoantibodies. In: Annual meeting SID; 2008; Japan; 2008.
- [197] Li N, Liu, Z., Wang, J., Warren, S.J.P., Diaz, L.A. Inhibition of experimental pemphigus by the p53 inhibitor pifithrin-alpha. *J Invest Dermatol* 2007;127:Abstract 64.
- [198] Heupel WM, Zillikens D, Drenckhahn D, Waschke J. Pemphigus vulgaris IgG directly inhibit desmoglein 3-mediated transinteraction. *J Immunol* 2008;181:1825-34.
- [199] Heupel WM, Muller T, Efthymiadis A, Schmidt E, Drenckhahn D, Waschke J. Peptides Targeting the Desmoglein 3 Adhesive Interface Prevent Autoantibody-induced Acantholysis in Pemphigus. *J Biol Chem* 2009;284:8589-95.
- [200] Waschke J, Bruggeman P, Baumgartner W, Zillikens D, Drenckhahn D. Pemphigus foliaceus IgG causes dissociation of desmoglein 1-containing junctions without blocking desmoglein 1 transinteraction. *J Clin Invest* 2005;115:3157-65.
- [201] Bialy-Golan A, Brenner S. Penicillamine-induced bullous dermatoses. *J Am Acad Dermatol* 1996;35:732-42.
- [202] Nagao K, Tanikawa A, Yamamoto N, Amagai M. Decline of anti-desmoglein 1 IgG ELISA scores by withdrawal of D-penicillamine in drug-induced pemphigus foliaceus. *Clin Exp Dermatol* 2005;30:43-5.
- [203] Diaz LA, Sampaio SA, Rivitti EA, et al. Endemic pemphigus foliaceus (Fogo Selvagem): II. Current and historic epidemiologic studies. *J Invest Dermatol* 1989;92:4-12.
- [204] Fernando SL, Broadfoot AJ. Treatment options for pemphigus foliaceus. *Giornale italiano di dermatologia e venereologia : organo ufficiale, Societa italiana di dermatologia e sifilografia* 2009;144:363-77.