

We are IntechOpen, the world's leading publisher of Open Access books Built by scientists, for scientists

4,800

Open access books available

122,000

International authors and editors

135M

Downloads

Our authors are among the

154

Countries delivered to

TOP 1%

most cited scientists

12.2%

Contributors from top 500 universities



WEB OF SCIENCE™

Selection of our books indexed in the Book Citation Index
in Web of Science™ Core Collection (BKCI)

Interested in publishing with us?
Contact book.department@intechopen.com

Numbers displayed above are based on latest data collected.

For more information visit www.intechopen.com



Ultrasound Guided Non Surgical Closure of Post Angiographic Femoral Arteriovenous Fistula (AVF) and Pseudoaneurysm (PSA)

Akram M. Asbeutah, Pushpinder S. Khera and
Abdullah Ramadan

Additional information is available at the end of the chapter

<http://dx.doi.org/10.5772/55835>

1. Introduction

1.1. Indications for AVF treatment

Local complications of femoral arterial catheterization like hematomas, pseudoaneurysm (PSA) and arteriovenous fistula (AVF) are increasing in incidence due to the large number of patients undergoing diagnostic and therapeutic angiographic procedures through this route [1 - 3] (see figure 1). A PSA refers to a confined collection of thrombus and blood associated with tear of one or more layers of an arterial wall [4]. An iatrogenic AVF occurs when an arterial puncture inadvertently extends to involve an adjacent vein leading to a communication between the two. Color flow Doppler ultrasound is the imaging modality of choice for the diagnosis and assessment of a PSA, with a high sensitivity and specificity [5].

Incidence of post-angiographic femoral PSA and AVF varies between 0.07-9% [1], [6]. The risk factors include age more than 65 years, low or high femoral arterial puncture, anticoagulation and use of a large arterial sheath size [7].

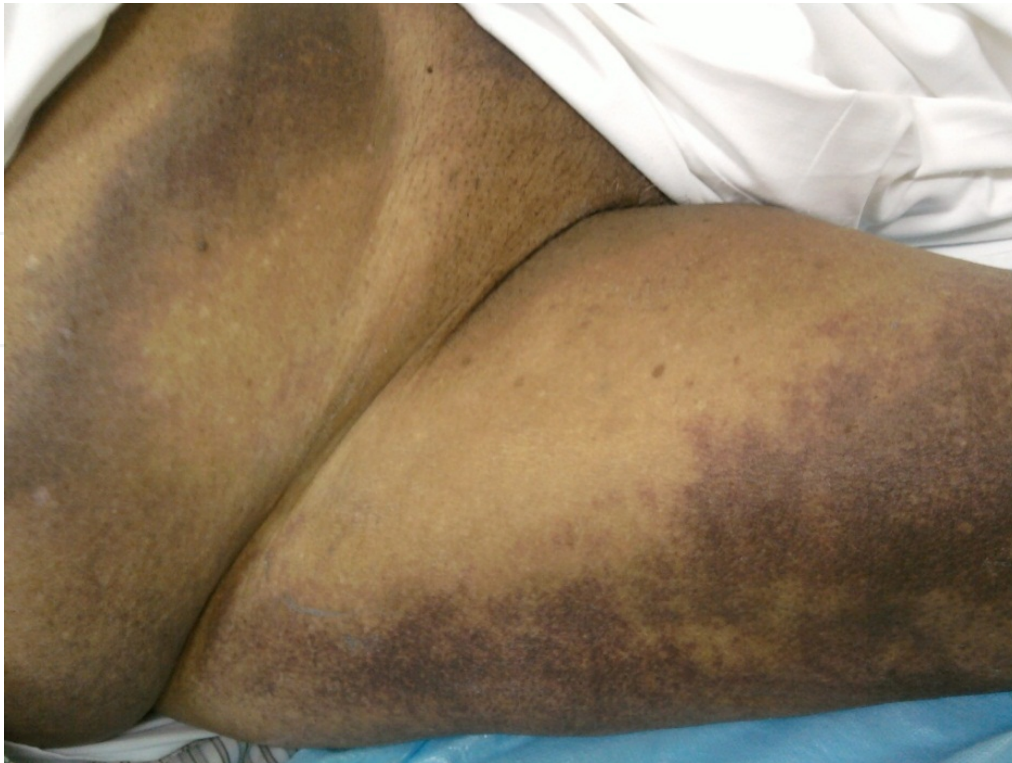

Figure 1. Ecchymosis of the right thigh and lower abdominal wall.

2. AFV diagnosis using imaging modalities

In the femoral region, turbulence is seen within either the common femoral or profunda femoral vein with arterialized signals shown on the Doppler spectrum (see Figure 2A). The fistulous communication can be seen on color flow Doppler, although it may be difficult to localize with duplex ultrasound alone (see Figure 2B). The turbulence associated with the fistula can be confused with turbulent signals due to extrinsic compression of the vein by hematoma or PSA, which is also a common complication following catheterization. The characteristic findings of a PSA include a slow swirling flow [Yin -Yang sign] within a hypoechoic lesion which is connected to the parent artery via a neck (see Figure 3 A-D). The latter displays a characteristic “to-and-fro” high velocity flow [4]. Doppler features of an AVF include a region of aliasing interposed between an artery and vein with increased diastolic flow in the artery and turbulent flow within the vein [8].

Visualization of the communicating channel allows a confident diagnosis of AVF rather than extrinsic venous compression by the surrounding hematoma or PSA. The use of computerized axial tomography (CTA) can resolve the problem (see Figure 4 A-B).

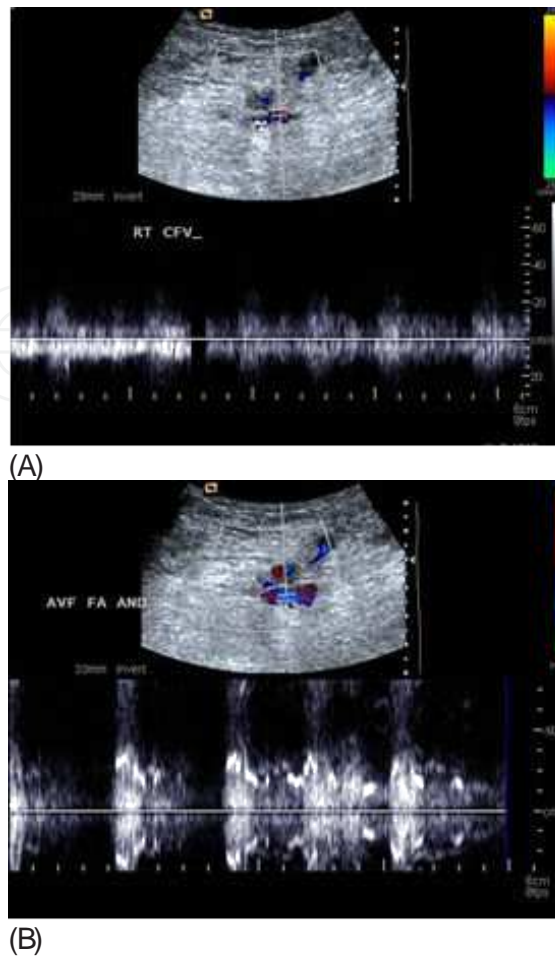


Figure 2. (A) Color Doppler image depicts arterial signals within the FV waveform indicating an arterio-venous communication; (B) Color Doppler image showing turbulent waveform within the AV fistula.

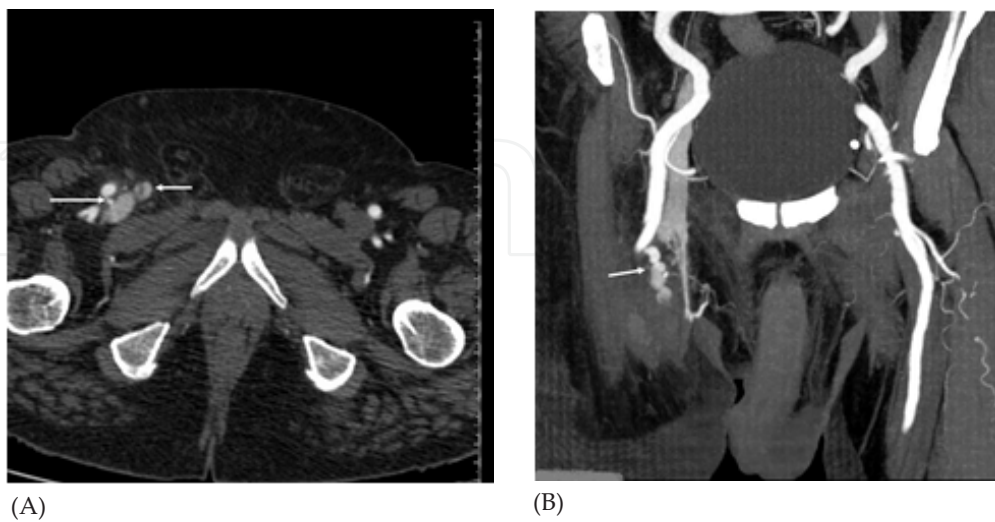

Figure 4. (A) CT angiography axial image depicts a thin linear communication (long arrow) between the posterior wall of FA and FV with opacification of the latter and the proximal great saphenous vein (short arrow); and (B) Coronal

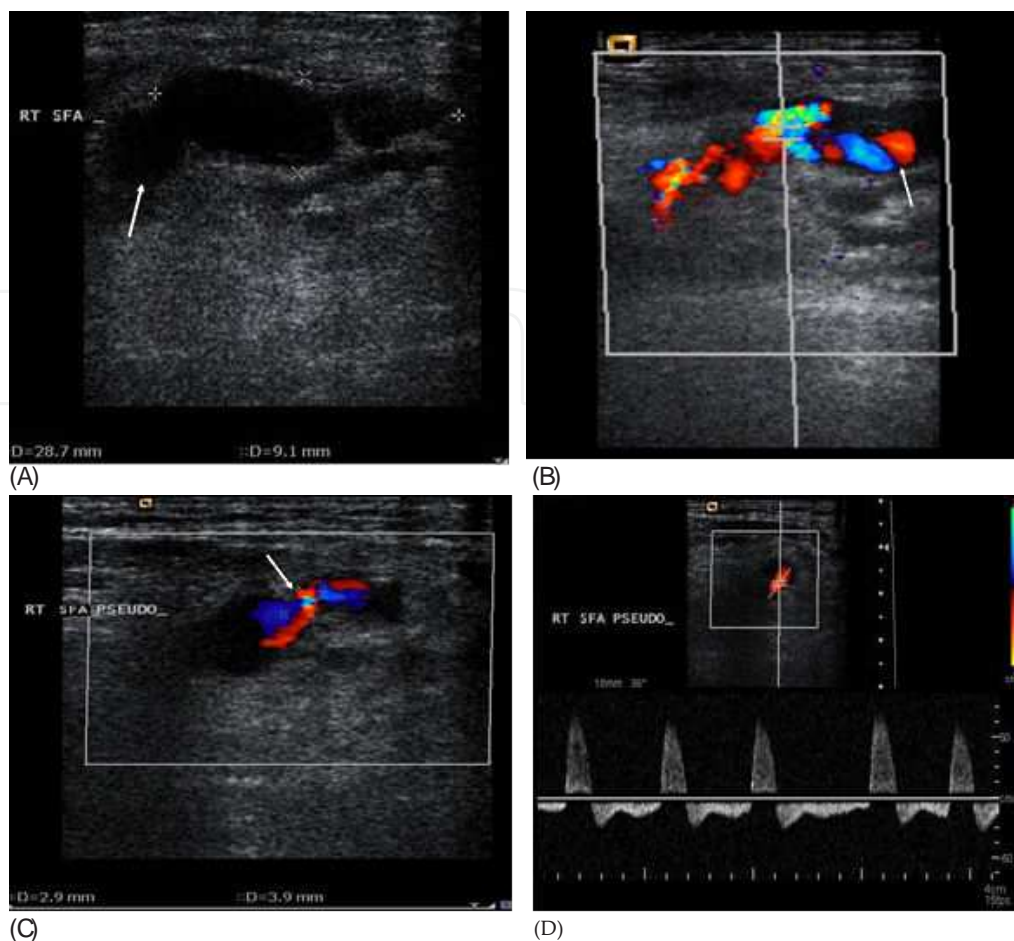


Figure 3. (A) Grey scale image showing the pseudoaneurysm as an oblong sonolucent structure anterior to the right FA (arrow); (B) Color Doppler image shows swirling flow within it the "Yin -Yang sign" (arrow); (C) The connection (neck) between the FA and PSA (arrow); and (D) Pulsed wave Doppler image of the PSA neck depicts to-and-fro flow within it.

reformatted image showing the PSA (arrow) arising from the FA. The CFV and the external iliac veins are opacified due to presence of the AV fistula.

3. Methods of treatment for AVF

Transcutaneous therapy aimed at achieving closure of the fistula has been described using ultrasound monitoring and by applying pressure over the fistula for periods of 20 to 60 minutes success rates are 30% or lower [12].

Despite ultrasound guided thrombin injection [UGTI] is an off label use of topical thrombin which is not FDA approved for injection, but it is only the treatment of choice when favorable anatomy is present such as a well defined narrow neck for post catheterization PSA [5 - 7]. Ultrasound guided compression [USGC] without thrombin injection retains a high success rate [6, 7] and it is a useful substitute for inducing thrombosis in the PSA and closure of AVF tract, with good results [10-17]

4. Treatment algorithm for AVF

Any patient who experiences local site pain disproportionate to that expected after an angiographic procedure should be evaluated with duplex ultrasound to rule out the presence of a PSA and/or AVF. Color Doppler ultrasound and spectral analysis has a high sensitivity [94%] and specificity [97%] for detection of a PSA [4].

Untreated PSA can lead to progressive lesion enlargement, infection, compression neuropathy and rupture [12]. Until the early nineties, surgery was the only treatment available for PSA and AVF closure. Presently it is only rarely employed to treat the post catheterisation PSA, when other treatment options fail or if a complication develops [13].

In 1991 Fellmeth et al. described a method of ultrasound guided compression (USGC) for closing post catheterization femoral PSA and AVF [12]. Subsequent studies confirmed a high rate of success [varying from 75% to >90%] for closure of PSA by this method [14 - 15]. In patients on anticoagulants, the success rate is reported to be between 30%-73 % [14 - 17]. Success rate for AVF closure is described between 33%-50% [12 - 16].

The mechanical compression is exerted using the ultrasound probe and is positioned directly over the neck of the PSA or the tract in case of the AVF [12]. It is titrated so as to obliterate blood flow within them. At all times an adequate flow is maintained in the concerned artery. The compression is usually continued for cycles of 10 minutes each with intermittent release to assess for closure of the neck. This can be repeated till the neck is closed or else discontinued if the physician/patient develops fatigue [13].

The only limiting factor in USGC method is the time it takes to induce thrombosis to close the PSA or AVF tract [13]. Patient may experience intra-procedural pain which responds to intravenous analgesia [12]. Complications are rare and include vasovagal reactions, PSA rupture, skin necrosis and DVT [13].

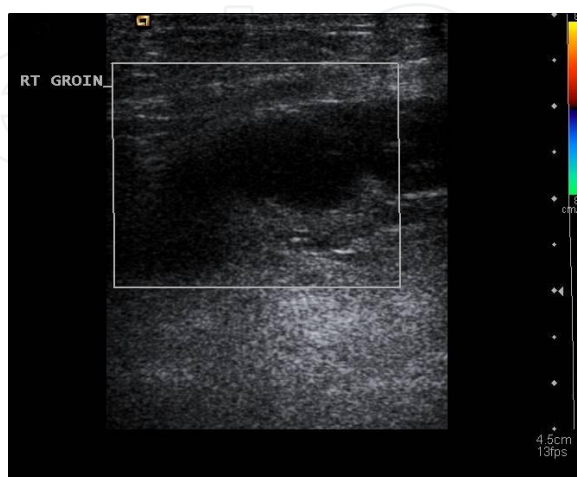

Figure 5. Successful post compression thrombosis of the PSA &AVF.

Successful obliteration of the PSA and the AVF is the main goal of the whole procedure (see Figure 5). This is the major goal every treating physician should achieve for better patient management and treatment.

Ultrasound guided compression of the post-angiographic femoral arterial injuries is a technically simple and relatively safe method.

Author details

Akram M. Asbeutah^{1*}, Pushpinder S. Khera² and Abdullah Ramadan²

*Address all correspondence to: asbeutah_akram@hotmail.com or akram.asbeutah@hsc.edu.kw

1 Department of Radiologic Sciences, Faculty of Allied Health Sciences, Kuwait University, Sulaibekhat, Kuwait

2 Department of Radiology, Al-Sabah Hospital, Ministry of Health, Kuwait

References

- [1] Babu, S. C, Piccorelli, G. O, Shah, P. M, Stein, J. H, & Clauss, R. H. Incidence and results of arterial complications among 16,350 patients undergoing cardiac catheterization. *J Vasc Surg* (1989). , 10, 113-16.
- [2] Glaser, R. L, Mckellar, D, & Scher, K. S. Arterio-venous fistulas after cardiac catheterization. *Arch Surg* (1989). , 124, 1313-15.
- [3] Bourassa, M. G, & Noble, J. Complication rate of coronary arteriography: a review of 5250 cases by percutaneous femoral technique. *Circulation* (1976). , 53, 106-14.
- [4] Burke, B. J, & Friedman, S. G. Ultrasound in the diagnosis and management of arterial emergencies. In, Zwiebel WJ(ed). *Introduction to vascular ultrasonography*, 5th edition. Philadelphia, Elsevier Saunders,(2005). , 381-99.
- [5] Coughlin, B. F, & Paushter, D. M. Peripheral pseudoaneurysms: evaluation with duplex US. *Radiology* (1988). , 168, 339-42.
- [6] Kresowik, T. F, Khoury, M. D, Miller, B. V, Winniford, M. D, Shamma, A. R, Sharp, W. J, et al. A prospective study of the incidence and natural history of femoral vascular complications after percutaneous transluminal coronary angioplasty. *J Vasc Surg* (1991). , 13, 328-336.

- [7] Morgan, R, & Belli, A. M. Current treatment methods for postcatheterization pseudoaneurysms. *J Vasc Interv Radiol* (2003). , 14, 697-710.
- [8] La Perna LOlin JW, Goines D, Childs MB, Ouriel K. Ultrasound-guided thrombin injection for the treatment of postcatheterization pseudoaneurysms. *Circulation* (2000). , 102, 2391-95.
- [9] Taylor, B. S, Rhee, R. Y, Muluk, S, Trachtenberg, J, Walters, D, Steed, D. L, et al. Thrombin injection versus compression of femoral artery pseudoaneurysms. *J Vasc Surg* (1999). , 30, 1052-59.
- [10] Weinmann, E. E, Chayen, D, Kobzantev, Z. V, Zaretsky, M, & Bass, A. Treatment of postcatheterisation false aneurysms: ultrasound-guided compression vs ultrasound-guided thrombin injection. *Eur J Vasc Endovasc Surg* (2002). , 23, 68-72.
- [11] Altstidi, R, Lehmkuhl, H. B, Voss, E, Herold, C, Becker, D, Giinter, E, et al. Ultrasound-guided nonsurgical closure of postangiographic femoral artery injuries. *Vasc Endovascular Surg* (1997). , 31, 781-90.
- [12] Fellmeth, B. D, Roberts, A. C, Bookstein, J. J, Freischlag, J. A, Forsythe, J. R, Buckner, N. K, et al. Postangiographic femoral artery injuries: nonsurgical repair with US-guided compression. *Radiology* (1991). , 178, 671-675.
- [13] Webber, G. W, Jang, J, Gustavson, S, & Olin, J. W. Contemporary management of postcatheterization pseudoaneurysms. *Circulation* (2007). , 115, 2666-74.
- [14] Eisenberg, L, Paulson, E. K, Kliewer, M. A, Hudson, M. P, DeLong, D. M, & Carroll, B. A. Sonographically guided compression repair of pseudoaneurysms: further experience from a single institution. *Am J Roentgenol* (1999). , 173, 1567-73.
- [15] Steinkamp, H. J, Werk, M, & Felix, R. Treatment of postinterventional pseudoaneurysms by ultrasound-guided compression. *Invest Radiol* (2000). , 35, 186-92.
- [16] Schaub, F, Theiss, W, Heinz, M, Zagel, M, & Schomig, A. New aspects in ultrasound-guided compression repair of post-catheterization femoral artery injuries. *Circulation* (1994). , 90, 1861-65.
- [17] Dean, S. M, Olin, J. W, Piedmonte, M, Grubb, M, & Young, J. R. Ultrasound guided compression closure of postcatheterization pseudoaneurysms during concurrent anticoagulation: a review of seventy-seven patients. *J Vasc surg* (1996). , 23, 28-34.

