

We are IntechOpen, the world's leading publisher of Open Access books Built by scientists, for scientists

4,800

Open access books available

122,000

International authors and editors

135M

Downloads

Our authors are among the

154

Countries delivered to

TOP 1%

most cited scientists

12.2%

Contributors from top 500 universities



WEB OF SCIENCE™

Selection of our books indexed in the Book Citation Index
in Web of Science™ Core Collection (BKCI)

Interested in publishing with us?
Contact book.department@intechopen.com

Numbers displayed above are based on latest data collected.
For more information visit www.intechopen.com



Fat Grafting in Breast Reconstruction with Expanders and Prostheses in Patients Who Have Received Radiotherapy

Jose Ma Serra-Renom, Jose Ma Serra-Mestre and
Francesco D'Andrea

Additional information is available at the end of the chapter

<http://dx.doi.org/10.5772/56073>

1. Introduction

Around 70% of breast reconstruction interventions currently incorporate tissue expansion and prostheses (Plastic Surgery Statistics Report, 2010). The popularity of the technique is due in part to its apparent simplicity. However, to ensure satisfactory results and to avoid long-term complications a long learning curve is required, and certain modifications should be made to the conventional techniques.

Breast reconstruction incorporating tissue expansion and prostheses presents a series of clear advantages. The most significant are its less invasive nature and its shorter recovery times – both highly important issues in patients who have already suffered major physical and psychological distress. It is also particularly beneficial in bilateral cases, in which achieving symmetry is a key objective, and in thin patients with small breasts. The technique obtains good results without increasing the morbidity of donor sites or causing the formation of new scars, as it uses the surrounding tissue which has the same color, texture and sensitivity.

At the same time, however, the technique has certain limitations, which we will discuss below. A high percentage of patients undergo radiotherapy, thereby increasing tissue fibrosis and the formation of capsular contracture and negatively affecting surgical outcomes. The use of textured implants, and above all the performance of fat grafting has significantly reduced the effect of this complication by providing thicker subcutaneous tissue [1,2] and improving the quality of the irradiated tissue [3].

2. Fat grafting in the breast

Fat injection is widely accepted as a useful technique for handling defects and asymmetries in breast surgery [4-6]. The availability of sufficient donor tissue, the low morbidity of the liposuctioned area, the benefit of the liposuction to the patient, and the ease of application have been decisive factors in its recent expansion. Today, however, fat is seen not only as an autologous filler, but also as a regenerator of the injected tissue thanks to the preadipocytes it contains. This regenerative capacity is of particular interest in breast surgery due to the tissue damage caused by radiotherapy.

Rigotti [3] demonstrated the improvement in irradiated tissues after serial injection of fat, reporting values on the LENT-SOMA scale (which provides an objective assessment of post-radiation skin changes) from 3-4 to 0-1. Along the same lines, our research group demonstrated the formation of a new subcutaneous plane in the post-mastectomized breast after radiation therapy, reducing the formation of the capsule around the prosthesis and improving tissue quality [1]. These results have since been corroborated by other authors [7-10].

The use of fat grafts has been a matter of controversy since the 1980s. It has been suggested that fat injection modifies radiological images in both mammography and magnetic resonance imaging (MRI), which may hinder the radiological control after surgery and may interfere with the early detection of breast cancer. In our view, however, the radiological findings after fat injection are not pathognomonic for tumor growth, but in fact are clearly differentiated images which radiologists in the twenty-first century should be able to recognize – just as they have had to learn to distinguish the changes appearing in other conventional breast surgery (reduction, augmentation, mastopexy, and so on) which are commonly accepted today.

When performing breast reconstruction, the breast already presents scars and calcifications as a result of tumor removal. In its 2009 publication, the ASPS Fat Graft Task Force updated its recommendation on the use of fat injection [11].

So far, no increase in local recurrence of breast cancer has been found in association with fat injection, nor any increase in the risk of new cancers. In fact, breast augmentation surgery raises aromatase activity 20 times more than fat grafting.

2.1. Volume maintenance and fat graft viability

It is important to identify the variables that may affect the adipocytes and adipose-derived stem cells (ASC) during the processing of fat tissue from its extraction to its injection into the recipient site. Numerous studies have been performed, but certain aspects remain unresolved. It is not the aim of this chapter to discuss the physiology of fat tissue in great technical detail; below is a brief summary of some of the procedures for optimizing outcome in terms of cell viability and, as a result, greater volume maintenance.

Fat harvesting

As far as the choice of donor site is concerned, we advocate obtaining the fat from the periumbilical area due to the ease of preparing a single surgical field comprising the donor, the

abdomen, and the recipient, the breast. The abdomen usually has enough fat to allow removal and to hide the incisions made in the navel and the pubis. This also enables us to extract the fat in a criss-cross pattern and avoids leaving visible scars and irregularities, even if they are minimal.

In the literature there is no consensus regarding the best donor site. One study favors the lower abdomen, where it is believed that there is a higher concentration of stem cells (ASC) [12]; however the results were obtained on the basis of c-kit expression, which measures not just the stem cells but lymphocytes as well. For Fraser et al [13], the hips are the best area, while other authors see no particular advantages between different areas of extraction.

Local anesthesia (especially lidocaine and epinephrine) has been reported to impair adipocyte metabolism, reducing glucose transport and the viability of the ASC [14]. However, that study was performed in vitro and did not take into account the actual concentration of anesthetic in the fluid being infiltrated. The authors note that the time between infiltration and aspiration may be relevant in prolonging contact between cells and the anesthetic [14].

Another important variable in the cell viability of the stromal fraction is the aspiration pressure. Today it is accepted that the lower the pressure, the higher the survival [15], so we favor the use of a 10 cc syringe with the plunger withdrawn 2 cc (0.37 at) for the extraction of small volumes, or a fat aspirator at 0.5 at for larger volumes.

The choice of cannula does not seem to be a problem, although there is a relationship between the diameter of the cannula and the aspiration pressure.

Fat Processing

Some studies report that washing achieves higher cell viability and survival than Coleman's centrifugation method (3000 rpm × 3 min) [16], although the results obtained with the two techniques are similar and both can be considered valid. Numerous studies have assessed the effects of centrifugation on fat aspirates to optimize the centrifugal force for fat transplantation and to obtain a high number of intact ASC [17, 18]. A centrifugal force of 1200 g is recommended.

Other decisive factors in cell viability are the time the fat tissue is extracted and the temperature to which it is exposed. Matsumo et al [19] studied the oil ratio, the presence of glycerol-3-phosphate dehydrogenase and adipose stem cells in different samples at different temperatures and times of preservation. They concluded that ASC persisted at room temperature practically for four hours, with a progressive destruction up to 24 hours. Carvalho et al. [20] reported that acceptable fat tissue viability can be maintained at room temperature until 24 hours after extraction. For longer periods, adipose tissue preservation banks have recently been designed.

Fat Grafting

The key factor is to achieve the correct three-dimensional distribution of fat in different planes from the depth to surface, creating a criss-cross pattern and avoiding the accumulation of large quantities of fat. The diameter of the hole of the cannula used to make the injection should be

the same as the one used to extract the fat, in order to keep mechanical damage to the adipocytes to a minimum.

2.2. Procedure

Atraumatic procurement of adipose tissue

When surgery is performed under general anesthesia or sedation, we create the tumescence of the abdominal region using a multiperforated tumescent cannula with a luer lock connection measuring 1.6 mm x 9-15 cm, with a saline and adrenaline solution at a ratio of 500 cc saline, 1 mg of adrenaline and 20 cc of lidocaine 2%.

When surgery is performed under local anesthesia in a second operation to optimize the outcome, two hours prior to surgery the extraction area (previously indicated to the patient during a visit) is covered with a topical anesthetic cream (EMLA™). A light massage is performed to ensure good penetration and the whole area is then covered with abundant cream and a plastic film. At the time of surgery the cream is removed and we infiltrate a small quantity of undiluted anesthetic at the two points where the incisions will be made. We then create the tumescence with a 30 cc solution of 2% lidocaine and 0.5 mg adrenaline. In both cases, we wait 20 minutes for the anesthetic to take effect.

Via the same incision used to make the tumescence, we introduce the 2 mm x 15 cm Coleman cannula connected to a 10 ml syringe with a luer lock tip, and maintain the plunger withdrawn about 2 ml with the dominant hand; with the other we make a pinch in the abdomen and make forward and backward movements at this level without losing the vacuum. In this way the syringe fills up with fat using a moderate vacuum pressure in order to keep trauma to a minimum. In cases in which greater quantities of fat are required and liposuction is performed, we use a 3 mm liposuction cannula and the liposuction device at a pressure of 0.5 atmospheres (FIG.1).

As it is very important not to leave irregularities in the abdomen, it is advisable to change the site and direction of the aspirations. To prevent irregularities it is also useful to make an incision in the pubis and to criss-cross the tunnels of the pubis and umbilicus.

Once the fat extraction is completed, we regularize the donor site using a flat liposuction cannula without aspiration. As we fill the syringes, we remove the plunger, cover the distal end and place them upright on a support rack. We now suture the incisions and apply a bandage to the abdomen for a week. After this period, abdominal massages are performed.

Adipose tissue processing

Centrifugation

When the necessary amount of fat has been extracted, it is centrifuged at 2000 rpm for two minutes.

After centrifuging, three levels can be observed in each of the syringes. The lower one contains blood and debris, water and components of the solution used for the tumescence; the middle layer consists of adipocytes and ASCs, and the top layer is formed by the oil resulting from

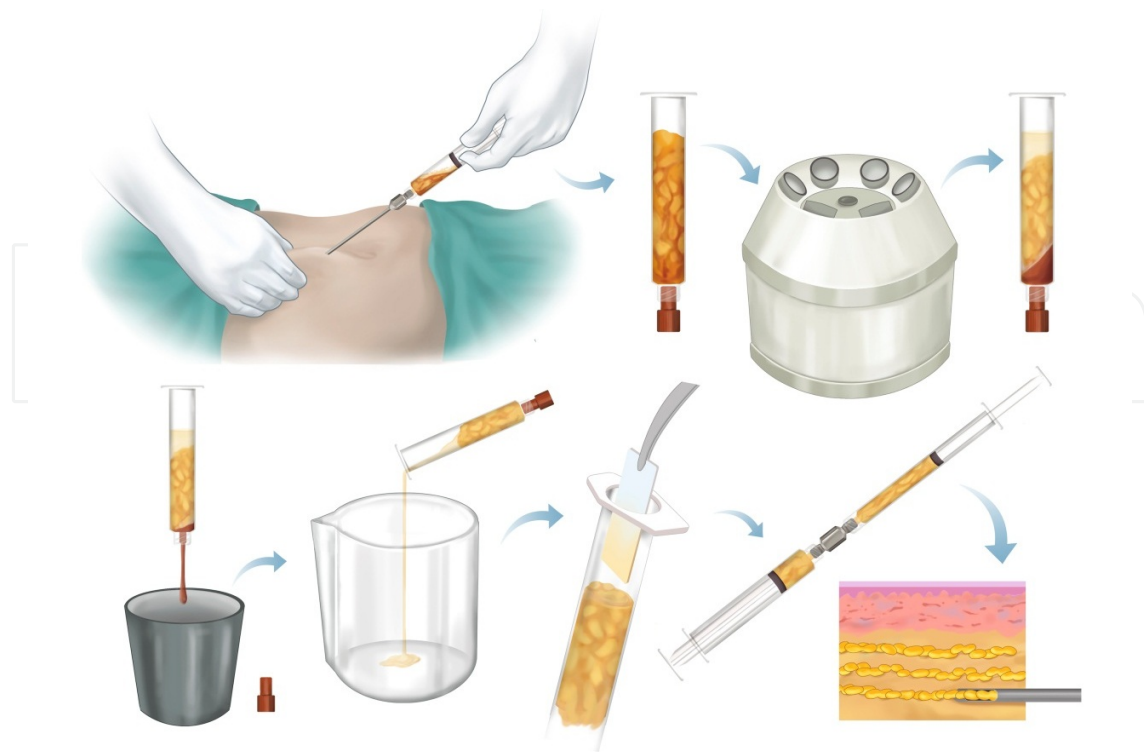

Figure 1. Harvest of fat grafts → Fat grafts are processed after centrifugation. The upper (oil) portion and the lower (red blood cells) portion should all be discarded. The fat is then injected creating several levels of injection.

the broken down fatty acids. This must be removed, as it has an acid pH and makes it difficult for the fat to “take” as a graft. To separate the hematic level we open the bottom plug and allow the blood to flow out into a tray. The broken down fatty acids in the top level can be removed by decantation, and if necessary the oil can be removed with the aid of a small lined gauze. Once the fat has been obtained, we connect the 10 ml syringe to the 1 ml syringes with a Luer Lock Transfer connector. This device is used to transfer fat by attaching a syringe to each end with a stopcock.

Washing

In this process we separate the tumescent liquid, anesthetics, lipids and broken down blood cells from the adipose tissue by washing and filtering the fat with saline solution or Ringer Lactate.

Once "purified" the fat is transferred to 10 ml syringes, and then, as with the method described above, it is transferred to the 1ml syringes via a Luer Lock Transfer connector, ready for injection.

Recently marketed systems such as Puregraft™ wash and filter the fat through membranes similar to those used in dialysis.

Injection of adipose tissue

To monitor the results as we inject the fat, we change the patient's position on the operating table and seat her. With a n° 11 scalpel we make the incisions needed, and with a blunt

microinfiltration cannula (Coleman number 192729 or, if there is abundant fibrosis, the V7microinfiltration dissecting cannula), straight or convex, with a blunt tip and a 2 mm lateral orifice connected to a 1 ml syringe, we make the tunnels and inject the fat. Thus the injected fat enters in a single line and in small quantities [1ml), thereby enhancing graft survival and the integration of the adipose tissue implanted into the recipient site. This blunt cannula has a side hole in the tip, which is the same size as the holes of the cannula that we used to extract the fat, to avoid injury. These grafts should deposit very small amounts of fat in each tunnel, about 1 mm. First we introduce the cannula without infiltrating, and then infiltrate as we withdraw it. The effect is like the beads on a necklace; we create several levels of injection and it is essential to repeat the procedure several times at different levels so as to ensure that these micro-beads of fat “take” properly. It is also very important to introduce the fat in different areas creating a mesh or criss-cross pattern and making tunnels at all levels to prevent the accumulation of fat. The surrounding tissue revitalizes each lipoma, each small bead of fat tissue, and the body incorporates it as living tissue. In addition we should note that this fat contains preadipocytes, stem cells with a high capacity for angiogenesis. Therefore, by injecting this fat, we are not just adding volume but we are introducing mesenchymal stem cells with a great angiogenic capacity for the tissue repair of the implanted area. We finish with a 6/0 suture in each one of these holes and immobilize the area with hypoallergenic adhesive plasters to prevent the movement of the grafts.

2.3. Hotspots in fat injection with expanders and implants

From the cosmetic point of view, fat grafting overcomes the limitations of breast reconstruction with implants. To do so, along with the three-dimensional dispersion of the fat at various levels from the depth to the surface through the creation of the mesh or criss-cross pattern described above, the areas in which breast prostheses are not able to correct the defect require special attention. On the one hand, in the upper quadrants (especially in the upper outer quadrant) fat grafting provides the shape for the tail of the breast, something that the breast prosthesis does not do. In the upper-medial quadrant with the injection of fat we can reconstruct the cleavage. In the lower quadrants, fat grafting improves aesthetic appearance and adds thickness to the subcutaneous tissue, enhancing naturalness and creating a better-defined inframammary fold (FIG. 2).

3. Immediate breast reconstruction

3.1. Preoperative marking

Prior to surgery, we mark the reference lines with the patient in standing position.

First, the surgical oncologist draws the incision of the mastectomy to be performed. Then we draw the pocket we will create for insertion of the expander. To do this, we mark the midline from the sternal notch to the navel and delimit the width of the pocket, marking the anterior axillary line and a line 1.5 cm from the midline. We mark the current inframammary fold and an orientative point where we will place the new one, parallel to the current fold and at a

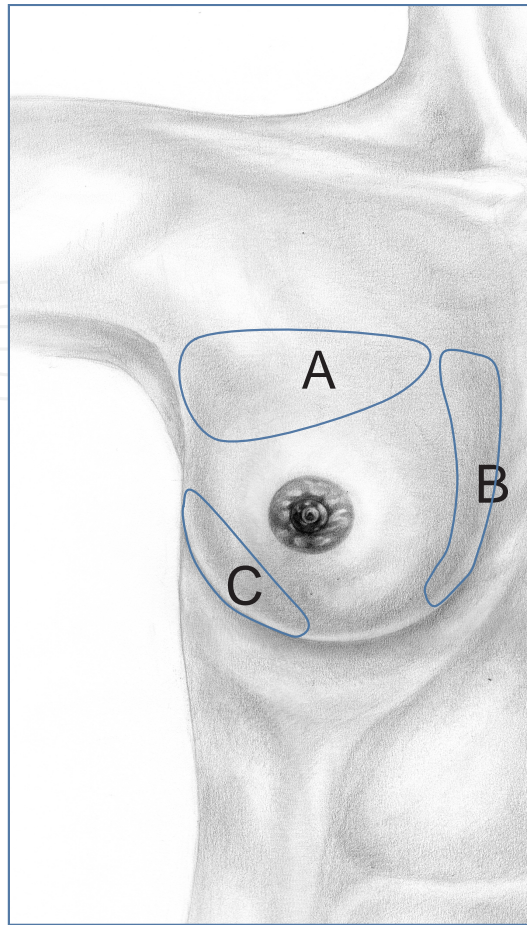


Figure 2. Areas in which breast prostheses are not able to correct the defect.

distance corresponding to half the result of the pinch test (the thickness of the skin and of subcutaneous fat panniculus), in most cases around 1-2 cm below. Note that these measures are approximate, and the new definitive fold will be placed using as a reference the healthy contralateral side, now reformed, 1 or 2 cm below the sixth rib.

In the contralateral healthy side, breast reduction, mastopexy or augmentation may be required. We prefer to perform symmetry surgery during this first stage since this gives us a second chance to correct the scars of the breast reduction or mastopexy when we replace the expander with the final prosthesis. In addition, if we have performed breast augmentation, being able to use the definitive contralateral breast as a reference helps us to calculate the size of the prosthesis needed on the mastectomized side during the second intervention.

3.2. Surgical technique

Approach to the contralateral breast

Among the main objectives of the reconstruction is to make the shape and volume of the two breasts as symmetrical as possible. In most patients, this requires cosmetic treatment of the

healthy breast. We favor performing any cosmetic treatment necessary during the first stage. Better results are achieved if we perform the symmetrization with the expander and the fat grafting with the healthy, reformed side as our reference; this approach also allows us to make any alterations necessary in the second intervention.

If the healthy breast is small, we perform a breast augmentation. If a mastopexy is indicated, our technique of choice is the vertical scar technique [21]. If breast reduction is required, first we measure the distance from the sternal notch to the nipple. If it is less than 30 cm, we use our vertical scar technique [21]; if it is between 30 and 35 cm we use the "T" scar technique [22], and when it is above 35 cm we perform a free nipple implant and use the inferior pedicle to give projection to the breast, held in place by a band of the pectoralis major muscle [23].

First stage

At the same time as the aesthetic treatment of the healthy breast, and once the mastectomy is complete, we partially detach the pectoralis major muscle at the level of the fourth, fifth and sixth ribs (Fig.3A).

We begin this detachment with the free external edge of the muscle. It is important to perform this dissection above the pectoralis minor muscle; if carried out below this muscle, the dissection causes much more bleeding. It is very important to dissect the free edge of the pectoralis major muscle. Once identified, we introduce the index finger and with simple blunt dissection we identify the entire pocket without detaching any rib insertions, as this would cause bleeding. We place a retractor in the lateral edge and, using slight traction and taking care not to damage the muscle, we elevate the pectoralis major muscle like a tent. This simple maneuver allows us to detach the muscle from the sixth rib. We perform this detachment with the electric scalpel and with full vision. On reaching the sternon we detach the muscle up to the fourth rib.

We place the new inframammary fold 1 or 2 cm below the level of the sixth rib. Next, we suture the free lower edge of the pectoral muscle to the lower skin flap of the mastectomy, 2 cm from its free edge (Fig.3B).

It is important not to damage the muscle and to ensure that it does not tear when it is sutured to the subcutaneous tissue 2 cm from the lower edge of the mastectomy. Occasionally, if the subcutaneous tissue is thin we do not suture the muscle but place it 2 cm from the free edge, using transfixion stitches. We hold these stitches in place with steristrips.

Next we place the expander and fill it slightly with approximately 100cc of saline solution to prevent the formation of folds, but without creating tension in the skin, in order to avoid damage if the skin flaps are very thin. Finally we insert an aspiration drain and suture the skin.

Our technique [24] achieves an anatomical inclination in the upper quadrants as the expander is below the pectoral muscle, and the expansion of the lower quadrants is highly satisfactory since the muscle is detached and a curved shape is obtained, especially in the case of the lower external quadrant.

After two weeks, the expander is filled with 50 cc per week until the same size is achieved as the contralateral breast. Once the breasts are the same size, we perform a slight over-expan-

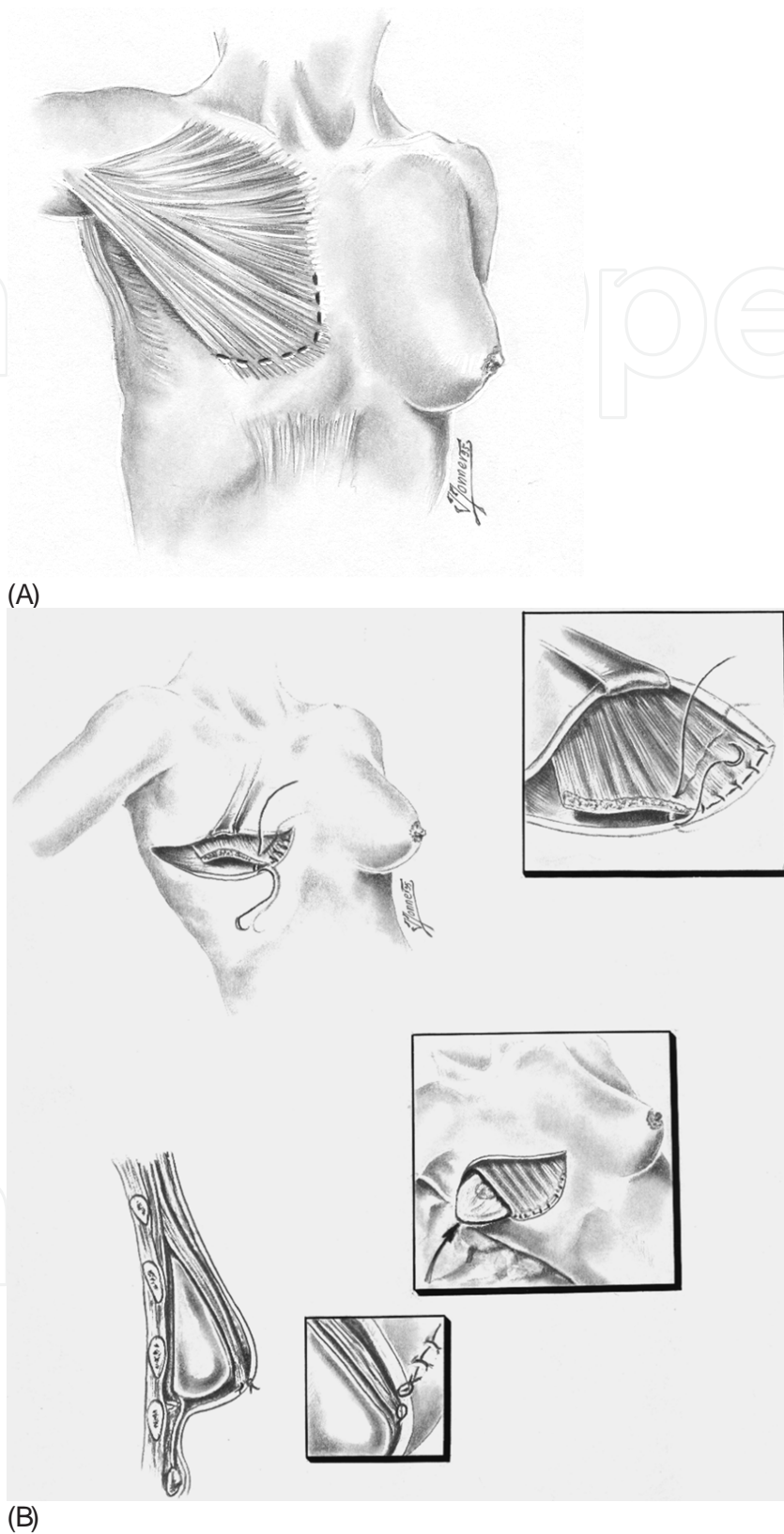


Figure 3. A: Partial detachment of the pectoralis major muscle from the fourth, fifth and sixth ribs. B: Suture of the lower free border of the pectoral major muscle to the lower skin flap of the mastectomy, 2 cm from the incision.

sion prior to the second intervention. If radiotherapy or chemotherapy is required, we follow the established protocol without any modifications.

Second stage

At 3 months after the first surgery, we replace the expander with the definitive prosthesis via a 4 cm incision in the lateral external third of the mastectomy scar and around the free edge of the pectoral muscle.

We use sizers to calculate the dimensions of the prosthesis required. After checking the correct volume, we insert the final prosthesis. We use anatomical prostheses with cohesive silicone. After inserting the prosthesis and suturing the skin, we perform fat grafting in the whole breast. In the upper quadrants we inject the fat in the subcutaneous plane between the muscle and skin, and also between the muscles, and in the lower quadrants between the capsule and the skin to achieve good reconstruction.

With this technique [1] we improve the quality of the tissue and reshape the breast to make it as symmetrical as possible to the contralateral breast, which if necessary will also receive fat grafting.

In this second stage, if necessary, we retouch the healthy side to achieve an optimal aesthetic result, and reconstruct the nipple-areola complex. (Fig.4 A-G).

4. Delayed breast reconstruction with endoscopy and intraoperative expansion

4.1. Preoperative marking

On the mastectomized side we mark the midline extending from the sternal notch to the navel. We define the width of the pocket, marking the anterior axillary line and a line 1.5 cm from the midline. We mark the new inframammary fold at the level of the sixth rib plus half the thickness of the pinching test (1 or 2 cm, depending on the patient).

On the contralateral healthy side, the marking depends on the surgery being performed, as explained above.

4.2. Surgical technique

Approach to the contralateral breast

As in the case of immediate reconstruction, in the first stage we perform aesthetic correction of the contralateral healthy breast, if required.

First stage

The expander is inserted by endoscopy through a 4 cm incision in the lateral external third of the mastectomy scar at the level of anterior axillary line, and with the aid of our endoscopic

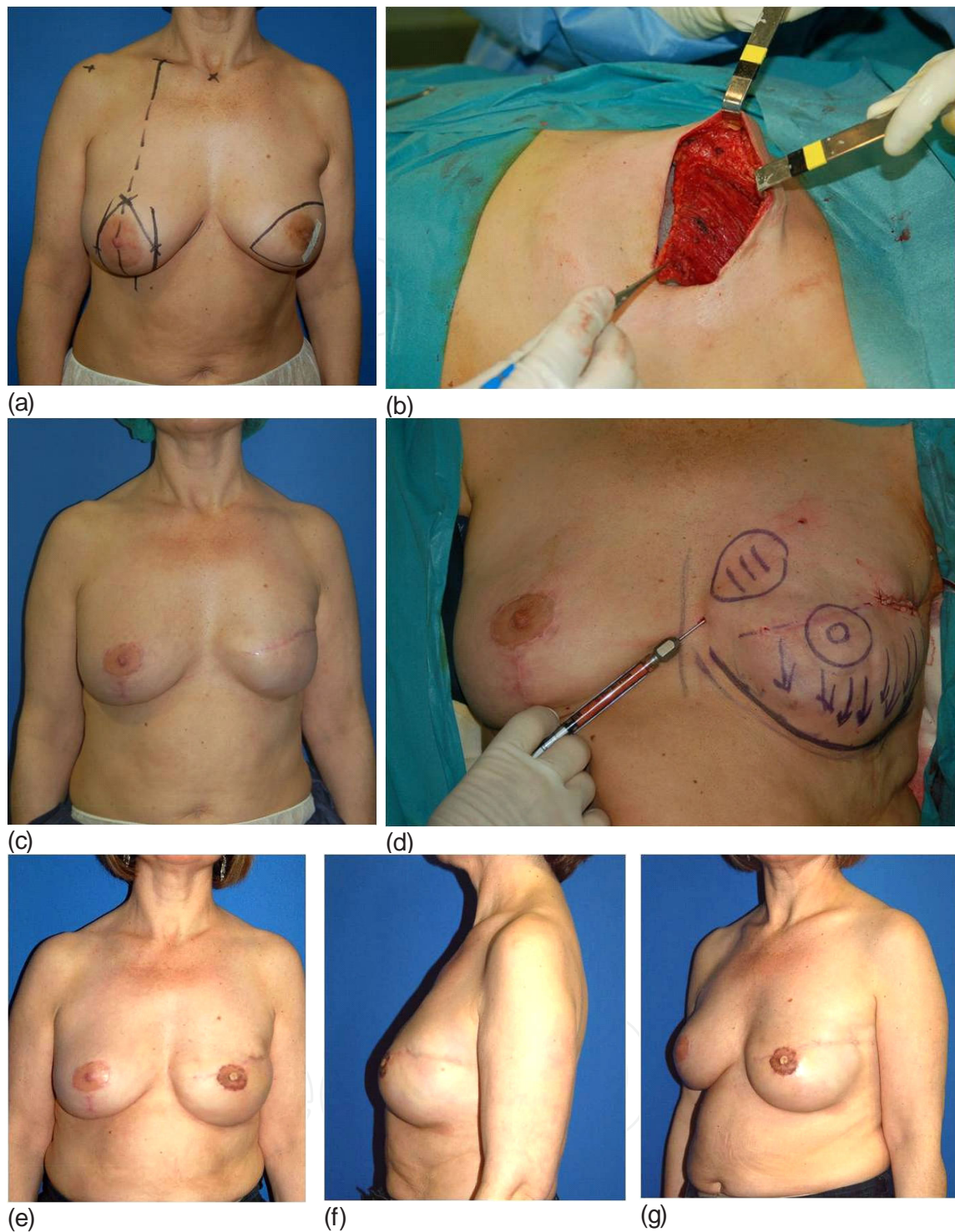


Figure 4. Patient aged 55 in whom a mastectomy was performed in the left breast, with immediate reconstruction with expander, prosthesis and fat grafting: (a) Preoperative frontal view. (b) Once the mastectomy is complete, we partially detach the pectoralis major muscle (c) Frontal view of the patient prior the second stage. (d) Fat grafting. (e) Frontal view 1 year after reconstruction. (f) Lateral view 1 year postoperatively. (g) Oblique view 1 year postoperatively.

retractor [25] we create the submuscular pocket in the upper quadrants and below the subcutaneous plane in the lower quadrants. We place the new fold at the same level as the

contralateral breast. We then put the expander (with integral injection dome) in place and perform the volume increase required without causing damage to the skin. In up to 90% of cases, symmetrical volumes can be achieved between the two breasts in this first stage [26].

Simultaneously, a member of the team collects and prepares the fat. In this first stage we perform fat grafting only in the upper quadrants, injecting fat into the subcutaneous plane and the pectoral muscle.

Second stage

In this second stage, we replace the expander with the final prosthesis through the same incision as in the first stage and after calculating the dimensions of the prosthesis required using sizers.

We reconstruct the NAC and make any cosmetic corrections necessary in the contralateral breast (for example, to the scar formed by breast reduction if this operation has been performed).

In this second stage we inject fat between the capsule and the skin in the lower quadrants, and between skin and muscle and inside the muscle in the upper quadrants, in order to obtain good aesthetic results and to achieve symmetry between the two breasts. We also perform fat grafting of the contralateral breast if necessary: for example, to fill a small vacuum in the upper quadrants.

This injection of fat not only improves symmetry, but to a large extent avoids the formation of a hardened capsule and improves vascularization, skin quality and subcutaneous tissue neof ormation after radiotherapy. It gives the reconstructed breast a very natural appearance and feel. (Fig. 5 A-G).

5. Complications and their management

Expanders and implants

The problems that may occur with the implant (extrusion and the formation of a capsule) are well known. Fortunately, extrusion or complete loss of the implant is rare. To prevent it, we always perform the incision in the lateral third of the mastectomy scar, in the anterior axillary line, so that the weakest point (the incision) does not correspond to the area in which the prosthesis exerts maximum pressure. In addition, the position of the muscle between the scar and the expander and the suture 2 cm from the free edge of the lower mastectomy flap keep the probability of this complication to a minimum. As for the formation of a periprosthetic capsule in the long term, Cordeiro [27] reports a rate of capsule grade III-IV formation of 18% and Alderman [28] a rate of 15%. Similar rates have been reported in other series.

While chemotherapy does not appear to alter the results, radiotherapy is a predisposing factor for the formation of a symptomatic periprosthetic capsule. The use of textured implants and especially the performance of fat grafting reduces this complication even in irradiated patients [1, 3, 8].

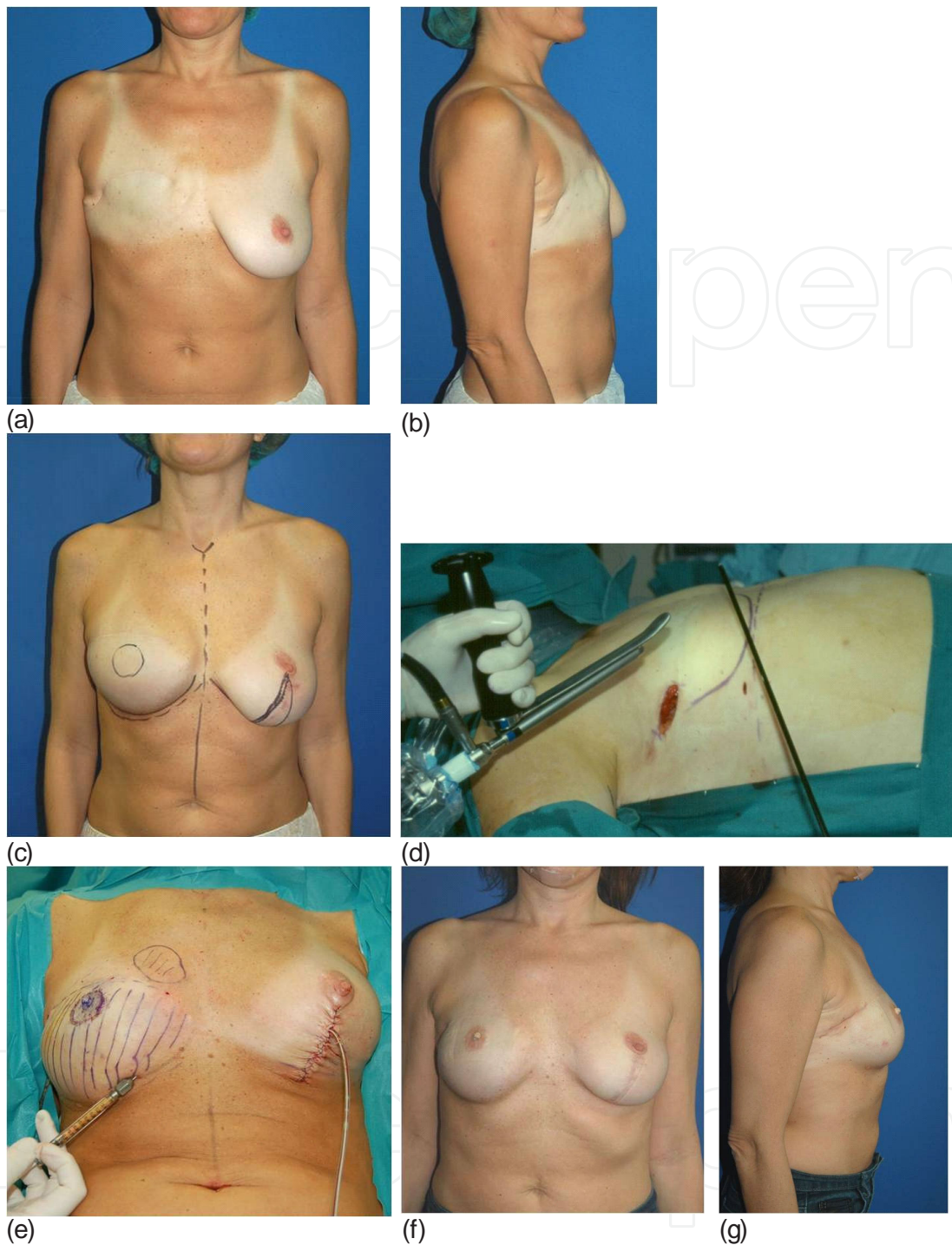

Figure 5. Patient aged 35 in whom a mastectomy was performed in the right breast, with delayed reconstruction with expander, prosthesis and fat grafting. (a) Preoperative frontal view. (b) Lateral view of the mastectomized side. (c) Frontal view of the patient prior the second stage. (d) The expander is inserted by endoscopy through a 4 cm incision in the lateral external third of the mastectomy scar at the level of anterior axillary line. (e) Fat grafting. (f) Frontal view at 1 year after reconstruction. (g) Lateral view of the mastectomized side.

Another possible complication is infection, which has an incidence of between 2% and 9%. In severe cases surgical cleaning, proper antibiotic coverage and implant removal are required.

It is also important to avoid damage to the mastectomy skin flaps, as this may lead to ischemia and partial necrosis of the skin.

Some authors hold that good results in terms of symmetry and naturalness cannot be achieved in unilateral cases. Our experience shows that with the changes we have made to the conventional technique [1, 24, 26] we obtain results that are consistent with the range of satisfaction rates reported by other authors, between 85% and 90%. The detachment of the pectoralis muscle allows proper expansion of the lower quadrants, while in the upper quadrants it produces a very natural inclination. Fat grafting improves the quality of the tissue, thickens the subcutaneous tissue and completes the symmetrization of the two sides. It also enables us to define the cleavage in the upper medial quadrants and the tail of the breast in the lateral quadrants. However, the key to achieving good results in unilateral cases is the correct choice of cosmetic treatment of the healthy contralateral breast.

Fat grafting

The injection of fat in breast surgery is a widely used method with very low complication rates. This is because fat is an autologous material, completely biocompatible, non-migratory and non-teratogenic; the tissue lost is replaced with similar tissue, applying the principle of “replace like with like”.

In spite of the low rate of complications, the surgeon’s experience and familiarity with the technique for obtaining, processing and injecting the fat are key elements for achieving good results.

It should be borne in mind that the fat is handled prior to its implantation and also that the adipose tissue is deprived of vascularization from the moment of extraction until its integration in the receptor tissue, with the result that there is a risk of infection. For this reason, maintaining maximum sterility during the procedure, ensuring asepsis of the area, and subsequent vigilance are all essential. Antibiotic prophylaxis immediately prior to surgery is very useful.

Another possible complication is damage to neighboring structures such as vessels or nerves. For this reason we use blunt cannulas and always before injecting the fat we perform a slight aspiration to ensure that we are not injecting the fat into vessels to avoid the risk of fat embolization.

As surgeons gain experience with these techniques, irregularities or the problems of hypo- and hypercorrection of the defects become less frequent. However, hypocorrection of defects is preferable to hypercorrection, because it can be resolved by further injections.

As in any surgical technique, inflammation or small hematomas will be present in the days immediately after the intervention. In these cases the use of anti-inflammatory drugs, cold therapy or even homeopathy may be helpful.

In the medium to long term calcifications may appear, but they bear no resemblance to the ones produced by tumor growth and are easy to recognize; there may also be oil droplets or fat cysts. If the fat has been injected incorrectly, in large accumulations, areas of necrosis or hardening may appear due to the encapsulation of this ischemic fat. This may cause patients serious concern because, understandably, they attribute it to the tumor.

As regards the area of extraction, it is very important to avoid irregularities. While obtaining the fat the direction of the tunnels should be varied and during the postoperative period drainage and massage should be provided, as after liposuction.

6. Conclusion

Major advances have recently been made in microsurgical reconstruction techniques and in the development of biomaterials for texturized breast implants. The search for improved results requires complementing conventional reconstruction techniques with other procedures. The injection of correctly treated fat helps to overcome the limitations of the various breast reconstruction techniques and achieves a very low complication rate.

By creating an appropriate pocket for the tissue expansion, achieving symmetry in the contralateral breast and injecting fat to palliate the sequelae of the radiotherapy, tissue reconstruction with expanders, prosthesis and fat grafting is a safe method that obtains satisfactory results.

Author details

Jose Ma Serra-Renom¹, Jose Ma Serra-Mestre^{2*} and Francesco D'Andrea³

*Address all correspondence to: jmserramestre@gmail.com

1 Institute of Aesthetic and Plastic Surgery Dr. Serra-Renom Hospital Quiron Barcelona. Universitat Internacional de Catalunya, Spain

2 Department of Plastic Reconstructive and Aesthetic Surgery Second University of Naples, Italy

3 Department of Plastic Reconstructive and Aesthetic Surgery Second University of Naples, Italy

References

- [1] Serra-Renom, J. M, Muñoz-Olmo, J. L, & Serra-Mestre, J. M. Fat grafting in postmastectomy breast reconstruction with expanders and prostheses in patients who have received radiotherapy: formation of new subcutaneous tissue. *Plast Reconstr Surg.* 2010 Jan; 125(1):12-8.

- [2] Serra-Renom, J. M, Muñoz-Olmo, J. L, & Serra-Mestre, J. M. Breast reconstruction with fat grafting alone. *Ann Plast Surg.* 2011 Jun; 66(6):598-601.
- [3] Rigotti G, Marchi A, Galie M, et al. Clinical treatment of radiotherapy tissue damage by lipoaspirate transplant: a healing process mediated by adipose-derived adult stem cells. *Plast Reconstr Surg.* 2007; 119(5):1409–1422.
- [4] Spear SL, Wilson HN, Lockwood MD. Fat injection to correct contour deformities in the reconstructed breast. *Plast Reconstr Surg.* 2005;116:1300–1305.
- [5] Serra-Renom, J. M, Muñoz-Olmo, J. L, & Serra-Mestre, J. M. Treatment of tuberous breasts grade III with puckett's technique (modified) and fat grafting to correct the constricting ring. *Aesthetic Plast Surg.* 2011 Oct; 35(5):773-81.
- [6] Serra-Renom, J. M, Muñoz-Olmo, J. L, & Serra-Mestre, J. M. Endoscopic-assisted aesthetic augmentation of tuberous breasts and fat grafting to correct the double bubble. *Aesthetic Plast Surg.* 2012 (in press).
- [7] Ribuffo D, Atzeni M, Serratore F, et al. Cagliari University Hospital (CUH) protocol for immediate alloplastic breast reconstruction and unplanned radiotherapy. A preliminary report. *Eur Rev Med Pharmacol Sci.* 2011 Jul;15(7):840-4.
- [8] Petit JY, Lohsiriwat V, Clough KB, et al. The oncologic outcome and immediate surgical complications of lipofilling in breast cancer patients: a multicenter study--Milan-Paris-Lyon experience of 646 lipofilling procedures. *Plast Reconstr Surg.* 2011 Aug;128(2):341-6.
- [9] Sarfati I, Ihrai T, Kaufman G, et al. Adipose-tissue grafting to the post-mastectomy irradiated chest wall: preparing the ground for implant reconstruction. *J Plast Reconstr Aesthet Surg.* 2011 Sep;64(9):1161-6.
- [10] Salgarello M, Visconti G, Barone-Adesi L. Fat grafting and breast reconstruction with implant: another option for irradiated breast cancer patients. *Plast Reconstr Surg.* 2012 Feb;129(2):317-29.
- [11] Gutowski KA; ASPS Fat Graft Task Force. Current applications and safety of autologous fat grafts: a report of the ASPS fat graft task force. *Plast Reconstr Surg.* 2009 Jul; 124(1):272-80.
- [12] Padoin, A. V, Braga-Silva, J, Martins, P, et al. Sources of processed lipoaspirate cells: influence of donor site on cell concentration. *Plast Reconstr Surg.* 2008 Aug; 122(2): 614-8.
- [13] Fraser JK, Wulur I, Alfonso Z, et al. Differences in stem and progenitor cell yield in different subcutaneous adipose tissue depots. *Cytotherapy.* 2007, 9:459.
- [14] Keck M, Zeyda M, Gollinger K et al. Local Anesthetics Have a Major Impact on Viability of Preadipocytes and Their Differentiation into Adipocytes. *Plast. Rec. Surg.* 2010, 126:1500.

- [15] Erdim M, Tezel E, Numanoglu A, et al. The effects of the size of liposuction cannula on adipocyte survival and the optimum temperature for fat graft storage: an experimental study. *J Plast Reconstr Aesthet Surg*. 2009, 62:1210.
- [16] Coleman S, Mazzola R. *Fat Injection From Filling to Regeneration*. St Louis, MO: Quality Medical Publishing; 2009.
- [17] Ferraro GA, De Francesco F, Tirino V, et al. Effects of a new centrifugation method on adipose cell viability for autologous fat grafting. *Aesthetic Plast Surg*. 2011 Jun; 35(3):341-8.
- [18] Kurita M, Matsumoto D, Shigeura T, et al. Influences of centrifugation on cells and tissues in liposuction aspirates: optimized centrifugation for lipotransfer and cell isolation. *Plast Reconstr Surg* 2008 Mar;121(3):1033-41; discussion 1042-3
- [19] Matsumoto D, Shigeura T, Sato K, et al. Influences of preservation at various temperatures on liposuction aspirates. *Plast Reconstr Surg*. 2007, 120:1510.
- [20] Carvalho PP, Yu G, Wu X et al. Processing and passing of human adipose-derived stromal/stem cells: use of animal free products and extended storage at room temperature. IFATS proceedings, Dallas, 2010.
- [21] Serra-Renom, J. M, & Fontdevila, J. New marking designs for vertical scar breast reduction. *Aesthet Surg J*. 2004; 24(2):171-5.
- [22] Georgiade NG. *Aesthetic Breast Surgery*. Baltimore. Williams & Wilkins; 1983.
- [23] Graf RM. Reduction mamaplasty and mastopexy using the vertical scar and the thoracic Wall flap technique. *Aesth Plast Surg*. 2003; 27:06-12.
- [24] Serra-Renom, JM , Fontdevila J, Monner J. Mammary reconstruction using tissue expander and partial detachment of the pectoralis major muscle to expand inferior breast quadrants. *Ann Plast Surg*. 2004;53:317–321.
- [25] Serra JM. Retractor with mobile endoscope. *Plast Reconstr Surg*. 1997;100:529–531.
- [26] Serra-Renom, J. M, Guisantes, E, Yoon, T, et al. Endoscopic breast reconstruction with intraoperative complete tissue expansion and partial detachment of the pectoralis muscle. *Ann Plast Surg*. 2007;58:126–130.
- [27] Cordeiro, P. G, & McCarthy, C. M. A single surgeon's 12-year experience with tissue expander/implant breast reconstruction: part I. A prospective analysis of early complications. *Plast Reconstr Surg*. 2006 Sep 15;118(4):825-31.
- [28] Alderman AK, Wilkins EG, Kim HM, et al. Complications in postmastectomy breast reconstruction: Two-year results of the Michigan Breast Reconstruction Outcome Study. *Plast Reconstr Surg*. 109: 2265, 2002.

