

We are IntechOpen, the world's leading publisher of Open Access books Built by scientists, for scientists

4,800

Open access books available

122,000

International authors and editors

135M

Downloads

Our authors are among the

154

Countries delivered to

TOP 1%

most cited scientists

12.2%

Contributors from top 500 universities



WEB OF SCIENCE™

Selection of our books indexed in the Book Citation Index
in Web of Science™ Core Collection (BKCI)

Interested in publishing with us?
Contact book.department@intechopen.com

Numbers displayed above are based on latest data collected.

For more information visit www.intechopen.com



Congenital Aortic Stenosis in Children

Hirofumi Saiki and Hideaki Senzaki

Additional information is available at the end of the chapter

<http://dx.doi.org/10.5772/54806>

1. Introduction

Congenital aortic stenosis (AS) is caused by abnormal morphological development of the aortic valve. [1, 2] Valvular abnormalities may be accompanied by supra- or subvalvular stenosis. The embryogenic process that forms aortic valves begins approximately 31–32 days of gestation. Cavity formation in the basal portion of the truncus arteriosus is a key process in the development of the leaflet and sinus of Valsalva, which are important components of the aortic valve. Therefore, incomplete formation of the cavity causes various morphological abnormalities of the aortic valve, including bicuspid valve with or without commissural fusion, tricuspid valve with commissural fusion, monocuspid valve, and myxomatoid leaflet valve (dysplastic valve). The most frequent type of congenital AS is a bicuspid aortic valve, [3] accounting for approximately 90% of AS cases.

Although the morphological features of the aortic valve are closely associated with the AS severity, the pathophysiology and resultant clinical manifestation of AS are fundamentally determined by the severity of the stenosis (effective orifice area). In this sense, congenital AS in children is classified into 2 major types: severe AS that becomes symptomatic and necessitates interventions during the neonatal period or early infancy and a milder form of AS with signs and/or symptoms that develop later in childhood.

In this chapter, we will outline the pathophysiology, clinical characteristics, and management of congenital AS observed in children (from fetus to adolescence) for each type of AS mentioned above. We will also briefly discuss the differences in ventricular adaptation, which are strongly linked to the clinical manifestation of AS, to the increased afterload caused by AS between children and adults.

2. Pathophysiology of congenital AS

The mechanism underlying the increase in severity of AS in children is similar to that seen in adults. The orifice size can decrease because of increased thickness and rigidity of the valve leaflets, independent of the morphological anomalies of the aortic valve, although native abnormal morphological features have greater impact on the progression of stenosis in children than in adults. The mechanisms underlying the exacerbation of stenosis also need to be determined. Valvular fibrosis, lipid accumulation, [4,5] inflammatory changes, [6] and acquired fibrotic fusion of commissures, which increase cusp thickness/stiffness, [5,7] could also be associated with the development of valvular stenosis, even in childhood AS. Metabolic syndrome is an emerging issue even in children and may be associated with these exacerbating mechanisms, [8] resulting in calcification, which reduces the possibility of valvular plastic surgery. In addition, bicuspid aortic valves possibly develop aortic calcification earlier than tricuspid aortic valves. [9,10] In this section, we will discuss the hemodynamic aspects of aortic stenosis in fetuses, neonates, and children.

2.1. AS with signs and symptoms that develop during the fetal or neonatal period

The fundamental underlying pathophysiology of AS involves an increase in afterload to the left ventricle (LV). The mechanism by which the LV copes with this increase in afterload is an increase of myocardial mass (hypertrophy) to generate a higher force to confront the increased afterload. If the aortic valve stenosis is too severe to allow the LV to become adaptive, LV contractility is depressed and the LV becomes markedly dilated. In this critical condition, the fetal circulation can maintain, to some extent, the systemic output using the right ventricle (RV), because there are interatrial communication (foramen ovale) and ductus arteriosus in the fetal circulation. The ascending aortic flow and sometimes even the coronary arterial flow rely on retrograde blood flow from the ductus arteriosus. However, an LV exposed to massive afterload with relatively reduced coronary blood flow supply is at high risk of progressive ventricular failure, and is associated with an increased risk of sudden cardiac death. If the patient can survive this condition for a certain period, a marked increase in LV end-diastolic pressure (EDP) hinders the blood flow from the left atrium entering into the LV, leading to a gradual reduction of LV cavity volume. This process is postulated as one mechanism of evolving hypoplastic left heart syndrome (HLHS). Degeneration of the endocardium may accompany this process, representing a condition known as endocardial fibroelastosis. [11]

In other cases, an increase in LV afterload may allow the LV to exert its adaptive mechanism of hypertrophy, which also inhibits LV inflow due to increased LV stiffness and resultant EDP rise. [12] This is another form of evolving HLHS physiology (Figure 1A).

Of course, the above pathophysiological mechanisms should be understood as a continuum, [13, 14] and some patients may be born with a markedly dilated LV and depressed contractility, known as critical AS (Figure 1B). Such patients suffer from severe circulatory failure and pulmonary congestion, which is often life threatening and requires emergency intervention, either by catheters or surgery, as discussed below.

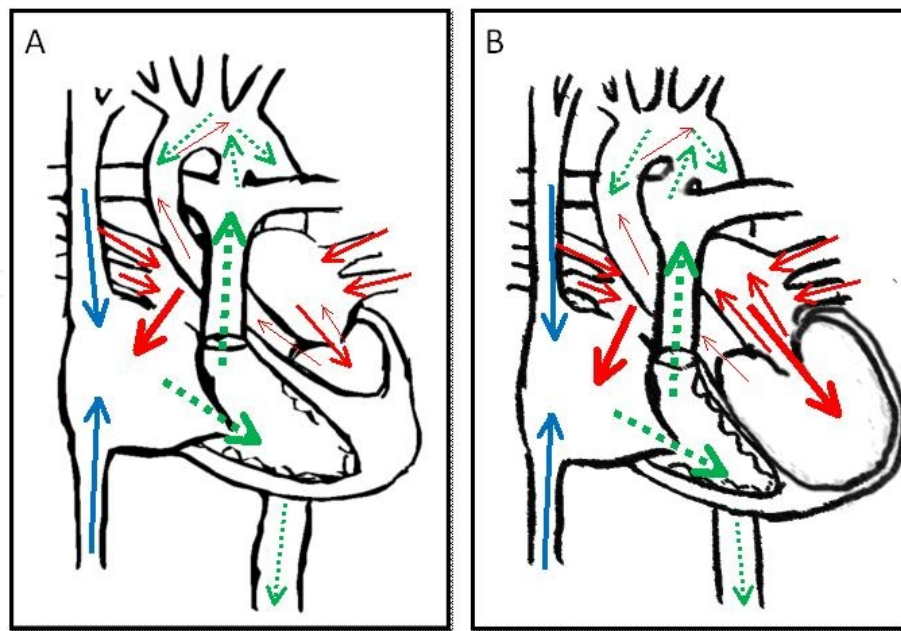


Figure 1. A schema of hypoplastic left heart syndrome (A) and that of critical aortic stenosis (B).

2.2. AS with signs and/or symptoms that develop during late infancy and school age

When the severity of AS is mild such that the LV can cope with the increased afterload, patients present with clinical symptoms during late infancy or school age. Although their LV exhibits hypertrophy, AS may be mild enough in patients such that they will be asymptomatic. There are also a group of patients who had no signs and symptoms other than heart murmur. In general, the aortic valves of this group of patients can supply the systemic blood flow during the neonatal period. This is verified by the fact that the ductus flow during the neonatal period shows left-to-right shunting. The timing of the onset of AS symptoms in this group is dependent on the severity of stenosis that is associated with the LV's capability to exert its adaptive mechanism to increased afterload. Of note, unlike adult onset AS, the severity of AS in children is also influenced by somatic growth, which induces a relative increase in the blood flow through the aortic valve and thereby causes augmentation of LV afterload. In addition, it was reported that an increased pressure gradient across the aortic valve is related to earlier progression of stenosis and a higher frequency of complicating aortic regurgitation. [15, 16] Therefore, the pathophysiology of AS in this age group may be dependent on preload change due to aortic regurgitation as well as the increasing afterload. In the clinical setting, it is important to follow-up with these patients periodically to detect such changes and to determine the appropriate timing and method of treatment. Therefore, we will discuss methods for monitoring the dynamic changes in AS in this particular group of patients in the following section.

2.2.1. Monitoring methods for AS

Clinical symptom evaluation, physical examination, electrocardiogram (ECG), and echocardiography are essential sources for obtaining comprehensive information for appropriate

management of AS in this patient group. If fainting, convulsion, or resuscitated cardiac arrest are observed, relieving AS is indicated for preventing further adverse events. [17, 18] Although angina and syncope are reported to be observed only in <10% of patients whose peak-to-peak pressure gradient is greater than 80 mmHg, chest pain is an important clinical sign indicating the need for intervention, as adverse events are likely to occur within a few years after the complaint of initial chest pain.

ECG examinations are informative if ST-segment changes are observed. Usually, severe AS shows a 0–90°QRS-axis with high voltages in the left precordial leads. However, it is important to note that the above ECG findings of LV hypertrophy do not necessarily reflect the severity of the stenosis. Wagner et al. reported that one-third of AS patients with peak-to-peak pressure gradients greater than 80 mmHg do not exhibit the above LV hypertrophic findings on ECG. [17] In contrast, the ST strain pattern in the left precordial leads is thought to be more specific to LV hypertrophy and reflects the severity of AS (Figure 2).

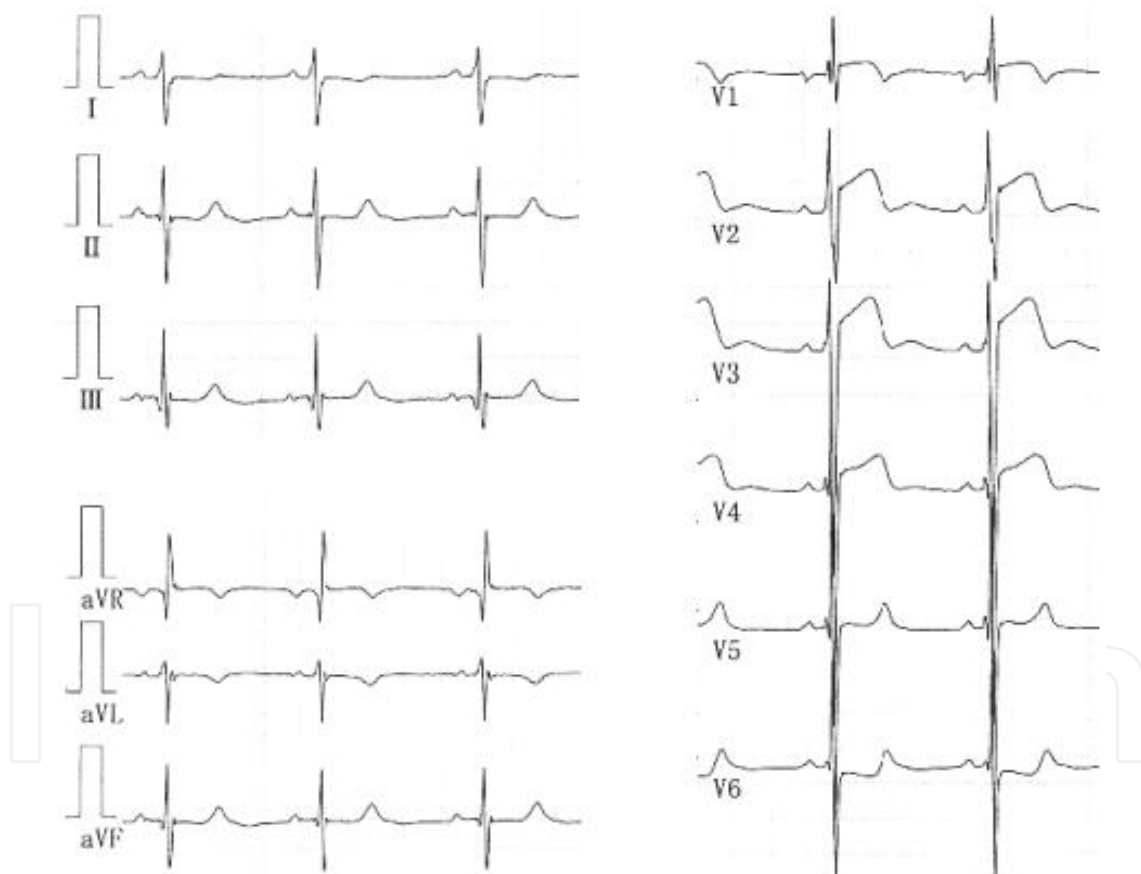


Figure 2. Electrocardiogram of severe aortic stenosis. This is an electrocardiogram (ECG) of a patient with severe aortic stenosis with an estimated pressure gradient of 140mmHg. Surprisingly, ECG shows no prominent finding of left ventricular hypertrophy other than changes in ST-T segment.

Holter ECG is also useful for predicting sudden deaths, even in asymptomatic AS patients. Wolfe et al. reported that multiform ventricular premature contraction, couplet, and ventricular tachycardia are serious arrhythmias that are associated with sudden cardiac death. [19]

Exercise testing may provide more accurate information about the risk of cardiac events than other examinations. Lewis et al. demonstrated the usefulness of exercise testing to identify sub-clinical ischemia in patients with severe AS. [26] Thus, exercise testing and Holter ECG may play a key role in clinician decision making for the management of AS patients.

Echocardiography is a direct method for evaluating the anatomical features and severity of AS. Valvular anatomy can be assessed for leaflet number, balance, thickening, or doming. The annulus diameter is also important, particularly when intervention is indicated. M-mode study in short-axis view provides information regarding LV pressure calculated by Glanz's equation: $LV \text{ systolic pressure} = 225 * LVPWs / LVIDs$, where LVPWs and LVIDs represent LV systolic posterior wall thickness and LV systolic diameter, respectively. [20] This equation is clinically useful, because the peak-to-peak pressure gradient can be evaluated when coupled with the arterial pressure measurement. The LV dimension and wall thickness values provide information regarding the risk of cardiac events and ischemia. In addition, combining an echocardiography study with exercise testing may be useful for predicting a higher risk of cardiac events, even in asymptomatic patients. [21] Velocity measurement by spectral pulse wave and continuous wave Doppler reflects the severity of AS if cardiac function is not impaired. The pressure gradient calculated by applying the Bernoulli equation in the outflow tract is one of the guides for determining the need for intervention, although it has some limitations. [22, 23] Spectral pulse wave Doppler could also be a powerful tool for confirming the localization of obstruction and estimating the valvular area.

The indication for the catheter examination is limited, but this modality provides accurate information regarding coronary arteries and severity of AS. Because the LV outflow tract is truncated, the severity of AS tends to be over-estimated by velocity-derived pressure gradient. In contrast, a precise PIPG as well as a peak-to-peak gradient can be evaluated by the catheter examination (Figure 3). The aortic valve area is also calculated by Gorlin's method. [24]

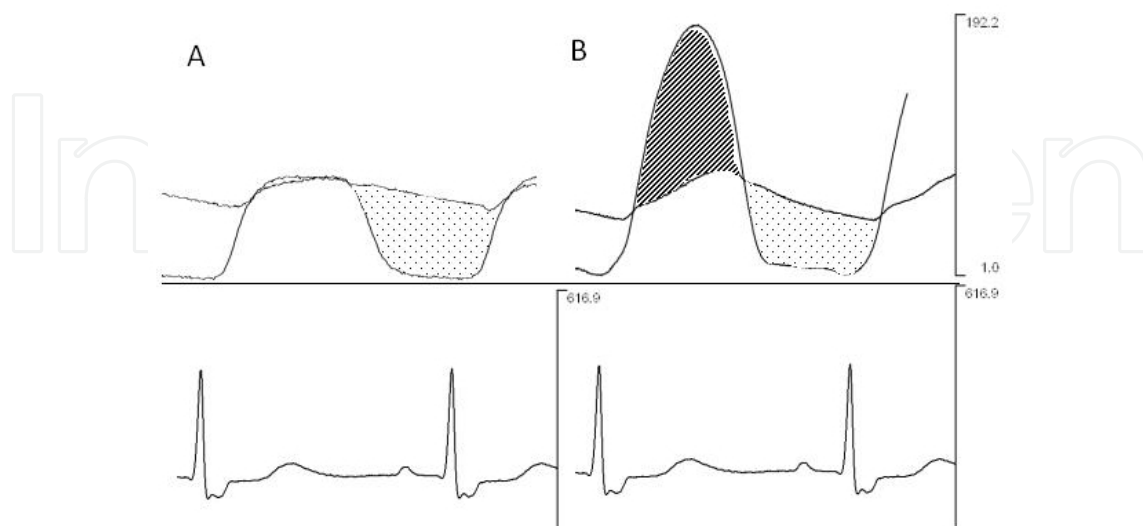


Figure 3. Simultaneous measurements of ascending aortic pressure and left ventricular pressure by the catheter examination. Both instantaneous and peak to peak pressure gradient can be clearly monitored. A; normal, B; aortic stenosis

3. Treatment of AS

3.1. Fetal and neonatal AS

If the patients have an established HLHS circulation with an underdeveloped LV, all the treatment options are directed to the future completion of the Fontan circulation, a final goal for patients with single ventricular circulation. However, if the LV size and components are to be sufficient to generate systemic output when the excessive afterload due to AS is relieved, interventions for the aortic valve per se are indicated, including either catheters or surgery. [25] The most attractive merit of catheter intervention (percutaneous transluminal aortic valvuloplasty [PTAV]) is that it is less invasive. In this procedure, cardiopulmonary bypass, which is a prerequisite for surgical procedures, can be avoided. PTAV is known to accelerate annular growth even in small sized aortic valve [26] if mitral valve stenosis is not complicated [27]. In performing PTAV, the carotid artery is generally used for blood access because lower body hypoperfusion makes it difficult to achieve access from the femoral artery and has a high risk of arterial obstruction with a prolonged sheath insertion, and because the curvature of aortic arch makes it difficult to manipulate the catheter and successfully pass it through the tiny aortic orifice (Figure 4). Therefore, central nervous system damage can be a potential adverse event associated with PTAV. More importantly, PTAV is a procedure used to enlarge the aortic orifice area by tearing the weak portions of the valve, not necessarily in the anatomically proper portion (commissures). Therefore, PTAV cannot be applied to valves with pre-existing aortic regurgitation because the procedure generally worsens this condition, which could be fatal. It was reported that 15% of 113 patients younger than 60 days old who had undergone PTAV developed significant aortic regurgitation. [26] Surgical interventions in this patient group include aortic valve plasty (AVP) and aortic valve replacement (AVR) with the autologous pulmonary artery valve (Ross procedure). The advantage of open AVP is that surgeons can perform the procedure on the basis of a detailed examination of the valve anatomy, which may reduce the risk of aortic regurgitation. Bhabra et al. [28] reported that if the aortic valve is tricuspid, the rate of freedom from reintervention after open AVP was 92% and that of AVR was 100% at a 10-year follow-up. These rates for bicuspid valves were only 33% and 57%, respectively. This report emphasizes the importance of valve morphology as a determinant of outcome following AVP. The other surgical option is the Ross procedure, which is particularly useful when sub/suprastenosis coexists with valvular stenosis (Ross-Konno procedure). The survival rate for the Ross procedure was 77% and rate of freedom from reintervention was 50%, comparable to the results of the Norwood procedure. [29-31] To apply the Ross procedure, autologous graft (pulmonary valve) function is important. Concha et al. reported that the rate of freedom from autograft failure at a 5-year follow-up was 95%, demonstrating a low incidence of autograft failure. [32] However, future pulmonary insufficiency remains as a matter of concern in long-term follow-ups.

We often encounter intermediate cases between established HLHS with underdeveloped LV and potentially normal-sized LV under excessive afterload. In such situations, accurate diagnosis about whether the LV has the potential to generate systemic output after relieving afterload is of primary importance. If the LV is judged to be incapable of generating systemic

output, then the systemic circulation should rely on the RV. In such a case, the Fontan procedure becomes a goal of treatment. Multicenter studies have elucidated that the outcome of biventricular repair with a small LV is much worse than that of the Fontan procedure [13, 14], although the survival rate of Fontan completion for patients with a small LV or severely reduced LV function is only approximately 50-70%, even in the recent reports. [33-35]

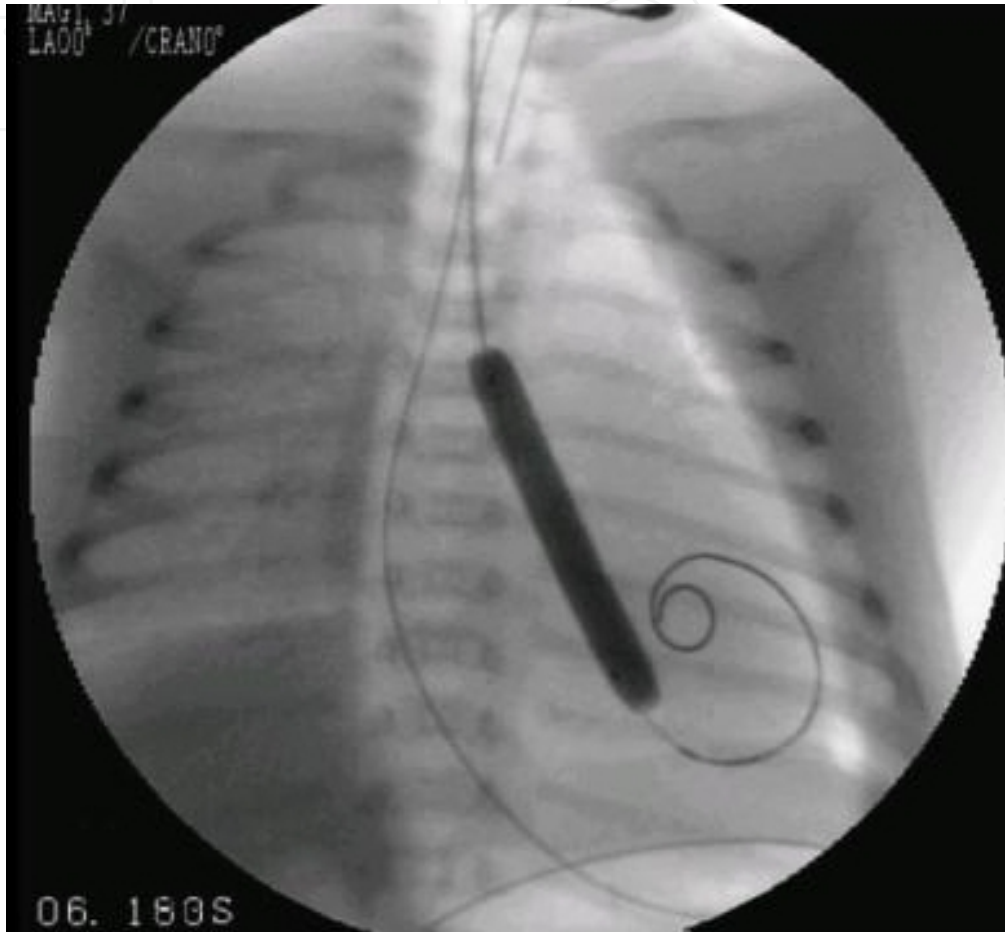


Figure 4. Percutaneous transluminal aortic valvuloplasty performed for a patient with critical aortic stenosis

Based on the pathophysiology of evolving HLHS as previously discussed and the poor survival rate of HLHS patients, fetal intervention has been attempted, aimed at relieving AS at earlier stages before the LV cavity is reduced. For the first time, Maxwell et al. reported their experience of intrauterine balloon dilatation of the fetal aortic valve in 1991. [36] Thereafter, a case series of 12 fetuses that underwent balloon valvuloplasty in the third trimester were reported, with no improvement was observed in their LV growth. [37] Tworetzky et al. also reported the results of fetal intervention for 24 AS patients (ranging from 21 to 29 weeks of gestation) who were thought to have a high probability of developing HLHS. [38] Technical success was achieved in 14 patients, but only 3 patients were able to undergo two-ventricular repair. Therefore, fetal intervention should be regarded as experimental at present, as many issues remain to be solved.

3.2. AS with signs and symptoms that develop during late infancy and school age

The treatment strategy for AS in which signs and/or symptoms develop later in childhood is different from that for neonatal AS. The American College of Cardiology/American Heart Association Guidelines for the management of AS of this group [31] recommended that patients with a peak instantaneous pressure gradient (PIPG) measured by Doppler echocardiography ≥ 70 mmHg be considered for cardiac catheterization and treatment in asymptomatic children and young adults. If the patients desire to participate in competitive sports or become pregnant, a PIPG of 50–70 mmHg is an indication for further evaluation and interventions. If patients have symptoms (angina, syncope, or dyspnea on exertion), a PIPG ≥ 50 mmHg is the indication for treatment. If the PIPG is less than 50 mmHg and a symptom is present, another origin of the symptom should be investigated.

There are several treatment options for cases in which intervention is indicated, including PTAV, open AVP, the Ross procedure, and AVR. Procedure selection is primarily dependent upon whether the patient's somatic size (aortic annular size) is large enough to use a prosthetic valve, because AVR is considered as the first-line procedure at present. If the prosthetic valve is not available, procedures other than AVR are selected so that patients can live with their own valve until they can use a prosthetic aortic valve. In such situations, the most important concept for treatment is that the procedure should be regarded as a bridge to AVR. Therefore, the aim of any intervention should be to reduce the afterload without any significant aortic regurgitation so that patients can grow uneventfully until AVR can be performed. In this sense, if these patients do not have heart failure but have exertion-induced ischemic signs, restriction of exercise without invasive intervention may be selected to achieve a better outcome. Application of PTAV in this age group is relatively limited because AVP is thought to be better than PTAV in terms of preserving aortic valve function, [39, 40] and because aortic insufficiency caused by valvuloplasty is known to be progressive in nature. [15, 16] However, some patients may still benefit from PTAV to achieve the therapeutic goal in this AS group. The Ross procedure is also not regarded as a definitive repair surgery, because neo-aortic regurgitation and pulmonary insufficiency are frequently observed postoperative complications, which require further interventions in the future. [40, 41] Therefore, the Ross procedure indication is limited to patients who cannot grow due to severe aortic insufficiency.

4. The hemodynamic effects of AS on ventricular function in children

In this last section, we briefly comment on the differences in LV geometric and functional changes between adult- and child-onset of AS. The natural history of LV geometric and functional changes in adult-onset AS is characterized by LV concentric hypertrophy in the early stage, followed by diastolic dysfunction, systolic dysfunction with eccentric hypertrophy, and heart failure at the end-stage. [42] Most of the patients who are candidates for surgical intervention are ranked in the state between diastolic and systolic ventricular dysfunction. Delayed relaxation characterizes early-stage ventricular diastolic dysfunction, and thus is observed in almost all AS patients, [43] while increased diastolic stiffness is observed in more

advanced stages in which LV hypertrophy and fibrosis may coexist. The degree of diastolic dysfunction is important for predicting prognosis because it takes years to achieve reverse remodeling of diastolic function after normalization of afterload. [44]

In contrast to the relatively uniform geometric and functional LV changes observed in adult-onset AS, such changes in children's AS are diverse and somewhat different from those of adults. The difference primarily stems from the diversity of the initial impact of afterload on the LV. Because adult onset of AS is largely due to a bicuspid valve or atherosclerotic change with aging, AS gradually increases LV afterload. This allows the LV to confront the increased afterload by inducing hypertrophic changes. However, the severity of AS that initially imposes afterload on the LV is diverse in children, as previously discussed, thus excessive afterload may not allow the LV to become hypertrophic, resulting in LV dilation and systolic dysfunction as observed in critical AS. With increasing age, the LV geometry and function gradually resembles those of adult AS: a hypertrophic LV with diastolic dysfunction. However, it is rare in children to observe a marked increase in LV diastolic stiffness, even in cases of hypertrophic LV (Figure 5). In addition, it is interesting that LV relaxation appears to be relatively preserved in children with AS and hypertrophic LV. These differences in LV functional responses between children and adults may have a clue to a better management of patients with AS.

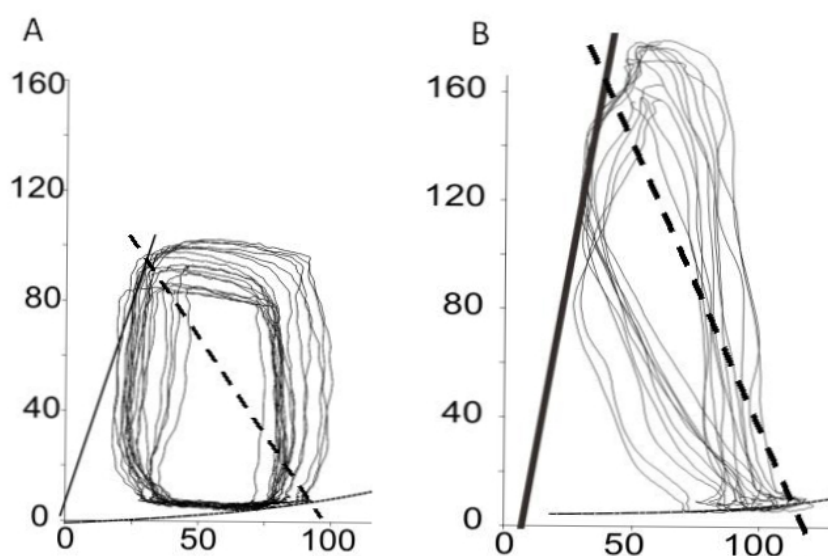


Figure 5. Examples of left ventricular pressure-volume relationships in a control patient (A) and a patient with aortic stenosis (B). The steep slope of the end-systolic pressure-volume relationship (solid line) and arterial elastance (dashed line) indicate increased ventricular contractility and afterload. Note that the slope of the end-diastolic pressure-volume relationship in aortic stenosis is comparable to that of control.

5. Conclusions

In adults, AS generally develops slowly, with the progression of valve calcification or leaflet degeneration being independent of the existence of substrates for congenital abnormalities.

This allows the LV to adapt to the increased afterload by becoming concentrically hypertrophied. Therefore, it takes a long time before LV systolic function is severely impaired and critical events occur.⁴⁵ Because valvular calcification is a commonly observed morphological change and because a prosthetic valve is generally available for adults, aortic valve replacement is selected as a first-line treatment and plastic surgery is seldom chosen for this population. Thus, the treatment strategy is rather straightforward.

In contrast, as discussed in this chapter, a wide range of clinical phenotypes is seen in pediatric AS. Depending on the severity of the native aortic valve abnormality and associated hemodynamic features, AS could be one of the most severe forms of congenital heart defects in children, leading to a critical condition in neonates or even during fetal life. In the milder form of pediatric AS, no clinical symptoms are seen throughout the patient's life. Therefore, the complexity of the treatment approach depends upon the patient's age, body size, and associated cardiac anomalies. In particular, because of the limited availability of prosthetic aortic valves for small children, the native valve morphological features constitute an extremely important determinant of treatment strategy. A detailed assessment of LV function as well as accurate anatomical diagnosis, including analysis of the potential utility of the native aortic valve, is essential for achieving a better outcome for patients. The use of specific medications [46] and prevention of metabolic syndrome from childhood may help improve outcomes.

Accumulation of information regarding the outcomes of underdeveloped valves, detailed mechanisms underlying disease progression, surgical outcomes, and improvements in surgical techniques should lead to considerably improved outcomes in the pediatric population.

Author details

Hirofumi Saiki and Hideaki Senzaki*

Department of Pediatric Cardiology, Saitama Medical Center, Saitama Medical University, Saitama, Japan

References

- [1] Falcone, M. W, Roberts, W. C, & Morrow, A. G. Perloff JK: Congenital aortic stenosis resulting from a unicommissural valve. Clinical and anatomic features in twenty-one adult patients. *Circulation* (1971).
- [2] Aortic Stenosis In Moss's Heart disease in infants, Children, and adolescents, Baltimore The Lippincott Williams and Wilkins Co. (2001).
- [3] Michelena, H. I, Desjardins, V. A, & Avierinos, J. F. Natural history of asymptomatic patients with normally functioning or minimally dysfunctional bicuspid aortic valve in the community. *Circulation* (2008).

- [4] Palta, S, Pai, A. M, & Gill, K. S. Pai RG: New insights into the progression of aortic stenosis: implications for secondary prevention. *Circulation* (2000).
- [5] Pohle, K, Maffert, R, & Ropers, D. Progression of aortic valve calcification: association with coronary atherosclerosis and cardiovascular risk factors. *Circulation* (2001).
- [6] Olsson, M, Dalsgaard, C. J, Haegerstrand, A, Rosenqvist, M, & Ryden, L. Nilsson J: Accumulation of T lymphocytes and expression of interleukin-2 receptors in nonrheumatic stenotic aortic valves. *J Am Coll Cardiol* (1994).
- [7] Parolari, A, Loardi, C, & Mussoni, L. Nonrheumatic calcific aortic stenosis: an overview from basic science to pharmacological prevention. *Eur J Cardiothorac Surg* (2009).
- [8] Capoulade, R, Clavel, M. A, & Dumesnil, J. G. Impact of metabolic syndrome on progression of aortic stenosis: influence of age and statin therapy. *J Am Coll Cardiol* (2012).
- [9] Pomerance A: Pathogenesis of aortic stenosis and its relation to age. (1972). *Br Heart J*.
- [10] Hope, M. D, Urbania, T. H, Yu, J. P, & Chitsaz, S. Tseng E: Incidental aortic valve calcification on CT scans: significance for bicuspid and tricuspid valve disease. *Academic radiology* (2012).
- [11] Mcelhinney, D. B, Vogel, M, & Benson, C. B. Assessment of left ventricular endocardial fibroelastosis in fetuses with aortic stenosis and evolving hypoplastic left heart syndrome. *Am J Cardiol* (2010).
- [12] Mcelhinney, D. B, Marshall, A. C, & Wilkins-haug, L. E. Predictors of technical success and postnatal biventricular outcome after in utero aortic valvuloplasty for aortic stenosis with evolving hypoplastic left heart syndrome. *Circulation* (2009).
- [13] Lofland, G. K, Mccrindle, B. W, & Williams, W. G. Critical aortic stenosis in the neonate: a multi-institutional study of management, outcomes, and risk factors. Congenital Heart Surgeons Society. *J Thorac Cardiovasc Surg* (2001).
- [14] Jacobs, J. P, Mavroudis, C, & Jacobs, M. L. Lessons learned from the data analysis of the second harvest ((1998). of the Society of Thoracic Surgeons (STS) Congenital Heart Surgery Database. *Eur J Cardiothorac Surg* 2004, 26(1):18-37.
- [15] Eroglu, A. G, Babaoglu, K, & Saltik, L. Echocardiographic follow-up of congenital aortic valvular stenosis. *Pediatr Cardiol* (2006).
- [16] Davis, C. K, Cummings, M. W, & Gurka, M. J. Gutgesell HP: Frequency and degree of change of peak transvalvular pressure gradient determined by two Doppler echocardiographic examinations in newborns and children with valvular congenital aortic stenosis. *Am J Cardiol* (2008).
- [17] Wagner, H. R, Weidman, W. H, & Ellison, R. C. Miettinen OS: Indirect assessment of severity in aortic stenosis. *Circulation* (1977). Suppl):I, 20-3.

- [18] Wagner, H. R, Ellison, R. C, Keane, J. F, & Humphries, O. J. Nadas AS: Clinical course in aortic stenosis. *Circulation* (1977). Suppl):I, 47-56.
- [19] Wolfe, R. R, Driscoll, D. J, & Gersony, W. M. Arrhythmias in patients with valvar aortic stenosis, valvar pulmonary stenosis, and ventricular septal defect. Results of hour ECG monitoring. *Circulation* (1993). Suppl):I89-101., 24.
- [20] Glanz, S, Hellenbrand, W. E, & Berman, M. A. Talner NS: Echocardiographic assessment of the severity of aortic stenosis in children and adolescents. *Am J Cardiol* (1976).
- [21] Lancellotti, P, Lebois, F, Simon, M, Tombeux, C, & Chauvel, C. Pierard LA: Prognostic importance of quantitative exercise Doppler echocardiography in asymptomatic valvular aortic stenosis. *Circulation* (2005). Suppl):I, 377-82.
- [22] Little, S. H, & Chan, K. L. Burwash IG: Impact of blood pressure on the Doppler echocardiographic assessment of severity of aortic stenosis. *Heart* (2007).
- [23] Giardini, A. Tacy TA: Pressure recovery explains doppler overestimation of invasive pressure gradient across segmental vascular stenosis. *Echocardiography* (2010).
- [24] Gorlin, R. Gorlin SG: Hydraulic formula for calculation of the area of the stenotic mitral valve, other cardiac valves, and central circulatory shunts. I. *Am Heart J* (1951).
- [25] Mccrindle, B. W, Blackstone, E. H, & Williams, W. G. Are outcomes of surgical versus transcatheter balloon valvotomy equivalent in neonatal critical aortic stenosis? *Circulation* (2001). Suppl 1):I, 152-8.
- [26] Mcelhinney, D. B, Lock, J. E, Keane, J. F, & Moran, A. M. Colan SD: Left heart growth, function, and reintervention after balloon aortic valvuloplasty for neonatal aortic stenosis. *Circulation* (2005).
- [27] Han, R. K, Gurofsky, R. C, & Lee, K. J. Outcome and growth potential of left heart structures after neonatal intervention for aortic valve stenosis. *J Am Coll Cardiol* (2007).
- [28] Bhabra, M. S, Dhillon, R, & Bhudia, S. Surgical aortic valvotomy in infancy: impact of leaflet morphology on long-term outcomes. *Ann Thorac Surg* (2003).
- [29] Shinkawa, T, Bove, E. L, Hirsch, J. C, & Devaney, E. J. Ohye RG: Intermediate-term results of the Ross procedure in neonates and infants. *Ann Thorac Surg* (2010). discussion 32.
- [30] Hansen, J. H, Petko, C, Bauer, G, Voges, I, & Kramer, H. H. Scheewe J: Fifteen-year single-center experience with the Norwood operation for complex lesions with single-ventricle physiology compared with hypoplastic left heart syndrome. *J Thorac Cardiovasc Surg* (2012).
- [31] Feinstein, J. A, Benson, D. W, & Dubin, A. M. Hypoplastic left heart syndrome: current considerations and expectations. *J Am Coll Cardiol* (2012). Suppl):S, 1-42.
- [32] Concha, M, Aranda, P. J, & Casares, J. The Ross procedure. *Journal of cardiac surgery* (2004).

- [33] Feinstein, J. A, Benson, D. W, & Dubin, A. M. Hypoplastic left heart syndrome: current considerations and expectations. *J Am Coll Cardiol*, 59(1 Suppl):S, 1-42.
- [34] Graham, E. M, Zyblewski, S. C, & Phillips, J. W. Comparison of Norwood shunt types: do the outcomes differ 6 years later? *Ann Thorac Surg*, , 90(1), 31-5.
- [35] Photiadis, J, Sinzobahamvya, N, & Hraska, V. Asfour B: Does bilateral pulmonary banding in comparison to norwood procedure improve outcome in neonates with hypoplastic left heart syndrome beyond second-stage palliation? A review of the current literature. *Thorac Cardiovasc Surg*, , 60(3), 181-8.
- [36] Maxwell, D, & Allan, L. Tynan MJ: Balloon dilatation of the aortic valve in the fetus: a report of two cases. *Br Heart J* (1991).
- [37] Kohl, T, Sharland, G, & Allan, L. D. World experience of percutaneous ultrasound-guided balloon valvuloplasty in human fetuses with severe aortic valve obstruction. *Am J Cardiol* (2000).
- [38] Tworetzky, W, Wilkins-haug, L, & Jennings, R. W. Balloon dilation of severe aortic stenosis in the fetus: potential for prevention of hypoplastic left heart syndrome: candidate selection, technique, and results of successful intervention. *Circulation* (2004).
- [39] Rehnstrom, P, Malm, T, & Jogi, P. Outcome of surgical commissurotomy for aortic valve stenosis in early infancy. *Ann Thorac Surg* (2007).
- [40] Miyamoto, T, Sinzobahamvya, N, & Wetter, J. Twenty years experience of surgical aortic valvotomy for critical aortic stenosis in early infancy. *Eur J Cardiothorac Surg* (2006).
- [41] Williams, I. A, Quaegebeur, J. M, & Hsu, D. T. Ross procedure in infants and toddlers followed into childhood. *Circulation* (2005). Suppl:I, 390-5.
- [42] Lund, O, Flo, C, & Jensen, F. T. Left ventricular systolic and diastolic function in aortic stenosis. Prognostic value after valve replacement and underlying mechanisms. *Eur Heart J* (1997).
- [43] Murakami, T, Hess, O. M, Gage, J. E, & Grimm, J. Krayenbuehl HP: Diastolic filling dynamics in patients with aortic stenosis. *Circulation* (1986).
- [44] Villari, B, Vassalli, G, Monrad, E. S, Chiariello, M, & Turina, M. Hess OM: Normalization of diastolic dysfunction in aortic stenosis late after valve replacement. *Circulation* (1995).
- [45] Rosenhek, R, Binder, T, & Porenta, G. Predictors of outcome in severe, asymptomatic aortic stenosis. *N Engl J Med* (2000).
- [46] Leskela, H. V, Vuolteenaho, O, & Koivula, M. K. Tezosentan inhibits uptake of proinflammatory endothelin-1 in stenotic aortic valves. *J Heart Valve Dis* (2012).

