

# We are IntechOpen, the world's leading publisher of Open Access books Built by scientists, for scientists

4,800

Open access books available

122,000

International authors and editors

135M

Downloads

Our authors are among the

154

Countries delivered to

TOP 1%

most cited scientists

12.2%

Contributors from top 500 universities



WEB OF SCIENCE™

Selection of our books indexed in the Book Citation Index  
in Web of Science™ Core Collection (BKCI)

Interested in publishing with us?  
Contact [book.department@intechopen.com](mailto:book.department@intechopen.com)

Numbers displayed above are based on latest data collected.  
For more information visit [www.intechopen.com](http://www.intechopen.com)



---

# Evolution of Surgical Approaches for Lung Resection

---

Trevor Williams and Wickii T. Vigneswaran

Additional information is available at the end of the chapter

<http://dx.doi.org/10.5772/56641>

---

## 1. Introduction

Early surgical interventions were highly morbid, painful and deadly. Understanding of antisepsis, after Lister's first report in 1867 and development of anesthetic techniques, in particular chloroform and ether made way for early successful surgical intervention. Thoracic surgery and lung resection, however, proved more difficult to advance than other surgical specialties due to the problem of pneumothorax. The principles of intra-thoracic and intra-pleural surgery developed during the early 20th century with significant progress in a short time.

Lung surgery prior to the late 1800's was largely rare reports of draining deep abscesses, resecting prolapsing gangrenous tissue after trauma and resecting portions of the chest wall with small segments of accompanying lung. Tuffier performed the first partial lung resection that consisted of placing a ligature on the lung, excising and suturing the lung to the periosteum.[1], [2] Initial works demonstrating the feasibility of lung resection came from extensive animal experimentation. Block of Danzig described many lung resections in rabbits and dogs. The animals survived surgery and returned to health. The problem of pneumothorax however plagued the operative and the post-operative period. Positive pressure ventilation was not immediately seen as a solution to advance intra-thoracic surgery and those who did use it were divided between the use of face-masks, intra-pharyngeal and endotracheal insufflation. Sauerbruch, in Germany, with the support of the internationally acclaimed Von Mikulicz, persisted for many years operating in expensive negative pressure chambers. He pioneered the first tank ventilator in 1907, allowing surgeons to operate on an open thorax with the patient's head and anesthesiologist literally in another room. Surgery in the US, less hindered by the negative pressure camp, was quicker to adopt endotracheal intubation, the use of bellows and ultimately endobronchial lung isolation ventilation. Negative pressure was used extensively however and persisted through the polio epidemic until the late 1930's.[2], [3]

Lung surgery developed and progressed because of chronic infections of the lung and pleura particularly tuberculosis and bronchiectasis. Lilienthal described the plight of his patients in 1922[4]:

Occasionally an individual coughs his way through life - never a long one - and manages to exist as a semi-invalid, with copious foul expectoration no medicine can control, being a handicap difficult to bear. Patients have even threatened suicide if refused the chance for cure by operation, though they knew the danger was great.

The stethoscope existed from the early 1800's making some diagnosis possible. Higher level of precision and certainty regarding surgical intervention became possible with the advent X-Ray by Röntgen's in 1895. This was quickly taken up by the medical field and the first chest X-ray was performed in 1896.

Gluck from Germany is credited with the first lobectomy in 1907. Morrision Davies reported a landmark lobectomy in 1912 describing individual vessel and bronchial ligation much like we do today but his technique was not followed for some twenty years. It was believed at that time that bronchial stump healing was dependent on the amount of peribronchial tissue remaining after resection and mass ligation was the preferred method.[1] The lung resection was performed in stages as illustrated. The first operation consisted of rib resection without entering the pleura, as done by Robinson at the Massachusetts General Hospital in 1917. Abrading the pleura during the first operation was common to help adhesions form and prevent a pneumothorax during the second operation. A week later the pleura is entered and the lobe resected if the patient tolerated. The bronchus and vasculature were clamped en-mass, transfixed with a suture or left with a clamp in place to be removed a week later. Peri-operative mortality was about 50%. Getting out of the operating room was often an urgency given cyanosis from large amounts of purulent sputum. The diseased lung could be left in place and allowed to slough. The diseased bronchial stump would likely open regardless. Infection was expected post-operatively, packs were left in the chest and wounds granulated in over months.

Samuel Robinson's presidential address to the American Association of Thoracic surgery in 1923 was very telling:

The danger of pneumothorax in wide operation on the human thorax has been dispelled...since the development of the differential pressure apparatus...(regarding bronchiectasis) The patient is placed on the operating table...There may be cyanosis...evacuation of large amounts of pungent, purulent sputum...the pleura is no sooner opened... the need for general anesthesia is obvious...The lower lobe obstinately resists being delivered, the pleural adhesions are strong and widespread... ropelike and tenacious... work with a knife and scissors is blind... the patient's condition may become distressing...then the difficulties multiply. The complete liberating at one setting may have to be abandoned. Tight closure of the chest without drainage seems inadvisable under such conditions, and yet necessary to avoid the ills of post-operative pneumothorax. Suddenly it seems time to return the patient to his bed. Not much has been accomplished... The intra-thoracic pressure has been so altered; the lung expansion is further minimized. Then come the dangers of pleural infection, later in convalescence. There is more operating to do... Nevertheless, we have obtained cures.[1]

Brunn published a landmark paper in 1929 on one stage lobectomy. He described the concept of early lung expansion using closed suction drainage. Local anesthesia was used, phrenicotomy, cautery for lung and air testing. He emphasized an airtight closure to allow lung expansion but used a clamp on the pedicle, which caused necrosis and ultimately a bronchopleural fistula with empyema. The argument at the time was that the expanded lung restricted the space into which the empyema would fill allowing it and the subsequent fistula to more easily be controlled and permit an easier recovery.[3],[5]

Nissen performed his first pneumonectomy in 1931 using a staged technique. In 1932 Shensstone & Janes published an article delineating their experience with 14 operations, five fistula and three deaths. They emphasized not crushing the hilum to preserve the bronchial blood supply, catgut (not silk which could harbor infection) to close the bronchus and suturing the stump to the undersurface of the remaining lobe. The phrenic nerve was crushed and an underwater drain used. Tourniquets and snares were subsequently developed and became common operating equipment.[1], [2], [6] Evarts Graham performed the first single stage pneumonectomy for lung cancer in 1933. He used cautery liberally during his operations reporting somewhat lower mortality in the 20% range.

By the end of the 1930's dissection technique was established. Kent and Blades and Belsey and Churchill delineated the anatomy for lobar and segmental resection. A landmark article in 1940 by Kent and Blades is said to have set the stage for the future of thoracic surgery and the segment, rather than the lobe, was proposed to be the new unit of the lung.[3], [7] Overholt described the intersegmental vein for a plane of dissection and he emphasized the utility of suction over simply underwater drainage.[3] Tumors involving or approaching major airways precluded lesser resections. The lower lobe would be sacrificed for large upper lobe tumors or bronchial tumors. Price-Thomas performed the first sleeve lobectomy in 1947. Since that time all matter of bronchial and arterial reconstructions evolved to preserve lung tissue.[8] Regarding completeness of cancer treatment, now we know sleeve lobectomy has 5-year survival rates better than pneumonectomy with improved quality adjusted life years as determined by decision analysis.[9]

The use of the surgical stapler became common in the 1950's and 60's. Initially, a Russian stapler with a single row of staples oriented parallel to the bronchus was replaced with two rows of staggered staples oriented perpendicularly to the bronchus. Though not eliminating bronchial fistula, stapling was found to be superior to suture techniques in closure of bronchus. It also permitted less sacrifice of lung parenchyma and decreased blood loss.[10]

## 2. Current practice

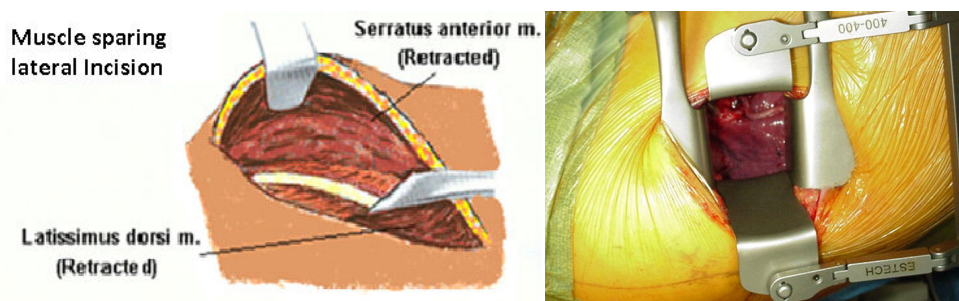
The classic postero-lateral thoracotomy, as practiced until recently, provides excellent access to the thoracic cavity but involves transecting the latissimus and serratus muscles and subperiosteal rib resection. With increasing application of thoracic surgery, younger more active patients and improved peri-operative pain control, reduced morbidity became increasingly important.[11] With improved survival, improving quality of life and early return to full

activity became very important. Post-thoracotomy syndrome, defined as post-operative pain lasting greater than two months, occurred in 50% of thoracotomies. Interventions to reduce this in the immediate post-operative period include modifications in surgical technique and, among others, the use of epidural catheters, which has shown improvement in long-term pain relief. Early post-operative pain control helps clear secretions, maintain lung function and reduce complication.[12]

A myriad of thoracic incisions developed, the widely used posterolateral thoracotomy has been modified to decrease the length, reduce the amount of muscle disrupted and protect the intercostal nerves all with varying amounts of patient benefit in terms of improved pain control, lung function and shoulder strength.[13], [14] Alternative incisions include the sternotomy, the clamshell incision, axillary and anterior thoracotomies. Median sternotomy allows access to the majority of both thoracic cavities. Proposed by Cooper, they discovered during cadaver dissection that after division of the pulmonary ligament the vast majority of the lung can be resected. This was ideal for the increasing numbers of patients found to have resectable pulmonary metastasis bilaterally. Only the left lower lobe was felt to be a less ideal operative field because of the need for retracting the heart. Post-sternotomy patients recovered peak airflow and vital capacity significantly sooner when compared to posterolateral thoracotomy patients.[15]

The clamshell incision was championed by Bains. Bilateral submammary anterior thoracotomies and a transverse sternotomy performed in the supine position are referred to as the clamshell incision. This is useful for bilateral pulmonary disease, extensive lung tumors involving the mediastinum and large mediastinal tumors. Sternotomy is felt to be more limiting for centrally and posteriorly located tumors that are accessible by clamshell. The hemiclamshell involves a unilateral anterior thoracotomy with sternal extension. The inner half of the clavicle can be removed with extension of the incision laterally for a trapdoor incision.[16]

Distortion of normal anatomy and division of muscles was thought to be an important contributor to post-operative morbidity and therefore muscle sparing techniques were developed. Bethencourt & Holmes developed the muscle sparing posterolateral thoracotomy. The incision begins 2cm anterior to the latissimus and ends 2 cm posterior and inferior to the tip of the scapula. The latissimus is dissected from the subcutaneous tissues and the serratus. The posterior boarder of the serratus is divided from its fascia and underlying tissues. The serratus is retracted forward, the latissimus posteriorly and the fourth to the seventh interspace may be chosen for entry into the chest cavity (Figure 1). Excessive subcutaneous flap elevation leads to seromas which caused these authors to place drains routinely. It is anecdotally reported that patients had less pain, improved arm motion and earlier ambulation.[17] Ginsberg preferred a vertical incision, or vertical axillary throacotomy, which requires no creation of subcutaneous flaps and is made in the midaxillary line. The latissimus and serratus are similarly elevated and retracted. The exposure takes the shape of a square rather than a parallelogram, which can cause some difficulty inserting staplers or suturing. Patients are said to be pain free and the cosmetic outcome superior.[18]

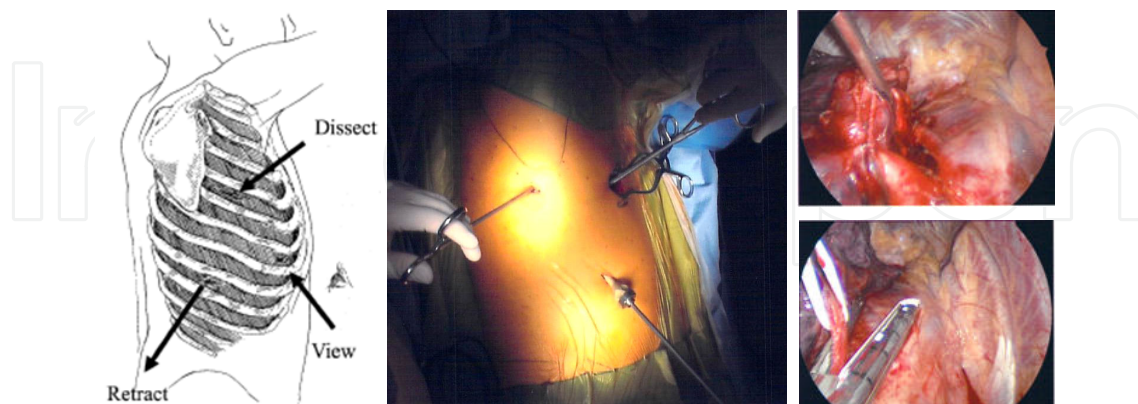


**Figure 1.** Muscle sparing lateral thoracotomy. The cartoon illustrates the preservation and retraction of the serratus anterior muscle and latissimus dorsi muscle, exposing the intercostal space. The incision provides excellent exposure to hilar structures and allows complex lung resections.

Physiologic studies demonstrate improvements in maximal inspiratory/expiratory pressure at three months, lesser degrees of intercostal nerve impairment and improved shoulder function with muscle sparing techniques.[14], [19], [20] Prospective studies comparing muscle sparing and muscle splitting thoracotomies did not find differences in immediate or longer term post-operative pain or physical function.[19], [21] Notably adequate epidural anesthesia was provided in these trials. It is postulated that the intercostal nerves are the primary source of pain related to thoracotomy and efforts to spare these nerves the intercostal sutures has been rigorously studied. This is done by dissection of the intercostal neurovascular bundle or the entire muscle off of the undersurface of the superior rib to be closed and or drilling/suturing through the ribs, to avoid any nerve compression/trauma. With these steps pain scores and analgesic requirements were reported to be significantly less compared to conventional methods.[13], [14]

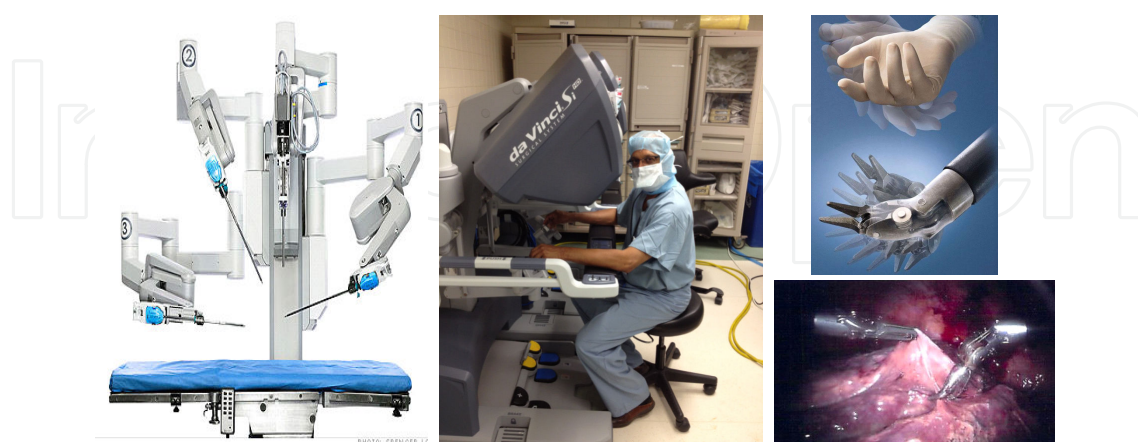Building on the concept improving patient outcomes, surgery in general has moved towards less invasive with the help of video technology. Video assisted thoracoscopic surgery (VATS) is the thoracic variant. Much smaller incisions through which a camera and longer instruments enter allow surgeons to perform lung resections of the same quality as open techniques. Thoracoscopy has its roots in the early 20th century when Jacobaeus in Stockholm used a modified cystoscope for a tuberculosis effusion. He used a two port technique to perform adhesiolysis - primarily to allow collapse therapy for tuberculosis treatment.<sup>3</sup> With high resolution video equipment for endoscopic viewing in combination with single lung ventilation and endoscopic stapling VATS exploded in the 1990s. Two to four 5-10 mm incisions are placed in a 180 degree arc with the surgical site of interest at the apex of a baseball diamond, triangulated. One of these ports is enlarged to extract a specimen. The larger “utility port” is usually placed anterior to the latissimus high on the chest wall (Figure 2). Currently close to 40% of lung resections are performed in the US using VATS technique[22], [23] A recent analysis of the Society of Thoracic Surgery database from 2000-2010 found that 35% (4531/12970) of all lobectomies registered are performed by VATS techniques. This has increased from 20% in a previous analysis in 2006.[24], [25] Additionally, they found that respiratory complication increased significantly after thoracotomy compared to VATS in patients with decreased pulmonary function (FEV1 < 60%). A randomized trial found VATS techniques have less complications overall (18% vs. 50%)[26]. Less narcotic requirements are

universal and there were lower incidences of pneumonia and atrial fibrillation, improved shoulder range of motion and pulmonary function, less hospital stay and need for nursing home transfers.[22]



**Figure 2.** Video assisted thoracoscopic surgical (VATS) approach for lung resection. The anterior utility incision provides access to majority of the dissection. Endoscopic stapling device make this surgical approach for lung resection safe and feasible.

The late 1990's saw the development of robotic surgical systems with Intuitive's da Vinci system. The technique utilizes instruments that hinge on a chest wall fulcrum and operate within a cone. The da Vinci system uses multiarticulated instruments that provide seven degrees of rotational freedom, akin to a surgeon's wrist and can be placed exactly where dissection is needed with three-dimensional optics. The skin incisions and trocars are not appreciably different from VATS but the mobility at the end of the instrument is. Da Vinci can be used to retract, grasp, cut, ligate and suture. There is however absence of haptic feedback and therefore tension of tissues is determined solely from visual input (Figure 3).



**Figure 3.** Robotic approach to lung resection is the latest evolution in lung resection. The surgeon operates from a remote location using the console to control the robot that is 'docked' to the patient. The instrument articulations are such, it is more versatile than the human hand, allowing detail dissection in small spaces, however lacks the tactile sensation.

Many centers are pushing the envelope to investigate the merits of robotic lobectomy and finding good outcomes.[27] True investigation determining the benefits of robotic surgery over VATS are lacking. It is questioned whether we should be spending our efforts promoting robotic surgery when VATS, with its clear benefits, is not widely adopted.[28] Cost analysis finds robotic lobectomy is cheaper than open thoracotomy principally because of length of hospital stay.

Surgery for lung resection evolved through the twentieth century from a highly morbid procedure with upwards of 50% mortality to a streamlined <2% mortality and 2-3 day admission procedure.[29] Refinements in anesthesia, anatomic dissection and minimal access techniques continue to benefit patients. The current trend in high technology application remains to be proven for lung resection but the surgery for lung is continuing to evolve.

## Author details

Trevor Williams and Wickii T. Vigneswaran\*

\*Address all correspondence to: [wvignesw@surgery.bsd.uchicago.edu](mailto:wvignesw@surgery.bsd.uchicago.edu)

Department of Surgery, University Of Chicago Medicine, Chicago, IL, USA

## References

- [1] Meade R. A History of Thoracic Surgery. Springfield, IL: Charles Thomas, 1961.
- [2] Mountain K, Pomerantz. Thoracic Surgery Clinics: History of Thoracic Surgery, Feb 2000.
- [3] Hurt R. The History of Cardiothoracic Surgery: From Early Times: Parthenon Publishing Group, 1996.
- [4] Lilienthal H. Resection of the lung for suppurative cases with a report based on 31 operative cases in which resection was done or intended. *Ann Surg* 1922; 75(3): 257-320.
- [5] HB B. Surgical principles underlying one-stage lobectomy. *Arch Surg* 1929; 18:490-6.
- [6] Shenstone NS, Janes RM. Experiences in pulmonary lobectomy. *Can Med Assoc J* 1932; 27(2):138-45.
- [7] Faber LP. Individual ligation technique for lower lobe lobectomy. *Ann Thorac Surg* 1990; 49(6):1016-8.
- [8] Thomas CP. The present position relating to cancer of the lung. Lobectomy with sleeve resection. *Thorax* 1960; 15:9-11.



- [9] Ferguson MK, Lehman AG. Sleeve lobectomy or pneumonectomy: optimal management strategy using decision analysis techniques. *Ann Thorac Surg* 2003; 76(6):1782-8.
- [10] Betts RH, Takaro T. Use of a lung stapler in pulmonary resection. *Ann Thorac Surg* 1965; 24:197-202.
- [11] Kittle CF. Which way in?--The thoracotomy incision. *Ann Thorac Surg* 1988; 45(3):234.
- [12] Soto RG, Fu ES. Acute pain management for patients undergoing thoracotomy. *Ann Thorac Surg* 2003; 75(4):1349-57.
- [13] Cerfolio RJ, Bryant AS, Maniscalco LM. A nondivided intercostal muscle flap further reduces pain of thoracotomy: a prospective randomized trial. *Ann Thorac Surg* 2008; 85(6):1901-6; discussion 1906-7.
- [14] Ziyade S, Baskent A, Tanju S, et al. Isokinetic muscle strength after thoracotomy: standard vs. muscle-sparing posterolateral thoracotomy. *Thorac Cardiovasc Surg* 2010; 58(5):295-8.
- [15] Cooper JD, Nelems JM, Pearson FG. Extended indications for median sternotomy in patients requiring pulmonary resection. *Ann Thorac Surg* 1978; 26(5):413-20.
- [16] Bains MS, Ginsberg RJ, Jones WG, et al. The clamshell incision: an improved approach to bilateral pulmonary and mediastinal tumor. *Ann Thorac Surg* 1994; 58(1):30-2; discussion 33.
- [17] Bethencourt DM, Holmes EC. Muscle-sparing posterolateral thoracotomy. *Ann Thorac Surg* 1988; 45(3):337-9.
- [18] Ginsberg RJ. Alternative (muscle-sparing) incisions in thoracic surgery. *Ann Thorac Surg* 1993; 56(3):752-4.
- [19] Nosotti M, Baisi A, Mendogni P, et al. Muscle sparing versus posterolateral thoracotomy for pulmonary lobectomy: randomised controlled trial. *Interact Cardiovasc Thorac Surg* 2010; 11(4):415-9.
- [20] Benedetti F, Vighetti S, Ricco C, et al. Neurophysiologic assessment of nerve impairment in posterolateral and muscle-sparing thoracotomy. *J Thorac Cardiovasc Surg* 1998; 115(4):841-7.
- [21] Athanassiadi K, Kakaris S, Theakos N, et al. Muscle-sparing versus posterolateral thoracotomy: a prospective study. *Eur J Cardiothorac Surg* 2007; 31(3):496-9; discussion 499-500.
- [22] de Hoyos A, Kerstein Kea, Mahtabifard A. General Thoracic Surgery. Shields, T ed. Ch 33-35. 7th ed. Philadelphia, PA: Lippincott, 2009.
- [23] Brunelli A, Xiume F, Refai M, et al. Bilateral staged uniportal VATS for synchronous lung cancers. *Interact Cardiovasc Thorac Surg* 2006; 5(5):658-9.

- [24] Ceppa DP, Kosinski AS, Berry MF, et al. Thoracoscopic lobectomy has increasing benefit in patients with poor pulmonary function: a society of thoracic surgeons database analysis. *Ann Surg* 2012; 256(3):487-93.
- [25] Boffa DJ, Allen MS, Grab JD, et al. Data from The Society of Thoracic Surgeons General Thoracic Surgery database: the surgical management of primary lung tumors. *J Thorac Cardiovasc Surg* 2008; 135(2):247-54.
- [26] Hokschi B, Ablassmaier B, Walter M, et al. [Complication rate after thoracoscopic and conventional lobectomy]. *Zentralbl Chir* 2003; 128(2):106-10.
- [27] Park BJ, Melfi F, Mussi A, et al. Robotic lobectomy for non-small cell lung cancer (NSCLC): long-term oncologic results. *J Thorac Cardiovasc Surg* 2012; 143(2):383-9.
- [28] Swanson SJ. Robotic pulmonary lobectomy--the future and probably should remain so. *J Thorac Cardiovasc Surg* 2010; 140(5):954.
- [29] Tovar EA, Roethe RA, Weissig MD, et al. One-day admission for lung lobectomy: an incidental result of a clinical pathway. *Ann Thorac Surg* 1998; 65(3):803-6.

