

We are IntechOpen, the world's leading publisher of Open Access books Built by scientists, for scientists

4,800

Open access books available

122,000

International authors and editors

135M

Downloads

Our authors are among the

154

Countries delivered to

TOP 1%

most cited scientists

12.2%

Contributors from top 500 universities



WEB OF SCIENCE™

Selection of our books indexed in the Book Citation Index
in Web of Science™ Core Collection (BKCI)

Interested in publishing with us?
Contact book.department@intechopen.com

Numbers displayed above are based on latest data collected.

For more information visit www.intechopen.com



Management of Midfacial Fractures

Sertac Aktop, Onur Gonul, Tulin Satilmis,
Hasan Garip and Kamil Goker

Additional information is available at the end of the chapter

<http://dx.doi.org/10.5772/54644>

1. Introduction

The management of midfacial fractures includes the treatment of facial fractures, dentoalveolar trauma, and soft-tissue injuries, as well as associated injuries, mainly of the head and neck [1]. The management of fractures of the maxillofacial complex remains a challenge for the oral maxillofacial surgeon, demanding both skill and expertise [2]. The success of treatment and implementation of preventive measures are more specifically dependent on epidemiologic assessments [3]. Midfacial fractures can occur in isolation or in combination with other serious injuries, including mandibular, ophthalmologic, cranial, spinal, thoracic, and abdominal trauma, as well as upper and lower orthopedic injuries [4]. The epidemiology of facial fractures varies in type, severity, and cause depending on the population studied. Differences among populations in the causes of maxillofacial fractures may be the result of differences in risk and cultural factors among countries, but are more likely to be influenced by the severity of injury [1,5]. The causes of maxillofacial fractures have changed over the past three decades, and they continue to do so. The main causes worldwide are traffic accidents, assaults, falls, sport-related injuries, and warfare [6-8]. Many articles pertaining to the incidence and causes of maxillofacial injuries have been published [1,4,7-10]. In 2003, Motamedi [7] reported the distribution of facial fractures as 72.9% mandibular, 13.9% maxillary, 13.5% zygomatic, 24.0% zygomatico-orbital, 2.1% cranial, 2.1% nasal, and 1.6% frontal injuries [Figure 1].

Causes of these maxillofacial injuries were automobile (30.8%) and motorcycle (23.2%) accidents, altercations (9.7%), sport (6.3%), and warfare (9.7%) [Figure 2].

The distribution of maxillary fractures was 54.6% Le Fort II, 24.2% Le Fort I, 12.1% Le Fort III, and 9.1% alveolar [7] [Figure 3].

According to Cook and Rowe [4], midfacial injuries occur most frequently in individuals aged 21–30 years (43%). The 11–20-year and 31–40-year age groups each account for 20% of these

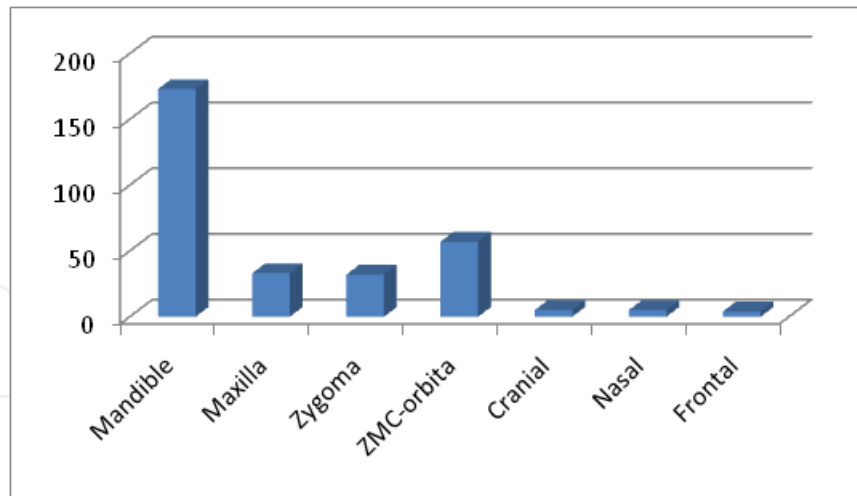


Figure 1. Fracture sites are shown for 237 maxillofacial trauma patients according to Motamedi

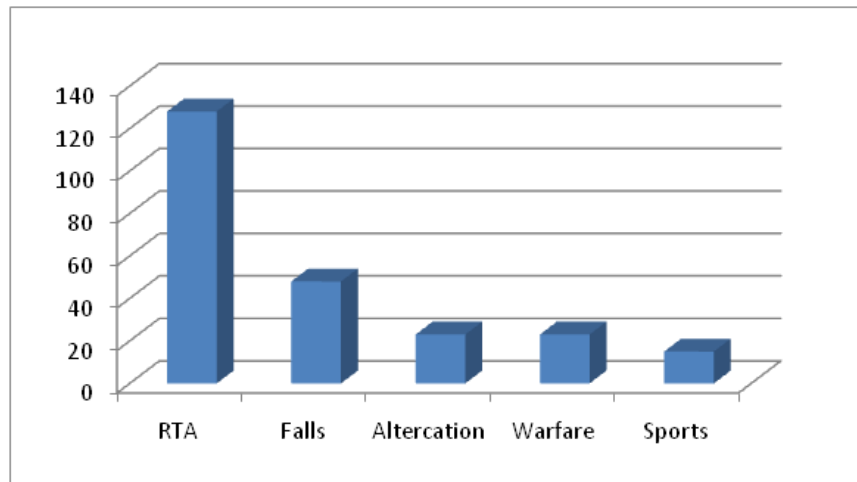


Figure 2. The causes of fracture for Motamedi's assessment of maxillofacial trauma patients

fractures. Most (83.1%) midfacial fractures occur in males, with the remainder (16.9%) occurring in females [4] [Figure 4].

Thoren [9] noted that injuries are associated with 25.2% of midfacial fractures. These injuries most commonly affect a limb (13.5%), followed by the brain (11.0%), chest (5.5%), spine (2.7%), and abdomen (0.8%) [9].

2. Surgical anatomy

The anatomy of the head is complex; the physical properties of the skin, bone, and brain differ markedly and the facial skeletal components articulate and interdigitate in a complex fashion, with the consequence that a given facial bone is rarely fractured without disrupting its

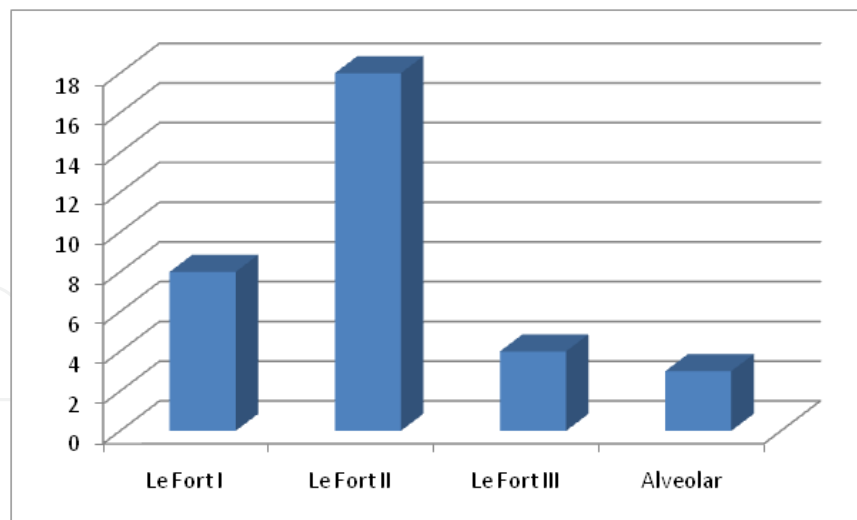


Figure 3. Distribution of maxillary fractures in Motamedi's assessment of maxillofacial trauma patients

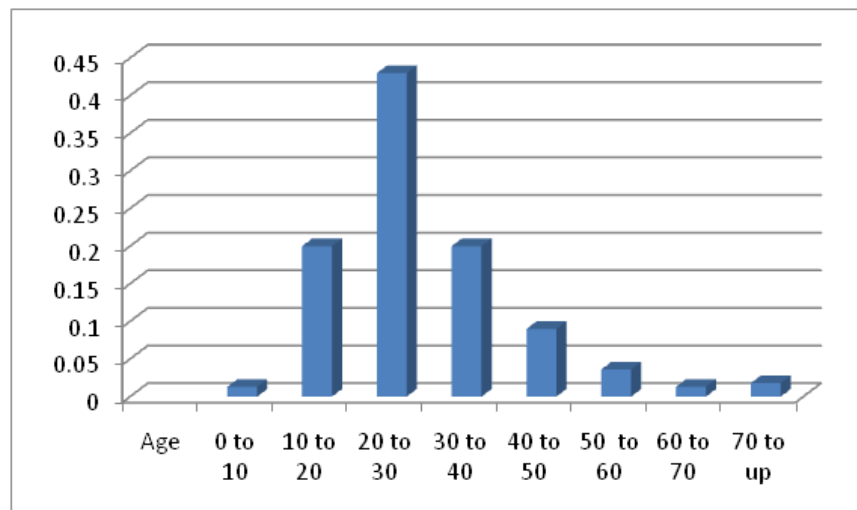


Figure 4. Age distribution of midfacial fracture patients according to Cook and Rowe.

neighbor [10]. The severity and pattern of a fracture depend on the magnitude of the causative force, impact duration, the acceleration imparted by impact to the affected part of the body, and the rate of acceleration change. The surface area of the impact site is also relevant [11,12]. The middle third of the facial skeleton is defined as an area bounded superiorly by a line drawn across the skull from the zygomaticofrontal suture, across the frontonasal and frontomaxillary sutures, to the zygomaticofrontal suture on the opposite side; and inferiorly by the occlusal plane of the maxillary teeth, or, in an edentulous patient, by the maxillary alveolar ridge. It extends posteriorly to the frontal bone in the superior region and the body of the sphenoid in the inferior region, and the pterygoid plates of the sphenoid are usually involved in any severe fracture [13].

The middle third of the facial skeleton comprises the following bones [14] [Figure 5]:

- Two maxillae
- Two zygomatic bones
- Two zygomatic processes of the temporal bones
- Two palatine bones
- Two nasal bones
- Two lacrimal bones
- The vomer
- The ethmoid and attached conchae
- Two inferior conchae
- The pterygoid plates of the sphenoid

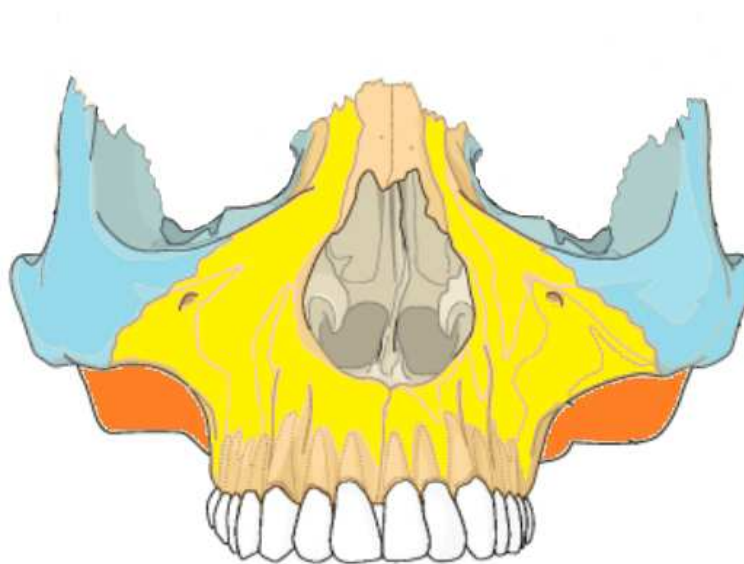


Figure 5. Bones of the middle third of the facial skeleton

The frontal bone and the sphenoid body and greater and lesser wings are not usually fractured. In fact, they are protected to a considerable extent by the cushioning effect achieved as the fracturing force crushes the comparatively weak bones comprising the middle third of the facial skeleton [13].

3. Initial management of the midfacial trauma patient

The initial assessment and management of a patient's injuries must be completed in an accurate and systematic manner to quickly establish the extent of any damage to vital life-support

systems. Patients are assessed and treatment priorities are established based on patients' injuries and the stability of their vital signs. Injuries can be divided into three general categories: severe, urgent, and non-urgent. Severe injuries are immediately life threatening and interfere with vital physiologic functions; examples are compromised airway, inadequate breathing, hemorrhage, and circulatory system damage or shock. These injuries constitute approximately 5% of patient injuries but represent more than 50% of injuries associated with all trauma deaths. Urgent injuries make up approximately 10–15% of all injuries and present no immediate threat to life. Patients with this type of injury may present with damage to the abdomen, orofacial structures, chest, or extremities that requires surgical intervention or repair, but their vital signs are stable. Non-urgent injuries account for approximately 80% of all injuries and are not immediately life threatening. Patients with this type of trauma eventually require surgical or medical management, although the exact nature of the injury may not become apparent until significant evaluation and observation are performed. The goal of initial emergency care is to provide life-saving and support measures until definitive care can be initiated. Any trauma victim with altered consciousness must be considered to have a brain injury. The level of consciousness is assessed by serial Glasgow Coma Scale evaluations [15] [Table 1].

Action	Score
Eye Opening	4
Spontaneous	3
To speech	2
To pain	1
None	6
Motor Response	5
Obeys	4
Localises pain	3
Withdraws from pain	2
Flexion to pain	1
Extension to pain	5
None	4
Verbal Response	3
Oriented	2
Confused	1
Inappropriate	
Incomprehensible	
None	

Adapted from Teasdale and Jennett [15]. A patient's score determines the category of neurologic impairment: 15 = normal, 13 or 14 = mild injury, 9–12 = moderate injury, and 3–8 = severe injury.

Table 1. Glasgow Coma Scale.

Other signs of brain damage include restlessness, convulsions, and cranial nerve dysfunction (e.g. a nonreactive pupil). The classic Cushing triad (hypertension, bradycardia, and respiratory disturbances) is a late and unreliable sign that usually closely precedes brain herniation. Hypotension is rarely due to head injury alone. Patients suspected of sustaining head trauma should not receive any premedication that will alter their mental status (e.g. sedatives or analgesics) or neurologic examination (e.g. anticholinergic-induced pupillary dilation).

3.1. Primary Survey: ABCs

During the primary survey, life-threatening conditions are identified and reversed quickly. This period calls for quick and efficient evaluation of the patient's injuries and almost simultaneous life-saving intervention. The primary survey progresses in a logical manner based on the ABC mnemonic: airway maintenance with cervical spine control, breathing and adequate ventilation, and circulation with control of hemorrhage. The letters D and E have also been added: a brief neurologic examination to establish the degree of consciousness, and exposure of the patient *via* complete undressing to avoid overlooking injuries camouflaged by clothing. Maxillofacial injuries may result in airway compromise caused by any of several factors: blood and secretions, a mandibular fracture that allows the tongue to fall against the posterior wall of the pharynx, a midfacial injury that causes the maxilla to fall posteroinferiorly into the nasopharynx, and foreign debris such as avulsed teeth or dentures. A large tonsillar suction tip should be used to clear the oral cavity and pharynx. The establishment of an oral airway assists with tongue position; however, care must always be taken to avoid manipulation of the neck and to provide access to the oral cavity and dentition for the reduction and fixation of any fractures requiring a period of intermaxillary fixation. Neither midfacial fractures nor cerebrospinal rhinorrhea are contraindications to nasal intubation. Care should be taken to pass the tube along the nasal floor into the pharynx, and the tube should be visualised before tracheal intubation. Hypertension or tachycardia during intubation can be attenuated with the intravenous administration of lidocaine or fentanyl. Intubation while the patient is awake causes a precipitous rise in intracranial pressure. Nasal passage of an endotracheal or nasogastric tube in a patient with a basal skull fracture risks cribriform plate perforation and cerebrospinal fluid infection. Slight elevation of the head will improve venous drainage and decrease intracranial pressure.

3.2. Physical examination

The physical examination should begin with an evaluation of soft-tissue injuries. Lacerations should be debrided and examined for disruption of vital structures, such as the facial nerve or parotid duct. The eyelids should be elevated to allow evaluation of the eyes for neurologic and ocular damage. The face should be symmetric, without discolouration or swelling suggestive of bony or soft-tissue injury. The bony landmarks should be palpated, beginning with the supraorbital and lateral orbital rims and followed by the infraorbital rims, malar eminences, zygomatic arches, and nasal bones. Any steps or irregularities along the bony margin are suggestive of a fracture. Numbness over the area of distribution of the trigeminal nerve is usually noted with fractures of the facial skeleton. The oral cavity should be inspected and

evaluated for lost teeth, lacerations, and occlusal alterations. Any tooth lost at the time of injury must be accounted for because it may have been aspirated or swallowed. The neck should also be examined for injury. Subcutaneous air may be visualised if massive injury is present; if subtle, it may be detected only by palpation. The presence of air in the soft tissue may be the result of tracheal damage. Any externally expanding edema or hematoma of the neck must be observed closely for continued expansion and airway compromise. Carotid pulses should be assessed. Palpation should be performed to detect abnormalities in the contour of the thyroid cartilage and to confirm the midline position of the trachea in the suprasternal notch.

3.3. Preoperative considerations

Patients with midfacial trauma often pose the greatest airway challenges to the anaesthesiologist. Preoperative airway evaluation must be detailed and thorough. Particular attention should be focused on jaw opening, mask fit, neck mobility, maxillary protrusion, macroglossia, dental pathology, nasal patency, and the existence of any intraoral lesion or debris. If any forewarning sign of problems with mask ventilation or endotracheal intubation is observed, the airway should be secured prior to anaesthesia induction. This process may involve fiberoptic nasal or oral intubation or tracheostomy. Nasal intubation with a preformed or straight tube with a flexible angle connector is usually preferred in dental or oral surgery. The endotracheal tube can then be directed cephalically and connected to breathing tubes passing over the patient's head.

3.4. Intraoperative management

Reconstructive surgery can be associated with substantial blood loss. Strategies to minimise bleeding include a slight head-up position, controlled hypotension, and local infiltration with epinephrine solutions. Because the patient's arms are typically tucked along the sides of the body, at least two intravenous lines should be established prior to surgery. This step is especially important if one line is used for the delivery of an anaesthetic or hypotensive agent. An arterial line can be helpful in cases of marked blood loss, as a surgeon leaning against the patient's arm may interfere with non-invasive blood pressure cuff readings. An oropharyngeal pack is often placed to minimize the amount of blood and other debris reaching the larynx and trachea. Due to the proximity of the airway to the surgical field, the anaesthesiologist's location is more remote than usual. This situation increases the likelihood of serious intraoperative airway problems, such as endotracheal tube kinking, disconnection, or perforation by a surgical instrument. Airway monitoring of end-tidal CO₂, peak inspiratory pressures, and esophageal stethoscope breath sounds assumes increased importance in such cases. At the end of the surgery, the oropharyngeal pack must be removed and the pharynx suctioned. Although the presence of some bloody debris during initial suctioning is not unusual, repeated efforts should be less productive. If there is a chance of postoperative edema involving structures that could potentially obstruct the airway (e.g. the tongue), the patient should be left intubated. Otherwise, extubation can be attempted once the patient is fully awake and shows no sign of continued bleeding. Appropriate cutting tools should be placed at the bedside of a patient with

intermaxillary fixation (*e.g.* maxillomandibular wiring), in case of vomiting or other airway emergency.

4. Dentoalveolar fractures

Fracture of the alveolar process is a common injury, comprising 2–8% of all craniofacial injuries. Nearby soft tissues and teeth are often damaged, increasing the severity of the situation [16]. The most common causes of such fractures are falls, motor vehicle accidents, sporting injuries, altercations, child abuse, and playground accidents. Direct or indirect force on a tooth, the latter transmitted most commonly through overlying soft tissues, may cause dentoalveolar injury [17].

4.1. Clinical examination

The practitioner should first ask when, where, and how the injury occurred and whether any treatment has been provided since that time. Answers to these simple questions could provide important clues. The patient's general health status should be known and his or her current situation examined when any nausea, vomiting, unconsciousness, amnesia, headache, or visual disturbance has occurred after injury. The examination of a patient's dentoalveolar injuries should assess the condition of the extraoral and intraoral soft tissues, jaws, and alveolar bone; establish the presence of any tooth displacement or mobility; and include tooth percussion and pulp testing [18]. Lacerations, abrasions, and contusions are very common in dentoalveolar injuries. Any vital structure crossing the line of laceration should be noted. The removal of blood clots, saline irrigation, and cleaning of the oral cavity facilitate inspection. Any foreign body within surrounding tissues should be examined carefully because bone or tooth fragments might have penetrated these areas, depending on the mechanism of injury. All fractured or missing teeth and restorations should be assumed to have been swallowed, aspirated, or lodged in adjacent structures. Alveolar segment fractures can be detected readily by visual examination and palpation. However, examination may be difficult because of post-injury pain. Sublingual ecchymosis on the mouth floor is pathognomonic for an underlying mandibular fracture. Step defects, crepitation, malocclusion, and gingival lacerations should raise the suspicion of possible underlying bony defects. The presence of fractured teeth should be noted. The depth of the fracture is very important. Complete mobility of the crown may indicate crown–root fracture. Post-injury occlusion should be checked and any displacement, intrusion, or luxation should be examined carefully. Percussion tests to determine sensitivity and pulp vitality should be performed to rule out periodontal ligament injury and many types of tooth fracture.

4.2. Imaging

Radiographic studies should be performed before intraoral manipulation. Radiography should determine the presence of root or jaw fracture, degree of extrusion or intrusion and its relationship to possible existing tooth germs, extent of root development, and presence of tooth

fragments and foreign bodies lodged in soft tissues. The combination of periapical, occlusal, and panoramic radiographs is used most frequently for the detection of damage to underlying tissues. Periapical radiographs provide the most detailed information about root fractures and tooth dislocation. Occlusal radiographs, however, provide larger fields of view and nearly the same level of detail as periapical radiographs; they are also very useful for the detection of foreign bodies. Panoramic radiographs provide useful screening views and visualize fractures of the mandible, maxilla, alveolar ridges, and teeth. Computed tomography (CT) offers insufficient resolution for the diagnosis of dental trauma, but cone-beam CT technology provides sufficient resolution to serve as a valuable tool in the diagnosis of various dental injuries [17,19,20].

4.3. Classification

The most commonly used simple and comprehensive classification of dentoalveolar injuries was developed by Andreasen [21] [Figure 6].

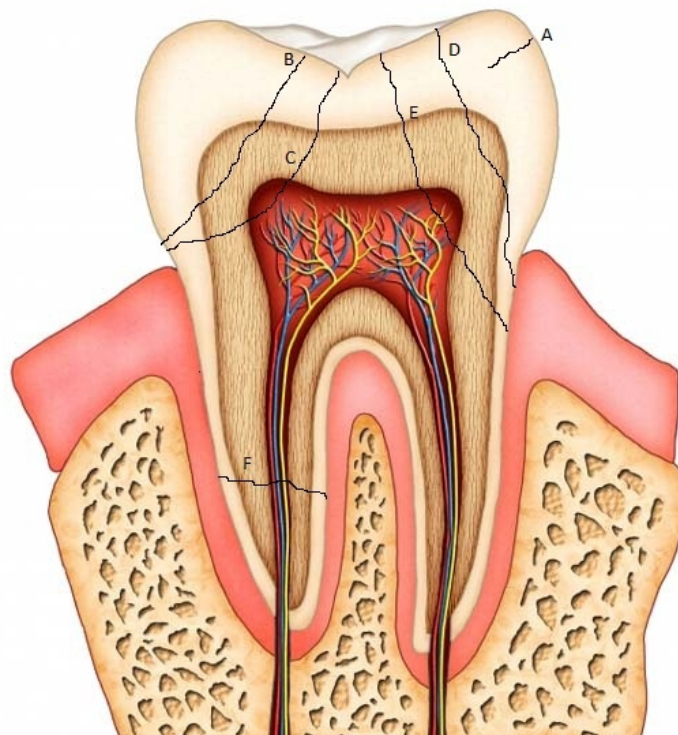


Figure 6. Diagram of Andreasen's classification

Dental tissues and pulp

- Simple crown infraction (crack in the tooth without loss of tooth substance)
- Uncomplicated crown fracture (confined to enamel, or enamel and dentine, with no root exposure)
- Complicated crown fracture (pulp exposure)

- Uncomplicated crown–root fracture (involving the enamel, dentine, and cementum without pulp exposure)
- Complicated crown–root fracture (involving the enamel, dentine, and cementum with pulp exposure)
- Root fracture (involving the dentine and cementum with pulp exposure)

Injuries to periodontal tissues

- Concussion: injury to the periodontium producing sensitivity to percussion without tooth loosening or displacement
- Subluxation: the tooth is loosened but not displaced
- Extrusive luxation, lateral luxation, intrusive luxation
- Avulsion: tooth displacement without accompanying comminution or fracture of the alveolar socket

Injuries to the supporting bone

- Comminution of the alveolar housing, often with intrusive or lateral luxation
- Fracture of a single wall of an alveolus
- Fracture of the alveolar process *en bloc* in a dentate patient; the fracture line does not necessarily extend through a tooth socket
- Fracture involving the main body of the mandible or maxilla

4.4. Treatment

The aim of dentoalveolar fracture treatment is to re-establish the normal form and function of the masticatory system. The involvement of pulp tissue makes a great difference in the treatment protocol.

4.4.1. Dental tissues and pulp

Simple crown infractions do not require treatment. Multiple cracks can be sealed with restorative materials to prevent staining. For uncomplicated crown fractures affecting only the enamel, grinding of the sharp edges is one possible solution. In cases of extensive enamel loss, a composite restoration may be used for recontouring. If a considerable amount of dentine is exposed, it should be covered with glass ionomer as an emergency treatment, and permanent composite restoration with bonding agents can be performed immediately or at a later stage. If the missing fragment is found, bonding to the tooth can be attempted with dentine bonding agents. Periodic follow-up visits should be scheduled to monitor pulp vitality. The management of complicated crown fractures is more challenging. If the exposed pulp tissue is vital, pulp capping or pulpotomy should be performed in cases without extensive crown loss. In cases of severe loss of crown substance or a lengthy interval between injury and treatment, pulp extirpation should be performed *via* Ca(OH)₂ application in the root canal. Permanent

root canal filling is carried out later in such cases. If the exposed pulp tissue is already necrotic, $\text{Ca}(\text{OH})_2$ should be applied immediately after canal debridement. The course of treatment for uncomplicated crown–root fractures depends on the fracture location. An intact coronal fragment must be removed and inspected carefully to determine whether restoration of the remaining fragment is possible. If the fracture does not extend too far apically, the remaining fragment is suitable for restoration, and the pulp has not been exposed, the treatment protocol is the same as described above for crown fractures. Gingivectomy, ostectomy, or orthodontic extrusion might be required later for tooth restoration. In complicated crown–root fractures, pulp extirpation and $\text{Ca}(\text{OH})_2$ application are recommended during the emergency stage, followed by the permanent restoration of the remaining tooth fragment after root canal filling. Surgical extrusion is an option for such fractures because the pulp tissue cannot be devitalised as in uncomplicated crown–root fractures. When no combination of procedures successfully renders the remaining fragment restorable, extraction of the tooth is necessary. When root fractures are located above or close to the gingival crevice, the whole tooth should be extracted; when the remaining tissue allows tooth restoration, only the coronal fragment should be removed for root canal therapy and post and core restoration. Fractures between the middle and apical thirds of the tooth have a good prognosis for pulp survival and the joining of root fragments to one another during healing. A displaced or mobile fragment should be repositioned correctly and the tooth should be splinted for 2–3 months. During this time, the fragments usually calcify. The tooth should be inspected for signs of pulp necrosis during follow-up visits and root canal therapy should be performed if necessary.

4.4.2. Injuries to periodontal tissues

Concussed teeth present only tenderness to percussion in the horizontal and vertical directions. Removing the tooth from occlusion is the only accepted treatment option in such cases. Subluxated teeth show no clinical or radiographic displacement, but damage to the periodontal ligament tissue is present. Periodontal tissue rupture can cause bleeding from the gingival margin crevice. Treatment in these cases is the same as described for concussion, and follow-up monitoring of pulp vitality is necessary. Extrusive luxation is characterized by neurovascular and periodontal ligament rupture with mobility and bleeding from the gingival margin. Pulp necrosis and external root resorption may be seen in later stages. The tooth should be positioned properly and splinted to uninjured adjacent teeth with an acid-etch/resin splint for 3 weeks. Other methods of splinting used routinely in oral and maxillofacial surgery are not recommended. If pulp necrosis occurs, endodontic therapy should be performed. Lateral extrusions often involve the alveolar bone, and may be characterized by complex gingival lacerations and step deformities. The goal of treatment is to properly reposition the alveolar bone and tooth, which can be accomplished with the application of an acid-etch/resin splint for 4–8 weeks. Intrusive luxation is characterized by obvious tooth displacement and comminution and fracture of the alveolus. The risks of pulpal necrosis and inflammatory root resorption are higher in such cases than in other dentoalveolar injuries. Affected teeth with complete root development and closed apices should be repositioned and stabilized with a non-rigid splint. Endodontic therapy within 10–14 days after injury, including canal filling with $\text{Ca}(\text{OH})_2$, is recommended to retard or inhibit the inflammatory or replacement resorption

process. Intrusion of an incompletely developed tooth is discussed in the 'Midfacial Fractures in Children' section below. The fate of an avulsed tooth depends on the cellular viability of the periodontal fibres that remain attached to the root surface prior to reimplantation. Important factors determining the success of treatment measures are the length of time that the tooth has been out of the socket, the state of the tooth and periodontal tissues, and the manner in which the tooth has been preserved before replantation. Avulsed teeth should be stored temporarily in milk, saliva, saline, or Hank's solution. More than 15 min of extraoral exposure of a periodontal ligament will deplete most cell metabolites in the dental tissue. Teeth in poor hygienic condition and those with moderate to severe periodontal disease, gross caries involving the pulp, apical abscess, infection at the replanting site, and bony defects and/or alveolar injuries involving the loss of supporting bone are generally not replanted. For individuals with avulsed teeth with mature or closed apices who present within 2 h after injury, the tooth is placed in Hank's solution for about 30 min, then in doxycycline (1 mg/20 mL saline) to inhibit bacterial growth and aid pulpal revascularization; replantation and splinting with an acid-etch/resin splint for 7–10 days are then performed. Endodontic cleansing and shaping of the canal should be performed, and $\text{Ca}(\text{OH})_2$ filling should be applied immediately prior to splint removal. The use of final gutta-percha obturation 6–12 months later is contingent on the resolution of canal and/or root pathology. To optimise the success of treatment, avulsed teeth should be replanted and stabilized within 2 h, before periodontal ligament cells become irreversibly necrotic. Teeth with apical openings >1 mm in diameter have a much better prognosis than do those with more mature or closed apices; however, when the extraoral period exceeds 2 h, apical root morphology has little effect on the treatment success rate.

4.4.3. *Injuries to the supporting bone*

Most alveolar fractures occur in the premolar and incisor regions. The treatment of these fractures involves proper reduction and rapid stabilization. Manipulation by pressure and rigid stabilization of the fragments are accepted closed-reduction techniques. Major displacement or difficulty with closed reduction may necessitate open reduction. Alignment of the involved teeth, edema of the segments, restoration of proper occlusion, and edema of the teeth in the fractured segment are important. The removal of teeth with no bony support may be considered, but should not be performed before the fractured bony segments have healed, even if the teeth are considered to be unsalvageable. Segment edema can be performed with acrylic or metal cap splints, orthodontic bands, fibreglass splints, transosseous wires, small or mini cortical plates, or transgingival lag screws; these materials should be applied for at least 4 weeks.

4.4.4. *Complications*

Pulp canal obliteration is characterized by the deposition of hard tissue within the root canal space and dark-yellow discolouration of the clinical crown. This complication is seen most frequently after tooth luxation or horizontal root fracture. A tooth with pulpal canal obliteration does not require treatment unless the pulp tissue becomes necrotic and develops periradicular radiolucency. Pulp necrosis is the most likely complication of dentoalveolar injury. Its

incidence depends on the type and severity of injury and the extent of root development; teeth with fully formed roots are affected more often. If pulp necrosis is detected, root canal therapy should be initiated immediately to prevent inflammatory root resorption. Internal root resorption can be an issue after most dentoalveolar injuries. This process is usually detected radiographically; if it is identified at an early stage, root canal therapy has an excellent prognosis. The risk of tooth fracture after endodontic therapy is increased in cases of large defects. Follow-up radiography is useful for the detection of internal root resorption. If necrotic pulp is not removed, inflammation of the root surface may occur and the tooth root will be resorbed. Inflammatory root resorption can be detected radiographically and treated by $\text{Ca}(\text{OH})_2$ dressing after canal debridement. Ankylosis can occur following damage to large areas of the periodontal membrane, as a primary result of trauma, or as a result of inflammatory root resorption. Osseous replacement proceeds slowly in adults; the tooth may serve for several years, but will loosen eventually.

5. Le Fort fractures

Rene Le Fort famously characterized the types of midfacial fracture caused by anteriorly directed forces [22-24] [Figure 7-9]. Most Le Fort fractures are caused by motor vehicle accidents, and this type of trauma is often associated with other facial fractures and orthopaedic and neurologic injuries.

5.1. Clinical Examination

5.1.1. *Le Fort I fractures (Guerin fracture)*

In Le Fort I fractures, a horizontal fracture line separates the inferior portion of the maxilla, the horizontal plates of the palatal bones, and the inferior one-third of the sphenoid pterygoid processes from the superior two-thirds of the face, which remain associated with the skull. The entire maxillary dental arch may be mobile or wedged in a pathologic position. The patient may have an anterior open bite. Step deformities can be palpated intraorally if edema allows. Hematomas in the upper vestibule (Guerin's sign) and epistaxis may occur. Le Fort I fractures can be detected readily by orthopantomography, and CT provides a superior level of detail. [Figure 7].

5.1.2. *Le Fort II fractures*

In Le Fort II fractures, the pyramidal mid-face is separated from the rest of the facial skeleton and skull base. The fracture begins inferior to the nasofrontal suture and extends across the nasal bones and along the maxilla to the zygomaticomaxillary suture, including the inferomedial third of the orbit. The fracture then continues along the zygomaticomaxillary suture to and through the pterygoid plates. [Figure 8].

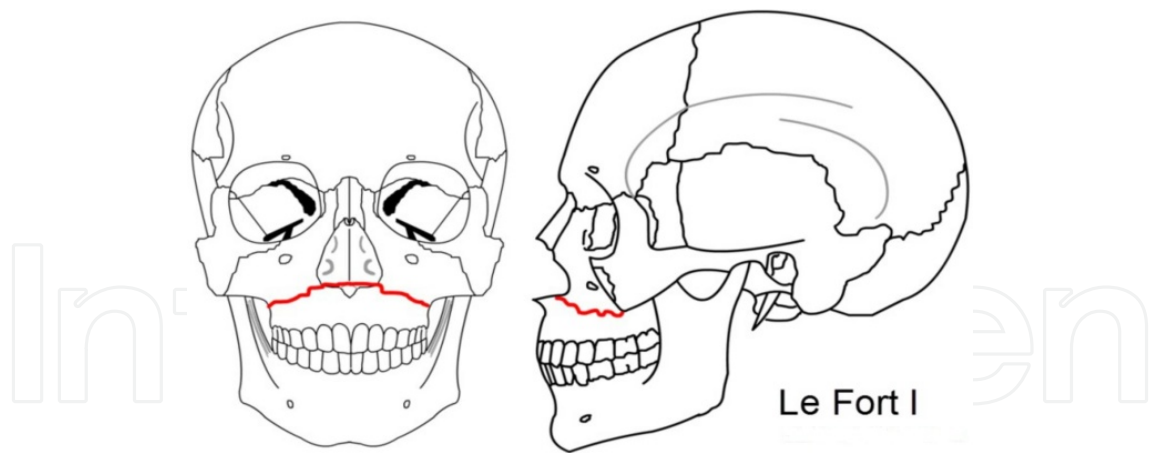


Figure 7. Le Fort I Fracture (Figure adapted from www.radiologytutorials.com)

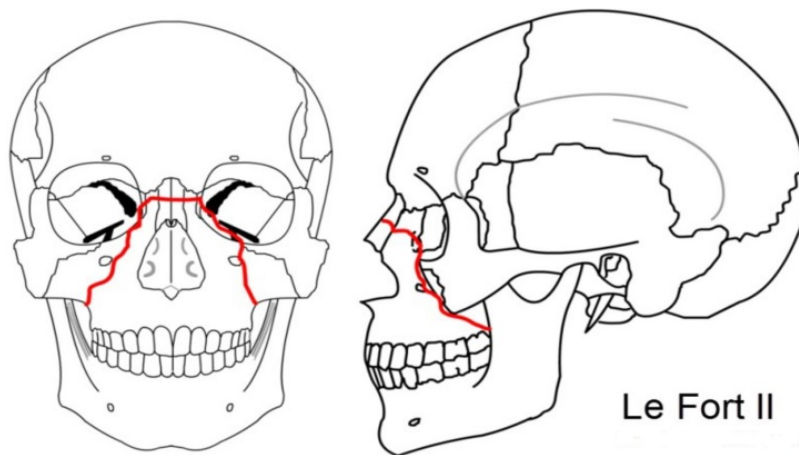


Figure 8. Le Fort II Fracture (Figure adapted from www.radiologytutorials.com)

5.1.3. Le Fort III fractures

In Le Fort III fractures, the face is essentially separated along the base of the skull due to force directed at the level of the orbit. The fracture line runs from the nasofrontal region along the medial orbit, through the superior and inferior orbital fissures, and then along the lateral orbital wall through the frontozygomatic suture. It then extends through the zygomaticotemporal suture and inferiorly through the sphenoid and the pterygomaxillary suture. In the past, Water's and lateral views were used to identify Le Fort fractures. CT and three-dimensional CT are now used most frequently, and axial and coronal scans are most useful for identifying midfacial fractures. Pterygoid plate fractures are found in all types of Le Fort fracture. Le Fort I fractures can be seen through the lateral aspect of the piriform aperture. Fractures of the infraorbital rim and zygomaticomaxillary buttress are unique to Le Fort II fractures. Only Le Fort III fractures involve the lateral orbital wall and zygomatic arch, and cerebrospinal fluid leakage can be a matter of concern. [Figure 9].

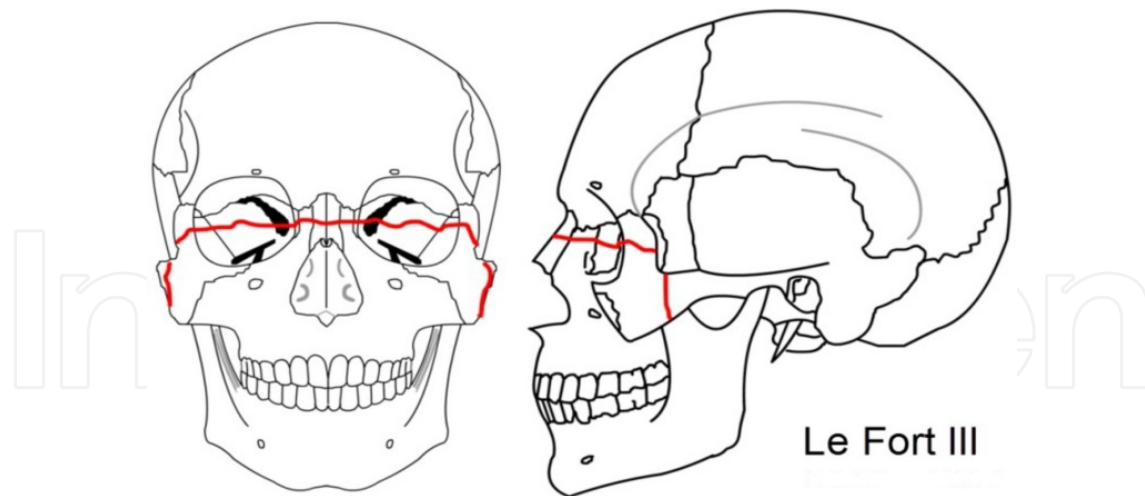


Figure 9. Le Fort III Fracture (Figure adapted from www.radiologytutorials.com)

5.1.4. Treatment

The basic principle employed in the treatment of Le Fort fractures is fixation of the maxilla to the next highest stable structure, which differs with Le Fort fracture level. At the Le Fort I level, fixation is performed along the vertical buttresses of the maxilla at the piriform and zygomatic buttress. At higher Le Fort levels, fixation to the nasal bones, orbital rims, or zygomaticofrontal sutures may be necessary. The restoration of proper occlusion is a main goal of treatment. Reconstruction and fixation of the paranasal and zygomaticoalveolar buttresses are often sufficient to re-establish the proper position of the maxilla in Le Fort I fractures. Fractures with minimal or no displacement can heal spontaneously. Bleeding from the nasal wall or septal cracks is common and can be managed by various types of nasal packing. Tamponades can be used at other bleeding sites, such as those with lacerations or abrasions. Intermaxillary fixation with arch bars should be performed after reduction of the maxilla, followed by internal fixation of the maxillary vertical buttresses with plates and screws. Le Fort I fractures can generally be approached *via* maxillary vestibular incisions. Reduction of the maxilla can be challenging because of impaction, telescoping, or a significant interval of time between injury and treatment. If resistance is encountered during mobilisation of the maxilla, Rowe or Hayton-Williams disimpaction forceps may be used to help reduce the fracture [Figure 10,11].

Incomplete fractures may make maxillary mobilisation difficult; in such cases, completion of the fracture with osteotomies can facilitate reduction. In cases of severe comminution, inadequate dentition, periodontal disease, or edentulous arches (Gunning splints), fabricated occlusal or palatal splints can be applied to establish intermaxillary fixation.

Le Fort II fractures can be reduced with Rowe impaction forceps and intermaxillary fixation. A maxillary buccal vestibule incision and any of various approaches to the orbital rim can be used if open reduction is necessary. Bilateral Lynch incisions are to expose the nasofrontal suture [Figure 12].

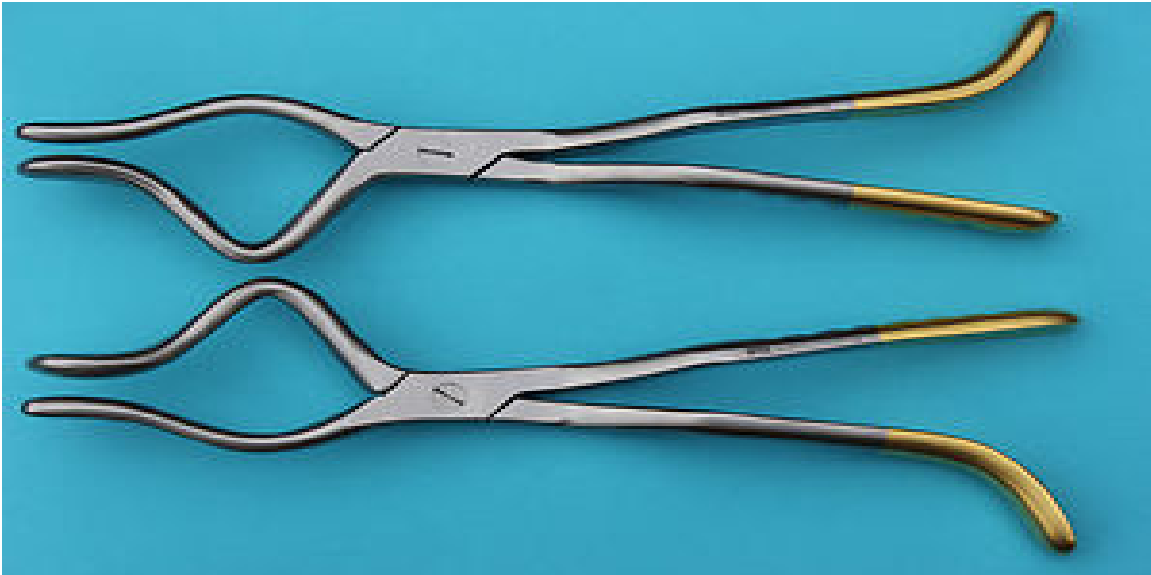


Figure 10. Rowe disimpaction forceps



Figure 11. Hayton Williams forceps

Le Fort III fractures rarely occur in isolation and are usually components of panfacial fractures. Bicoronal incisions can be used to expose the naso-orbito-ethmoidal region, frontozygomatic sutures, and lateral orbital rims. Pre-auricular, lower lid, and maxillary vestibular incisions can be performed when necessary.

5.1.5. Complications

Patients who have undergone intermaxillary fixation may experience breathing problems, which can be resolved by opening the nasopharyngeal airways. Hemorrhage of the posterior superior alveolar artery should be suspected when profuse bleeding occurs following any fracture of the posterior alveolar wall. Rapid decreases in blood pressure, hemoglobin, and hematocrit are other signs of fatal hemorrhage. If the artery cannot be ligated, embolization is indicated after the identification of the bleeding source *via* angiography. Some forms of trauma cause paranasal sinus fractures. Sinus complications, such as chronic sinusitis, polyps,

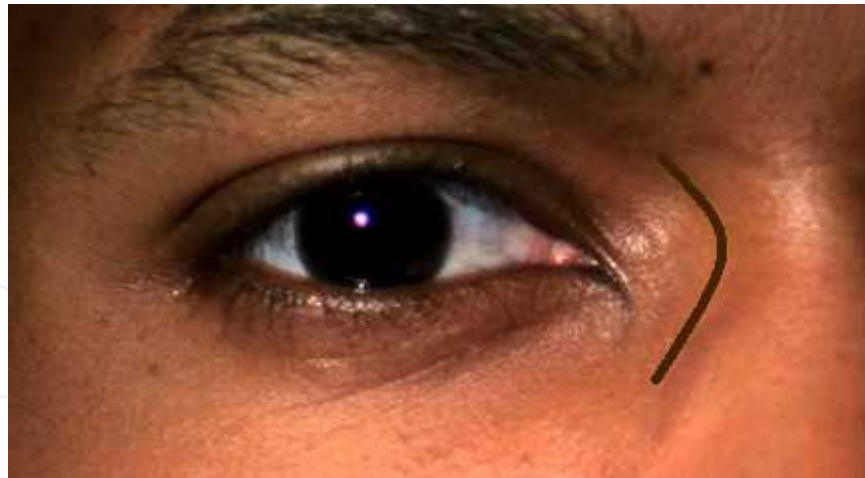

Figure 12. Lynch incision line

mucocoele formation, and acute sinus infection may occur in such cases. Proper anatomic reduction of the sinuses can restore normal sinus function. Vision-related complications can be an issue before or after the reduction of a fracture, especially a high Le Fort fracture. Blindness, enophthalmos, and diplopia can occur due to intraorbital or retrobulbar hemorrhage or damage to the optic nerve caused by bone fragments. Improper rigid fixation of fracture segments will result in malocclusion; this complication usually occurs in patients with anterior open bites and/or class III fracture patterns. Improper rigid fixation may also cause numbness of the area innervated by the infraorbital nerve due to impingement of this nerve. A second surgical procedure is required to correct such complications. Malunion of maxillary fractures can obstruct the nasolacrimal ducts. Non-union of the segments may result in an inadequate blood supply, malpositioning, or infection. Foreign bodies, fractured teeth, and hematomas may cause infection.

6. Fractures of the zygomatic bone

Zygomatic bone fracture is the second most common midfacial injury, following nasal fracture. A zygomatic complex fracture is characterized by separation of the zygoma from its four articulations (frontal, sphenoidal, temporal, and maxillary). An independent fracture of the zygomatic arch is termed an isolated zygomatic arch fracture [Figure 13,14].

6.1. Clinical examination

The face is inspected and palpated to identify asymmetry caused by displaced fragments of the facial skeleton. Pain, ecchymosis, and periorbital edema with subconjunctival hemorrhage are the earliest clinical signs of a non-displaced zygomatic bone injury. Displaced fractures generally cause depression of the malar eminence and infraorbital rim. Damage to the zygomaticotemporal and infraorbital nerves may cause paraesthesia or anaesthesia in the cheek, lateral nose, upper lip, and maxillary anterior teeth. Epistaxis and diplopia are common

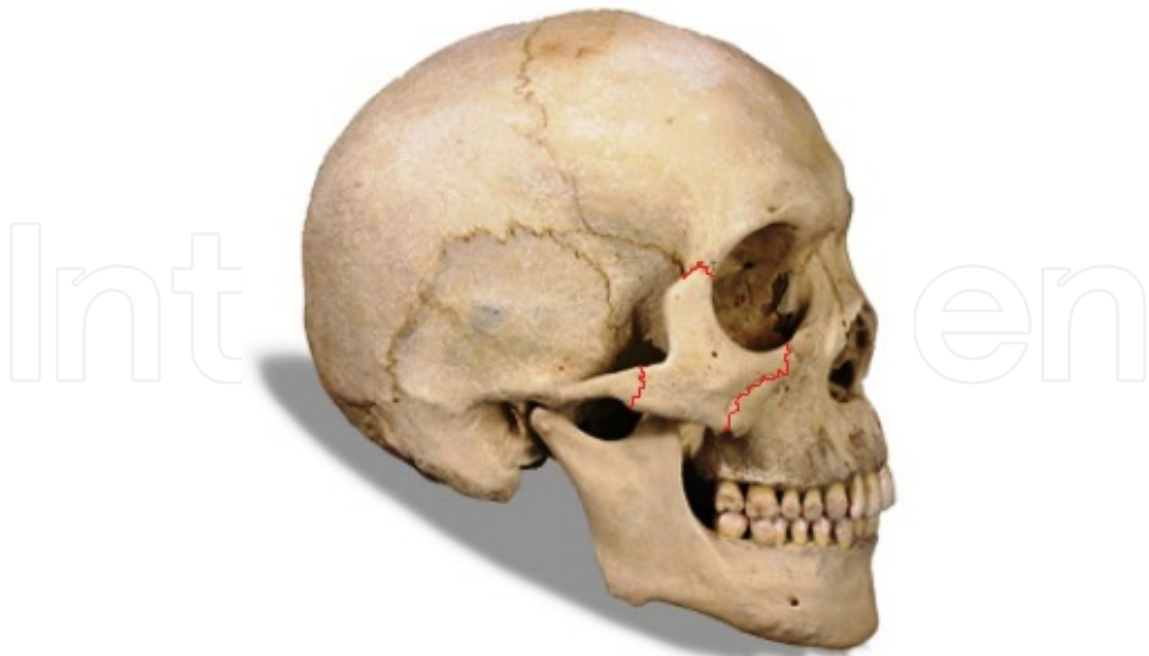

Figure 13. Zygomatic complex fracture

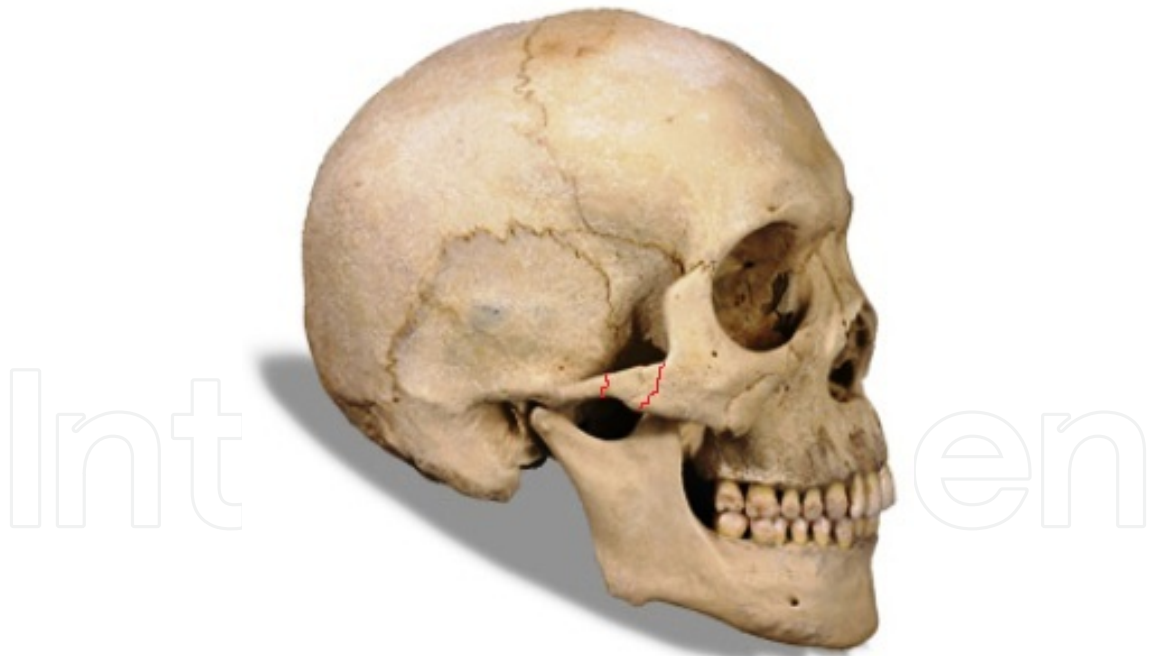

Figure 14. Isolated Zygomatic Arch fracture

in zygomatic bone fractures. Limitation of motion in the extraocular muscles and enophthalmos or exophthalmos should be noted, as they can be signs of fracture of the orbital floor or medial or lateral orbital walls. In such cases, ophthalmologic consultation should be consid-

ered before surgical intervention. An isolated zygomatic arch fracture typically has an M-shaped pattern, with two fragments collapsed medially and often impinging on the masseter muscle or even the muscular process of the mandible. Medial displacement of the zygomatic arch may cause mandibular trismus as a result of masseter muscle spasm or mechanical impingement of the coronoid process against the displaced segments. Direct lateral force causes an isolated zygomatic arch fracture or an inferomedially displaced zygomatic complex fracture; frontal force usually produces an inferoposteriorly displaced fragment. Extraoral step deformities of the zygomatic arch and inferior and superolateral orbital margins, as well as intraoral step deformities of the zygomaticomaxillary buttress, may be palpable if the region is free of edema. Axial and coronal CT images inhibit visualisation of the buttress of the midfacial skeleton. Three-dimensional images may be used to obtain additional information about the relationships of displaced and rotated fractured segments to surrounding bony structures. Plain radiography employing Waters' and Caldwell's views can also be used to detect zygomatic complex fractures. The submentovertex view is very helpful for the evaluation of the zygomatic arch and malar projection.

6.2. Treatment

The management of zygomatic bone fractures depends on the degree of displacement and the resultant aesthetic and functional deficits. Surgery can be delayed until the majority of facial edema is gone. Isolated zygomatic arch and zygomatic complex fractures with minimal or no displacement are not managed surgically. A soft diet restriction can help to avoid secondary fracture displacement. When displacement and minimal comminution are present, the Gillies technique is the standard reduction treatment for isolated zygomatic arch fractures [Figure 15]. In the Gillies approach, a 2-cm-long temporal incision is made behind the hairline, and the subcutaneous and superficial temporal fascia are dissected to the level of the temporalis muscle to reach the underlying temporal surface of the zygomatic bone; a zygomatic elevator is then used to reduce the arch fracture [25]. The use of a J-shaped hook elevator through a periauricular incision made anterior to the articular eminence and inferior to the zygomatic arch is an alternative approach for reducing zygomatic arch fractures. This approach is faster than the Gillies approach, but it can easily cause damage to the frontal branches of the facial nerve. Fixation of zygomatic arch fractures can be performed by packing the temporal fossa or using transcutaneous circumzygomatic arch wires while providing support with metal or aluminum finger splints. Open reduction is rarely performed in highly comminuted zygomatic arch fractures because it requires a time-consuming coronal incision.

Displaced zygomatic complex fractures require open reduction and internal fixation. Miniplates and microplates provide the best results with minimal complications. A useful option for displaced zygomatic fractures is the application of a transcutaneous Carroll–Girard screw in the malar region [Figure 16].

This technique enables excellent manipulation of the fractured segment for reduction. Reduction of the frontozygomatic suture, zygomaticomaxillary buttress, and inferior orbital rim should be the main goal of the treatment protocol. The perfect reduction of these three points of reference allows proper positioning of the fractured segment. The location and

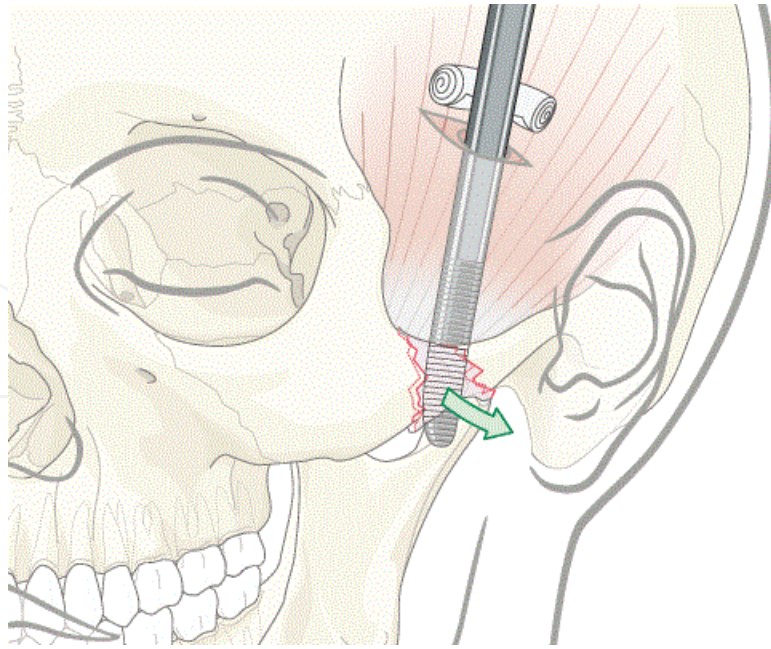


Figure 15. Gillies approach to zygomatic arch (Figure adapted from www.aofoundation.org)

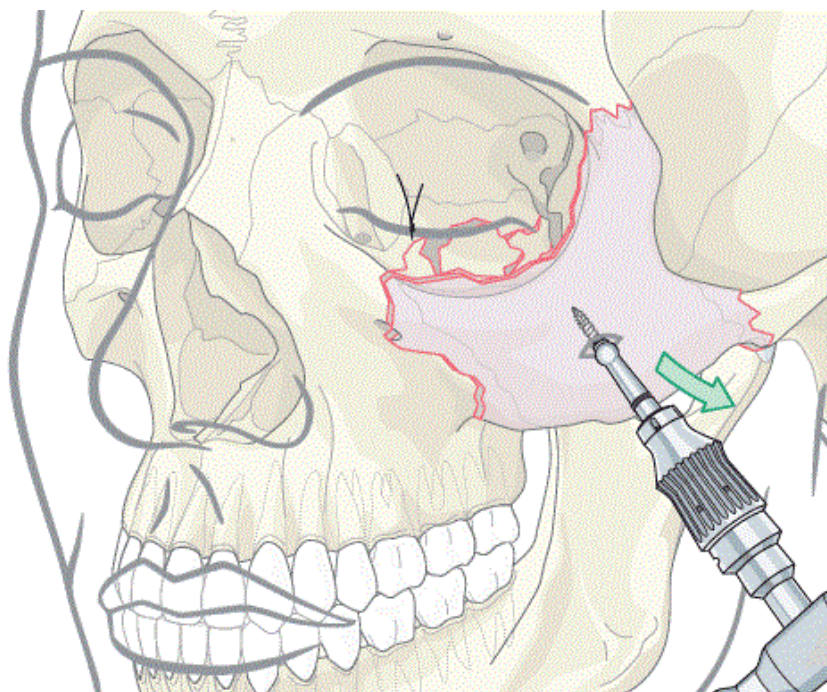


Figure 16. Use of Carroll-Girard screw (Figure adapted from www.aofoundation.org)

number of fixation sites depend on the fracture pattern, location, direction of displacement, and degree of instability. In more severe fractures, perfect reduction can be achieved with the use of the zygomatic arch as a fourth reference point. The zygomaticomaxillary buttress should be reduced first *via* an intraoral approach, while this structure is easy to reach; this technique

leaves no scar and may achieve reduction of the entire fractured segment. The zygomaticomaxillary buttress is approached surgically through a 3–5-mm-long incision in the maxillary vestibule above the mucogingival junction, extending from the canine region to first molar region. The protocol for minimally comminuted and displaced fractures should be temporary edema of the zygomaticofrontal suture with wires, reduction of the zygomaticomaxillary buttress and inferior orbital rim, and then replacement of the temporary zygomaticofrontal edema with a plate. The zygomaticofrontal suture is approached surgically through a lateral eyebrow incision, and the inferior orbital rim is approached *via* subciliary and transconjunctival incisions [Figure 17-19].

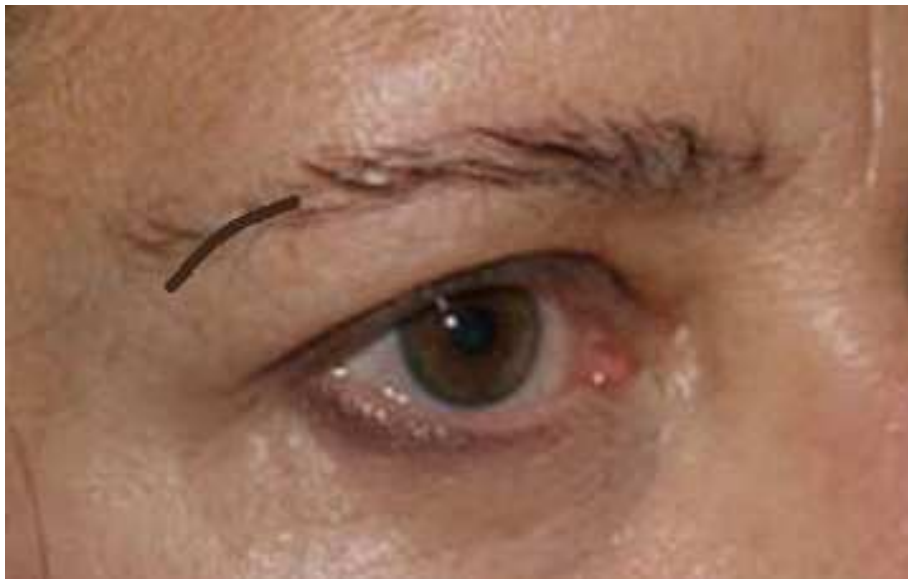

Figure 17. Lateral eyebrow incision line

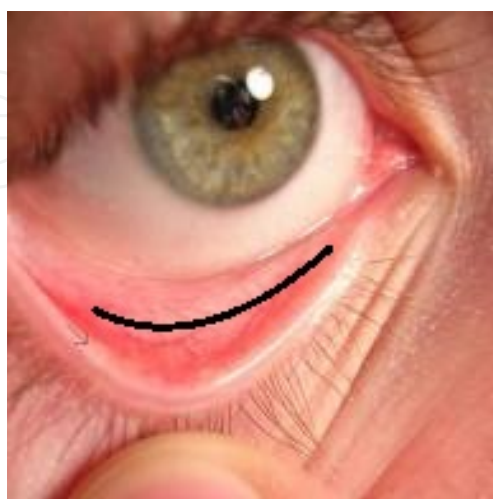

Figure 18. Transconjunctival incision line

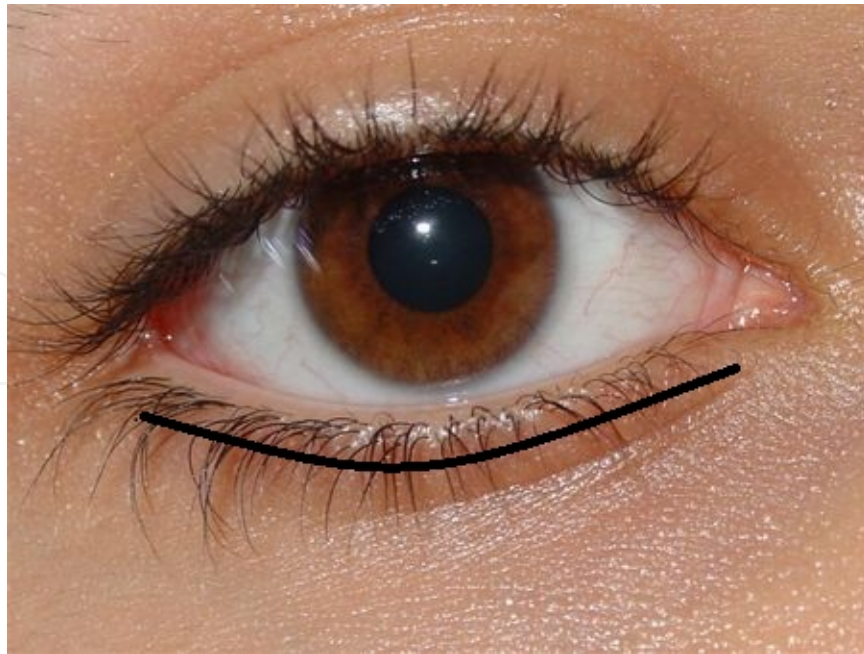

Figure 19. Subciliary incision line

In complex and highly comminuted fractures, the zygomatic arch should be reconstructed first; a coronal flap is usually used to gain access to this structure.

6.3. Complications

Restoration of the natural contour of the zygoma is the key to restoring facial projection in patients with displaced and comminuted fractures. Inadequate flattening the zygomatic arch and failure to achieve optimal rotation of the zygomaticomaxillary complex result in malar eminence flattening, asymmetry, and widening of the face. Inadequate reduction or edema of segments may cause malunion.

Poor or excessive reconstruction of the orbital rim should be avoided because an increase in orbital volume can cause enophthalmos and a decrease can cause exophthalmos. Diplopia can be caused by edema, hematoma, injury to cranial nerves 3, 4, or 6, and damage to extraocular muscles, and may heal spontaneously except in the latter case.

Although damage to the zygomaticomaxillary and zygomaticofacial nerves is less common, zygomaticomaxillary complex fractures often cause damage to the infraorbital foramen. Anaesthesia of the lower eyelid and malar and upper lip areas is common in infraorbital nerve injuries. Proper reduction of the fractured segments usually minimizes the risk of permanent symptoms. Blindness immediately after surgery may indicate impingement of the orbital apex contents by a bony fragment. Retrobulbar hematomas rarely develop, but compression of the central retinal artery causing disruption of the retinal circulation may lead to irreversible ischaemia of the optic nerve and permanent blindness.

Patients with zygomatic fractures may suffer from trismus, which may be caused by impingement of the zygomatic bone on the coronoid process of the mandible or ankylosis of the

coronoid process to the zygomatic arch. If a previous zygomatic bone or arch fracture has been reduced improperly, the zygomatic bone should be repositioned *via* osteotomy; otherwise, coronoidectomy is the most common solution.

7. Orbital fractures

Isolated orbital fracture is not a common type of midfacial fracture, but the incidence of midfacial fractures involving the orbit is high because all Le Fort II and III fractures and those of the naso-orbito-ethmoidal and zygomaticomaxillary complexes involve orbital injury. Orbital fractures may affect the internal and/or external orbital frame. Thus, fractures of the orbital region can be discussed in the context of zygomaticomaxillary complex, naso-orbito-ethmoidal complex, and isolated orbital fractures.

7.1. Clinical examination

As discussed above, zygomaticomaxillary complex fracture is the most common fracture type with orbital involvement. Like naso-orbito-ethmoidal fractures (discussed below), zygomaticomaxillary complex fractures are caused by blunt force applied directly to the bone. Isolated fractures of the orbit often occur as a result of direct force to the globe of the eye. A sudden increase in intraorbital pressure creates an outward force that causes fracture of the weakest bony structures in internal orbital walls. Isolated orbital fractures can be classified as 'blow-out' or 'blow-in'. Most blow-out fractures affect the anteroinferomedial aspect of the orbital cavity and displace the orbital globe posteromedially and inferiorly. A significant increase in the volume of the orbital cavity results in enophthalmos of the globe. Herniation of the orbital roof and globe to the maxillary sinus occurs in such fractures. When an isolated fracture is caused by low-energy force, linear fracture of the orbit may be detected. Linear fractures retain periosteal attachments and do not cause orbital globe herniation to the maxillary sinus or complete perforation of the maxillary sinus roof. More severe trauma causes a complex fracture involving two or more orbital walls. In complex internal orbital fractures, the globe is often displaced posteriorly and the optic canal may be involved. Blow-in fractures affect the orbital roof and may be diagnosed after severe injury of the anterior skull base. Rupture of the orbital roof reduces the orbital volume and often causes anteroinferior globe displacement.

The affected region should be inspected carefully to identify the presence of edema, chemosis, ecchymosis, lacerations, ptosis, asymmetric lid drape, canalicular injury, and/or canthal tendon disruption. Any step deformity or mobility around the orbital rim should be palpated before edema develops in surrounding tissues. Neurosensation of the infraorbital and supraorbital nerves should be tested. Ophthalmologic consultation is very important and necessary. Limitation of ocular movements can be caused by mechanical entrapment or neurologic injury. Three-dimensional CT and magnetic resonance imaging are preferred for the evaluation of orbital fractures. Waters' projection is the most useful plain radiographic modality because it enables visualisation of the orbital floor and roof. Ophthalmic ultrasonography and color Doppler imaging can provide additional information.

7.2. Treatment

Subciliary and transconjunctival incisions are the most aesthetically acceptable approaches to the orbital floor. Linear injuries of the orbital floor require no intervention unless they show signs of soft-tissue entrapment in fractured but self-reduced sites. In patients with blow-out or blow-in fractures, soft- and hard-tissue reduction and reconstruction are necessary. Grafting of the injured site with autografts, allografts, or alloplastic materials may be necessary to achieve proper anatomic reduction and stability and to prevent soft-tissue contraction. The iliac crest and nasal septal cartilage are the best donor sites for autografts, and the use of alloplastic titanium mesh can be successful in cases requiring extra support.

7.3. Complications

Most internal orbital fractures cause volumetric contraction or expansion of the orbital cavity, which may lead to diplopia, enophthalmos, exophthalmos, proptosis, and/or extraocular muscle imbalance. Extraocular muscle imbalance and diplopia can be the result of extraocular muscle entrapment or neuropathy of the 3rd to 5th cranial nerves. An increase in orbital volume causes enophthalmos, which may occur weeks or months after injury.

For some challenging fractures of the orbital floor, the transconjunctival approach may be safer than other methods. The placement of a transconjunctival incision at the conjunctival fornix appears to minimize the risk of eyelid malposition. A transantral endoscopic approach is an alternative method that avoids potential damage caused by lower-lid incisions.

8. Naso-orbito-ethmoidal fractures

Naso-orbito-ethmoidal fracture can occur either in isolation or in association with other midfacial fractures. Most associated injuries affect the cervical spine and ocular and intracranial regions. This fracture type is caused by focused high-energy transfer to the intercanthal area. Because the naso-orbito-ethmoidal area contains several types of tissue (bone, cartilage, tendons, ocular tissue) restoration is challenging.

8.1. Clinical examination

Naso-orbito-ethmoidal fractures are characterized by three major post-injury symptoms: increased intercanthal distance, diminished nasal projection, and impaired nasofrontal and lacrimal drainage.

Markowitz *et al.* [26] developed the most widely used classification system for naso-orbito-ethmoidal fractures, which distinguishes three fracture types [Figure 20]:

- Type I: the medial canthal tendon is attached to a single, large central fragment
- Type II: the medial canthal tendon is attached to a comminuted but manageable central fragment; the canthal tendon remains attached to a fragment that is sufficiently large to allow osteosynthesis

- Type III: the medial canthal tendon is attached to a comminuted and unmanageable central fragment; the fragments are either too small to allow osteosynthesis or completely detached.

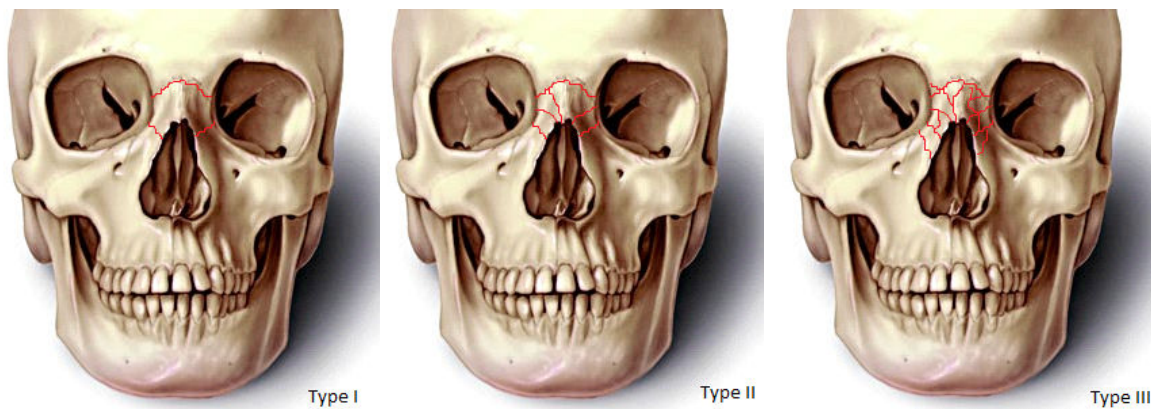


Figure 20. Classification of Nasoorbitoethmoidal fractures

Periorbital ecchymosis, subconjunctival hemorrhage, and pain are the most common signs and symptoms of naso-orbito-ethmoidal fractures. Other signs and symptoms include skin and mucosal lacerations, epistaxis, nasal obstruction, edema, telecanthus, and increased canthal angles. Depression of the bony segment causes internal and external nasal cosmetic deformities. Edema may obscure such depression for up to 5 days, and most surgeons recommend the postponement of surgery until the edema has resolved. The impaction of bony segments to the orbit may cause exophthalmos, proptosis, or ptosis. Fractures of cribriform plate and posterior wall of the frontal sinus may cause cerebrospinal fluid leakage. Nasal bone mobility, traumatic telecanthus, crepitus, and depressibility of the area are the clinical digital-examination findings for naso-orbito-ethmoidal fractures.

Increased intercanthal distance, termed telecanthus, is a key deformity resulting from naso-orbito-ethmoidal injury. Normal intercanthal distances are 29–36 mm in males and 29–34 mm in females; a distance exceeding 40 mm is classified as telecanthus and may indicate that surgical treatment is required. The medial canthal tendon is a very important anatomic factor in naso-orbito-ethmoidal injuries resulting in telecanthus. The pretarsal portions of the orbicularis oculi muscle in the upper and lower lids unite at the canthus to form the medial canthal tendon. The superficial portion of this tendon provides support to the eyelids and maintains the integrity of the palpebral fissure. Restoration of this component after canthal detachment is critical for maintaining proper eyelid appearance. The deeper portion, also called Horner's muscle, attaches to the posterior lacrimal crest and assists in the movement of fluid through the lacrimal system. Disruption of the medial canthal tendon causes contraction of the orbicularis oculi muscle, increasing the intercanthal distance and laterally displacing the rounded contour of the medial palpebral fissure. The 'bowstring test' is a useful method of assessing the status of the medial canthal tendon's attachment to the bone. This test involves lateral pulling of the lid while palpating the tendon area to detect movement of fracture segments [27] [Figure 21].

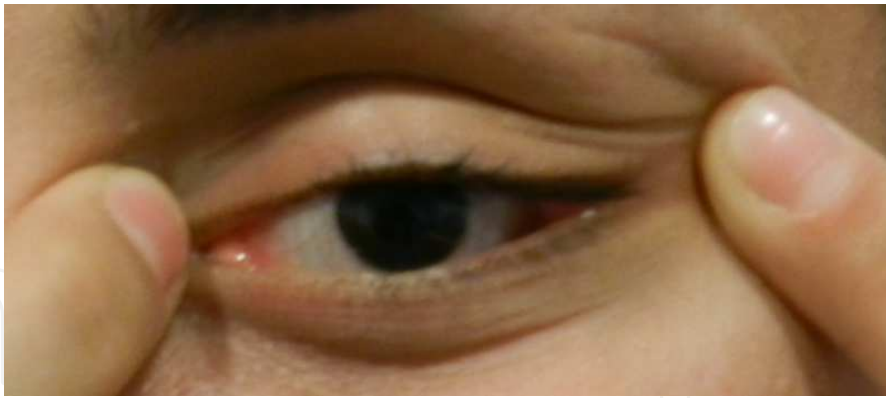

Figure 21. Bowstring test

Two- and three-dimensional CT using axial and coronal views are the most valuable imaging methods for the diagnosis of naso-orbito-ethmoidal fractures. The use of conventional imaging techniques is not recommended because these modalities do not provide adequate information.

8.2. Treatment

The goals of naso-orbito-ethmoidal fracture treatment are the resolution of the three major issues described above: Establishment of proper nasal projection, narrowing of the intercanthal distance, and establishment of the nasofrontal and lacrimal fluid route. The surgeon should seek to achieve satisfactory results in a single surgery because corrective secondary surgery may cause scarring and fibrosis. For this reason, most authors have advocated the postponement of surgery for 3–7 days to allow for the recession of edema. For naso-orbito-ethmoidal fractures involving a single fragment (type I), treatment can be attempted with closed reduction and the provision of intranasal packing support. If the fragment cannot be reduced satisfactorily by closed reduction, the operation should be converted immediately to an open reduction to avoid the need for secondary surgery. In most cases, a transoral approach is sufficient to reach the injured area without an additional incision.

Proper restoration of types II and III naso-orbito-ethmoidal fractures usually require wide access, which can be provided only by a coronal flap. Wide exposure of the nasal bones and medial orbital walls can be achieved readily. When necessary, a transoral approach can be used to access the paranasal areas and a transconjunctival approach can be used to expose the inferior orbital rim or inferomedial wall. Existing lacerations can also be used to access the injured area. Transcutaneous approaches are not considered to be acceptable because they cause facial scarring.

In severe naso-orbito-ethmoidal injuries, nasal dorsal strut grafting is often required to re-establish support for the entire nose. This graft is cantilevered from the stable frontal bone and placed in the subcutaneous plane, extending inferiorly to the nasal tip.

When the medial canthal tendon is detached completely or attached to an unusable bone fragment, its proper position must be secured immediately using medial canthopexy. The

medial canthal tendon should be reduced into a position slightly posterosuperior to the posterior lacrimal crest. The tendon is then sutured with a wire passing transnasally to a cantilevered miniplate on the opposing (undamaged) side. The canthopexy should be positioned sufficiently deep in the orbit to achieve the proper shape of the palpebral fissure and lower lid, as the superficial portion of the medial canthal tendon secures the position of the lower lid and contour of the palpebral fissure. Proper positioning of the medial canthal tendon will achieve correct lacrimal fluid drainage, which is aided by the deep portion of the tendon. When nasofrontal obstruction is a concern, endoscopic frontal sinus surgery can be indicated to re-establish nasofrontal drainage. The medial canthal tendon should be slightly over-reduced in canthopexy procedures to compensate for remodelling of related tissues.

8.3. Complications

Cosmetic deformities are foreseeable after nasal and naso-orbito-ethmoidal injuries. Postoperative septal hematoma, septal abscess, and/or destructive fracture of the septal cartilage/bone are the postoperative causes of nasal deformity. Massive comminution of the naso-orbito-ethmoidal complex is classically associated with saddle nose deformity. Bone grafting is required in most patients to establish proper nasal projection, symmetry, and contour. However, even bone grafts can be associated with potential resorption problems in the long term. Depending on the fracture level, cartilage or bone grafts and nasal implants can be used to improve the appearance of these deformities.

Septal deviation due to inadequate closed reduction often results in external nasal asymmetry. Direct septal visualisation *via* the open rhinoplasty approach is preferred for the correction of this defect.

After naso-orbito-ethmoidal injury, scar contracture results in cosmetic and functional deformities. Thus, secondary surgery should be avoided because it may result in scarring.

Open reduction and internal fixation procedures often damage the medial canthal tendon or nasolacrimal apparatus. As a result, epiphora related to nasolacrimal duct obstruction can be an issue. Intubation or stenting of the lacrimal duct may be necessary in such cases.

9. Midfacial fractures in children

Midfacial fractures are not common in children; they account for only 1–8% of pediatric fractures [28-31] and usually affect the mandible. This low incidence is related to the protection provided by the mandible and cranium, which absorb most of the traumatic impact, and to the elastic nature of midfacial bones and flexibility of osseous suture lines [32]. Children form a distinct patient group in maxillofacial surgery due to significant differences between the facial skeletons of children and adults. Depending on the patient's age, these differences include small bone size, small paranasal sinus volume, growth potential, the presence of tooth germs in alveoli during primary and mixed dentition stages, a more rapid healing process compared with adults, and difficulty with cooperation resulting in the need for general

anaesthesia in more cases than in adults [33]. The proportion of children in whom midfacial fractures are identified has increased over time, probably due to the increased use of adequate imaging modalities [34]. CT has largely supplanted standard radiography as the preferred imaging method for pediatric facial trauma.

The presence of tooth germs in alveoli potentially creates zones of weakness in the jaws and limits the placement of certain plate and screw types, given the need to avoid damage to the developing dentition. The treatment of pediatric patients with midfacial fractures using intermaxillary fixation is also quite difficult, and erupting or exfoliating teeth can be an issue. On the other hand, the on-going processes of tooth eruption and exfoliation may compensate for minor inaccuracies in reduction and fixation. Recognition of the differences between children and their adult counterparts is important in facial rehabilitation.

Several aspects of dentoalveolar trauma management in children differ from that in adults. Developing roots have open apices, and the preservation of pulp vitality is important. In complicated crown and crown–root fractures, pulpotomy can be performed 1–2 mm below the exposed pulp tissue and $\text{Ca}(\text{OH})_2$ or mineral trioxide aggregate can be applied. The second step in such cases is composite restoration or bonding of the crown fragment to the tooth. If the pulp is necrotic, apexification with intracanal application of $\text{Ca}(\text{OH})_2$ must be used instead of pulpotomy. In pediatric cases of intrusion, spontaneous re-eruption may occur. Orthodontic repositioning can be a second treatment plan unless movement is observed within about 3 weeks. In the pediatric dentition, osseous replacement in ankylosis occurs much faster than in adults; dentoalveolar ankylosis usually interferes with alveolar process growth, and the tooth might be malpositioned.

Fractures in the maxillary region tend to be less comminuted in children than in adults because children's paranasal sinuses are not fully developed. Open reduction and internal fixation are the preferred treatment methods, but intermaxillary fixation may be necessary in some cases. Avoiding damage to permanent tooth germs is a mandatory indication for closed reduction. Intermaxillary fixation with arch bars presents some difficulties in patients with mixed dentition, but the fixation period can be shorter than in adults. Teeth may be avulsed by the force of arch bars, and the fixation of arch bars to the teeth may not provide adequate retention because of weak and undeveloped roots. For this reason, the fabrication and use of Gunning splints to provide retention from the zygomatic arches, piriform apertures, and mandible *via* circumferential wires is recommended when intermaxillary fixation is necessary. As in adults, restoration of the normal anatomic position of the midfacial skeleton in children generally requires open reduction and stable fixation with miniplates and screws. In pediatric Le Fort II and III fractures, open reduction and internal fixation are necessary to re-establish proper anatomic and functional relationships. Pediatric fractures in the maxillary region are often of the greenstick type, which increases the complexity of fragment reduction. Because a greenstick fracture line limits fragment movement, proper reduction may require osteotomy.

Paediatric orbital fractures resulting in herniation and extraocular muscle entrapment require immediate intervention and even orbital exploration. Fractures of the orbital floor or wall in children heal rapidly, increasing the risks of scar cicatrization and related ischemic necrosis of entrapped tissues.

Because the development of the nasal septum is a very important factor in facial growth, post-traumatic septal hematoma, which may cause septal necrosis and resorption, should not be ignored because it may result in saddle nose deformity.

Author details

Sertac Aktop*, Onur Gonul, Tulin Satilmis, Hasan Garip and Kamil Goker

Department of Oral and Maxillofacial Surgery, Marmara University, Istanbul, Turkey

References

- [1] Gassner R, Tuli T, Hachl O, Rudisch A, Ulmer H. Cranio-Maxillofacial Trauma: A 10 Year Review Of 9543 Cases With 21 067 Injuries. *Journal Of Cranio-Maxillofacial Surgery*. 2003;31:51–61
- [2] Thomas DW, Hill CM: Etiology And Changing Patterns Of Maxillofacial Trauma. In: Booth PW, Schendel SA, Hausamen JE (Eds) *Maxillofacial Surgery*, Vol. Churchill Livingstone, 3, 2000
- [3] Mouzakes J, Koltai PJ, Kuhar S, Bernstein DS, Wing P, Salsberg E: The Impact Of Airbags And Seat Belts On The Incidence And Severity Of Maxillofacial Injuries In Automobile Accidents In New York State. *Arch Otolaryngol – Head Neck Surg*. 2001;127:1189–1193
- [4] Cook H E, Rowe M. A Retrospective Study Of 356 Midfacial Fractures Occurring In 225 Patients. *J Oral Maxillofac Surg*. 1990;48:574–578
- [5] Girotto JA, Mackenzie E, Fowler C, Redett R, Robertson B, Manson PN: Long-Term Physical Impairment And Functional Outcomes After Complex Facial Fractures. *Plast Reconstr Surg*. 2001;108:312–327
- [6] Afzelius LE, Rosen C: Facial Fractures: A Review Of 368 Cases. *Int J Oral Surg*. 1980;9:25
- [7] Motamedi M H K. An Assessment Of Maxillofacial Fractures: A 5-Year Study Of 237 Patients. *J Oral Maxillofac Surg*. 2003;61:61–64
- [8] Ansari M H. Maxillofacial Fractures In Hamedan Province, Iran: A Retrospective Study (1987–2001). *Journal Of Cranio-Maxillofacial Surgery*. 2004;32, 28–34
- [9] Thorén H, Snäll J, Salo J, Taipale L S, Kormi E, Lindqvist C, Törnwall J. Occurrence And Types Of Associated Injuries In Patients With Fractures Of The Facial Bones. *J Oral Maxillofac Surg*. 2010;68:805–810

- [10] Banks P, Brown A: Etiology, Surgical Anatomy And Classification. In: Banks P, Brown A (Eds), *Fractures Of The Facial Skeleton*. Philadelphia, USA: Elsevier, 1e4, 2001
- [11] Shankar A N Et Al.. The Pattern Of The Maxillofacial Fractures E A Multicentre Retrospective Study. *Journal Of Cranio-Maxillo-Facial Surgery* Xxx (2012) 1-5 Doi: 10.1016/J.Jcms.2011.11.004
- [12] Simpson DA, Mclean AJ: Mechanisms Of Injury. In: David DJ, Simpson DA (Eds) *Cranio-maxillofacial Trauma*, Vol. 101. Churchill Livingstone, 1995
- [13] Killey H C. *Fractures Of The Middle Third Of The Facial Skeleton*. Bristol: John Wright & Sons Limited, 1977
- [14] Norton N S. *Netter's Head And Neck Anatomy For Dentistry*. Philadelphia: Saunders Elsevier, 2007
- [15] Teasdale G, Jennett B. Assessment of coma and impaired consciousness: a practical scale. *Lancet* 1974;2:81-4.
- [16] Z. Nya'ra'dy, E. Orsi, K. Nagy, L. Olasz, J. Nya'ra'dy: Transgingival lag-screw osteosynthesis of alveolar process fracture. *Int. J. Oral Maxillofac. Surg.* 2010; 39: 779-782.
- [17] Ellis E III. Soft Tissue and Dentoalveolar Injuries. In: Hupp J R et al. (ed.). *Contemporary Oral and Maxillofacial Surgery Fifth Edition*. Missouri: Mosby Elsevier; 2008. p474-7
- [18] Fonseca RJ, Marciani RD, Hendler BH. Oral and maxillofacial surgery, trauma. Vol 3. Diagnosis and management of dentoalveolar injuries. Philadelphia (PA):W.B. Saunders Co; 2000. p. 48-50.
- [19] Snawder KD, Bastawni AE, O'Toole TJ. Tooth fragments lodged in unexpected areas. *JAMA* 1976;233:1378-9.
- [20] Leather D L, Gowans R E. Management of Alveolar and Dental Fractures, In: Miloro M (ed.) *Peterson's Principles of Oral and Maxillofacial Surgery Second Edition*. London: BC Decker Inc; 2004; 383-400.
- [21] Andreasen JO, editor. *Traumatic injuries of the teeth*. 1st ed. Philadelphia (PA): W.B. Saunders; 1972.
- [22] Le Fort R. Etude experimentale sur les fractures de la machoire superiore. *Rev Chir* 1901; 23:208-27.
- [23] Le Fort R. Etude experimentale sur les fractures de la machoire superiore. *Rev Chir* 1901;23:360-79.
- [24] Le Fort R. Etude experimentale sur les fractures de la machoire superiore. *Rev Chir* 1901;23:479-507.

- [25] Gillies HD, Kilner TP, Stone D. Fractures of the malarzygomatic compound, with a description of a new x-ray position. *Br J Surg* 1927;14:651.
- [26] Markowitz BL, Manson PN, Sargent L, et al. Management of medial canthal tendon in nasoethmoid orbital fractures: the importance of the central fragment in classification and treatment, *Plast Reconstr Surg*. 1991;87:843-853
- [27] Furnas DW, Bircoll MJ. Eyelash traction test to determine if the medial canthal ligament is detached. *Plast Reconstr Surg* 1973;52:315-7.
- [28] Rowe NL. Fractures of the jaws of children. *J Oral Surg*. 1969;27:497-507
- [29] Posnick JC, Wells M, Pron GE. Pediatric facial fractures: evolving patterns of treatment. *J Oral Maxillofac Surg*. 1993;51:836-844
- [30] Gassner R, Tuli T, Höchl O, et al. Craniomaxillofacial trauma in children: a review of 3385 cases with 6060 injuries in 10 years. *J Oral Maxillofac Surg*. 2004;62:399-407
- [31] Qaqish C, Caccamese Jr JF. Pediatric Mid-face Fractures. In: Bagheri SC, Bell RB, Khan HA (ed.). *Current therapy in oral and maxillofacial surgery*. Missouri: Saunders Elsevier; 2012.p851-8
- [32] Ferreira P, Marques M, Pinho C, Rodrigues J, Reis J, Amarante J. Midfacial fractures in children and adolescents: a review of 492 cases. *British Journal of Oral and Maxillofacial Surgery*. 2004;42:501 – 505
- [33] Iatrou I, Theologie-Lygidakis N, Tzerbos F. Surgical Protocols And Outcome For The Treatment Of Maxillofacial Fractures In Children: 9 Years' Experience. *Journal Of Cranio-Maxillo-Facial Surgery*. 2010;38:511-516
- [34] Thorén H, Iso-Kungas P, Iizuka T, Lindqvist C, Törnwall J. Changing trends in causes and patterns of facial fractures in children *Oral Surg Oral Med Oral Pathol Oral Radiol Endod*. 2009;107:318-324.

IntechOpen

