

We are IntechOpen, the world's leading publisher of Open Access books Built by scientists, for scientists

4,800

Open access books available

122,000

International authors and editors

135M

Downloads

Our authors are among the

154

Countries delivered to

TOP 1%

most cited scientists

12.2%

Contributors from top 500 universities



WEB OF SCIENCE™

Selection of our books indexed in the Book Citation Index
in Web of Science™ Core Collection (BKCI)

Interested in publishing with us?
Contact book.department@intechopen.com

Numbers displayed above are based on latest data collected.

For more information visit www.intechopen.com



Diagnosis and Management of Temporomandibular Disorders

Fina Navi, Mohammad Hosein Kalantar Motamedi,
Korosh Taheri Talesh, Esshagh Lasemi and
Zahra Nematollahi

Additional information is available at the end of the chapter

<http://dx.doi.org/10.5772/55018>

1. Introduction

Temporomandibular disorder (TMD) is one of the most common disorders in the maxillofacial region which usually presents with pain, unusual sounds, discomfort in chewing and locking of the jaw. TMD patients comprise a considerable proportion of patients seeking treatment; early diagnosis is important because it is proven that acute TMD responds well to treatment in contrast to chronic TMD. True diagnosis and treatment of TMD can be difficult, as these patients often suffer from some other disorder at the same time. In these cases, a successful treatment is due to true diagnosis of all initiating factors, predisposing and perpetuating factors and treatment of other established disorders. An important point is the close relation of intrajoint disorders to disorders of masticatory muscles. Today, it has been proven that disorder of masticatory muscles can lead to TMD. The opposite of this, is also true. Correct diagnosis is essential. The diagnostic steps and differential diagnosis of TMD and the treatment protocols from supportive treatment, splint therapy and physiotherapy to temporomandibular joint (TMJ) surgeries are explained herein. We hope this chapter can help better understand TMJ disorders, diagnosis and recognition of the signs and symptoms of disorders of the temporomandibular and masticatory system.

2. Temporomandibular disorder (TMD)

TMD is a general term including clinical problems which affect masticatory muscles, TMJ and adjacent structures. TMD is the most common non-dental pain in the maxillofacial region. The

most common sign of TMD is pain in masticatory muscles, or preauricular region and on the TMJ which becomes severe when chewing or upon other mandibular movements. TMD patients have limitation and asymmetry in mandibular movements. They often have clicking, popping, grating and crepitus. Patients may complain from headache, earache and pain in the mandibulofacial region. Masticatory muscle hypertrophy and an unusual facet of occlusal surfaces of the dentition due to excessive mandibular movements such as bruxism or grinding may be present. Management of TMJ disorders usually includes finding the cause or etiology. Parafunction and trauma are common causes of TMD. Stress and mental problems are secondary aggravating factors. [1,2]

2.1. History

After initial studies in 1934, Costen proposed that patients suffering from auricular pain, pressure and fullness in the ear and swallowing problems (Costen syndrome) improve by occlusion correction. In the 1960s, the quality of clinical examinations and scientific studies improved; the importance of occlusion in TMD etiology in 1970 was studied. Methods including tomography, arthrography, computed tomography (CT) scan and magnetic resonance imaging (MRI) lead to improvements in examination of intracapsular structures. Today the information in this field show that patients with orofacial pains may suffer from disorders such as systemic, neuromuscular, vascular, and mental or a combination of disorders associated with TMD; some headway in pain mechanism, neurology, physiology and neuropharmacology have been made. Different studies demonstrated that TMD treatment has changed based on the diagnosis of the etiology and stage of the disorder. [1,2]

2.2. TMJ anatomy

Temporomandibular joint is the junction site of the mandibular condyle to skull base or glenoid fossa of the temporal bone. A disc separates the two bones. The part of the disc which is in contact with mandibular condyle bone consists of fibrous connective tissue without any nerve or vessel. This joint is a compound one. The disc is divided into three parts, in sagittal view: anterior, posterior and middle. The middle zone is the thinnest part. The disc becomes thicker in the anterior and posterior parts. In coronal view, the medial part of the disc is thicker than the lateral part (Fig. 1). [1]

Disc shape is determined by condyle morphology and mandibular fossa. The disc may become displaced or destroyed via degenerative forces. In the posterior part, the disc is attached to a loose connective tissue of nerve and vessels named retrodiscal tissue. In the superior posterior part, it is attached to a connective tissue full of elastic bands named superior retrodiscal layer or bilaminar zone. This tissue connects the disc to the tympanic bone posteriorly. Below this, there is the inferior retrodiscal layer which connects the inferior border of the posterior edge of the disc to the posterior part of condyle joint surface. Inferior disc layer and superior retrodiscal tissue are made of collagen and elastic fibers, respectively. Anteriorly to the disc, superior and inferior adhesions of it connect to the capsular ligament. Both of these adhesions are made of collagen fibers. Between the capsular ligaments, the disc is adherent to fibers of the superior or lateral pterygoid muscle. The disc adheres to the capsular ligament, not only anteroposterior-

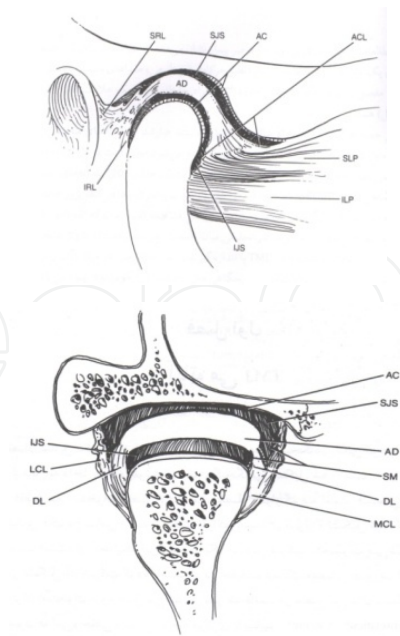


Figure 1. TMJ in sagittal and coronal views.

ly, but also mediolaterally. The joint is divided into two separate and distinct spaces. The superior space is located between the glenoid fossa and superior part of the disc; the inferior disc space lies between the disc and condyle. Internal surfaces of superior and inferior spaces are lined with special endothelial cells which secrete synovial fluid. This fluid has two functions: 1- Molecular transport and metabolism and 2- Lubrication of joint surfaces; the fluid is secreted on the joint surfaces under pressure and results in friction reduction. During function, forces entering to the joint surfaces lead to movement of this fluid into intrajoint tissues. In coronal view, the condyle has a medial and lateral pole; the medial pole is thicker than the lateral one. The TMJ is supported by three major and two minor ligaments. [1,2]

Major ligaments are:

1. Collateral ligaments
2. Capsular ligament
3. Temporomandibular ligament

Minor ligaments are:

1. Sphenomandibular ligament
2. Stylomandibular ligament

2.3. TMD etiology

TMD is considered as a multifactorial disorder and there is no special or individual cause for it. There are factors which can damage the balance in TMJ and the masticatory system. Bone deformations, soft tissue metaplasia of TMJ and muscle activity reduction are often adaptive

responses to changes. Hyperactivity of masticatory muscles resulting from parafunctional habits can lead to adaptive responses in dynamic balance because of hyperactivity and high load in the long term. Excessive changes in any of the above functions can lead to disability to adapt leading to TMJ disorders. For example, external trauma to any part results in injuries and disorders in normal joint function. Moreover, anatomic, systemic, pathophysiological and emotional causes can make the disorder more severe. [1,2]

2.3.1. Trauma

Nowadays, trauma is believed to be the initial cause of TMD. In fact, excessive trauma because of parafunctional forces can damage the masticatory system. These damages may result in joint injuries and pain in eating, smiling, yawning or excessive opening of the mouth. External trauma such as a punch, sport activities and injuries because of dental practice can lead to TMD. An important type of trauma is parafunctional trauma. Postural habits such as head forwarding or holding the phone handset place pressure on joints and muscles which result in musculoskeletal pains such as headaches in TMD patients. Additional habits and movements such as clenching, bruxism, attrition, lip biting and abnormal posture of the jaws common in society may lead to TMD. Although in some patients, it is known as an initial factor, parafunctional habits can be aggravated by stress, anxiety, sleeping and eating disorder. [1,2]

2.3.2. Anatomical factors

Anatomical factors affecting the TMJ can be hereditary, developmental or acquired. Some skeletal disorders such as small mandibular arch, class II occlusion etc. can affect the TMJ. However, millimetric changes in face vertical dimension, overbite, over jet or cross bite alone, are not the only cause of TMD. Today it is believed that dental occlusion disorders are second in importance.

2.3.3. Pathophysiological factors

These include: degenerative disorders, endocrine disorders, infections and blood disorders. It is revealed that viscosity of synovial liquid and its lack of lubricant property may be the initial cause of internal derangement and clicking.

2.3.4. Mental factors

Stress and mental stresses, can result in excessive load on masticatory system and parafunctional habits. Mental and emotional disorders can be predisposing TMD causes. So, it is highly important to consider the socio-mental factors upon examination of patients with TMD.

3. Temporomandibular disorders classification

Classifying TMDs, makes diagnosis easier. As there are numerous similar disorders and pains in the head and neck region, differential diagnosis is paramount (Table 1).

1. Deviation in form
2. Disc displacement with reduction
3. Disc displacement without reduction
4. Dislocation
5. Inflammatory conditions: Synovitis Capsulitis
6. Arthritides: Osteoarthrosis Osteoarthritides Polyarthritides
7. Ankylosis: Fibrosis Bony

Table 1. Classifying temporomandibular disorders

In differential diagnosis of TMJ disorders and pains, problems such as neoplasms, migraine, neuralgia and mental disorders should be considered. Moreover, it is noticeable that, growth-developmental disorders include aplasia, hypoplasia, hyperplasia and dysplasia can lead to TMJ problems.

Aplasia is defective growth of skull or mandible bones. These belong to one group of mandibular anomalies named hemifacial microsomia or first and second brachial arch syndrome. These are the most common developmental defects which have no articular fossa or eminence and the patient suffers from hearing problems.

Hypoplasia is low or incomplete growth of bones which is congenital or acquired. This is milder than aplasia. Many craniofacial anomalies include incomplete growth of cranial and mandibular bones, for example Treacher-Collins syndrome.

Hyperplasia is extensive growth of bones in congenital or acquired form which is unilateral in mandibular body, coronoid or condyle and leads to asymmetry. [1-3]

Dysplasia or fibrosis dysplasia is a benign disorder with defective mandible or maxilla growth which demonstrates itself as fibrotic connective growth. On radiography, it varies from lucent to ground glass.

Neoplasia may be benign or malignant. From the benign ones, osteoma, chondroma, osteoblastoma, chondroblastoma, ameloblastoma and synovial chondromatosis (which is common in TMJ) can be named. Malignant tumors such as osteosarcoma, Ewing sarcoma, chondrosarcoma, fibrosarcoma and adenocarcinoma are usually rare. About 1% of malignant tumors metastasize to jaws.

Fractures can result in displacement, damage of joint surfaces, ligaments and disc in combination with bleeding, then adhesion, or joint derangement can be expected.

In general, intrajoint disorders are divided into 6 classes:

1. Joint deformation (deviation in form)
2. Disc displacement which itself divided into: reducing and nonreducing
3. Joint dislocation
4. Inflammation
5. Articular bone inflammation (arthritides)
6. Ankylosis

Joint deformation is a mechanical painless disorder or deviation in the form of internal hard and soft tissues which may be developmental or acquired. Deviation in form is due to destructive forces resulting in physiologic deformation. Any growth or acquired remodeling and anatomic deformation that destroy joint surfaces results in mechanical interference that clinically results in joint noises or clicking during opening and closing.

Diagnostic criteria:

1. One of the most important signs of this disorder is deviation of the jaw on mouth opening and closing.
2. Complaint of mandibular movements. (i.e. locking or dislocation)
3. Repeatable joint noises during mandibular opening and closing.
4. Radiographic findings may demonstrate bony changes or deviation in joint form (i.e. flattening of condyle head or fossa)

Disc displacement: Disc displacement is the most common TMD in which the disc is displaced anteriorly. It may be with or without reduction.

Disc displacement or dislocation with reduction: Normal relationship between disc and condyle is altered on mouth opening. The disc is anterior to the condyle corrected upon translating (opening) and a click may be heard. Upon closing the condyle slips posteriorly and reaches the retrodiscal tissue and reduces. Usually, a second noise is also heard just before mouth closing but with less sound. These two noises or clicks are named reciprocal which are the results of disc displacement. As disc dislocation with reduction is common, some consider it as physiological. So, there may be no need to treat in a painless disorder. If any pain exists, it will be seen upon joint movements usually upon reduction. Severe trauma plays an important role especially in cases resulting in distraction or ruptured ligaments or capsule (Fig. 2, 3). [1,2]

Diagnostic criteria:

1. If pain exists, it becomes severe upon joint movements.
2. Repeatable noise usually upon opening and closing.

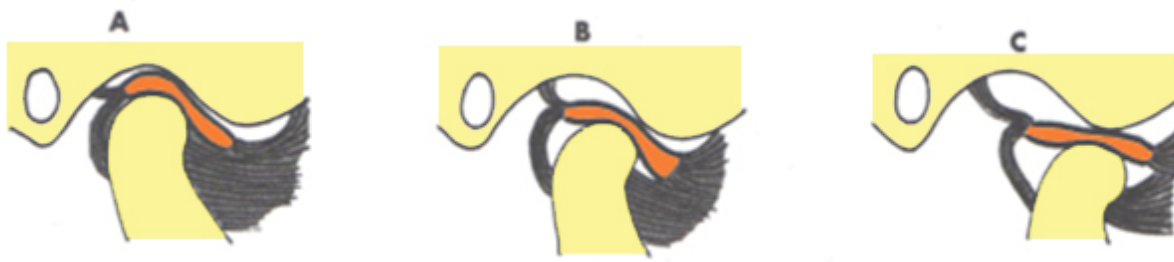


Figure 2. Normal relationship between condyle and disc; they move together.

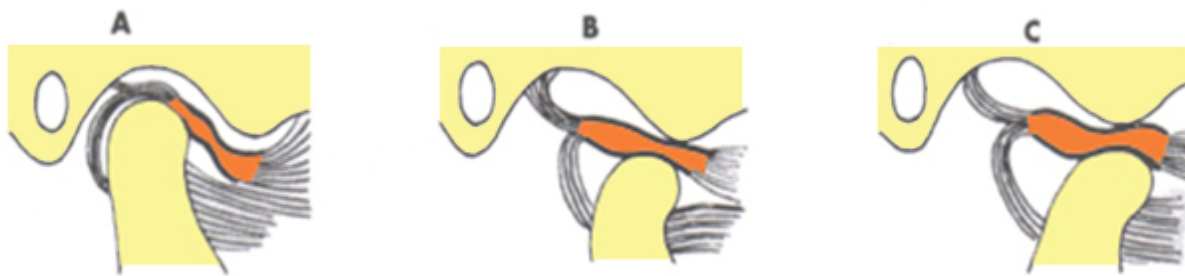


Figure 3. Disc displacement with reduction.

3. MRI images demonstrate disc dislocation which is greater upon opening.

Disc displacement or dislocation without reduction: In this state there is alteration in translating movements and an abnormal relationship remains in opening and closing. Thus, the disc does not return to its correct position and remains dislocated anteriorly without any correction during translating movement. The term “closed lock” is used to describe this disorder (the jaw is locked and will not open). The disc is stuck anterior to the condyle and maximum opening is only 10 to 15 mm. The type of condyle and disc movement is only rotational (hinge movement). During opening, the mandible deviates to the affected side. In lateral movements, inflammation and derangement is present in posterior disc tissues. Joint noises are absent here. In acute cases, pain becomes severe by forced mandibular movements. In chronic cases, pain is distinctively less and in many patients, there is no pain. In chronic cases, a history of joint noises and then limitation in mandibular opening is usually present (Fig.4). [1,2]

Diagnostic criteria: (acute type)

1. Pain accelerates during forced mandibular movements.
2. Mouth opening movements are limited (hinge movement only).
3. Deviation to the affected site exists upon mandibular opening.
4. Limitation exists in lateral movements.

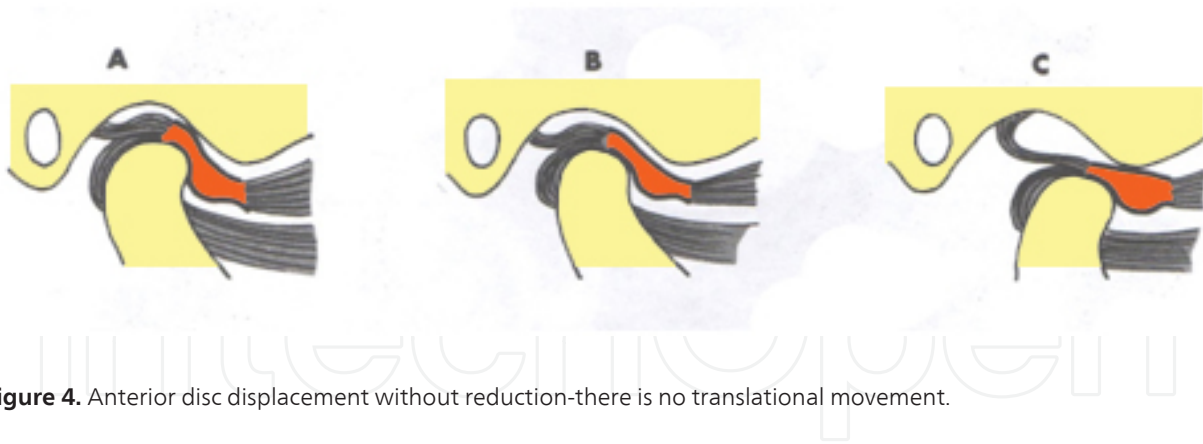

Figure 4. Anterior disc displacement without reduction-there is no translational movement.

5. Soft tissue MRI reveals nonreducing disc displacement.

Acute disc displacement must be treated urgently by pulling the mandible downward and forward to allow the disc to “pop” in place posteriorly.

Diagnostic criteria: (chronic type)

1. Pain if exists, is less than acute type.
2. History of joint noises then mouth opening limitation
3. There is mandibular opening limitation
4. There is lateral movement limitation
5. MRI images demonstrate nonreducing disc displacement

Mandibular dislocation is a situation in which the condyle is displaced anteriorly in front of the articular eminence and is unable to return to its normal position. To describe it, the term “open lock” is used as the mouth locks in open position (Fig. 5) .

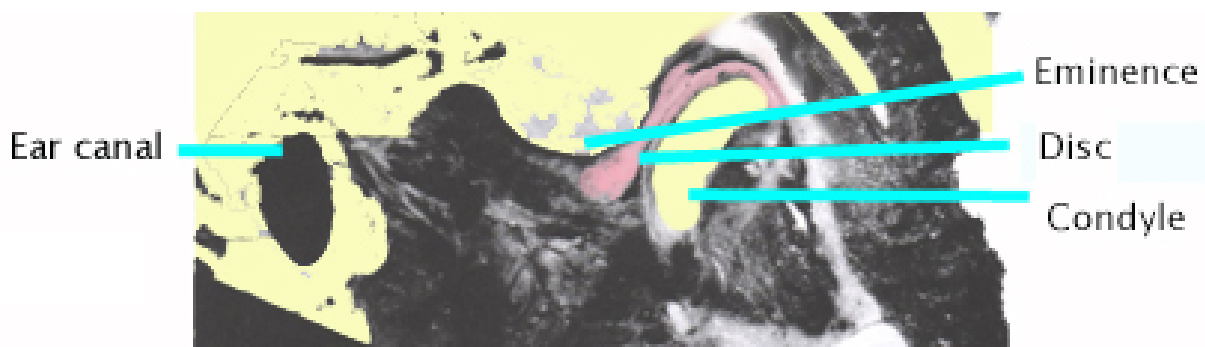


Figure 5. Mandibular dislocation - the position of the condyle head is in front of the articular eminence.

It is caused by:

1. Disc-condyle mandibular hypermobility.
2. Excessive translating movement of the condyle.

3. Atrophied articular eminence.

Acute mandibular dislocation must be treated urgently by pulling the mandible downward and backward to allow the condyle to “pop” in place posteriorly.

Diagnostic criteria

1. Closing Disability

2. Pain, if acute

Inflammation: Initial inflammation is rare and usually presents as rheumatologic disorders. Inflammation including synovitis, capsulitis and retrodiscitis often occur following trauma, damage, infection or other joint disorders. Pain in these disorders is acute and occurs with other joint movements.

Synovitis: Wearing of synovial tissue of TMJ can occur after trauma, intracapsular irritation and even unusual function. Clinical features of synovitis are local pain which becomes severe during mandibular movements. In many cases, fluctuant swelling in synovitis and pain inhibits posterior teeth from occluding.

Capsulitis: Capsular inflammation may occur because of distraction of capsular ligaments. Differential diagnosis of capsulitis from synovitis is difficult. It is painful. There is tenderness to palpation. The most important cause of capsulitis is macro- trauma. It is impossible to differentiate between capsulitis from synovitis clinically.

Retrodiscitis: Inflammation and degeneration is possible following excessive forces on retrodiscal tissues replete with nerves and vessels. As with other inflammations, it appears as dull pain upon clenching. Both of mild and severe traumas are causative factors. Sudden trauma to the chin results in condyle pressure on retrodiscal tissues and thus, inflammation and degeneration may occur in the long-term.

Diagnostic criteria

1. Local concentrated pain at rest which becomes severe in function and clenching

2. There is limitation in mandibular movement because of pain. Sometimes, swallowing leads to no contact of posterior teeth on that side. MRI may demonstrate inflammation.

3. If there is inflammation in the joint and teeth cannot occlude on the affected side.

Joint inflammations: They may be local, diffuse or generalized.

- Osteoarthrosis
- Osteoarthritis

Diffuse type includes: Polyarthritis which itself has 6 groups:

- Traumatic arthritis
- Infectious arthritis
- Rheumatoid arthritis

- Hyperuricemia arthritis
- Psoriatic arthritis
- Ankylosing arthritis

Osteoarthrosis: This is known as a degenerative noninflammatory condition of the joint. As we know, functional forces entering joint surfaces result in remodeling stimulation to adaptation of the condyle during life. It is a natural reaction of subjoint bone. However, if forces are more than adaptive capacity and condyle remodeling, degeneration or osteoarthritis will appear. In milder forces to joint surfaces and bone remodeling with no symptoms, it is named osteoarthrosis as conditions are stable but the shape of bone changes.

Clinical observations

It is painless. Limitation in mandibular movements and deviation to the affected side occurs on opening.

Radiographic findings

Bone remodeling, changes in shape and size which are signs of physiologic adaptive mechanical stress are seen. However, initial degeneration of joint can be demonstrated with arthroscopy.

Diagnostic criteria

1. Crepitus, (grating sound)
2. Limitation in mandibular movements resulting in deviation to the affected side on opening.
3. If radiography shows bony changes, they include: subchondral sclerosis, osteophyte, density loss, subjoint cysts.

Osteoarthritis: This is a degenerative condition sometimes associated with a secondary inflammation of the TMJ (i.e. synovitis). Osteoarthritis is a degenerative process of condyle and fossa surfaces resulting in their changes. It has slow progression then cartilage remodels and reshapes. Osteoarthritis may be a component of a systemic disorder.

Etiology

When articular surfaces are unable to bear the forces, the capacity of functional adaptation cannot respond and thus, degeneration ensues. If bony changes are active, it is named osteoarthritis.

Clinical features

Limitation of opening is present because of articular pain. Crepitus is obviously common. Condyle palpation leads to pain.

Radiographic findings

Include: bony changes in subarticular bone of condyle and fossa, sclerosis, subarticular cysts, osteophyte, low density and roughness. In progressive conditions, extensive condyle degen-

eration is present. It is considerable that patient may have signs before demineralization in radiography. Individuals suffering from osteoarthritis usually have unilateral pain which becomes worsened in mandibular movements and also in late afternoon and night. Articular changes may be due to trauma, destructive forces, infection or an idiopathic process (Fig. 6).

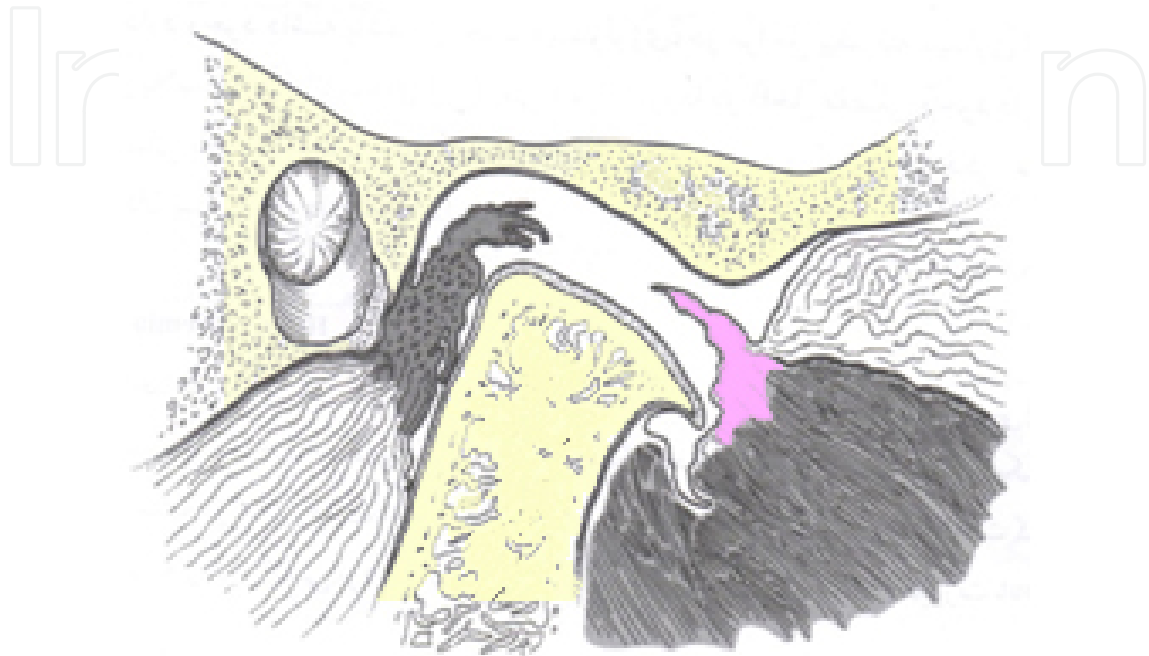


Figure 6. Degenerative lesions in the TMJ with disc perforation.

Diagnostic criteria:

1. Pain upon function due to inflammation.
2. Trigger points to palpation are present.
3. Crepitus
4. Limitation in mandibular movements with deviation to the affected side on opening
5. Radiographic changes include : subchondral sclerosis, osteophyte, narrowing of articular space

Polyarthritides: This includes a variety of articular disorders which are less common. Their signs and symptoms are like in osteoarthritis but with completely different etiology. Different types include: Traumatic arthritis, infectious arthritis, rheumatoid arthritis, hyperuricemia arthritis, psoriatic arthritis and ankylosing arthritis.

Traumatic arthritis: Major trauma to the jaw leads to articular surface changes and inflammation. Clinically, patients have consistent pain becoming severe with movements and opening limitation.

Infection Arthritis: It occurs because of bacterial infection from adjacent structures.

Rheumatoid arthritis: It is an autoimmune chronic systemic disorder which leads to synovitis. Clinical features are continuous pain, pain on swallowing and limitation in mandibular movements. It involves joints of the legs, at first. In 5%, there are signs in the TMJ. In about 80% of patients, rheumatoid factor is positive. In initial stages, there is no distinctive radiographic sign because changes are in soft tissues. But after progressing, erosive changes, subchondral cysts, decrease in articular space, bone degeneration and osteoporosis can be seen. In acute cases, inflammation and tenderness to palpation is present. Limitation in mandibular movement leads to ankylosis progress. Condyle degeneration may result in VD reduction and anterior open bite. Crepitus or joint noises may be present, also. Histologically, in progressive stages, there is severe secretion of lymphocytes, plasma cells and lysosomic enzymes with exudates in the joint. It usually affects the TMJs bilaterally and is more common in women (Fig. 7).

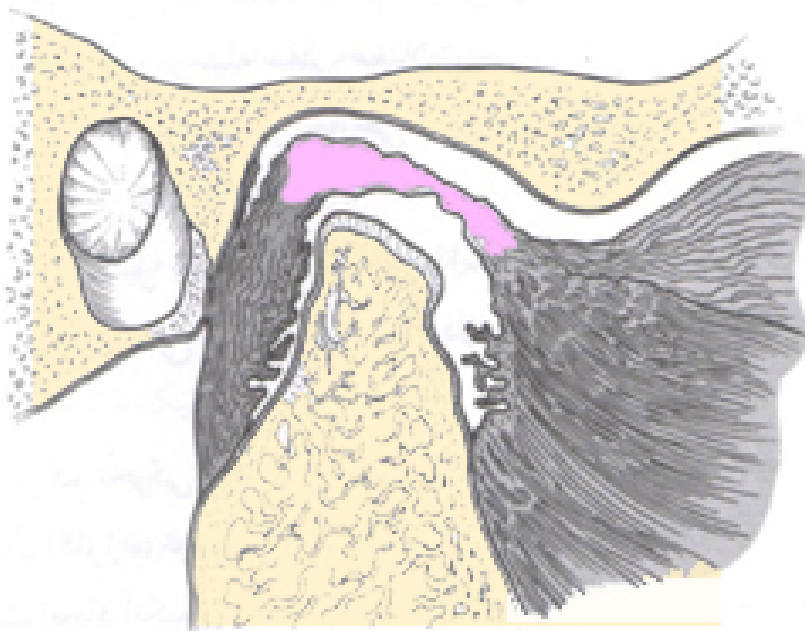


Figure 7. Degenerative changes in rheumatoid arthritis-attenuation of the condyle.

Hyperuricemia: In this disorder, crystals of sodium urate in periarticular tissues increase which lead to, warmth, tenderness to palpation and pain in mandibular movement. Gout is a common hereditary disease in men. In laboratory tests, uric acid and erythrocyte sedimentation rate in blood is high. In radiography, punch-out bone erosions can be seen.

Psoriatic arthritis: This is an autoimmune disease accompanied by psoriasis dermatic lesions. Psoriatic arthritis affects men more than women and Rh factor is negative. Radiographic findings reveal osteoarthritis changes with erosion, osteoporosis and narrowing of articular space. This polyarthritis is asymmetric. Joint signs are pain, warmth, pain on swallowing and limitation in mandibular movements.

Ankylosing spondylitis: Ankylosing spondylitis or Marie-Strumpel disease is a chronic inflammatory disease with unknown cause. There is HLA-B27 marker. It involves joints of the vertebrae. There is calcification in ligaments tending toward bony ankylosis here. It is more common in men. There are signs such as arthritis and iridocyclitis present. The possibility of involving TMJ is low but in cases of TMJ involvement, signs are mild and the most important one of them is limitation in mandibular movements, pain, and diffuse stiffness in muscles. These patients have severe signs in other joints. On radiography, bone margins of subchondral bone are absent and sclerosis, bony erosions, narrowing of joint space and extensive ankylosis are visible.

Ankylosis: In general, ankylosis means abnormal immobility of the jaw and mandibular movements because of adhesion. It is divided into 2 major groups: bony and fibrotic. In fibrotic ankylosis fibrous adhesion or fibrotic changes in capsular ligaments occurs. It is the most common form which occurs between condyle and disc or between disc and fossa. Bony ankylosis occurs between condyle and glenoid fossa, and leads to fusion. In another classification, low mobility disorders are divided into three groups:

Trismus because of stiffness of masticatory muscles.

1. Pseudoankylosis which results from extracapsular causes and leads to reduced mandibular movements.
2. True ankylosis: It results from fibrosis adhesion or bony fusion. The most severe form of it is low mobility because of bony adhesion of condyle to glenoid fossa.

The most common form of low mobility is trismus from infection, trauma, malocclusion, tumors and mental problems.

The most common cause of pseudoankylosis is due to zygomatic arch and condyle fracture. This fracture leads to transgression of a part of these structures to articular space and finally, inhibition of condyle movements. Adhesion of the coronoid process and hypertrophy around it, or fibrosis of the temporalis muscle, can be considered as other causes of pseudo ankylosis. In true ankylosis, trauma is the most common cause of bony ankylosis. Following trauma, in children, after 3 to 6 months, mandibular movements become progressively reduced; the most important mechanism after trauma, is bone formation following intracapsular hematoma or intracapsular fracture. The most important cause of ankylosis after trauma is intracapsular infection. With a lower percentage, ankylosis occurs after intracapsular inflammations such as rheumatoid arthritis, Still's disease, Marie-Strumpel disease etc. Fibrosis or bony ankylosis is also common after arthroplasty. Bony type occurs after disectomy as well. In initial diagnosis, panoramic radiography can be used. More complete information is gained from CT scans. If fibrotic ankylosis is present, articular space decreases. Articular space loss is a sign of disc destruction; the space may fill with bone. [1,4]

Etiology: The most common cause of is macrotrauma which leads to tissue damage, inflammation and hemarthrosis. These increase the formation of fibrous matrix. The other cause of ankylosis is surgery that often results in fibrotic changes and reduced mandibular movements. Fibrosis ankylosis of mandible is the continuous progression of joint adhesion.

Clinical features: Patients have history of damage or capsulitis with reduced mandibular movements (which is painless). Mandibular movements in all directions (opening, lateral and protrusive) are limited. If ankylosis is unilateral, the jaw deviates to the affected site on opening. In most cases of ankylosis, the condyle can rotate to some degree thus the patient is able to open his/her mouth 20 to 25 mm. Bilateral ankylosis in children results in severe retrognathia and bird face with open bite.

Diagnostic criteria (fibrosis type):

1. Reduced opening limit
2. Distinctive deviation to the affected site
3. There is no translational movement of condyle

Diagnostic criteria (bony type):

1. Severe mandibular movements limitation
2. Deviation to the affected site in unilateral cases
3. When it is unilateral, lateral movements to the unaffected site is clearly limited.
4. Bony proliferation and immobility of the condyle on radiography (Fig. 8).

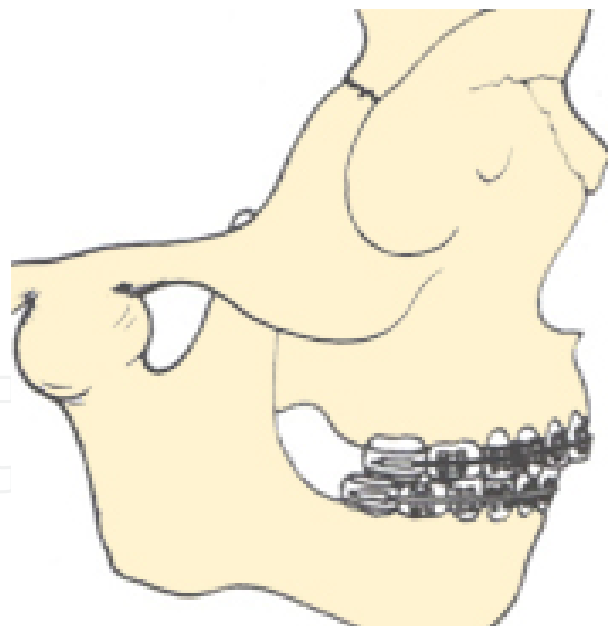

Figure 8. Complete bony ankylosis

Adhesion: Sticking of joint surfaces to each other may occur between condyle and disc (inferior articular space) or between disc and glenoid fossa (superior articular space). This may follow long-term forces (for example clenching during sleep), hemarthrosis, macro trauma and or surgery.

Clinical features:

In adhesion between disc and fossa, normal translational movement is limited, so the condyle just has rotational movement. In this case, opening range is about 25 to 30 mm.

If this kind of adhesion occurs permanently in the superior joint space, the disc remains posterior to the condyle which in fact is posterior dislocation of the disc.

In adhesions of the inferior joint space, translational movements may be normal. But the condyle is unable to do rotational movement with the disc. The result is a jolt during mouth opening.

Masticatory muscles disorders

Masticatory muscles disorders in the head and neck region, include: myofacial pains, myositis, spasm, protective splinting, contracture and neoplasia. In most patients with TMD, the muscles are tender to palpation and 40% of them have pain chewing food. Fibromyalgia is a chronic muscle pain.

Myofacial pain

Myofacial pain can be misleading by tension type headache resulting from tiredness.

Etiology :

The most important causes are : Systemic factors such as vitamin deficiency, viral infection, mental stress and sleep disorders. The chief complaint of the patient is various pains, recurrent pains, temporal headache etc. Here, the patients show the site of pain not the source of it.

Clinical features:

The most important sign of myofacial pains is trigger point. Other signs are pain at rest and upon activity.

Diagnostic criteria:

1. Poorly localized pain
2. Localized trigger point in muscles or fascia
3. Pain decrease in localized anesthetic injection

Myositis or inflammatory myalgia

This is a muscular tissue inflammation resulting from localized causes such as trauma or infection. Myositis is divided in two types of inflammatory reactions:.

Diagnostic criteria: (type 1)

1. Pain increase in mandibular movements
2. Pain following long and abnormal use of muscles

Diagnostic criteria: (type 2 : diffuse)

1. Pain is usually acute in localized areas
2. Localized tenderness to palpation in all parts of the muscles
3. Pain increase in mandibular movements
4. Moderate to severe limited movements due to inflammation

Myospasm or tonic contraction myalgia:

Myospasm is a toxic muscular contraction created by CNS

Myospasm or acute trismus is an acute disorder and sudden and involuntary contraction.

Diagnostic criteria:

1. Acute pain
2. Persistent contraction of muscle
3. Hyperactivity of EMG
4. Pain decrease in activity
5. Pain at rest and tenderness to palpation

Evaluation and diagnosis of temporomandibular disorders

The patient history should include chief complaint, history of the present illness, medical and dental history and individual history (Table 2).

-
1. Do you have difficulty, pain or both when opening your mouth, for instance when yawning?

 2. Does your jaw stick, locked, or go out?

 3. Do you have difficulty, pain or both when chewing, talking or using your jaws?

 4. Are you aware of noises on the jaw joint?

 5. Do your jaws regularly feel stiff, tight or tired?

 6. Do you have pain in or about the ears, temples or cheeks?

 7. Do you have frequent headaches and or neck aches?

 8. Have you had a recent injury to your head, neck or jaw?

 9. Have you been aware of any recent changes in your bite?

 10. Have you previously been treated for a jaw joint problem? If so when?

Masticatory muscle disorders

-
1. Myofacial pain

 2. Myositis

 3. Spasm

4. Protective splinting

5. Contracture

6. Neoplasia

Usual examinations in TMD

1. Measure range of motion of the mandible or opening and right and left lateral excursions (note any uncoordination in the movement)

2. Palpate for pre- auricular or interameatal TMJ tenderness

3. Auscultate and or palpate for TMJ sounds (clicking or crepitus)

4. Palpate for tenderness in the masseter and temporalis muscle

5. Note excessive occlusal wear , excessive tooth mobility , buccal mucosal lateral tongue scalloping

6. Inspect symmetry and arrangement of the face, jaw and dental arches

Differential diagnosis of oral and maxillofacial pains:

1. Intracranial structures

2. Extracranial structures

3. Neuromuscular disorders

4. Neuropathic pain disorders

5. Continuous pain disorders

6. Sympathetic maintained pain

7. Psychogenic pain disorders

8. Somatoform disorders

Pseudoankylosis :

1. Depressed zygomatic arch fracture

2. Fracture dislocation of the condyle

3. Adhesions of the coronoid process

4. Hyper trophy of the coronoid process

5. Fibrosis of the temporalis muscle

6. Myositis ossificans

7. Scar contracture following thermal injury

8. Tumor of the condyle or coronoid process

True ankylosis:

1. Inter capsular fracture (child)

2. Medial displaced condylar fracture (adult)

3. Obstetric trauma

4. Intracapsular fibrosis

5. Infection : otitis media		
6. Suppurative arthritis		
7. Inflammation: ,	Rheumatoid arthritis	Stills disease
8. Ankylosing spondylitis		
9. Mari Strumpel disease		
Surgical : Post operative complications of TMJ surgery Orthognathic surgery		
Hypomobility of the mandible		
1. Odontogenic :myofacial pain , malocclusion , erupting teeth		
2. Infection: pterygomandibular , lateropharyngeal , temporal		
3. Trauma: fracture of the mandible , muscle contusion		
4. Tumors: nasopharyngeal tumors, tumors that invade jaw muscle		
5. Psychological: hysterical trismus		
6. Pharmacologic: phenothiazines		
7. Neurologic: tetanus		
Sign and symptoms of mental disorders		
1. Inconsistent , inappropriate and or vague of pain		
2. Over-dramatization of symptoms		
3. Symptoms that vary with life events		
4. Significant pain of greater than 6 month duration		
5. Repeated failures with conventional therapies		
6. Inconsistent response to medications		
7. History of other stress – related disorders		
8. Major life events e.g. new job , marriage , divorce , death		
9. Evidence of drug abuse		
10. Clinically significant anxiety or depression		
11. Evidence of secondary gain		

Table 2. Questionnaire about TMD

Recommended Imaging for TMD:

Panoramic view:

It is a valuable method in diagnosis of TMD. Advantages are low price and the possibility of comparing both sides of mandible and fossae.

Generally, information from panoramic view include: whole evaluation of maxilla and mandible bilaterally (coronoid process and condyle).

Magnetic Resonance Imaging (MRI):

Today, MRI often is used to diagnose of TMD. This method evaluates both joints at the same time. Video film is achieved from mandibular movements during imaging, also. On the other hand, the danger of high radiation is obviated.

Computed tomography (CT Scan):

This technique is used in recognizing bony abnormal cases or anomalies of TMJ (such as developmental anomalies, trauma and neoplasia). CT does not play an important role in diagnosing disc displacement because it is problematic in showing the disc. CT scan with direct sagittal plane provides high quality images. It is the best method in evaluating bone structures (ankylosis) in combination with TMJ.

Disadvantages:

1. High price
2. No suitable images of soft tissue within the joint
3. No possibility of imaging during motion of disc and condyle

Arthrography:

It refers to the injection of a radiopaque contrast medium into the inferior, superior or both spaces and evaluating intracapsular soft tissues. Dynamic and functional movement of the disc and condyle can be assessed via fluoroscopy and video in this method. This technique is very precise in observing intracapsular derangement. Arthrography is the method choice to recognize disc perforations.

Disadvantages:

It is a minimally invasive method, may result in infection, hematoma, disc injury, or hypersensitivity to the medium.

Diagnoses achieved by arthrography:

1. Disc dislocation with reduction
2. Disc dislocation without reduction
3. Perforation
4. Adhesion

Mental and socio-behavioral evaluation:

In patients with TMD especially who suffer from chronic pain sometimes stress due to muscle hyperactivity may be recognized as a major factor. So there should be some questions in order to evaluate behavioral, social and emotional factors because they may result in initiation, or

exacerbation of the disorder. On the other hand, long-term chronic pains with function disorder can lead to mental changes. Anxiety and depression are recognized by simple questions.

Additional clinical tests:

Biopsy:

This is helpful in diagnosis of benign and malignant tumors of the TMJ; the most important of them are chondroma, chondrosarcoma and osteochondromatosis.

Diagnostic anesthesia injection:

These injections include:

1. Nerve block (auriculotemporal nerve)
2. Trigger points injection
3. TMJ injections

4. Conservative therapy

Treatment goals in patients with TMD are : Pain relief and return of function. These goals will be achieved only if diagnosed properly and the treatment plan takes mental and physical problems into consideration. Predisposing factors must be eliminated. In many cases, signs and symptoms of TMD are transient and self-limited without any serious sequelae and no invasive treatment is needed. [1,2]

Conservative treatments such as behavioral modifications, physiotherapy, medication therapy and splint therapy decreases signs and symptoms in most patients suffering from TMD. There are many studies that emphasize this point; 86% or more of these patients with disc displacement become pain-free and regain acceptable function. [1,2]

In general, TMD treatments are divided into two separate phases :

Phase 1: Includes education, anxiety control, behavioral modifications, medication therapy and splint therapy.

Phase 2: Dental rehabilitation, occlusion correction, fixed prosthesis, restorative treatments, orthodontic treatments and orthognathic surgery. The concept of treatment phase 2 is that it will be done automatically after completion of phase 1. In spite of successful conservative treatment in TMD, some patients do not improve. These patients are divided in two groups:

1. Pain and dysfunction is as a result of changes in joint structures. Joint surgery may be needed in this case.
2. 2- Patients with chronic syndromes or combination of factors. In this case, a treatment plan for chronic pain and a group of specialists may be needed. Selective treatments include:

3. Patient education and stress control
4. Mental therapy
5. Pharmacotherapy
6. Physiotherapy
7. Splint therapy
8. Occlusal correction
9. Surgery

Patient education and stress control: Successful treatment lies in awareness, patient motivation and cooperation. Dentist should explain clinical findings, diagnostic information, treatment choices and prognosis in simple terms. Necessary instructions should include;

1. Muscle relaxant by voluntary limitation in mandibular function
2. Parafunctional habits modification
3. Physiotherapy at home

The program should emphasize avoiding chewing hard food or gum, yawning, singing, excessive talking, bruxism and clenching and bad sleeping habits. Home physiotherapy plan includes moist warm towels on sensitive areas can decrease sensitivity and pain and also increase the range of mandibular movements. Heat relaxes muscles in the form of warm and moist compress. Patient's stress and habits can be treated by a combination of different methods such as behavioral modifications, medication therapy and physiotherapy. Patient cooperation and motivation play an important role here.

Pharmacotherapy:

It is effective in treatment of TMD. Clinical experiences show that pharmacotherapy and supportive treatment will accelerate patient improvement. It is noticeable that no drug has a complete range of effectiveness in TMD. The most effective drugs to treat all kinds of TMD include analgesics and nonsteroidal anti-inflammatory drugs (NSAIDs), corticosteroids, muscle relaxants, anti-depressants and anti-anxiety drugs. Analgesics and corticosteroids in acute TMD pain, nonsteroidal anti-inflammatory drugs and muscle relaxants in both acute and chronic disorders and tricyclic anti-depressants in chronic problems are recommended. It is advised that tranquillizing drugs three times a day for two weeks be given.

Analgesic drugs:

These drugs are used to decrease pain in TMD. Non-narcotics are effective on mild to moderate pains. The primary form aspirin inhibits prostaglandin synthesis. Ibuprofen is effective in skeletal muscular pains (dosage: 600 – 800 mg three times daily). These drugs may have gastrointestinal side-effects.

Corticosteroids:

These drugs have effective anti-inflammatory properties but rarely used in TMD.

Muscle relaxant drugs:

These drugs are advised for muscle hyperactivity inhibition in TMD; mainly benzodiazapines.

Anti depressant drugs:

Recently, antidepressant drugs are used in different kinds of chronic pains. For example, pain decrease is expected in low dose of Amitriptyline (Elavil) 10 mg before sleep for some weeks. This 1/10 to 1/20 dosage is because of its antidepressant property. This drug can be used in individuals who have depression and sleep disorder due to their chronic pain and is effective in treatment of headache resulting from muscle contraction and musculoskeletal pains. It increases the stage 4 (delta) of sleep and reduces rapid eye movement (REM) in sleep. They may be effective in treatment of nightly bruxism, also. In dosage between 10 to 75 mg, they are effective in treatment of orofacial chronic pains. Antidepressant drugs should be advised by specialists. Recommendations of these drugs are for individuals who have depression not only TMD.

Antianxiety drugs:

They are effective when TMD is associated with anxiety. They reduce the patient's reaction to stress. The most common drugs in this group is diazepam which should not be given for more than 10 days. Dosage of 2.5 to 5 mg before sleeping results in muscle relaxation and probable decrease in parafunctional habits.

Local anesthetic drugs:

As it was said before, local anesthetic drugs are used for two aims of treating and diagnosing. When we are suspecting neuralgia, or treating disc or mandibular dislocations. [5,6]

Physical therapy:

A group of supportive treatments used as an important part of successful treatment of TMD includes physiotherapy.

Physical therapy modalities: This treatment includes: Thermal therapy, ultrasound, electrogalvanic stimulation therapy, low voltage electric stimulation, acupuncture and low-level laser. [7]

Thermal therapy:

Heat leads to blood flow increase at that site. A moist warm towel can be used in the site for 10-15 minutes, on and off.

Ultra sound:

This method results in increasing temperature of internal tissue surfaces, so deep surfaces become warmer. Its mechanism is translating high frequency to heat during passing through tissues. This heat is able to penetrate.

Splint therapy: 1 – Interocclusal splint, 2 – Anterior repositioning splint

Splints solves muscle tension and TMJ pain decreases. In anterior displacement of disc and degenerative joint disorder, splint decreases direct pressure in TMJ area so joint and muscles

have a passive state. Occlusal splints use in TMD treatments as temporary and conservative treatment decrease occlusal direct load in TMJ region. It allows the patient to seek the most comfortable muscle and joint position without excessive influence of the occlusion. It is advised to use the splint at night for several months because results appear then. Theoretically, the position of disc and condyle head is corrected and condyle is placed in a proper relation with the disc. So, posterior disc ligaments shorten maintaining the disc in proper relationship to the condyle. However, splints may be required for a year or more to stabilize treatment, provide relief pain and discomfort of TMJ (Figs. 9, 10).

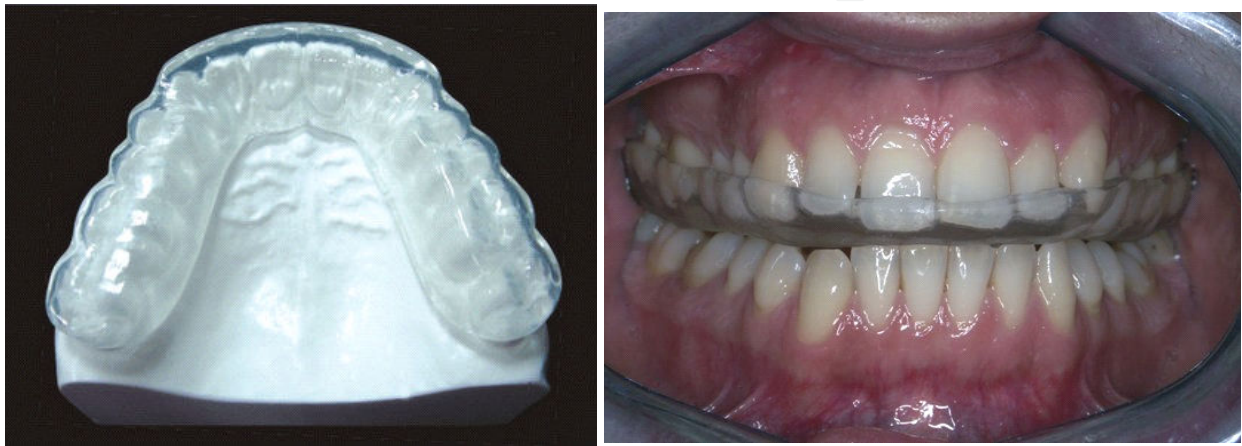


Figure 9. Maxillary hard acrylic splint.

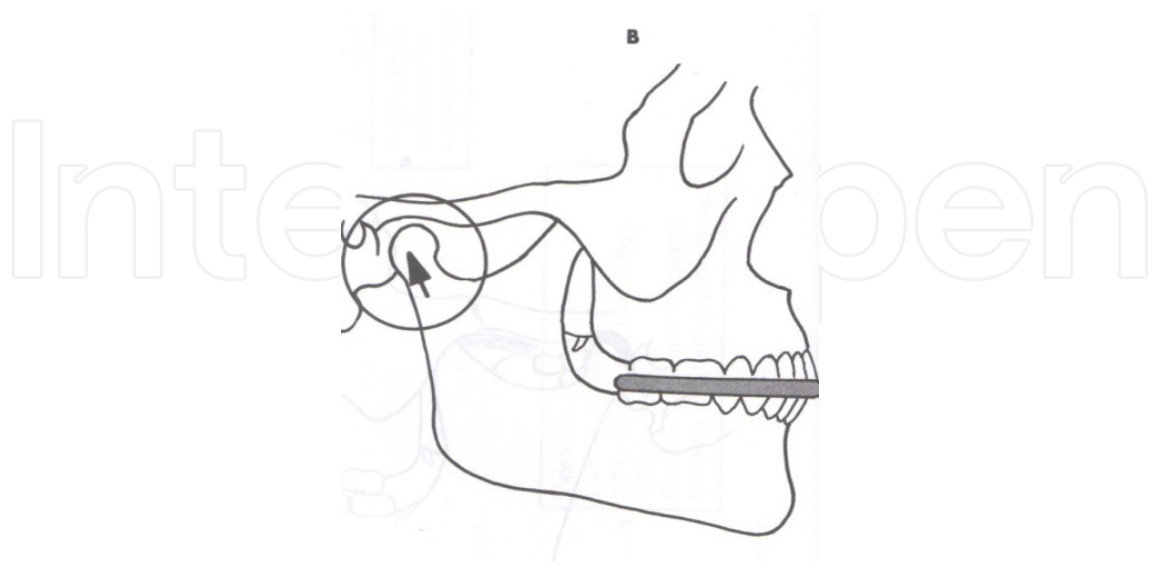


Figure 10. Maxillary hard acrylic splint increases joint space when used; it allows for disc reduction, relieves spasms, redistributes occlusal forces and prevents attrition.

5. TMJ surgery

Although most patients with TMJ disorders can be treated by nonsurgical and conservative treatment, in some, surgery is necessary. The common TMJ surgeries are:

1. Arthrocentesis
2. Arthroscopy
3. Disc – repositioning surgery
4. Condylotomy
5. Arthroplasty
6. Total joint displacement

Arthrocentesis:

Arthrocentesis involves placing a suitable needle into the superior joint space and aspiration for histopathology examinations, and then a large amount of lactated Ringer's solution is injected into the superior joint space to debride the superior joint space. This is done by a maxillofacial surgeon who has enough skill and experience in TMJ surgery to prevent adverse effects. Most patients undergoing arthrocentesis prefer local anesthesia and sedation.

Arthroscopy

Use of arthroscopy in diagnosing, treating and surgery of TMJ disorders is very popular. In comparison with open surgery and direct cutting of local tissues, arthroscopy is more comfortable with less adverse effects. In Arthroscopy, at first, a small cannula is placed into the superior joint space, followed by insertion of an arthroscope with a light source. The end of arthroscope is connected to a TV and a video monitor which allows perfect visualization of all aspects of the joint including glenoid fossa and joint disc. Intrajoint space just can be visualized and joint space can be washed and pathologic adhesions can be lysed. One cannula is used for visualization, where as instruments are placed through the other one are instruments such as forceps, scissors, sutures, cautery, medication needles, laser instrumentation and shavers. So, Arthroscopy is possible for disc displacement, disc attachment release, posterior band cautery, and suture techniques. Laser fibers can also be used to eliminate adhesions and inflamed tissue and cutting adhesions. A variety of TMJ disorders, including internal disorders, hypomobility as a result of fibrotic adhesions, DJD, hypermobility or excessive movements of joint can be treated by arthroscopy.

It is noteworthy that before and after arthroscopy, conservative treatments such as splint therapy and physiotherapy are used (Fig. 11).

Disc repair:

In advanced disorders, the joint disc may be severely damaged. Sometimes it can be repaired but in other cases there is no alternative except to remove it. Disc repair or replacement is done with autogenous grafts include dermis, temporalis fascia, auricular cartilage or inferior nasal

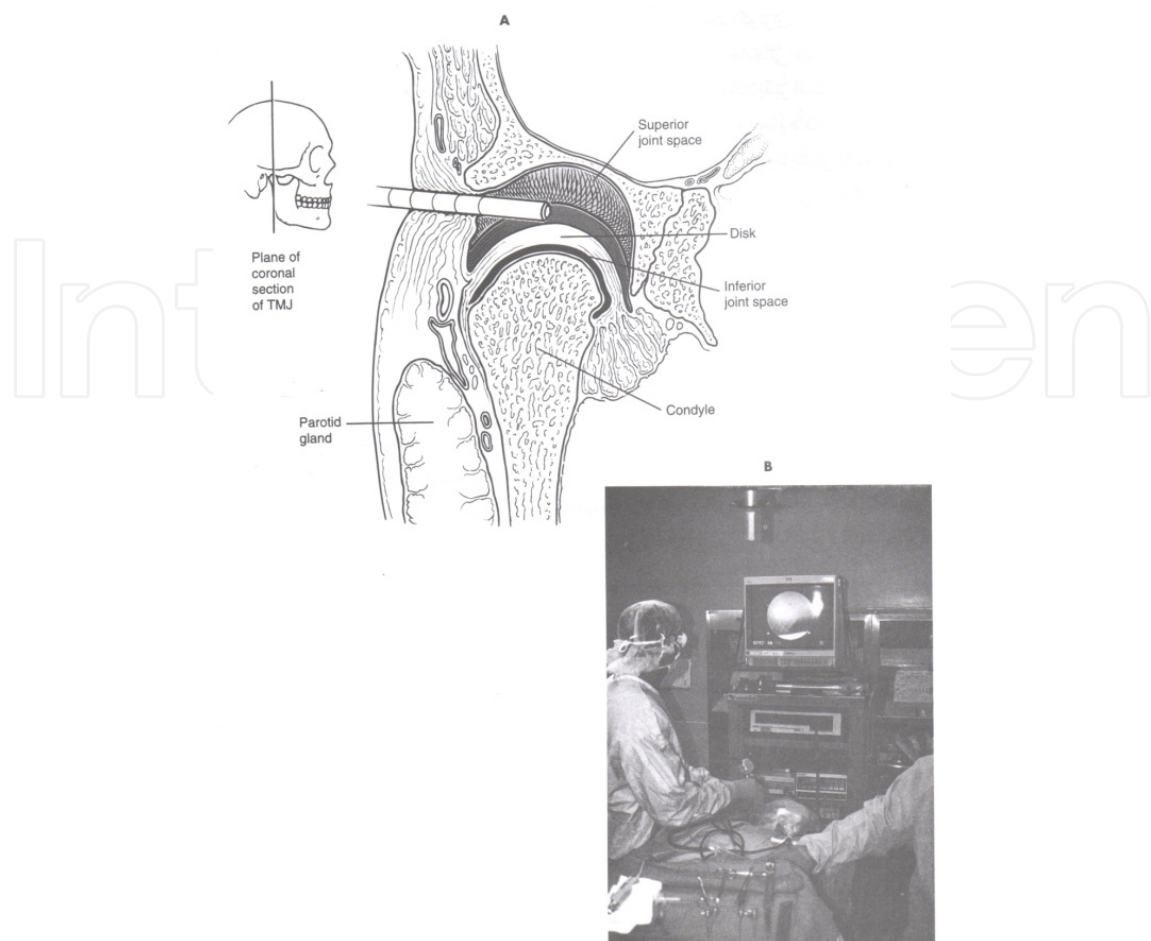


Figure 11. Arthroscopy of the superior joint space.

concha. Although, long-term results of these methods are not desirable in all cases, but most patients are satisfied from local function improvement and pain decrease.

Condylotomy of TMJ:

In this method, a subcondylar osteotomy in the ramus is used which starts from the sigmoid notch and ends inferiorly to the condylar neck. The lateral pterygoid muscle pulls the head of the condyle in a new passive relationship with disc and joint socket. It is suggested in some disorders such as recurrent anterior disc displacement and in degenerative joint disease.

Arthroplasty:

It is a treatment choice in bony ankylosis and fibrosis of TMJ. In this method, a part of the condyle head is removed. A gap is created between the head of the condyle and glenoid fossa so the patient can open his/her mouth.[4]

Total joint replacement:

Sometimes, advanced degenerative lesions lead to condyle process destruction, so it is necessary to repair that part by autogenous graft or other implants. In advanced rheumatoid

arthritis, neoplastic lesions, trauma and damage to local structures, there are destructions in many parts of the condyle and glenoid fossa. Costochondral graft often is used to replace condyle head and neck. In total joint replacement, titanium is used which has the same shape as the glenoid fossa and condyle head. This avoids severe pains, limitation or ankylosis, complete closed lock, deformation and severe malocclusion. (Fig.12)

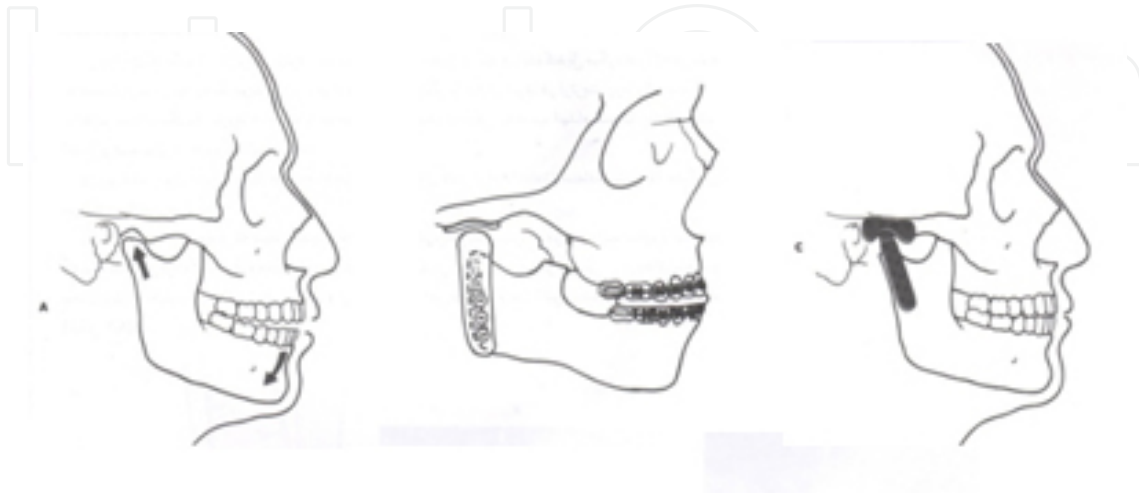


Figure 12. Total joint replacement – condyle removal and replacement via prosthesis.

Myofascial pain dysfunction syndrome (MPDS)

Causes pain, discomfort and inflammation in muscles and joints affecting function and activity of the masticatory system. This is a maxillofacial muscle disorder due to parafunctional habits or muscular hyperactivity and because of stress and anxiety.

Methods of stress control include: Exercise, avoiding stressful factors, psychological consultant, behavioral modification, soft diet for 4 weeks, trying to maximum opening the mouth without pressure, pain, slowly and with stretching exercises.

Medication:

1. Analgesic and anti inflammatory drugs

Ibuprofen – piroxicam, or acetaminophen codeine 3 – 4 times daily for 10 – 14 days

2. Muscle relaxant :

In individuals with muscles hyperactivity and severe pain give (3 -4 times daily for 10 – 14 days) diazepam (2- 5 mg 3 – 4 times in a day).

2. Tricyclic anti – depressant such as Amitriptyline (Elavil) lead to sleep improvement, nightly bruxism decreases and muscle pain improvement.

Triptizol Tab 10 – 25 mg, nightly before sleep

Physical therapy: Includes: Relaxation therapy, Ultrasound heating, stretching, pressure massage

Permanent occlusion modification:

After a reversible and conservative treatment, some people need permanent treatment and occlusal adjustment. It includes: prosthetic restoration, orthodontic treatment, orthognathic surgery and occlusal equilibration if it is necessary. These treatments in indicated patients may provide long-term treatment effects.

Surgical treatments include:

Arthrocentesis, Arthroscopy, Disc repair or removal, Disc repositioning, Condylotomy, Total joint replacement.

Author details

Fina Navi¹, Mohammad Hosein Kalantar Motamedi³, Koroush Taheri Talesh²,
Esshagh Lasemi² and Zahra Nematollahi⁴

1 Scientific Faculty, Department of Oral and Maxillofacial Surgery, Azad University of Medical Sciences, Tehran, Iran

2 Department of Oral and Maxillofacial Surgery, Azad University of Medical Sciences, Tehran, Iran

3 Department of Oral and Maxillofacial Surgery, Trauma Research Center, Baqiyatallah University of Medical Sciences, Tehran, Iran

4 Private Practice Dentistry, Tehran, Iran

References

- [1] Dowlat Abadi MMotamedi MHK, Taheri KT. Textbook of Temporomandibular Disorders. Shayan Nemodar Publications, Tehran, (2009). , 2009, 5-100.
- [2] Mortazavi, S. H. Motamedi MHK, Navi F, Pourshahab M, Bayanzadeh SM, Hajmiragha H, Isapour M: Outcomes of management of early temporomandibular joint disorders: How effective is nonsurgical therapy in the long-term? National J Maxillofac Surg, (2010).
- [3] Motamedi, M. H. Treatment of condylar hyperplasia of the mandible using unilateral ramus osteotomies. J Oral Maxillofac Surg. (1996). Oct;discussion 1169-70, 54(10), 1161-9.

- [4] Behnia, H, Motamedi, M. H, & Tehranchi, A. Use of activator appliances in pediatric patients treated with costochondral grafts for temporomandibular joint ankylosis: analysis of 13 cases. *J Oral Maxillofac Surg.* (1997). discussion 1414-6., 55, 1408-14.
- [5] Motamedi, M. H, Rahmat, H, Bahrami, E, Sadidi, A, Navi, F, Asadollahi, M, & Eshkevari, P. S. Trigeminal neuralgia and radiofrequency. *Today's FDA.* (2010). Sep-Oct; 22(5):54-5, 57-9.
- [6] Bohluli, B, Motamedi, M. H, Bagheri, S. C, Bayat, M, Lassemi, E, Navi, F, & Mohar-amnejad, N. Use of botulinum toxin A for drug-refractory trigeminal neuralgia: preliminary report. *Oral Surg Oral Med Oral Pathol Oral Radiol Endod.* (2011). Jan;Epub 2010 Jul 31, 111(1), 47-50.
- [7] Lassemi, E, & Jafari, S. M. Motamedi MHK, Navi F, Lasemi R: Low-level Laser Therapy in the Management of Temporomandibular Joint Disorder. *JOLA,* (2008).