

We are IntechOpen, the world's leading publisher of Open Access books Built by scientists, for scientists

4,800

Open access books available

122,000

International authors and editors

135M

Downloads

Our authors are among the

154

Countries delivered to

TOP 1%

most cited scientists

12.2%

Contributors from top 500 universities



WEB OF SCIENCE™

Selection of our books indexed in the Book Citation Index
in Web of Science™ Core Collection (BKCI)

Interested in publishing with us?
Contact book.department@intechopen.com

Numbers displayed above are based on latest data collected.
For more information visit www.intechopen.com



Peripartum Myocarditis

Marina Deljanin Ilic and Dejan Simonovic

Additional information is available at the end of the chapter

<http://dx.doi.org/10.5772/54778>

1. Introduction

Cardiac disease in pregnancy is a leading cause of maternal and neonatal morbidity and mortality [1]. Pregnancy not only poses a risk of maternal mortality but also of serious morbidity such as heart failure, stroke and cardiac arrhythmias. Heart failure during pregnancy was recognized as early as 19th century [2], however, the syndrome was not recognized as a distinct clinical entity until the 1937, when Gouley et al. [3] described the clinical and pathologic features of seven pregnant women who had severe and often fatal heart failure. In 1971, Demakis et al. [4] described 27 patients who presented during the puerperium with cardiomegaly, abnormal electrocardiographic findings, and congestive heart failure, and named the syndrome peripartum cardiomyopathy (PPCM). The European Society of Cardiology [5] recently defined peripartum cardiomyopathy as an idiopathic cardiomyopathy presenting with heart failure secondary to left ventricular systolic dysfunction towards the end of pregnancy or in the months following delivery, where no other cause of heart failure is found. It is a diagnosis of exclusion. The left ventricle may not be dilated but the ejection fraction is nearly always reduced below 45%.

The etiology of this disease remains uncertain, but a number of possible causes of PPCM have been proposed [5], including myocarditis, abnormal immune response to pregnancy, maladaptive response to the hemodynamic stress of pregnancy, stress activated cytokines, viral infection, and prolonged tocolysis. In addition, there have been a few reports of familial PPCM [6 - 8], raising the possibility that some cases of PPCM are actually familial dilated cardiomyopathy unmasked by pregnancy. Overall, there is more evidence to support myocarditis or an autoimmune process as the cause of the disease than for other proposed etiologies.

The beginning of the myocarditis hypothesis is related to work of Gouley et al. [3], who reported several cases of heart failure in women dying in the puerperium. Also, they found enlarged hearts with focal areas of necrosis and fibrosis and they also proposed infection as a

possible cause of heart failure in these women. After that, Melvin and colleagues proposed myocarditis as the cause for PPCM and reported a dense lymphocyte infiltrate with variable amounts of myocyte oedema, necrosis, and fibrosis in right ventricular biopsy specimens. They also noted that treatment with prednisone and azathioprine resulted in clinical improvement and loss of inflammatory infiltrate on repeated biopsies in the three patients studied [9,10]. Rizeq et al. [11] also found an inflammatory component in less than 10% of biopsy samples from patients with PPCM, a proportion similar to that found in age-and-sex-matched patients with idiopathic dilated cardiomyopathy. The highest frequency of myocarditis (78%) was reported by Midei et al., who found 14 of the 18 patients to have borderline and/or established histologic myocarditis. In that study resolution of myocarditis was associated with improved left ventricular function in the post-partum period [12]. A decade later, Felker and colleagues [13] confirmed that the absence or presence of inflammation on endomyocardial biopsy tissue did not predict outcome in patients with PPCM. However in that endomyocardial biopsy study, the authors also showed a high incidence of active viral myocarditis, using the Dallas criteria, in 26 of 51 PPCM patients. Bultmann et al. [14] found that after a viral infection, a pathologic immune response might occur that is inappropriately directed against native cardiac tissue proteins, leading to ventricular dysfunction. However, in that study the same incidence and types of viral positivity were noted also in controls.

Why should myocarditis be more common in pregnancy? It is assumed that the amended or muted immune response during pregnancy allows viral replication and greater likelihood of myocarditis in the setting of a viral infection [15]. Also it is known that pregnancy results in an immuno compromised state and that the decreased humoral and cellular immunity in pregnancy, together with higher levels of corticosteroids, and raised titres of 'blocking antibodies' formed in normal pregnancy, may allow greater viral replication than in age-matched non-pregnant individuals, and thus, a greater probability of viral myocarditis in the context of infection [16,17].

Farber and Glasgow [16] in their animal studies demonstrated that pregnant mice are more susceptible to viral infections than non-pregnant ones. Furthermore, they found that these viruses multiply to a greater level in the hearts of pregnant mice. The physiologic and hemodynamic changes of pregnancy may result in an increased susceptibility to viral myocarditis, higher virus load (such as coxsackie and echoviruses), and worsening of myocardial viral lesions [16, 17]. Pregnancy may predispose women to a more severe form of viral myocarditis when they are infected by a cardiotropic virus [18]. Immunologic studies in women have demonstrated enhanced suppressor cell activity during pregnancy [19], which could augment susceptibility to viral infections [20, 21].

2. Pathogenesis

2.1. Infection

Myocarditis is the term used to indicate acute infective, toxic or autoimmune inflammation of the heart [22]. It can be caused by many different viruses and the microbial pathogenesis may

be complex. Myocardial inflammatory reaction can be directed against the specific virus infection or predominantly reflects local autoimmune processes. Probably combination of autoimmune processes and virus-associated pathogenicity determines the outcome of the disease. A wide spectrum of agents has been associated with myocarditis, and the more common of these are listed in Table 1.

Etiology	Examples
Infectious	Adenovirus, Coxsackievirus, Cytomegalovirus, Epstein–Barr virus, HIV-1, Borrelia (Lyme’s disease), Toxoplasmosis, Actimonices, Chlamydia, Coxiella burneti, Echinococcus granulosus
Drug induced	Amphetamines, Anthracyclines (especially doxorubicin), Catecholamines, Cocaine, Cyclophosphamid, Trastuzumab
Systemic diseases (autoimmune disease)	Crohn’s disease, Kawasaki disease, Sarcoidosis, Ulcerative colitis, Cardiac rejection, Peri-partum myocarditis, Giant cell myocarditis, Systemic lupus erythematosus, Dermatomyositis
Hypersensitivity to drugs	Hydrochlorothiazide and loop diuretics, Methyldopa Penicillin, Ampicilin, Sulphadiazine, Sulphamethoxazole

HIV - human immunodeficiency virus

Table 1. Common etiology of myocarditis

During the acute viremic stage, viral replication can be present, in the absence of significant host immune responses. Viruses can enter the cardiac myocytes, fibroblasts, or endothelial cells through receptor-mediated endocytosis. Acute myocardial injury can result from either direct virus-mediated lytic processes or is caused by the emerging antiviral immune response. In fulminant cases of myocarditis, resulting myocyte necrosis may cause a significant loss of contractile tissue, which is accompanied by rapidly developing heart failure and early death of the host. It seems that the virus enters cardiomyocytes or macrophages via specific receptors and coreceptors. For example, a receptor for the coxsackie and adenoviruses 2 and 5 is the coxsackie adenoviral receptor [23]. Coreceptor has a role in serotypes B1, B2, and B5, and it is estimated that this activation may play a role of coreceptor acceleration and can cause an increase in virulence of Coxsackie virus B3. Virulence of Coxsackie virus B3 depends on the viral genome, as well as a host of factors, which may be increased by deficient levels of selenium or copper [24]. During the second stage of infection initial immune response is essential in defending the body during early infection. Natural killer cells and macrophages cause cytokine production (tumor necrosis factor- α , interleukin-1, interleukin-2, and interferon gamma) and inflammatory cell infiltration of the myocardium. The third stage consists of fibrotic reparation and cardiac dilatation in the presence or absence of low-level persistent viral genomes [25]. Important place of myocarditis pathogenesis belongs to the mechanism of molecular mimicry, which means that the activated T killer cells are not just attacking viruses and viral antigens, but they can function on their own proteins, in this case myosin. Further activation of B cells

leads to production of specific antibodies as a central place in the subacute and chronic phase of myocarditis. This leads to further necrosis, fibrosis, cardiac remodeling, dilatation, and chronic heart failure (figure 1).

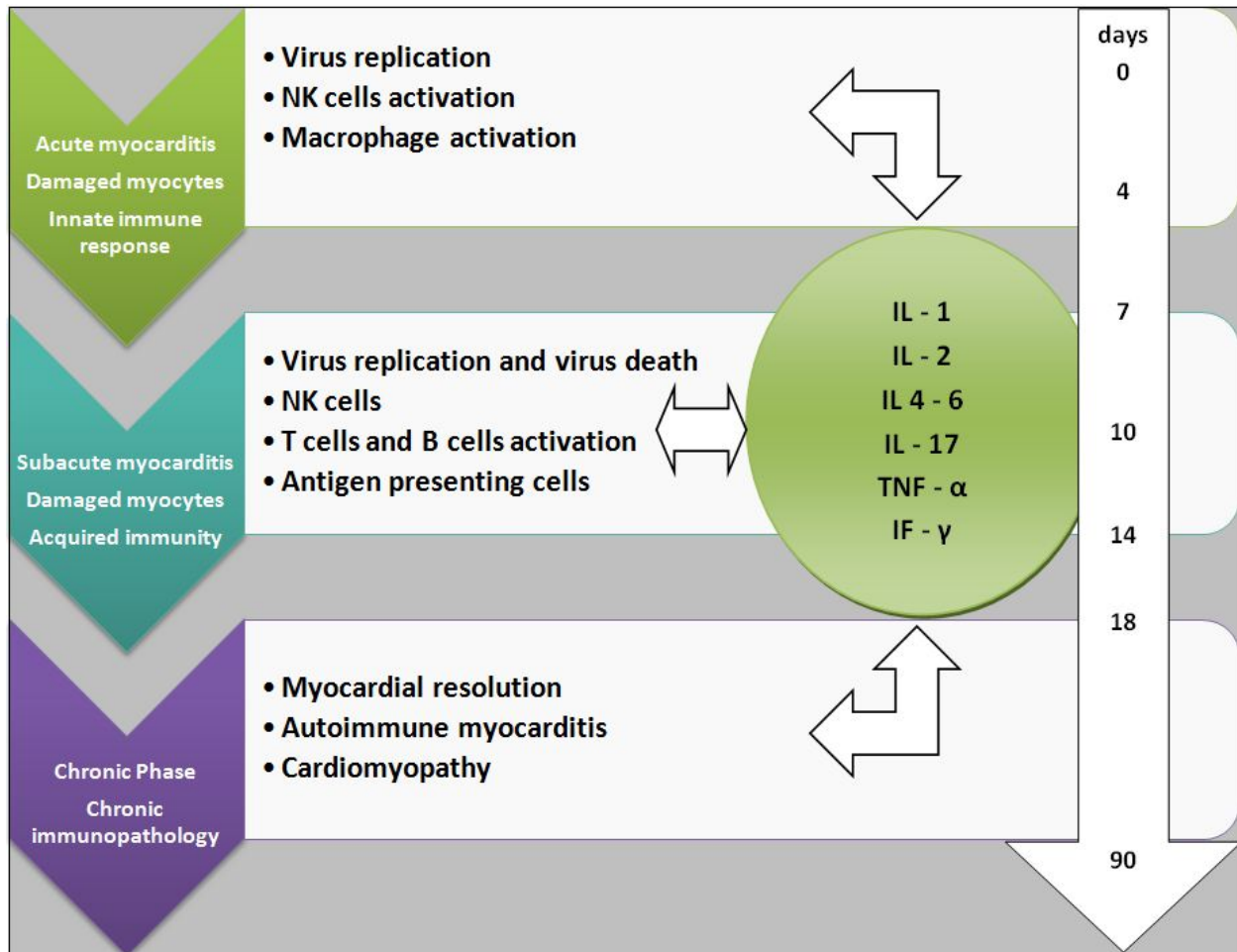


Figure 1. Transition from inflammation to cardiomyopathy

Because of the myocarditis-like inflammatory response seen in endomyocardial biopsy specimens (EMBs) from patients with PPCM, a possibility is reactivation of latent virus infection as a consequence of impaired immune mechanisms during pregnancy [26]. However, no investigation regarding the prevalence of viral genomes in PPCM has been published until recently, when endomyocardial biopsy specimens from 26 patients with PPCM revealed viral genomes (parvovirus B19, human herpes virus 6, Epstein–Barr virus, and human cytomegalovirus) in 8 patients (30.7%) that were associated immunohistologically with interstitial inflammation [14]. The presence of viral genomes in EMBs was associated with inflammatory cardiomyopathy exclusively in patients with PPCM but not in control subjects. Bachmaier et al. [27] reported experimental data supporting the Chlamydia hypothesis. A peptide from the murine heart muscle-specific alpha myosin heavy chain that has sequence homology to the 60-kDa cysteine-rich outer membrane proteins of *Chlamydia pneumoniae*, *Chlamydia psittaci*

and *Chlamydia trachomatis* was shown to induce autoimmune inflammatory heart disease in mice. Injection of the homologous *Chlamydia* peptides into mice also induced perivascular inflammation, fibrotic changes and blood vessel occlusion in the heart. *Chlamydia* DNA functioned as an adjuvant in the triggering of peptide-induced inflammatory heart disease. In the study of Cenac et al. [28], 96% of patients with PPCM versus 80% of controls were positive for *Chlamydia* IgG antibodies.

3. Autoimmune mechanisms

The introduction of fetal cells of hematopoietic origin into the maternal circulation may have a significant influence on the immune and genetic alterations. In women with PPCM, high titers of autoantibodies against select cardiac tissue proteins (adenine nucleotide translocator, branched chain α -keto acid dehydrogenase) and increased levels of tumor necrosis factor- α , interleukin-6, and soluble Fas receptors (an apoptosis signaling receptor) have been reported, suggesting a possible role of abnormal immunologic activities and inflammatory cytokines in pathogenesis of this disease [29-31].

The serum from women with peripartum cardiomyopathy has been found to contain autoantibodies in high titers, which are not present in serum from patients with idiopathic cardiomyopathy [32]. Most of these antibodies are against normal human cardiac tissue proteins of 37, 33, and 25 kD. The peripheral blood in these patients has a high level of fetal microchimerism in mononuclear cells, an abnormal cytokine profile, and low levels of CD4⁺ CD25^{lo} regulatory T cells. Some authors postulated that after delivery the fast degeneration of the uterus results in fragmentation of tropocollagen by collagenolytic enzymes releasing actin, myosin, and their metabolites [33]. Antibodies are formed against actin that cross-react with the myocardium, and the patient subsequently has a cardiomyopathy.

4. Prevalence and clinical features

The prevalence of acute peripartum myocarditis is unknown because most cases are not recognized on account of non-specific, only mild, or no symptoms, but sudden death may occur [22]. The clinical manifestations of myocarditis are various. Myocarditis may develop as a complication of an upper respiratory or gastrointestinal infection with general symptoms, particularly fever and skeletal myalgia, malaise, and anorexia. Since myocarditis may not develop for several days or weeks after symptoms and after return to a normal activity, there is a risk of overexertion, which may be dangerous. Arrhythmias or conduction disturbances may be life threatening despite only mild focal injury, whereas more widespread inflammation is necessary before cardiac dysfunction can cause symptoms.

The initial presentation may be with heart failure or suspected acute myocardial infarction. Acute onset of chest pain is usual and may mimic myocardial infarction or be associated with pericarditis. Symptoms resembling those of heart failure such as dyspnea, dizziness, ankle

edema, and orthopnea can occur even in normal pregnancies. Therefore, a pregnant woman in whom peripartum myocarditis and/or cardiomyopathy is developing may consider her symptoms to be normal. If swelling and other heart failure symptoms develop suddenly in an otherwise normal pregnancy, this should prompt further investigation.

5. Investigations

The initial evaluation of acute peripartum myocarditis includes detailed history and careful physical examination.

The ECG is not specific for diagnosis, but it may show sinus tachycardia, focal or generalised abnormalities, ST-segment elevation, fascicular blocks or atrioventricular conduction disturbances [34]. Although the ECG abnormalities are non-specific, an abnormal ECG may draw attention to the heart and lead to other investigations.

The chest x ray may be normal, or show cardiac enlargement, pulmonary venous congestion or pleural effusions.

There is no specific serum marker for myocarditis. Laboratory tests may show leukocytosis, elevated erythrocyte sedimentation rate, eosinophilia, or an elevation in the cardiac fraction of creatine kinase. Evidence of myocyte necrosis may be found with an increase in creatine kinase or appearance of troponin, indicating myocytolysis. The highest enzyme concentrations occur early and will probably have returned to normal by about a week after onset [35].

Cardiac autoantibodies can be demonstrated only late in the disease process, and a viral origin of myocarditis can only be proved if the virus is detected within an altered myocardium. Levels of BNP do not change significantly during normal pregnancy or in the postpartum period, but are markedly elevated in patients with peripartum cardiomyopathy [36]. So, an early measurement of BNP could help in detection of systolic dysfunction and elevation of left ventricle end-diastolic pressure.

Echocardiography may reveal segmental or generalised wall motion abnormalities, left ventricular dilatation, or a pericardial effusion. Echocardiography allows other causes of heart failure to be excluded but pronounced focal changes in wall motion may lead to confusion with myocardial infarction, especially if the ECG changes also suggest this [37]. The advent of novel echocardiographic techniques provides the opportunity to study peripartum myocarditis further. These techniques include those for studying ventricular long-axis function, right ventricular function, tissue Doppler techniques including strain and strain rate echocardiography, and speckle tracking echocardiography. New echo technologies, mainly three-dimensional echocardiography (3DE) and speckle tracking echocardiography, have become available and are competitive with cardiac magnetic resonance imaging (MRI) in accuracy while being less expensive and more widely available [38]. Unfortunately, these novel techniques have not been widely utilized to study peripartum myocarditis and PPCM.

Cardiac magnetic resonance imaging has been recently developed for the diagnosis of myocarditis. It allows more accurate measurement of chamber volumes and global and

segmental myocardial function than echocardiography has a higher sensitivity for the detection of LV thrombus [39], and it can characterize the myocardium [40]. In suspected myocarditis MRI can localize and quantify tissue injury, including edema, hyperemia, and fibrosis. In recent series of 82 patients with myocarditis who had biopsy-proven disease, MRI alone made the correct diagnosis in 80% cases [41]. There are limited data during organogenesis available, but MRI is probably safe, especially after the first trimester [42].

In the acute phase, the use of contrast media such as gadolinium-diethylene triamino pentaacetic acid (gadolinium-DTPA) helps to differentiate accurately healthy from inflamed or injured tissue. Furthermore, delayed contrast enhancement with gadolinium can help differentiate the type of myocyte necrosis: myocarditis vs ischemia. Myocarditis has a nonvascular distribution in the subepicardium with a nodular or band-like pattern, whereas ischemia has a vascular distribution in a subendocardial or transmural location [43]. Gadolinium can be assumed to cross the fetal blood-placental barrier, but data are limited. The long-term risks of exposure of the developing fetus to free gadolinium ions are not known, and therefore gadolinium during pregnancy should be avoided, but after delivery it represents a useful method for myocarditis diagnosis. Breast feeding does not need to be interrupted after administration of gadolinium [44,45] The importance of MRI is the fact that it is a non-invasive method, there is no risk unlike endomyocardial biopsy, and it can be used to monitor the effects of therapy.

The diagnostic gold standard is endomyocardial biopsy (EMB) with the histological Dallas criteria [46, 47] in conjunction with the new tools of immunohistochemistry and viral polymerase chain reaction (PCR). EMB and PCR are particularly important for those patients who are not experiencing improvement in the early weeks after the diagnosis and therapy, since emerging new antiviral and immunomodulatory treatments depend upon knowing if virus is present or absent in cardiac tissue. It is recommended that MRI should be performed before taking tissue samples, to reduce the sampling error. Leurent et al. [48] advocate using cardiac MRI to guide biopsy to the abnormal area, which may be much more useful than blind biopsy. Whether endomyocardial biopsy should be done in the setting of peripartum myocarditis is still controversial. Some authors not recommend it [49, 50] while Midei et al. [12] recommend endomyocardial biopsy of all patients with peripartum cardiomyopathy and myocarditis who fail to normalize left ventricular function after one week of standard medical therapy.

6. Management

The most important thing in treatment planning is clinical status of the mother and the fetus. If the patient is haemodynamically stable vaginal delivery should be carried out. Urgent delivery irrespective of gestation duration should be considered in women with advanced heart failure and haemodynamic instability despite treatment. Caesarean section is recommended with combined spinal and epidural anaesthesia. An experienced interdisciplinary team is required (cardiologist, obstetrician, anaesthesiologist, neonatologist and intensive care physician) [51].

Heart failure should be treated according to guidelines on heart failure [52], and it can be divided into supportive (heart failure therapy, heart rhythm disturbances, cardiogenic shock), and specific therapy (immunosuppressive therapy, interferon, immunoglobulin, immune-adsorptive therapy, immune-modulation). Heart failure therapy involves administration of diuretics, vasodilators, inotropes, beta blockers, angiotensin-converting enzyme inhibitors (ACEI), angiotensin II receptor blockers (ARBs), anticoagulation therapy, and mechanical support with intraaortic balloon pump or ventricular assist devices in cardiogenic shock as a bridge to recovery or heart transplantation. During pregnancy, ACEI, ARBs and renin inhibitors are contraindicated because they can cause birth defects, although they are the main treatment for postpartum women with heart failure [53, 54]. Digoxin, beta-blockers, loop diuretics, and drugs that reduce afterload such as hydralazine and nitrates have been proven to be safe and are the mainstays of medical therapy of heart failure during pregnancy [15, 55]. Warfarin can cause spontaneous fetal cerebral hemorrhage in the second and third trimesters and therefore is generally contraindicated during pregnancy [56].

7. Specific therapy

In case of early stages of myocarditis, administration of antiviral medications that target viral attachment to host-cell receptors, virus entry, or virus uncoating, would be effective.

Interferon beta. It was shown that beta interferon can decrease the number of viruses up to complete regression, the accumulation of viral RNA and viral coat protein. Interferon beta (IFN- β 1a) may affect the elimination of viruses, repair left ventricular ejection fraction and clinical status of patients [57]. In the study of Schmidt-Luce et al. [58], parvovirus B19 and human herpes virus-6 responded less well upon IFN- β treatment with respect to virus clearance and hemodynamic changes, although affected patients can improve clinically, despite incomplete virus clearance following reduction of virus load and/or improvement of endothelial dysfunction. Complete clearance of those viruses may need longer treatment, higher doses, or even change of the antiviral treatment regimens. Currently, there is no approved treatment for chronic viral heart disease, but data have demonstrated that subgroups of patients who had not improved upon regular heart failure medication may get significant benefit even years after onset of chronic disease.

Immunosuppressive therapy. It could be considered in patients with proven myocarditis. Administration of immunosuppressive (corticosteroids, azathioprine, cyclosporine) is still controversial and investigators have emphasized the need to rule out viral infection before starting immunosuppressive treatment, as the treatment may activate a latent virus, with subsequent deterioration in myocardial function [59]. In published randomized study on the Tailored Immunosuppression in Inflammatory Cardiomyopathy (TIMIC study) authors confirmed a positive treatment response in patients with chronic active myocarditis [60]. According to studies performed until now, immunosuppressive therapy should not be routinely administered to patients with myocarditis. However, patients with giant cell myocarditis, autoimmune or hypersensitive myocarditis with heart failure can benefit from this therapy. The best responders may be those with active autoimmune response without persisting viral genome [61].

Immunoglobulin. In case of autoimmune myocarditis, inflammatory process in the myocardium is triggered by a transient viral infection. Instead of anticytokine or immune-suppression therapy, a possible strategy is passive immunization through the infusion of immune globulins. Bozkurt and colleagues added intravenous immune globulin to conventional heart failure therapy in 6 women with PPCM and reported a significantly greater improvement in left ventricular ejection fraction compared with 11 control patients who received conventional therapy alone. Although the results seemed encouraging, a very small number of patients and the lack of a blindly randomized, well-matched control group limited the study [62]. However, McNamara et al. [63] reported that improvement of left ventricular ejection fraction was identical in both the intravenous immune globulin treatment arm and in the placebo arm. These results suggest that for patients with recent-onset dilated cardiomyopathy, immunoglobulins do not improve left ventricular ejection fraction. There are no reliable data for the application of this type of therapy in the adult population with viral myocarditis who do not respond to immunosuppressive therapy [61].

Adsorptive immune therapy. Involves the use of plasmapheresis to remove circulating cytokines and antibodies to cardiomyocytes, beta-adrenergic receptors, adenosinetriphosphate carriers, myosin. If this treatment is applied five or more days, beside elimination of circulating antibodies and immune complexes, it also effects the elimination from the heart muscle. Removal of circulating antibodies by immunoadsorption improved cardiac function and clinical and humoral markers of heart failure severity (NT-proBNP) [64]. Immunoadsorption can also decrease myocardial inflammation, and in patients with inflammatory cardiomyopathy, left ventricular systolic function improved after protein A immunoadsorption [65]. The value of adsorptive immune therapy should be confirmed in larger studies.

Monoclonal antibodies. There are some data about possible use of monoclonal antibodies in myocarditis due to T-cell mediated inflammation. Wang et al. [66]. showed that administration of anti-CD4 monoclonal antibody can induce immune tolerance to porcine cardiac myosin. Cardiac function of antibody-treated rats was significantly increased compared with untreated rats 18 days postimmunization examined by transthoracic echocardiography. Also, antibody-treated rats had no proliferative response to porcine cardiac myosin examined by lymphocyte proliferation assay, and administration of anti-CD4 monoclonal antibody significantly prevented production of anti-cardiac myosin antibodies. The conclusion of that study was that immune tolerance to cardiac myosin could be induced by anti-CD4 monoclonal antibody in vivo, and cardiac dysfunction and myocardial injury could be prevented by induction of immune tolerance.

8. Prognosis

Recovery from acute myocarditis often surprises and delights after life threatening illness. Clinical recovery may be slow and delayed even up to a year or more after delivery. Even when it appears to be complete, a portion of cardiovascular reserve has been lost, as is indicated by the myocytolysis found on biopsy [22]. It is also uncertain how many patients will progress

to cardiomyopathy. Recurrence in future pregnancies is not invariable, but there are few data. Pregnancy should therefore be discouraged in any woman with residual myocardial dysfunction or, if possible, delayed for some years.

9. Summary

Myocarditis is an inflammatory disease of the myocardium that is diagnosed by histological, immunological and immunochemical criteria, and is associated with cardiac dysfunction. There has been greater evidence for myocarditis as a cause of PPCM than any other proposed aetiological factor. The prevalence of acute peripartum myocarditis is unknown because most cases are not recognized on account of non-specific, only mild, or no symptoms, but sudden death may occur. However, the initial presentation may be with acute or chronic heart failure or mimics acute myocardial infarction. The combination of biomarkers from blood samples together with imaging techniques such as echocardiography and MRI may help to confirm the diagnosis of myocarditis. The diagnostic gold standard is endomyocardial biopsy with the histological Dallas criteria in conjunction with the new tools of immunohistochemistry and viral polymerase chain reaction. Whether endomyocardial biopsy should be done in the setting of peripartum myocarditis is still an open question. The most important thing in treatment planning is clinical status of the mother and the fetus. Heart failure in postpartum women should be treated according to guidelines on heart failure. Pregnant women should not receive angiotensin-converting enzyme inhibitors, angiotensin receptor blockers, or warfarin because of potential teratogenic effects. Specific therapy strategies may include: immunosuppressive therapy, interferon, immunoglobulin, immune-adsorptive therapy, immune-modulation. Subsequent pregnancies carry a high risk of relapse, even in women who have fully recovered left ventricular function.

Author details

Marina Deljanin Ilic^{1*} and Dejan Simonovic²

*Address all correspondence to: marinadi@open.telekom.rs

1 Institute of Cardiology, Niška Banja, University of Niš Faculty of Medicine, Serbia

2 Institute of Cardiology, Niška Banja, Serbia

References

- [1] Gelson E, Johnson M, Gatzoulis M, Uebing A. Review Cardiac disease in pregnancy. Part 2: acquired heart disease. *The Obstetrician & Gynaecologist*. 2007;9:83–87.

- [2] Richie C. Clinical contributions to the pathology, diagnosis, and treatment of certain chronic diseases of the heart. *Edinb Med Surg J*. 1849; 2: 333.
- [3] Gouley BA, McMillan TM, Bellet S. Idiopathic myocardial degeneration associated with pregnancy and especially the puerperium. *Am J Med Sci* 1937;19:185–99.
- [4] Demakis JG, Rahimtoola SH, Sutton GC, et al. Natural course of peripartum cardiomyopathy. *Circulation* 1971; 44:1053–61.
- [5] Sliwa K, Hilfiker-Kleiner D, Petrie MC, et al. Current state of knowledge on aetiology, diagnosis, management, and therapy of peripartum cardiomyopathy: a position statement from the Heart Failure Association of the European Society of Cardiology Working Group on peripartum cardiomyopathy. *Eur Heart J* 2010; 12: 767–78.
- [6] Pierce JA, Price BO, Joyce JW. Familial occurrence of postpartal heart failure. *Arch Intern Med* 1963;111:651–55.
- [7] Pearl W. Familial occurrence of peripartum cardiomyopathy. *Am Heart J* 1995;129:421–2.
- [8] Massad LS, Reiss CK, Mutch DG, Hasket EJ. Family peripartum cardiomyopathy after molar pregnancy. *Obstet Gynecol* 1993;81:886–88.
- [9] Melvin KR, Richardson PJ, Olsen EG, Daly K, Jackson G. Peripartum cardiomyopathy due to myocarditis. *N Engl J Med* 1982; 307:731–34.
- [10] Sanderson JE, Olsen EG, Gatei D. Peripartum heart disease: an endomyocardial biopsy study. *Br Heart J* 1986; 56:285–91.
- [11] Rizeq MN, Rickenbacher PR, Fowler MB, Billingham ME. Incidence of myocarditis in peripartum cardiomyopathy. *Am J Cardiol* 1994; 74: 474–77.
- [12] Midei MG, DeMent SH, Feldman AM, Hutchins GM, Baughman KL. Peripartum myocarditis and cardiomyopathy. *Circulation* 1990; 81: 922–28.
- [13] Felker GM, Thompson RE, Hare JM, et al. Underlying causes and long-term survival in patients with initially unexplained cardiomyopathy. *N Engl J Med* 2000; 342:1077–84.
- [14] Bultmann BD, Klingel K, Nabauer M, Wallwiener D, Kandolf R. High prevalence of viral genomes and inflammation in peripartum cardiomyopathy. *Am J Obstet Gynecol* 2005; 193:363–65.
- [15] Pearson GD, Veille JC, Rahimtoola S, et al. Peripartum cardiomyopathy: National Heart, Lung, and Blood Institute and Office of Rare Diseases (National Institutes of Health) workshop recommendations and review. *JAMA* 2000;283:1183–88.
- [16] Farber PA, Glasgow LA. Viral myocarditis during pregnancy: encephalomyocarditis virus infection in mice. *Am Heart J* 1970;80: 96–102.

- [17] Lyden DC, Huber SA. Aggravation of coxsackievirus, group B, type 3-induced myocarditis and increase in cellular immunity to myocyte antigens in pregnant Balb/c mice and animals treated with progesterone. *Cell Immunol* 1984;87:462–72.
- [18] O'Connell JB, Costanzo-Nordin MR, Subramanian R, et al. Peripartum cardiomyopathy: clinical, hemodynamic, histologic, and prognostic characteristics. *J Am Coll Cardiol* 1986;8:52–56.
- [19] Kovithavongs T, Dossetor JB. Suppressor cells in human pregnancy. *Transplant Proc* 1978;10:911–3.
- [20] Thong YH, Steele RW, Vincent MM, Hensen SA, Bellanti JA. Impaired in vitro cell-mediated immunity to rubella virus during pregnancy. *N Engl J Med* 1973;289:604–06.
- [21] D'Cruz IA, Balani SG & Iyer LS. Infectious hepatitis and pregnancy. *Obstet Gynecol* 1968;31:449–55.
- [22] Oakley, CM. Myocarditis, pericarditis and other pericardial diseases. *Heart* 2000;84:449–54.
- [23] Coyne CB, Bergelson JM. Virus-induced Abl and Fyn kinase signals permit coxsackie virus entry through epithelial tight junctions. *Cell* 2006; 124: 119-31.
- [24] Cooper LT, Rader V, Ralston NV. The roles of selenium and mercury in the pathogenesis of viral cardiomyopathy. *Congest Heart Fail* 2007; 13: 193-99.
- [25] Mahfoud F, Gärtner B, Kindermann M, et al. Virus serology in patients with suspected myocarditis: utility or futility? *Eur Heart J* 2011; 32: 897-903.
- [26] Murphy JG. Peripartum cardiomyopathy. In: Cooper LT, editor. *Myocarditis: from bench to bedside*. Totowa (NJ): Humana Press; 2003. p. 589–608.
- [27] Bachmaier K, Neu N, de la Maza LM, Pal S, Hessel A, Penninger JM. Chlamydia infections and heart disease linked through antigenic mimicry. *Science* 1999;283:1335–39.
- [28] Cenac A, Djibo A, Sueur JM, Chaigneau C, Orfila J. Chlamydia infection and peripartum dilated cardiomyopathy in Niger. *Med Trop(Mars)* 2000;60:137–40.
- [29] Ansari AA, Neckelmann N, Wang YC, Gravanis MB, Sell KW, Herskowitz A. Immunologic dialogue between cardiac myocytes, endothelial cells and mononuclear cells. *Clin Immunol Immunopathol* 1993;68:208–14.
- [30] Sliwa K, Skudicky D, Bergemann A, Candy G, Puren A, Sareli P. Peripartum cardiomyopathy: analysis of clinical outcome, left ventricular function, plasma levels of cytokines and Fas/APO-1. *J Am Coll Cardiol* 2000;35:701–05.
- [31] Karaye KM, Henein MY Peripartum cardiomyopathy: A review article *Int J C International Journal of Cardiology* 2011;150:325-31.

- [32] Ansari AA, Fett JD, Carraway RE, Mayne AE, Onlamoon N, Sundstrom JB. Autoimmune mechanisms as the basis for human peripartum cardiomyopathy. *Clin Rev Allergy Immunol* 2002; 23:301–324.
- [33] Knobel B, Melamud E, Kishon Y. Peripartum cardiomyopathy. *Isr J Med Sci* 1984;20:1061–63.
- [34] Ukena C, Mahfoud F, Kindermann I, et al. Prognostic electrocardiographic parameters in patients with suspected myocarditis. *Eur J of Heart Failure* 2011; 13: 398-405.
- [35] Smith SC, Ladenson JH, Mason JW, et al. Elevations of cardiac troponin I associated with myocarditis. Experimental and clinical correlations. *Circulation* 1997;95:163–68.
- [36] Forster O, Hilfiker-Kleiner D, Ansari AA, et al. Reversal of IFN-gamma, oxLDL and prolactin serum levels correlate with clinical improvement in patients with peripartum cardiomyopathy. *Eur J Heart Fail* 2008;10:861–68.
- [37] Karjalainen J, Heikkila J. Incidence of three presentations of acute myocarditis in young men in military service: a 20 year experience. *Eur Heart J* 1999;20:1120–25.
- [38] Galderisi M, Henein MY, D'hooge J, et al. European Association of Echocardiography. Recommendations of the European Association of Echocardiography: how to use echo-Doppler in clinical trials: different modalities for different purposes. *Eur J Echocardiogr* 2011;12:339–53.
- [39] Mouquet F, Lions C, de Groot P, Bouabdallaoui N, Willoteaux S, Dagorn J, Deruelle P, Lamblin N, Bauters C, Beregi JP. Characterisation of peripartum cardiomyopathy by cardiac magnetic resonance imaging. *Eur Radiol* 2008;18: 2765–69.
- [40] Di Bella G, de Gregorio C, Minutoli F, et al. Early diagnosis of focal myocarditis by cardiac magnetic resonance. *Int J Cardiol* 2007; 117:280–81.
- [41] Baccouche H, Mahrholdt H, Meinhardt G, et al. Diagnostic synergy of non-invasive cardiovascular magnetic resonance and invasive endomyocardial biopsy in troponin-positive patients without coronary artery disease. *Eur Heart J* 2009; 30: 2869-79.
- [42] De Wilde JP, Rivers AW, Price DL. A review of the current use of magnetic resonance imaging in pregnancy and safety implications for the fetus. *Prog Biophys Mol Biol* 2005;87:335–53.
- [43] Laissy JP, Hyafil F, Feldman LJ, et al. Differentiating acute myocardial infarction from myocarditis: diagnostic value of early- and delayed-perfusion cardiac MR imaging. *Radiology* 2005; 237:75–82.
- [44] Kanal E, Barkovich AJ, Bell C, et al. ACR guidance document for safe MR practices: 2007. *AJR Am J Roentgenol* 2007;188:1447–74.
- [45] Webb JA, Thomsen HS, Morcos SK. The use of iodinated and gadolinium contrast media during pregnancy and lactation. *Eur Radiol* 2005;15:1234–40.

- [46] Aretz HT, Billingham ME, Edwards WD. Myocarditis: a histopathological definition and classification. *Am J Cardiovasc Pathol* 1987;1:3–14.
- [47] Lieberman EB, Hutchis GM, Herskowitz A, Rose NR, Baughman KL. Clinicopathologic description of myocarditis. *J Am Coll Cardiol*. 1991;18:1617-26.
- [48] Leurent G, Baruteau AE, Larralde A, et al. Contribution of cardiac MRI in the comprehension of peripartum cardiomyopathy pathogenesis. *Int J Cardiol* 2009; 132:91–3.
- [49] Cooper LT, Baughman KL, Feldman AM, et al. The role of endomyocardial biopsy in the management of cardiovascular disease: a scientific statement from the American Heart Association, the American College of Cardiology, and the European Society of Cardiology. Endorsed by the Heart Failure Society of America and the Heart Failure Association of the European Society of Cardiology. *Eur Heart J* 2007; 28:3076–93.
- [50] Baughman KL. Peripartum cardiomyopathy. *Curr Treat Options Cardiovasc Med* 2001; 3:469–80.
- [51] Vera Regitz-Zagrosek, Carina Blomstrom Lundqvist, Claudio Borghi et al. Guidelines on the management of cardiovascular diseases during pregnancy. The Task Force on the Management of Cardiovascular Diseases during Pregnancy of the European Society of Cardiology (ESC). *Eur Heart J* 2011; 32: 3147–97.
- [52] John J.V. McMurray JJV, Adamopoulos S, Stefan D. Anker SD, et al. ESC Guidelines for the diagnosis and treatment of acute and chronic heart failure 2012. The Task Force for the Diagnosis and Treatment of Acute and Chronic Heart Failure 2012 of the European Society of Cardiology. Developed in collaboration with the Heart Failure Association (HFA) of the ESC. *Eur Heart J* 2012; 33: 1787–1847.
- [53] Cooper WO, Hernandez-Diaz S, Arbogast PG, Dudley JA, Dyer S, Gideon PS, Hall K, Ray WA. Major congenital malformations after first-trimester exposure to ACE inhibitors. *N Engl J Med* 2006;354:2443–51.
- [54] Andrade SE, Raebel MA, Brown J, et al. Outpatient use of cardiovascular drugs during pregnancy. *Pharmacoepidemiol Drug Saf* 2008; 17:240–47.
- [55] Sliwa K, Fett J, Elkayam U. Peripartum cardiomyopathy. *Lancet* 2006; 368:687–93.
- [56] Narin C, Reyhanoglu H, Tulek B, et al. Comparison of different dose regimens of enoxaparin in deep vein thrombosis therapy in pregnancy. *Adv Ther* 2008; 25:585–94.
- [57] Khul U, Pauschinger M, Schwimmbeck PL, et al. Interferon-beta treatment eliminates cardiotropic viruses and improves left ventricular function in patients with myocardial persistence of viral genomes and left ventricular dysfunction. *Circulation* 2003; 107: 2793-98.
- [58] Schmidt-Lucke C, Spillmann F, Bock T, et al. Interferon-beta modulates endothelial damage in patients with cardiac persistence of parvovirus B19V. *J Infect Dis* 2010; 201: 936-45.

- [59] Fett JD. Inflammation and virus in dilated cardiomyopathy as indicated by endomyocardial biopsy. *Int J Cardiol* (2006)., 112:125–26.
- [60] Frustaci A, Russo M, Chimenti C. Randomized study on the efficacy of immunosuppressive therapy in patients with virus-negative inflammatory cardiomyopathy: the TIMIC study. *Eur Heart J* 2009; 30: 1995–2002.
- [61] Lui PP, Schultheiss HP. Myocarditis. In: Braunwald E, Zipes DP, Libby P, (eds). *The Text Book Of Cardiovascular Medicine - 8th edition*. WB Saundres Company, Philadelphia – Toronto 2007; 1775-92.
- [62] Bozkurt B, Villaneuva FS, Holubkov R, et al. Intravenous immune globulin in the therapy of peripartum cardiomyopathy. *J Am Coll Cardiol* 1999;34:177– 80.
- [63] McNamara DM, Holubkov R, Starling RC, et al. Controlled trial of intravenous immune globulin in recent-onset dilated cardiomyopathy. *Circulation* 2001; 103:2254–59.
- [64] Herda L.R., Trimpert C., Nauke U.; et al. Effects of immunoadsorption and subsequent immunoglobulin G substitution on cardiopulmonary exercise capacity in patients with dilated cardiomyopathy, *Am Heart J* 2010;159: 809-16.
- [65] Bulut D., Scheeler M., Wichmann T., Borgel J., Miebach T., Mugge A.; Effect of protein A immunoadsorption on T cell activation in patients with inflammatory dilated cardiomyopathy, *Clin Res Cardiol*. 2010; 99:633-38.
- [66] Wang QQ, Wang YL, Yuan HT et al. Immune tolerance to cardiac myosin induced by anti-CD4 monoclonal antibody in autoimmune myocarditis rats. *J Clin Immunol*. 2006; 26(3): 213-21.

