

We are IntechOpen, the world's leading publisher of Open Access books Built by scientists, for scientists

4,800

Open access books available

122,000

International authors and editors

135M

Downloads

Our authors are among the

154

Countries delivered to

TOP 1%

most cited scientists

12.2%

Contributors from top 500 universities



WEB OF SCIENCE™

Selection of our books indexed in the Book Citation Index
in Web of Science™ Core Collection (BKCI)

Interested in publishing with us?
Contact book.department@intechopen.com

Numbers displayed above are based on latest data collected.
For more information visit www.intechopen.com



Implant-Based Dual-Plane Reconstruction of the Breast Following Sparing Mastectomy

Egidio Riggio and Maurizio B. Nava

Additional information is available at the end of the chapter

<http://dx.doi.org/10.5772/56466>

1. Introduction

The immediate restoration of the breast is considered as the most favourable treatment for women undergoing a primary mastectomy since many years, but it is not always true as it can occur in case of radiation therapy. Nowadays many patients care the aesthetics of the breast more than only ten years ago. An immediate definite reconstruction is unfrequently achievable using flaps or implants due to both clinical and surgical reasons. In our institution, a one-stage reconstruction embraces a minor part of patients. The first improvement of the cosmetic outcome starts with the preservation of native skin envelope in the immediate breast reconstruction (IBR) when this event is followed by less visible scars and reduced risk for skin necrosis. Toth and Lappert [1] described a skin-sparing mastectomy in 1991. The reconstructions without nipple are less pleasant as already suggested by Wellisch et al. [2] Furthermore the nipple is often difficult to be restored with the same characteristics present before a skin-sparing mastectomy (SSM). Moreover preserving nipple and areola is much more grateful for the patients. The problem can arise if the breast is ptotic or large breast where the maintenance of redundant skin and nipple is risky. A moderate periareolar deepithelization or a skin-reducing mastectomy would be helpful trying to maintain more blood supply to the nipple-areola complex and skin around. [3] By the way, apart of the plastic surgery's implications, nipple-sparing mastectomy (NSM) is already the gold standard in the women at high genetic risk (BRCA1-2) as risk-reducing mastectomy. [4-6] Based on the expectations of more conservative approaches, NSM is progressively extending the indications in the treatment of the breast cancer, such as multifocal IDCs, T1-T2 IDC, T3 after tumor regression by neoadjuvant therapy. [7] The local recurrence risk is acceptable after peripheral tumors smaller than 3 cm. [8-11]

The challenging goal of any IBR is given by the chance for a one-stage procedure with the same complication rate and aesthetic outcome as the two-stage reconstruction. In the past the single-stage reconstruction with implants was consistently considered more complicated and risky than the reconstruction with autologous flap. [12] However complications were reported in all the immediate reconstructions, not only using permanent implants. [13] In addition poor IBR results were strictly related to both the inadequate surgical skill and the unsatisfactory selection for the right patient or breast implant as well. [14] Also the permanent expander alone or combined to the latissimus dorsi flap was extensively considered in some institutions as demonstrated by Gui et al. [15] The current standard for the implant reconstruction after mastectomy is the two-stage reconstruction with temporary expander followed by permanent implant, and secondarily the reconstruction using autologous free and pedicled flaps.

In the last decade the Acellular Dermal Matrix (ADM) has been used and successfully reported into the expander-based reconstruction especially in US, even if associated to higher incidence of seroma (3.9%), infection (2.7%) and total failure (3.0%) as underlined in a meta-analysis of complications recently published. [16] Moreover ADM significantly adds a cost to the two-stage IBR and hence but only few publications suggest single-stage implant-based IBR with ADM in a positive way. [17, 18] Theoretically it would be expected that ADM can facilitate the IBR in one stage, i.e. without using temporary expander. The oncoplastic surgeons that are still using successfully the two-stage reconstruction with expander but with no kind of mesh, frequently occurring in Europe, cannot understand the real advantage of ADM in two steps. The need for ADM or synthetic mesh in case of expander-based reconstruction may be due to the behaviour of the breast surgeon that does not spare both muscular fascia and a strip of soft tissues along the submammary fold during mastectomy. The one-stage procedure offers significant advantages: reducing recovery costs, avoiding the fixed second operation, decreasing the days of convalescence (including the series of tissue expansion) and achieving a more prompt restoration of body image and perception. [19]

The key point of any single-step IBR is the correct selection of patients where a satisfactory grade of symmetry can be reached. The patient expectations for the best and most prompt cosmetic result have greatly increased compared to only ten years ago. Nevertheless the ideal procedure is still far from being found.

In the meantime, based on the refusal for dermal matrix derived by cadaver human-tissue like Alloderm (Lifecell Corp., Branchburg NJ USA) mainly in Europe, the marketing system is proposing new biomeshes [20-22], like the Strattice (Lifecell Corp., Branchburg NJ USA) and the Meso Biomatrix (Kensey Nash Corp. Exton PA USA) derived by porcine dermis and mesothelium respectively as well as alloplastic meshes, i.e. the TiLOOP made of titanized polypropylene (Pfm medical titanium, GfE Medizintechnik GmbH, Nurnberg Germany) or the Seriscaffold of biodegradable silk (Allergan Inc. Irvine CA USA).

In our opinion far from commercial inputs, on the contrary, the breast meshes should have a limited use in case of IBR while a well-tailored surgical technique can still achieve more physiological outcomes. The dual-plane technique here illustrated is an example how a feasible

autologous pocket for silicone implant allows to reach the goal of a breast reconstruction in a single procedure.

2. Immediate reconstruction after primary breast cancer

Breast reconstruction should ideally be both immediate and definitive so as to avoid patients undergoing further surgery later. It is generally considered, from an oncological and psychological point of view, that there are no contraindications to immediate reconstruction excepting particular cases but it is not so clear about the definite single stage, whereas it is already established for the breast cancer conservative treatment. [23]

One-stage reconstruction after skin-sparing-mastectomy and specially nipple-sparing mastectomy (NSM) is performed thanks to several procedures: a) autologous flaps (DIEP, TRAM, Latissimus dorsi + implant); b) autologous preparation of the pocket used for permanent implant (saline or silicone)/expandable permanent implant (Becker or other types), c) preparation of an implant pocket with support of autologous (tissue biomatrix) or alloplastic meshes tailored for breast surgery. The one-stage IBR might not always be indicated, e.g. in presence of local radiated tissues where a delayed reconstruction is often formerly discussed with the patient. The example of the autologous flaps may be paradigmatic. Flaps have the great benefit of restoring the breast with soft and well-vascularized tissues, and this advantage becomes essential when breast tissues were before irradiated. Nevertheless when reconstruction is immediate, there are side effects that withdraw from the elective choice of a distant flap for several reasons: a) longer operation and recovery time with all the related medical complications; b) misunderstanding of the real implications of that kind of surgery in patients much more worried of cancer implications at the moment of the pre-op consultation; c) higher hazard for postponement of the oncological care (chemotherapy or irradiation) in case of flap failure and wound complications, that are more severe if compared with reconstruction by silicone implant, although their occurrence is infrequent. Flap failure after IBR strongly compromises patient body image and self-esteem, and moreover complicates any further reconstruction. Some review studies recommend delayed flap reconstruction in patients at high risk for adjuvant radiation therapy. [24, 25] On the contrary, in case of expander or prosthesis, also the worst complication could be treated by an easier removal of the device, with a limited delay of the cancer therapy. Moreover this failure can be solved afterward by using a flap or a tissue expander another time.

IBR does not interfere with the progress of the disease but it should be chosen the less risky procedure to reconstruct the breast. The ideal treatment must reduce at a minimum the occurrence of major surgical complications that can significantly delay the following chemotherapy and/or radiotherapy in breast cancer patients. In such a way, also the ADM, the other kinds of biomatrix, and in particular the alloplastic meshes can conceal higher incidence of complications, seroma and implant extrusion as first, then extreme thinning of the lower pole soft tissue above the implant compared with an autologous IBR performed only through a special preparation of the muscular and fascial pocket for implant.

We believe that the permanent implant pocket must retain these special features to have a final success: a) to be well vascularized, b) to be resilient, pliable, and adequately large; c) to be separated from the subcutaneous mastectomy pocket and the axillary cavity, as to decrease the risk for seroma or infection; to be partially free of the active contractions and reactive stiffness of the pectoralis maior muscle but contemporarily avoiding any malposition and malrotation of the implant.

Since mastectomy interferes with the psychologic, social, and sexual well-being of the women, it should be proper that the final statement about the kind of breast reconstruction is going to be realized by a well-informed patient. She must have the right of opting for both the immediate and easiest type of reconstruction, also the patient with a radiation to be post-operatively planned or that with a poor cancer prognosis. In that case she may promptly have something looking like a breast. It does not matter if the implantable device will be a permanent implant or a "temporary" saline expander as well.

3. Planning for the one-stage implant-based breast reconstruction

Contrary to prior surgical approaches to implant-based IBR and without use of dermal matrix and alloplastic mesh, the technique here described permits to extend the one-stage reconstruction to patients with larger breast or minimal ptosis, even satisfying the demand of bilateral enlargement of the breast. The technique is easier to be used in bilateral mastectomies either for those sparing the nipple or those sparing only skin, in unilateral mastectomy, preferably if nipple-sparing.

3.1. Clinical fundamentals

Some of the patients undergoing skin- or nipple-sparing mastectomy can be eligible for this kind of IBR, nearly the 30%. The ideal breast is the breast without ptosis, with weight less than 500 g, with good skin elasticity or at least moderate redundancy as occurring in the skin after pregnancy. The last is the most favourable condition in order to plan augmentation of the prior breast size. Women with large breast (D/DD breast cup size) or severe ptosis and the obese patients must be excluded. Cautious contraindications are given by the heavy smoker patient (>30 cigarettes a day) or by the breast with multiple prior scars. However the primary evaluation is addressed towards the expectations of the single women about the breast shape and size. It is not psychologically easy to explain all the plastic and cosmetic aspects to a women often worried by the cancer just discovered and distressed thinking about the incoming oncological treatments. The mood of many patients may not allow good understanding of some among the following queries: 1-stage vs. 2-stage reconstruction; implant vs. autologous flap; expander vs. permanent implant; best shape vs best symmetry of the breast; timing of the complimentary contra-lateral surgery and hence choice for augmentation, mastopexy or reduction respectively.

Immediate aesthetic correction of the healthy breast is suggested in the majority of the patients requiring total augmentation. On the contrary, if required, pexy is much better to be carried

out at a second stage. Adequate symmetry is very difficult to be attained in case of contralateral reduction as well as pexy alone or with augmentation. The nipple-areola position and breast size cannot be well planned during mastectomy because the definitive shape of the new breast and the same nipple/areola position are to be evaluated after healing. The risk for asymmetric displacement is real in case of every nipple-sparing mastectomy. Moreover, it is well known that the nipple/areola complex can be barely placed in another position after mastopexy or breast reduction. For this type of patients the contralateral surgery should be delayed regardless of the possibility of IBR in a single step. The decision to plan a larger implant size and also decide the ultimate augmentation of the healthy breast can be taken at the time of the pexy or reduction as well.

On the other hand, permanent implant can also be changed with another of better shape and volume corresponding to the contra-lateral breast at a second stage that becomes possible, but not necessary, if symmetry is already satisfactory following the previous immediate reconstruction. It should be clear to the patient that the one-stage reconstruction with a permanent implant gives a prompt and definitive result but is not unchangeable. In fact a surgical revision may always take place improving all the breast, if the result is not satisfactory.

Another preoperative valuation regards the preservation of soft tissues in the lower section of the breast, which means not only in the inner plane but also in the outer, i.e. the skin. The dual-plane technique cannot match up with those surgical approaches planning inframammary or vertical incision for the mastectomy. [26] These incisions can compromise any natural refilling of the lower breast, and hence lead to the insertion of expander instead of permanent implant, or to the aid of ADM with higher costs for the hospital. The overall preference for a lateral radial, even in presence of previous areola scars, is supported by data reported in literature, Riggio et al. [27] reported 1% of areola necrosis in a preliminary clinical study. Garwood et al. [28] decreased the same risk to a 5% rate, and pointed out that the incision of at least 30% of areola circumference is already to be considered as independent risk factor for necrosis. Of course, the lateral radial incision is preferred because of lower risk of skin ischemia and of more accurate dissection behind nipple and areola, but it is not enough if the mastectomy does not spare the whole subcutaneous layer and its vascular network. Sometimes incision can include earlier lumpectomy scars and partial areolar incision are performed in presence of prior scars. The periareolar deepithelialization is rarely carried out if there is vertical skin excess.

3.2. Anatomical fundamentals

Any preparation for a full-coverage autologous pocket, i.e. made of local tissues of the breast, first bases on the thorough preservation of the inframammary fold frame during mastectomy. The real anatomy of the superficial fascial system inside the submammary fold unit was finely described by Riggio et al. (2000), Fig.1. [29]

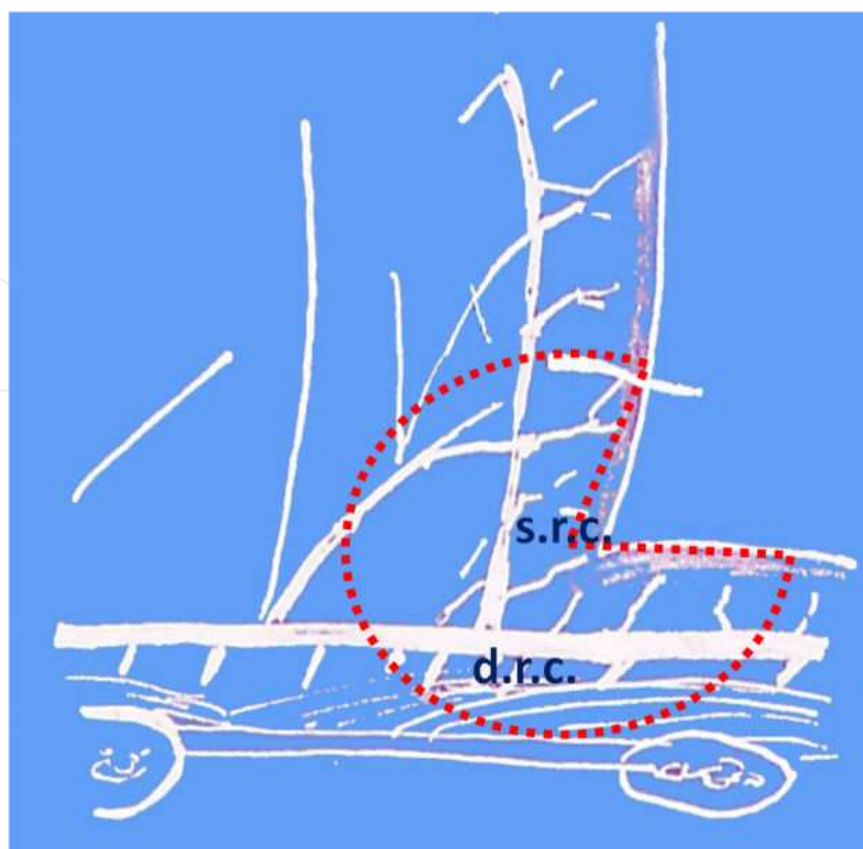


Figure 1. The inframammary fascial system: *s.r.c.*, *superficial retinacula cutis* into the superficial subcutaneous (adipose) layer between skin and superficial fascia and its annex (the breast gland envelope); *d.r.c.*, *deep retinacula cutis* into the deep subcutaneous (areolar/adipose) layer between superficial fascia and deep fascia (the musculo-fascial plane). The density and thickness of the connective frame is here particular, *the dotted red encircle*. There is also thin areolar tissue between muscle and rib cage.

The fine anatomy is made of multiple subcutaneous attachments, i.e. thickened retinacula between the superficial and deep fascia (zone of adherence), where contiguous connective micro-frames of the superficial and deep subcutaneous layers persist as different anatomical microunits of the same fascial frame, as according to the functional concept of skin-superficial fat-superficial fascial system described by Lockwood in the trunk and extremities (1991) and to the study of Nava et al. (1998) that already explained the fascial system in the surgical reconstruction of the inframammary fold. [30, 31]

Maintaining the attachments of the inframammary fascial system at the deep plane (fascio-muscular layer) is mandatory along all the inframammary contour (Fig.2). The breast surgeon has to avoid any cut or undermining at the submammary level, in both the superficial and deep subcutaneous layers. Maintaining a few millimeters of soft tissues above the inframammary line can totally spare the connections, also called (deep retinacula) between the superficial system and muscular plane. This care allows the mastectomy field to be maintained far from the submuscular pocket for implant.

The preservation of the pectoralis fascia is viable and its resection is not justified by any evidence-based oncological reason in routine modified radical mastectomy for invasive breast

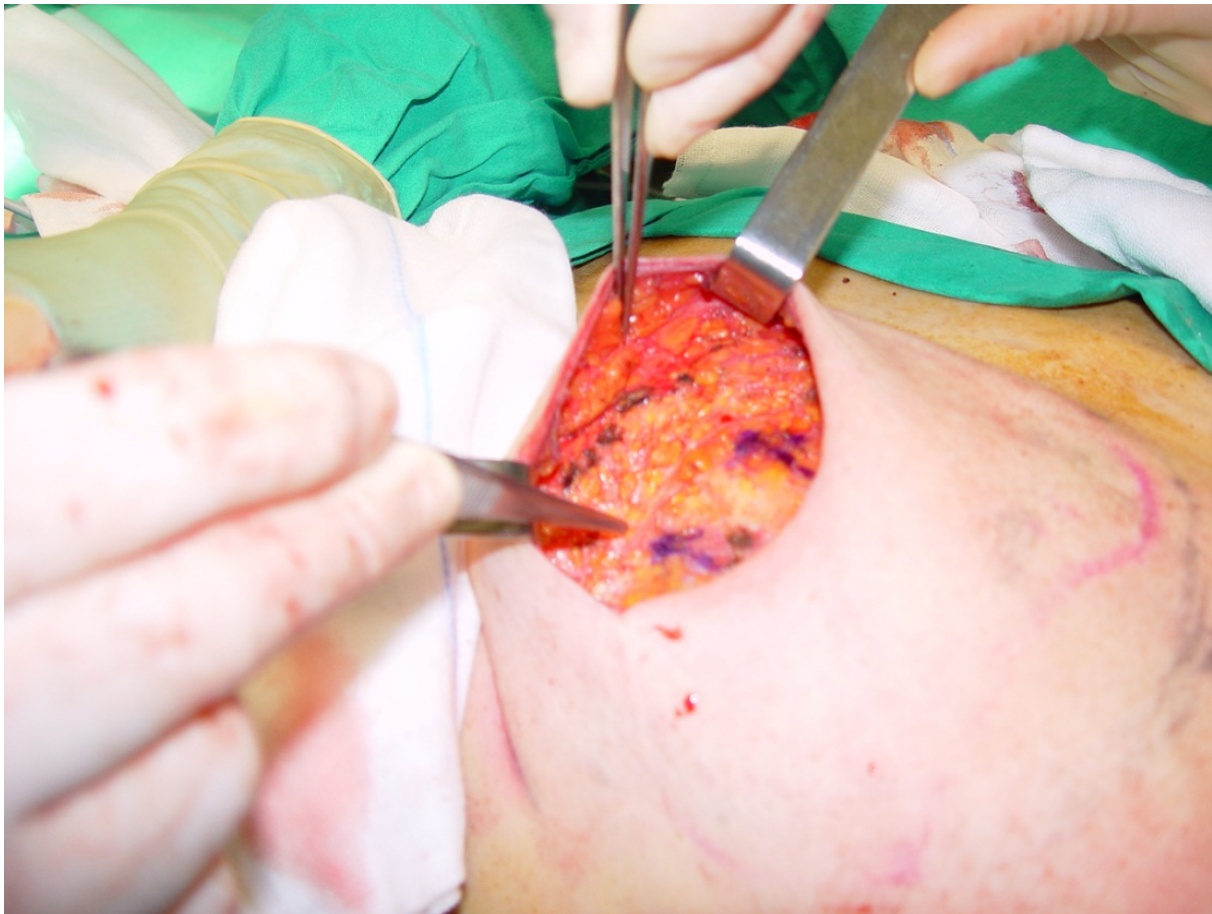

Figure 2. The inframammary superficial fascia, direct prolongation of the abdominal fascia (Scarpa's fascia), extends to the retromammary space and properly links the superficial connective frame to the deep fascia (the pectoralis maior and serrate anterior muscular plane) along all the inframammary fold. The mastectomy must preserve this strip of soft tissue after dissecting off the breast gland. *Intra-operative view.*

cancer. [32] On the other hand, sparing this fascia is also important that occurs at two levels: 1) at the inferomedial portion because it allows to release the muscle insertions preserving the stability of the implant coverage; 2) close to the free border of the pectoralis maior and above the serratus anterior because it allows correctly to suture the pocket above the implant without dehiscence.

Before starting with reconstruction (Fig.3), the plastic surgeon must check the following topics: a) the anatomical quality of the surgical field (some conditions interfere with the pocket preparation, e.g. cranial insertions of the pectoralis maior muscle far from the inframammary level); b) a prior mastectomy dissection carefully preserving both the inframammary fascial system and the deep fascia along the lower border of the pectoralis maior muscle. Any leakage should be sutured using vicryl 2/0 stitches but, if the musculofascial layer is going to tear again, the plan for permanent implant must be discontinued pro expander, avoiding the saline inflation intra-operatively. All patients have before to be warned that the insertion of a permanent implant is not sure until the end of the surgical procedure.

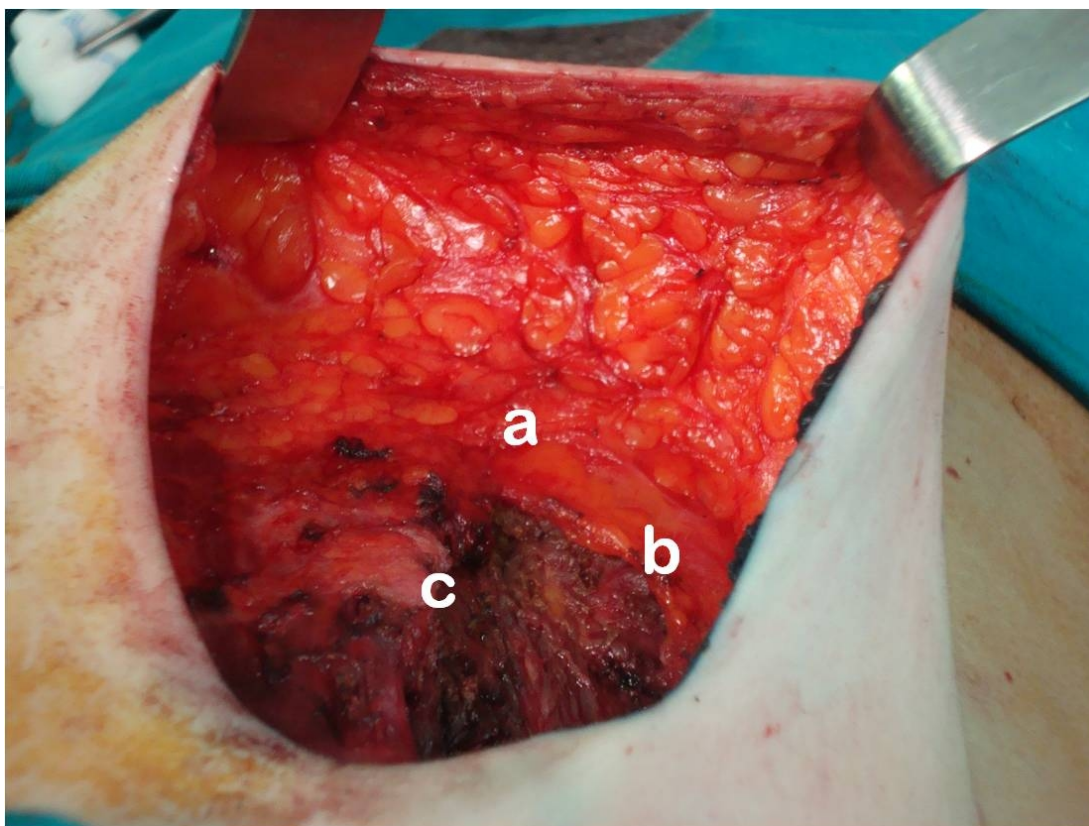


Figure 3. The surgical field of the submammary zone after radical modified mastectomy with preservation of: a) the inframammary unit, made of subcutaneous fatty tissue, superficial fascia and related retinacula; b) both aponeurosis of the pectoralis major and serratus anterior muscle and likely the fascia between the two muscles (this layer, if discontinued by the prior dissection must be rebuilt using some stitches or occasionally a small patch of absorbable material; c) the muscles and proper fascia (deep fascia). The surgeon that destroys the submammary fascial frame precludes the immediate chance for any satisfying 1-stage reconstruction with silicone implant.

4. The dual-plane pocket for 1-stage immediate reconstruction with highly-cohesive implants

The best presentation in IBR is given by the aesthetic preservation of the nipple-areola complex when oncologically safe. The removal of skin around the nipple limits the use of the same technique in the skin-sparing group of mastectomy. Maintaining all the breast skin envelope results in skin redundancy which becomes too wide in case of larger or pendant breast. The skin, after the Cooper's ligaments resection, is free to extend, especially when skin is less elastic (after weight loss, pregnancy, aging). Side effect of the skin excess is the growing risk for the necrosis of the inner skin. This complication is uncommon if patient selection and subcutaneous dissection are correct whilst, on the other hand, other complications are common as skin folding, scar retraction, and NAC displacement. They are difficult to be solved secondarily and really compromise breast aesthetics and body perception. IBR gives an answer to this problem related to skin excess and tries immediately to replace as much as possible the volume loss

after parenchyma excision with larger implants. A prompt expansion volume is able of filling, or better overfilling, the skin envelope and stabilizing the nipple position. The cutaneous envelope of the breast is consistently major than the respective volume breast only except the teenager's breast. On the contrary, a T-inverted skin reduction together with the nipple preservation, jeopardize the vascular supply to the same nipple and areola apart from the implant dimensions. Breast shape can be outlined by a tear-drop device with high-cohesive silicone and then better maintained through the gel memory. Highly cohesive implants generate a certain strain strength on the envelope at the same way as a rapid expansion does. This is more stable than the strenght produced by saline expander or low-cohesive gel devices. Highly cohesive gel withstands external pressures, e.g. muscular strenght or scar-tissue retraction, with poor inner displacement of the filling gel. Bio-mechanics of the forces acting on the female breast and the physical properties of breast tissues are strictly related to every plastic surgery procedure but, unfortunately, their knowledge is still less than average. [33, 34] We can take advantage from the bio-mechanical properties of the high-cohesive gel, soft tissue and muscle too, preparing a full-vascularized, partially sub-muscular, complete coverage for the implant. The pocket must not be the same as the pocket prepared for an expander to be inflated progressively after surgery and then substituted. Surgical refinements must be maximized in a single-stage reconstruction. In addition, the planning for implant size and shape is more and more challenging in IBR in order to achieve the best symmetrical outcome.(Fig 4)

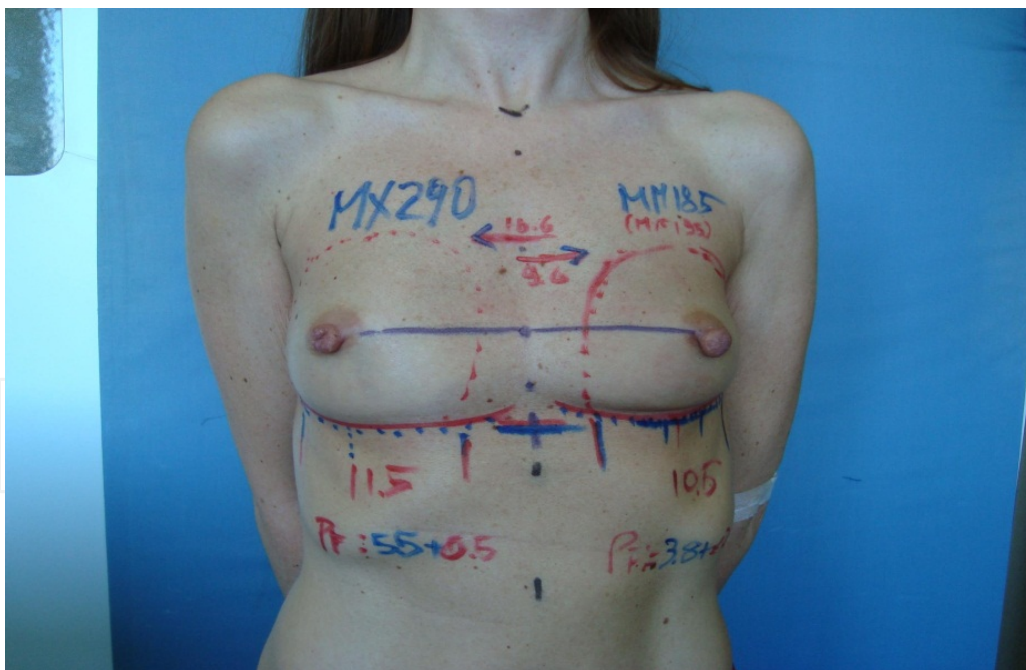


Figure 4. Preoperative planning for nipple-sparing mastectomy (DCIS) + IBR with anatomical implant (natrelle high-cohesive 410MX 290g) in the right breast and submuscular augmentation (natrelle high-cohesive 410MM 185g)

The selection for tear-drop implants will depend on the anatomic landmarks of breast and chest wall in the same way as planned in aesthetic surgery. Width, height, and projection are

to be measured choosing shape and size of the implant. Here width and height of implant are difficult to be planned accurately compared to the selection for a temporary expander or to the 2-stage reconstruction (expander substitution). Only bilateral reconstruction makes easier the choice, here the preliminary indications are consistently maintained during surgery. Intra-operatively plastic surgeon must evaluate the limits of breast removal and the remaining soft-tissue thicknesses in order to change the implant in width or height usually by about 0.5-1 cm more or less. It is also recommended to weigh the specimen after mastectomy and compare the breast weight with the implant weight taking into account that is better to choose an implant a little bigger than the breast weight. Soft-tissue retraction and atrophy can occur after normal healing or radiotherapy. When contemporary enlargement of the contralateral breast is planned, augmentation is preferably sub-muscular with the aim of improving implant symmetry and better screening of the healthy breast.

4.1. Submuscular preparation of the pocket: Part I

After harvesting the free edge of the pectoralis maior muscle, with identification of the deeper pectoralis minor muscle (Fig. 5), dissection begins from the lateral part of the proper fascia of pectoralis minor and carries below the of the serratus anterior muscle and proper fascia laterally and downward (Fig. 6).

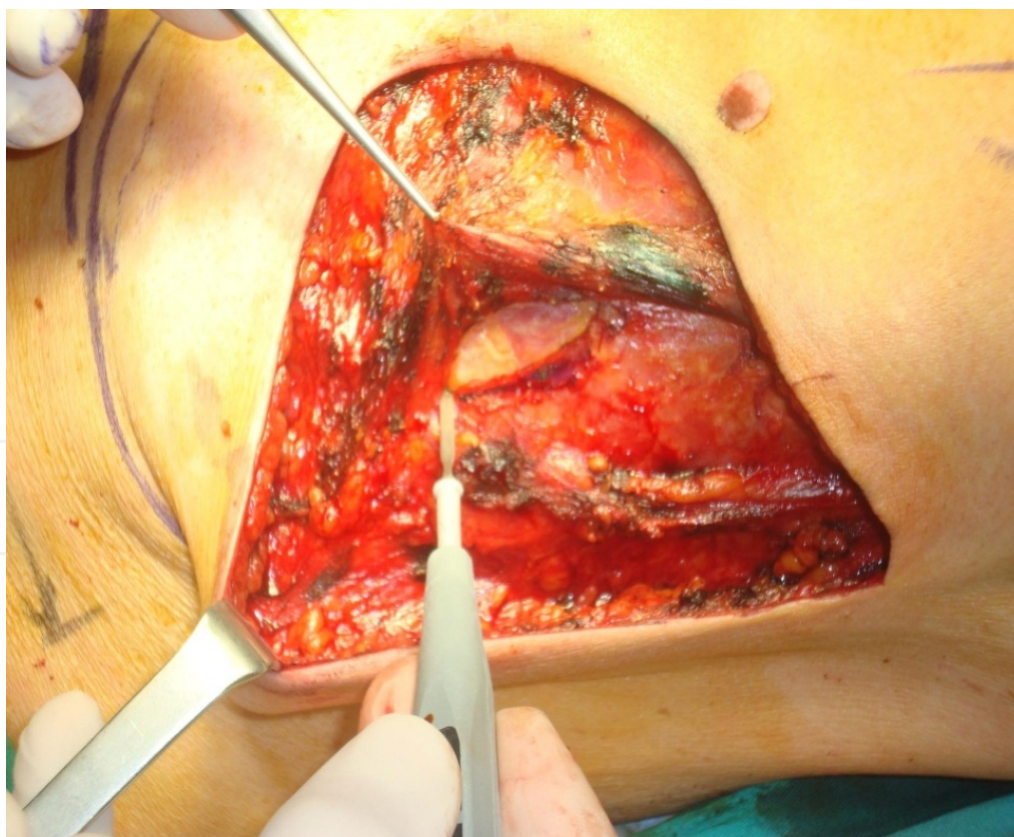


Figure 5. Along the upper lateral border of the pectoralis maior muscle, scoring the deep muscular fascia towards the pectoralis minor muscle.

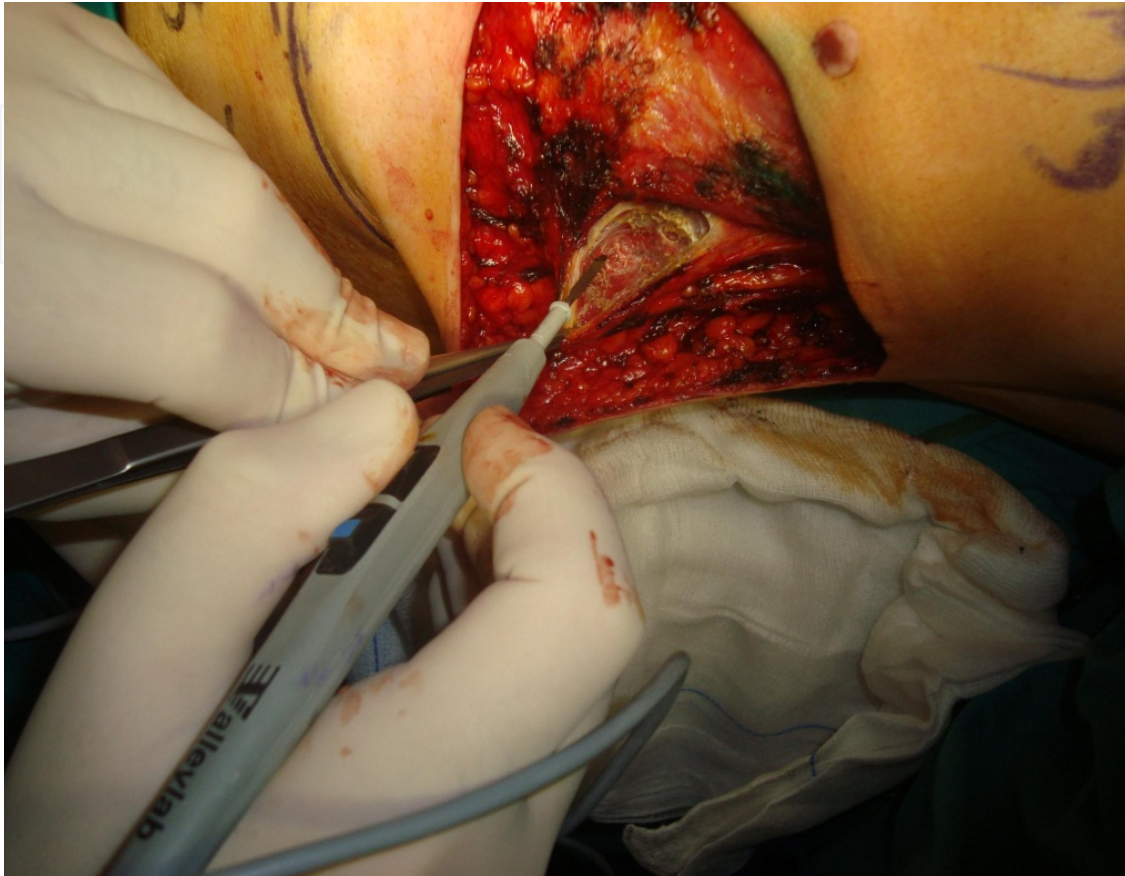


Figure 6. Harvest of the serratus anterior fascia and muscle, never only fascia, but trying to split the muscular fibers

Serratus anterior muscle can be split using an intramuscular dissection when the thickness is adequate and the proper fascia has been spared during mastectomy. The aim is leaving a layer of muscle fibers above the rib cage with the following effects: a) a more pliable coverage in the lateral side of the device pocket; b) maintenance of some active work of the deeper part of the muscle; pain reduction after surgery. The lateral limit of the pocket must exactly correspond to the implant width at the aim of avoiding implant malposition.

Then the upper and medial undermining is carried out under the pectoralis maior muscle and the extension will depend on the implant size. The pocket width must precisely correspond to the device width in order to avoid any lateral malposition (Fig. 7)

Dissection carries on towards the lower fibers of the serratus anterior and the lower insertions of the pectoralis maior and (Fig.8). As usual in breast surgery, the lower medial insertions of the pectoralis muscle are scored. The submuscular undermining reaches the visible submammary line (Fig.9).

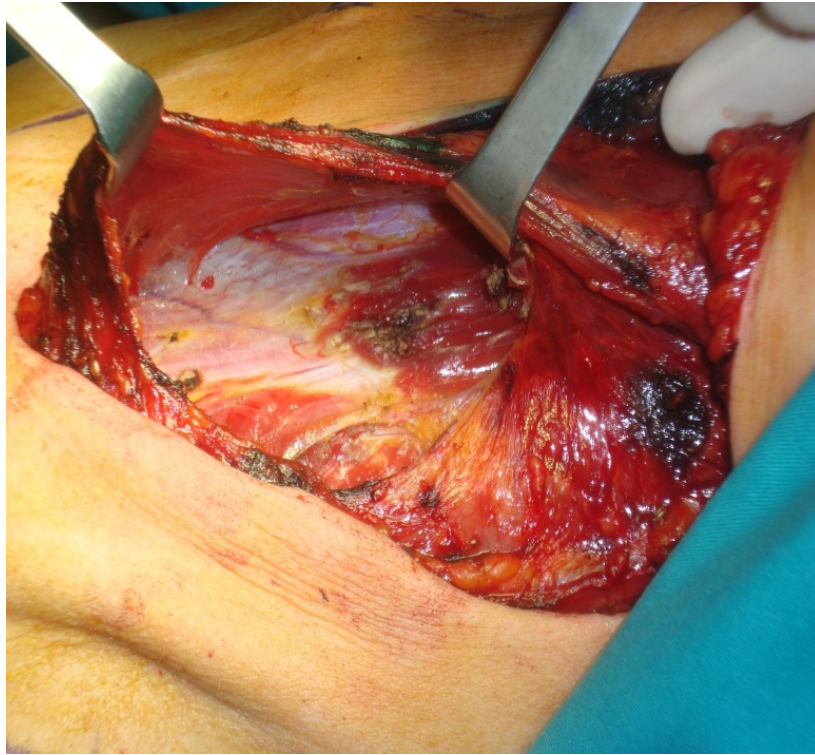


Figure 7. The submuscular dissection in the midpart of the implant coverage

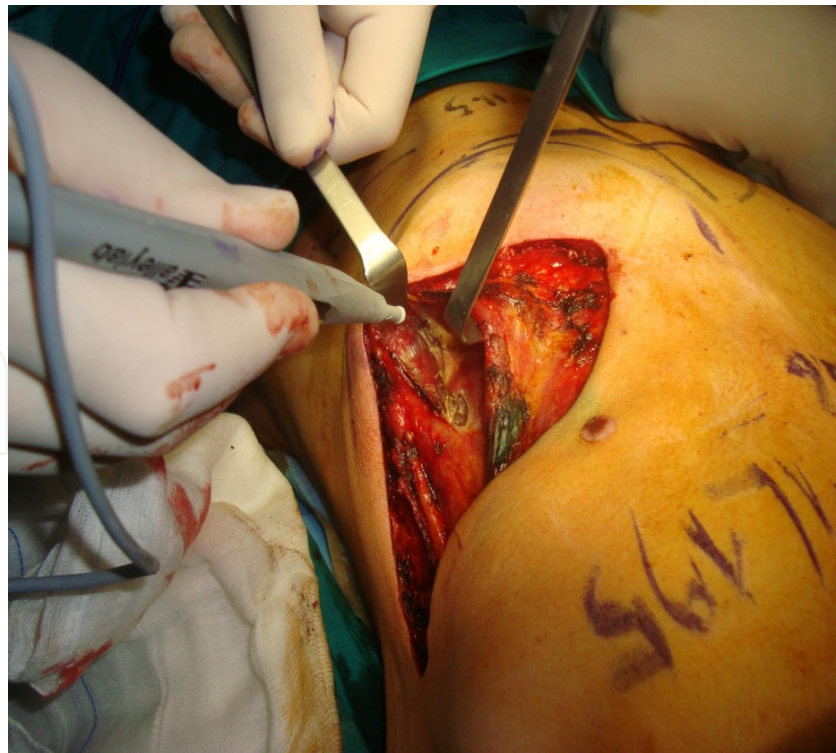

Figure 8. Scoring fibers and insertions of the muscles towards the inframammary zone

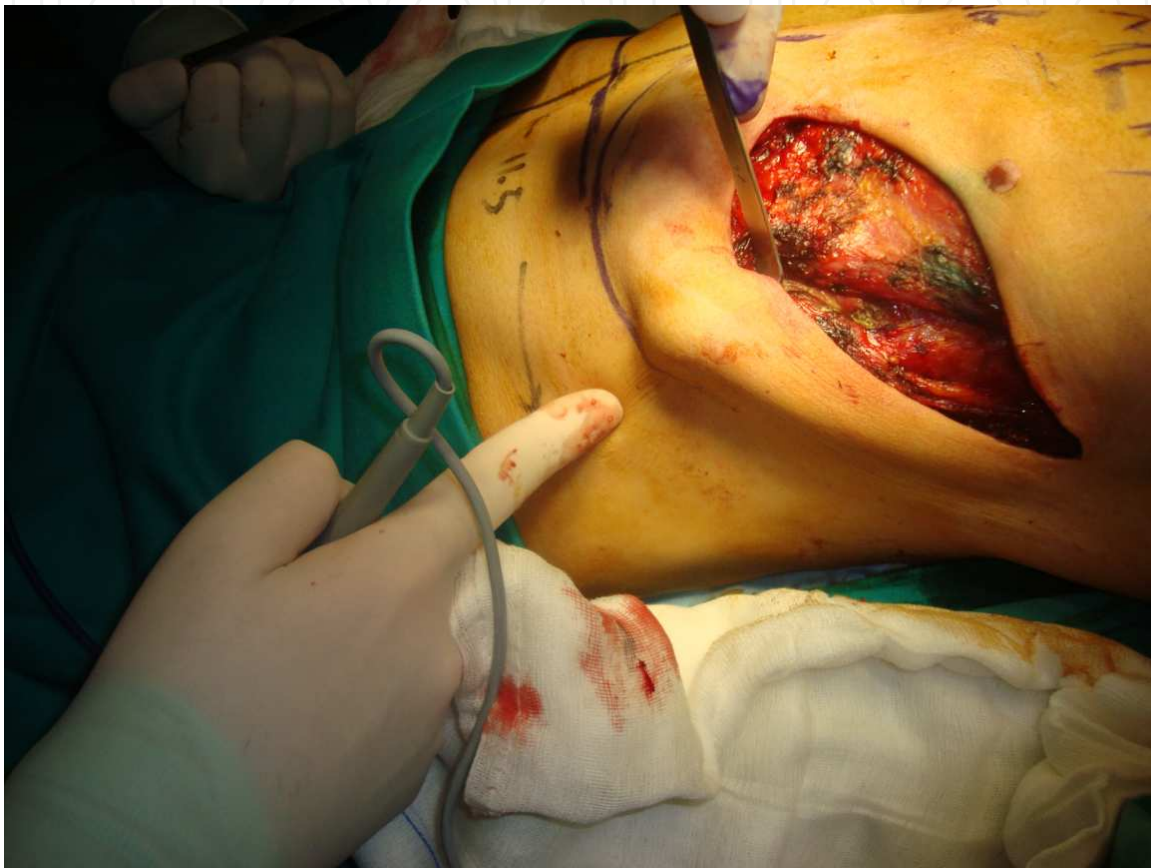


Figure 9. The submuscular pocket ends into the inframammary fold, any downward over-dissection should be avoided.

In a two-stage reconstruction with tissue expander, the submuscular pocket is complete when partial or total release of the deep fascia is performed at the same inframammary line, also called pectoralis fascia or muscular fascia, overlaying the muscles (Fig.10, 11). The superficial fascia must be preserved because it will expand progressively and physiologically. Also the deep fascia, if thin, can expand as well. On the other hand, in case of ADM-based IBR, the deep fascia is totally dissected just above the inframammary level and then the lower edge of the biomatrix is sutured along the inframammary fold.

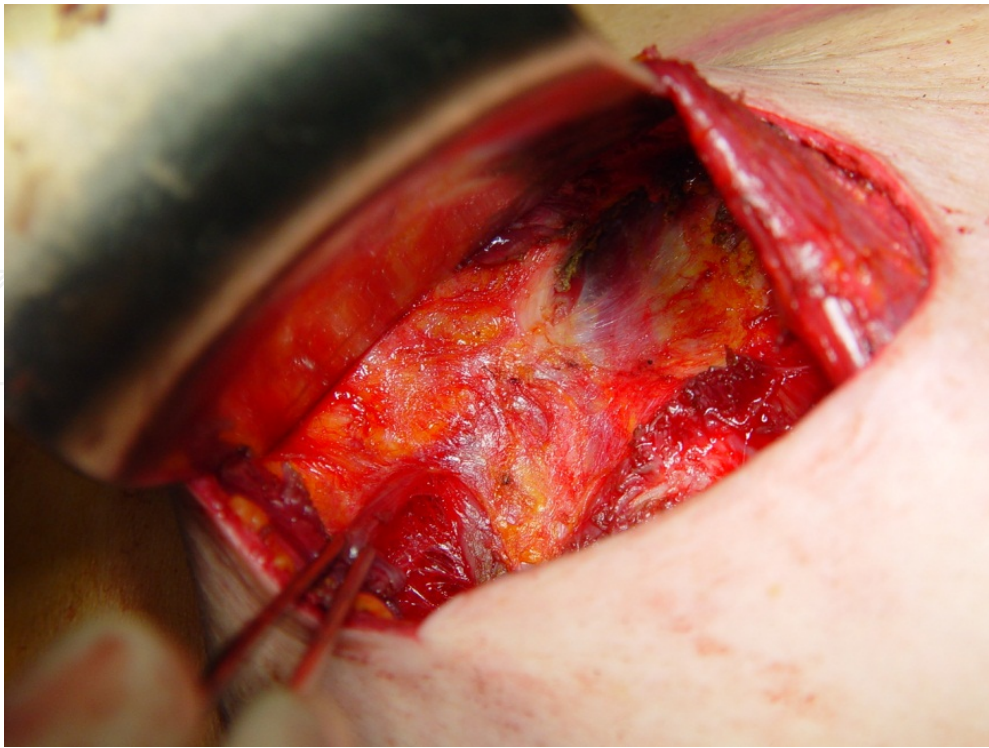


Figure 10. The deep fascia along the inframammary fold observed behind the section of the muscle fibers

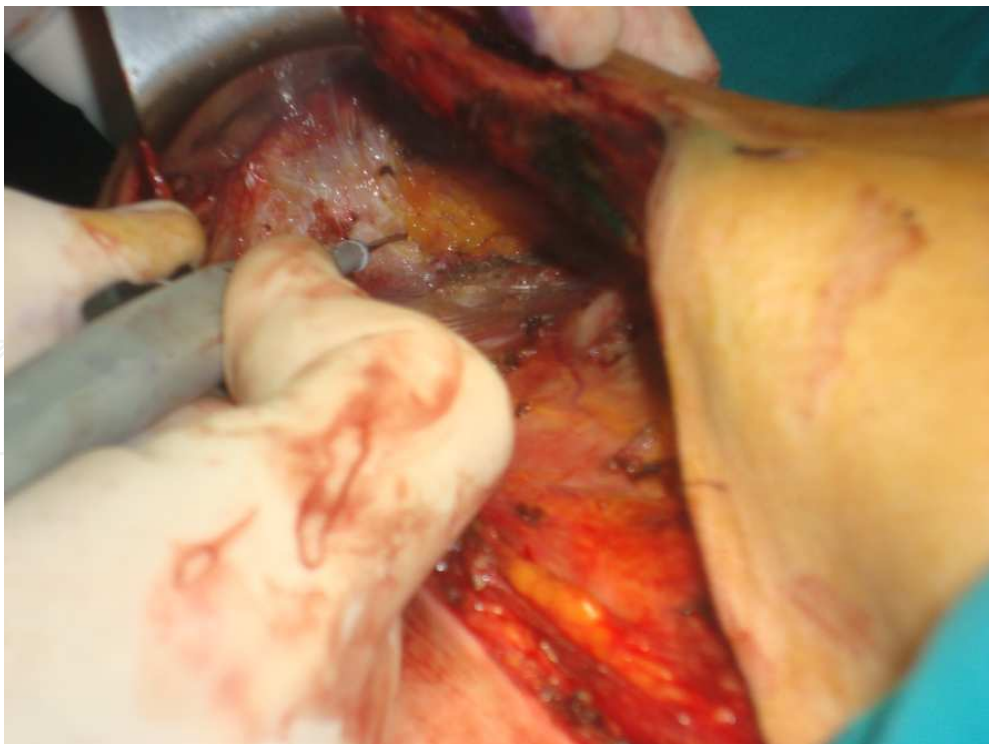


Figure 11. Total release of the deep fascia and deep retinacula cutis along the inframammary fold

4.2. Subcutaneous/subfascial preparation of the pocket: Part II – The dual-plane reconstruction

Summarizing the first part, the submuscular pocket results:

- partially scored medially, close to the sternal border, from the 4th rib down to the inframammary level;
- completely scored, including the whole musculo-fascial plane, along all the inframammary fold under the pectoralis maior and serratus anterior as far as the most lateral portion of the submuscular pocket. The final maneuver gives access to the deep adipose layer infero-laterally where fat is generally thicker.

Dissection allows to achieve a vertical enlargement of the lower pocket about 2-3 cm, seldom wider after scoring the deep retinacula cutis. This is that for more than a decade the Authors have been used to perform in the one-stage IBR with permanent implants, even some series of patients were recently published by other authors. [35] Expandable devices, Becker's or other types, were never used in these patients. Devices were tear-drop shaped and pre-filled with silicone gel highly cohesive. The patients were few compared with the patients with 2-stage reconstruction. Breast size was small to medium and weight lower than 300 grams. Because the possible results were not so satisfactory and the demand for sparing mastectomy was growing up, since 2008 the possibilities of transposing the former knowledge upon the inframammary reconstruction (Nava et al., 1998) were taken into account, in order to define the details of a proper technique for IBR in over 130 cases (Riggio et al., 2012). [27, 31]

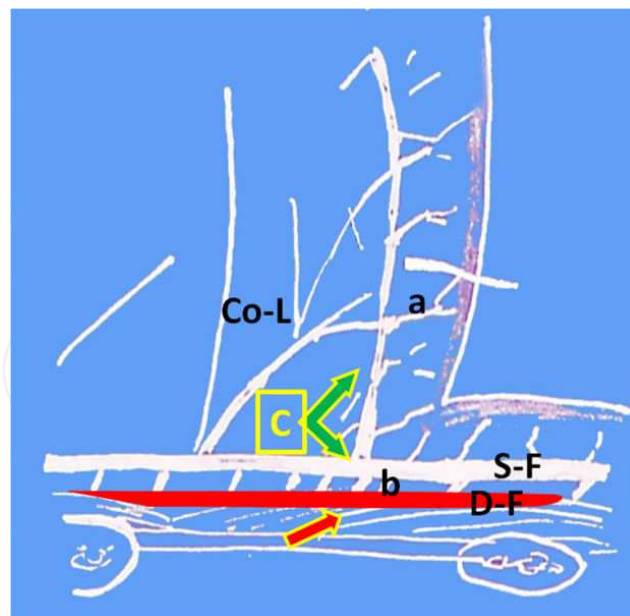


Figure 12. The surgical anatomy of the inframammary fascial system of connective tissue: a, superficial retinacula cutis; b, deep retinacula cutis; Co-L, Cooper's Ligaments; S-F, superficial fascia (horizontal white line); D-F, deep fascia overlying the muscles (horizontal red line); C, the levels of the electro-surgical scores in the dual-plane technique: green arrows into the superficial fascial plane and red arrow into the deep plane. It is possible to release the deep fascia a few millimeters beneath the fold, whereas the superficial fascia must be scored a few millimeters above.

The modified technique improves the enlargement of the lower breast substantially through the total release of the superficial fascia together with the superficial retinacula cutis above the whole inframammary line (Fig.12). It is fundamental that every surgeon may notionally understand, practically recognize, and surgically respect the fine anatomy of the submammary fold.

The multiple scores can obtain a better enlargement of the lower breast compared to the same manoeuvre performed in the second stage of reconstruction after expander because soft tissues can here contain some grade of fibrosis and the pre-existing connective frame be distorted. The scores must be performed behind the skin plane perpendicularly, avoiding any dermal bruising, and just above the corresponding external submammary line, a few millimeters, so as to avoid the bottoming-out of the pocket (Fig. 13, 14, 15, 16)

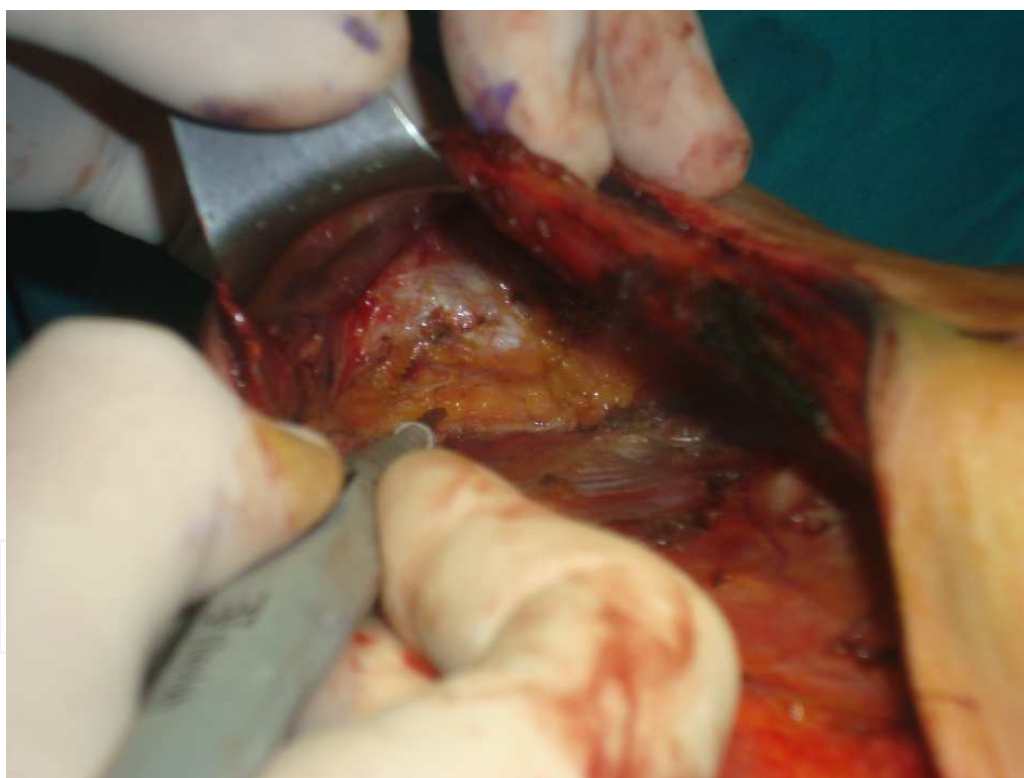


Figure 13. The vertical scoring of the superficial fascia through the previous deep fasciotomy and access to the deep subcutaneous layer, along the inframammary fold. The upper and lower free borders are part of the deep fascia already scored.

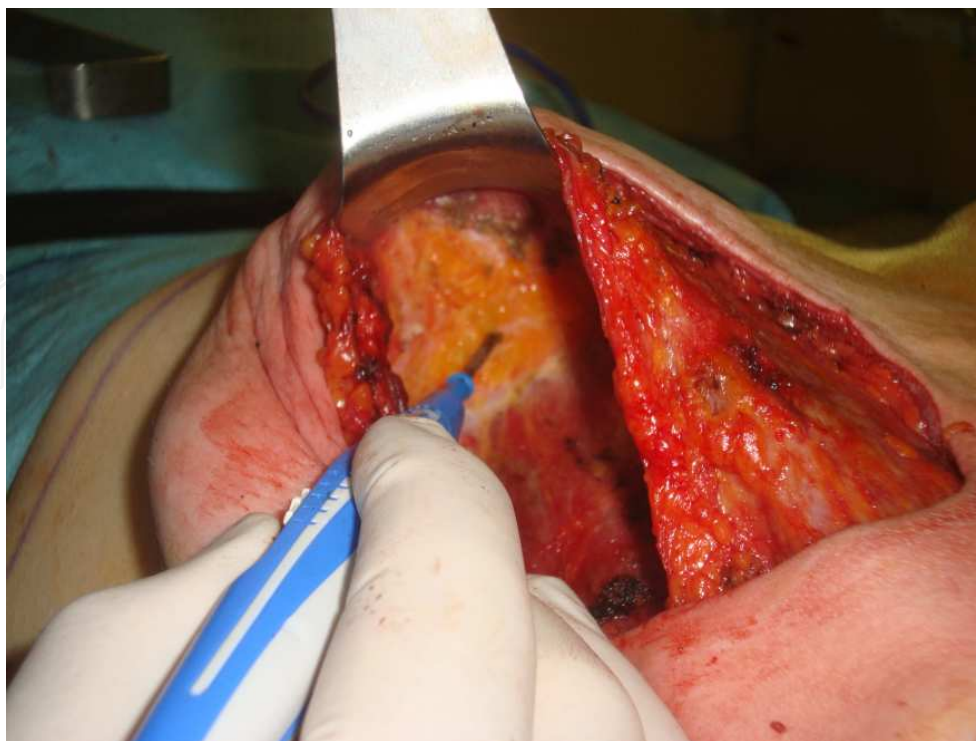


Figure 14. The tip of the electrical scalpel indicates where the superficial fascia layer is placed, above the inframammary fold, and the advancement of the pocket enlargement.

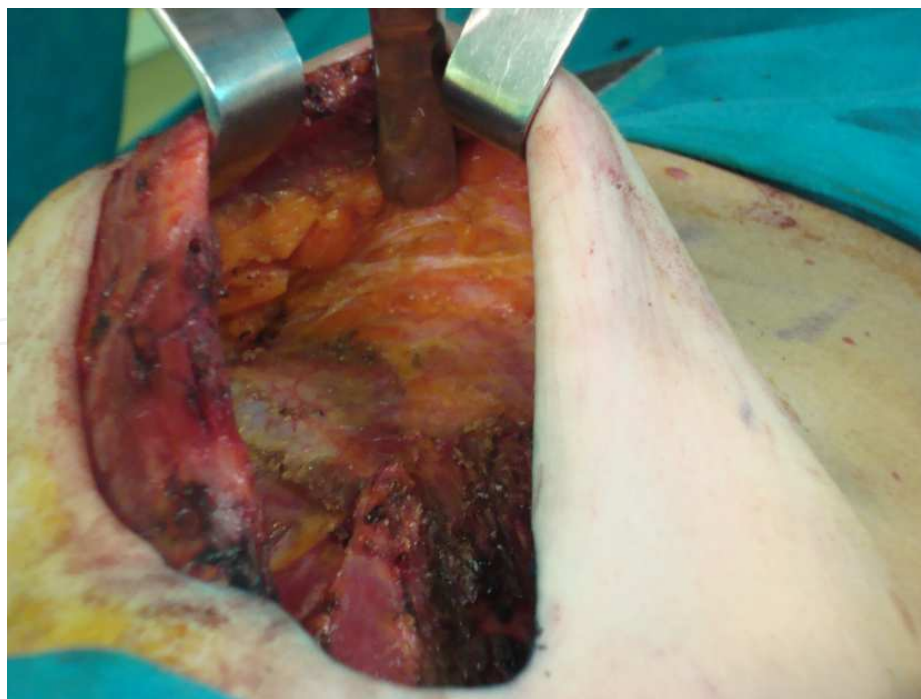


Figure 15. The submammary pocket after superficial fasciotomy, a few millimeters above the inframammary fold. The scored borders of the superficial fascia are visible below the middle retractor.

The dual-plane technique is able to add further 3-4 cm of height in the lower pocket, made of soft and vascularized tissue (Fig.16), totally integrated to the upper coverage made of muscular tissue (pectoralis maior and serratus anterior muscles). The total release of the connective inframammary frame can reach the 7 cms including the previous deep-fascial. It lets free skin and adipofascial layer spontaneously to reach the top of extensibility. This extension is to be compared with a rapid expansion. In the meantime, muscles are free to move upwards and so accomplishing the ultimate dual-plane construction of an implant coverage that is totally and continuously vascularized: the lower third of pliable soft tissue and the upper two thirds of firmer muscular tissue (Fig.17, 18).

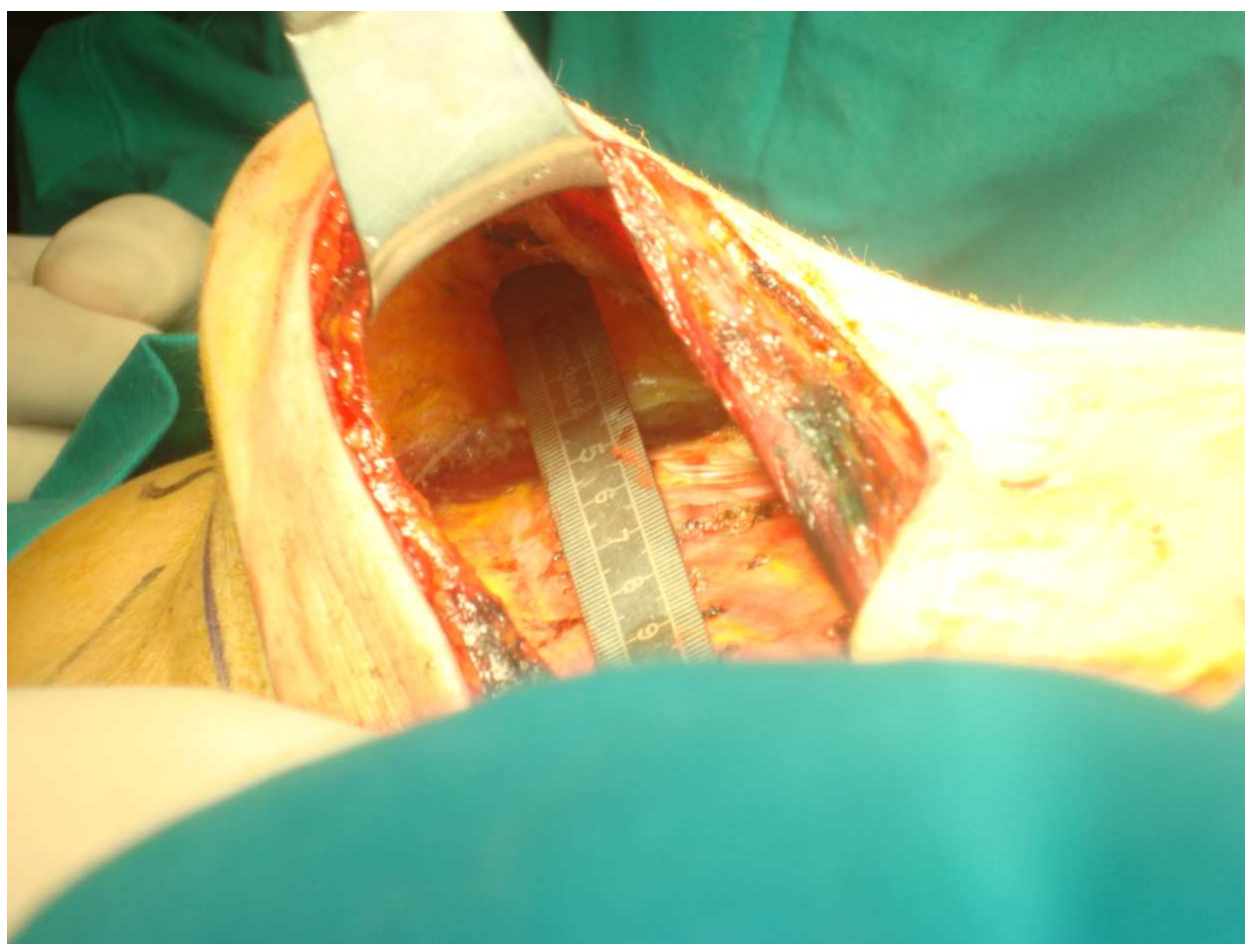


Figure 16. The autologous composite pocket is completing.

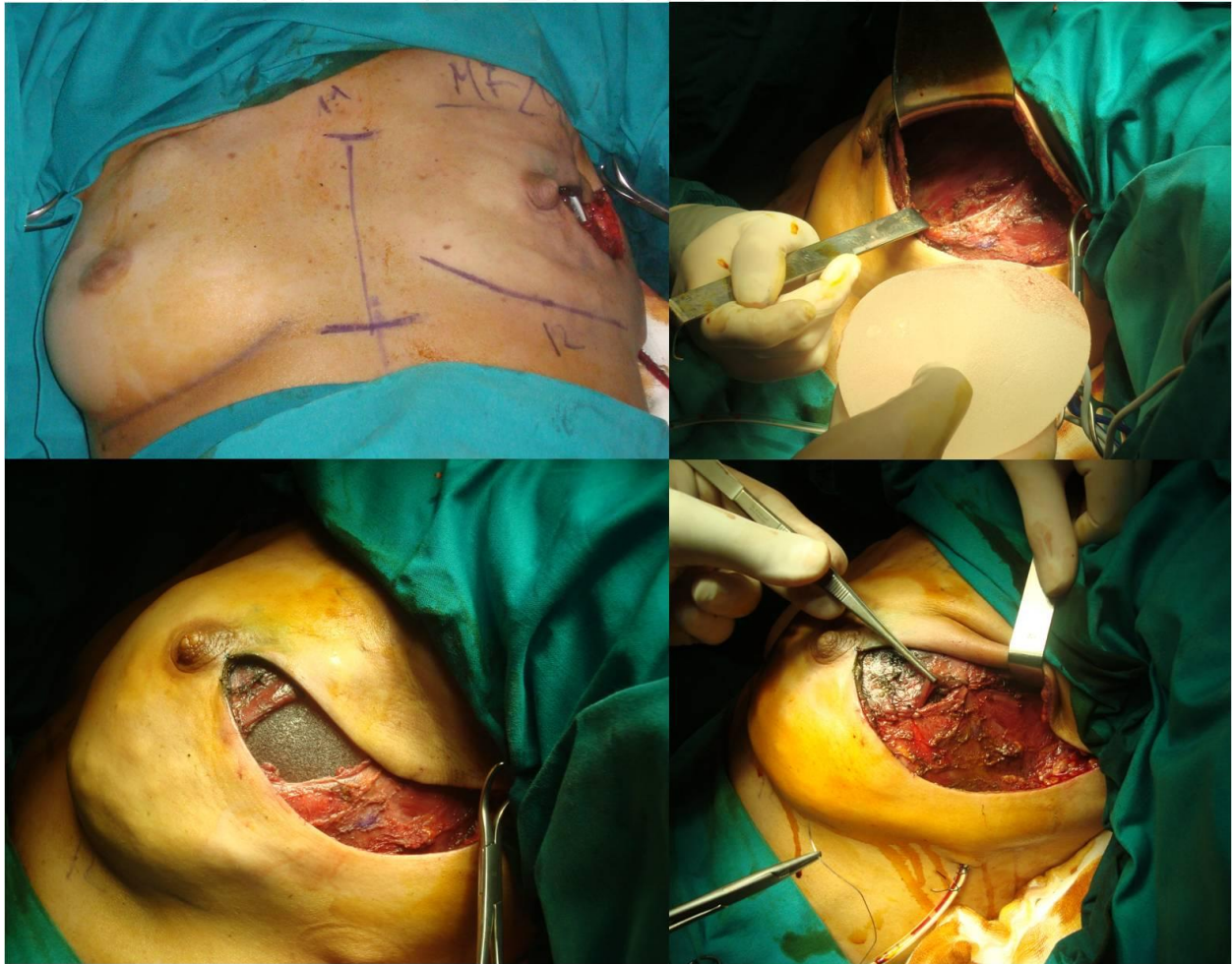
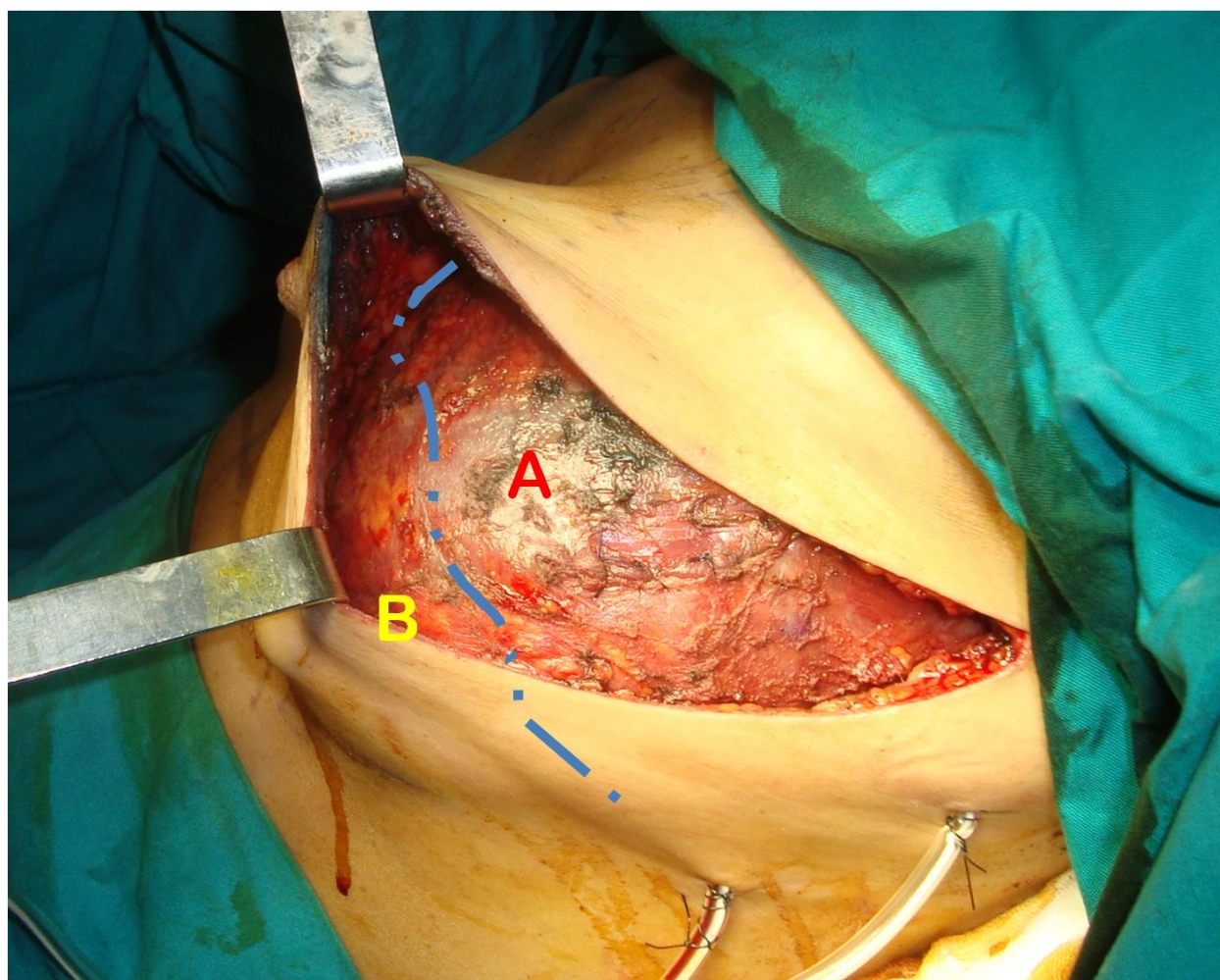


Figure 17. The insertion of the permanent anatomical implant behind the dual-plane coverage. This pocket is totally isolated by the subcutaneous pocket of the removed parenchyma. A drain is inserted under the implant and another between the axillary and subcutaneous compartments. The closure of the pocket is carried out between the free border of the pectoralis maior and the surgical edge of the serratus anterior, using several figure-to-eight stitches of vicryl 2.0.



IntechOpen

Figure 18. The composite coverage, skin-adipo-fascial tissue downwards and muscular upwards is nourished by a continuous vascular network, preventing complications related to reduced vascular supply and to biomatrix. The blue line illustrates the implant envelope divided in muscular (A) and subcutaneous-subfascial coverage (B).

Of course, the breast shape will be given by the anatomical implant but only the high-cohesiveness of the silicone gel can maintain and hence stretch the pocket in the following weeks (Fig.19). A saline implant or expander does not retain any true form; even if totally inflated it will never be the same of a “gummy-bear” implant. The different bio-mechanical effect also helps in re-establishing the true projection of implant that initially appears to be constricted by the tension of the muscular coverage.

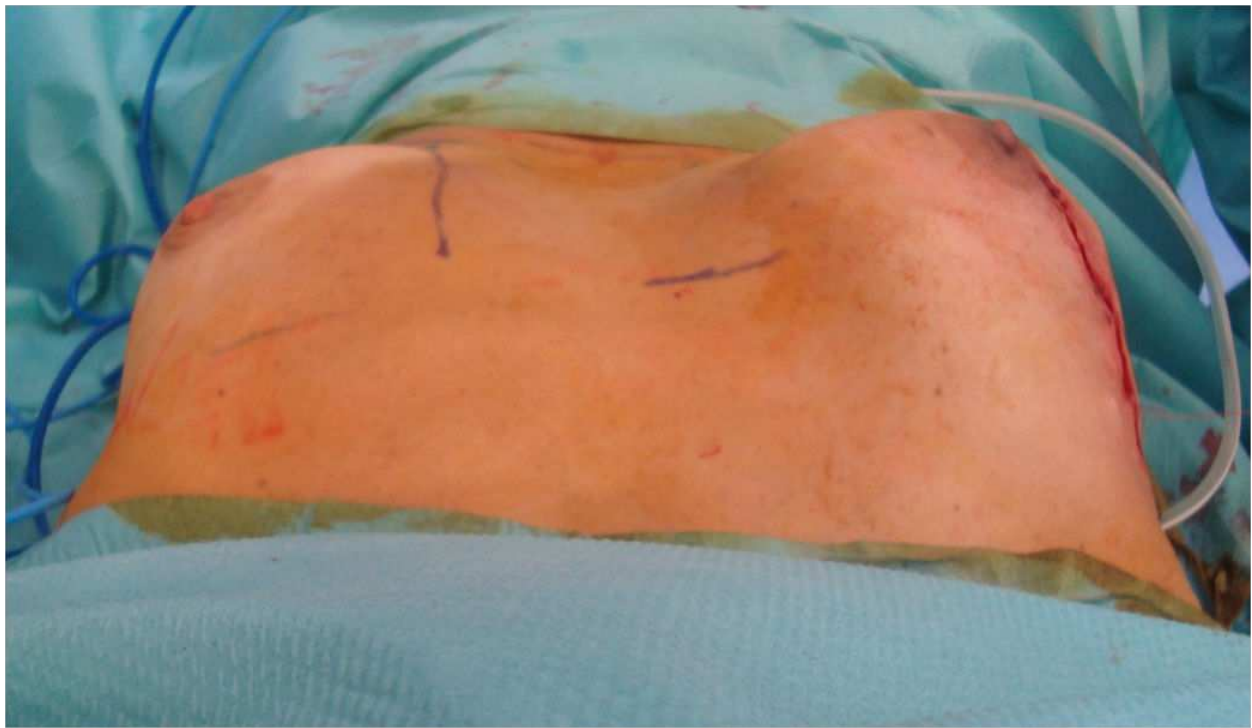


Figure 19. The one-stage immediate reconstruction of a nipple-sparing mastectomy using a permanent silicone implant (Natrell 410MX 370-grams by Allergan Inc.) in dual-plane autologous pocket. No ADM or synthetic mesh was used. High profile and fullness of this implant-based reconstruction are already visible after skin closure compared with the healthy breast. *Intra-operative bird's-eye view, patient in supine position.*

4.3. Tips and tricks

The fixation of the central inframammary fold. After scoring the superficial fascia above the inframammary fold, even if the symmetry was totally respected, the level inside appears to be bottomed out inside in some patient. It ought to be due to the abdominal superficial tension which pulls down the lower edge of the fascia already resected. The following procedure can solve the defect according to the former technique of inframammary redefinition already introduced by the same Author Nava. One or two stitches of absorbable material, usually vicryl 0, fix the lower edge of the superficial fascia already scored at the midpoint of the inframammary line into the residual deep fascia or deeper fibers of the serratus anterior or, if necessary, the intercostal fascia (Fig.20). Sometimes, when mastectomy is unilateral, the same procedure is performed for major definition of the central fold as to create a minimal folding to the inframammary line at the aim of a better symmetry with the contralateral breast or only to avoid even minimal descent of the implant.

The external partial myotomies. This is a technical detail introduced by the first Author Riggio, and specifically used in the new one-stage dual-plane IBR for those cases where the central strain strength of the pectoralis maior muscle is higher than usual. The muscle scoring must be carried out after the closure of the device pocket and after estimating the grade of compression produced by the muscle force against the implant. By this way two effects come out: 1) reducing the tension along the suture line of the device pocket, 2) decompressing the

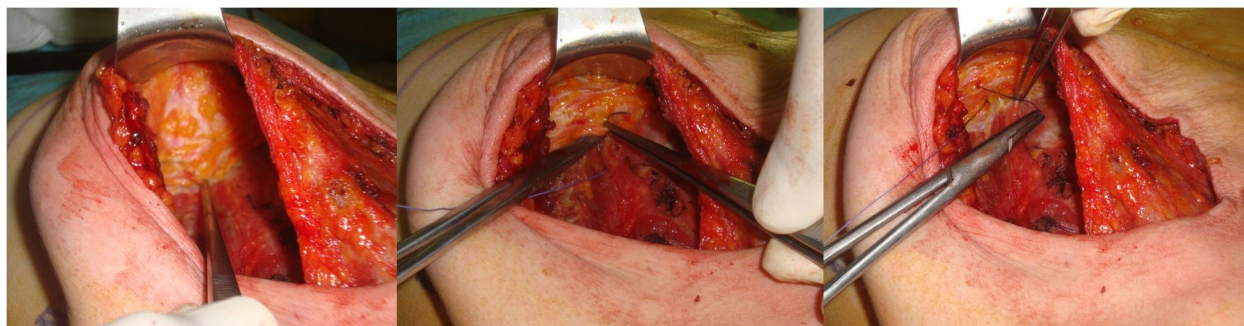


Figure 20. The lower edge of the superficial fascia is identified corresponding to the central point of the inframammary line and then pinched and fixed to the muscular fascia using a single stitch of vicryl 0, after Nava et al..

lower pole of the high-cohesive implant and improving the immediate profile of the lower breast. The correct placement, length, and direction of the partial sections are illustrated in the following Fig.21 and 22. The scores includes fascia and superficial fibers of the pectoralis maior muscle, close to the central part of the coverage.

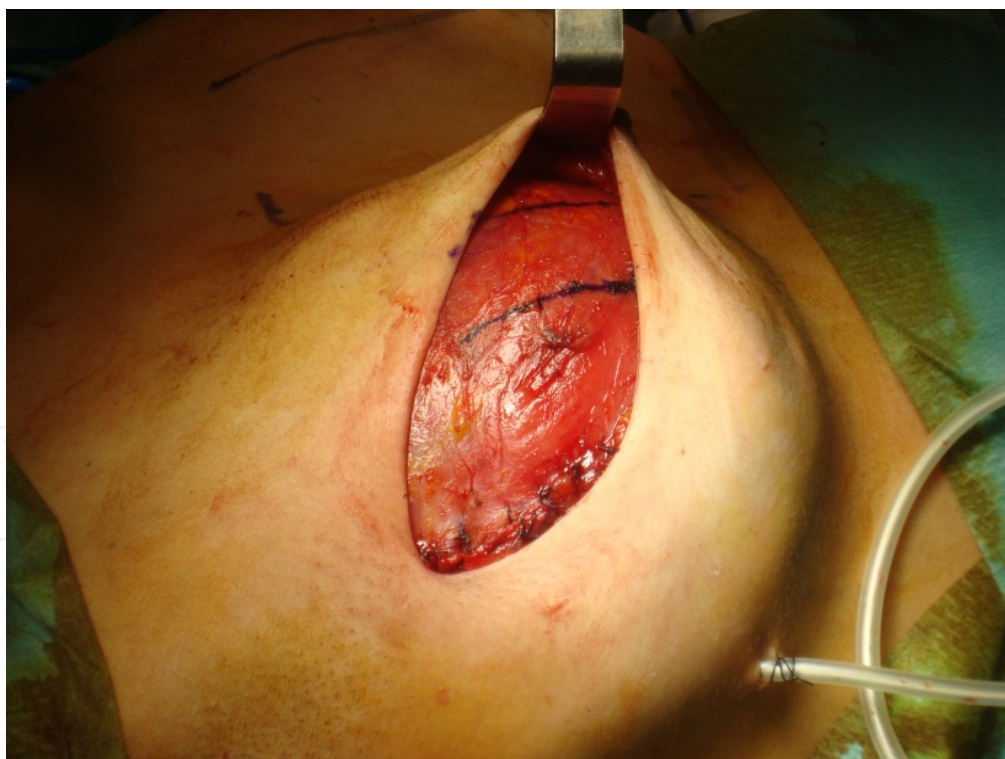


Figure 21. One or two lines of incision are drawn with blue 4 cm far from the suture of the pocket, in this figure visible near the lateral skin border. They are parallel to the suture line but usually crossing the oblique orientation of the muscle fibers.

The internal lateral myotomies. Similar incisions (one-two scores) can be carried out along the inner surface of the harvested serratus anterior muscle, that means inside the pocket laterally, before the implant insertion. The scoring must be vertical and is useful to release and lengthen the inferior-lateral pocket much better. They can be partial or total depending on the stiffness more than the thickness of the serratus fibers.

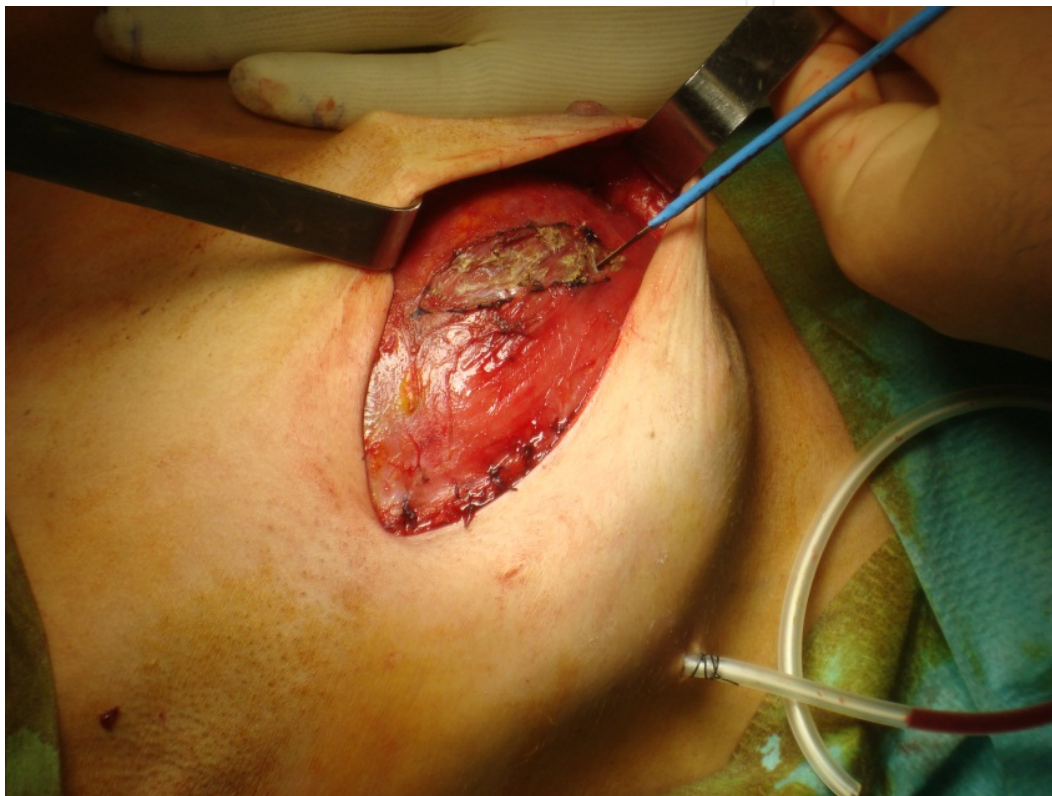


Figure 22. Scoring the fascia and the most superficial fibers of the mid-lower portion of the pectoralis maior muscle corresponding to the central part of the dual-plane pocket. This fine procedure was named by Riggio as external partial myotomy for the tension discharge.

5. Conclusions

The dual-plane technique can be indicated for a selected group of patients, the others follow different guidelines for reconstruction (Fig.23, 24).

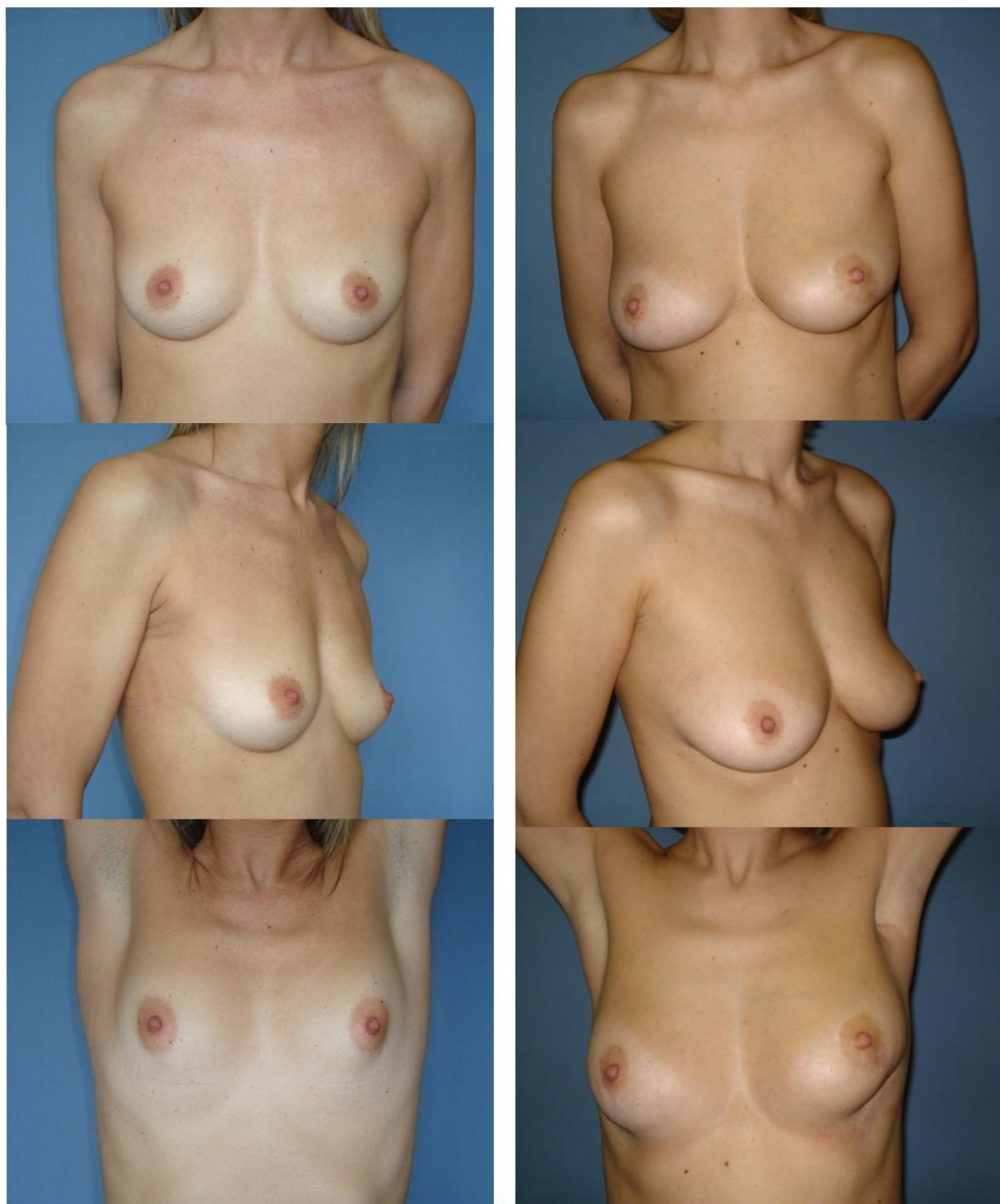

Figure 23. Here are the cases of two sisters affected by BRCA2, 35-year-old and 37-year-old respectively, with similar breast but different cancer history, pre-op views. The first underwent bilateral risk-reducing without sparing the nipple bilaterally, no prior cancer (*left column*). In the meantime, also the second sister underwent risk-reducing mastectomy but the prior conservative cancer treatment (quadrantectomy + radiation therapy + chemotherapy) changed the reconstructive perspectives in the left breast (*right column*).

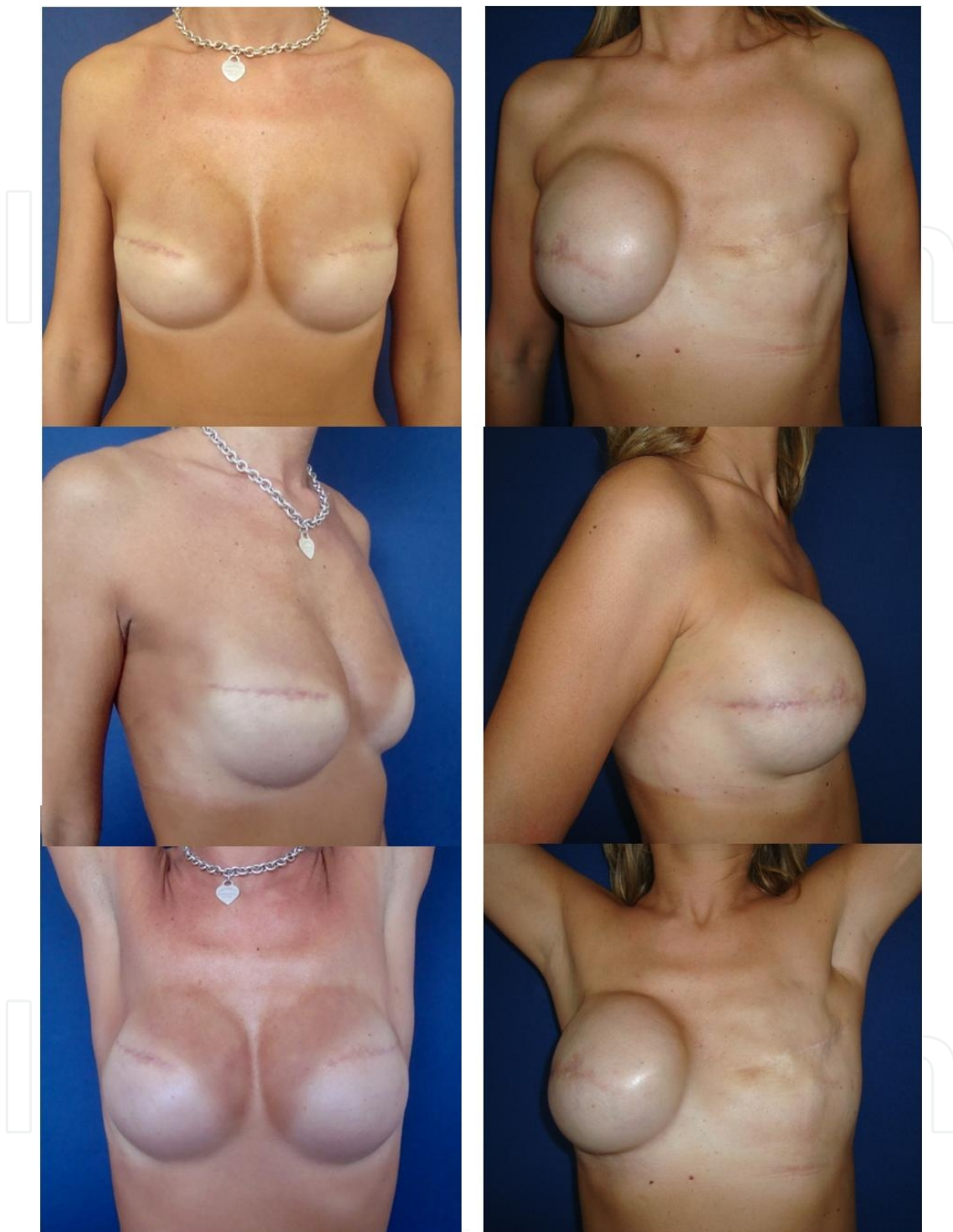

Figure 24. The same two patients, post-op views. The first sister received one-stage IBR with full-height/full-projection implants, Allergan Natrelle 410FF 375g, result after five months (*left column*). The second received IBR with expander insertion on the right whilst the left reconstruction was posposed because of previous radiotherapy and the refusal for DIEP flap (*right column*); she preferred to be treated with serial lipofilling and then expander. Pocket preparation and following outcome are different if used the dual-plane composite pocket for stable implant instead of a standard sub-muscular pocket for saline expander. Expander in the right breast inflated about 400cc, after the first lipofilling in the left side, nine months after mastectomy.

The presence of the following features bring together to perform a safe IBR with the technique described in the chapter: a) low to medium size; b) absent to poor ptosis; c) intra-operative careful respect for the deep fascia along the lateral borders of pectoralis major and serratus anterior muscles; d) intra-operative preservation of the submammary fascial system. Both risk-reducing and oncological sparing mastectomies can be equally reconstructed with the technique. Nipple-sparing and/or bilateral mastectomies can achieve better results (Fig.25). As well the unilateral mastectomy combined to contralateral augmentation. More than the 30% of IBR involves either immediate (Fig.26) or delayed augmentation of the healthy breast (Fig.27).

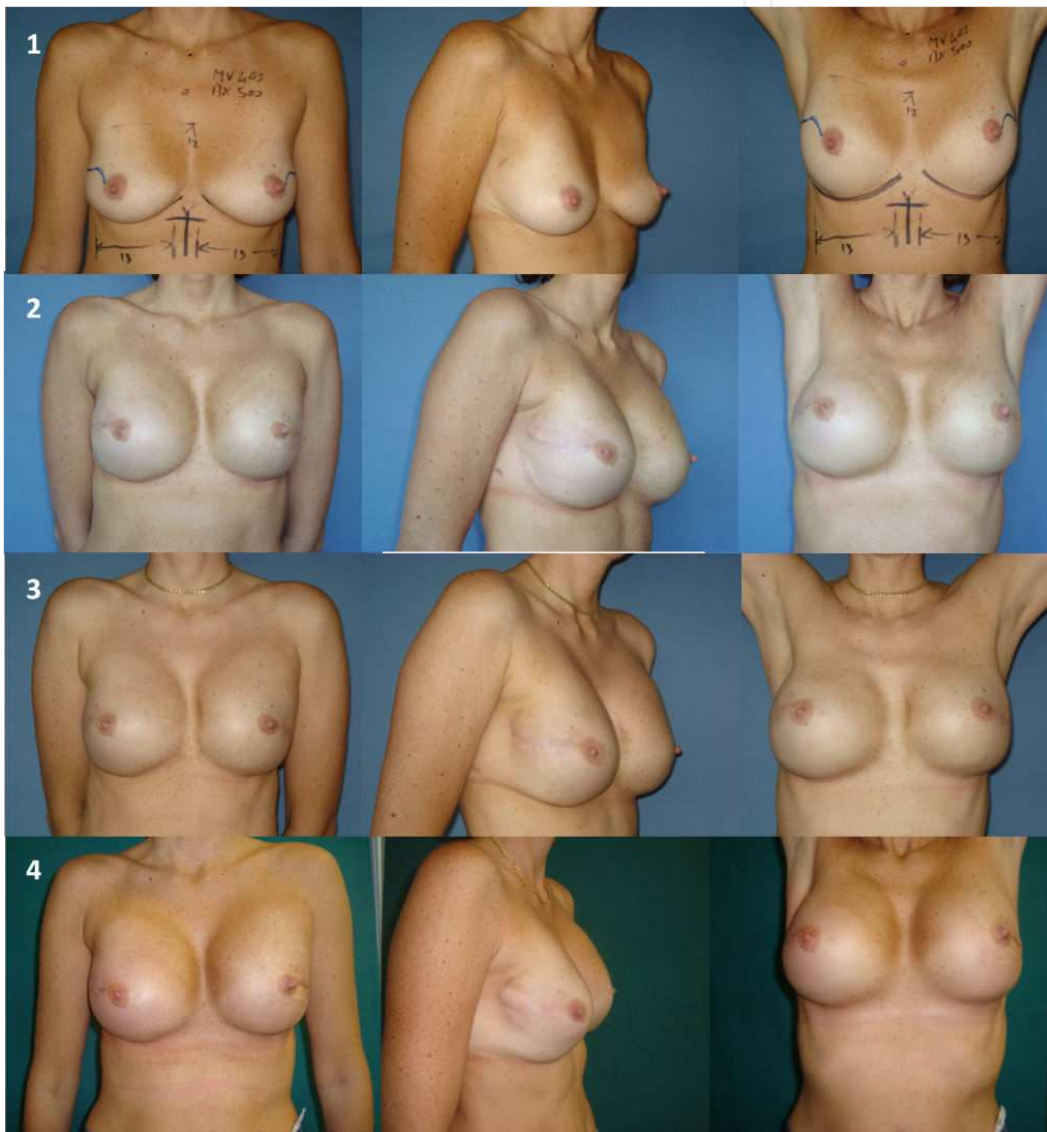

Figure 25. A 38-year-old patient with small breast, no ptosis, affected by right breast cancer in BRCA1. Right nipple-sparing total mastectomy + left risk-reducing bilateral mastectomy and one-stage IBR with Allergan Natrelle implants 410FX 495g. The breast was largely augmented. Preop (*line 1*), post-op views after 3.5 months (*line 2*), post-op views after 8 months (*line 3*), post-op views after 3 years and 9 months (*line 4*). The Baker's grade of capsular contracture was consistently 2 in both sides.

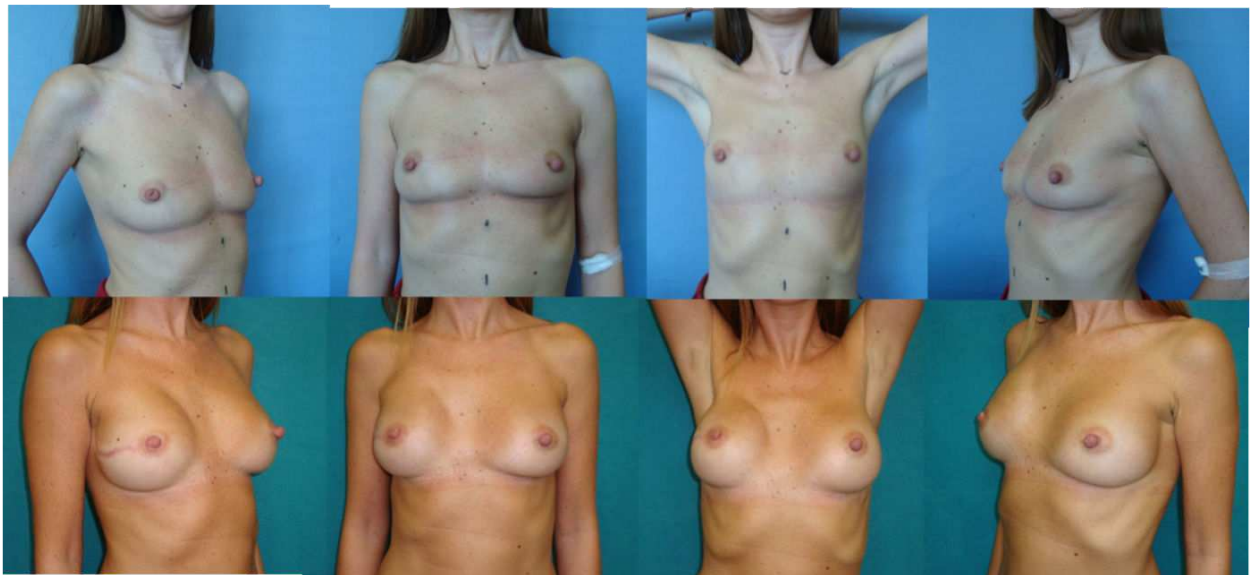

Figure 26. A 37-year-old patient with right breast cancer. Nipple-sparing mastectomy and one-stage IBR with Allergan Natrelle 410MX 290g + breast submuscular augmentation with 410MF 195g. Pre-op and post-op views after 7 months.

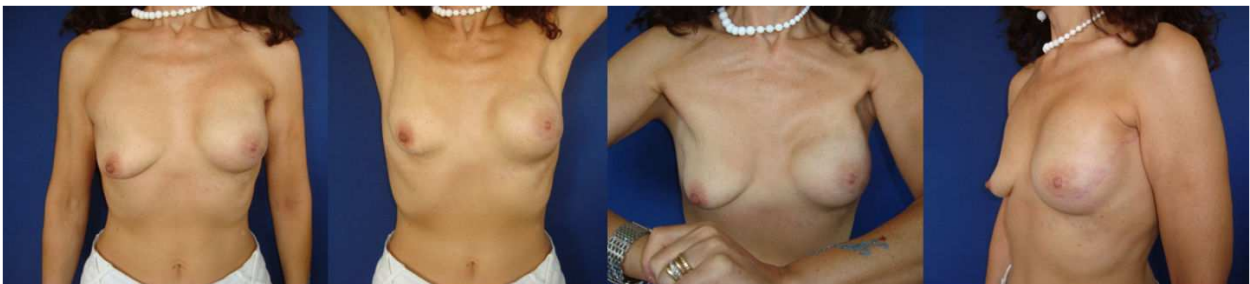

Figure 27. A 49-year-old patient with left breast cancer. Nipple-sparing mastectomy and one-stage IBR with Allergan Natrelle full-height/full projection 410FX 315g. The contralateral augmentation was postponed because contemporary correction of the healthy breast in presence of both moderate ptosis and lower constricted pole was evaluated to have few chances of achieving symmetrization safely in a single stage.

Although some surgeon disagrees, no tension spreads on the skin cover using the dual-plane technique. Fast reaching of the definite volume and related major pressure of the device top do not represent a distinct risk for skin necrosis. The technique was safely used in moderate smokers. This is possible because the device volume discharges pressure along the muscular cover at the first moment and, only after some weeks, the muscle is stretching. However skin cover is never tightened by the cohesive implant because skin surface after mastectomy is generally loose and larger than the parenchyma volume, especially in the lower half. Therefore the mammary skin could envelop a bigger prosthesis with poor tension. The largest implant was of 580g. Immediate increase of the previous breast size carry advantages as the overfilling of the breast boundaries, reduction of skin folding, and minor areola-nipple displacement because better stabilizes its position. The volume correction of minor differences were

deliberately postponed after complete healing, i.e. at least six months later, and concerned 10% as minimal. The choice for a delayed operation of the healthy breast was prudently dictated by the most predictable evaluation of breast symmetry and shape. This became mandatory if the contralateral breast had need for some mastopexy with augmentation or alone.

Author details

Egidio Riggio* and Maurizio B. Nava

Plastic Reconstructive Surgery Unit, Fondazione IRCCS Istituto Nazionale dei Tumori, Milano, Italy

References

- [1] Toth, B. A, & Lappert, P. Modified skin incisions for mastectomy: the need for plastic surgical input in preoperative planning. *Plast Reconstr Surg* (1991). , 87, 1048-53.
- [2] Wellisch, DK, & Schain, . , Little JWIII. The psychological contribution of nipple addition in breast reconstruction. *Plast Reconstr Surg* 1987;80:699-704.
- [3] Nava, M. B, Cortinovis, U, Ottolenghi, J, Riggio, E, Pennati, A, Catanuto, G, Greco, M, & Rovere, G. Q. Skin-reducing mastectomy. *Plast Reconstr Surg* (2006). discussion 611-13., 118(3), 603-10.
- [4] Rusby, J. E, Smith, B. L, & Gui, G. P. Nipple-sparing mastectomy. *Br J Surg* (2010). , 97(3), 305-16.
- [5] Metcalfe, K. A, Semple, J. L, & Narod, S. A. Time to reconsider subcutaneous mastectomy for breast-cancer prevention? *Lancet Oncol* (2005). , 6, 431-34.
- [6] Garcia-etienne, C. A, & Borgen, P. I. Update on the indications for nipple-sparing mastectomy. *J Support Oncol* (2006). , 4, 225-330.
- [7] Ashikari, R. H, Ashikari, A. Y, Kelemen, P. R, & Salzberg, C. A. Subcutaneous mastectomy and immediate reconstruction for prevention of breast cancer for high-risk patients. *Breast Cancer* (2008). , 15, 185-91.
- [8] Laronga, C, Kemp, B, Johnston, D, Robb, G. L, & Singletary, S. E. The incidence of occult nipple-areola complex involvement in breast cancer patients receiving a skin-sparing mastectomy. *Ann Surg Oncol* (1999). , 6, 609-613.
- [9] Sacchini, V, Pinotti, J. A, Barros, A. C, Luini, A, Pluchinotta, A, Pinotti, M, et al. Nipple-sparing mastectomy for breast cancer and risk reduction: oncologic or technical problem? *J Am Coll Surg* (2006). , 203, 704-714.

- [10] Crowe, J. P, Patrick, R. J, Yetman, R. J, & Djohan, R. Nipple-sparing mastectomy update: one hundred forty-nine procedures and clinical outcomes. *Arch Surg* (2008). , 143, 1106-10.
- [11] Gerber, B, Krause, A, Dieterich, M, Kundt, G, & Reimer, T. The oncological safety of skin sparing mastectomy with conservation of the nipple-areola complex and autologous reconstruction: an extended follow-up study. *Ann Surg* (2009). , 249, 461-468.
- [12] Kroll, S. S, & Baldwin, B. A comparison of outcomes using three different methods of breast reconstruction. *Plast Reconstr Surg* (1992). , 90, 455-62.
- [13] William O'Brien Per-Olof Hasselgren, Robert P. Hummel, Robert Coith, David Hyams, Lawrence Kurtzman, Henry W. Neale. Comparison of postoperative wound complications and early cancer recurrence between patients undergoing mastectomy with or without immediate breast reconstruction. *The American Journal of Surgery*, July (1993). , 166(1), 1-5.
- [14] Spear, S. L, & Majidian, A. Immediate breast reconstruction in two stages using textured, integrated-valve tissue expanders and breast implants: A retrospective review of 171 consecutive breast reconstructions from 1989 to 1996. *Plast Reconstr Surg* (1998). , 101, 53-63.
- [15] Gui, G. P, Tan, S. M, Faliakou, E. C, Choy, C, Hern, A, & Ward, R. A. Immediate breast reconstruction using bidimensional anatomical permanent expander implants: a prospective analysis of outcome and patient satisfaction. *Plast Reconstr Surg* (2003). , 111(1), 125-38.
- [16] Ho, G, Nguyen, T. J, Shahabi, A, Hwang, B. H, Chan, L. S, & Wong, A. K. A systemic review and meta-analysis of complications associated with acellular dermal matrix-assisted breast reconstruction. *Ann Plast Surg*. (2012). , 68, 345-56.
- [17] Cassileth, L, Kohanzadeh, S, & Amersi, F. One-Stage immediate breast reconstruction with implants: A new option for immediate reconstruction. *Ann Plast Surg*. (2011). Jul 5 [Epub ahead of print].
- [18] Spillane, C. A, Ashikari, A. Y, Koch, R. M, & Chabner-thompson, E. An 8-Year experience of direct-to-Implant Immediate Breast reconstruction using Human acellular dermal matrix (Alloderm). *Breast*. (2010). , 127, 514-23.
- [19] Singh, N, Reaven, N. J, & Funk, S. E. Immediate 1-stage vs. tissue expander postmastectomy implant breast reconstructions: A retrospective real-world comparison over 18 months. *J Plast Reconstr Aesthet Surg*. (2012). , 65, 917-23.
- [20] Connor, J, et al. Retention of structural and biochemical integrity in a biologic mesh supports tissue remodeling in a primate abdominal wall model. *Regen Med*. (2009). , 4(2), 185-95.
- [21] Hoganson, D. M, Owens, G. E, Doherty, O, Bowley, E. M, Goldman, C. M, Harilal, S. M, Neville, D. O, Kronengold, C. M, & Vacanti, R. T. JP. Preserved extracellular ma-

- trix components and retained biological activity in decellularized porcine mesothelium. *Biomaterials*. (2010). Sep; 31(27), 6934-40.
- [22] Products TiLOOP® Bra: http://www.pfmmedical.com/en/productcatalogue/pfm-medical/mesh_implants_breast_surgery/tiloopR_bra/index.html
- [23] Riggio, E. and Valentina Visintini Cividin V. Breast Reconstruction Approach to Conservative Surgery. ((2012). in *Breast Reconstruction- Current Techniques*, Marzia Salgarello (Ed.), 978-9-53307-982-0 InTech, 243-278.
- [24] Pomahac, B, Recht, A, May, J. W, Hergrueter, C. A, & Slavin, S. A. New trends in breast cancer management: is the era of immediate breast reconstruction changing? *Ann Surg*. (2006). Aug; 244(2), 282-8.
- [25] Rozen, W. M, Ashton, M. W, & Taylor, G. I. Defining the role for autologous breast reconstruction After mastectomy: social and oncologic implications. *Clinical Breast Cancer*, (2008). , 8(2)
- [26] Maxwell, G. P, Storm-dickerson, T, Whitworth, P, Rubano, C, & Gabriel, A. Advances in nipple-sparing mastectomy: oncological safety and incision selection. *Aesth Surg J* (2011). , 31(3), 310-9.
- [27] Riggio, E, Ottolenghi, J, & Nava, M. Breast operative technique for single-stage reconstruction after conservative skin sparing mastectomies: a preliminary study. *Surg Tech Development*. (2012). , 2, 4-9.
- [28] Garwood, E. R, Moore, D, Ewing, C, Hwang, E. S, Alvarado, M, Foster, R. D, & Esserman, L. J. Total skin-sparing mastectomy: complications and local recurrence rates in 2 cohorts of patients. *Ann Surg* (2009). , 249(1), 26-32.
- [29] Riggio, E, Quattrone, P, & Nava, M. Anatomical study of the breast superficial fascial system: the inframammary fold unit. *Eur J Plast Surg* (2000). , 23, 310-315.
- [30] Lockwood, T. E. Superficial fascial system (SFS) of the trunk and extremities: a new concept. *Plast Reconstr Surg* (1991). , 87, 1009-1018.
- [31] Nava, M, Quattrone, P, & Riggio, E. Focus on the breast fascial system: a new approach for inframammary fold reconstruction. *Plast Reconstr Surg* (1998). , 102, 1034-1045.
- [32] Vallejo da Silva A, Rodriguez FR, Loures CM, Gloria Silami Lopes V. Mastectomy in the era of implant-based reconstruction: Should we be removing the pectoralis fascia? *Breast*. (2012). Jul 22. [Epub ahead of print]
- [33] Gefen, A, & Dilmoney, B. Mechanics of the normal woman's breast. *Technol Health Care* ((2007)). , 15 (4), 259-71
- [34] Riggio, E. Breast Augmentation with Extra-projected and High-Cohesive Dual-Gel Prosthesis 510: A Prospective Study of 75 Consecutive Cases for a New Method (the Zenith System). *Aesthetic Plast Surg* (2012). , 36(4), 866-78.

- [35] Salgarello, M, & Farallo, E. Immediate breast reconstruction with definitive anatomical implants after skin-sparing mastectomy. *Br J Plast Surg* (2005). , 58(2), 216-22.

IntechOpen

IntechOpen

