

We are IntechOpen, the world's leading publisher of Open Access books Built by scientists, for scientists

4,800

Open access books available

122,000

International authors and editors

135M

Downloads

Our authors are among the

154

Countries delivered to

TOP 1%

most cited scientists

12.2%

Contributors from top 500 universities



WEB OF SCIENCE™

Selection of our books indexed in the Book Citation Index
in Web of Science™ Core Collection (BKCI)

Interested in publishing with us?
Contact book.department@intechopen.com

Numbers displayed above are based on latest data collected.

For more information visit www.intechopen.com



Glioblastomas, Astrocytomas: Survival Amelioration Adding Hyperthermia to Conformal Radiotherapy and Temozolomide – Use of Pegylated Doxorubicin and Hyperthermia in the Treatment of a Recurrent Case

Gianfranco Baronzio, Gurdev Parmar,
Michela De Santis and Alberto Gramaglia

Additional information is available at the end of the chapter

<http://dx.doi.org/10.5772/55966>

1. Introduction

Fifty per cent of primary brain tumours are Glioblastoma (GBM), the rest is constituted by astrocytomas and less aggressive tumours [1,2]. GBM is biologically an aggressive tumor quickly developing genetic heterogeneity and therapeutic resistance [2,3]. No specific markers exist for GBM at the moment as reported by Kesari [4], but new imaging techniques including diffusion weighted imaging (DWI), perfusion weighted imaging (PWI or MR), are aiding in better defining disease development and progression. According to the World Health Organization (WHO), astrocytomas are classified into four prognostic grades [4,5]. Grade I and two are classified as low grade gliomas whereas grade III and IV are classified as high grade gliomas, despite the fact that these grades indicate tumor aggressiveness they have not been reliable in predicting the response to therapy. Kesari has outlined that other factors such as overexpression of some growth factors and their receptors have prognostic relevance [4]. Overexpression of Platelet derived growth factor (PDGF) and its receptors indicates a tumor is less aggressive and has a better prognosis compared to GBM expressing the Epidermal Growth Factor (EGFR) [4,6].

Almost 45% of GBM have molecular alterations of the enzyme 06-methylguanine-DNA methyltransferase(MGMT) and mutations of isocitrate dehydrogenase 1 (IDH1) [7]. MGMT, affects signalling pathways and has an important role with alkylating cytostatic drugs such as Temozolomide (TMZ). Methylation of MGMT is associated to a better prognosis and response

to TMZ [8]. More recently, a specific and target therapy has been suggested by authors such as Reardon and Wen [3] who have provided a complete list of these inhibitors for this disease including: Gefitinib (Iressa®), Erlotinib (Tarceva®), Thalidomide (Thalidomid®), Bevacizumab (Avastin®), and proteasome inhibitors (bortezomid).

Another approach at the moment not completely in use is immunotherapy [9, 10]. EGFR is expressed in near the 50% of patients with GBM [11]. Inhibitors of EGFR, like Iressa and Tarceva have been used with limited success [12]. A phase II study with Gefitinib has been conducted by Rich et al. in which fifty-seven patients have been treated orally once daily with 500 mg of oral Iressa®. No objective responses were seen, possibly because only 21% of patients had measurable disease at treatment initiation. Iressa® was well tolerated and a dose increase was thus suggested [13]. Studies with Tarceva® has given similar results with a minimum benefit not superior to standard treatment of care with radiotherapy and TMZ [14]. Another modest response has been obtained inhibiting the PDGF receptors using imatinib (Gleevec®) [10, 16].

Lastly, as angiogenesis due tumor hypoxia is a common processes in GBM [17,18], the inhibitor of Vascular Endothelial Growth Factor (VEGF) bevacizumab (Avastin) has been studied extensively in treating resistant GBM [17, 19]. Avastin has recently been used as single agent or in combination with several drugs, such as carboplatin [20], Ectoposide [21], Lomustine and TMZ [17]. Avastin, is a recombinant monoclonal immunoglobulin able to inhibit VEGF and to normalize tumor vasculature [21,22], but, the promises on GBM have not been confirmed and 98.8% of patients experienced adverse effects such as fatigue, headache, hypertension, thromboembolism, cerebral haemorrhage, convulsion and infarction [22]. Another antiangiogenic factor Thalidomide has been used in GBL [23]. Thalidomide exert its anti tumoral activity through several mechanisms, such as: inhibition of angiogenesis, cytokine-mediated pathways and adhesion molecules modulation, inhibition of cyclooxygenase-2 and stimulation of immuno response [24]. Another approach is immunotherapy. As known GBL is an immunogenic tumor exerting an immunosuppressive effects on cell mediated immunity partially by regulatory T cells [25,26,27]. This kind of therapy is however experimental and dependent on laboratory skilled personal.

However, none of these association are really superior to TMZ + radiotherapy, regarding survival, and are also becoming cost - prohibitive [28]. Understanding this issue we have started to add hyperthermia (HT) to TMZ and Conformal Radiotherapy (CRT). The basis for adding HT together radiotherapy have been described since 2006 [29]. Hypoxia, the increased apoptosis induced by heat and the additive response to CRT are the most important reasons for adding HT in the treatment of GBM [29]. Animal and human studies have also indicated that there are significant chemosensitizing effects of adding HT to chemotherapy such as nitrosureas derivates [29, 30]. Previous studies not yet published by our group have shown that HT with TMZ is additive. We have thus be (TMZ) (5F,11 M median age 44.64 ± 9.95 yr), and were eligible to be compared with 15 patients with (GBM) treated with CFRT plus TMZ (see table 2)(15 GBM, 7F,8M; 52.13 ± 16.17 yr). Four of them (Astrocytoma IV) were previous treated with CCNU, with disease progression (see. Table. 1). All patients had a histological proven malignant GBM or anaplastic astrocytomas. Since 2001, we have begun to use capacitive HT in association to TMZ and conformal radiotherapy. Follow up of patients was collected

at a mean interval of 65 days, with a large range [40-90] days for those patients with a disease stabilization.

PTS	Year	Gender	Histology	TMZ	CCNU	ECOG	Gy	RTV	Ner HT Cycle	A/D	Survival Ms
1	36	F	GBM	X			45	65.6	2	D	25
2	52	M	GBM	X			42	101	1	D	12
3	54	F	GBM	X			60		1	A	75
4	57	M	GBM	X			14	42	3	A	51
5	51	M	GBM	X			20	57	2	A	20
6	45	F	GBM	X			65	43.4	1	A	20
7	70	M	GBM	X			28	28.4	5	A	96
8	31	M	GBM	X			14	64	1	D	7
9	41	F	GBM			3	41	64	1	D	12
10	33	M	GBM				28	28.4	2	A	83
11	60	F	GBM			1	65	64	1	D	12
12	40	F	Astro IV	X	X	10	25	72.5	1	D	9
13	43	M	Astro IV	X	X	2	47.6	33.6	2	D	7
14	59	M	Astro IV	X	X	4	45	32.9	1	A	19
15	37	M	Astro IV		X	1	42	101	1	D	12
16	45	F	Astro IV			1	44	113	1	A	98
17	44	M	Astro IV			10	39.6		3	A	82
18	44	M	Astroll			10	45	65.6	4	A	111
19	34	M	Astroll	X			39.6	44	1	D	23
20	44	F	Astroll			10	43	112	6	D	17
21	34	M	Astroll				45		1	A	76
22	40	F	Astro II	X					4	D	12
23	30	M	Astro II	X					6	A	60
24	46	M	Astro II	X					6	A	30
25	46	M	Astro II	X					9	A	17
25>		9F- 16M	11GBM, 6 Astro IV, 8 Astro II				39.9±14. 39	62.91±27. 95		13A-12D	39.44±34.2 5

Pts: Patients; GBM: Glioblastomas, Astro: Astrocytomas; RTV: radiotherapeutic volume; Gy: Gray; D: dead, A: Alive; Ms: months

Table 1. Characteristics of patients with GBM – ASTRO- II- IV treated with CFRT+ HT

1.1. Conformal radiotherapy

Computer tomographic (CT) scans using a spiral CT scanner and magnetic resonance scanner (MR) were performed on each patients. These scans are elaborated for determin-

ing the cancer size and shape in 3 dimensions (3D). In this way precisely focused, high dose, radiation beams can be delivered to cancer mass in multiple treatment sessions. Before radiation, patients are fitted with a head frame, meantime CT and MR scans are performed to determine treatment planning. After the acquisition of these informations, patients are positioned on treatment couch and the linear accelerator directs arcs of radioactive photon beams to tumor. The pattern of the arc is computer - matched to the tumor shape using specific multileaf collimators. The CT/MR data of patients are sent to a computerized treatment platform. Through, this platform CT/MR images are fused using an image fusion software and the CTV is defined and contoured manually by clinicians and physicists. In our department, an integration of images with metabolic information such as single photon emission computed tomography (SPECT) has also been used. This permits sometimes to obtain a more accurate tumor visualization. The fusion of images is obtained by a commercial software package (Ergo- 3Dline®). Obtained the CTV, normally, a margin over these countered borders must be defined to take into account the possible microscopic extension of the tumour not evidenced on the CT/MR scans. These margins are generally countered 10-30 mm around the CTV obtaining the planned target volume (PTV). After PTV determination a new contour is done ensuring PTV coverage by 95% isodose line with the aim for obtaining a uniform dose homogeneity. Treatment is performed using a Varian Clinac 2100, 6mv. The median dose used for GBM and anaplastic astrocytomas treated with HT were of 36.87 ± 17.75 Gy versus 39.2 ± 15.57 Gy for patients treated with CFRT+TMZ alone. The radiotherapeutic volume were 54.04 ± 22.53 mm³ versus 85.12 ± 50.37 mm³ respectively.

1.2. Capacitive hyperthermia

For treating our patients we used a device (Synchrotherm) developed by Duer ®, Vigevano, Italy. This device consists of the following components: 1) a Radiofrequency generator (13.56 Mhz) 2) a pair of mobile plates or electrodes with independent superficial cooling system, 3) a heat exchanger, 4) a computerized control console. The thermal profiles to obtain a probable deposition of the energy were obtained by heating patterns produced in a static phantoms. A cylindrical phantom made of 4% agar gel plus 0.2% NaCl was made and the various isotherms were monitored and reconstructed through computerizations of images obtained by a special film sensible to temperature. A flexible vinyl sheet, forming a space filled with 0.4% NaCl solution, covered the surfaces of the electrodes. The saline solution circulated between the electrode and the heat exchangers. Differently to other cooling system, the two electrodes were independently controlled and were simply adaptable to the contour of the brain patients, thanks to their flexibility. These plates are coupled to opposite side of the patient 's brain and kept in place thanks to a girdle permitting a better contact over the irregularity of the skull contour. Capacitive hyperthermia treatment were given to the patients 30 ' after the CFRT; during the HT session 500cc of mannitol at 19%, plus 4-8 mg of desamethazone were infused. HT treatments lasted for all patients 1 hour, and for five days consecutively. Some of these patients received more than one HT treatment/month (median 3 maximum 5 HT treatments).

2. TMZ administration

TMZ was administered orally 200mg/m² /day on day one to five, after written informed consent. A full blood examination was performed before each new cycle. The treatment cycles were repeated every 28 days. The patients fasted 4 hours before TMZ use, and were submitted to conformal radiotherapy (CFRT), following our standards supplementation with omega-3 fatty acids and silymarin for preventing radionecrosis.

3. Rationale for using liposomal doxorubicin

Temozolomide is an imido-tetrazine readily absorbed orally and able to cross the Blood brain barrier. TMZ has demonstrated activity against Glioblastoma, astrocytoma of various degree and brain metastases [3, 15]. Although TMZ has become the drug of choice in association with radiotherapy for Glioblastoma, many Glioblastoma develop resistance to the drug and become incurable. The reasons for this resistance is at the moment not completely understood and seems linked to the presence of certain subpopulations of cancer- stem cells inside the tumor mass [32]. This possible resistance has forced our group to look for other drugs active on GBM. We have chosed liposomal doxorubicin for various reasons that we will be describe here.

Liposomal doxorubicin (Caelyx®), is a formulation of hydrochloride doxorubicin wrapped by a film composed by phospholipids and polymers of methoxypolyethylene (mPEG) embedded in the lipid surface [33]. This association determines favorable pharmacokinetic profile characterised by an extended circulation time, a reduced volume of distribution, thereby promoting an increased tumour uptake [34, 35]. Tumor abnormal microcirculation and permeability is responsible for the increased uptake and retention of liposomal drugs, see Maeda [36]. This phenomenon is greatly increased by Hyperthermia, as demonstrated by Ponce and Dvorak [37, 38]. Dvorak was one of the first to use the combination of Caelyx® and hyperthermia on hepatocarcinoma and after his study reported that the combination of hyperthermia and doxorubicin itself may be supra-additive, resulting in enhanced antitumor efficacy in the heated region and in decrease of toxicity [38]. Caelyx® has been investigated by Koukourakis in glioblastoma and in metastatic brain tumours [39]. These authors in agreement with Chua and Lesniak group concluded that liposomal doxorubicin selectively overcome the blood brain barrier and accumulate 13-19 times higher in the Glioblastoma [40, 41]. Furthermore, Chua [40] has demonstated the possibility of using Caelyx® in association with temozolomide in recurrent Glioblastoma. Liposomal doxorubicin was associated with disease stabilization and a modest haematologic toxicity. These studies have convinced our group to use pegylated doxorubicin in a recurrent case of GBM. The case is here briefly described.

4. Case of patient treated with Caelyx

The patient (right handed man) was first surgically treated (Dec 2005) for left posterior parietal Glioblastoma then the patient underwent RT (45 Gy CFRT in 18 fractions followed by a boost CFRT to reduced target of 20 Gy in 4 fractions) and started and continued Temodar (10 cycles) until progression (Jan 07) followed by ACNU (2 Cycles) until progression (March 2007) and then we started LD and Radiofrequency Hyperthermia (HT).

During the first period the cycles were done at 45 days interval then, after a initial good response and stabilization, the treatment was done at larger interval up to 9 CT+HT (the last treatment was done in Nov 2007).

The treatment was as follows: 12 mgm² IV + steroids in glucose solution and assumption of 200 mg of Quercetin in day 1 and one hour of HT at least four hour later. From day 2 to 5 the patient underwent 4 further consecutive days of HT and quercetin (100 mg before and after the completion of treatment).

HT was delivered by means of a 13.56 MHz radiofrequency capacitive device (Synchrotherm Duer) via two opposite plates at the maximum tolerated power for at least one hour for five consecutive days.

4.1. Statistical analysis

Survival curves were calculated according to Kaplan-Meier method, Starting on the first day of HT. Survival was compared using the log-rank test and the K-test. Significance was posed as $p \leq 0.05$ [11].

4.2. Results

As it is possible to see comparing table 1 and table 2 there is no statistical difference between the two groups regarding age, gy administered and volume of tumour treated. The difference on survival curves (see Fig. 1) using the log-rank test and the K-test are important and more than the 50% of patients treated with CFRT+HT+TMZ are alive at 26 months. We can object than the comparison of the two groups is not completely homogeneous. In fact, the group in table 2 treated with TMZ + CFRT are only GBM, on the contrary in table 1 there is the presence of Astrocytoma of II degree. At a second look at table 1, an important observation emerges however, the GBM group has a long survival that is sometimes 3 times that of table 2, see pts 1, 3 table 2 and pts 3,7,10 of table1. It seems clear that HT adds something regarding survival and no side effects have been reported by patients. The patient treated with Caelyx® after surgery Dec 2005, had progression of the disease. He received CFRT in February 2006 and 10 cycles of Temodal. The patient on March 2009 shows progression and possible resistance to Temodal, we decided to treat the patient with 11 cycles of Caelyx + HT. The patient situation is illustrated in Fig 1(progression of disease after 10 cycle of Temodal, 2006) and Fig 2 after 11 cycles of Caelyx + HT (2009). The decrease of volume is evident. The patient is still alive and in treatment with a dose of 80 mg of Talidomide taken orally at evening, as a single dose.

Pts	Gender	Age	RTV(cm ³)	Gy	D / A	Ms Survival
1	F	30	31.6	36.4	D	30
2	M	52	65.4	20	D	13
3	F	64	108	40.5	D	37
4	M	22	56.8	25	D	9
5	M	69	76.9	45.6	D	15
6	M	57	64.1	70	D	1
7	F	61	175	18	D	2
8	F	65	64.5	35	D	10
9	F	47	19.8	54	D	25
10	M	66	136.9	45.5	D	4
11	M	50	226	42	D	13
12	F	45	19.9	54	D	19
13	M	67	67.9	20.4	D	26
14	M	65	119	20	D	14
15	F	22	45	45	D	5
15	7F- 8M	52.13±16.177	85.12±50.37	39.2±15.57	15 D	14.87±10.7

Pts: Patients; RTV: radiotherapeutic volume; Gy: Gray; D: dead, A: Alive; Ms: months

Table 2. Characteristics of Patients with GBM treated with CFRT + TMZ

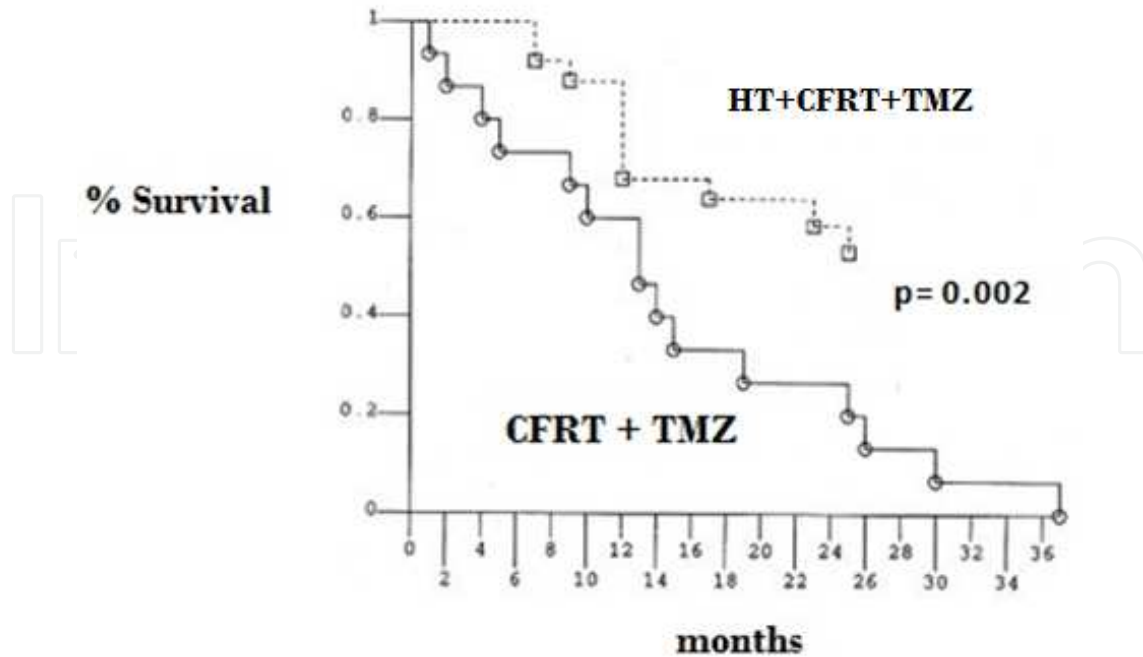


Figure 1. Survival curve of patients treated with HT + CFRT + Temodal, compared with CFRT + Temodal

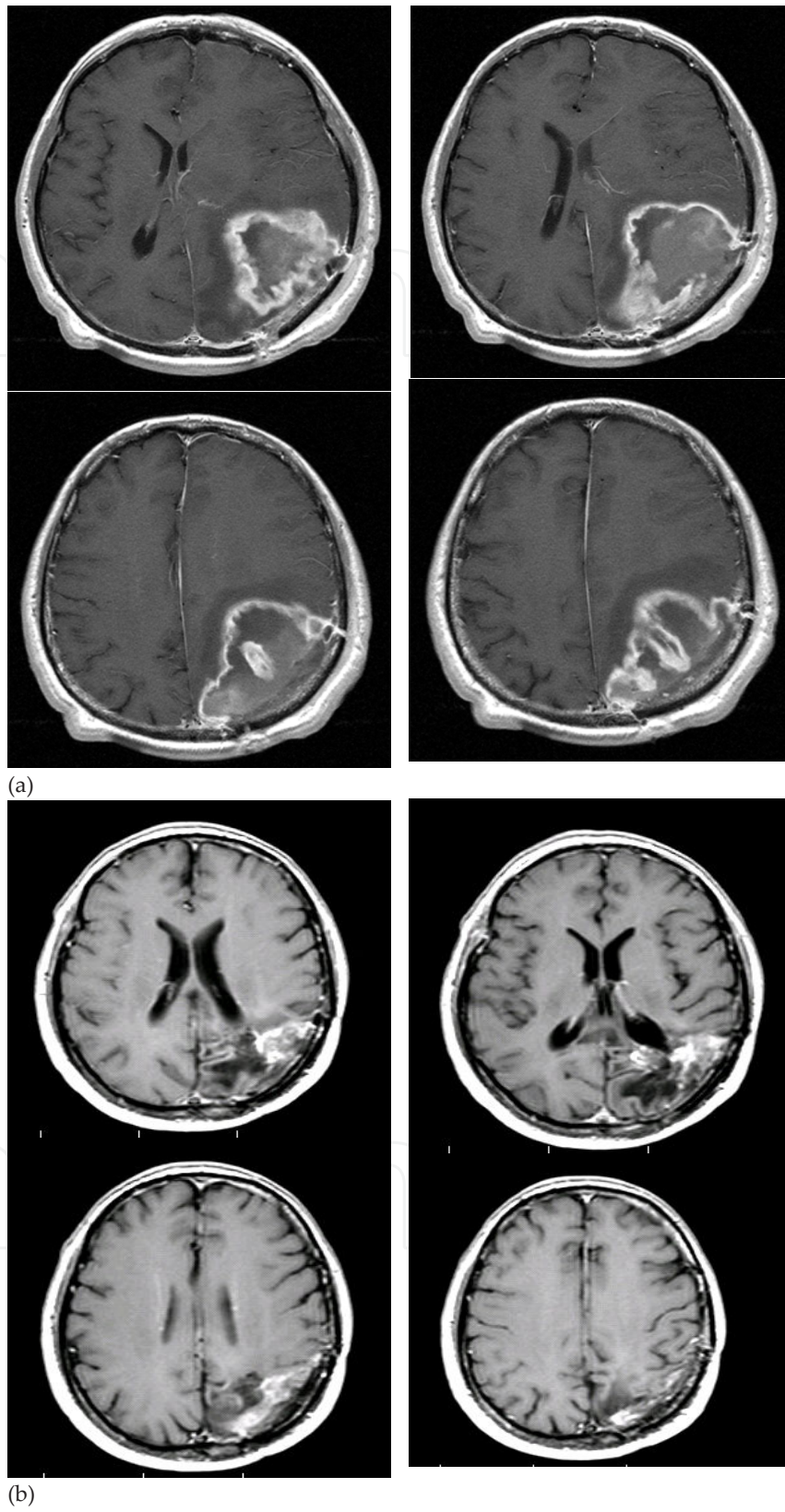


Figure 2. a. Patient with recurrent and drug resistance before Hyperthermia and Caelyx treatment. b. Decrease of GBM volume after Hyperthermia and Caelyx treatment

5. Conclusions

Our study, is in agreement with the previous studies on HT [29], and show that the association with temozolomide is feasible and that this triple treatment (Chemotherapy, Conformal Radiotherapy and hyperthermia) represents a promising new approach to the treatment of glioblastomas. In this initial work we have not analyzed patients treated with hyperthermia without TMZ, so we cannot understand if the increase in life survival must be ascribed simply to HT or to the combination with temozolamide. The quantity of patients is limited but we are encouraged to use external capacitive HT in association with the standard therapy of our institution. In a near future, we hope to be able to distinguish the effects of the two therapies. We hope also to analyze the compliance of the patients to hyperthermia and to be able to study the side effects of HT on brain. We want to point out that most of works done on brain and hyperthermia regards studies with interstitial HT [29]. Interstitial HT represents to our opinion a limit to a larger use of this technique in association with CFRT and chemotherapy, whereas capacitive HT show a simpler use and seems to be well tolerated by patients.

Author details

Gianfranco Baronzio^{1*}, Gurdev Parmar², Michela De Santis³ and Alberto Gramaglia³

*Address all correspondence to: barongf@intercom.it

1 Centro Medico Kines, Castano primo, (Mi), Italy

2 Integrated Health Clinic, Fort Langley, B.C., Canada

3 Radiotherapy and Hyperthermia Department, Policlinico di Monza, Monza, Italy

References

- [1] Parkin, D. M. Global cancer statistics in the year 2000. *Lancet Oncol.* (2001). Sep;; 2(9), 533-43.
- [2] Lino, M, & Merlo, A. Translating biology into clinic: the case of Glioblastoma. *Curr Opin Cell Biol.* (2009). Apr;; 21(2), 311-6.
- [3] Reardon, D. A, & Wen, P. Y. Therapeutic advances in the treatment of Glioblastoma: rationale and potential role of targeted agents. *Oncologist.* (2006). Feb;; 11(2), 152-64.
- [4] Kesari, S. Understanding glioblastoma tumor biology: the potential to improve current diagnosis and treatments. *Semin Oncol.* (2011). Dec;38 Suppl 4:S, 2-10.

- [5] Schneider, T, Mawrin, C, Scherlach, C, Skalej, M, & Firsching, R. Gliomas in adults. *Dtsch Arztebl Int.* (2010). Nov;; 107(45), 799-807.
- [6] Ekstrand, A. J, Sugawa, N, James, C. D, & Collins, V. P. Amplified and rearranged epidermal growth factor receptor genes in human glioblastomas reveal deletions of sequences encoding portions of the N- and/or C-terminal tails. *Proc Natl Acad Sci U S A.* (1992). May 15;; 89(10), 4309-13.
- [7] Bleeker, F. E, Molenaar, R. J, & Leenstra, S. Recent advances in the molecular understanding of glioblastoma. *J Neurooncol.* (2012). May;; 108(1), 11-27.
- [8] MartinezRamon; Schackert, Gabriele; Yaya-Tur, Ricard; Rojas-Marcos, Iñigo; Herman, James G.; Esteller, Manel ((2006). Frequent hypermethylation of the DNA repair gene MGMT in long-term survivors of glioblastoma multiforme". *Journal of Neuro-Oncology* , 83(1), 91-3.
- [9] Daga, A, Bottino, C, Castriconi, R, Gangemi, R, & Ferrini, S. New perspectives in glioma immunotherapy. *Curr Pharm Des.* (2011). , 17(23), 2439-67.
- [10] Polivka J JrPolivka J, Rohan V, Topolcan O, Ferda J. New molecularly targeted therapies for glioblastoma multiforme. *Anticancer Res.* (2012). Jul;; 32(7), 2935-46.
- [11] Rao, S. K, Edwards, J, Joshi, A. D, Siu, I. M, & Riggins, G. J. A survey of glioblastoma genomic amplifications and deletions. *J Neurooncol.* (2010). Jan;; 96(2), 169-79.
- [12] Lassman, A. B, Rossi, M. R, Raizer, J. J, Abrey, L. E, Lieberman, F. S, Grefe, C. N, Lamborn, K, Pao, W, Shih, A. H, Kuhn, J. G, Wilson, R, Nowak, N. J, Cowell, J. K, Deangelis, L. M, Wen, P, Gilbert, M. R, Chang, S, Yung, W. A, Prados, M, & Holland, E. C. Molecular study of malignant gliomas treated with epidermal growth factor receptor inhibitors: tissue analysis from North American Brain Tumor Consortium Trials 01-03 and 00-01. *Clin Cancer Res.* (2005). Nov 1;; 11(21), 7841-50.
- [13] Rich, J. N, Reardon, D. A, Peery, T, Dowell, J. M, Quinn, J. A, Penne, K. L, Wikstrand, C. J, Van Duyn, L. B, Dancey, J. E, Mclendon, R. E, Kao, J. C, & Stenzel, T. T. Ahmed Rasheed BK, Tourt-Uhlig SE, Herndon JE 2nd, Vredenburgh JJ, Sampson JH, Friedman AH, Bigner DD, Friedman HS. Phase II trial of gefitinib in recurrent glioblastoma. *J Clin Oncol.* (2004). Jan 1;; 22(1), 133-42.
- [14] Raizer, J. J, Abrey, L. E, Lassman, A. B, Chang, S. M, Lamborn, K. R, Kuhn, J. G, Yung, W. K, Gilbert, M. R, Aldape, K. A, Wen, P. Y, Fine, H. A, Mehta, M, Deangelis, L. M, Lieberman, F, Cloughesy, T. F, Robins, H. I, & Dancey, J. Prados MD; North American Brain Tumor Consortium. A phase II trial of erlotinib in patients with recurrent malignant gliomas and nonprogressive glioblastoma multiforme post radiation therapy. *Neuro Oncol.* (2010). Jan;; 12(1), 95-103.
- [15] Addeo, R, & Caraglia, M. Combining temozolomide with other antitumor drugs and target-based agents in the treatment of brain metastases: an unending quest or chasing a chimera? *Expert Opin Investig Drugs.* (2011). Jul;; 20(7), 881-95.

- [16] Raymond, E, Brandes, A. A, Dittrich, C, Fumoleau, P, Coudert, B, Clement, P. M, Frenay, M, Rampling, R, Stupp, R, Kros, J. M, Heinrich, M. C, Gorlia, T, & Lacombe, D. van den Bent MJ; European Organisation for Research and Treatment of Cancer Brain Tumor Group Study. Phase II study of imatinib in patients with recurrent gliomas of various histologies: a European Organisation for Research and Treatment of Cancer Brain Tumor Group Study. *J Clin Oncol.* (2008). Oct 1;; 26(28), 4659-65.
- [17] Plate, K. H, Scholz, A, & Dumont, D. J. Tumor angiogenesis and anti-angiogenic therapy in malignant gliomas revisited. *Acta Neuropathol.* (2012). Dec;; 124(6), 763-75.
- [18] Yang, L, Lin, C, Wang, L, Guo, H, & Wang, X. Hypoxia and hypoxia-inducible factors in glioblastoma multiforme progression and therapeutic implications. *Exp Cell Res.* (2012). Nov 15;; 318(19), 2417-26.
- [19] Haar, C. P, Hebbar, P, & Wallace, G. C. th, Das A, Vandergrift WA 3rd, Smith JA, Giglio P, Patel SJ, Ray SK, Banik NL. Drug resistance in glioblastoma: a mini review. *Neurochem Res.* (2012). Jun;; 37(6), 1192-200.
- [20] Mrugala, M. M, Crew, L. K, Fink, J. R, & Spence, A. M. Carboplatin and bevacizumab for recurrent malignant glioma. *Oncol Lett.* (2012). Nov;; 4(5), 1082-1086.
- [21] Sweet, J. A, Feinberg, M. L, & Sherman, J. H. The role of avastin in the management of recurrent glioblastoma. *Neurosurg Clin N Am.* (2012). Apr;; 23(2), 331-41.
- [22] Goel, S, Duda, D. G, Xu, L, Munn, L. L, Boucher, Y, Fukumura, D, & Jain, R. K. Normalization of the vasculature for treatment of cancer and other diseases. *Physiol Rev.* (2011). Jul;; 91(3), 1071-121.
- [23] De Boüard, S, & Guillo, J. S. Angiogenesis and anti-angiogenic strategies for glioblastoma]. *Bull Cancer.* (2005). Apr;; 92(4), 360-72.
- [24] Fanelli, M, Sarmiento, R, Gattuso, D, Carillio, G, Capaccetti, B, Vacca, A, Roccaro, M, & Gasparini, G. Thalidomide: a new anticancer drug? *Expert Opin Investig Drugs.* (2003). Jul;; 12(7), 1211-25.
- [25] Daga, A, Bottino, C, Castriconi, R, Gangemi, R, & Ferrini, S. New perspectives in glioma immunotherapy. *Curr Pharm Des.* (2011). , 17(23), 2439-67.
- [26] Lowther, D. E, & Hafler, D. A. Regulatory T cells in the central nervous system. *Immunol Rev.* (2012). Jul;; 248(1), 156-69.
- [27] Wainwright, D. A, Sengupta, S, Han, Y, & Lesniak, M. S. Thymus-derived rather than tumor-induced regulatory T cells predominate in brain tumors. *Neuro Oncol.* (2011). Dec;; 13(12), 1308-23.
- [28] Holdhoff, M, & Grossman, S. A. Controversies in the adjuvant therapy of high-grade gliomas. *Oncologist.* (2011). , 16(3), 351-8.
- [29] Baronzio, G. F, Cerretta, V, Baronzio, A, Freitas, I, & Mapelli, M. Gramaglia A: Thermochemotherapy association: Biologic rationale, preliminary observations on its use

- on malignant Brain tumors. In *Hyperthermia in Cancer treatment. A primer*. Baronzio GF and Hager D editors (2006). Springer Business Ed. New York., 128-155.
- [30] Schem, B. C, & Dahl, O. Thermal enhancement of ACNU and potentiation of thermochemotherapy with ACNU by hypertonic glucose in the BT4An rat glioma. *J Neurooncol.* (1991). Jun;, 10(3), 247-52.
- [31] Beal, K, Abrey, L. E, & Gutin, P. H. Antiangiogenic agents in the treatment of recurrent or newly diagnosed glioblastoma: analysis of single-agent and combined modality approaches. *Radiat Oncol.* (2011). Jan 7;6:2.
- [32] Johannessen, T. C, & Bjerkgvig, R. Molecular mechanisms of temozolomide resistance in glioblastoma multiforme. *Expert Rev Anticancer Ther.* (2012). May;, 12(5), 635-42.
- [33] Green, A. E, & Rose, P. G. Pegylated liposomal doxorubicin in ovarian cancer. *Int J Nanomedicine.*(2006). , 1(3), 229-39.
- [34] Gabizon, A, Shmeeda, H, & Grenader, T. Pharmacological basis of pegylated liposomal doxorubicin: impact on cancer therapy. *Eur J Pharm Sci.* (2012). Mar 12;, 45(4), 388-98.
- [35] Holloway, R. W, Grendys, E. C, Lefebvre, P, Vekeman, F, & Mcmeekin, S. Tolerability, efficacy, and safety of pegylated liposomal Doxorubicin in combination with Carboplatin versus gemcitabine-Carboplatin for the treatment of platinum-sensitive recurrent ovarian cancer: a systematic review. *Oncologist.*(2010). , 15(10), 1073-82.
- [36] Maeda, H. Macromolecular therapeutics in cancer treatment: The EPR effect and beyond. *J Control Release.* (2012).
- [37] Ponce, A. M, Vujaskovic, Z, Yuan, F, Needham, D, & Dewhirst, M. W. Hyperthermia mediated liposomal drug delivery. *Int J Hyperthermia.* (2006). May;, 22(3), 205-13.
- [38] Dvorak, J, Zoul, Z, Melichar, B, Petera, J, Vesely, P, Vosmik, M, & Dolezel, M. Liposomal doxorubicin combined with regional hyperthermia: reducing systemic toxicity and improving locoregional efficacy in the treatment of solid tumors. *J Chemother.* (2004). Nov;16 Suppl , 5, 34-6.
- [39] Koukourakis, M. I, Koukouraki, S, Fezoulidis, I, Kelekis, N, Kyrias, G, Archimandritis, S, & Karkavitsas, N. High intratumoural accumulation of stealth liposomal doxorubicin (Caelyx) in glioblastomas and in metastatic brain tumours. *Br J Cancer.* (2000). Nov;, 83(10), 1281-6.
- [40] Chua, S. L, Rosenthal, M. A, Wong, S. S, Ashley, D. M, Woods, A. M, Dowling, A, & Cher, L. M. Phase 2 study of temozolomide and Caelyx in patients with recurrent Glioblastoma multiforme. *Neuro Oncol.* (2004). Jan;, 6(1), 38-43.
- [41] Lesniak, M. S, Upadhyay, U, Goodwin, R, Tyler, B, & Brem, H. Local delivery of doxorubicin for the treatment of malignant brain tumors in rats. *Anticancer Res.* (2005). Nov-Dec;25(6B);, 3825-31.