

We are IntechOpen, the world's leading publisher of Open Access books Built by scientists, for scientists

4,800

Open access books available

122,000

International authors and editors

135M

Downloads

Our authors are among the

154

Countries delivered to

TOP 1%

most cited scientists

12.2%

Contributors from top 500 universities



WEB OF SCIENCE™

Selection of our books indexed in the Book Citation Index
in Web of Science™ Core Collection (BKCI)

Interested in publishing with us?
Contact book.department@intechopen.com

Numbers displayed above are based on latest data collected.
For more information visit www.intechopen.com



Liver Metastases – Surgical Treatment

Alejandro Serrablo, Luis Tejedor and
Jose-Manuel Ramia

Additional information is available at the end of the chapter

<http://dx.doi.org/10.5772/55898>

1. Introduction

Liver metastases are now detected at earlier stages because of the improvement in imaging techniques and the closer follow-up of cancer patients. The right lobe is metastasized to more frequently than the left, mainly due to the preference of tumour emboli circulating through the right portal vein as a feature of the portal stream. Liver metastases may also arise from draining lymphnodes through venolymphatics communications or the thoracic duct [1]. Lymphatic metastases may arise from these portal blood born liver metastases, usually pointing to a very poor prognosis.

All patients with colorectal liver metastases (CLM) are classified as having stage IV disease in the TNM classification of liver tumours given by the International Union Against Cancer (UICC) and the American Joint Committee on Cancer (AJCC), but they form a very heterogeneous group (synchronous and metachronous metastases, node-positive and node-negative disease, unilobar and bilobar lesions, and extrahepatic or no extrahepatic disease) and their long-term outcomes may vary widely. Several clinical scores [2-6], based on retrospective data, have been developed to predict more accurately the prognosis of these patients and thus to stratify their management, but their validation is still limited.

2. Colorectal liver metastases

The liver is the most frequent and often unique site of metastasis in patients with colorectal cancer, both at the time of diagnosis (20–25% of cases) or after an apparently radical surgery on the primary tumour (40% of cases) [7]. Less than one third of patients with CLM have disease limited to one lobe and in only 10% of cases is metastasis solitary.

CLM are usually asymptomatic but patients may develop abdominal discomfort, weight loss, general malaise and hepatomegaly with advanced disease. Jaundice, ascites and occasionally portal hypertension are late signs. Pain and fever related to necrosis and infarction of a metastasis are usually transient symptoms.

CLM are often harder to palpate than the normal liver, extend by concentric growth and may spread to other structures by penetrating the usually rigid Glisson's capsule.

The natural history of metastatic colorectal cancer is variable. Median survival without treatment is less than eight months from presentation but the prognosis is better for those patients with isolated CLM. Survival of patients with untreated CLM at five years is unusual.

2.1. Diagnosis

Diagnosis of CLM is mainly based in imaging studies, with history, physical examination and serum levels of alkaline phosphatase, aspartate aminotransferase, glutamyl transferase and carcinoembryonic antigen playing a minor role. Accurate detection of CLM has important prognostic implications, since untreated liver metastases have a poor prognosis (5-year survival rate of 0-3%) while the resection with curative intent offers a much better one (5-year survival rate from 35% to 58%) [8]. The imaging of these lesions, needed for a careful pre-operative selection of patients, should assess their number, size and segmental location, their differential diagnosis with benign lesions, possible hilar lymph node involvement (although the pre-operative diagnosis is difficult), the evaluation of vascular invasion, the liver volume (insufficient residual volume of liver parenchyma is a contraindication to surgery), and the presence of extrahepatic disease (although peritoneal carcinomatosis is very difficult to detect).

The specificity of imaging studies detecting CLM is higher than 85%, and the sensitivity for detection of liver metastases is progressively increasing from transabdominal ultrasound (US) to multi-detector computed tomography (CT), magnetic resonance imaging (MRI) and fluorodeoxyglucose-enhanced positron emission tomography (FDG PET) [9]. FDG PET and CT can be combined to provide fused images, achieving high spatial resolution and functional information in the same images (FDG PET/CT).

Biopsy of suspected CLM is not usually done in patients with potentially resectable disease because imaging studies are generally accurate enough and percutaneous biopsy may be associated with extrahepatic dissemination.

CT scan remains the dominant imaging modality both for detection of CLM and preoperative planning as well as for treatment monitoring and post-treatment surveillance. CT combined with FDG PET/CT may avoid additional studies and may improve patient management [32-34]. Contrast-enhanced MRI should be reserved for problem solving. Because MRI sensitivity in detecting extrahepatic disease in the peritoneum and chest is low, it is not a desirable primary imaging modality.

2.1.1. Ultrasonography

US is a rapid and non-invasive method for screening patients with suspected liver metastases. While it is highly efficient in distinguishing patients with diffuse hepatic metastases, it is more

operator dependent than other imaging studies and its sensitivity (50-70%) and specificity are surpassed by other imaging methods.

Contrast-enhanced US (CEUS) improves the sensitivity compared to conventional B-mode sonography by using microbubbles of gas that flood the blood pool after intravenous injection. Metastases show characteristic images in arterial, portal and delayed phases, thereby increasing CEUS sensitivity and specificity in staging liver metastases and approaching those of CT and MRI [8]. As CEUS improves the detection of metastases smaller than 1 cm and of those lesions that are isoechoic with respect to adjacent liver parenchyma, it improves the performance of US in around 13.7% of the cases [10]. CEUS can be suboptimal in visualizing certain parts of the liver, especially in obese patients and/or in cases of steatosis and may find difficult to differentiate hypervascular metastases from haemangiomas and metastases from small cysts [11]. For these reasons, US should not be the imaging method of choice in the assessment of CLM.

2.1.2. Computed tomography

CT sensitivity and specificity are high (70–85% and 90% respectively) especially for lesions bigger than 1.5–2 cm. Although sensitivity is lower for small subglissonian metastases, multi-slice CT enables detection of lesions of 0.5 cm in size (thicknesses of 2 or 4 mm are the most effective for detection of focal liver lesions, with an identical detection rate of 96% for both) [12]. Fast data acquisition allows bi-phasic contrast-enhanced scan during the arterial-dominant and the portal perfusion phases after bolus contrast administration, prior to the equilibrium phase (hepatic venous or interstitial). This part of the study should be considered as standard for the optimised view of the complex vascularization of the liver and potential hepatic lesions.

CT can be used for evaluating the liver lesion, liver parenchyma and hepatic vessels in the same sitting, since its software grants 3-D data sets, which improves multiplanar imaging, demonstrates the vascular anatomy and characterizes the lesions well. This feature, together with improvements in bolus-tracking, facilitates CT-angiography of the liver and mesenteric vessels, which can be invaluable in patients undergoing hepatic resection or transarterial chemo or radio-embolisation. The CT portal venogram is useful in evaluation of the portal system. Quantitative perfusion studies can also be done.

CT software is also able to highlight different liver segments, assess liver volume and to create vascular maps for arterial and portal inflow and hepatic venous drainage, which are necessary in evaluating the feasibility of major hepatectomies. A simulation of surgical resection can be performed. This information can be shown visually using coloured maps or three-dimensional movies [13], which are tools increasingly used because they ease surgical dissection but still requiring validation.

The utility of CT as a pre-operative tool to evaluate CLM is inversely proportional to the time elapsed between imaging and surgery, which may explain the conflicting reports on the accuracy of CT [14].

2.1.3. Magnetic resonance imaging

Although CT is usually preferred because of its availability and its good surveillance of the extrahepatic abdominal organs and tissues, MRI has an advantage in the characterization of focal lesions. It is also used for patients who cannot receive intravenous iodinated contrast material or there is concern about the risk of radiation from repeated exposure to CT. MRI sensitivity and specificity (85-90% and up to 95% respectively) are higher than those of CT, but this comparison needs to be reassessed periodically, owing to the rapid evolution of both technologies.

The extracellular agent gadolinium-chelate complex is the most commonly used contrast media in dynamic MRI. The current standard MRI liver protocol includes a T2-weighted sequence, a T1-weighted sequence and a three-phase technique after administration of gadolinium. Detection of CLM is maximized during the portal venous phase, like in CT scan. Organ-specific contrast agents with hepatocyte specificity (mangafodipir trisodium [MnDPDP], gadobenate dimeglumine [Gd-BOPTA]) or reticuloendothelial system specificity (superparamagnetic iron oxide [SPIO] particles, captured by Kupffer cells) increase the sensitivity and specificity [15,16], but data about their benefits are controversial and they are generally expensive and not widely available.

Diffusion-weighted MR imaging (DWI) depicts differences in molecular diffusion caused by the random motion of molecules without the need for a contrast agent [8] and can obtain quantitative indices, helpful in the assessment of disease response to novel therapeutics (including antivascular and anti-angiogenic therapy) [17]. It can be a simple and sensitive method for screening focal hepatic lesions and very useful for differential diagnosis [18].

2.1.4. Positron emission tomography

FDG PET sensitivity and specificity are high for CLM (92–100% and 85–100% respectively). However, false negative and false positive findings in FDG PET for CLM are not negligible [19] and its positive predictive value (PPV) is not high. Thus, some teams recommend histological confirmation when the findings suggest non-resectability [20]. Some studies have demonstrated high diagnostic values of FDG PET in the evaluation of liver metastases [21-23] confirming its superior sensitivity on a per patient basis, but not on a per lesion basis. Nevertheless, its role is not yet clear owing to the small number of studies [24].

In the context of CLM, FDG PET/CT may avoid unnecessary surgery when it detects extrahepatic foci of disease that are not depicted or characterized as malignant by other imaging methods [25]. When these patients have a FDG PET prior to surgery, there is a lower probability of non-therapeutic laparotomy [26] and an improved survival [27], reflecting better patient selection. As a drawback, this technology is not suitable for liver resection planning.

2.1.5. Intraoperative ultrasonography

The best standard of reference when comparing diagnostic studies is laparotomy with bimanual palpation and intraoperative ultrasonography (IOUS). This method finds additional

lesions in 33% of patients with preoperative diagnosed CLM and new lesions in 5% of patients without known CLM [1].

IOUS has higher sensitivity (98%) than transabdominal US, CT and MRI (its specificity is 95%), allows the detection of lesions 0.5 cm in size and defines the relationship between lesion, vessels and biliary structures. It is generally considered the gold standard for detecting liver lesions and is regarded as a routine investigation, since it modifies the planned surgical strategy in 18-30% of the patients. In addition, Doppler and spectral Doppler facilitate the technique of surgical resection.

Laparoscopy allows an assessment of the peritoneal spread, liver surface, extrahepatic disease and vessel invasion. Its combination with laparoscopic ultrasound (LIOUS) modifies the initial surgical plan in 20–30% of the cases [12].

Contrast enhanced IOUS (CEIOUS) shows some benefit over pre-operative imaging and IOUS since it improves the ability to characterize already detected lesions and facilitate the detection of new ones [28-31].

2.2. Surgical treatment

2.2.1. Resectable CLM

Hepatic resection offers the only chance of long-term survival for patients with CLM, the first large series concluding that there was a benefit for surgery in selected patients with CLM being reported in 1978 [35]. The 5-year survival rate for these patients has increased from about 30% two decades ago to nearly 60% nowadays, with a 10-year overall survival of 20–25% for radically resected patients [36].

Criteria for resectability

The resectability rate has improved thanks to pre-operative imaging techniques, patient selection, surgical techniques, postoperative care and new cytotoxic and biologic agents for preoperative and post-operative treatment. Thereby, the criteria for resectability of these cases have changed dramatically. The number of lesions (1 to 3 unilobar metastases), the size of the lesion (less than 5 cm), the interval of time (preferably presenting at least 12 months after resection of the primary tumour), the minimum margin of 1 cm in width and the absence of hilar adenopathy or extrahepatic disease, are no longer considered as determinant factors when considering resectability.

The number of metastases is not a risk factor for long-term survival providing that a R0 resection (complete resection with no microscopic residual tumour) has been achieved [37]. Some studies have shown that the degree of response to chemotherapy is a stronger predictor factor for longterm survival than the number of metastasis. Although reports have been conflicting, evidence shows that size is not a resectability factor, but a factor related to tumour aggressiveness. Likewise, the width of the surgical margin has no effect on survival whenever the margin is microscopically negative [38-40], though resection planning should aim for an optimum margin, i.e. greater than one centimeter in width. Extrahepatic disease was consid-

ered a contraindication to liver resection until few years ago. Five-year survival rates of 12% to 37% after hepatic resection in selected patients, independent of the location of the extrahepatic disease (lung, primary colorectal recurrence, retroperitoneal or hepatic pedicle lymph nodes, peritoneal carcinomatosis, miscellaneous) have been reported [41-45]. In most of the patients, peritoneal disease is regarded as a contraindication to hepatic resection, but can be considered in cases of stable or chemo-responsive disease when an R0 resection is achievable. These patients should be classified as having borderline resectability [46]. Positive hilar lymph nodes have been associated with a poor survival and are also generally considered as a contraindication to liver resection of CLM. Again, however, some studies have shown lengthy survival in some patients, particularly if involved nodes are limited to the hepatoduodenal-retropancreatic area [47,48], although this nodes are not routinely removed.

In short, only two criteria for resectability are universally meaningful: (1) It must be possible to remove all disease with a negative margin; (2) There must be adequate remaining hepatic reserve. The only traditional prognostic indicator of recurrence that precludes long-term survival is a positive resection margin [34].

Accordingly, CLM are considered as resectable when they can be completely resected, two adjacent liver segments can be spared while sustaining an adequate vascular inflow and outflow and biliary drainage, and the volume of the future liver remnant (FLR) is adequate (at least 20% of the total estimated volume for liver with normal parenchyma, 30–60% for liver with chemotherapy, steatosis or hepatitis, 40–70% for liver with cirrhosis) [46]. To assess resectability clinically it is useful to estimate FLR to body weight ratio, which should be greater than 0.5. However, there is no universally adopted guideline for “resectability” of primary or metastatic liver cancer and often the experience of the individual surgeon plays an essential role.

Chemotherapy

Optimal regimens and timing of chemotherapies when liver resection is possible are unclear. The efficacy of the peri-operative chemotherapy on survival for resectable liver metastases has not been justified. Some authors suggest that treatment of resectable CLM, in the absence of high-risk features, should begin with surgery and then consider adjuvant chemotherapy [2]. There is no evidence to support neoadjuvant chemotherapy in patients with resectable disease [49]. Moreover, since around 7% of tumours will progress while on chemotherapy, this approach may compromise a few patient’s chance of cure if routinely used. If high-risk features are present, most physicians prefer a short course of systemic pre-operative chemotherapy. Patients with a perforated tumour or a considerable lymphatic burden are considered candidates for neoadjuvant chemotherapy before liver surgery. The EORTC 40983 study evaluated peri-operative chemotherapy vs. surgery alone in resectable hepatic metastases and did not demonstrate a clear advantage of preoperative chemotherapy in patients with resectable CLM. Neither could this study determine if neoadjuvant, adjuvant or peri-operative chemotherapy was superior. In this trial, the postoperative complication rate was significantly increased in those patients who received perioperative chemotherapy versus surgery alone. Some of these complications were biliary fistula, hepatic failure, intra-abdominal infection, and the need for re-operation. Supporters of peri-operative treatment point out that surgery

is facilitated and that the treatment provides information on tumour biology. The same study demonstrated that no patient progressed to an unresectable condition, that short cycles of treatment provided minimal liver toxicity and that survival improved in the chemotherapy sub-group [50]. Livers affected by chemotherapy are usually more rigid, more difficult to manage and tend to bleed more easily at surgery. Moreover, questions about the management of “ghost lesions” after complete response, that cannot be detected with IOUS, remain unanswered.

When resection is considered appropriate, it is imperative to have a high quality abdominopelvic CT (or MRI) within a month of the date of surgery. A chest CT should be done at that time.

Resection

Detailed knowledge of liver anatomy, inflow and outflow control, low central venous pressure, IOUS, ultrasonic dissection, argon beam coagulation, etc. contribute to reduce blood loss during the resection of CLM. Intraoperative bleeding is the main cause of postoperative morbidity and mortality since blood transfusion is associated to a decreased long-term survival, an increased perioperative mortality, a higher complication rate, a longer hospital stay, and an increased risk of infectious complications [51].

Hepatic segmentectomy, based on Couinaud segments, is preferable for localize lesions; a non-segmental resection may be technically more difficult and compromise the vascularity of adjacent residual liver. Nevertheless, IOUS must be used before attempting a wedge resection of an apparently superficial nodule. For larger or multiple CLM, standard anatomical resections must be employed. Additionally, the Brisbane 2000 Terminology of Liver Anatomy and Resections is recommended to avoid confusion in the terms used when describing surgical techniques [52].

The inability to obtain a free surgical margin during liver resection for CLM should not be a contraindication to surgery, provided complete macroscopic removal of all metastatic lesions is achieved (positive margins or R1 resection), since survival is similar to that of R0 resection, despite a higher recurrence rate (5-year and 10-year overall survival rates are 61% and 43% in R0 vs. 57% and 37% in the R1) [53].

Laparoscopic liver resection are now more frequently performed since the first one reported in 1992 [54]. It shows advantages in the short term over open surgery but there are still no data to indicate the impact of this procedure on long term outcome.

Mortality is less than 5% and morbidity is around 30%, given the wide variations in surgical aggressiveness. Postoperative hepatic failure can be a lethal complication. This depends on the volume and the function of the residual liver. In general, the larger the hepatic resection the greater the probability of postoperative complications. Other complications that may contribute to or be related to postoperative liver failure include haemorrhage, bile leak, intra-abdominal sepsis, and cardiopulmonary dysfunction.

In regard to surgery of synchronous and metachronous CLM, simultaneous colon and liver resection has been shown to be safe and efficient, since prognosis is not dependent on the time of resection of CLM.

2.2.2. *Initially non-resectable CLM*

Some techniques may be used when CLM are not at first resectable because of an insufficient FLR. Strategies to increase the volume of the hepatic remnant include conversion chemotherapy, portal vein occlusion, staged liver resection and combination of these procedures. Also, ablative techniques may be considered alone or in conjunction with resection.

Chemotherapy

Chemotherapy leads to improved survival in patients with unresectable CLM. In these cases, upfront chemotherapy in asymptomatic patients compared with resection of the primary tumour does not seem to affect survival significantly. However, without liver resection 60% of the patients are alive after 2 years so that resection of the primary lesion for palliative reasons and local control is recommended in rectal cancer [55].

The goal of conversion chemotherapy is downsizing the tumour for re-considering its resection. New chemotherapeutic regimens combining 5-FU, folinic acid and oxaliplatin (FOLFOX) and/or irinotecan (FOLFIRI) have improved response rates (approximately 50%), enabling 10-30% of the patients with initially unresectable disease to be operated [56]. Combined with biologic agents that target angiogenesis (bevacizumab) and the epidermal growth factor receptor (EGFR) in K-ras wildtype tumours (cetuximab), response rates of up to 70% are achieved [34]. A new re-evaluation for resection should be done after 2 or 3 months of pre-operative chemotherapy and every 2 months thereafter. Hepatic arterial infusion (HAI) of chemotherapy may be added to systemic therapy, obtaining a higher concentration of drugs in the liver with less systemic toxicity. Although response rates are higher than systemic chemotherapy, survival does not change so far. Furthermore, its complication rates are so high (57%) that it is discarded as a first option.

Chemotherapy should be stopped when the CLM have been downsized to the point where hepatic resection is possible in order to reduce liver toxicity and to avoid a complete clinical response. A complete response on CT scan does not mean cure since in over 80% of the cases there are viable cancer cells in the initial site of the metastasis [57]. These ghost lesions have to be removed or ablated, considering the FLR [58-60].

Tumour progression is associated with a poor outcome, even after potentially curative hepatectomy. Therefore, tumour control before surgery is crucial to offer a chance of prolonged remission in patients with multiple metastases [56]. Only 50% of tumours can be expected to show a partial response to chemotherapy. Patients deemed to be resectable during systemic treatment should be considered as surgical candidates regardless of the associated adverse predictive factors.

Peri-operative complications, including hepatobiliary complications, are more frequent with lengthy pre-operative chemotherapy, probably related to the prolonged and sequential use of multiple regimens [61]. Adjuvant treatment, usually FOLFOX, may be used following surgery, but HAI combined with systemic chemotherapy is also an option. Trials examining the role of adjuvant chemotherapy are difficult to conduct because of the rapidly changing chemotherapy regimens and drugs [62]. Since post-operative morbidity affects long-term survival [63], length

of chemotherapy treatment must be taken into account. In recent years more and more patients with stable long-term disease (more than 20 months) are considered for surgical treatment.

Portal vein occlusion

When the FLR is insufficient portal vein occlusion should be considered. In 1990 Makuuchi presented the portal vein embolization (PVE) of the right portal branch to induce hypertrophy of the left side of the liver, enabling a safer removal of large or multiple tumours, mostly located in the right hemiliver and segment IV [64]. The rationale behind this approach is to induce atrophy of the tumour-bearing lobe with subsequent hypertrophy in the contralateral lobe by diverting the portal venous flow into the liver section that is expected to remain. In general, two methods of portal vein occlusion can be employed: PVE or surgical portal vein ligation (PVL). Neither technique has clear advantage.

Portal occlusion increases the FLR between 10% to 46% within 2 to 8 weeks and enables a R0-resection in 70% to 100% of selected cases. However, some patients show tumour progression after PVE, but it is not clear whether this is just a matter of time (from portal vein occlusion to operation) or is due to growth stimuli to the tumour by the induced liver regeneration. Portal vein occlusion also constitutes a dynamic pre-operative test on the capacity of the liver to respond to the surgical aggression: If a hypertrophy greater than 5% is achieved, there is a low risk of a severe post-operative liver insufficiency [65].

The concomitant administration of chemotherapy may decrease both the tumour load and the post-operative recurrences. Chemotherapy does not seem to affect the hypertrophy induced by PVE. A few studies using bevacuzimab recommend a 6 week waiting period before surgery, although its influence on the hypertrophy is unclear.

Percutaneous PVE is usually well tolerated with minimum side effects such as fever, nausea, and transient abnormality of liver function test, and with a complication rate below 5% [66]. Major liver surgery after PVE has a complication rate of 1% for the PVE itself and a complication rate of 8.8% for the subsequent resection [67]. It increases the feasibility of liver resection by 19%. The actuarial survival rate after surgery is 40% at 5 years, similar to that of patients resected without PVE [68].

Two-stage hepatectomy

It is the combination of two sequential and planned liver resections when it is impossible to resect all liver metastases in a single procedure, while preserving at least 30% of functional liver volume to avoid post-operative liver failure. The first surgery attempts to resect the majority of CLM and to get hypertrophy of the remnant liver. The technique should be planned well in advance to achieve complete removal, admitting that around 30% of patients will not be rescued on the second hepatectomy.

Usually, on the first hepatectomy the FLR is cleared out of tumours with non-anatomic resections and/or radiofrequency ablation or at most a single segment resection [69]. This first stage can also be performed together with laparoscopic or open colorectal resection. After a period of recovery of 4 to 6 weeks and subsequent hypertrophy of the tumour-free lobe, tumour removal is completed by resection of the larger tumour mass in the contralateral liver lobe.

The majority of patients in whom this approach failed, did so because they had developed disease progression in the meantime.

As another option, two to four weeks after the first stage PVE may be performed [70]. The second surgery can be done on the fourth or fifth week after PVE, when a CT confirms that an adequate hypertrophy of the non-embolized hemi-liver is achieved. Alternatively, portal vein occlusion can be done during the first hepatectomy through the ligation and alcoholization of the right portal vein, which is the side more often embolized [71,72]. This modification is based on evidence that PVL triggers a similar or better regenerative response than PVE and could be safely applied, even in combination with partial hepatectomies of the left hemiliver.

In contemporary series of two-stage resection after PVE, 69% to 72% of the patients completed the second stage, the most common reason for dropout being tumour progression. Chemotherapy responsive patients who completed the resection have a 5-year survival rate of 32%-51% [73,74]. If new CLM or extrahepatic lesions are found, such as localized peritoneum implants, resection can still be performed if a R0 resection can be achieved. Pre-operative chemotherapy may be administered during the entire process.

Associating Liver Partition and Portal Vein Ligation for Staged Hepatectomy (ALPPS)

This technique has been recently described [75] It is a new concept of two-staged extended right hepatectomy with initial surgical exploration, right PVL, and in situ splitting (ISS) along the right side of the falciform ligament to induce rapid hypertrophy of the left lateral lobe in patients with marginally resectable or primarily nonresectable primary and metastatic liver tumours.

The selective embolization or ligation of segment IV portal branches when an extended right hepatectomy is planned has a significant impact on the hypertrophy of the FLR. However, the completeness of segment IV branch embolization requires optimal access and may frequently be incomplete. Combining PVL with ISS by nearly total parenchymal dissection induce a median hypertrophy of 74% (above that achieved by PVL or PVE alone) after a median time interval of 9 days.

This short time interval of about one week for hypertrophy overrides the risk of tumour progression in the meantime. Although for some patients the ALPPS can be the only chance to allow resection at all, further research needs to be conducted about short- and long-term results, such as accelerated development of micrometastases on the future remnant liver, systemic stress responses affecting the second step of resection, and survival and progression patterns [76]. In order to address the oncologic benefit of this new approach a registry has been created [77].

Laparoscopy has also been used in this technique, showing that it is feasible and may be worthwhile in experienced hands [78,79].

Some authors have highlighted possible drawbacks of ALPPS such an increased morbidity and mortality rates in the first reported series [80], the presence a devascularized, necrotic segment 4 in patients who could not be candidates for second stage because of insufficient

hypertrophy [81] and scarce advantages over the previous techniques [82], recommending to reserve ALPPS for cases of unexpected tumour extension [83].

Technical advantages of ALPPS include an easier second procedure (the rapid hypertrophy of the remnant liver enables the second surgery before the development of adhesions), a faster recovery for the patient, with the possibility of restoring chemotherapy earlier, and the performance of the colorectal resection simultaneously with the first step of the procedure, including the tumour cleaning of the FLR (thus minimizing the risk of complications associated with postoperative liver failure) [84]. Of course, refinement in technical aspects and optimized patient selection for this procedure is needed (Figure 1).

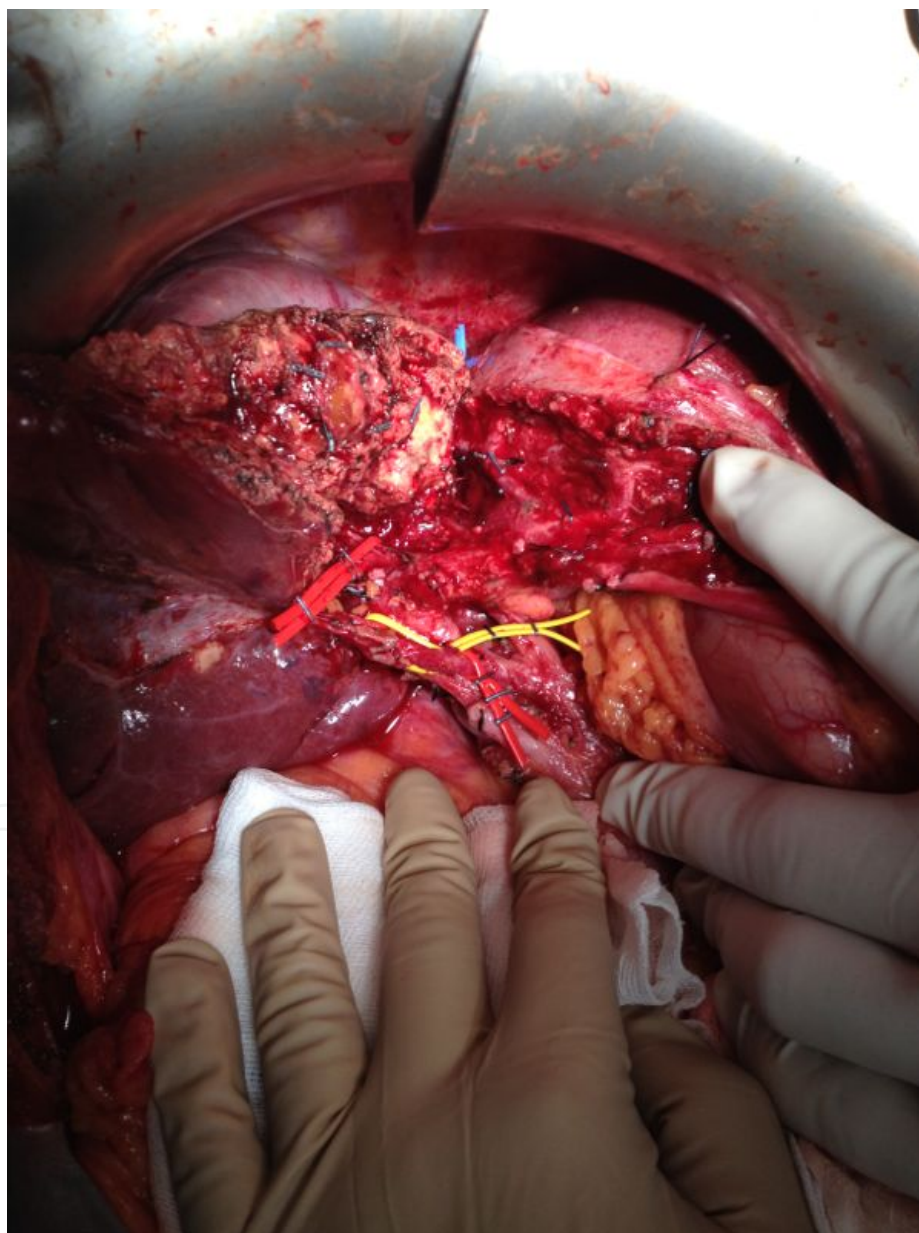


Figure 1. First stage of ALPPS

Ablative techniques

The precise role of ablative therapy is yet to be established. It can be used in patients with associated comorbidity that precludes resection and in patients who decline surgery, although there are significant risks associated with the procedure. Also patients with treatable extrahepatic disease or whose tumours have been downsized by chemotherapy but are not resectable may be considered for ablative therapy.

In radiofrequency ablation (RFA) a needle is placed into the centre of the metastasis. Alternating current results in frictional heat, which can reach up to 100°C, causing coagulative necrosis and irreversible tissue injury. The ablation zone varies in shape and size. Vessels situated next to the ablated tissue interfere with the ablative techniques by the “heat sink effect”. Minor complications occur in 2.4 to 12% of patients; major complications appear in up to 5.6%; mortality rate is approximately 0.5% [85]. RFA treatment can achieve a 3-year survival rate of 25%. The combination of RFA and systemic chemotherapy has been shown to achieve a 5-year survival rate of 30% [86-88].

Laser-induced thermotherapy (LITT) consists in the local administration of laser light delivered to the tumour by means of fibers of quartz crystal. The heating effect destroys tissue. Morbidity and mortality are similar to RFA. Local tumour control at 6 months is achieved in approximately 97% of the patients [85].

For microwave ablation (MWA), microwaves are used to agitate water molecules in the tissue and produce frictional heat which leads to large volumes of coagulative necrosis. Transmission is not limited by tissue desiccation and charring as in RFA, allowing higher intratumoural temperatures, a larger ablation zone, shorter treatment time, and more complete tumour killing. Five-year survival rates of 32% have been reported.

High-intensity focused ultrasound (HIFU) is an innovative technique for the extracorporeal treatment of different tumour masses. Treatment is administered with a lens-focused transducer that elevates the tissue temperature to 60°C. In addition, the mechanical effects of the highintensity ultrasound assist the destruction of the tumour cells. Adverse effects seems to be minor [89].

Cryotherapy uses liquid nitrogen or argon to cool tumour tissue down to -180°C. The formation of intracellular ice crystals leads to a mechanical destruction of the interstitium. Cells on the borderline of the ablation zone are destroyed by dehydration and occlusion of small vessels. Repeating cycles of freezing and thawing are used to ensure irreversible cell damage. Complications are reported in approximately 30% of all cases. Mortality rates between 1.5% and 4%. An “ice-cracking” of the liver tissue is seen in 5 to 28% of the patients receiving the treatment. Five-year and 10-year survival rate of 44% and 19% are reported, respectively [90]. The increased local recurrence rates and the high complication rates have led to a diminishing use of this technique.

2.2.3. Total vascular exclusion: In-situ, ante-situ and ex-situ procedures

Techniques learned in liver transplantation, reduced adult-sized liver for children, living related donor liver transplantation and split liver transplantation are useful in liver resection.

Some tumours deemed unresectable with standard techniques can be resected using in-situ, ante-situ and ex-vivo or bench liver surgery.

The common basis for these techniques is the total vascular exclusion (TVE) of the liver and the perfusion of the organ by preservation hypothermic solution. The techniques differ in the extent to which liver is mobilized from its vascular connections, hilum and caval vein. Usually, veno-venous bypass is used to avoid venous congestion during prolonged caval and portal crossclamping and a hypothermic preservation solution is instilled through the portal vein. Hypothermic perfusion leads to a better tolerance to ischemia [91]. Wrapping of the liver with ice-cold towels is recommended to optimize the effect of cold preservation.

The main indications of the three techniques are tumours that involve vascular structures of the hilum, venous confluence or inferior vena cava (IVC), or are in close proximity to them. The technique to use depends on the tumour location and its relationship with the three hepatic veins and caval vein. In the ante-situ procedure the division of the suprahepatic vena cava allows rotation of the liver around the coronary axis, providing optimal exposition of the venous confluence and the retrohepatic vena cava. In the ex-situ technique the liver is completely removed from the patient and perfused with preservation solution, allowing complex reconstructions of hepatic veins or portal structures after which the liver is reimplanted. Since the first description by Pichlmayr in 1988, the technique has been sparingly applied in selected patients [92,93] due to its high morbidity and mortality.

The involvement of the IVC does not necessarily preclude resection since it can be resected and reconstructed with an autogenous vein graft or a prosthetic material. Morbidity and mortality rates (40% and 4.5-25%, respectively) appears to be balanced by the possible benefits, particularly when the lack of alternative approaches is considered [94].

2.2.4. Re-resection: Repeat hepatectomy

Recurrence may occur in up to 75% of CLM resected patients. About 70% of them are observed within the first 12 months after resection and 92% appear within 24 months [95]. Fifty percent of these relapses are in the liver [96] but only 5-27% of the patients are candidates for potentially curative repeated hepatectomy. Repeat hepatectomy is a safe and effective procedure under the same criteria of selection of the first hepatectomy. Although the prognostic variables provide rough indicators of prognosis, they should not be used as absolute contraindications to surgery. Each case needs a particular and specific evaluation: disease-free interval, number of metastases, quality of life, general health condition, resectable extrahepatic disease, assessment of residual liver volume, etc. by the multidisciplinary team.

Recurrence after repeat hepatectomy has been reported in 60–80% of patients [97]. Some patients have resectable disease limited to the liver and may be candidates for a third or even fourth hepatic resection.

Between 9% and 30% of patients with a second hepatectomy for CLM have a third resection [2,98-100] and around 4% of them have a fourth resection [101].

The safety of multiple repeated hepatic resections has been demonstrated, with a low mortality rate (0%-2%) and a morbidity rate of 5%-30%, not significantly different from those who have had only one or two liver resections. LiverMet Survey published the largest series (n = 251) of third hepatectomies for recurrent CLM showing a survival benefit of 29% at 5 years. Technically, re-hepatectomies are more difficult than the first procedure because of dense adhesions and because the liver parenchyma may be more fibrotic or friable.

3. Non-colorectal liver metastases

Pancreas, breast, ovary, rectum and stomach are the following sources of liver metastasis after those of colonic origin in decreasing order of frequency [102]. Liver metastases from colorectal cancer have a less aggressive clinical and biological behavior than those from others solid tumours, like breast or lung, in which the liver is another site of systemic disease [103].

3.1. Liver metastases for neuroendocrine tumours

Gastrointestinal neuroendocrine tumours (NETs) are a diverse group of tumours that originate throughout the gastrointestinal tract and are characterized by a relative slow growth rate and the potential to produce and secrete a variety of hormones. NETs can be classified into carcinoid and pancreatic histological subtypes. NETs of pancreatic origin can be non-functioning or can produce hormonally active substances: insulin, gastrin, vasoactive intestinal peptide. Carcinoid tumours arise commonly in the midgut and may secrete serotonin and other bioactive amines.

Most of NETs will have disseminated disease at the time of diagnosis, with a 5-year survival between 50% and 80%. The liver is the most common organ involved, followed by bone and lung [104]. Almost 10% of all liver metastases are neuroendocrine in origin. The presence of liver metastases of NETs (LMNETs) is a distinguishing feature of malignant neuroendocrine tumours and is the rate-limiting step for patient's survival [105]. LMNETs occur in 50% to 75% of small-bowel carcinoids, in 5% to 70% of foregut carcinoids and about 14% of hindgut carcinoids. Furthermore, in many patients the liver remains the only site of metastatic disease for a prolonged period of time. Usually LMNETs are multifocal, bilobar and in more than half of the cases involve more than 50% of the liver parenchyma [106]. In spite of it, Hodul et al concluded that hepatic resection resulted in an almost double 5-year survival rate compared with the non-resected group (47-82% vs. 30-40%, respectively) [107].

Management of LMNETs is challenging, since there is not a firm consensus on the optimal treatment strategy, except the Steimüller's guidelines [108,109] (Table 1).

Several studies have shown 5-year survival rates of up to 85% in R0 resection for both primary and secondary sites (Table 2). Cytoreduction is useful as a palliative approach but it needs to reach at least 90% of tumour volume reduction to improve both survival and symptoms [110].

Table 2: Liver resection for neuroendocrine liver metastases

1. LMNET without extrahepatic disease:

- a Preferred treatment: surgical resection of both primary and all liver metastasis ± local ablative techniques (may be one or two-step procedure)
- b Treatment if unresectable disease or poor surgical candidate: continued biotherapy, hepatic artery chemoembolization (TACE) or embolization and RFA
- c Liver transplantation considered in rare cases (less than 1%)

2. LMNET with extrahepatic disease:

- a Preferred treatment: biotherapy or other systemic nonsurgical treatment
- b Palliative treatment if symptoms progress:
 - If small number of isolated liver metastases less than 3-4 cm: RFA, TACE or embolization; may consider minor or anatomic resection in selected cases
 - If complex pattern or liver metastases: RFA, or embolization; may consider major liver resection together with RFA for selected cases
 - If diffuse pattern of liver metastases: TACE or embolization

Table 1. Consensus guidelines for the treatment of liver metastases from endocrine tumours:

Authors	Year	# of patients	Resolution of symptoms (%)	Survival (%)
Sarmiento et al [110]	2003	170	96	75 at 3 years; 61 at 5 years
Knox et al [111]	2003	13	82	85 at 5 years
Touzios et al [106]	2005	19	95	72 at 5 years
Musunuru et [112]	2006	13	100	83 at 3 years

Table 2. Liver resection for neuroendocrine liver metastases

After surgery, the normalization of tumour markers, 5-hydroxyindoleacetic acid (5-HIAA) and chromogranin A predict a complete resection. This last marker is more sensitive than 5-HIAA to diagnose progression or recurrence.

RFA has been used as the sole method to achieve relief of symptoms and local control. Although this goal is attained in 60% to 80% of cases of LMNETs, a sustained response rate is low.

TACE is contraindicated when the tumour size exceeds 50% of the liver due to the risk of liver failure. The duration of response is short and here is also a risk of causing carcinoid tumour lysis syndrome or crises.

Several authors advocate liver and multivisceral transplant in unresectable LMNETs, but the role of liver transplantation in patients with LMNETs remains controversial, especially given the shortage of donors. Less than 1% of all liver transplants have been performed for LMNETs and, outside of a few small studies, survival does not seem to have improved. Frilling et al

suggested a set of criteria for transplantation of patients with LMNETs: age younger than 65, primary tumour under control, absence of extrahepatic disease proven over a 6-month period, progression of liver tumours and excessive hormonal symptoms refractory to medical therapy [113].

An aggressive surgical approach using multi-modality therapy (resection, embolization and RFA) leads to long-term survival in these patients. Although long-term cure can only be achieved in a small proportion of patients with malignant NETs, significant long-term palliation can be achieved. This aggressive surgical approach can be recommended, keeping in mind that additional liver-directed procedures may be required or combined with surgery to achieve effectiveness for a good quality of life.

3.2. Non-colorectal non-neuroendocrine liver metastases

Despite the established agreement on the advantage of liver resection for metastatic colorectal and neuroendocrine tumours, the role of hepatic surgery in patients with liver metastases from non-colorectal non-neuroendocrine (NCRNNE) carcinoma is not well defined. However, the results reported in a number of recent studies support a developing trend toward surgery in this setting.

There are many reasons for this lack of clear-sightedness. Because of these ununiformed characteristics, the conclusions are that prognostic factors for liver metastases from NCRNNE remain uncertain. These is due to many reports include neuroendocrine tumour patients in their analysis and consequently alter survival data. In fact, most series are not comparable in terms of mid- and long-term (tumour-free) survival, as they include patients with NCRNNE hepatic metastases from different primary malignancies, different frequency of isolated hepatic metastases and different tumoural behaviour, different sensitivity to chemotherapy and different length of disease-free interval between the resection of the primary tumour and the diagnosis of the liver metastases. In addition, to influence the variability of the series, many studies include recruitment periods of 10 years or more so the chemotherapy regime has been changed a lot and the results should be taken with caution.

In recent years, despite the poor results, liver resection for metastases suitable for surgery have been carried out. The main reasons for this attitude have been above-mentioned. Also, there are no data that actually suggest the usefulness of alternative treatments for NCRNNE liver metastases, so this reinforces the role of surgery.

The aggressive policy used by some surgeons and oncologists, in relation to metastases confined to the liver, should be moderated considering generic variables, such as disease-free interval from the primary tumour. Twelve months is considered as the generic minimum period between primary tumour and secondary disease to give an indication for surgery for liver metastases. After this first year, any further time interval should be considered as a progressively increasing positive prognostic factor. A longer disease-free interval is believed to indicate less aggressive tumour biology or less account of tumoural stem-cells [103]. In a retrospective study of 1452 patients treated at 41 centres, Adam et al demonstrated that liver resection for NCRNNE hepatic metastases is safe and effective (Table 3). The authors catego-

rized the outcome according to the primary tumour and the 5-year survival after liver resection into: favorable (adrenal, testicular, ovarian, small bowel, ampullary, breast, renal, and uterine tumours); intermediate (gastric adenocarcinoma, exocrine pancreas, cutaneous melanoma, choroidal melanoma, and duodenal tumours); and poor (gastroesophageal junction, pulmonary, esophageal, and head and neck tumours) [114].

Author	Years	# of patients	5 years survival
Harrison LE 1997 [116]	1980-1995	96	37%
Hemming AW 2000 [117]	1978-1998	37	45%
Laurent C 2001 [118]	1980-1997	39	35%
Yamada H 2001 [119]	1990-1995	33	12.1%
Takada Y 2001 [120]	1987-1999	14	NR
Karavias DD 2002 [121]	1994-2001	18	NR
Weitz J 2005 [122]	1981-2002	141	57%*
Ercolani G 2005 [123]	NS	142	34.3%
Adam R 2006 [114]	1983-2004	1452	36%

Table 3. Studies with NCRNNE liver metastases resection

The role of liver resection for NCRNNE liver metastases is still a matter of discussion because only small studies have been carried out in this field and the conclusive outcomes are collective and not specific for each type of tumour. In a comparative analysis, Reddy et al studied the results of liver resection for metastatic tumours in 360 consecutive patients (245 colorectal and 33 neuroendocrine versus 82 NCRNNE primaries). There were no difference in median overall survival between patients with metastases from colorectal and noncolorectal disease. The long-term outcome after resection of NCRNNE was nearly equivalent to that of colorectal tumours [115].

3.2.1. Gastrointestinal stromal tumours liver metastases

Gastrointestinal stromal tumours (GIST) are the most common mesenchymal neoplasms of the gastrointestinal tract and account for 1%-3% of all gastrointestinal malignancies [124]. It is thought that these tumours differentiate from intestinal pacemaker cells, also known as interstitial cells of Cajal [125,126]. They affect mostly males between the ages of 50 and 70, and are usually found incidentally at early stages. Large or advanced lesions may present with a variety of clinical findings, including bleeding, abdominal pain, early satiety, bowel obstruction or perforation.

The only definitive treatment for GIST is surgical resection. These tumours demonstrate a broad spectrum of biological behaviours, from indolent to rapidly progressive malignancies [127]. The liver is known to be a common metastatic site for GIST and previous studies have

reported that 55%-72% of patients develop hepatic metastasis following complete resection of the primary tumour [128]. Previously described treatment modalities for hepatic metastases from GIST include anthracycline and ifosfamide-based chemotherapy regimes, TACE, surgical resection and hepatic transplantation. However, high recurrence rates and poor survival outcomes following hepatic transplantation have been reported. Radical surgical resection, including hepatectomy, is the only potential treatment modality for this clinical condition. Liver resection itself has been shown to prolong survival; this seems especially true for patients with small metastasis and a long disease-free interval. A time to metastasis of 2 years has actually been an independent predictor of outcome in a large group of patients with a median survival of 61 months [129].

Imatinib mesylate (Glivec®), a selective inhibitor of tyrosine kinase, has revolutionized the management of this disease in recent years. Imatinib has a significant shrinking effect on GIST and can be used when primary GIST have attained a very large size or are in unfavorable locations, increasing the risk of positive resection margins [125]. Imatinib has also become the first line of treatment for recurrent and/or metastatic GIST. Before the advent of tyrosine kinase inhibitors (TKIs), surgical resection was the primary treatment for hepatic gastrointestinal stromal tumour (GIST) metastases. Although TKIs have improved survival in the metastatic setting, outcomes after multimodal therapy comprised of hepatectomy and TKIs for GIST are unknown. A recent report concludes that combination therapy for GIST liver metastases comprised of surgical resection and TKIs therapy is more effective than surgery or TKIs therapy alone [130]. There are significant prognostic implications in GIST cases with hepatic metastasis. Recent studies have shown an overall median survival time of 39 (33-40) months following surgery. Resection of GIST liver metastases may be curative when the primary disease has been eradicated and negative surgical resection margins are attained (Table 4).

Author	Years	# of patients	Median survival (months)	Recurrence (months)
Ng [131]	1957-1987	5	33	Not recorded
Chen et al. [132]	1984-1995	6	39	3 (50%)
Lang et al. [133]	1983-1996	18	40	9 (60%)
DeMatteo et al. [128]	1982-1998	56	39	47 (84%)
[134].	1989-2001	10	39	7 (70%)
[135]	1984-2003	18	36	14 (77%)
Gomez et al. [127]	1993- 2005	12	43	8 (73%)

Table 4. Surgical resection for hepatic metastases from GIST, sarcomas and leiomyosarcomas

Surgical resection with curative intent for hepatic metastases from GIST should be considered when feasible, as it may improve survival outcomes in selected patients. Recurrence of disease can be managed with further surgery, RFA, imatinib mesylate therapy or a combination of these treatment modalities.

3.2.2. Liver Metastases from Breast Cancer (LMBC)

Patients with visceral metastases from breast cancer have an unlucky prognosis. Liver metastases are infrequent as the sole site of systemic disease and even rarer as a solitary metastasis. Only 3% to 11% of the patients have the liver as the single involved organ out of 65% of breast cancer patients with liver metastases as part of the disseminated disease [136]. Although systemic treatment can achieve response in around 60% of patients, long-term survival is unusual, varying from 1 to 15 months [137]. Moreover, around 70% of these liver metastases are negative for hormonal receptors so that chemotherapy is usually the only treatment.

Extrahepatic disease has been considered as a contraindication for liver resection in these patients, but some reports have not found differences in survival between operated patients with or without extrahepatic breast cancer metastases, bearing in mind that most of these extrahepatic lesions were bone metastases treated with chemotherapy and radiotherapy previously to surgery [138]. This retrospective study of 454 patients operated on for metastatic breast cancer reported that 41 and 21% of these patients remain alive at 5 and 10 years, respectively.

Few series of liver resection have been published [139,140], describing around 250 patients operated in a few highly specialized centers (Table 5).

Autor	N	Solitary Metastasis	5 years Survival Rate	Pronostic factors
Sakamoto et al (2005) [141]	34	19/34	21	extrahepatic diseases
Carlini et al (2002) [142]	17	15/17	46	
Yoshimoto et al (2000)[143]	25	14/25	27	"/> 1 year
Selzner et al (2000) [144]	17		22	"/> 4 years
Pocard et al (2001)[145]	65	44/65	46	N0
Seifert et al (1999)[136]	15		53(3 years)	R0
Raab et al (1996)[146]	34	21/35	18	Local Recurrence
Scheuerlein et al (1998)[147]	21	9 of 21	60(2 years)	R0

Table 5. Liver resection from breast cancer

These differences among series in outcome following hepatic resection may merely reflect difference in selection criteria and in tumour biology. Resection criteria for liver metastases from breast cancer are not yet clearly defined and a number of questions remain to be answered: Must hepatectomy be done in patients with extrahepatic disease? Which chemotherapy regimens must be given before and after surgery? Which is the best timing for liver surgery?

Eighty percent of the liver metastases were due to primary tumours less than 5 cm in size and the number of patients with a solitary metastasis varied from 41% to 79%. The lapse of time between breast surgery and diagnosis of the liver lesions was 21 to 60 months [140,145].

Response to chemotherapy appears to be an important predictor of survival following hepatic resection for liver metastases from breast cancer. In the Adam paper, patients who remained stable or progressed on prehepatectomy chemotherapy were 3.5 times more likely to die than responders. Indeed, preoperative chemotherapy is a modality to prolong survival and the response can be considered as a selection criteria.

Two prognostic factors have been identified by several authors [145]: prolonged tumour-free interval (1-2 years) between breast cancer surgery and liver metastases diagnosis and no lymph node involvement at the time of breast cancer. Liver surgery should be offered to every patient with a good performance status, with predictable R0 resection and with a long disease-free interval (Figure 2).

In synchronous tumours, disease must be stabilized with chemotherapy. To consider surgery, there should not be extrahepatic disease or it must be a solitary bone metastasis. Surgery can be technically hampered because of the effects of chemotherapy on liver parenchyma. Hillar lymphadenectomy can be considered since positive lymph nodes are frequent, although they do not exclude resection.

Liver recurrence is very high but the best chemotherapy regimen in these cases is to be defined. Survival after resection is longer compared with other treatments, although disease-free time is usually brief.

Other studies suggest that liver resection in highly selected patients may function as a cytoreductive rather than a curative procedure, because breast liver metastases is considered as a disseminated disease, but as a cytoreductive approach it improves the survival rate.

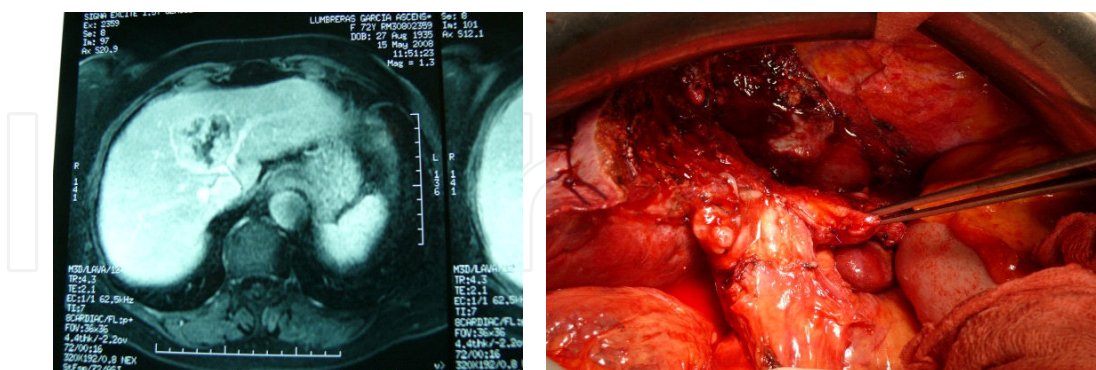


Figure 2. years old woman with alone liver metastases that involved two hepatic veins. We removed Sg 2,3,4,5,and 8. She is disease-free 5 years after liver resection.

3.2.3. Liver metastases from melanoma

Up to 30% of patients with melanoma develop distant metastases. After the lungs and brain, the liver is the third most involved organ. Previously considered an infrequent condition,

autopsy studies have shown liver metastases in 55%-75% of the patients with melanoma [148,149]. Diagnosis is generally made by imaging studies during follow-up, since symptoms are suggestive of advanced disease. FDG PET/CT shows a sensitivity of 85%, a specificity of 100% and a positive predictive value of 98% [150]. Median survival in these patients ranges between 2 and 6 months [151]. Palliative radiotherapy and systemic chemotherapy do not prolong survival and, although interferon- α and interleukin-2 have yielded promising response rates, these are rarely durable [152].

Liver resection achieves 5-year survival rate between 5% and 25% [153] (Table 6). A reduction in immunosuppressive factors and a slowing of the growth of occult metastases have been proposed as part of the beneficial effects of surgery [154]. A large series reports a 21% 5-year survival rate for 104 patients after resection of liver metastases from melanoma of choroidal origin and a 22% 5-year survival rate for 44 patients with the same condition but with a cutaneous source [114]. The same paper confirmed that choroid melanomas were commonly associated with multiple intrahepatic tumours but were less likely than cutaneous melanomas to be associated with extrahepatic disease. A series collected from four centres showed that the location of the primary tumour substantially impacts on the recurrence and survival after resection of secondary liver tumours. Among 40 patients who underwent liver resection, the rate of recurrent hepatic metastases was higher among patients with ocular (53.3%) compared to those with cutaneous tumours (17.4%) [148].

Authors	Year	n	5-year survival (%)	Median survival (months)
Ripley et al. [155]	2010	35	53	-
Rose et al. [149]	2001	24	29	28
Pawlik et al. [148]	2006	24	47.2(2years)	23.6
Chua et al. [153]	2010	13	40 (3years)	21
Herman et al. [156]	2007	10	-	22
Crook et al. [157]	2006	5	-	-

Table 6. Liver resection in melanoma

Positive prognostic factors are a R0 resection, a solitary metastasis and absence of extrahepatic disease [155]. Resection with negative margins offers the only chance of long-term survival, since for R1 and R2 resection there are not periods of survival longer than 6 months.

For all the authors, liver resection must not be considered as a curative treatment but as a part of the whole oncologic treatment because of its cytoreductive nature. Reported series during the last decade show that liver resection of metastases from melanoma are infrequent, that the interval between treatment of primary and secondary tumour is long (49 to 96 months), that mayor hepatectomies are performed in 50% to 60% of the patients and that survival varies widely (0% to 53%), which indicates that this is a very heterogeneous group of patients with a very variable criteria for resection.

3.2.4. Liver metastases from gastric cancer and others non-colorectal gastrointestinal adenocarcinoma

Many reports defend liver resection for metastatic gastric cancer although the indications for resection have not been established. Frequently, liver metastases suggest an advance disease with a mean survival of less than 6 month. Last studies showed increased survival benefit with 5-year survivors between 20%-42%.

Positive pronostic factors have been indentified: solitary tumour or no more than 3 nodules, size less than 5 cm, unilobular distribution, resection margin more than 10 mm and disease-free interval between gastric cancer resection and liver metastases longer than 1 year [158]. In a study by Thelen the multivariate analysis revealed only resection margin as an independent prognostic factor for survival [159]. Shirabe concluded that synchronous hepatectomy should not be a contraindication for hepatic resection [160] (Table 7).

Authors	Year	n	5-year survival (%)
Ambiru et al. [161]	2001	40	15
Zacherl et al. [162]	2002	15	0
Saiura et al. [163]	2002	10	20
Okano et al. [164]	2002	19	21
Shirabe et al. [160]	2003	36	11
Sakamoto et al. [158]	2003	26	4
Roh et al. [165]	2005	11	18
Summary		157	12,1

Table 7. long-term of liver resection in gastric cancer

In conclusion, the results of liver resection in liver gastric metastases should not be dismissed simply because there is not prospective, randomized data. For patients with hepatic disease amenable to surgical resection, treatment alternatives include systemic chemotherapy, locoregional ablative therapies with or without systemic treatment or surgical resection with or without systemic treatment. It is not unreasonable to consider liver resections in highly selected patients as part of multidisciplinary care for this malignancy.

For other non-colorectal gastrointestinal adenocarcinoma the available evidence for hepatectomy is extremely limited, and this treatment strategy lacks utility. Most authors, despite having performed hepatectomies for these metastatic tumours, agree that it is associated with a poor prognosis.

3.2.5. Liver metastases from lung cancer

We can re-emphasize that the refinements in perioperative care and surgical techniques have significantly improved the safety of liver surgery, and operative mortality has decreased to around 1% in tertiary referring centres. For this, in the last 10 years liver resection has been

proposed not only for colorectal and neuroendocrine metastases, but also for metastatic tumour from other sites such as lung cancer.

Liver resection for lung cancer metastases are rare and few number of cases are reported in the literature. The reported cases appear frequently with other kind of metastatic liver tumour in more large series. Lindlell et al., in the largest serie, reported three cases but did not show the outcome [166]. Di Carlo reported a case of long-term survival [167].

In summary, when a patient has one or two liver nodules with more than one year of disease-free interval from the resection of primary tumour, hepatic resection can be a therapeutic option [168]. Liver involvement is managed surgically only under these exceptional circumstances.

3.2.6. Liver metastases from ovarian and testicular cancer

Epithelial ovarian cancer is a highly chemosensitive disease, and platinum-based therapies bring about significant diminution of tumour volume in most of the patients. Regrettably, the patients develop resistance to platinum chemotherapy after 24-36 months. Notwithstanding, many centres, despite stage III-IV advanced ovarian cancer, with a median survival of 3.5 years, propose very aggressive management with surgical debulking [169]. Five-years disease-specific survival after hepatic resection in patients with hepatic metastases from NCRNNE carcinoma is comparable to the 5-year survival of patients after hepatic resection for colorectal cancer, ranging from 9% to 38%, depending on the type of primary tumour. For this, multiple studies have shown an important survival benefit when primary cytoreductive surgery precedes the initiation of chemotherapy for advanced ovarian cancer. The benefits of cytoreductive surgery are also obvious in patients with recurrent disease. More than 70% of patients with advanced stage disease suffer recurrence and the benefits of second debulking depend on chemosensitivity, feasibility of surgery and tumour behaviour.

The liver is rarely the only site of metastatic ovarian cancer but also hepatectomy can be important in a cytoreduction approach. Ovarian cancer can involve the liver through peritoneal lesions on the surface or with intraparenchymal metastases [170]. Survival is clearly improved for stage IV disease patients with complete and adequate debulking, even hepatectomy.

In conclusion, hepatic metastases should not preclude attempts at optimal secondary cytoreductive surgery. When cytoreductive resection is performed by pelvic and hepatobiliary surgeons, morbidity and mortality appear no different from that attributed to aggressive surgical debulking itself.

Metastasectomy is wel established in the management of disseminated non-seminomatous germ cell testicular carcinoma that does not completely respond to chemotherapy. Testicular cancer has often been described as 'the model of a curable cancer'. Previously to the mid-1970s treatment cured less than 5% of patients; by 1984, the cure rate for testicular cancer was higher 80% and experimental protocols began to focus on the refractory cases or 'poor risk' patients. The key to success in the treatment of metastatic germ cell tumours is due to the multidisciplinary approach. Although after chemotherapy it can be difficult to differentiate active

residual tumour from necrosis or fibrosis, the probability of achieving cure by surgical resection is high. For these reasons, lymphadenectomy and visceral resection are recommended if there is imaging evidence of residual disease [171]. In some cases complete excision requires multivisceral radical resections as a last attempt to cure patients who have exhausted all other therapeutic options. Complete surgical resection of all measurable disease is the gold standard and correlates with improvement in both relapse-free and overall survival after hepatectomy, with actuarial survival rates of 78% at 3 years in these tumours.

3.2.7. Renal cell carcinoma and urothelial cancer

The available data on hepatic resection for renal cell cancer (RCC) metastases and urothelial cancer (UC) are limited to case reports. In metastatic RCC, the liver involvement is present in 20% of the patients and carries less than 10% of overall 1-year survival rate. Furthermore, only 5% of metastatic RCC patients have the liver as only involved organ. However, five-year survival of 33% has been reported following resection of lung, brain or lymph node metastases in association with chemotherapy in UC. Furthermore, metastasectomy has been used for palliation with good results [171]. However Alves et al. reported 46 liver resection for metastatic RCC patients with a 5-year survival of 13% [172].

These limited data determine inconsistent recommendations for hepatectomy in metastatic RCC and UC. In RCC, the use of sunitinib or sorafenib as neoadjuvant or post-hepatectomy therapy could improve the outcome.

Author details

Alejandro Serrablo^{1*}, Luis Tejedor² and Jose-Manuel Ramia³

*Address all correspondence to: almaley@telefonica.net

1 Hepatopancreatic biliary Surgical Unit, Miguel Servet University Hospital, Zaragoza, Spain

2 General Surgery Service, Punta de Europa Hospital, Algeciras, Spain

3 Hepatopancreatic biliary Surgical Unit, Guadalajara University Hospital, Guadalajara, Spain

References

- [1] Hugh, T. J, Ghaneh, P, & Poston, G. J. Hepatic metastases. In: Garden OJ (ed.) Hepatobiliary and Pancreatic Surgery. Philadelphia: Elsevier Saunders; (2005). , 97-130.

- [2] Fong, Y, Fortner, J, Sun, R. L, Brennan, M. F, & Blumgart, L. H. Clinical score for predicting recurrence after hepatic resection metastatic colorectal cancer: analysis of 1001 consecutive cases. *Ann Surg* (1999). , 230, 309-18.
- [3] Nordlinger, B, Guiguet, M, Vaillant, J. C, Balladur, P, Boudjema, K, & Bachellier, P. Surgical resection of colorectal carcinoma metastases to the liver. A prognostic scoring system to improve case selection, based on 1568 patients. *Cancer* (1996). , 77, 1254-62.
- [4] Rees, M, Tekkis, P. P, Welsh, F. K, Rourke, O, & John, T. TG. Evaluation of long-term survival after hepatic resection for metastatic colorectal cancer: a multifactorial model of 929 patients. *Ann Surg* (2008). , 247, 125-35.
- [5] Zakaria, S, Donohue, J. H, Que, F. G, Farnell, M. B, Schleck, C. D, Ilstrup, D. M, & Nagorney, D. M. Hepatic resection for colorectal metastases: value for risk scoring systems? *Ann Surg* (2007). , 246, 183-91.
- [6] Iwatsuki, S, Dvorchik, I, Madariaga, J. R, Marsh, J. W, Dodson, F, Bonham, A. C, Geller, D. A, Gayowsky, T. J, Fung, J. J, & Starzl, T. E. Hepatic resection for metastatic colorectal adenocarcinoma: a proposal of a prognostic scoring system. *J Am Coll Surg* (1999). , 189, 291-9.
- [7] Adam, R, Wicherts, D. A, De Haas, R. J, et al. Patients with initially unresectable colorectal liver metastases: is there a possibility of cure? *J Clin Oncol* (2009). , 27, 1829-35.
- [8] El Khodary, M, Milot, L, & Reinhold, C. Imaging of Hepatic Metastases. In: Brodt P (ed.) *Liver Metastasis: Biology and Clinical Management*. New York: Springer Science+Business Media B.978-9-40070-291-2, 2011, 307-353.
- [9] Kinkel, K, Lu, Y, Both, M, Warren, R. S, & Thoeni, R. F. (2002). Detection of hepatic metastases from cancers of the gastrointestinal tract by using noninvasive imaging methods (US, CT, MR Imaging, PET): a meta-analysis. *Radiology* 2002;; 224, 748-56.
- [10] Chami, L, Lassau, N, Malka, D, Ducreux, M, Bidault, S, Roche, A, & Elias, D. Benefits of Contrast-Enhanced Sonography for the Detection of Liver Lesions: Comparison with Histologic Findings. *AJR* (2008). , 190, 683-90.
- [11] Larsen LPS Role of contrast enhanced ultrasonography in the assessment of hepatic metastases: A review. *World J Hepatol* (2012). , 2(1), 8-15.
- [12] Guglielmi, A, Pachera, S, & Ruzzenente, A. Surgical Therapy of Hepatic Metastases. In: Delaini GG (ed.) *Rectal Cancer: New Frontiers in Diagnosis, Treatment and Rehabilitation*. Milan: Springer-Verlag; (2005). , 227-241.
- [13] Laghi, A, Sansoni, I, Celestre, M, Paolantonio, P, & Passariello, R. Computed Tomography. In: Lencioni R, Cioni D, Bartolozzi C (eds.) *Focal Liver Lesions Detection, Characterization, Ablation*. Berlin Heidelberg: Springer-Verlag; (2005). , 17-32.

- [14] Yang, S, Ho, S, Hanna, S. S, Gallinger, S, Wei, A. C, Kiss, A, & Law, C. Utility of pre-operative imaging in evaluating colorectal liver metastases declines over time. *HPB* (2010). , 12(9), 605-9.
- [15] Bluemke, D. A, Paulson, E. K, Choti, M. A, Desena, S, & Clavien, P. A. Detection of Hepatic Lesions in Candidates for Surgery: Comparison of Ferumoxides-Enhanced MR Imaging and Dual-Phase Helical CT. *AJR* (2000). , 175, 1653-58.
- [16] Vidiri, A, Carpanese, L, Annibale, D, Caterino, M, Cosimelli, M, Zeuli, M, David, M, & Crecco, V. M. Evaluation of Hepatic Metastases from Colorectal Carcinoma with MR-Superparamagnetic Iron Oxide. *J Exp Clin Cancer Res* (2004). , 23(1), 53-60.
- [17] Koh, D. M, Scurr, E, Collins, D. J, Pirgon, A, Kanber, B, Karanjia, N, Brown, G, Leach, M. O, & Husband, J. E. Colorectal hepatic metastases: quantitative measurements using single-shot echo-planar diffusion-weighted MR imaging. *Eur Radiol* (2006). , 16, 1898-905.
- [18] Koike, N, Cho, A, Nasu, K, Seto, K, Nagaya, S, Ohshima, Y, & Ohkohchi, N. Role of diffusion-weighted magnetic resonance imaging in the differential diagnosis of focal hepatic lesions. *World J Gastroenterol* (2009). , 15(46), 5805-12.
- [19] Udayasankar, U, Chamsuddin, A, Mittal, P, & Small, W. C. Diagnostic imaging and image-guided interventions of hepatobiliary malignancies. In: Blake MA, Kalra MK (eds.) *Imaging in Oncology*. New York: Springer Science+Business Media, LLC; (2008). , 199-228.
- [20] Valls, C, Martinez, L, Ruiz, S, & Alba, E. Radiological imaging of liver metastases. In: Vauthey JN, Hoff PMG, Audisio RA, Poston GJ (eds.) *Liver metastases*. London: Springer-Verlag; (2009). , 1-13.
- [21] Bipat, S, Van Leeuwen, M. S, Comans, E. F, Pijl, M. E, Bossuyt, P. M, Zwinderman, A. H, & Stoker, J. Colorectal liver metastases: CT, MR imaging, and PET for diagnosis-metaanalysis. *Radiology* (2005). , 237, 123-31.
- [22] Wiering, B, Krabbe PFM, Jager GJ, Oyen WJG, Ruers TJF. The Impact of Fluor-18-Deoxyglucose-Positron Emission Tomography in the Management of Colorectal Liver Metastases: A Systematic Review and Metaanalysis. *Cancer* (2005). , 104(12), 2658-70.
- [23] Patel, S, McCall, M, Ohinmaa, A, Bigam, D, & Dryden, D. M. Positron emission tomography/computed tomographic scans compared to computed tomographic scans for detecting colorectal liver metastases: a systematic review. *Ann Surg* (2011). , 253(4), 666-71.
- [24] Niekel, M. C. Bipat Sh, Stoker J. Diagnostic Imaging of Colorectal Liver Metastases with CT, MR Imaging, FDG PET, and/or FDG PET/CT: A Meta-Analysis of Prospective Studies Including Patients Who Have Not Previously Undergone Treatment. *Radiology* (2010). , 257(3), 674-84.
- [25] Sørensen, M, Mortensen, F. V, Høyer, M, Vilstrup, H, & Keiding, S. and The Liver Tumour Board at Aarhus University Hospital. FDG-PET improves management of

- patients with colorectal liver metastases allocated for local treatment: a consecutive prospective study. *Scand J Surg* (2007). , 96, 209-13.
- [26] Pawlik, T, Assumpcao, L, Vossen, J, Buijs, M, Gleisner, A, Schulick, R, & Choti, M. Trends in nontherapeutic laparotomy rates in patients undergoing surgical therapy for hepatic colorectal metastases. *Ann Surg Oncol* (2009). , 16(2), 371-78.
- [27] Fernandez, F. G, Drebin, J. A, Linehan, D. C, Dehdashti, F, Siegel, B. A, & Strasberg, S. M. Fiveyear survival after resection of hepatic metastases from colorectal cancer in patients screened by positron emission tomography with F-18 fluorodeoxyglucose (FDGPET). *Ann Surg* (2004). , 240(3), 438-50.
- [28] Fioole, B, De Haas, R. J, Wicherts, D. A, Elias, S. G, Scheffers, J. M, Van Hillegersberg, R, & Van Leeuwen, M. S. Borel Rinkes IH. Additional value of contrast enhanced intraoperative ultrasound for colorectal liver metastases. *Eur J Radiol* (2008). , 67(1), 169-76.
- [29] Leen, E, Ceccotti, P, Moug, S. J, & Glen, P. MacQuarrie J, Angerson WJ, Albrecht T, Hohmann J, Oldenburg A, Ritz JP, Horgan PG. Potential value of contrast-enhanced intraoperative ultrasonography during partial hepatectomy for metastases: an essential investigation before resection? *Ann Surg* (2006). , 243, 236-40.
- [30] Nakano, H, Ishida, Y, Hatakeyama, T, Sakuraba, K, Hayashi, M, Sakurai, O, & Hataya, K. Contrast-enhanced intraoperative ultrasonography equipped with late Kupffer-phase image obtained by sonazoid in patients with colorectal liver metastases. *World J Gastroenterol* (2008). , 14(20), 3207-11.
- [31] Torzilli, G. Del Fabbro D, Palmisano A, Donadon M, Bianchi P, Roncalli M, Balzarini L, Montorsi M. Contrast-enhanced intraoperative ultrasonography during hepatectomies for colorectal cancer liver metastases. *J Gastrointest Surg* (2005). , 9, 1148-53.
- [32] Bipat, S, & Van Leeuwen, M. S. IJzermans JNM, Comans EFI, Planting AST, Bossuyt PMM, Greve J-W, Stoker J. Evidence-based guideline on management of colorectal liver metastases in the Netherlands. *Ned J Med* (2007). , 63(1), 1-14.
- [33] Doan, P. L, Vauthey, J. N, Palavecino, M, & Morse, M. A. Colorectal Liver Metastases. In: Clavien PA, Breitenstein S (eds.) *Malignant Liver Tumours. Current and Emerging Therapies*. Oxford: Wiley-Blackwell; (2012). , 342-346.
- [34] Vauthey, J. N. The AHPBA (2006). Consensus Conference: Focus on Improving Resectability in Patients With Hepatic Colorectal Metastases. *Medscape Oncology* 2006. <http://www.medscape.org/viewarticle/524135> accessed 27 August 2012)
- [35] Foster, J. H. Survival after liver resection for secondary tumours. *Am J Surg* (1978). , 135, 389-94.
- [36] Kopetz, S, Chang, G. J, Overman, M. J, Eng, C, Sargent, D. J, Larson, D. W, Grothey, A, Vauthey, J. N, Nagorney, D. M, & McWilliams, R. R. Improved survival in meta-

- static colorectal cancer is associated with adoption of hepatic resection and improved chemotherapy. *J Clin Oncol* (2009). , 27, 3677-83.
- [37] Altendorf-hofmann, A, & Scheele, J. A critical review of the major indicators of prognosis after resection of hepatic metastases from colorectal carcinoma. *Surg Oncol Clin N Am* (2003). , 12, 165-92.
- [38] Figueras, J, Burdio, F, Ramos, E, Torras, J, Llado, L, Lopez-ben, S, Codina-barreras, A, & Mojal, S. Effect of subcentimeter nonpositive resection margin on hepatic recurrence in patients undergoing hepatectomy for colorectal liver metastases. Evidences from 663 liver resections. *Annals of Oncology* (2007). , 18, 1190-95.
- [39] Lordan, J. T, & Karanjia, N. D. Size of surgical margin does not influence recurrence rates after curative liver resection for colorectal cancer liver metastases. *Br J Surg* (2007). , 94, 1133-8.
- [40] Poultsides, G. A, Schulick, R. D, & Pawlik, T. M. Hepatic resection for colorectal metastases: the impact of surgical margin status on outcome. *HPB* (2010). , 12, 43-9.
- [41] Elias, D, Liberale, G, Vernerey, D, Pocard, M, Ducreux, M, Boige, V, Malka, D, Pignon, J. P, & Lasser, P. Hepatic and extrahepatic colorectal metastases: when resectable, their localization does not matter, but their total number has a prognostic effect. *Ann Surg Oncol* (2005). , 12, 900-9.
- [42] Elias, D, Ouellet, J. F, & Bellon, N. Extrahepatic disease does not contraindicate hepatectomy for colorectal liver metastases. *Br J Surg* (2003). , 90, 567-74.
- [43] Khatri, V. P, Petrelli, N. J, & Belghiti, J. Extending the frontiers of surgical therapy for hepatic colorectal metastases: is there a limit? *J Clin Oncol* (2005). , 23, 8490-9.
- [44] Minagawa, M, Makuuchi, M, Torzilli, G, Takayama, T, Kawasaki, S, Kosuge, T, Yamamoto, J, & Imamura, H. Extension of the frontiers of surgical indications in the treatment of liver metastases from colorectal cancer: long-term results. *Ann Surg* (2000). , 231, 487-99.
- [45] Kanemitsu, Y, Kato, T, Hirai, T, & Yasui, K. Preoperative probability model for predicting overall survival after resection of pulmonary metastases from colorectal cancer. *Br J Surg* (2004). , 91, 112-20.
- [46] Vauthey, J. N. Colorectal Liver Metastases: Treat Effectively Up Front and Consider the Borderline Resectable. *J Clin Oncol* (2007). , 25(29), 4524-5.
- [47] Adam, R, De Haas, R. J, Wicherts, D. A, Aloia, T. A, Delvart, V, Azoulay, D, Bismuth, H, & Castaing, D. Is hepatic resection justified after chemotherapy in patients with colorectal liver metastases and lymph node involvement? *J Clin Oncol* (2008). , 26(22), 3672-80.

- [48] Jaeck, D. The significance of hepatic pedicle lymph nodes metastases in surgical management of colorectal liver metastases and of other liver malignancies. *Ann Surg Oncol* (2003). , 10, 1007-11.
- [49] Lehmann, K, & Rickenbacher, A. AWeber, Pestalozzi BC, Clavien PA. Chemotherapy Before Liver Resection of Colorectal Metastases: Friend or Foe? *Ann Surg* (2012). , 255(2), 237-47.
- [50] Nondlinger, B, Sorbye, H, Glimelius, B, Poston, G. J, Schlag, P. M, Rougier, P, Bechstein, W. O, Primrose, J. N, Walpole, E. T, Finch-jones, M, Jaeck, D, Mirza, D, Parks, R. W, Collette, L, Praet, M, Bethe, U, Van Cutsem, E, Scheithauer, W, & Gruenberger, T. Perioperative chemotherapy with FOLFOX4 and surgery versus surgery alone for resectable liver metastases from colorectal cancer (EORTC Intergroup trial 40983): a randomised controlled trial. *Lancet* (2008). , 371, 1007-16.
- [51] Kooby, D. A, Stockman, J, Ben-porat, L, Gonen, M, Jarnagin, W. R, Dematteo, R. P, Tuorto, S, Wuest, D, Blumgart, L. H, & Fong, Y. Influence of transfusions on perioperative and long-term outcome in patients following hepatic resection for colorectal metastases. *Ann Surg* (2003). , 237, 860-70.
- [52] Strasberg, S. M, Belghiti, J, Clavien, P. A, Gadzijev, E, Garden, J. O, Lau, W. Y, Makuuchi, M, & Strong, R. W. Terminology Committee of the International Hepato-Pancreato-Biliary Association: The Brisbane 2000 Terminology of Liver Anatomy and Resections. *HPB* (2000). , 2, 333-9.
- [53] De Haas, R. J, Wicherts, D. A, Flores, E, Azoulay, D, Castaing, D, & Adam, R. R. resection by necessity for colorectal liver metastases: Is it still a contraindication to surgery? *Ann Surg* (2008). , 248(4), 626-37.
- [54] Gagner, M, Rheault, M, & Dubuc, J. Laparoscopic partial hepatectomy for liver tumour. *Surg Endosc* (1992).
- [55] Cellini, C, Hunt, S. R, Fleshman, J. W, Birnbaum, E. H, Bierhals, A. J, & Mutch, M. G. Stage IV rectal cancer with liver metastases: is there a benefit to resection of the primary tumour? *World J Surg* (2010). , 34(5), 1102-8.
- [56] Adam, R, Delvart, V, Pascal, G, Castaing, D, Azoulay, D, Giacchetti, S, Paule, B, Kunstlinger, F, Ghémard, O, Levi, F, & Bismuth, H. Rescue surgery for unresectable colorectal liver metastases downstaged by chemotherapy: a model to predict long-term survival. *Ann Surg* (2004). , 240, 644-57.
- [57] Benoist, S, Brouquet, A, Penna, C, Julié, C, El Hajjam, M, Chagnon, S, Mity, E, Rougier, P, & Nordlinger, B. Complete response of colorectal liver metastases after chemotherapy: does it mean cure? *J Clin Oncol* (2006). , 20(24), 3939-45.
- [58] Abdalla, E. K, Adam, R, Bilchik, A. J, Jaeck, D, Vauthey, J. N, & Mahvi, R. Improving resectability of hepatic colorectal metastases: Expert consensus statement. *Annals of Surgical Oncology* (2006). , 13(10), 1271-80.

- [59] Donadon, M, Ribero, D, Morris-stiff, G, Abdalla, E. K, & Vauthey, J. N. New paradigm in the management of liver-only metastases from colorectal cancer. *Gastrointest Cancer Res* (2007). , 1(1), 20-7.
- [60] Garden, O. J, Rees, M, Poston, G. J, Mirza, D, Saunders, M, Ledermann, J, Primrose, J. N, & Parks, R. W. Guidelines for resection of colorectal cancer liver metastases. *Gut* (2006). Suppl 3): iiiiii8., 1.
- [61] De Haas, R J, Wicherts, D. A, Andreani, P, Pascal, G, Saliba, F, Ichai, P, Adam, R, Castaing, D, & Azoulay, D. Impact of expanding criteria for resectability of colorectal metastases on short- and long-term outcomes after hepatic resection. *Ann Surg* (2011). , 253(6), 1069-79.
- [62] Power, D. G, & Kemeny, N. E. Role of adjuvant therapy after resection of colorectal cancer liver metastases. *J Clin Oncol* (2010). , 28(13), 2300-9.
- [63] Laurent, C. Sa Cunha A, Couderc P, Rullier E, Saric J. Influence of postoperative morbidity on long-term survival following liver resection for colorectal metastases. *Br J Surg* (2003). , 90(9), 1131-6.
- [64] Makuuchi, M, Thai, B. L, Takayasu, K, Takayama, T, Kosuge, T, Gunven, P, Yamazaki, S, Hasegawa, H, & Ozaki, H. Preoperative portal embolization to increase safety of major hepatectomy for hilar bile duct carcinoma: a preliminary report. *Surgery* (1990). , 107, 521-7.
- [65] Ribero, D, Abdallah, E. K, Madoff, D. C, Donadon, M, Loyer, E. M, & Vauthey, J. N. Portal vein embolization before major hepatectomy and its effects on regeneration, resectability and outcome. *Br J Surg* (2007). , 94, 1386-96.
- [66] Abdallah, E. K, Hicks, M. E, & Vauthey, J. N. Portal vein embolization: rationale, technique and future prospects. *Br J Surg* (2001). , 88, 165-75.
- [67] Nagino, M, Kamiya, J, Nishio, H, Ebata, T, Arai, T, & Nimura, Y. Two hundred forty consecutive portal vein embolizations before extended hepatectomy for biliary cancer: surgical outcome and long-term follow-up. *Ann Surg* (2006). , 243, 364-72.
- [68] Azoulay, D, Castaing, D, Smail, A, Adam, R, Cailliez, V, Laurent, A, Lemoine, A, & Bismuth, H. Resection of non-resectable liver metastases from colorectal cancer after percutaneous portal vein embolization. *Ann Surg* (2000). , 4, 480-86.
- [69] Adam, R, Laurent, A, Azoulay, D, Castaing, D, & Bismuth, H. Two-stage hepatectomy: a planned strategy to treat irresectable liver tumours. *Ann Surg* (2000). , 232, 777-85.
- [70] Jaeck, D, Oussoultzoglou, E, Rosso, E, Greget, M, Weber, J. C, & Bachellier, P. Two-stage hepatectomy procedure combined with portal vein embolization to achieve curative resection for initially unresectable multiple and bilobar colorectal liver metastases. *Ann Surg* (2004). , 240, 1037-49.

- [71] Clavien, P. A, Petrowsky, H, Deoliveira, M. L, & Graf, R. Strategies for safer liver surgery and partial liver transplantation. *N Engl J Med* (2007). , 356(15), 1545-59.
- [72] Kianmanesh, R, Farges, O, Abdalla, E. K, & Sauvanet, A. Ruzsniowski, Belghiti J. Right portal vein ligation: a new planned two-step all-surgical approach for complete resection of primary gastrointestinal tumours with multiple bilateral liver metastases. *J Am Coll Surg* (2003). , 197, 164-70.
- [73] Brouquet, A, Abdalla, E. K, Kopetz, S, Garrett, C. R, Overman, M. J, Eng, C, Andreou, A, Loyer, E. M, Madoff, D. C, Curley, S. A, & Vauthey, J. N. High survival rate after two-stage resection of advanced colorectal liver metastases: responsebased selection and complete resection define outcome. *J Clin Oncol* (2011). , 29, 1083-90.
- [74] Narita, M, Oussoultzoglou, E, Jaeck, D, Fuchschuber, P, Rosso, E, Pessaux, P, Marzano, E, & Bachellier, P. Two-stage hepatectomy for multiple bilobar colorectal liver metastases. *Br J Surg* (2011). , 98(10), 1463-75.
- [75] Schnitzbauer, A. A, Lang, S. A, Goessmann, H, Nadalin, S, Baumgart, J, Farkas, S. A, Fichtner-feigl, S, Lorf, T, Goralcyk, A, Hörbelt, R, Kroemer, A, Loss, M, Rümmele, P, Scherer, M. N, Padberg, W, Königsrainer, A, Lang, H, Obed, A, & Schlitt, H. J. Right Portal Vein Ligation Combined With In Situ Splitting Induces Rapid Left Lateral Liver Lobe Hypertrophy Enabling 2-Stage Extended Right Hepatic Resection in Small-for-Size Settings. *Ann Surg* (2012). , 255(3), 405-14.
- [76] Andriani, O. C. Long-Term Results With Associating Liver Partition and Portal Vein Ligation for Staged Hepatectomy (ALPPS). *Annals of Surgery* (2012). e5.
- [77] Clavien-3, P. A, & Santibañes, E. The ALPPS: Time to Explore! *Ann Surg* (2012). e, 18-9.
- [78] Machado MACMakdissi FF, Surjan RC. Totally Laparoscopic ALPPS Is Feasible and May Be Worthwhile. *Annals of Surgery* (2012). e13.
- [79] Conrad, C, Shivathirthan, N, Camerlo, A, Strauss, C, & Gayet, B. Laparoscopic Portal Vein Ligation With In Situ Liver Split for Failed Portal Vein Embolization. *Annals of Surgery* (2012). e, 14-5.
- [80] Aloia, T. A, & Vauthey, J. N. Associating Liver Partition and Portal Vein Ligation for Staged Hepatectomy (ALPPS): What Is Gained and What Is Lost? *Annals of Surgery* (2012). e9.
- [81] Jain, H. A. Bharathy KGS, Negi SS. Associating Liver Partition and Portal Vein Ligation for Staged Hepatectomy: Will the Morbidity of an Additional Surgery Be Outweighed by Better Patient Outcomes in the Long-Term? *Annals of Surgery* (2012). e10.
- [82] Narita, M, Oussoultzoglou, E, Ikai, I, Bachellier, P, & Jaeck, D. Right Portal Vein Ligation Combined With In Situ Splitting Induces Rapid Left Lateral Liver Lobe Hyper-

- trophy Enabling Staged Extended Right Hepatic Resection in Small-for-Size Settings. *Annals of Surgery* (2012 2). e7-8., 2.
- [83] Dokmak, S, & Belghiti, J. Which limits to the "ALPPS" Approach? *Annals of Surgery* (2012). e6.
- [84] Santibañes, E, & Clavien, P. A. Playing Play-Doh to Prevent Postoperative Liver Failure: The "ALPPS" approach. *Annals of Surgery* (2012). , 256(3), 415-7.
- [85] Konopke, R, Roth, J, Volk, A, Pistorius, S, Folprecht, G, Zoepfel, K, Schuetze, C, Laniado, M, Saeger, H. D, & Kersting, S. Colorectal Liver Metastases: an Update on Palliative Treatment Options. *J Gastrointestin Liver Dis* (2012). , 21(1), 83-91.
- [86] Solbiati, L, Livraghi, T, Goldberg, S. N, et al. Percutaneous radiofrequency ablation of hepatic metastases from colorectal cancer: long-term results in 117 patients. *Radiology* (2001). , 221, 159-66.
- [87] Sorensen, S. M, Mortensen, F. V, & Nielsen, D. T. Radiofrequency ablation of colorectal liver metastases: long-term survival. *Acta Radiol* (2007). , 48, 253-8.
- [88] Machi, J, Oishi, A. J, Sumida, K, Sakamoto, K, Furumoto, N. L, Oishi, R. H, & Kylstra, J. W. Long-term outcome of radiofrequency ablation for unresectable liver metastases from colorectal cancer: evaluation of prognostic factors and effectiveness in first- and second-line management. *Cancer J* (2006). , 12, 318-26.
- [89] Kennedy, J. E. High-intensity focused ultrasound in the treatment of solid tumours. *Nat Rev Cancer* (2005). , 5, 321-7.
- [90] Al-asfoor, A, Federowicz, Z, & Lodge, M. Resection versus no intervention or other surgical interventions for colorectal cancer liver metastases. *Cochrane Database Syst Rev* (2008). CD006039.
- [91] Azoulay, D, Eshkenazy, R, Andreani, P, Castaing, D, Adam, R, Ichai, P, Naili, S, Vinet, E, Saliba, F, Lemoine, A, Gillon, M. C, & Bismuth, H. In situ hypothermic perfusion of the liver versus standard total vascular exclusion of complex liver resection. *Ann Surg* (2005). , 2005, 241-277.
- [92] Hemming, A. W, Chari, R. S, & Cattral, M. S. Ex vivo liver resection. *Can J Surg* (2000). , 43(3), 222-4.
- [93] Lodge JPAmmori BJ, Prasad KR, Bellamy MC. Ex vivo and in situ resection of inferior vena cava with hepatectomy for colorectal metastases. *Ann Surg* (2000). , 231(4), 471-9.
- [94] Hemming, A. W, & Reed, A. I. Langham MR Jr, Fujita S, Howard RJ. Combined resection of the liver and inferior vena cava for hepatic malignancy. *Ann Surg* (2004). , 239, 712-21.
- [95] Langenhoff, B. S, Krabbe, P. F, & Ruers, T. J. Efficacy of follow-up after surgical treatment of colorectal liver metastases. *Eur J Surg Oncol* (2009). , 35, 180-6.

- [96] Petrelli, N. Perioperative or adjuvant therapy for resectable colorectal hepatic metastases. *J Clin Oncol* (2008). , 26(30), 4862-3.
- [97] Smith, M. D, & McCall, J. L. Systematic review of tumour number and outcome after radical treatment of colorectal liver metastases. *Br J Surg* (2009). , 96(10), 1101-13.
- [98] Söreide, J. A, Eiriksson, K, Sandvik, O, Viste, A, Horn, A, Johnsen, G, & Grønbech, J. E. Surgical treatment of liver metastases from colorectal cancer. *Br J Surg* (2008). , 128, 50-3.
- [99] Petrowsky, H, Gonen, M, Jarnagin, W, Lorenz, M, Dematteo, R, Heinrich, S, Encke, A, Blumgart, L, & Fong, Y. Second liver resections are safe and effective treatment for recurrent hepatic metastases from colorectal cancer: a bi- institutional analysis. *Ann Surg* (2002). , 235, 863-71.
- [100] Yamamoto, J, Kosuge, T, Shimada, K, Yamasaki, S, Moriya, Y, & Sugihara, K. Repeat liver resection for recurrent colorectal liver metastases. *Am J Surg* (1999). , 178, 275-81.
- [101] Adam, R, Pascal, G, Azoulay, D, Tanaka, K, Castaing, D, & Bismuth, H. Liver resection for colorectal metastases: the third hepatectomy. *Ann Surg* (2005). , 238, 871-83.
- [102] International Agency for Research on Cancer: GLOBOCAN 2008 dataWorld Health Organization. Cancer Incidence, Mortality and Prevalence Worldwide in (2008). <http://www-dep.iarc.fr> accessed 22 August 2012)
- [103] Borrego-Estella, V. M, & Serrablo, A. In: Borrego-Estella VM (ed.) Estudio de las metástasis hepáticas de cáncer colorrectal con rescate quirúrgico en un hospital de tercer nivel. Identificación de marcadores biológicos pronósticos. Salamanca: Colección VITOR; (2010). , 12-19.
- [104] Berge, T, & Linell, F. Carcinoid tumours. Frequency in defined population during a 12-year period. *Acta Pathol Microbiol Scand* (1976). , 84(4), 322-30.
- [105] Hellman, P, Lundström, T, Öhrvall, U, Eriksson, B, Skogseid, B, & Oberg, K. Tiensuu Janson E, Akerstrom G. Effect of surgery on the outcome of midgut carcinoid disease with lymph node and liver metastases. *World J Surg* (2002). , 26, 991-7.
- [106] Touzius, J. G, Kiely, J. M, Pitt, S. C, Rilling, W. S, Quebbeman, E. J, Wilson, S. D, & Pitt, H. Neuroendocrine hepatic metastases: does aggressive management improve survival? *Ann Surg* (2005). , 241(5), 776-83.
- [107] Hodul, P, Malafa, M, Choi, J, & Kvols, L. The role of cytoreductive hepatic surgery as an adjunct to the management of metastatic neuroendocrine carcinomas. *Cancer Control* (2006). , 13, 61-71.
- [108] Lee PSYCheow PC, Teo JY, Ooi LLPJ. Surgical treatment of neuroendocrine liver metastases. *Int J Hepatol* (2012). Epub 2012 Jan 26.
- [109] Steinmueller, T, Kianmanesh, R, Falconi, M, Scarpa, A, Taal, B, Kuekkeboom, D. J, Lopes, J. M, Perren, A, & Nikou, G. Delle Fave GF, O'Toole D, Frascati Consensus

Conference Participants: Consensus guidelines for the management of patients with liver metastases from digestive (neuro)endocrine tumours: foregut, midgut, hindgut, and unknown primary. *Neuroendocrinology* (2008). , 87, 47-62.

- [110] Sarmiento, J. M, Heywood, G, Rubin, J, Ilstrup, D. M, Nagorney, D. M, & Qne, F. G. Surgical treatment of neuroendocrine metastases to the liver: a plea for resection to increase survival. *J Am Coll Surg* (2003). , 197, 29-37.
- [111] Knox, C. D, Anderson, C. D, Lamps, L. W, Adkins, R. B, & Pinson, C. W. Long-term survival after resection for primary hepatic carcinoid tumour. *Ann Surg Oncol* (2003). , 10(10), 1171-5.
- [112] Musunuru, S, Chen, H, Rajpal, S, Stephani, N, Mcdermott, J. C, Holen, K, Rikkers, L. F, & Weber, S. M. Metastatic neuroendocrine hepatic tumours: resection improves survival. *Arch Surg* (2006). , 141, 1000-4.
- [113] Frilling, A, Rogiers, X, Malago, M, Liedke, O. M, Kaun, M, & Broelsch, C. E. Treatment of liver metastases in patients with neuroendocrine tumours. *Langenbeck 's Arch Surg* (1998). , 383, 62-70.
- [114] Adam, R, Chiche, L, Aloia, T, Elias, D, Salmon, R, Rivoire, M, Jaeck, D, & Saric, J. Le-Treut YP, Belghiti J, Mantion G, Mentha G and the Association Française de Chirurgie. Hepatic resection for noncolorectal nonendocrine liver metastases. Analysis of 1452 patients and development of a prognostic model. *Ann Surg* (2006). , 244(4), 524-35.
- [115] Reddy, S. K, Barbas, A. S, Marroquin, C. E, Morse, M. A, Kuo, P. C, & Clary, B. M. Resection of noncolorectal nonneuroendocrine liver metastases: a comparative analysis. *J Am Coll Surg* (2007). , 204, 372-82.
- [116] Harrison, L. E, Brennan, M. F, Newman, E, Fortner, J. G, Picardo, A, & Blumgart, L. H. Hepatic resection for noncolorectal, nonneuroendocrine metastases: a fifteen-year experience with ninety-six patients. *Surgery* (1997). , 121, 625-32.
- [117] Hemming, A. W, Sielaff, T. D, Gallinger, S, Cattral, M. S, Taylor, B. R, Greig, P. D, & Langer, B. Hepatic resection of noncolorectal nonneuroendocrine metastases. *Liver Transpl* (2000). , 6, 97-101.
- [118] Laurent, C, Rullier, E, Feyler, A, Masson, B, & Saric, J. Resection of noncolorectal and nonneuroendocrine liver metastases: late meatastases are the only chance of cure. *World J Surg* (2001). , 25, 1532-6.
- [119] Yamada, H, Katoh, H, Kondo, S, Okushiba, S, & Morikawa, T. Hepatectomy from non-colorectal and non-neuroendocrine tumour. *Anticancer Res* (2001). , 21, 4159-62.
- [120] Takada, Y, Otsuka, M, Seino, K, Taniguchi, H, Koike, N, Kawamoto, T, Koda, K, Adachi, S, Yuzawa, K, Nozue, M, Todoroki, T, & Fukao, K. Hepatic resection for metastatic tumours from noncolorectal carcinoma. *Hepatogastroenterology*. (2001). , 48, 83-6.

- [121] Karavias, D. D, Tepetes, K, Karatzas, T, Felekouras, E, & Androulakis, J. Liver resection for metastatic non-olorectal non-neuroendocrine hepatic neoplasms. *Eur J Surg Oncol* (2002). , 28, 135-9.
- [122] Weitz, J, Blumgart, L. H, Fong, Y, Jarnagin, W. R, Angelica, D, Harrison, M, & DeMatteo, L. E. RP. Partial hepatectomy for metastases from noncolorectal, nonneuroendocrine carcinoma. *Ann Surg* (2005). , 241, 269-76.
- [123] Ercolani, G, Grazi, G. L, Ravaioli, M, Ramacciato, G, Cescon, M, & Varotti, G. del Gaudio M, Vetrone G, Pinna AD. The role of liver resections for oncolorectal, non-neuroendocrine metastases: experience with 142 observed cases. *Ann Surg Oncol* (2005). , 12, 459-66.
- [124] Miettinen, M, & Lasota, J. Gastrointestinal stromal tumours: definition, clinical, histological, immunohistochemical, and molecular genetic features and differential diagnosis. *Virchows Arch* (2001). , 438, 1-12.
- [125] Gold, J. S. DeMatteo RP: Combined surgical and medical therapy, the gastrointestinal stromal tumour model. *Ann Surg* (2006). , 244, 176-84.
- [126] Miettinen, M, Rifai, W, Sobin, H. L, & Lasota, L. J. Evaluation of malignancy and prognosis of gastrointestinal stromal tumours: a review. *Hum Pathol* (2002). , 33, 478-83.
- [127] Gomez, D, Al-mukthar, A, Menon, K. V, Toogood, G. J, Lodge, J. P, & Prasad, K. R. Aggressive surgical resection for the management of hepatic metastases from gastrointestinal stromal tumours: a single centre experience. *HPB* (2007). , 9, 64-70.
- [128] Dematteo, R. P, Lewis, J. J, Leung, D, Mudan, S. S, Woodruff, J. M, & Brennan, M. F. Two hundred gastrointestinal stromal tumours: recurrence patterns and prognostic factors for survival. *Ann Surg* (2000). , 231, 51-8.
- [129] Husted, T. L, Neff, G, Thomas, M. J, Gross, T. G, Woodle, E. S, & Buell, J. F. Liver transplantation for primary or metastatic sarcoma to the liver. *Am J Transplant* (2006). , 6, 392-7.
- [130] Turley, R. S, Peng, P. D, Reddy, S. K, Barbas, A. S, Geller, D. A, Marsh, J. W, Tsung, A, Pawlik, T. M, & Clary, B. M. Hepatic resection for metastatic gastrointestinal stromal tumours in the tyrosine kinase inhibitor era. *Cancer* (2012). , 118(14), 3571-8.
- [131] Ng, E. H, Pollock, R. E, Munsell, M. F, Atkinson, E. N, & Romsdahl, M. M. Prognostic factors influencing survival in gastrointestinal leiomyosarcomas. Implications for surgical management and staging. *Ann Surg* (1992). , 215, 68-77.
- [132] Chen, H, Pruitt, A, Nicol, T. L, Gorgulu, S, & Choti, M. A. Complete hepatic resection of metastases from leiomyosarcoma prolongs survival. *J Gastrointest Surg* (1998). , 2, 151-5.

- [133] Lang, H, Nussbaum, K. T, Kaudel, P, Fruhauf, N, Flemming, P, & Raab, R. Hepatic metastases from leiomyosarcoma: a single center experience with 34 liver resections during a 15-year period. *Ann Surg* (2000). , 231, 500-5.
- [134] Shima, Y, Horimi, T, Ishikawa, T, Ichikawa, J, Okabayashi, T, Nishioka, Y, Hamada, M, Shibuya, Y, Ishii, T, & Ito, M. Aggressive surgery for liver metastases from gastrointestinal stromal tumours. *J Hepatobiliary Pancreat Surg* (2003). , 10, 77-80.
- [135] Nunobe, S, Sano, T, Shimada, K, Sakamoto, Y, & Kosuge, T. Surgery including liver resection for metastatic gastrointestinal stromal tumours or gastrointestinal leiomyosarcomas. *Jpn J Clin Oncol* (2005). , 35, 338-41.
- [136] Seifert, J. K, Weigel, T. F, Gonner, U, Bottger, T. C, & Junginger, T. Liver resection for breast cancer metastases. *Hepatogastroenterology* (1999). , 46, 2935-40.
- [137] Atalay, G, Biganzoli, L, Renard, F, Paridaens, R, Cufer, T, Coleman, R, Calvert, A. H, Gamucci, T, Minisini, A, Therasse, P, & Piccart, M. J. Clinical outcome of breast cancer patients with liver metastases alone in the anthracycline-taxane era: A retrospective analysis of two prospective, randomised metastatic breast cancer trials. *Eur J Cancer* (2003). , 39, 2439-49.
- [138] Adam, R, Aloia, T, Krissat, J, Bralet, M. P, Paule, B, Gachietti, S, Delvart, S, Azoulay, D, Bismuth, H, & Castaing, D. Is liver resection justified for patients with hepatic metastases from breast cancer? *Ann Surg* (2006). , 244, 897-908.
- [139] Elias, D, Maisonneuve, F, Druet-cabanc, M, Ouellet, J. F, Guinebretiere, J. M, Spielmann, M, & Delaloge, S. An attempt to clarify indications for hepatectomy for liver metastases from breast cancer. *Am J Surg* (2003). , 185, 158-64.
- [140] Weitz, J, Blumgart, L. H, Fong, Y, Jarnagin, W. R, Angelica, D, Harrison, M, & DeMatteo, L. E. RP. Partial hepatectomy for metastases from noncolorectal nonneuroendocrine carcinoma. *Ann Surg* (2005). , 241, 269-76.
- [141] Sakamoto, Y, Yamamoto, J, Yoshimoto, M, & Kasumi, F. Kosuge bT, Kokudo N, Maikuuchi M. Hepatic resection for metastatic breast cancer: prognostic analysis of 34 patients. *World J Surg* (2005). , 29, 524-7.
- [142] Carlini, M, Lonardo, M. T, Carboni, F, Petric, M, Vitucci, C, Santoro, R, & Lepiane, P. Liver metastases from breast cancer: Results of surgical resection. *Hepatogastroenterology* (2002). , 49, 597-601.
- [143] Yoshimoto, M, Tada, T, Saito, M, Takahashi, K, Uchida, Y, & Kasumi, F. Surgical treatment of hepatic metastases from breast cancer. *Breast Cancer Res Treat* (2000). , 59, 177-84.
- [144] Selzner, M, Morse, M. A, Vredenburgh, J. J, Meyers, W. C, & Clavien, P. A. Liver metastases from breast cancer: long-term survival after curative resection. *Surgery* (2000). , 127, 383-9.

- [145] Pocard, M, Pouillart, P, Asselain, B, Falcou, M. C, & Salmon, R. J. Resections hepaticques pour metastases de cancer du sein: resultats et facteurs pronostiques (65 cas). *Ann Chir* (2001). , 126, 413-20.
- [146] Raab, R, Nussbaum, K. T, Werner, U, & Pichlmayr, R. Liver metastases in breast carcinoma. Results of partial liver resection. *Chirurg* (1996). , 67, 234-7.
- [147] Scheuerlein, H, Schneider, C, Köckerling, F, & Hohenberger, W. Surgical therapy of liver metastases in breast carcinoma]. *Zentralbl Chir* (1998). Suppl , 5, 130-4.
- [148] Pawlik, T. M, Zorzi, D, Abdalla, E. K, Clary, B. M, Gershenwald, J. E, Ross, M. I, Aloia, T. A, Curley, S. A, Camacho, L. H, Capussotti, L, Elias, D, & Vauthey, J. N. Hepatic resection for metastatic melanoma: distinct patterns of recurrence and prognosis for ocular versus cutaneous disease. *Ann Surg Oncol* (2006). , 13, 712-20.
- [149] Rose, D. M, Essner, R, & Hughes, T. M. Tang PCY, Bilchik A, Wanek LA, Thompson JF, Morton DL. Surgical resection for metastatic melanoma to the liver: the John Wayne Cancer Institute and Sydney Melanoma Unit experience. *Arch Surg* (2001). , 136, 950-5.
- [150] Fuster, D, Chiang, S, Johnson, G, Schuchter, L. M, Zhuang, H, & Alavi, A. Is 18FDG PET more accurate than standard diagnostic procedure in the detection of suspected recurrent melanoma? *J Nul Med* (2004). , 45, 1323-7.
- [151] Stoelben, E, Sturm, J, Schmoll, J, Keilholz, U, & Saeger, H. D. Resection of solitary liver metastases of malignant melanoma. *Chirurg* (1995). , 66, 40-3.
- [152] Wood, T. F. DiFronzo LA, Rose DM, Haigh PI, Stern SL, Wanek L. Does complete resection of melanoma metastatic to solid intra-abdominal organs improve survival? *Ann Surg Oncol* (2001). , 8, 658-62.
- [153] Chua, T. C, Saxena, A, & Morris, D. L. Surgical metastasectomy in AJCC Stage IV M1c melanoma patients with gastrointestinal and liver metastases. *Ann Acad Med Singapore* (2010). , 39, 634-9.
- [154] Essner, R, Lee, J. H, Wanek, L. A, Itakura, H, & Morton, D. L. Contemporary surgical treatment of advanced-stage melanoma. *Arch Surg* (2004). , 139, 961-7.
- [155] Ripley, R. T, Davis, J. L, Klapper, J. A, Mathur, A, Kammula, U, Royal, R. E, Yang, J. C, Sherry, R. M, Hughes, M. S, Libutti, S. K, White, D. E, Steinberg, S. M, Dudley, M. E, Rosenberg, S. A, & Avital, I. Liver resection for melanoma with postoperative tumour-infiltrating lymphocyte therapy. *Ann Surg Oncol* (2010). , 17(1), 163-70.
- [156] Herman, P. Machado MAC, Montagnini AL, Albuquerque LA, Saad WA, Machado MC. Selected patients with metastatic melanoma may benefit from liver resection. *World J Surg* (2007). , 31, 171-4.
- [157] Crook, T. B. Jones Om, John TG, Rees M. Hepatic resection for malignan melanoma. *Eur J Surg Oncol* , 20032, 315-7.

- [158] Sakamoto, Y, Ohyama, S, Yamamoto, J, Yamada, K, Seki, M, Ohta, K, Kokudo, N, Yamaguchi, T, Muto, T, & Makuuchi, M. Surgical resection of liver metastases of gastric cancer: an analysis of a 17-year experience with 22 patients. *Surgery* (2003). , 133, 507-11.
- [159] Thelen, A, Jonas, S, Benckert, C, Lopez-hänninen, E, Neumann, U, Rudolph, B, Schumacher, G, & Neuhaus, P. Liver resection for metastatic gastric cancer. *Eur J Surg Oncol* (2008). , 34(12), 1328-34.
- [160] Shirabe, K, Shimada, M, Matsumata, T, Higashi, H, Yakeishi, Y, & Wakiyama, S. Analysis of the prognostic factors for liver metastasis of gastric cancer after hepatic resection: a multiinstitutional study of the indications for resection. *Hepatogastroenterology* (2003). , 50, 1560-3.
- [161] Ambiru, S, Miyazaki, M, Ito, H, Nakagawa, K, Shimizu, H, Yoshidome, H, Shimizu, Y, & Nakajima, N. Benefits and limits of hepatic resection for gastric metastases. *Am J Surg* (2001). , 181, 279-83.
- [162] Zacherl, J, Zacherl, M, Scheuba, C, Steininger, R, Wenzl, E, Muhlbacher, F, Jakesz, R, & Längle, F. Analysis of hepatic resection of metastasis originating from gastric adenocarcinoma. *J Gastrointest Surg* (2002). , 6, 682-9.
- [163] Saiura, A, Umekita, N, Inoue, S, Maeshiro, T, Miyamoto, S, Matsui, Y, Asakage, t, & Kitamura, M. M. Clinicopathological features and outcome of hepatic resection for liver metastasis from gastric cancer. *Hepatogastroenterology* (2002). , 49, 1062-5.
- [164] Okano, K, Maeba, T, Ishimura, K, Karasawa, Y, Goda, F, Wakabayashi, H, Usuki, H, & Maeta, H. Hepatic resection for metastatic tumours from gastric cancer. *Ann Surg* , 2002235, 86-91.
- [165] Roh, H. R, Suh, K. S, Lee, H. J, Yang, H. K, Choe, K. J, & Lee, K. U. Outcome of hepatic resection for metastatic gastric cancer. *Am Surg* (2005). , 71, 95-9.
- [166] Lindell, G, Ohlsson, B, Saarela, A, Andersson, R, & Tranberg, K. G. Liver resection of noncolorectal secondaries. *J Surg Oncol* (1998). , 69, 66-70.
- [167] Di Carlo I, Grasso G, Patane D, Russello D, Latteri F. Liver metastases from lung cancer: is surgical resection justified? *Ann Thorac Surg* (2003). , 76, 291-3.
- [168] Ercolani, G, Ravaioli, M, Grazi, G. L, Cescon, M, & Varotti, G. Del Gaudio M, Vetrone G, Zanello M, Principe A, Pinna AD. The role of liver resections for metastases from lung carcinoma. *HPB (Oxford)* (2006). , 8(2), 114-5.
- [169] Armstrong, D. K, Bundy, B, Wenzel, L, & Huang, H. Q. Baergen MSR, Lele S, Copeland LJ, Walker JL, Burger RA. Intraperitoneal cisplatin and paclitaxel in ovarian cancer. *N Engl J Med* (2006). , 354(5), 34-43.

- [170] Yoon, S. S, Jarnagin, W. R, Fong, Y, Dematteo, R. P, Barakat, R. R, Blumgart, L. H, & Chi, D. S. Resection of recurrent ovarian or fallopian tube carcinoma involving the liver. *Gynecol Oncol* , 2003;91, 383-8.
- [171] Rasco, D. W. Assikis, Marshall F. Integrating metastasectomy in the management of advance urological malignancies-when are we in 2005? *J Urol* (2006). , 176, 1921-6.
- [172] Alves, A, Adam, R, Majno, P, Delvart, V, Azoulay, D, Castaing, D, & Bismuth, H. Hepatic resection for metastatic renal tumours: is it worthwhile? *Ann Surg Oncol* (2003). , 10, 705-10.

IntechOpen

