

# We are IntechOpen, the world's leading publisher of Open Access books Built by scientists, for scientists

4,800

Open access books available

122,000

International authors and editors

135M

Downloads

Our authors are among the

154

Countries delivered to

TOP 1%

most cited scientists

12.2%

Contributors from top 500 universities



WEB OF SCIENCE™

Selection of our books indexed in the Book Citation Index  
in Web of Science™ Core Collection (BKCI)

Interested in publishing with us?  
Contact [book.department@intechopen.com](mailto:book.department@intechopen.com)

Numbers displayed above are based on latest data collected.  
For more information visit [www.intechopen.com](http://www.intechopen.com)



---

# **Interdisciplinary Surgical Management of Orbital and Maxillo-Ethmoidal Complex Disorders**

---

Jarosław Paluch, Jarosław Markowski, Jan Pilch,  
Agnieszka Piotrowska – Seweryn,  
Robert Kwiatkowski, Joanna Lewin-Kowalik,  
Czesław Zralek and Agnieszka Gorzkowska

Additional information is available at the end of the chapter

<http://dx.doi.org/10.5772/53486>

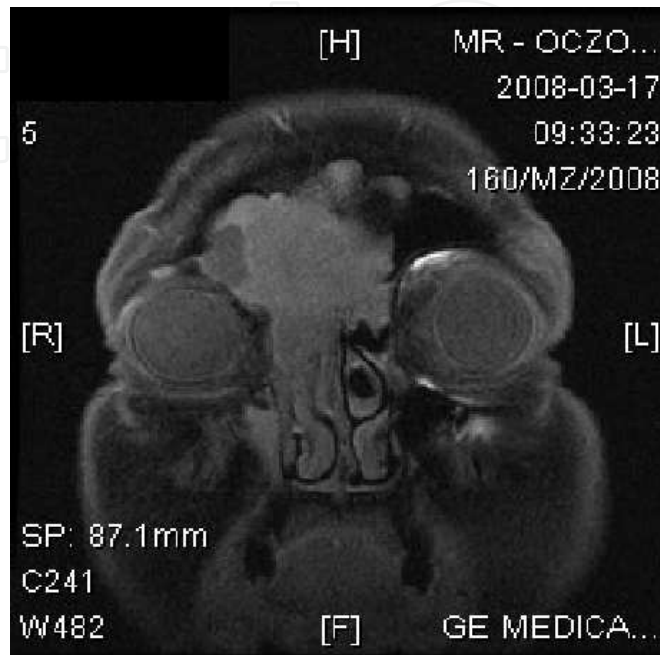
---

## **1. Introduction**

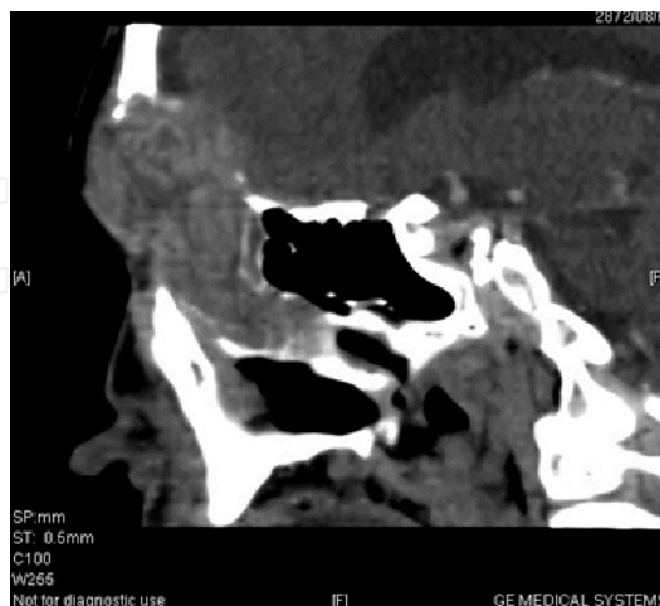Surgical management of the orbital and of maxillo-ethmoidal complex disorders is usually performed in patients with trauma, inflammation and/or neoplasms. Depending on the destroyed craniofacial region rhinotomy, sinusotomy, orbitotomy, maxillectomy and other types of operations are performed. In case of skull base extension the situation becomes more complicated leading to the necessity of co-operation of several specialists as well as modifications of surgical technique. Surgical procedures on eyeball are undertaken mainly by ophthalmologists, but no particular specialty has been yet dedicated for surgical treatment of other orbital regions. However, an attempt is made by surgeons, such as maxillo-facial surgeons, ENT surgeons, neurosurgeons, trauma surgeons, oncologic surgeons and rarely ophthalmologists. Patients, in whom operation is performed, are 'border-line' patients and the anatomical structures that are traumatised belong topographically to above specialties. It is very uncommon that there is an interdisciplinary team of surgeons available permanently in hospital to treat the described cases.

In the chapter the authors present as follows: interdisciplinary surgical management of orbital region and anterior cranial fossa, then maxillo-ethmoidal complex and anterior cranial fossa. Additionally, diagnostic problems and treatment of traumas and inflammatory diseases of the pterygopalatine fossa and infratemporal fossa with their histo-clinical characteristics are thoroughly described (Fig.1-2). According to nosologic classification epidemiology, etiology, diagnosis and surgical techniques including own modifications and clinical results,

especially in reference to neoplastic tumors is elaborated in both subsections. An integral part of the chapter consists of histo-clinical characteristic of the tumors of described region. A separate subdivision is dedicated to orbital complications and of anterior cranial fossa in the course of pansinusitis. Blow - out fracture is also mentioned in the chapter.



**Figure 1.** Massive inflammatory infiltration in maxillar sinus, ethmoidal sinus, frontal sinus with extension to anterior cranial fossa – MRI scan (own archives)



**Figure 2.** Malignant neoplasm of the orbit with extension to infratemporal fossa CT scan (own archives)

## 2. Epidemiology

Nowadays, **pansinusitis** is one of the most common diseases that occurs almost as often as arthritis and high blood pressure. Morbidity of chronic pansinusitis is 10,9% (according to Hastan D et al. ).

**Traumas** and intoxications are the third causes of deaths in Poland. Higher mortality present cardiovascular diseases and neoplasms. Traumas of head and neck are responsible for 60-72% of multi-organ traumas. They usually affect elderly men. They occur mainly due to collapses and accidents.

According to Szyfter et al. 3% of head and neck **neoplasms** and 05% of all neoplasms is localized in maxillo-ethmoidal complex. They occur mainly in men, in their 60s-80s. They infiltrate maxillary sinus in 50-70% of cases, nasal cavity in 15-30 and ethmoidal sinus in 10-20%. According to anatomical topography and terminology neoplasms of maxillo-ethmoidal complex and orbit with skull base extension expand in the region above Ohngren's plane that divides the maxillary sinus into an anterior-inferior part and superior-posterior. Tumors that arise in the first part have better prognosis.

## 3. Diagnostic methods

Diagnosis of traumas, inflammatory diseases and carcinomas of the described region has to be very precise in order to use appropriate surgical approach. Apart from basic diagnostic methods such as thorough anamnesis and examination, the authors emphasise a great role of nasal and nasopharyngeal endoscopy perfectly suited for the assessment of inflammatory and tumor penetration of nasal cavity and paranasal sinuses. However, in terms of carcinomas of orbit and the maxillo-ethmoidal complex with skull base penetration it is recommended to use imaging techniques that improve both the preclinical research and clinical treatment, such as computed tomography (CT), magnetic resonance imaging (MRI), positron emission tomography (PET) and ultrasound imaging. Recently various modalities of these techniques have been introduced to investigate the progression and treatment results of brain tumors. Among them we can name CT three-dimensional reconstruction, electron beam CT, dynamic CT enhancement, CT angiography, CT perfusion enhancement, high-resolution computed tomography (HRCT), diffusion-weighted imaging (DWI-MR), diffusion tensor imaging (DTI-MR) and many others. However, due to financial reasons conventional CT and MRI remains the most common diagnostic imaging method in the management of diseases of the described region.

Also, the authors focus on a great role of fine-needle biopsy as a determinant in diagnosis of orbital neoplasms and of infratemporal fossa. It has been found that histological types of maxillo-ethmoidal complex including pterygopalatine fossa and infratemporal fossa are as follows: pseudotumor, angioma, lymphoma, malignant epithelial neoplasms, neuromas and neurofibromas. Histological classification of intraorbital tumors has been thoroughly described by Handerson.

Histopathological results of biopsied tumors are essential for the following treatment, especially surgical management.

### 3.1. Fine-needle aspiration biopsy of orbital tumors

Fine-needle aspiration biopsy of orbital tumors verifies whether the tumor is neoplastic or non-neoplastic as well as it gives information about its malignancy. The most common orbital tumors are pseudotumors. The possibility to perform a biopsy depends on the localization of a tumor. In case of meningiomas localized in orbital conus in patient with good vision biopsy should be avoided due to the risk of damaging the optic nerve. Also, biopsy of cavernous hemangioma might develop complications such as bleeding and even haemorrhage.

A 25G hollow needle (length- 25 or 40mm) is used in fine-needle biopsy. The place of its insertion into the examined mass is verified with palpation. The insertion is carried out through the skin of eyelids without local anaesthesia. In case of impalpable tumors CT or MRI is used and the needle is continuously inserted until the resistance.

The consistence of most orbital tumors is solid. In case of cyst there is a liquid found and in teratomas – sebaceous masses.

The authors emphasise that diagnostic results obtained by fine-needle aspiration biopsy are not unequivocal and in lymphomas immunohistochemical examination is essential.

Also, it is worth mentioning that the described diagnostic methods are limited by 'diagnostic window' (short time in traumas, more time in inflammatory diseases and neoplasms).

## 4. Surgical management

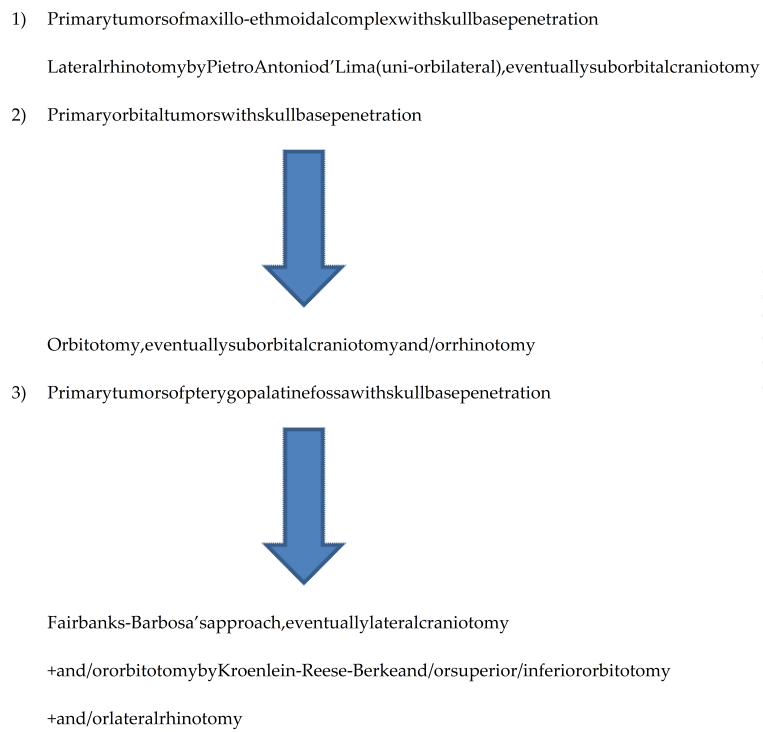
Surgical treatment in cases of trauma of craniofacial region, pterygopalatine fossa and infratemporal fossa is undertaken using an approach that gives access to damaged structures

### 4.1. Common approaches

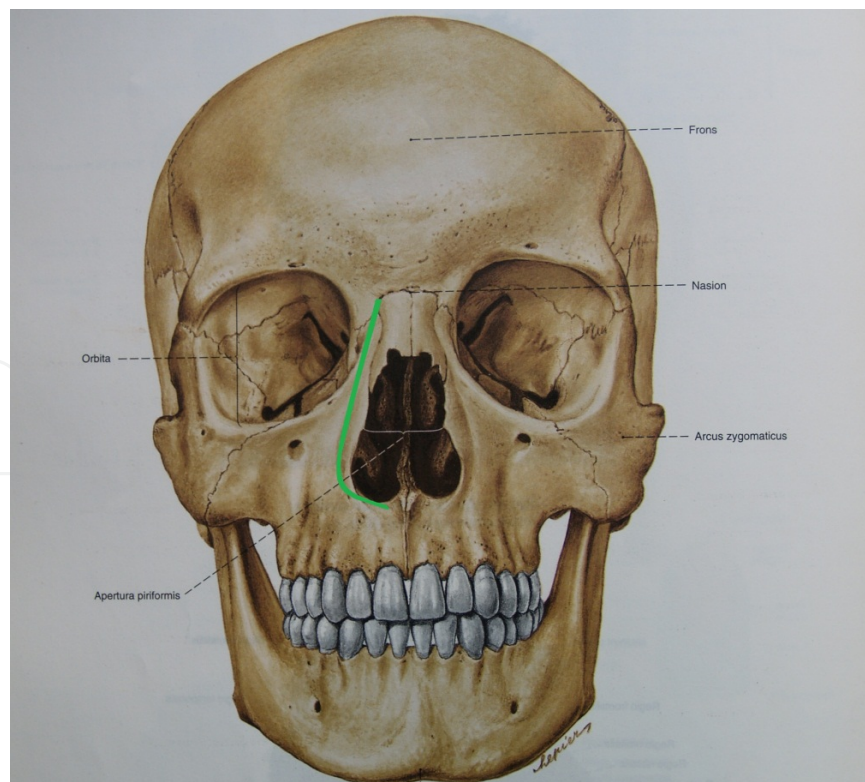
There are several approaches performed in the operation of described regions that are commonly used. Depending on the main disease (trauma, inflammation, primary tumor, metastases) and the operated area (nasal cavity, paranasal sinuses, pterygopalatine fossa, infratemporal fossa) we can name different types of rhinotomy, orbitotomy, sinusotomy, maxillectomy and craniotomy (Fig.3).

**Rhinotomy** enables an approach to nasal cavity, ethmoidal sinuses, maxillar sinuses as well as nasopharynx. The first lateral rhinotomy incision was introduced by Moure in 1902 (Fig.4).

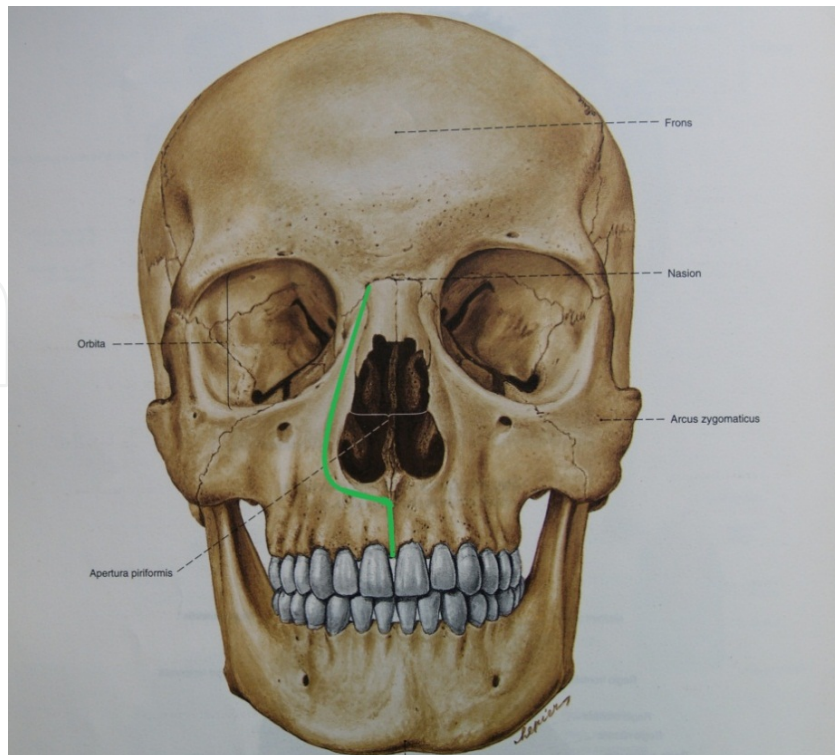
Since than some other scientist has improved the method, for instance Weber-Ferguson, whose incision and extensions enable medial maxillectomy (Fig.5-6), sometimes with orbital exenteration.



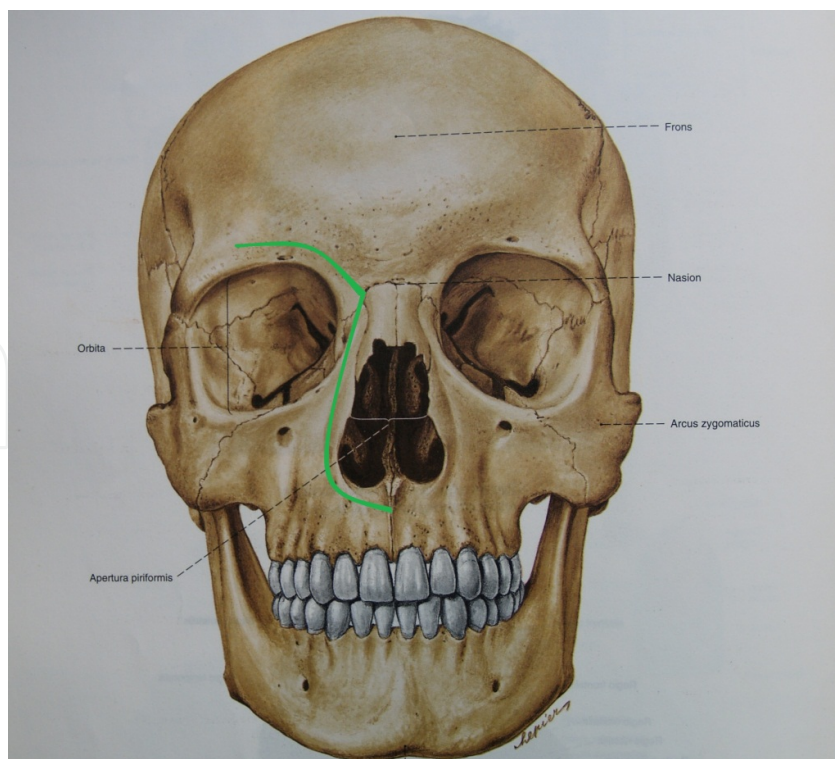
**Figure 3.** Possible surgical approaches in primary tumors of different regions with skull base penetration



**Figure 4.** Lateral rhinotomy- Moure's approach (the line indicates skin incision)

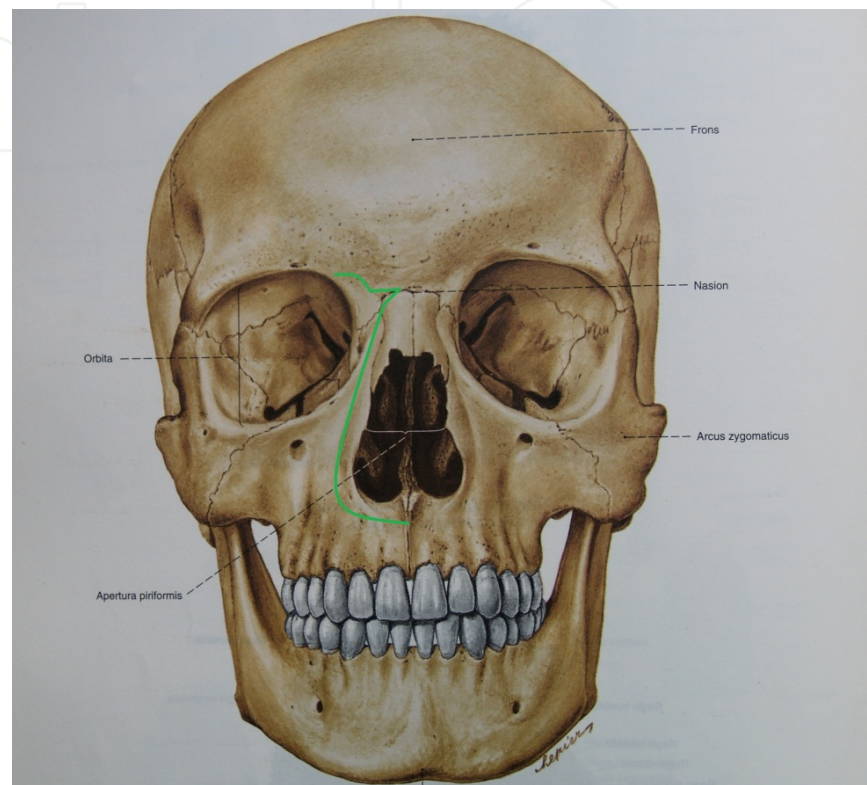


**Figure 5.** Weber-Ferguson incision. Lateral rhinotomy with inferior extension (the line indicates skin incision).



**Figure 6.** Weber-Ferguson incision. Lateral rhinotomy with superior extension (the line indicates skin incision).

Bechara Y. Ghorayeb has gone further, modifying Weber-Ferguson's incision. Namely, he created a V-shaped flap above the medial canthus in order to prevent scar retraction (Fig.7)



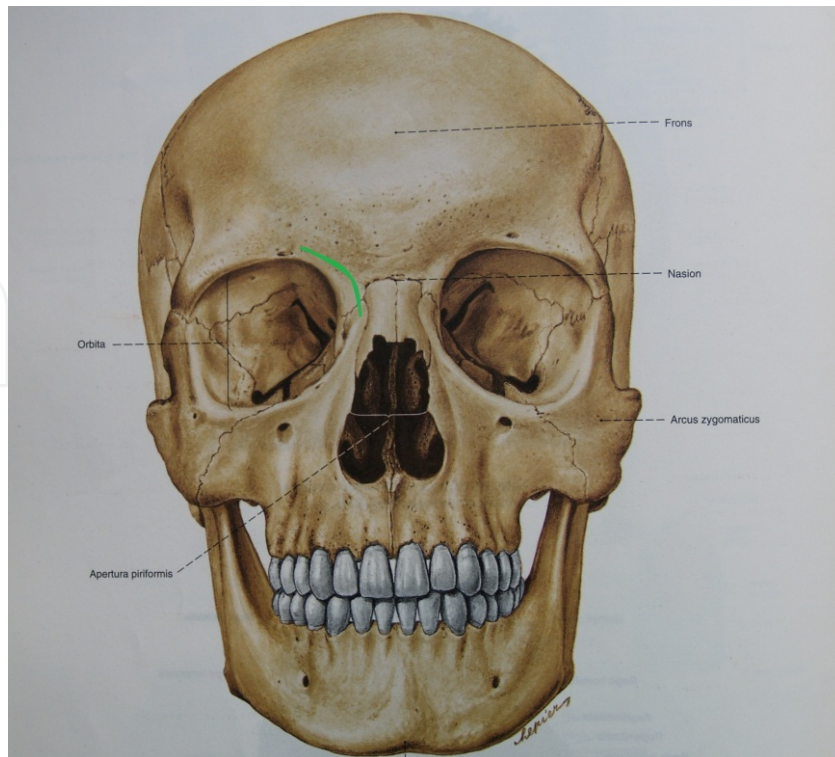
**Figure 7.** Modification of Weber-Ferguson incision- by Bechara Y. Ghorayeb (the line indicates skin incision).

Common approaches to **maxillar sinus** include:

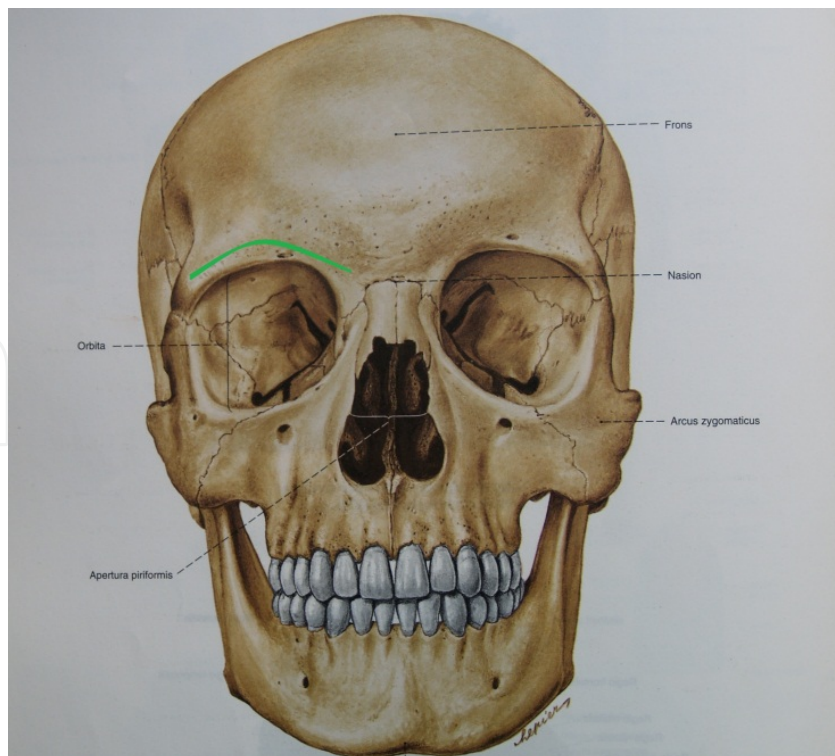
- Caldwell – Luc approach in fossa canina
- Denker's operation of maxillar sinus with resection of the anterior wall of maxillar sinus and lateral wall of the nasal cavity

In middle 80s of the twentieth century transcaruncular **orbitotomy** was performed at UCLA University and it is known as Baylis's approach. Later, Lynch described his medial orbitotomy (Fig. 8), which gives access to medio-superior part of the orbit and ethmoidal sinus and sphenoid sinus. Among other orbitotomies there is an anterior orbitotomy (Fig.9), lateral orbitotomy by Kroenlein-Reese-Berke (Fig.10-11) and posterior inferior orbitotomy, in which the technique is carried out through a standard Caldwell-Luc approach through the maxillary sinus. The posterior inferior orbital wall is removed and the inferior rectus is retracted either laterally or medially to gain access to the tumor, which is removed microsurgically.





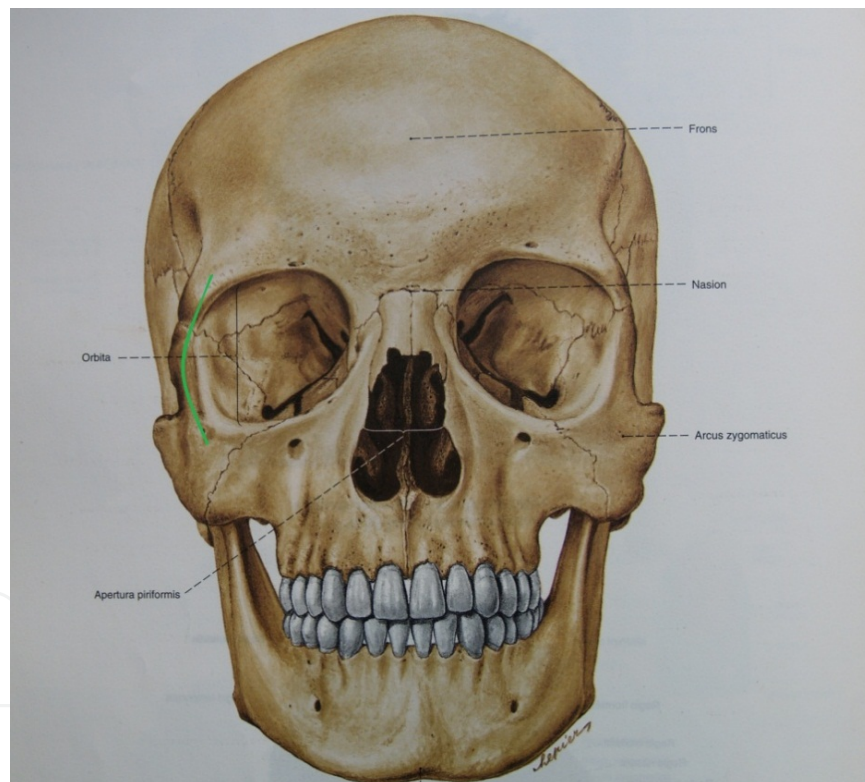
**Figure 8.** Lynch's medial orbitotomy (the line indicates skin incision)



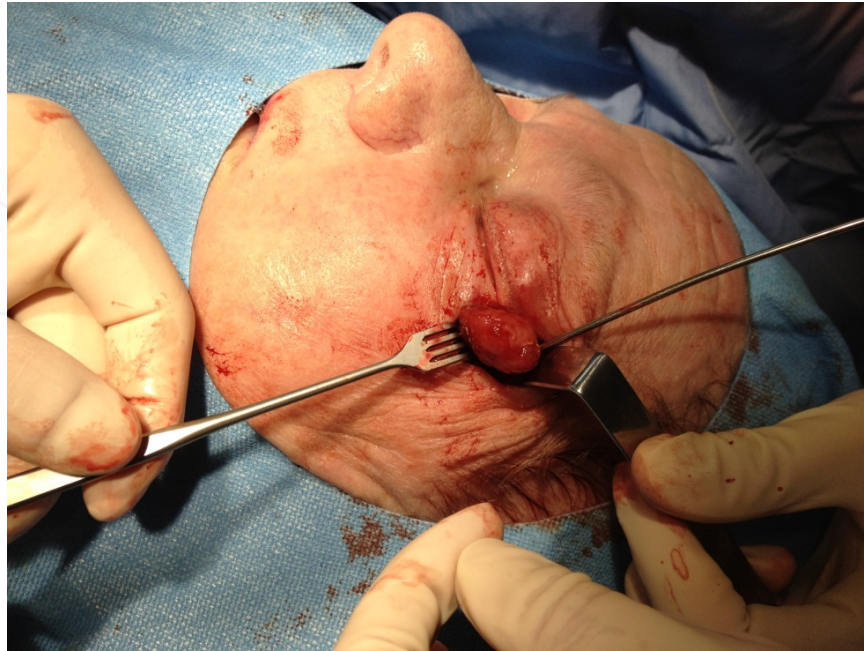**Figure 9.** Anterior orbitotomy – incision in supraciliary line (the line indicates skin incision)

In case of orbitotomy with bone removal, it is worth mentioning the names of particular operation, depending on the bone removed:

- Naffziger – removal of superior orbital wall
- Sewell – removal of medial orbital wall (ethmoidal sinus)
- Hirsch – removal of inferior orbital wall
- Kroenlein – removal of lateral orbital wall



**Figure 10.** Kroenlein- Reese-Berke lateral orbitotomy (the line indicates skin incision).



**Figure 11.** Lateral Kroenlein – Roose - Berke orbitotomy. Lipoma (own archives).

As far as operations on **frontal sinus** are concerned, it is essential to mention Kuemmel-Beck frontal trephine, which provides diagnostic information about the contents of the sinus and the function of the ostium. However, nowadays there are more and more endoscopic operations on the frontal sinus.

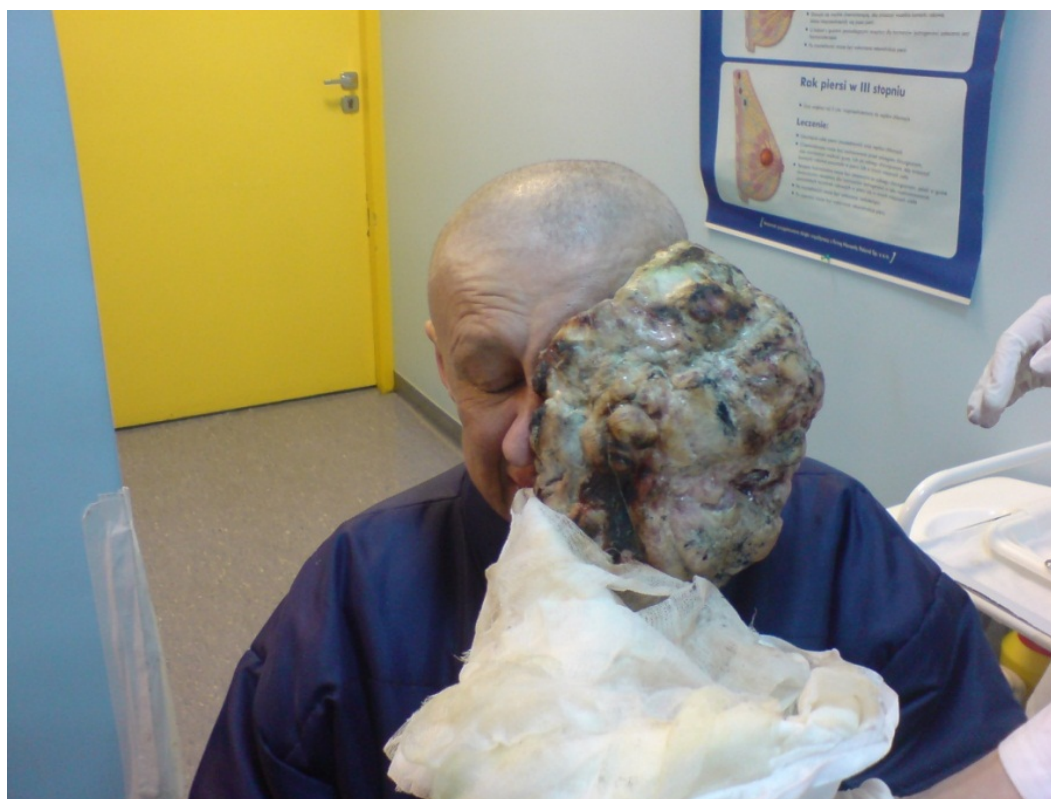More complicated operations that provide wide access to nasal cavities, inferior and medial part of maxilla, infratemporal fossa and pterygopalatine fossa include **midfacial degloving** and **cranio-facial resection**. While midfacial degloving leaves no scars, cranio-facial resection gives wider access to upper parts of nasal cavity, frontal sinus and skull base and it is usually performed by a team of ENT surgeons and neurosurgeons. If the orbit is involved orbital exenteration is carried out.

Surgical procedures are the basic method of treatment of tumors of anterior cranial fossa. This kind of surgical management is usually performed by a team of both ENT surgeons and neurosurgeons and the common approaches can be divided into **extracranial, intracranial and endoscopic**. Among intracranial approaches, transcranial-transbasal one should be mentioned. It is a frontal craniotomy which gives access to tumors of ethmoidal sinuses infiltrating skull base and sphenoid sinus as well as clival tumors. Subcranial approach is a modification of this technique. Apart from common orbitotomies we also have orbito-temporal and orbito-zygomatic approaches. Extracranial approaches are usually transsphenoidal. A separate group of operations on anterior cranial fossa is created by a combination of the two approaches- extra-and intracranial (known as cranio-facial resection= anterior fossa cranio-facial resection – AFCFR).

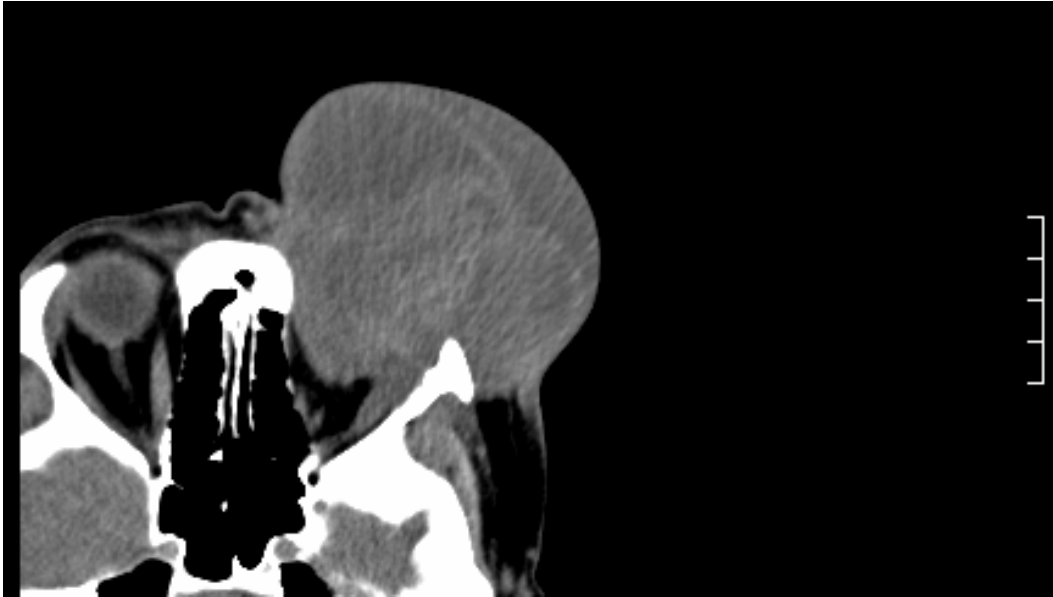
#### 4.2. Own modifications of common approaches

Surgical treatment in cases of trauma of craniofacial region, pterygopalatine fossa and infra-temporal fossa is performed with an approach that gives access to damaged structures. Presented surgical procedures are performed with internal approaches due to extensive character of inflammation/neoplasm. Therefore endoscopic techniques dedicated for limited diseases are not elaborated in the chapter.

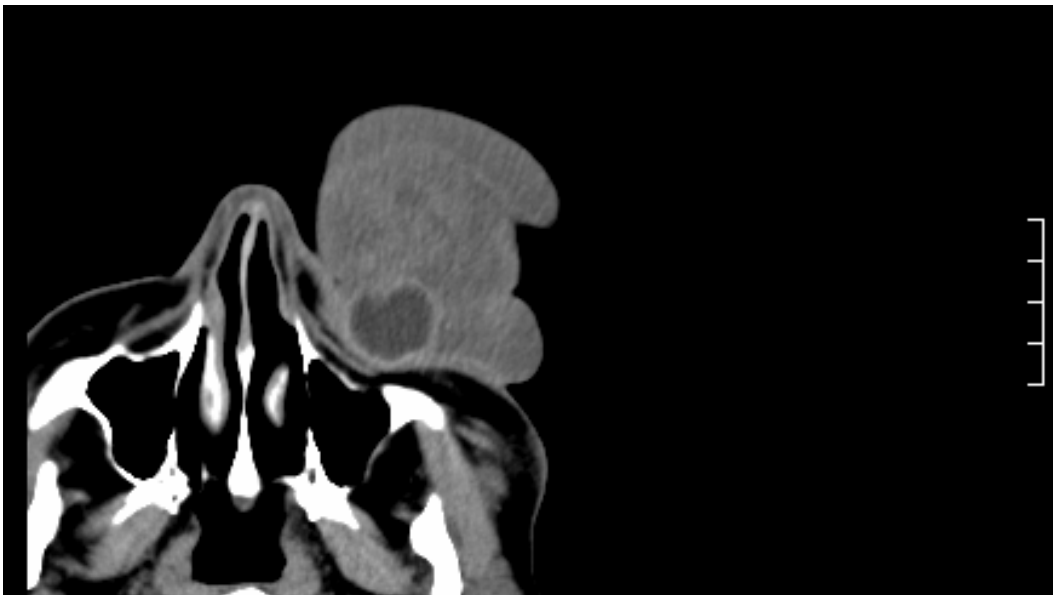
In case of tumors, the resection is conditioned by clinical staging- from endoscopic endonasal tumorectomy, through endoscopic surgery of orbit and pterygopalatine fossa up to advanced resections like own modification of “scalp” approach to half of viscerocranium (lateral rhinotomy+ superior/inferior orbitotomy + Fairbanks- Barbosa’s approach) (Case.1- Fig.12-16, Case.2 –Fig. 17-20, Case 3 – Fig. 21-23).



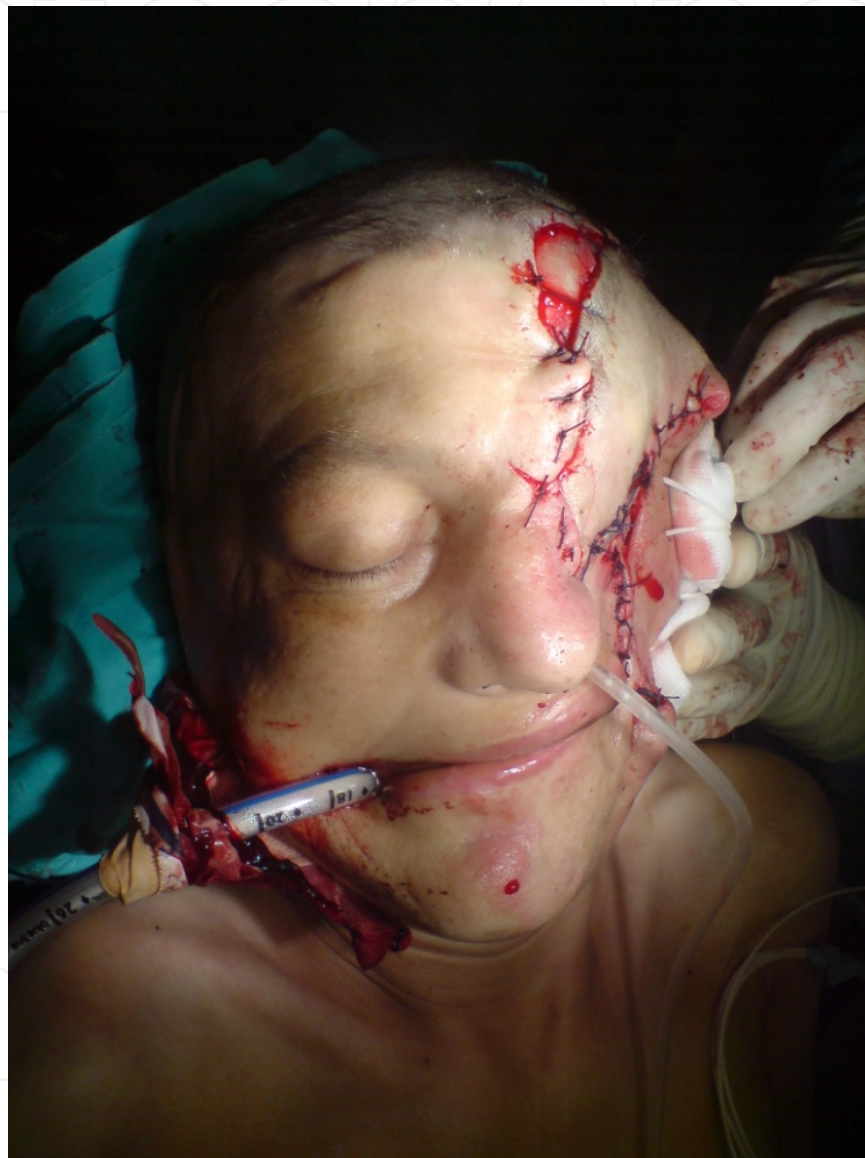**Figure 12.** Case 1. Massive orbital carcinoma with co-existing active tuberculosis. (The photo was taken on patient’s agreement)



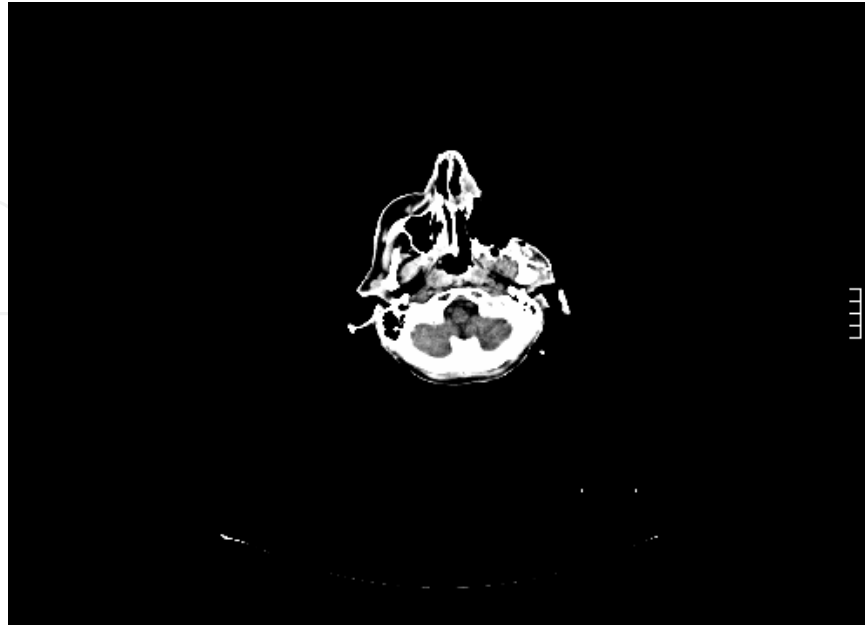
**Figure 13.** Case 1. Massive orbital carcinoma with co-existing active tuberculosis –preoperative CT scan.



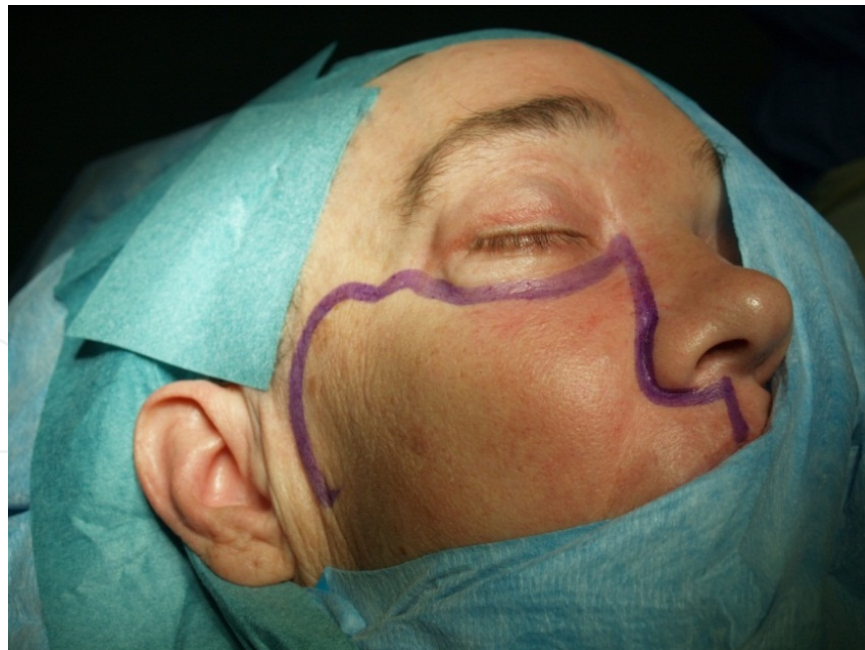**Figure 14.** Case 1. Massive orbital carcinoma with co-existing active tuberculosis– preoperative CT scan.



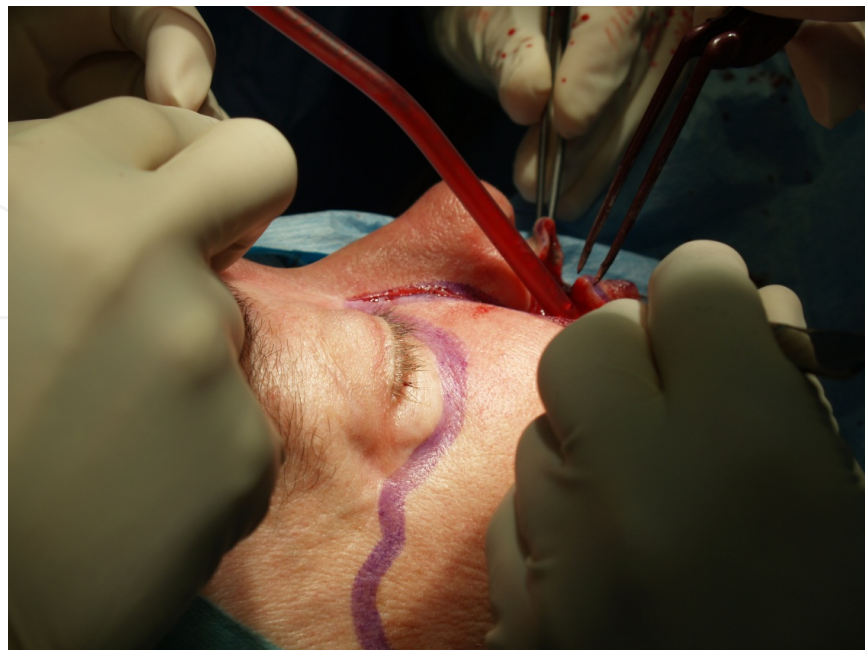**Figure 15.** Case 1. Massive orbital carcinoma with co-existing active tuberculosis– intraoperative view. Lateral rhinotomy + superior orbitotomy + subfrontal approach (The photo was taken on patient's agreement).



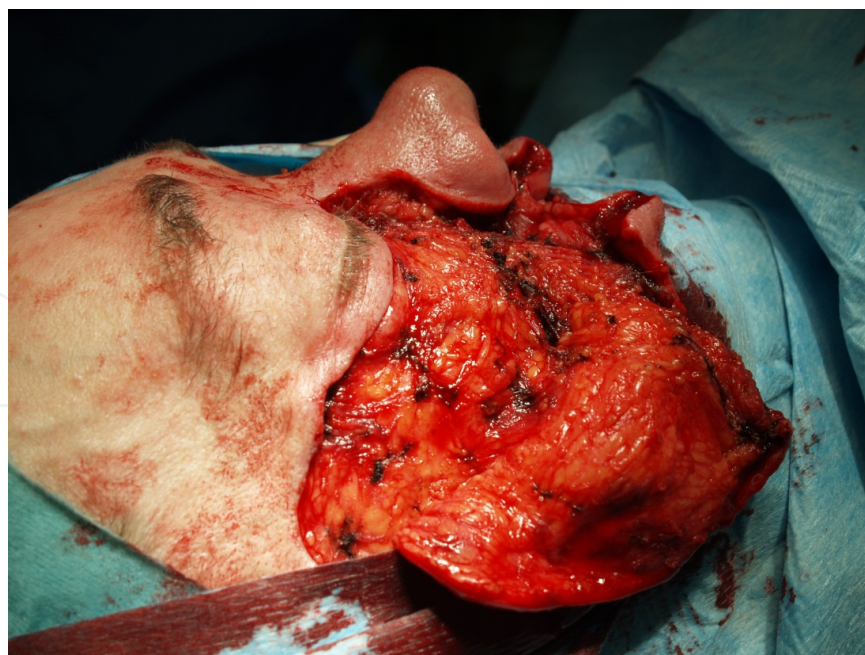**Figure 16.** Case 1. Massive orbital carcinoma with co-existing active tuberculosis– postoperative CT scan.



**Figure 17.** Case 2. Incision line (lateral rhinotomy+ inferior orbitotomy + Fairbanks- Barbosa's approach)of modified approach to massive carcinoma of maxillo-ethmoidal complex – pre-operative image (The photo was taken on patient's agreement).

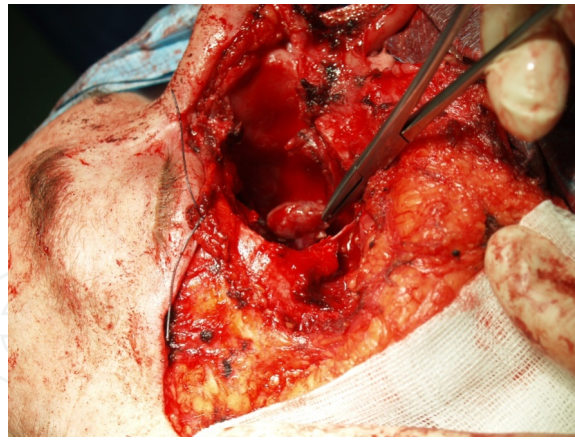


**Figure 18.** Case 2. Incision line of modified approach to massive carcinoma of maxillo-ethmoidal complex – interoperative image

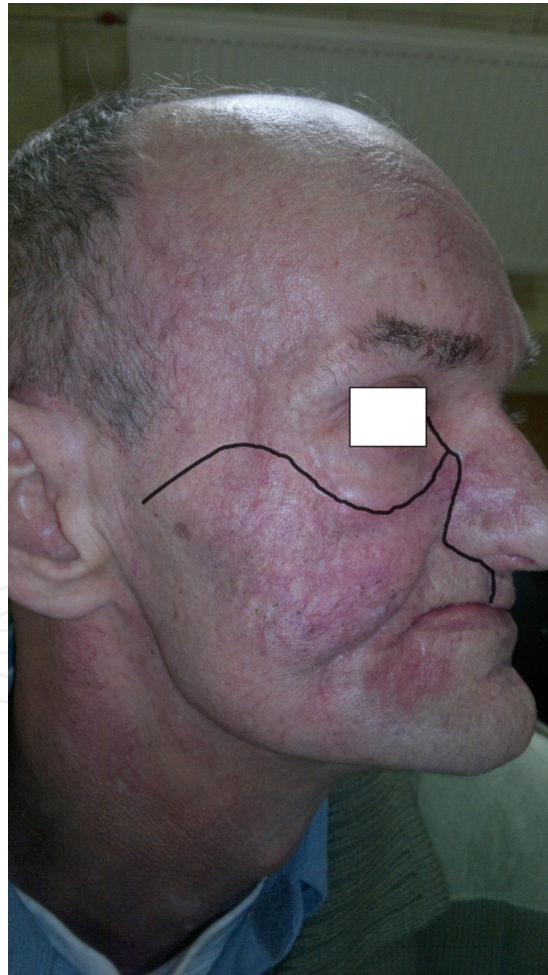

**Figure 19.** Case 2. Incision line (lateral rhinotomy+ inferior orbitotomy + Fairbanks- Barbosa's approach)of modified approach to massive carcinoma of maxillo-ethmoidal complex – interoperative image

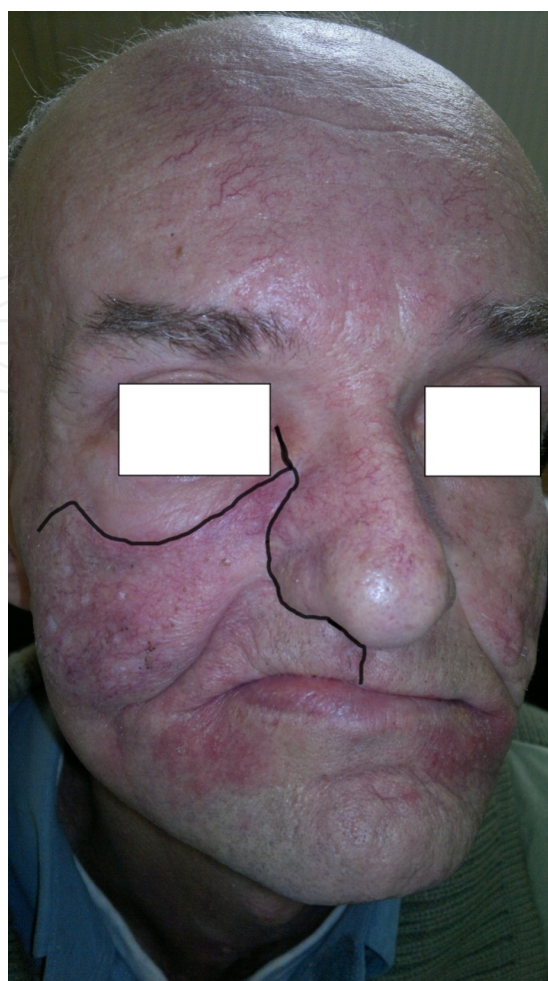



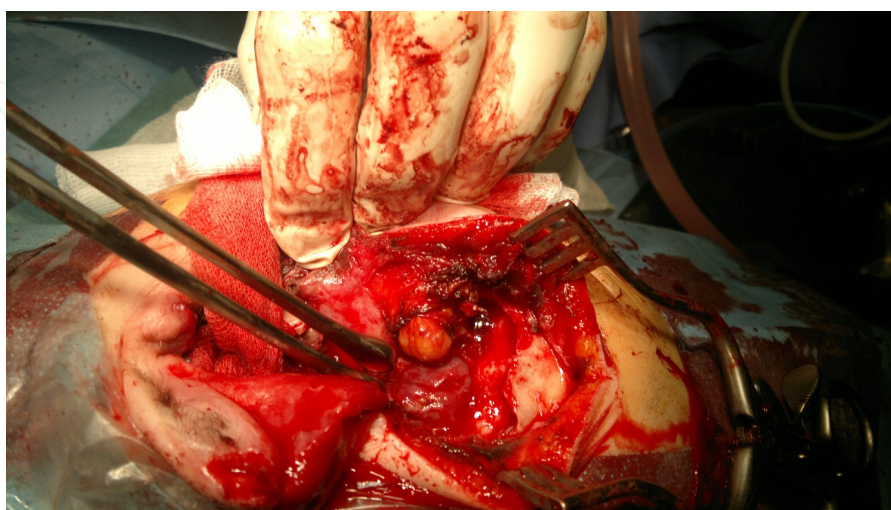
**Figure 20.** Case 2. Incision line (lateral rhinotomy+ inferior orbitotomy + Fairbanks- Barbosa's approach)of modified approach to massive carcinoma of maxillo-ethmoidal complex – interoperative image. The surgical tool indicated neo-plastic tissue.



**Figure 21.** Case 3. Incision line of modified approach to massive carcinoma of maxillo-ethmoidal complex – post-operative image (The photo was taken on patient's agreement).

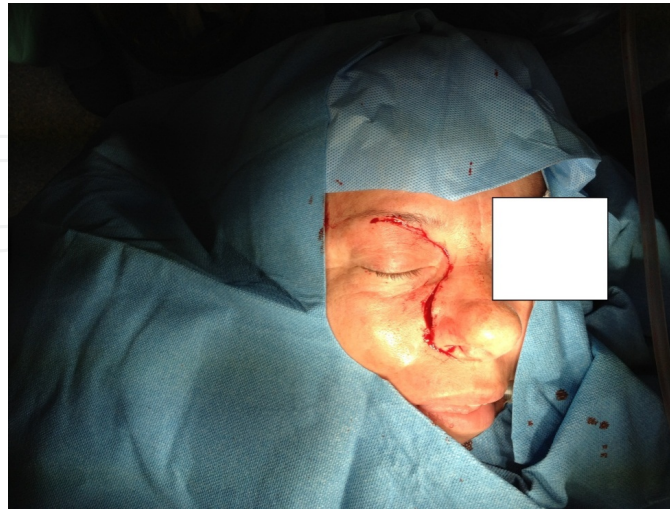

**Figure 22.** Case 3. Incision line of modified approach to massive carcinoma of maxillo-ethmoidal complex – post-operative image (The photo was taken on patient's agreement)

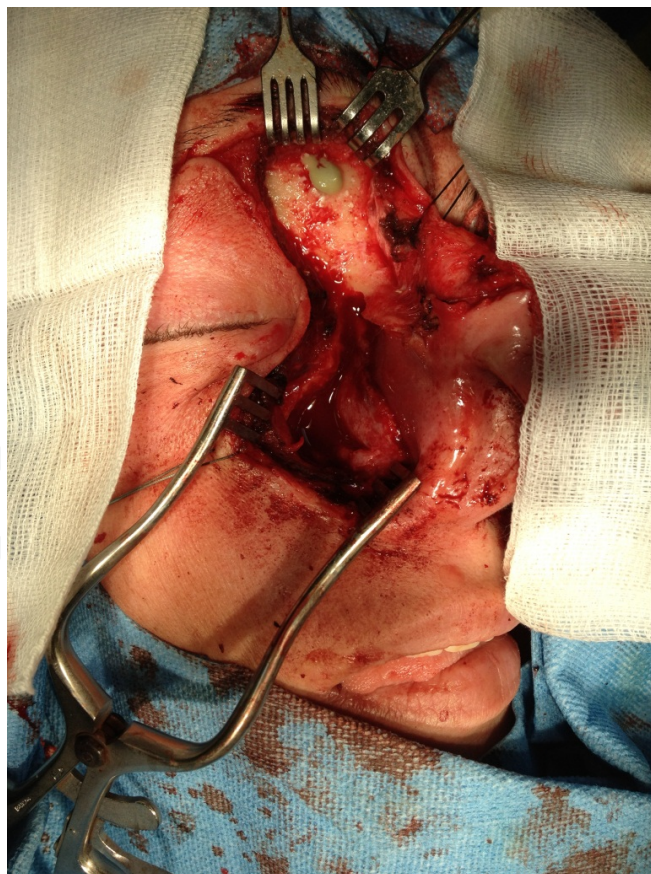


**Figure 23.** Case 3 - Intraoperative image (own archives)

In order to receive access to maxillo-ethmoidal complex and frontal sinus as well as anterior cranial fossa lateral rhinotomy combined with Uffendorfer's approach can be performed (Fig. 24-25)

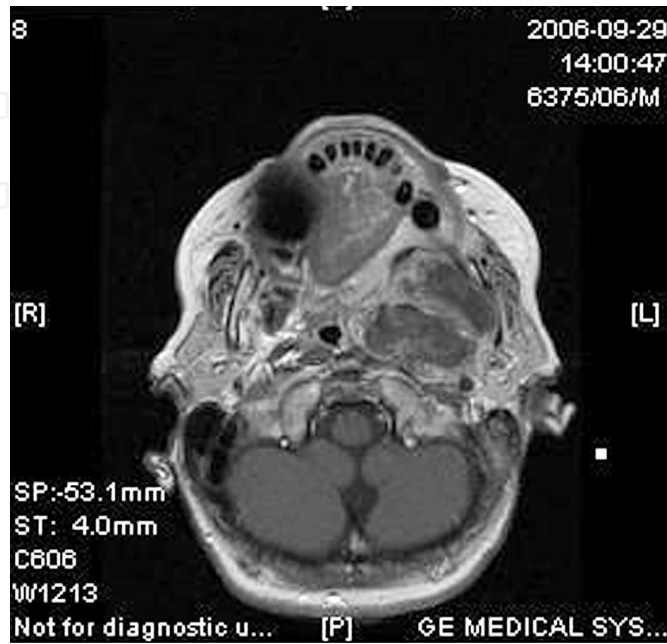


**Figure 24.** Case 4. Lateral rhinotomy + Uffendorfer scission line- intraoperative image (own archives).

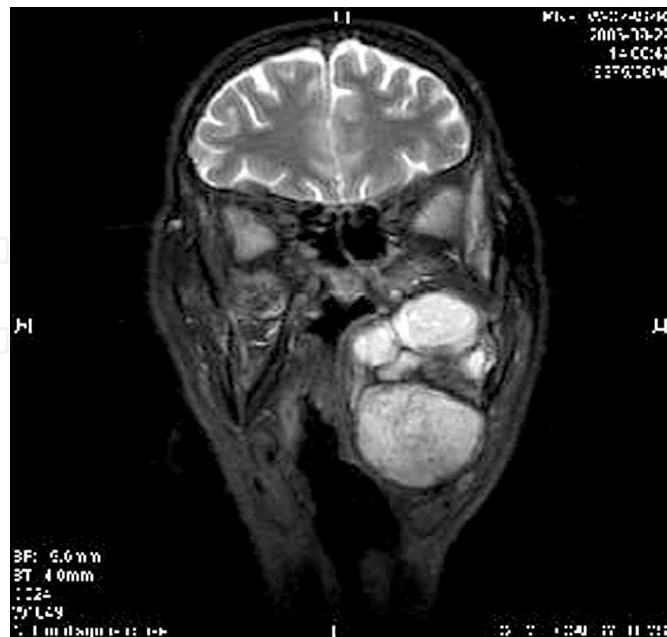

**Figure 25.** Case 4. Lateral rhinotomy + Uffendorfer section line – intraoperative image. Pus in frontal sinus. (own archives).

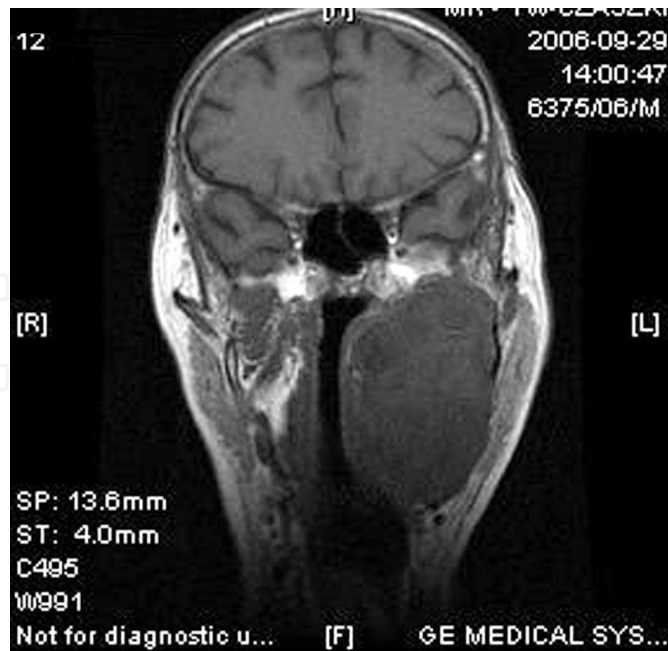
Another modification, such as Fairbanks-Barbossa's approach and lateral pharyngotomy can be used in order to perform surgical management of pathologies localized in the inferior part of Ohrngren's plane (Fig.26-28)



**Figure 26.** Case 5. A preoperative MRI scan showing tumour mass in left parapharyngeal region with pterygopalatine fossa and skull base penetration. Tumour reaches the level of lower wall of left maxillary sinus and infratemporal region.




**Figure 27.** Case 5. A preoperative MRI scan showing a substantial mass effect – tumour mass bulges towards nasopharynx and mesopharynx causing compression and displacement of those structures.



**Figure 28.** Case 5. A preoperative MRI scan showing tumour mass directly adjacent to the sphenoid bone and left parotid gland.

### 4.3. Other surgical aspects

In advanced neoplasms the operation is combined with simultaneous reconstruction of damaged areas, while in case of residual tissues an implantation of intraoperative applicators for brachytherapy might be used (Fig.29.). It is also possible to initiate adjuvant radiotherapy without reconstructive surgery.



**Figure 29.** Case 1. Applicators of brachytherapy implanted intraoperatively. Teletherapy was impossible to be performed due to active tuberculosis. Follow-up- 2,5 years without recurrence.

However, reconstructive surgery with vascular microanastomosis seems to be the priceless method of treatment, resulting in good functional and aesthetic effect.

Occasionally, it is essential to obliterate mechanically the vessel providing blood to traumatised region and/or use temporary or permanent endovascular embolization (esp. internal jugular vein) as the first step of therapeutic procedure. A wide drainage to nasal cavities is crucial for proper healing of inflammations or inflammatory complications of orbit and pterygopalatine fossa.

Also, the authors indicate that in the described region there is a risk of expanding the neoplastic and/or inflammatory tissue into 'critical structures' such as meninges, optic nerve, internal carotid artery, facial nerve and sinus cavernosus limits safe course of surgical procedures. The situation reveals due to natural extension of neoplastic and/or inflammatory tissue, intraoperative failure or high-dose radiotherapy. The presence of critical structures limits safe course of surgical procedure.

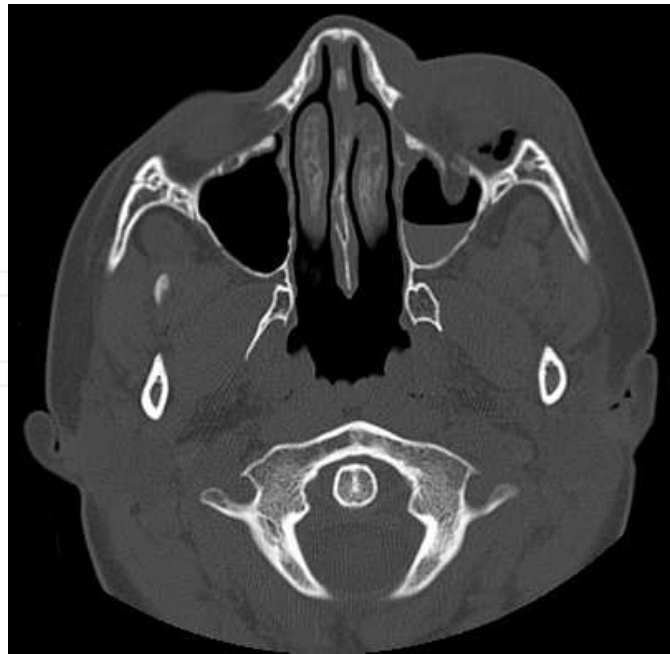It is also worth mentioning that in the course of chronic and, rarely, acute pansinusitis orbital complications are observed in 3,7-11 % of all patients hospitalized due to pansinusitis and they are associated with symptoms such as blurred vision, diplopia, deterioration of visual acuity, oedema of palpebra and oedema of the tissues of medial angle of the eye. In advanced situations exophthalmia may occur. The process can extend into extraorbital structures resulting in their oedema and phlegmons and/or abscess of the orbit. HRCT plays the greatest role in diagnosis. Surgical treatment consists of external opening of many sinuses and excision of the pathological tissues in the orbit. Ophthalmological examination with assessment of visual acuity, morphology of the eyeball and possible damage of optical nerve is essential in preoperative diagnosis of above cases. Optic nerve and sinus cavernosus are 'critical structures in surgical management of this limited region.

A separate subdivision should be dedicated to blow-out fracture which is an orbital floor fracture due to blunt trauma of the head. Very fine bones of this region, in case of their fracture, cause an entrapment of the orbital content (i.e. extraocular muscles, esp. inferior rectus and inferior oblique) in maxillar sinus. A damage of infraorbital canal with infraorbital nerve is often observed and in such case numbness in the region of lower eyelid, cheek, lateral part of nose, upper labium, upper teeth and gingivia can be diagnosed.

Symptoms include:

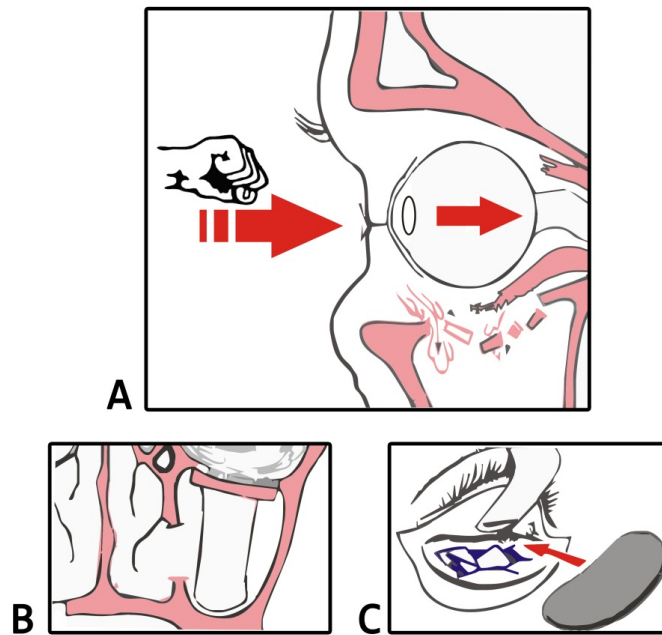
- enophthalmos
- diplopia
- pain during eye movement
- limited movements of eyeball

Computed tomography scanning is preferred in diagnosis of blow-out fractures (Fig.30)



**Figure 30.** CT scan- blow-out fracture.

In surgical management of blow-out fractures resection of the injured bone is performed by orbitotomy or an approach through maxillar sinus. Reconstruction consists of autogenic grafts (fascia, bone graft) or allogenic ones (silicon, Teflon) (Fig.31.)



**Figure 31.** A- Blow-out fracture- patomechanism, B- bone graft inserted through nasal cavity, C- allogenic graft inserted subciliarily

In most cases oculoplastic surgeons will wait 10-14 days following the trauma in order to enable an associated oedema and/or haemorrhage to be absorbed.

## 5. Results

The results of surgical management of tumors of described region depend on primary clinical staging assessed with TNM scale, the stage of malignancy, presence of associated disorders and patient's age. Survival rates depend on above factors and application of adjuvant oncologic treatment utilizing teletherapy, brachytherapy, chemical cytoreduction and combination of suggested methods.

In summary the authors emphasise the necessity of interdisciplinary treatment of orbit and maxillo-ethmoidal complex.

## Author details

Jarosław Paluch<sup>1</sup>, Jarosław Markowski<sup>1</sup>, Jan Pilch<sup>1</sup>, Agnieszka Piotrowska – Seweryn<sup>1</sup>, Robert Kwiatkowski<sup>2</sup>, Joanna Lewin-Kowalik<sup>3</sup>, Czesław Zralek<sup>4</sup> and Agnieszka Gorzkowska<sup>5</sup>

1 Department of Laryngology, Medical University of Silesia, Katowice, Poland

2 Radiotherapy Division, Katowice, Poland

3 Department of Physiology, Medical University of Silesia, Katowice, Poland

4 Department of Neurosurgery, Medical University of Silesia, Katowice, Poland

5 Department of Neurology, Medical University of Silesia, Katowice, Poland

## References

- [1] Bulsara, Ketan R.; Al-Mefty: Skull Base Surgery for Benign Skull Base Tumors; *Ossama. Journal of Neuro-Oncology* vol. 69 issue 1-3 August 2004. p. 181 – 189.
- [2] Byron J. Bailey : Head and neck surgery – Otolaryngology, Volume Two, J.B. Lippincott Company Philadelphia, 1993, 1110-1125
- [3] Chen T. William: Oculoplastic surgery. The essentials; Thieme New York 2001; ISBN 1-58890 – 027-4; 419-451
- [4] Handerson J.W.: Orbital Tumors, ed 3. New York: Raven Pres, 1994



- [5] Hastan D, Fokkens WJ, Bachert C et al. Chronic rhinosinusitis in Europe - an underestimated disease. A GA2LEN study. Allergy 2011; Published online ahead of print, May 2011
- [6] Hussain A, Hulmi OJ, Murray DP: Lateral rhinotomy through nasal aesthetic subunits. Improved cosmetic outcome; *J Laryngol Otol.* 2002 Sep;116(9):703-6.
- [7] Kennerdell JS, Maroon JC, Celin SE. :The posterior inferior orbitotomy; *Ophthal Plast Reconstr Surg.* 1998 Jul;14(4):277-80.
- [8] Kyuha C., Taeyun K., Kyungsun C., Myunghwan C., Jonghee Y., Chulhee C.: Diagnostic Techniques and Surgical Management of Brain Tumors, Current Optical Imaging Techniques for Brain Tumor Research: Application of in vivo Laser Scanning Microscopy Imaging with a Cranial Window System, ISBN: 978-953-307-589-1 , InTech 2011:155-172
- [9] Lund VJ, Stammberger H, Nicolai P, Castelnuovo P, Beal T, Beham A, Bernal-Sprekelsen M, Braun H, Cappabianca P, Carrau R, Cavallo L, Clarici G, Draf W, Esposito F, Fernandez-Miranda J, Fokkens W, Gardner P, Gellner V, Hellquist H, Hermann P, Hosemann W, Howard D, Jones N, Jorissen M, Kassam A, Kelly D, Kurschel-Lackner S, Leong S, McLaughlin N, Maroldi R, Minovi A, Mokry M, Onerci M, Ong YK, Prevedello D, Saleh H, Sehti DS, Simmen D, Snyderman C, Solares A, Spittle M, Stamm A, Tomazic P, Trimarchi M, Unger F, Wormald PJ, Zanation A; European Rhinologic Society Advisory Board on Endoscopic Techniques in the Management of Nose, Paranasal Sinus and Skull Base Tumours: European position paper on endoscopic management of tumours of the nose, paranasal sinuses and skull base; *Rhinol Suppl.* 2010 Jun 1;(22):1-143.
- [10] Margarino G., Scala M. , Mereu P., Comandin D.i, Schenone G., Galli A., Francaviglia N., Gipponi M.: Combined craniofacial approach to facial tumours involving the anterior skull base; *European Journal of Surgical Oncology (EJSO)* Volume 22, Issue 4, August 1996, Pages 361–365
- [11] Mingkun Y., Wei Y., Xiangqian Q, Jun Q., Zhenyang L., Wenfeng F. : "Diagnostic Techniques and Surgical Management of Brain Tumors", *Imaging Techniques in Brain Tumor*, ISBN 978-953-307-589-1, InTech 2011:43-66
- [12] Morioka M, Hamada J, Yano S, Kai Y, Ogata N, Yumoto E, Ushio Y, Kuratsu J: Frontal skull base surgery combined with endonasal endoscopic sinus surgery; *Surg Neurol.* 2005 Jul;64(1):44-9; discussion 49.
- [13] Neumann H.H., Tardy M.E., Jr, Kastenbauer E.R.: *Head and Neck Surgery. Volume 1, Face, Nose and Facial Skull, Part II*; Georg Thieme Verlag, Stuttgart, New York 1995, ISBN 3-13-547102-0, ISBN 0-86577-586-9: 476-498, 555-609
- [14] Paluch J., Markowski J., Gierek T., Pencak P., Witkowska M., Kajor M., Gorzkowska A., Piotrowska A.: *Resonance Tractography in Neuroradiological Diagnostic Aspects, Diagnostic Techniques and Surgical Management of Brain Tumors*, ISBN 978-953-307-589-1, InTech 2011: 199-204

- [15] Silver C.E. Atlas of Head and neck surgery; Churchill Livingstone, New York, Edinburgh, London, Melbourne 1986
- [16] Słoniewski P., Dzierżanowski J, Lipowski P., Szmuda T., Czapiewski P.: Orbital tumours operated by orbito-cranial approaches- results of treatment of 38 patients; Ann. Acad. Med. Gedan., 2010, 40, 81-89
- [17] Snyderman CH, Carrau RL, Kassam AB, Zanoian A, Prevedello D, Gardner P, Mintz A: Endoscopic skull base surgery: principles of endonasal oncological surgery; J Surg Oncol. 2008 Jun 15;97(8):658-64.
- [18] Spaeth G.L.: Chirurgia okulistyczna. Wyd.I polskie pod redakcją Jerzego Szaflika, Urban & Partner, Wrocław 2006, ISBN -10-8389581-1, ISBN -13-978-83-89581-53-2; 457-471
- [19] Szyfter W.: Nowotwory w otorynolaryngologii; Termedia Wydawnictwa Medyczne, Poznań 2012, ISBN: 978-83-62138-80-7; 139-144, 366-369
- [20] Ulgen T, Turhan T, Yurtseven T, Oner K.: Simple anterior orbitotomy; Minim Invasive Neurosurg. 2004 Apr;47(2):115-8.
- [21] Zhou W, Fang J, Ni X, Huang Z, Wang Q, Chen X, Chen XZ, Xu H: The modified rhinotomy for treatment of tumors involving skull base; Lin Chung Er Bi Yan Hou Tou Jing Wai Ke Za Zhi. 2010 Apr;24(7):301-3.

