

We are IntechOpen, the world's leading publisher of Open Access books Built by scientists, for scientists

4,800

Open access books available

122,000

International authors and editors

135M

Downloads

Our authors are among the

154

Countries delivered to

TOP 1%

most cited scientists

12.2%

Contributors from top 500 universities



WEB OF SCIENCE™

Selection of our books indexed in the Book Citation Index
in Web of Science™ Core Collection (BKCI)

Interested in publishing with us?
Contact book.department@intechopen.com

Numbers displayed above are based on latest data collected.

For more information visit www.intechopen.com



The History of Detecting Glaucomatous Changes in the Optic Disc

Ivan Marjanovic

Additional information is available at the end of the chapter

<http://dx.doi.org/10.5772/52470>

1. Introduction

At the present time it is much easier to recognize and to assess glaucomatous changes at the optic nerve than it used to be. This is possible thanks to modern devices and imaging techniques that allow much faster and better diagnosing. Even today, the single most important thing in this matter is to know the characteristics of the normal -healthy optic disc (Figure 1.). The appearance of the optic disc, as in the other biological variables varies widely among healthy individuals. This fact complicates the recognition of the pathological changes.

Today modern glaucoma diagnostic is unimaginable without technological support, when it comes to discovering as well as for following up glaucoma optic neuropathy.

With standard clinical exam aside, there is a number of imaging devices that we use in everyday practice, and to mention a couple i.e. CVF, HRT, GDX, OCT, PACHIMETRY, FUNDUS PHOTOS, CDI... and we agree that without the help of this wide technological spectrum of supporting diagnostic devices we could not be able to diagnose the disease or to track the glaucoma changes. Just stop for a second and remember how it was in the old days? Let's take a glance of the old days and how it all started?

There was the time when ophthalmologist did not have those sophisticated imaging devices; they even did not have slit lamps... despite the fact that they were glaucomatologists!

This chapter is dedicated to the pioneers of ophthalmology and glaucomathology; their legacy for future glaucomatologists.

The term optic disc is frequently used to describe the portion of the optic nerve clinically visible on examination. This, however, may be slightly inaccurate as 'disc' implies a flat, 2 dimensional structure without depth, when in fact the 'optic nerve head' is very much a 3 dimensional structure which should ideally be viewed stereoscopically.

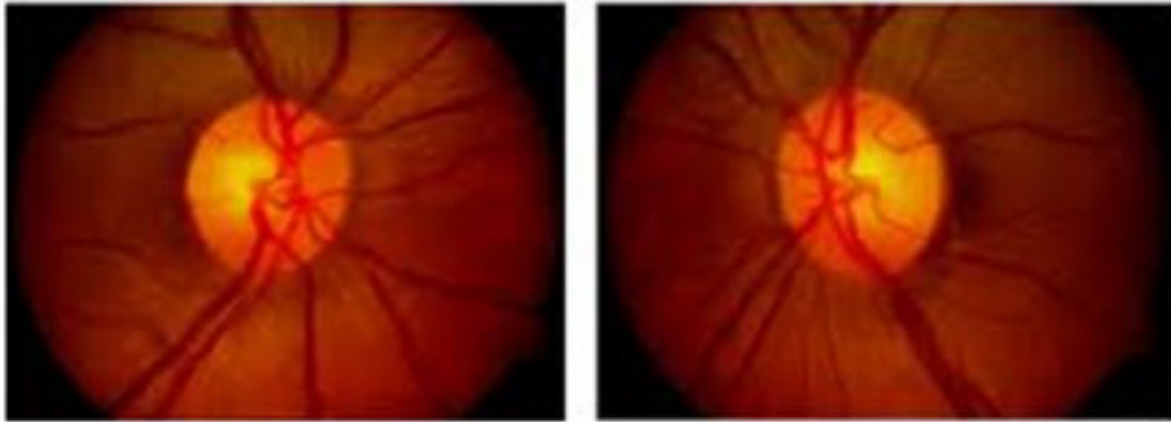


Figure 1. Healthy optic disc

Every disease has its history, as much in diagnosing-discovering it, as in quality and adequate treatment. History of the diseases categorized today under the term “glaucoma” may be divided into three major periods. First period is the earliest and it stretches from approximately 400 BC up until 1600 AD; during the course of this period the term “glaucoma” was used to refer to a general group of blinding ocular diseases without the distinctions that historians now can recognize. During the middle period from the beginning of the 17th century to the middle of the 19th century the cardinal signs of glaucoma, separately and in combination, were described in published texts. Finally, the third period starts with the introduction of the ophthalmoscope (Helmholtz, 1854) to the present.

1. First period (400 BC to 1600 AD)

Etymology of the term glaucoma is that it derives from the Greek word “glaukos”, which appears in the Homer’s notes, where it is mentioned as -a sparkling silver glare, later used for colours such as sky-blue or green. As a diagnosis by physicians, glaucoma is first mentioned in Hippocrates’ *Aphorisms* (Figure 2.), lists among the infirmities of the aged a condition he called “glaucosis” which he associated with “dimness of vision”. Later Aristotel did not mention any diseases called glaucoma particularly, although he helped create the foundation for research into the pathology of the disease, thus giving his contribution to early glaucoma research.

It is interesting that most authors, by the Roman era, used the term *glaucoma* for what is now known as *cataract*. For example, Oribasius (325-400 AD) quotes Ruphus from Ephesus (1st century AD) as using the term for “that condition of the crystalline body in which the same loses its original colour and instead becomes blue-grey”.

However, Archigenes, who practised at Rome in the time of Trajan (98-117 AD), used the term “ophthalmosglaukos” for a curable blindness that was not caused by cataract.

Archigenes revealed that he used the juice of the deadly nightshade, a mydriatic, in the treatment of this condition, adding, “the instilled juice of nightshade makes black the grey eyes.”

Galen (129-216 AD), (Figure 3.) defined glaucoma as a condition in which changes in fluids of the eye caused the pupil to become grey. He also refers to the mydriatic effect of nightshade.

Aetius, the physician of the emperor Justinian (482-565) AD, and a great Ophthalmologist, identified two forms of glaucoma, one a curable condition of the lens and the other an incurable condition that involved an effusion in which the pupil becomes thickly coagulated and dried.



Figure 2. Hippocrates (c.460 B.C.-c. 370 B.C.), a famous Greek physician, and the father of Medicine, who first used the term 'glaucosis' in his work 'Aphorisms' to describe conditions correlated with blindness and possibly glaucoma

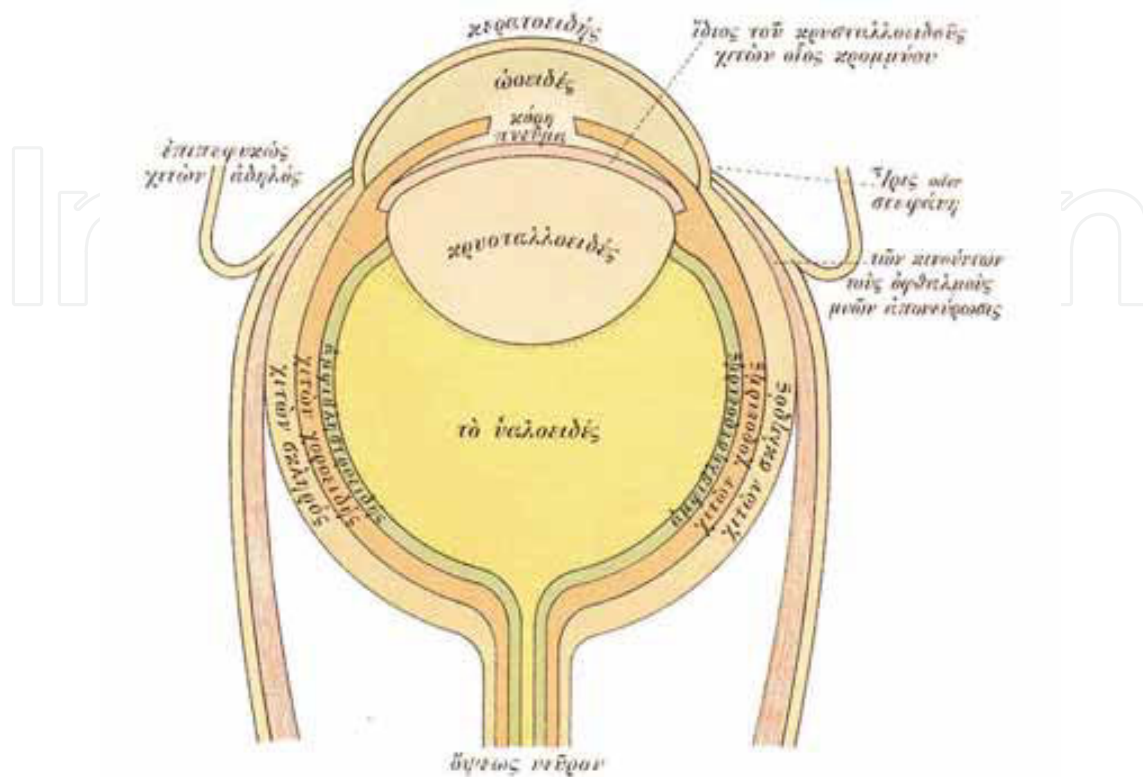


Figure 3. Anatomy of the Eye, according to Galen as the Arabs transferred to the West

2. Second period (1600 TO 1854)

This period is marked by the rising awareness among ophthalmologists that technology is a key to a proper diagnostic.

Glaucoma became more distinct when it comes to adult or elderly patients with the emergence of four characteristics: (1) the consistent failure of cataract operations to improve vision, (2) the clinical appearance of eyes in terminal stages of the disease, (3) a specific history indicating self-limited forerunners of the severe disease, and (4) the elevated intraocular pressure.

Important breakthrough in ophthalmology is marked with the anatomic findings of Brisseau (1707) and the introduction of the process of lens extraction by Daviel (1752). This led to a search for the site of glaucoma in other structures of the eye and to concentration on clinical signs that could be helpful in distinguishing between cataract and glaucoma. Since a majority of the eyes in which the diagnosis of glaucoma was made in the 18th century were in an advanced stage of visual loss and iris atrophy after one or several acute attacks or after a prolonged chronic course, the clinical picture was dominated by congestion (varicosities) of the anterior ciliary veins, a dilated, poorly reacting pupil, and a varying degree of nuclear lens opacity. On examination with the light sources of that period, a greenish reflection

could often be obtained; since this seemed to point to the real location of the disease, it became a prominent sign listed in the literature of the 18th and early 19th centuries.

The clinical features of advanced glaucoma, occasionally preceded by attacks of blurred vision that recurred with a high degree of uniformity, was first recorded in St. Yves' "Treatise of the Diseases of the Eyes" (1741) and was described in more detail by Weller (1826).

It is a well known fact that elevation of the intraocular pressure as a distinct sign of ocular disease, recognizable by undue resistance of the eyeball to indentation by the physician's finger, was first clearly mentioned in the "Breviary" of the itinerant English oculist Banister (1626). In 1738 an equally clear reference to hardness of the eye appeared in the independent writings of Johann Platner, professor of anatomy, surgery, and therapeutics at the University of Leipzig. As a distinct clinical symptom, hardness of the eyeball was apparently generally known and accepted in the 1820s, as one may judge from the almost simultaneous but independent texts by Demours of France (1818), Guthrie of England (1823), and Weller of Germany (1826).

William Mackenzie[1] had a great influence on European and American ophthalmology through his personal teaching and through his textbook, between 1830. and 1854. He distinguished between acute and chronic glaucoma and gave a detailed description of the course of the latter from a stage 1 characterized just by a greenish hue reflected from the pupil to a stage 6 in which the eyeball, after perforation of a corneal ulcer in absolute glaucoma, has become atrophic. Mackenzie was well aware of the abnormal hardness of the glaucomatous eye from the second stage on; also, he apparently was the first to recommend a form of posterior sclerotomy to relieve the abnormal hardness.

Duke-Elder in his *System of Ophthalmology*, also, in detail described this second period[2].

2. Third period (1854. to the present day)

With Eduard Jaeger, the grandson and son of distinguished Austrian ophthalmologist, began modern ophthalmology and modern ophthalmic exam. He was the first investigator who described and documented with the picture, ophthalmoscopic appearance of the glaucomatous disc in the literature. It was a picture from the monocular indirect ophthalmoscope, on which was described the glaucomatous disc as a swelling of the papillary tissues with respect to the surrounding retina[3].

Just a few months later, Albrecht von Graefe also described a prominence of the papilla in glaucoma[4]. His description of the optic disc, specially his description of the pulsation of the arteries in the glaucomatous eyes, became reliable and, at time, reliable indicator of elevated intraocular pressure. The ring-shaped zone around the disc was officialy named - *halo glaucomatosus*. At the von Graefe's clinic, after many examinations on rabbits with congenital fundus anomalies (i.e. coloboma of the uvea an optic nerve), examiners could not agree from ophthalmoscopic examinations whether observed parts of the fundus are elevated or depressed. The anatomic examination revealed tissue depression. This was confirmed by von Graefe's assistant, Adolf Weber[5], who will later in his life made significant contributions to the understanding of the mechanisms of glaucoma. His analysis of the monocular indirect

ophthalmoscopy revealed several factors, partly optic and partly perceptual, which caused misinterpretations of relative depth in the fundus.

Later, pathological findings confirmed ophthalmoscopic findings of the optic disc depression, what was interpreted as an effect of the elevated intraocular pressure, or- *pressure excavation of the papilla*. This had profound effect on von Graefe's theory and made him examine all known symptoms of glaucoma and their link with elevated intraocular pressure. This research turned intraocular pressure from a simple symptom to an "essence" of glaucoma.

Early classification of glaucoma was made at von Graefe's clinic.

First type of glaucoma was acute or inflammatory, which characterized with self-limited prodromal attacks of misty vision (in 70 % of the cases), patient is seeing rainbows around the candle flame; attacks increased in severity, length and frequency until the real disease suddenly erupted in the form of an acute attack of inflammation and severe reduction of vision. Partial vision recovery with temporary remission mostly occurred spontaneously or responding on a treatment with large doses of opiates, antiphlogistics and paracentesis. Many penetrating exams were carried out during the remissions. After analysis of all phases of this type of glaucoma, von Graefe made a concept according which an acute glaucoma is: "achoroiditis or an iridochoroiditis, with diffuse impregnation of vitreous and aqueous with exudative material which caused the rise in pressure through an increase in volume."

Second type was the chronic glaucoma. Prodromal attacks were without any sign of irritation, congestion or swelling; lengthen gradually and fused in a chronic form, characterized with the anterior ciliary veins dilatation, shallow anterior chamber, iris atrophy, glaucomatous cupping, arterial pulsation in the fundus; followed with reduction in vision.

The third type von Graefe simply named amaurosis with excavation of the optic nerve, and for him it was not in a group of glaucomatous diseases[6]. Normal anterior segment, with optic disc excavation, which lead to the vision impairment.

Completing this classification, von Graefe used the designation *glaucomatous diseases* for a disorders or conditions which secondarily lead to glaucoma and thereby may result in blindness.

In the late period of his research (1861.), von Graefe declared that an exclusion of amaurosis with the optic disc excavation from the group of glaucoma diseases was a mistake[7]. This correction he credited to Doners of Utrecht, his friend, who found a palpable tension among many eyes with so-called amaurosis with optic nerve excavation to be significantly above normal. Doners, after his research, prepositioned a term *glaucoma simplex*, for the glaucoma without anterior segment manifestations and other complications, and *glaucoma with ophthalmia*, for those disorders where other manifestations appeared, especially in the anterior segment. The common cause of all glaucoma-the elevated intraocular pressure, Doners ascribed to a hyper secretion of intraocular fluid due to irritation of secretory nerves.

It is interesting that von Graefe discovered also an ocular hypertension patients among his amaurosis with optic nerve excavation cases. He accepted Doner's term glaucoma simplex.

His posterity, first of all Schnabel[8], had verb his amaurosis with optic nerve excavation, implying that it was an optic nerve disease unrelated to elevated intraocular pressure.

Theory of inflammation, that von Graefe's proposed as a cause of intraocular pressure rise and a name of that type of glaucoma held until the clinical discovery of the angle closure mechanism in the 20th century. Some of the alternative terms that were used are: "irritative" (de Wecker[9]), "congestive" (Hansen-Grut), and, much later, "uncompensated" (Elschnig).

The Anglo-Saxon literature preferred terms as acute, subacute and chronic glaucoma

Finally, von Graefe in his last communication (1869), for the first time introduced a terms *primary* and *secondary glaucoma*.

2. Glaucoma – An optic nerve disease

In the late 1850s, German anatomist Heinrich Mueller[10] was the first who granted ophthalmoscopically observed depression of the optic disc. In his theory that was a result of an abnormally increased vitreous pressure acting upon the lamina and forcing it to recede. Mueller and his followers assumed that the receding lamina had taken the entire papilla with it, placing the nerve fibres on a steadily increasing stretch or pressing them against the sharp edge of the excavation. Consequence of that was optic nerve atrophy.

Considering that this concept was not uniform for all glaucomatous eyes (in some cases pathologists confirmed the lamina cribrosa displacement, in others not), the theory was add to the basic pressure hypothesis and was widely accepted but also a new ophthalmoscopic and pathologic facts of glaucoma were revealed.

Austrian ophthalmologist Isidor Schnabel (1842-1908)[8] was the first to describe in detail the nerve fibre breakdown with the formation of cavities as a characteristic of the glaucomatous process in the optic nerve. It was the earliest sign and for a long time the only glaucomatous change. In later stages the atrophy affected all portions of the optic nerve up to the entrance of the central vessels. In his opinion, cavernous atrophy was *the* glaucomatous atrophy. Schnabel saw the mechanism of the glaucomatous optic nerve disease in a process of imbibition of pathologic fluid from the vitreous by the nerve fibres, a process independent of the intraocular pressure. His findings were partly confirmed and partly refuted by subsequent investigators.

Another perspective on the origin and nature of the glaucomatous optic neuropathy was introduced by Priestley Smith[11]. The glaucomatous cup is not a purely mechanical result of exalted pressure, but is in part at least, an atrophic condition which, though primarily due to pressure, includes vascular changes and impaired nutrition in the area of the disc and around its margin which require a considerable time for their full development.

This Priestley Smith's original notion that the rise in pressure may cause damage to the tissues of the disc through its influence on blood circulation is valid until the present day.

3. Ocular hypertension – The mechanisms

Previously mentioned essence of glaucoma, recognized in the mid-1850s, attributed to excessive formation of intraocular fluid or hyper secretion and assumed to either a type of choroiditis (von Graefe) or a secretory neurosis (Donders).

The clear concept of the eye mechanisms that were involved in the intraocular pressure production, in that time, was not plain. German anatomist Schwalbe¹² began in 1860s the experimental study of the fluid exchange of the eye, searching the lymphatics in the anterior segment. When the dye is injected into the anterior chamber of the eye, in aqueous solution or suspension, it appears promptly in veins on the surface of the globe! His conclusion was that the anterior chamber is a lymphatic space in open communication with anterior ciliary veins.

Theodor Leber¹³ also injected dyes into the anterior chamber of the eye of a rabbit, and discriminated certain border structures. This disclosure stimulated many investigators of that time, including Leber, to investigate a cannular system and Schwalbe, to investigate the anterior chamber angle in animals. Thus Leber discovered normal outflow (on a fresh enucleated mammalian eye), he presented it as a filtration through the trabecular meshwork and a flow through ciliary and vortex veins. His conclusion was that the rate of outflow was, in principle, proportional to the perfusion pressure, except during an initial period, when the perfusion fluid took up the space occupied in the living eye by blood. He actually determined filtration coefficients, the forerunners of today's coefficients of aqueous outflow.

Since this outflow was from fresh enucleated eyes at the pressures prevailing in the living eye, Leber reasoned that the same process of outflow must also take place in the normal living eye. To maintain a stable in vivo pressure, the steady loss of fluid must be compensated for by steady formation of an equal amount of fluid, which Leber believed could also take place through a process of filtration. Thus, the filtration theory of aqueous formation and elimination was born. In a few human eyes enucleated in far-advanced stages of glaucoma, Leber found very low filtration coefficients which indicated abnormal resistance to aqueous outflow[14]. This finding fitted in well with the first detailed pathologic report on the condition of the chamber angle in far-advanced glaucoma[15]: "The most important finding in genuine glaucoma is the circular adhesion of the iris periphery to the periphery of the cornea or the obliteration of the space of Fontana."*

**Although Kieser of Göttingen had clearly shown in 1804 that the spaces described by Fontana in the eyes of herbivores did not exist in man, the term "Fontana's space" was still used in the 1870s and 1880s for the intertrabecular spaces of the human corneoscleral meshwork. Only the detailed studies of the region begun by Schwalbe in 1870 and continued by others made the term "Fontana's space" clearly inapplicable to the human eye.*

Considering that in either case glaucoma could result from an inflammatory or an obstructive process within the angle or from pressure from behind. It was realized almost immediately that the peripheral anterior synechiae could be either the cause or the effect of glaucoma. Pathologic specimens which supported these mechanisms were identified and re-

ported. The theory that glaucoma was principally a disorder of aqueous outflow (referred to generally as the Leber-Knies theory) rapidly gained ground.

The essence of the Leber's (Leber-Knies) filtration theory has stood the test of time. Leber's best apprentice, Erich Seidel, in 1920's, made some necessary additions to this theory, including the effects of the colloid osmotic pressure of the plasma proteins and of active transfer processes in the formation of aqueous[16].

Interesting appendage is that the essence of the Leber's theory, the idea, admittedly without experimental proof, of a steady directional circulation of fluid through the chambers of the eye had been expressed by earlier observers, specifically William Porterfield, more than 100 years before Leber.

4. Glaucoma mechanisms

During 1880s and 1890s, it was observed that chronic inflammatory glaucomas composed two thirds of all glaucomas. Angle closure glaucomas were dominant. Priestley Smith measured the horizontal corneal meridian in normal eyes 11.6mm and in glaucomatous eyes 11.2mm[17], what expressed dominance of the angle closure glaucoma in that period. 1888. Priestley Smith also introduced the concept of a predisposition to glaucoma, which consists in progressive narrowing of the circumferential space with age, due to the steady growth of the lens in eyes with small corneas. Anatomically, the ciliary processes in states of hyperaemia are crowded forward, pressing the iris against the anterior angle wall. This based on a Smith's experiment on the animal that a small excess of pressure in the vitreous chamber (as little as 4 mm Hg) makes the lens and the suspensory ligament advance in such a manner as to close the angle of the anterior chamber.

Next step was the discovery of shallowness of the anterior chamber as an important role in the mechanism of the acute glaucoma (in the eyes with acute inflammatory glaucoma)[18]. The description of the mechanism: if the pupil dilates in an eye with shallow anterior chamber, the iris, particularly with its thicker portion, can occlude the filtration angle and, thereby, raise the intraocular pressure. If contraction of the sphincter frees the filtration space, the event remains a prodromal attack. At a certain level of intraocular pressure the ocular veins are compressed at their place of entry into the sclera; venous stasis develops with increased transudation; that, and not inflammation, is the true nature of glaucoma.[18]

The Revolution on this field came in 1920. when Curran [19](Kansas City) and Seidel [16] (Heidelberg), on the basis of astute clinical observations, independently announced the concept of the relative pupillary block.

Curran's paper[19]: "normally the aqueous passes through the pupil from the posterior to the anterior chamber, but it is here contended that in glaucoma this passage is impeded on account of the iris hugging the lens over too great a surface extent. Some of the aqueous gets through while some passes back, forcing the lens and the iris still more forward. "

5. Ophthalmoscopy

Ophthalmoscopy, the most important single invention in ophthalmology, that had shaped its evolution, was introduced by Hermann von Helmholtz in December of 1850.[20] [21] However, Jan Purkinje (known for the Purkinje images) had described the complete technique and published it in Latin in 1823,[22] but his audience apparently was not yet ready and his publication went unnoticed. A quarter of a century later, however, the situation changed.

The ophthalmoscope was not based on any radically new concepts. Rather, it combined the appropriate application of various known principles with recognition of its potential impact and presentation to an appropriate audience. Under the leadership of men like Bowman in London, Donders in Holland, and von Graefe and von Helmholtz in Germany, ophthalmology emerged as the first organ-based specialty in medicine.

Bowman (1816 to 1892) is known for Bowman's membrane and for his work in anatomy and histology.

Donders (1818 to 1889) clarified the principles of refraction and accommodation (1864) and defined visual acuity as a measurable quantity. His coworker Snellen developed the Snellen chart.

In Berlin, Albrecht von Graefe (1828 to 1870) was a leader in stimulating the clinical application of new techniques and the careful documentation of new findings. He is remembered for Graefe's knife and Graefe's Archives (1854) (one of the first ophthalmic journals), and he founded the German Ophthalmological Society (Heidelberg, 1857).

Several workers had tried to visualize the inside of the eye but had fallen short of putting it all together. Kussmaul (known for "Kussmaul'sairhunger") described the imaging principles in a thesis in 1845[23] but failed to solve the illumination problem. Cumming[24](1846) in England and Brücke[25](1847) in Germany had shown that a reflection from the fundus could be obtained by bringing the light source in line with the observer, but they failed to solve the imaging problem. Babbage,[26] the English mathematician, reportedly constructed an ophthalmoscope in 1847, but his ophthalmologist friend did not recognize the importance and did not publish it until 1854, when von Helmholtz' instrument was well known.

In the fall of 1850, von Helmholtz tried to demonstrate the inside of the eye to the students in his physiology class. On December 6, he presented his findings to the Berlin Physical Society[20]; on December 17, he wrote to his father[27]:

"I have made a discovery during my lectures on the Physiology of the Sense-organs, which was so obvious, requiring, moreover, no knowledge beyond the optics I learned at the Gymnasium, that it seems almost ludicrous that I and others should have been so slow as not to see it.... Till now a whole series of most important eye-diseases, known collectively as black cataract, has been terra incognita.... My discovery makes the minute investigation of the internal structures of the eye a possibility. I have announced this very precious egg of Columbus to the Physical Society at Berlin, as my property, and am now having an improved and more convenient instrument constructed to replace my pasteboard affair..."

Helmholtz' monograph on ophthalmoscopy was published in 1851 and soon was widely circulated. The next year there were several important improvements contributed by other workers. Rekoss,[28] von Helmholtz' instrument maker, added two movable disks with lenses for easier focusing. Epkens, working with Donders in Holland,[27] introduced a perforated mirror for increased illumination. Ruete[29] in Germany did the same and also developed the indirect method of ophthalmoscopy. With these basic components in place, future generations provided technical improvements. In 1913, Landolt[30] listed 200 different types of ophthalmoscopes.

5.1. Direct ophthalmoscopy

If the patient's fundus is properly illuminated, the field of view is limited by the most oblique pencil of light that can still pass from the patient's pupil to the observer's pupil (Figure 4.). In direct ophthalmoscopy the retinal point that corresponds to this beam can be found by constructing an auxiliary ray through the nodal point of the eye.[30] The point farthest from the centerline of view that can still be seen is determined by the angle α , that is, the angle between this oblique pencil and the common optical axis of the eyes.

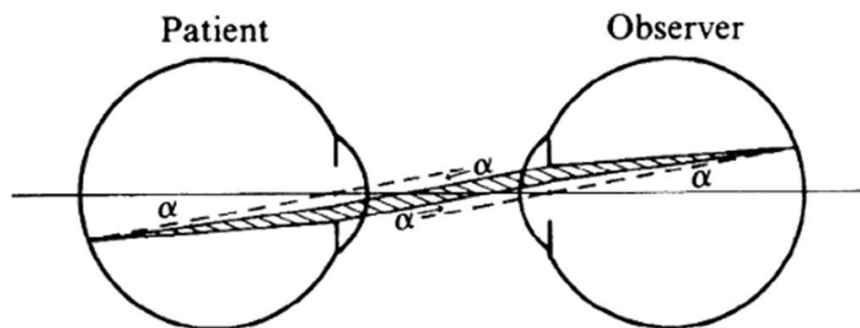


Figure 4. Field limits in direct ophthalmoscopy. The maximum field of view is determined by the most oblique pencil of rays (shaded) that can still pass from one pupil to the other.

Angle α , and therefore the field of view, is increased when the patient's or the observer's pupil is dilated or when the eyes are brought more closely together.

The more peripheral pencils of light use ever-smaller parts of each pupil. This means that, even if the patient's fundus is uniformly illuminated, the luminosity of the fundus image gradually decreases toward the periphery, so that there is no sharp limitation to the field of vision. In practice, therefore, the effective field of vision is determined by the illuminating system not by the viewing system. Most ophthalmoscopes project a beam of light of about one disc diameter.

5.2. Indirect ophthalmoscopy

Even with appropriate illumination, direct ophthalmoscopy has a small field of view (Figure 5.) shows that of four points in the fundus, points one and four cannot be seen because pencils of light emanating from these points diverge beyond the observer's pupil. To bring these

pencils to the observer's pupil, their direction must be changed (Figure 6). This requires a fairly large lens somewhere between the patient's and the observer's eye. This principle was introduced by Ruete[29]in 1852 and is called indirect ophthalmoscopy to differentiate it from the first method, in which the light traveled in a straight, direct path from the patient's eye to the observer.

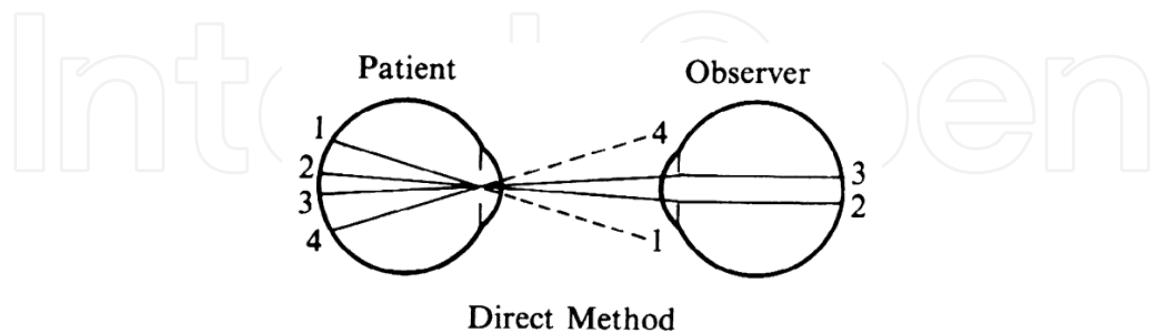


Figure 5. Limited field of view in the direct method. Peripheral pencils of light do not reach the observer's pupil.

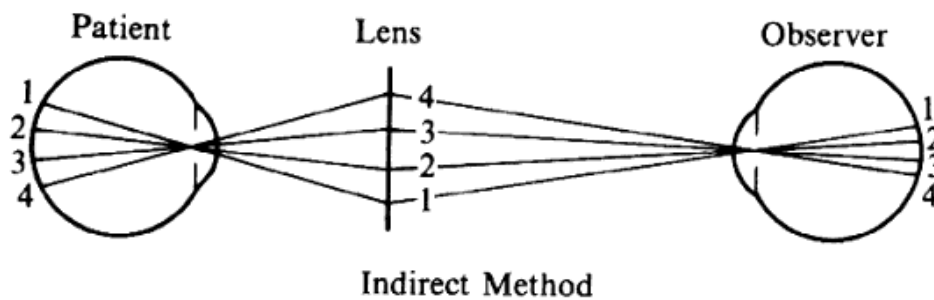


Figure 6. Extended field of view in the indirect method. The ophthalmoscopy lens redirects peripheral pencils of light toward the observer.

The use of the intermediate lens has several important implications that make indirect ophthalmoscopy more complicated than direct ophthalmoscopy.

The primary purpose of the ophthalmoscopy lens is to bend pencils of light toward the observer's pupil. Figure 3 also demonstrates one of the most characteristic side effects of this arrangement: Compared with the image in direct ophthalmoscopy, the orientation of the image on the observer's retina is inverted. For the novice, this often causes confusion in localization and orientation. Figure 3 further shows that in this arrangement the patient's pupil is imaged in the pupillary plane of the observer. In optical terms the pupils are in conjugate planes.

The most important changes are related to the change from candle light to gas light, to external electric light and, finally, to built-in electric light sources.[31]

Although the older generation found it difficult to adapt to the new instrument, the younger generation did so eagerly. One of them was Eduard von Jaeger (1828 to 1884) from Vienna,

best known for his print samples that were based on the print catalogue of the Vienna State Printing House. He was the son of a well-known ophthalmologist and an artistically gifted mother. In 1855, at the age of 27, he published his first atlas; he continued to add to his collection of authoritative fundus paintings until his death in 1884.[32]

6. Slit-lamp examination of the fundus

Although not generally considered as a method of ophthalmoscopy, fundus examination with the slit lamp offers an important addition to the traditional methods of direct and indirect ophthalmoscopy. It offers the advantage of high-power magnification through the microscope and flexible illumination with the slit-lamp beam. With appropriate contact lenses, it can offer higher magnification than direct ophthalmoscopy and a field several times wider than indirect ophthalmoscopy. These methods have become particularly important in combination with laser treatment.

Because the slit-lamp microscope has a fixed focus on a plane approximately 10 cm in front of the objective and because the image of the fundus of an emmetropic eye appears at infinity, the fundus cannot be visualized without the help of additional lenses. There are several options.

7. Negative lens

A negative lens placed in front of the objective of the microscope can move the microscope focus to infinity. The practical application of this principle was worked out by Hruby[33] [34]of Vienna (1942) with a lens known as the Hruby lens.

The optical principle is best understood if the lens is considered in conjunction with the eye, rather than as a part of the microscope. Parallel rays emerging from an emmetropic eye are made divergent by the Hruby lens and seem to arise from the posterior focal plane of that lens (Figure 7A.) For a -50-D lens, this would be 20 mm behind the lens (the usual Hruby lens is -55 D). The slit-lamp microscope is thus looking at a virtual image of the fundus in a plane somewhere in the anterior segment and must be moved a little closer to the patient than it would be for the regular external examination.

To estimate the field of view in this method, it may be assumed that only rays emerging parallel to the axis will reach the objective of the microscope and the observer's eye. When emerging from the eye, these rays must have been aimed at the anterior focal point of the Hruby lens. (Figure 7B), in which these rays are traced back to the retina, shows that the field of view (a) is proportional to the pupillary diameter as seen from the anterior focal point of the lens. This field is of the same order of magnitude as the field in direct ophthalmoscopy; it is largest when the lens is closest to the eye.

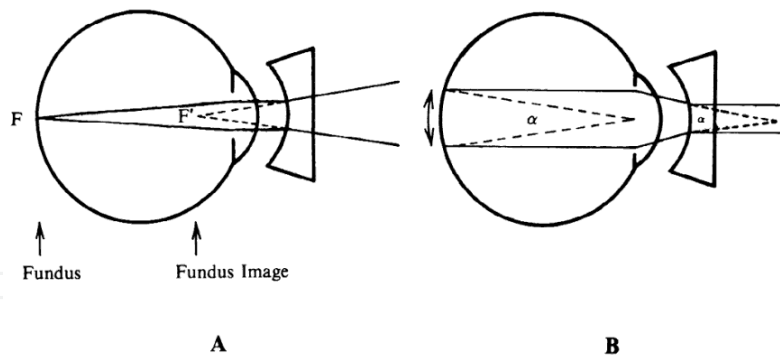


Figure 7. Hruby lens. A. The fundus image (F') is formed in the posterior focal plane of the lens. B. The field of view is proportional to the size of the pupil as seen from the anterior focal point of the lens.

With the lens close to the cornea, the fundus image will be close to the fundus plane and approximately actual size. The magnification to the observer is thus largely determined by the magnification of the microscope. At 16 \times , the magnification is about equal to that of direct ophthalmoscopy; at higher settings, the magnification is greater. Binocular viewing and slit illumination are advantages over direct ophthalmoscopy, even at similar magnification. Limitation to the posterior pole is a disadvantage.

8. Contact lens

When the Hruby lens is moved progressively closer to the eye, it will eventually touch the cornea and become a contact lens. If the curvature of the posterior lens surface equals the curvature of the anterior corneal surface, the image formation will not change, but two reflecting surfaces will be eliminated, and image clarity will increase.

The use of a contact lens for fundus examination was perfected by Goldmann[35]of Berne, Switzerland (1938). His contact lens is known for the three mirrors incorporated in it. These mirrors positioned at different angles make it possible to examine the peripheral retina with little manipulation of the patient's eye or of the microscope axis (Figure 8).

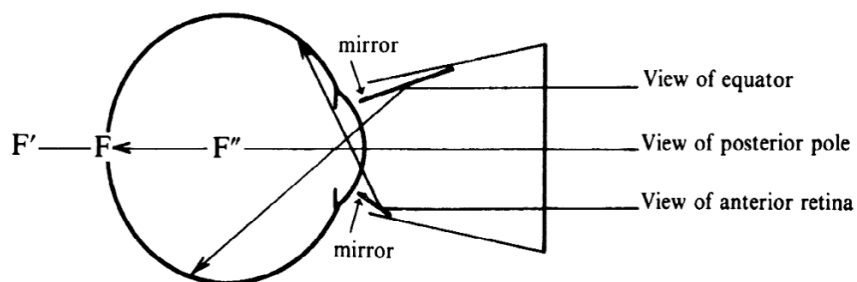


Figure 8. Three mirror contact lens by Goldmann. Two of the three mirrors are shown. They allow visualization of different parts of the fundus.

The refractive power of the cornea is eliminated in the contact lens. The only effective refractive element left would seem to be the far less powerful crystalline lens. The retina is situated well within the focal length of this lens, and the crystalline lens will therefore form a virtual image of the fundus (F) in a plane (F') behind the globe. How can the microscope focus on an image that far back? We overlooked one other refracting surface: the plano front surface of the contact lens. F' is seen through plastic and vitreous. To the observer in air F' appears at F'', through the same effect that makes a swimming pool appear shallower than it is. Because of this, the microscope again must focus on a plane inside the globe. As with the Hruby lens, magnification is largely determined by the microscope.

Thus, contact lens fundus microscopy extends our range of examination methods to details beyond the reach of ordinary direct ophthalmoscopy.

9. "Indirect" slit-lamp microscopy

The use of the Hruby lens and Goldmann contact lens is comparable to direct ophthalmoscopy, because no real intermediate image is formed. The equivalent of indirect ophthalmoscopy can be achieved by focusing the microscope on the real image formed by a high-power plus lens.

El Bayadi[36]introduced the use of a +60-D lens for this purpose. The inverted image formed by this lens is situated 16 mm (0.0167 m) in front of it. A practical problem with some older slit lamps is that they cannot be pulled back far enough to observe this image.

Compared with the Hruby (-55 D) lens, the El Bayadi (+60 D) lens offers the same major advantage as does indirect ophthalmoscopy: a larger field of view. With proper placement of the lens, the field is about six disc diameters (40 degrees), compared with the one- or two-disc diameter field of the Hruby lens.

With a 60-D lens the aerial image is as large as the fundus; thus the magnification is approximately equal to the microscope magnification (similar to that with the Hruby lens).

10. Contact lens for the indirect method

Can the field of view be widened even further? This is possible by using a contact lens of very high plus power with some additional optical tricks. Figure 9 illustrates the Rodenstock Panfunduscope, based on a design by Schiegel.[37]

The unit contains a high plus contact lens, which forms an inverted fundus image (F') located inside a second, spherical glass element.

In this arrangement, as in the previous example of a high myope (Figure 10), the image-forming and field-widening functions of the ophthalmoscopy lens are separated again. The contact lens forms the image; the spherical element serves to flatten the image and to redi-

rect the diverging pencils of rays toward the observer. Because these elements are so close to the eye, the field of view can be very wide. Indeed, without moving the lens, the view reaches 200 degrees, that is, from equator to equator, 4 to 5 times the diameter (16 times the area) of regular indirect ophthalmoscopy or of the El Bayadi lens.

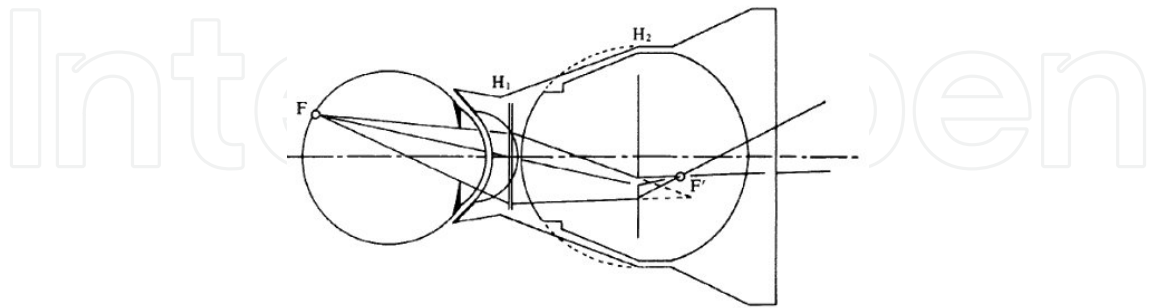


Figure 9. Contact lens arrangement for wide-angle indirect biomicroscopy. A high-power contact lens forms an inverted image (F') inside a spherical element, which redirects the light toward the observer.

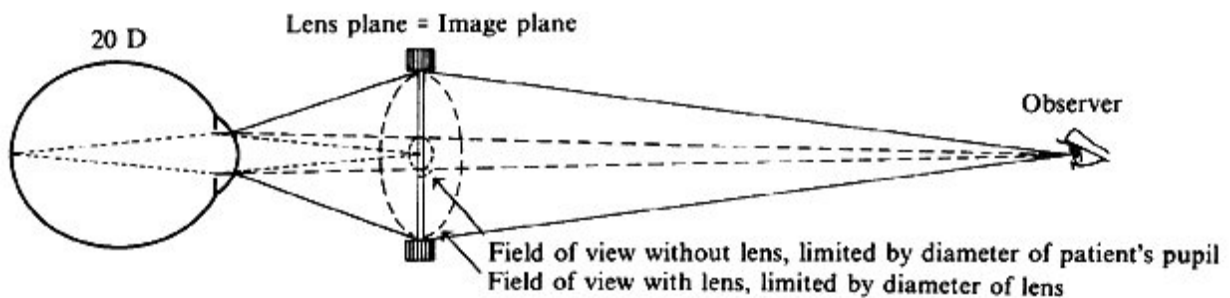


Figure 10. Indirect ophthalmoscopy of a high myope. The myopic eye forms its own aerial image (dotted lines) without the help of the ophthalmoscopy lens. Without the lens, only the central part of this image would be visible (dashed lines, limited by the patient's pupil). With lens (solid lines) the image is limited by the lens rim.

The size of the image inside the front lens is 70% of the retinal size; for detailed examination, therefore, 50% more microscope magnification is required than with the other slit-lamp methods. However, the principal use of this lens is not for its magnification but for its overview, an overview previously achievable only in fundus drawings or photocompositions.

Similar contact lens arrangements are used in specially designed fundus cameras that allow fundus photography of areas 100 degrees or more in diameter. With lenses such as these, the spectrum of our examining methods can be extended not only toward higher magnification than with direct ophthalmoscopy but also, at the other end, toward an overview of the fundus considerably beyond that obtainable with regular indirect ophthalmoscopy.

As the technology to calculate, design, and manufacture lenses with aspheric surfaces has improved, it has been possible to make lenses with higher powers and better light gathering abilities. The number and variety of lenses for indirect ophthalmoscopy and of contact lenses for slit-lamp microscopy has grown accordingly.

11. Related imaging techniques

11.1. Fundus photography

Fundus cameras have greatly improved the ability to document and follow fundus lesions. Eduard von Jaeger often spent countless hours drawing a single fundus, but today a photographic image is available in a fraction of a second. For reasons mentioned earlier, fundus cameras are built on the principle of indirect ophthalmoscopy. The observer's lens and retina are replaced by a camera lens and film. Because all components are enclosed in a rigid housing, more accessories can be built in. This includes a dual illumination system, which includes a constant light source for focusing and a flash for photography, and filters such as for fluorescein angiography. Rather than placing the viewing and illumination beams side by side, the illumination beam generally uses the periphery of the pupil and leaves the center for the observation beam.[38]

An angled glass plate that can be flipped to the right or to the left can be used to slightly deviate the observation beam to the right part or the left part of the patient's pupil to produce photo pairs that can be viewed stereoscopically.

Because newer lens designs have allowed the construction of wide-angle cameras, a special challenge has been to construct the optical system in such a way that the curved retina is imaged in a plane that can be captured on a flat film.

11.2. Adaptive optics

The optics of the eye are not perfect. Even if major errors are corrected with spherical and cylindrical lenses, small irregularities across the pupillary opening persist. The technique of adaptive optics was developed for astronomical telescopes to counteract image degradation by atmospheric irregularities. An adaptive optics system uses a grid to divide the pupillary opening into many small areas and determines a separate small correction for each area. The information is fed to a slightly deformable mirror with microactuators. Thus the image quality can be enhanced to the point at which the cone mosaic can be clearly visible. The setup is too laborious for use in routine photography. Because the corrective system has to be fixed in relation to the pupil, it cannot be implemented in glasses or contact lenses. However, the technique, also known as wavefront analysis, has found a place in the refractive sculpting of the cornea.[39]

12. Gonioscopy

Another important part of ophthalmic exam. First explored in by Trantas (1907.); then explored by Salzmann (1915-16.); Koeppe (1919-20.); and Troncoso (1925-30). Finally Otto Barkan (1887.-1958.) made gonioscopy a routine diagnostic method in the ophthalmologist's office, thereby bringing about the separation of the glaucomas due to the angle-closure mechanism from the open-angle glaucomas[40]that the elevation of the intraocular pressure

depends of abnormal resistance to aqueous outflow caused by anatomic or functional changes within the outflow channels.

Not until the 1890s did open-angle glaucoma become well proved and accepted in theories.

Thanks to gonioscopy, started recognition of a type or types of glaucoma without obstruction of the angle by the iris.

13. Secondary glaucomas

In the first edition of the Graefe-Saemisch Handbook of Ophthalmology (1877), Saemisch lists the following ocular diseases as frequently giving rise to secondary glaucoma: cicatricial ecstasies of the cornea, circular or total adhesions of the iris to the lens, iritis serosa, traumatic cataract, dislocations of the lens, intraocular tumours, hemorrhagic retinal processes (referring mainly, if not exclusively, to occlusions of the central retinal vein), and sclerectasia pastries (which probably referred to glaucoma in eyes with malignant myopia). Congenital hydrophthalmos was at the time also classified with the secondary glaucomas.

14. Tonometry

William Bowman introduced digital estimation of the ocular tension at the annual meeting of the British Medical Association in 1862. Estimation of the ocular tension by palpation became one of the ophthalmologist's special skills, and some ophthalmologists developed so much confidence in it that they viewed instrumental tonometry with suspicion.

The early beginning of instrumental tonometry, apparently made by von Graefe, who mentions preliminary trials of mechanical tonometers in a letter to Donders dated December 24, 1862. Unfortunately, none of these instruments, however, reached the drawing board stage.

The real beginning and the first tonometers actually produced and tested on human eyes were developed in Donders' clinic in Utrecht between 1863 and 1868. They were instruments for use on the sclera. The scleral curvature at the site of tonometer application was determined first; it then served as a reference plane for the measurement of the depth of the indentation.

Impression tonometry had its drawbacks. The principal flaw was that the indentation, by displacing a significant amount of intraocular fluid, changes the pressure which is intended to measure; this was clearly expressed for the first time by Adolf Weber in 1867. Weber was official inventor of the first applanation tonometer, which was intended to give a tension reading with only minimal fluid displacement. Despite its theoretic superiority, this instrument did not gain wide acceptance, because recognition of the point of perfect applanation without indentation proved to be difficult. Lately, the principles of applanation tonometry were explored by Maklakoff in 1885. and Imbert and Fick, father and son, a few years later. It

resulted a several new applanation tonometers, but only one of them, Maklakoff's model of 1892, has stood the test of time and has remained in use, mainly by groups in the USSR.

The beginning of the 20th century, digital tonometry was still a method of subjective assessment of the ocular pressure [41]. At that time neither applanation tonometer did not find widespread use in practice. Finally, in 1905 Schiøtz presented his impression tonometer and it did not take long for the instrument to acquire the epithet "the first clinically useful tonometer." First major comprehensive reports of the clinical value of Schiøtz tonometer began to appear in 1910. The essence of today's knowledge of the intraocular pressure in the normal and in the diseased human eye was acquired between 1910. and 1920. through the use of Schiøtz tonometers.

Disadvantages of digital and instrumental tonometry, realized by the pioneers of these methods, addressed to the properties of the eyeball wall, especially elasticity, affected estimation of the intraocular pressure. Early experimental attempts in that time, to measure these properties and to eliminate them revealed new variables. Schiøtz wrote in 1920: "I can not imagine any method available for living eyes by which errors due to variations of the envelope could be eliminated." [42] Thirty years later, the electronic form of his instrument came closest to yielding reasonable estimates of "ocular rigidity," the term introduced by Friedenwald for the resistance that the in vivo eyeball offers to a change in intraocular volume [43].

Correcting readings taken with the Schiøtz tonometer for deviation of the particular eye from average ocular rigidity, the coefficient of ocular rigidity lost some of its clinical importance through the tremendous progress in applanation tonometry that occurred in the early 1950s through the work of Goldmann, Perkins, and Maurice.

15. Goldman applanation tonometry

The technology to estimate intraocular pressure (IOP) has evolved tremendously since Sir William Bowman emphasized the importance of ocular tension measurements in 1826. In an address delivered at the annual meeting of the British Medical Association, Sir William underscored the critical role that digital estimation of ocular tension played in his practice. In his address, Sir William stated that "it is now my constant practice, where defective vision is complained of, to ascertain almost at the first instant the state of tension in the eye...It is easy enough to estimate the tension of the eye, though there is a right and a wrong way of doing even so simple a thing... With medical men, the touch is already an educated sense, and a very little practice should suffice to apply it successfully to the eye." [44]

Soon afterwards, digital tonometry became an essential clinical skill necessary to master by all ophthalmologists. When mechanical tonometry was first introduced in the late 1800s, many ophthalmologists felt so confident with their ability to estimate IOP by palpation that they viewed the new technology as inferior. Isador Schnabel, in an address to the Vienna Ophthalmological Society in 1908, was noted to state that although he did not object in prin-

ciple to mechanical tonometry, he expected "...very little from this test since digital tonometry by an expert is a much more accurate test".[45]

Although Grafe is credited with the first attempts to create instruments that mechanically measured IOP in the early 1860s, his proposed instruments were neither designed nor built. Rather, it was Donders who designed the first instrument capable of estimating IOP – albeit not accurately – with mechanical tonometry in the mid 1860s. The principle behind Donders's instrument was to displace intraocular fluid by contact with the sclera. The ophthalmologist first measured the curvature of the sclera at the site of contact, and then used this measurement as a reference plane to measure the depth of indentation. Smith and Lazerat refined this technology in the 1880s, and the discovery of cocaine by Carl Koller in 1884 led the way to corneal impression tonometry soon thereafter. With the aid of a powerful corneal anesthetic agent, corneal tonometry became the definitive choice of IOP measurements because it offered a well – defined and uniform site of impression when compared with the sclera.

Impression tonometry's major shortcoming was that it displaced so much fluid upon contact with the eye that the measured readings were highly variable and mostly inaccurate. What was needed was a way to displace a minimal amount of fluid to record IOP. This breakthrough came when Adolf Weber designed the first applanation tonometer in 1867, which gave a highly defined applanation point without indentation. After two decades of skepticism, the value of applanation tonometry was re-discovered when Alexei Maklakoff and others introduced new versions of applanation tonometers. In early 20th century, there were about 15 models of tonometers in use. In fact, Maklakoff's 1892 model is the basis of applanation tonometry today. However, digital tonometry still remained the gold standard among most ophthalmologists in the early 1900s.

The first clinically useful mechanical tonometer was designed and introduced by Hjalmar Schiøtz in the early 1900s. The instrument was simple, easy to use, and highly precise. It was quickly accepted and became the new gold standard beginning the 1910s. Innovations in calibration led to its increased use, and a tremendous amount of knowledge about the normal and glaucomatous eye was quickly acquired. An adjustment for ocular rigidity was introduced by Goldmann in the 1950s, which led to the development of Goldmann applanation tonometers. The Goldmann tonometers displace such little fluid that variations in ocular rigidity are mostly negligible. The electronic and non – contact tonometers used today rely heavily on the principles and instrumentation first introduced by Maklakoff, Schiøtz and Goldmann.

Today, for the most part, digital tonometry has been replaced by sophisticated technologies to estimate IOP. Today's instruments are incredibly accurate and easy to use. Yet, there is sometimes no good substitute for digital tonometry. For example, some ophthalmologists may prefer digital tonometry when estimating IOP in patients with keratoprostheses. In these situations, fingers that have mastered Sir William's art are highly desirable. In fact, it is said that the famous Dr. Claus Dohlman, Harvard professor of Ophthalmology at the Massachusetts Eye and Ear Infirmary, remains as accurate in measuring IOP with his fingers as any ophthalmologist using the high-tech tonometers of today!

16. Perimetry

Modern diagnostic of glaucoma is unimaginable without perimetry. The merit for measurements of peripheral vision for the diagnosis and follow-up of ocular disease, as many other things in ophthalmology, is attributed to Albert von Graefe. With a primitive campimeter—a sheet of paper with radial rows of dots which served as stimuli—he was probably the first (1856) to plot paracentral field defects in chronic glaucoma and to use them in the evaluation of surgical results. Similar to von Graefe's device, Haffmanns from Donder's clinic discovered the greater frequency in glaucoma simplex of serious involvement of the upper half of the field, which gave rise to an easily detectable nasal step [46].

In 1857, Förster introduced the first perimeter, which placed accent on large targets, such as the 10/330, which permitted only very gross measurements. The observations of that time did suggest partial reversibility of field defects if the pressure was lowered substantially by an iridectomy or sclerotomy. 1889. was a very important year for a development of techniques most appropriate for glaucoma. Bjerrum presented 2-meter screen, the 2-meter test distance, and the 2- to 5-ram white test objects. He discovered the relative or absolute scotomas, circling the point of fixation and including the blind spot, which became the hallmark of chronic glaucoma. Conceptually, it means the beginning of the nerve fibre bundle theory of the glaucomatous optic nerve disease.

Further major step was the occurrence of small scotomas in the zone from 12° to 20° from the point of fixation, in early glaucomas, presented by Peter [47]. These scotomas, in the beginning were not connected with the blind spot, but they reached it later via expansion.

The construction of smaller isopters, another early glaucoma characteristic, presented in 1920s, was clearly established with Bjerrum's technique. Bjerrum's technique also confirmed the regression of early glaucomatous defects following normalization of pressure documented by instrumental tonometry. The close relationship between pressure and field of vision was demonstrated further by Samojloff's observations [48] of temporary enlargement of the blind spot concurrent with osmotically induced pressure elevations. By stereocampimetry with minute targets, Evans was able to detect a gross form of parallelism between diurnal pressure fluctuations and the size of paracentral scotomas [49].

Also in 1920s was noticed that among patients with glaucomatous defects close to the point of fixation (late stages of glaucoma optic neuropathy), a surgical procedure, particularly iridectomy, could have an untoward effect and lead to further rapid shrinkage of the visual field. The incrimination of the iridectomy referred originally to the period when the alternative, the sclerotomy, had proved relatively free of unfavourable effects on the visual field. Subsequent experience with filtering operations temporarily led to the distinction between two classes of glaucoma operations: 1) the less risky: cyclodialysis and sclerotomy and 2) the riskier: iridectomy, sclerectomy, and trephination.

17. Glaucoma treatment

The early treatment of glaucoma has its course of history (Table 1. and Table 2.).

Main discoveries where:

1. A curative action of the iridectomy in certain glaucomas⁷[44],
2. The development of the filtering operations [50], and
3. The discovery of the first three ocular hypotensive drugs: eserine, pilocarpine, and epinephrine [51].

Surgical Treatment of Glaucoma (1830-1920)

1830 Mackenzie¹ recommends scleral punctures to release vitreous and to relieve the pressure on the retina.

1857 von Graefe's iridectomy⁶ almost overnight gains the position of *the* glaucoma operation.

1882 de Wecker, in a paper on the "filtering cicatrix"⁹, expresses the concept that in the presence of elevated intraocular pressure, a properly executed corneoscleral incision can heal in a manner allowing intraocular fluid to "filter," ie, be driven by a pressure gradient through the loose scar tissue into subconjunctival spaces.

1891 Bader [52] finds the occurrence of an iris prolapse during or shortly after an iridectomy a favourable sign, auguring success of the operation.

1903 Herbert reports on a series of subconjunctival fistula operations in which he purposely leaves the iris in the operative incision. The report includes the first detailed description of the transformation of the epibulbar tissues that become exposed to the steady flow of aqueous [53].

1905 Heine first reports on the operation of cyclodialysis^[54], based on Fuchs' [55] and Axenfeld's^[56] observation of the association between postoperative choroidal detachment, a tear or tears in the insertion of the ciliary muscle at the scleral spur, and hypotony.

1906 Lagrange first reports on his iridosclerectomy^[50].

1909 Freeland and Elliot independently substitute the trephine for Lagrange's scissors.

1913 At the first international review of glaucoma surgery the pronouncement is made that chronic glaucoma can only be arrested by establishing a filtering cicatrix in connection with the anterior chamber. The iridectomy loses its status of *the* glaucoma operation but still is first in favor for acute glaucoma [57].

1915 The abexterno incision is introduced by Foroni^[58].

1920 Seidel demonstrates the transconjunctival passage of aqueous after trephining procedures^[16].

Table 1. A summary of the early phases of the glaucoma surgical treatment.

Medical Treatment of Glaucoma (1863-1932)

- 1863 Argyll Robertson and von Graefe study the effect of extracts of the calabar bean on pupil and accommodation. Von Graefe finds the miotic effect useful in that it facilitates the iridectomy.
-
- 1876 Laqueur^[59] reports "a definite drop of the elevated tension after repeated installations of physostigmine in five cases of glaucoma simplex and in one case of secondary glaucoma."
-
- 1876 Weber studies the mechanisms underlying the hypotensive effect of physostigmine in rabbits and in man and advises caution in its use because of the marked swelling and engorgement of the ciliary processes caused by the drug ^[60].
-
- 1877 Laqueur gives the first clear-cut account of the successful termination by use of physostigmine of attacks of acute glaucoma and of the prevention of recurrences ^[61].
-
- 1877 Weber introduces pilocarpine with the hope that it will replace the iridectomy in some of the chronic and simple glaucomas and that it will serve to make up for the insufficient effect of the latter in many other cases ^[62].
-
- 1898 The hypotensive effect of topically administered adrenal extracts is discovered.
-
- 1902 Darier reports significant lowering of pressure in some glaucomas, induced by adrenaline alone or in combination with physostigmine^[51].
-
- 1909 Extensive clinical use of adrenaline has confirmed the beneficial results, but it has also brought to light the clear-cut untoward effects, ie, the drug may cause further elevation of pressure and even precipitate acute attacks in certain eyes.
-
- 1923 Hamburger reintroduces adrenaline; new, more potent, more stable preparations for topical use are becoming available. Untoward effects in certain eyes are rediscovered ^[63].
-
- 1932 Gonioscopy furnishes the answer to the unfavorable response of certain eyes to topical adrenaline.
-

Table 2. A summary of the early phases of the glaucoma medical treatment.

Author details

Ivan Marjanovic

Glaucoma Department, University Eye Clinic Clinical centre of Serbia and Belgrade University School of Medicine, Serbia

References

- [1] Mackenzie W: Practical Treatise on the Diseases of the Eye. London: Longmans, Reese, Orme Brown and Green, 1830, p 710.
- [2] Duke-Elder S, Jay B: Introduction to Glaucoma and Hypotony. In Duke-Elder S(ed): System of Ophthalmology. St. Louis: Mosby, 1969, Vol XI, p 337.

- [3] Albert DM: Jaeger's Atlas of Diseases of the Ocular Fundus. Philadelphia: Saunders, 1972, pp 67–79.
- [4] von Graefe A: Vorläufige Notiz über das Wesen des Glaucoms. Arch Ophthalmol 1:371, 1854.
- [5] Weber A: Ein Fall von partieller Hyperämie der Chorioidea bei einem Kaninchen. Arch Ophthalmol 2:133, 1855.
- [6] von Graefe A: Ueber die Wirkung der Iridectomie bei Glaucom. Arch Ophthalmol 3:456, 1857.
- [7] von Graefe A: Weitere Zusätze über Glaucom und die Heil-wirkung der Iridectomie. Arch Ophthalmol 8:254, 1861.
- [8] Schnabel I: Die Entwicklungsgeschichte der glaukomatösen Exkavation. Z Augenheilkd 14: 1, 1905.
- [9] de Wecker L: La cicatrice à filtration. Ann Ocul 87:133, 1882.
- [10] Mueller H: Anatomische Beiträge zur Ophthalmologie: Ueber Niveau-Veränderungen an der Eintrittsstelle des Sehnerven. Arch Ophthalmol 4:1, 1858.
- [11] Smith P: Glaucoma: Its Causes, Symptoms, Pathology and Treatment. London: Churchill, 1879, p 91.
- [12] Schwalbe G: Untersuchungen über die Lymphbahnen des Auges und ihre Begrenzungen. Arch mikrosk Anat 6:261, 1870.
- [13] Leber T: Studien über den Flüssigkeitswechsel im Auge. von Graefe's Arch Ophthalmol 19:87, 1873.
- [14] Bentzen CF, Leber T: Ueber die Filtration aus der vorderen Kammer bei normalen und glaukomatösen Augen. von Graefe's Arch Ophthalmol 41:208, 1895.
- [15] Knies M: Ueber das Wesen des Glaukoms. von Graefe's Arch Ophthalmol 22:163, 1876.
- [16] Seidel E: Weitere experimentelle Untersuchungen über die Quelle und den Verlauf der intraokularen Saftströmung: VI. Die Filtrationsfähigkeit, eine wesentliche Eigenschaft der Skleralnarben nach erfolgreicher Elliotscher Trepanation, von Graefe's Arch Ophthalmol 107:158, 1921.
- [17] Smith P: On the size of the cornea in relation to age, sex, refraction and primary glaucoma. Trans Ophthalmol Soc UK 10:68, 1890.
- [18] Czermak W: Einiges zur Lehre von der Entstehung und dem Verlaufe des prodromalen und acuten Glaukomanfalles. Prager med Wochenschr 22: 15, 1897.
- [19] Curran EJ: A new operation for glaucoma involving a new principle in the etiology and treatment of chronic primary glaucoma. Arch Ophthalmol 49:131, 1920.

- [20] Meeting of the Physikalische Gesellschaft, Berlin, December 6, 1850 (von Helmholtz' paper, read by his friend Dubois-Raymond, has been lost).
- [21] von Helmholtz H: Beschreibung eines Augenspiegels zur Untersuchung der Netzhaut im lebenden Auge, Berlin (1851). Translation in Arch Ophthalmol 46:565, 1951.
- [22] Albert DM, Miller WH: Jan Purkinje and the ophthalmoscope. Am J Ophthalmol 76:494, 1973.
- [23] Mark HH: The first ophthalmoscope? Arch Ophthalmol 84:520, 521, 1970.
- [24] Cumming W: On a luminous appearance of the human eye, and its application to the detection of disease of the retina and posterior part of the eye. R Med Chir Soc Lond 29:283, 1846.
- [25] Brücke E: Ueber das Leuchten der menschlichen Augen. Arch Anat Physiol Wissensch Med 25, 1847.
- [26] Jones W: Report on the ophthalmoscope. Br Med Chir Rev 14:425, 1854.
- [27] Rucker WF: A History of the Ophthalmoscope. Rochester, MN: Whiting, 1971.
- [28] von Helmholtz H: Ueber eine neue einfachste Form des Augenspiegel. Arch Physiol Heilk 2:827, 1852.
- [29] Ruete CGT: Der Augenspiegel und das Optometer für practische Aerzte. Gottingen, Prussia: Dieterich, 1852.
- [30] Landolt E: Die Untersuchungsmethoden. Berlin, 1:234, 1913.
- [31] Duke-Elder Sir Steward: System of Ophthalmology. Vol 7. Foundations of Ophthalmology: Heredity, Pathology, Diagnosis and Therapeutics. St. Louis: Mosby, 1962, 290–325.
- [32] Albert DM: Jaeger's Atlas of Diseases of the Ocular Fundus. Philadelphia: Saunders, 1972.
- [33] Hruby K: Spaltlampenmikroskopie des hinteren Augenabschnittes ohne Kontakglas. KIm Monatsbl Augenkeilkd 108:195, 1942.
- [34] Hruby K: Spaltlampenmikroskopie des hinteren Augenabschnittes. Vienna: Urban and Schwarzenberg, 1950.
- [35] Goldmann H: Zur Technik der Spaltlampenmikroskopie. Ophthalmologica 96:90, 1938.
- [36] El Bayadi G: New method of slit lamp micro-ophthalmoscopy. Br J Ophthalmol 37:625, 1953.
- [37] Schlegel HJ: Eine einfache Weitwinkeloptik zur spaltlampen-mikroskopischen Untersuchung des Augenhintergrundes. Doc Ophthalmol 26:300, 1969.

- [38] Pomerantzeff O, Webb RH, Delori FC: Image formation in fundus cameras. IOVS 18:630, 1979.
- [39] Roorda A: Adaptive optics ophthalmoscopy. J Refract Surg 16:S602, 2000.
- [40] Barkan O: Glaucoma: Classification, causes and surgical control: Results of microgonioscopic research. Am J Ophthalmol 21: 1099, 1938.
- [41] Draeger J: Geschichte der Tonometrie. Bibl Ophthalmol 56:1, 1961.
- [42] Schiøtz H: Tonometry. Br J Ophthalmol 4:201, 249, 1920.
- [43] Friedenwald JS: Calibration of tonometers. In Standardization of Tonometers, Decennial Report, Committee on Standardization of Tonometers. Am Acad Ophthalmol Otolaryngol, 1954, p 95.
- [44] Bowman W: Glaucomatous affections, and their treatment by iridectomy. Br Med J, Oct II, 1852, p 377-382.
- [45] Schnabel I., Klin Monatsbl Augenh 1908; 48:318.
- [46] Haffmanns JHA: Zur Kenntnis des Glaukoms. Arch Ophthalmol 8: 124, 1862.
- [47] Peter LC: A simplified conception of visual field changes in chronic glaucoma. Arch Ophthalmol 56: 337, 1927.
- [48] Samojloff A: Die Grössenzunahme des blinden Fleckes nach subkonjunktivalen Kochsalzinjektionen. Klin Monatsbl Augenheilkd 70:655, 1923.
- [49] Evans JN: Transient fluctuations in the scotoma of glaucoma. Am J Ophthalmol 18:333, 1935.
- [50] Kronfeld PC: The rise of the filtering operations. Survey Ophthalmol 17: 168, 1972.
- [51] Spengler E: Kritisches Sammel-Referat über die Verwendung einiger neuerer Arzneimittel in der Augenheilkunde. Z Augenheilkd 13:33, 1905.
- [52] Bader C: Sclerotomy in glaucoma. Trans 7th Internat Congr Med London, Section on Ophthalmol, 1881, p 98.
- [53] Herbert H: Subconjunctival fistula operation in the treatment of primary chronic glaucoma. Trans Ophthalmol Soc UK 23:324, 1903.
- [54] 54. Heine L: Die Cyklodialyse, eine neue Glaukomoperation. Dtsch med Wochenschr 31: 824, 1905.
- [55] 55. Fuchs E: Ablösung der Aderhaut nach Operation. von Graefe's Arch Ophthalmol 53:375, 1902.
- [56] Axenfeld T: Zur operativen Ablösung der Aderhaut, nebst einer Bemerkung zur Wirkung der Glaukomoperationen. Klin Monatsbl Augenheilkd 41:122, 1903.

- [57] Elliot RH, Lagrange F, Smith P: Report on glaucoma operations with special reference to the comparative results attained by iridectomy and its recent substitutes. Trans 17th Internat Congr Med London, Section on Ophthalmol, 1913, p 57.
- [58] Foroni C: Sclerectomy ab externo. von Graefe's Arch Ophthalmol 89:393, 1915.
- [59] Laqueur L: Neue therapeutische Indikation für Physostigmine. Centralbl med Wissensch 14:421, 1876.
- [60] Weber A: Ueber Calabar und seine therapeutische Verwendung. von Graefe's Arch Ophthalmol 22:215, 1876.
- [61] Laqueur L: Ueber Atropin und Physostigmin und ihre Wirkung auf den intraokularen Druck. von Graefe's Arch Ophthalmol 23:129, 1877.
- [62] Weber A: Die Ursache des Glaukoms. von Graefe's Arch Ophthalmol 23: 1, 1877.
- [63] Löhlein W: Ueberblick über den heutigen Stand der Glaukomtherapie. Zentralbl Gesamte Ophthalmol 22:1, 1930.

