

We are IntechOpen, the world's leading publisher of Open Access books Built by scientists, for scientists

4,800

Open access books available

122,000

International authors and editors

135M

Downloads

Our authors are among the

154

Countries delivered to

TOP 1%

most cited scientists

12.2%

Contributors from top 500 universities



WEB OF SCIENCE™

Selection of our books indexed in the Book Citation Index
in Web of Science™ Core Collection (BKCI)

Interested in publishing with us?
Contact book.department@intechopen.com

Numbers displayed above are based on latest data collected.

For more information visit www.intechopen.com



Nontuberculous Mycobacterial Keratitis

Ana Lilia Pérez-Balbuena,
David Arturo Ancona-Lezama,
Lorena Gutiérrez-Sánchez and
Virginia Vanzzini-Zago

Additional information is available at the end of the chapter

<http://dx.doi.org/10.5772/45964>

1. Introduction

Mycobacterium species that are considered typical are the tuberculosis species such as *M.tuberculosis*, *M.bovis*, *M.africanum* and *M.leprae*. These species have only human or animal reservoirs and are not transmitted by water. In contrast, the species Non-Tuberculosis or “atypical”, naturally are ubiquitous in soil and water and have been found as normal flora of skin, sputum, and gastric contents. These bacteria are resistant to common, disinfectants, chlorine, formaldehyde and glutaraldehyde.

NTM can cause infections on all adnexal and ocular tissues including the cornea, iris, lens, retina, choroid and optic nerve. Most NTM infections are caused by *M.chelonae* and *M.fortuitum*, that as we will discuss later, belong to the rapid growers group.

In this chapter, we will focus on keratitis caused by atypical mycobacterium, since a great number of recent clinical reports of NTM ocular infections are of keratitis. In common general ophthalmology procedures like refractive surgery, for example laser in situ keratomileusis (LASIK), Laser epithelial keratomileusis (LASEK), photorefractive keratectomy (PRK), and other specialized procedures such as penetrating keratoplasty (PKP), a transgression to natural barriers occurs, this constitutes a risk factor for infection by these organisms. In addition, LASIK is one of the most commonly performed procedures in ophthalmology practice.

Several factors may contribute to the development of mycobacterial keratitis following LASIK, making it difficult to determine the true origin of the infection in most cases. This procedure is often performed utilizing aseptic, but non sterile techniques. *Mycobacterium*

chelonei, *M. abscessus*, *M. fortuitum*, *M. szulgai*, and *M. mucogenicum* have been reported as the result of improper asepsis.

Atypical Mycobacteria corneal infections are rare, but devastating complications. Although rare, are a diagnostic and therapeutic challenge. Mycobacterium have been involved in several isolated cases as well as in outbreaks.[4-12]

2. Microbiological and laboratory profile

Mycobacterium species that are considered typical are the tuberculosis specie; *M.tuberculosis*. Many species enclosed in genus *Mycobacteriaceae* are true human pathogens as *Mycobacterium tuberculosis* complex, that include *M tuberculosis*, *M bovis*, non pathogenic *M bovis* BCG, *M africanum*, *M caprae*, *M microti*, and *M pinnipedii* are characterized by different phenotypes and mammalian host ranges, displays the most extreme genetic homogeneity with 0.01 to 0.03% nucleotides variation only. Growth rate in this group is 6 to 12 weeks. *M leprae* is the only non cultivable in vitro specie and has some genetic variations in relation to *M tuberculo-sis complex*.

The only genus of the *Mycobacteriaceae* family is the *Mycobacterium*, the *Mycobacteriaceae* belongs to the order *Actinomycetales*. Mycobacteria is an unusual ocular pathogen that has the following characteristics: intracellular bacilli, slow growing organisms, obligate aerobic, non-motile, non-capsulated, non-sporing, present a large amounts of lipids and true waxes in their cell walls, and are considered gram-positive and acid-fast.

Other places where NTM have been isolated are: contaminated tap water, saline solutions, disinfectant solutions, and hemodialyzers. Mycobacteria influences a number of ocular structures, including the cornea,iris, lens,retina, choroid and optic nerve.

Clinical manifestations of the typical mycobacteria are : lupus vulgaris on eyelid, phlyctenule, scleritis, lacrimal gland involvement, orbital periostitis, granulomatous panuveitis, secondary glaucoma and cataract, chorioretinal plaque or nodule, nerve palsies.

The incidence of tuberculosis has increased due to the growth in homelessness, the upsurge of intravenous drug abuse, neglect of tuberculosis programs, acquired immunodeficiency syndrome.

Runyon classified nontuberculous mycobacteria into four groups, described in [Table 1]. Runyon Classification of tuberculous and non-tuberculous *Mycobacterium* is based, on the growth rate, and pigment production. Groups I to III are slow growers that require approximately 2 to 3 or more weeks to form visible colonies in culture at 27°C. Group IV organisms are rapid growers, forming non-pigmented colonies in culture in one week.[1,14,15]

Out of the more than 130 actually validated species of non-tuberculousmycobacteria, 60 are slowly growingmycobacteria, that shows in solid culture media growth rates of 2 to 4 weeks, the most clinically significance and most frequently in isolated human samples are *M avium*, *M intracellulare*, *M kansasii*, *M marinum*, *M xenopi*, *M malmoense* and *M ulcerans*. In the

rapidly growing mycobacteria group with 7 -10 days of growing rate on solid culture media, there are three major clinically important species responsible for 80% of diseases in humans *M. chelonae*, *M. abscessus* and *M. fortuitum*, that are too frequently located in tap water and have been related with sepsis in bone marrow transplant, post-traumatic, surgical ocular and other surgical wound infections.

Slow Growers		Rapid Growers	
Group I	Group II	Group III	Group IV
(photochromogens)	(scotochromogens)	(nonchromogens)	(nonchromogens)
6-12 weeks	2-4 weeks	2-4 weeks	7-10 days
<i>M. marinum</i>	<i>M. scrofulaceum</i>	<i>M. avium</i>	<i>M. fortuitum</i> group
<i>M. kansasii</i>	<i>M. szulgai</i>	<i>M. intracellulare</i>	<i>M. fortuitum</i>
<i>M. simiae</i>	<i>M. gordonae</i>	<i>M. haemophilum</i>	<i>M. peregrinum</i>
<i>M. asiaticum</i>	<i>M. xenopi</i>	<i>M. paratuberculosis</i>	<i>M. mucogenicum</i>
	<i>M. flavescens</i>	<i>M. gastri</i>	<i>M. Senegalese</i>
		<i>M. malmoense</i>	<i>M. septicum</i>
		<i>M. nonchromogenicum</i>	<i>M. mageritense</i>
		<i>M. terrae</i>	<i>M. chelonae-abscessus</i> group
		<i>M. triviale</i>	<i>M. chelonae</i>
			<i>M. abscessus</i>
			<i>M. immunogenum</i>
			<i>M. smegmatis</i> group
			<i>M. smegmatis</i>
			<i>M. goodii</i>
			<i>M. wolinskyi</i>

Problem statement: To describe the experience in México (Asociación Para Evitar La Ceguera I.A.P. "Hospital Dr. Luis Sánchez Bulnes" [APEC]) in the management of keratitis caused by nontuberculous mycobacteria.

Application area: Cornea and Refractive Service and Microbiology Service

Research course: To describe of atypical *Mycobacterium* keratitis cases diagnosed and attended in the Cornea Service of our Hospital in the last 10 years.

Methods: This is a descriptive retrospective case series of five patients treated in our service.

Table 1. Runyon's Classification of Nontuberculous Mycobacterium

3. Laboratory diagnosis and bacteriology

In ophthalmological infections traumatic or post-surgical in origin, are frequently involved in non-tuberculous or atypical fast growing *Mycobacteria*, the species *M. chelonae*, *M. chelonae abscessus*, *M. fortuitum* have been isolated in many cases. These rapidly growing *Mycobacteria* share the cellular characteristics of *Mycobacterium* genus, like mycolic acids esters in its

cell wall, long straight or curved rods with irregular Gram staining [Figure 1], and specific red-magenta staining characteristic with Ziehl-Neelsen or Kinyoun cold techniques.[Figure 2] They are aerobic and capable of growing in 5 -10% CO₂ atmosphere and in blood agar media.[Figure 3] In addition, these microorganisms are arylsulfatase positive, catalase positive and niacin negative. [Figure 4]

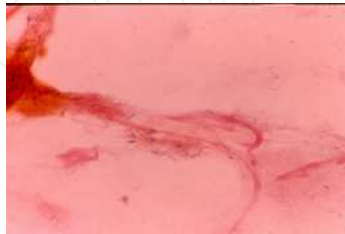

Figure 1. Gram positive and irregular stain and forms of *Mycobacterium chelonae*

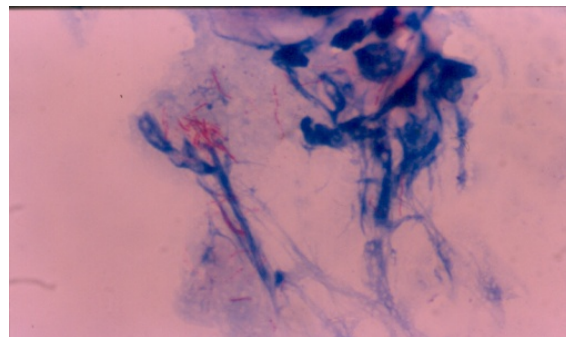


Figure 2. Red-magenta rods of *M. chelonae* in a corneal smear of patient with keratitis.

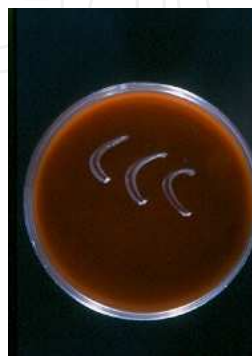

Figure 3. Colonies of *M. chelonae* in agar blood with Brain Heart Infusion (BHI) agar base after 7 days of incubation at 27°C and 5% CO₂ atmosphere.

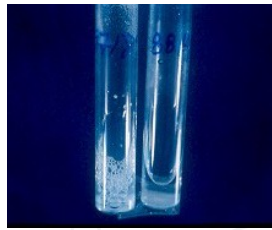


Figure 4. Catalase 65°C positive test (O₂ bubbles) for *Mycobacterium chelonae*.

To identify the microorganism, its phenotypic characteristics were used, such as pigmentation of colonies growing in the darkness (presented in Table 1) on Lowenstein-Jensen media.

The most common species of rapidly growing *Mycobacteria* belong to group IV of Runyon's classification, also known as colorless or nonchromatogens.[Figure 5]



Figure 5. *Mycobacterium chelonae* colonies in Lowenstein-Jensen medium after 7 days of incubation at 27°C.

For genotypic characterization, the 16Sr RNA gene sequencing, high performance liquid chromatography and polymerase chain reaction has been used.

4. Clinical features

Nontuberculous Mycobacteria can cause infections of all adnexal and ocular tissues. Most atypical Mycobacteria infections are caused by *M. chelonae*, and *M. fortuitum*.

Dacryocystitis and Canaliculitis: Present as epiphora and erythematous swelling in the medial canthal area, purulent material can be expressed with massage of the lacrimal sac.

Orbital Infections: Present with a gradual development of periorbital edema, without a significant proptosis and a superficial skin lesion may be present. The visual acuity will depend on the involvement of the optic nerve. [18,19]

Conjunctivitis and Scleritis: Present as conjunctival or as scleral injection and tenderness accompanied with chronic redness, irritation, discharge and pain. Sometimes, marked scleral thinning may develop. Scleral abscesses manifest late in the course of the disease as subconjunctival nodules. [20,21]

Endophthalmitis: Present with severe pain, decreased vision, and redness and discharge, may exist hypopyon, and variable amounts of granulomatous keratitic precipitates. Moderate vitreous inflammation is present in most cases.

Keratitis: The greatest number of recent clinical reports of nontuberculous Mycobacteria ocular infections are of keratitis, as seen in our hospital (Asociación Para Evitar La Ceguera en México "Dr. Luis Sánchez Bulnes" I.A.P. [APEC]). Keratitis most commonly follows trauma or surgery and has been associated with penetrating keratoplasty and refractive surgery.

Nontuberculous Mycobacteria keratitis is characterized by a delayed onset of symptoms that range typically from 1 to 3 weeks following the exposing event. There is decreased vision and an indolent course and some cases various degrees of pain, ranging from indolent to severe.

Presenting symptoms can include any of the following: pain, redness, photophobia, decreased vision, foreign body sensation and/or mild irritation. Presenting clinical signs include infiltrates in the corneal interface that can either be multiple white granular opacities <0.5mm in diameter with well defined borders or radiating projections, or a single white round lesion (0.1-2 mm in diameter) which may progress to satellite lesions. These infiltrates spread subsequently into the corneal stroma posteriorly and anteriorly and can result in perforation through the flap to surface. [Table 2]. A hypopyon is often found in untreated or poorly treated cases. [25,26]

Lazar and colleagues first described the presence of a "cracked windshield" appearance to the cornea around the edge of the central area of ulceration and infiltrate, seen transiently early in the course of the infection. [25,27,28] This sign consist of radiating lines from the central infiltrate in the middle third of the corneal stroma. It is important to mention that NTM keratitis has also been noted in the absence of epithelial defect with deep stromal keratitis. The corneal infiltrate may show irregular margins.

Signs	Symptoms
Single or multiple white granular opacities with well defined borders or radiating projections	Pain (mild)
Satellite infiltrates	Redness
Hypopyon	Photophobia
Mild or absent anterior chamber reaction	Tearing
"Cracked windshield" appearance	Foreign body sensation
	Decreased visual acuity

Table 2. Signs and symptoms of keratitis caused by mycobacterias

5. Predisposing factors

Nontuberculous Mycobacteria are opportunistic pathogens that require an alteration in the ocular barriers to produce infection. In nearly all reports, a previous history of minor to severe trauma is the common denominator. Men and women are equally affected among NTM keratitis patients who have had LASIK, in contrast to a 70% male preponderance among patients who have not had LASIK, the result of a higher prevalence of trauma in males. [Table 3] [5,29]

Risk factors associated with NTM keratitis

Trauma

Surgical trauma

Refractive surgeries

Laser in situ keratomileusis (LASIK)

Laser epithelial keratomileusis (LASEK)

Corneal transplantation

Radial keratotomy

Photorefractive keratectomy (PRK)

Penetrating keratoplasty (PKP)

Other ophthalmologic surgeries

Extracapsular cataract extraction

Small incision corneal cataract surgery

Suture removal

Contact lens wear

Corticosteroid use

Improper aseptic technique or sterilization of surgical instrumentation

Table 3. Risk factors for the development of nontuberculous mycobacterial keratitis.

Post-LASIK NTM keratitis: Laser in situ keratomileusis (LASIK) is the most commonly performed refractive surgical procedure, since it offers rapid visual rehabilitation, decreased stromal scarring, less postoperative pain, and the ability to treat a wider range of refractive disorders. LASIK preserves the integrity of Bowman’s membrane and the overlying epithelium, thus decreasing the risk for microbial keratitis. Several studies have reported an incidence of bacterial infection following LASIK procedures varying between 0% to 1.5%. [29,31,32] Solomon et. al published the first survey that provides information about

post-LASIK infectious keratitis. The most common organisms cultured were nontuberculous mycobacteria (48%) and staphylococci (33%). These findings are consistent with Chang's research, where he found that nearly 47% of infectious keratitis cases after LASIK appear to be caused by NTM; 32% being caused by *Mycobacterium chelonae* alone. In contrast to the acute or subacute onset of symptoms generally seen postoperatively in bacterial and fungal keratitis, rapid growing atypical mycobacteria may present with a slower onset of clinical disease, from 3 to 14 weeks (3.5 weeks in average) after the procedure. It is important to keep in mind that this is not a rule, and more rapidly growing NTM such as the *Mycobacterium chelonae-abscessus* group may present as soon as 10 days posterior to the refractive surgery. [1,33,34]

Innoculation of NTM to the flap-stromal interface probably takes place at the time of surgery, therefore, it is infrequent to find an epithelial defect, being present in less than half of cases. Corneal infiltrates appear to be entirely within the lamellar flap or at the flap interface and may be either multiple, tiny, white, granular opacities less than 0.5mm in diameter or a single white lesion ranging between 0.1-0.2mm in diameter. Anterior extension of infiltrate with ulceration or anterior perforation of the corneal flap or posterior extension into the stroma is a rare finding and is usually associated with a delay in diagnosis and the beginning of therapy. Anterior chamber reaction is not a common finding, occurring in only 20% of cases.[1,29]

6. Differential diagnosis

NTM keratitis can often be mistaken with other bacterial infections that cause nonsuppurative keratitis. Several authors suggest to keep in mind other causative organisms that may present, in the course of disease, similar clinical features such as fungal keratitis, infectious crystalline keratopathy, Nocardia keratitis, herpes simplex virus, and rarely Acanthamoeba keratitis. In our experience at APEC, the principal differential diagnosis must be made between fungal and Nocardia keratitis.

Fungal keratitis: Often preceded by history of trauma involving plants or foreign bodies. Like NTM, mycotic keratitis may worsen with the use of topical corticosteroids. These keratitis often do not respond to topical antibiotics, as seen with NTM keratitis. Multiple corneal fungal abscesses may emulate the multifocal presentation of NTM keratitis. Sabouraud's agar is essential for the identification of the causative fungus. [Figure 6]

Infectious Crystalline Keratopathy (ICK): "Cracked windshield" corneal appearance may be also seen in this keratitis caused most commonly by Streptococcus species, but unlike this entity, NTM keratitis presents with this sign transiently early in the course. Gorovoy et al first described Infectious crystalline keratopathy in 1984, describing it as a unique corneal infection characterized by and indolent, progressive course: a paucity of inflammation; and

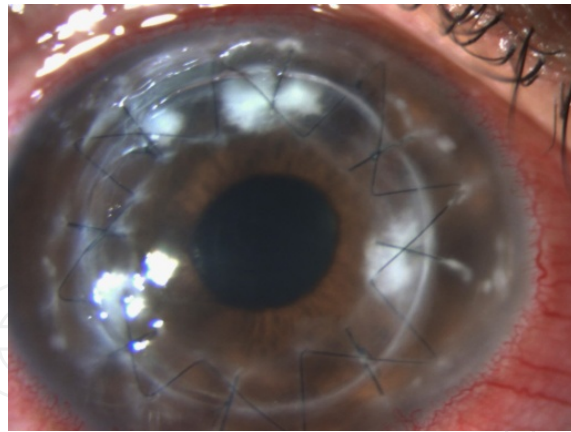


Figure 6. Candida keratitis after penetrating keratoplasty for keratoconus.

the formation of sharply demarcated, gray-white, branching, round, stellate, or needle-like opacities in the corneal stroma. Although the duration of the relatively recalcitrant course of the infectious crystalline keratopathy may mimic NTM keratitis, the crystalline appearance persists in ICK but is transient in NTM keratitis. Among post-LASIK patients, crystalline NTM keratitis occurs rarely (less than 10%).

Nocardiaasteroides infection: should also be considered, since it is an acid-fast microorganism capable of producing bacterial keratitis. The best way to differentiate Nocardia infection from NTM keratitis is with a Gram stain. Nocardia keratitis is more fulminant than NTM keratitis.[Figure 7]

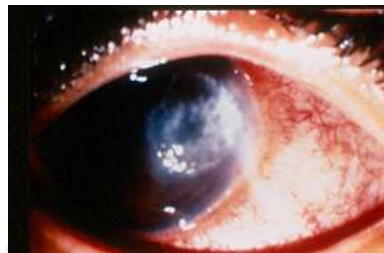

Figure 7. Nocardial keratitis as a differential diagnosis of NTM keratitis.

Deep lamellar keratitis can be confused with post-LASIK NTM keratitis. It usually presents within the first 7 days post-LASIK, and unlike NTM keratitis, it clears with topical corticosteroids. If the wrong diagnosis is made, the improper use of such medications contribute to the delay in diagnosis of post-LASIK NTM keratitis.

Acanthamoeba keratitis generally presents with out-of-proportion pain in comparison to the clinical findings. It is common to see ring ulcers in Acanthamoeba keratitis. This agent responds, unlike NTM, to topical biguanides and diamidines, and topical corticosteroids may be of some benefit.

Herpetic keratitis. In necrotizing stromal keratitis, herpetic keratitis can cause dense white stromal infiltrates that may be confused with NTM keratitis. Special features that are more typically found in herpetic keratitis are decreased corneal sensation and previous or concomitant history of herpes labialis lesions. NTM keratitis may simulate a non-suppurative herpetic keratitis, especially in cases caused by *Mycobacterium marinum*. There may also be a dendritic or geographic epithelial defect with minimal stromal infiltration, misleading the clinician and prompting treatment with antivirals. This can lead to the development of a severe, wide corneal infiltrate.

7. Our experience

Keratitis caused by atypical *Mycobacteria* is characterized by an indolent course and poor response to antibiotics. The diagnosis requires a high index of suspicion and their treatment is usually very difficult. The early diagnosis of nontuberculous mycobacterial keratitis following LASIK is not easy, because the overlying, noninvolved stroma hinders the collection of sufficient material for culture. In addition, such organisms are only detectable by culture in special media, such as Lowenstein-Jensen, and special stains like Ziehl-Neelsen, which may not be included among routine cultures in the microbiology service.

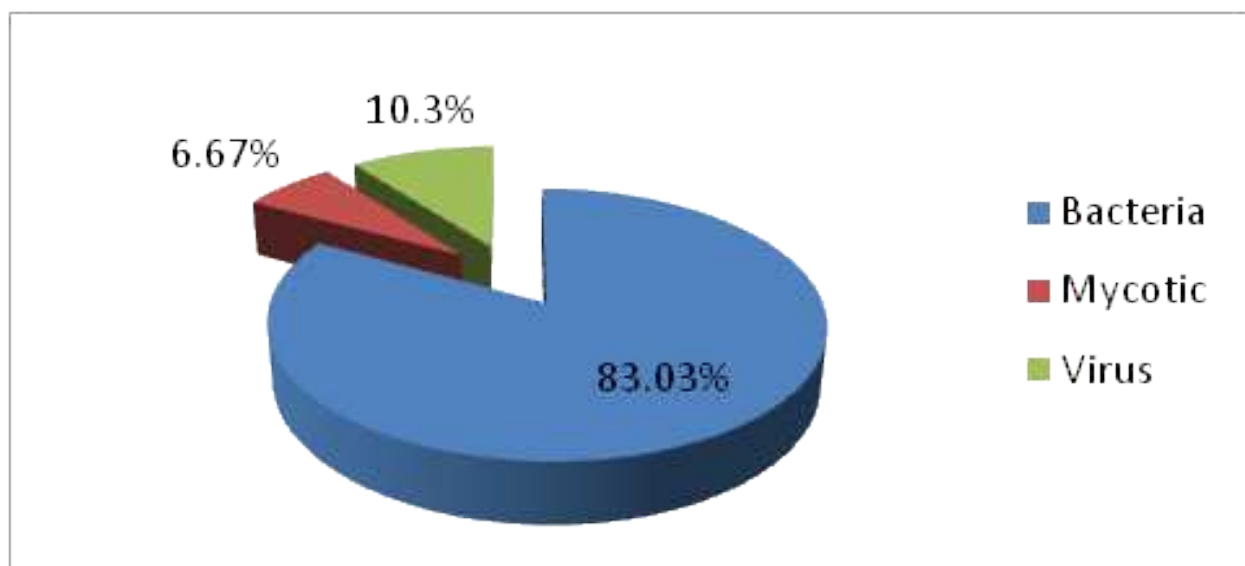


Table 4. Profile of microorganisms causing infectious keratitis; 2025 cases, during 10 years (2000-2010). Data of Asociación Para Evitar La Ceguera en México "Dr. Luis Sánchez Bulnes" I.A.P.

In our hospital, our service found an incidence of 2025 cases of infectious keratitis in the last 10 years (2000-2010). We found that 83.03% corresponded to infections caused by bacteria, 6.67% mycotic, and 10.3% originated by virus. [Table 4] Out of this percentage of bacterial keratitis, we report a frequency of 73.57% caused by gram positive, 9.22% caused by gram negative and 0.24% originated by nontuberculous mycobacteria. [Table 5]

In 100% of cases, the causative agent was *Mycobacterium chelonae*, correlating with the reported in literature.

Several authors reported an incidence between 0% and 1.5% of mycobacterial keratitis post-LASIK, our results (0.24%) correlate with these values. [29,31,32]

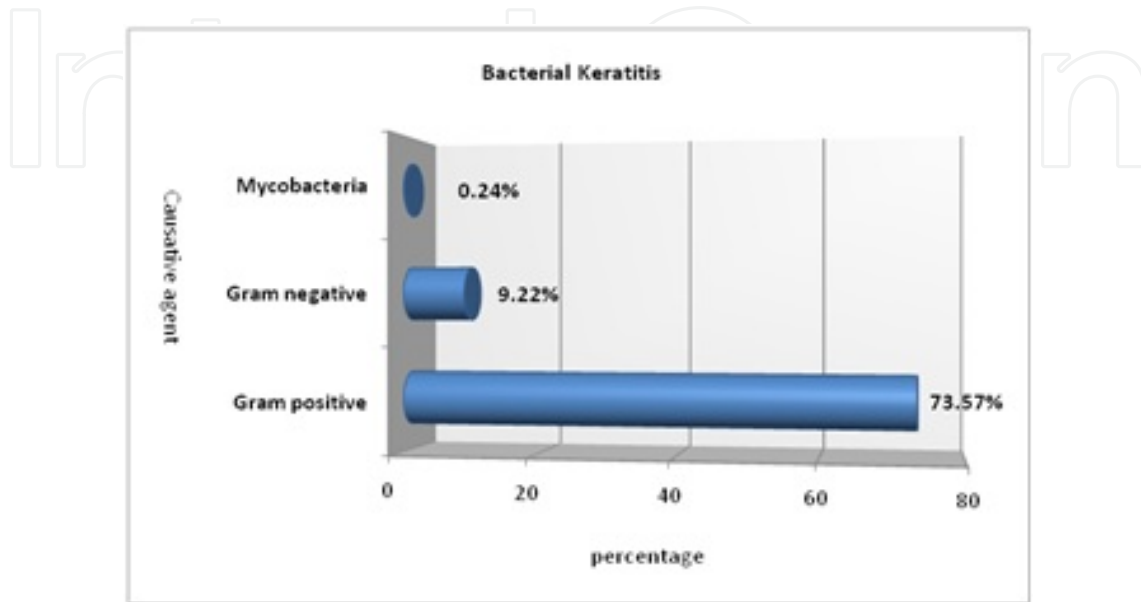


Table 5. The spectrum of bacterial agents causing keratitis. Data of Asociación Para Evitar La Ceguera en México "Dr. Luis Sánchez Bulnes" I.A.P

Almost all our cases (4 out of 6) of nontuberculous mycobacterial keratitis had as common background, a previous history of surgical trauma, specifically speaking of LASIK and PKP. We report one case of a contact lens user. A clinical summary of all cases reported in APEC to date, has been compiled in [Table 6,7]

The average age in our patients was of 36.6 years with a range from 12 to 58 years.

The average time that took from the onset of symptoms to the establishment of correct diagnosis in patients that underwent previous surgical therapy was 4.25 weeks, which results similar to the average of weeks reported in literature (3.5 weeks). [1,33,34]

In our hospital 15,028 LASIK surgeries were performed from 2001-2011. We report in our service a total of 4 cases of infectious keratitis following a LASIK procedure, which resembles an incidence of 1 infection every 3,757 procedures (0.026%). 2 cases (50%) correspond to post-LASIK keratitis caused by *Mycobacterium chelonae*, and the remaining 2 cases (50%) by gram positive bacteria (*Streptococcus pneumoniae*). These findings correlate with the reported by Solomon et al. (year 2003) of 1 infection for every 2919 procedures (0.034%), Donnenfeld et al. (year 2005) who reported an incidence of 1 in every 2131 (0.04%) LASIK procedures and L Lovet et al. (year 2010) with an incidence of 1 in every 2841 cases (0.035%). The study also mentions that 65.5% (76 cases) of the infections reported, presented in the first week

postoperatively. 6.03% (7 cases) presented in the second week, 14.65% (17 cases) presented between the second and fourth week and lastly 13.79% (16 cases) presented after 1 month. 2 of our cases, the ones caused by *Streptococcus pneumoniae*, presented in the first week postoperatively. 1 nontuberculous mycobacterial case presented between the second and fourth week (3 weeks), and lastly the remaining NTM keratitis case presented after 1 month (7 weeks). Speaking of ethiological factors, Solomon et al. reported that the most common microorganisms involved in post-LASIK keratitis are mycobacteria (48%) and coccus (33%), we found similar data in our retrospective analysis; Mycobacterial keratitis 50% and Streptococcus 50%.[30,39,40]

Case	Age/Sex	Eye	Delay in diagnosis	History	Infiltrates/Localization	Initial VA	Previous Eye therapy	Causative organism	Medical therapy
1	57/F	OS	7 weeks	Unilateral redness, photophobia and tearing 6 weeks after bilateral LASIK associated with flap ulcer.	A central epithelial defect measuring 5.0 x 3.0 mm associated with stromal infiltrates involving area of flap. Hypopyon of 1mm.	CF 50cm	Multitreated with Moxifloxacin, Dexamethasone Natamycin and Aciclovir	<i>M. chelonae</i>	Amikacin 3.3% Gatifloxacin 0.3% Topical Rifampin Clarithromycin PO BID
2	58/M	OS	3 weeks	DM. Uneventful bilateral PKP as treatment for keratoglobus. 14 years later unilateral corneal trauma with graft dehiscence and endothelial rejection. Second graft evolved with redness, photophobia, pain and diminished VA, 3 weeks later.	Paracentral lesion 3.0 x 2.0 mm at the graft-host junction, infiltrate with irregular edges, satellite lesion.	CF 2m	Multitreated with Neomycin, Polymixin and Dexamethasone phosphate	<i>M. chelonae</i>	Amikacin 3.3% Gatifloxacin 0.3% Clarithromycin PO BID Fluorometholone
3	27/M	OS	4 weeks	PKP for herpetic leucoma, 4 months later presented with loose suture and ulcer at the site.	Ulcer in graft-host junction.	CF 1m	Multitreated with Prednisolone, Ciprofloxacin, Vancomycin, Fluorometholone	<i>M. chelonae</i>	Gatifloxacin 0.3% Ciprofloxacin PO BID Lubricant eye drops
4	43/F	OS	6 weeks	Redness, photophobia and tearing. Contact lens user.	Paracentral infiltrate with satellite lesion.	CF 2m	Multitreated with Vancomycin, Tobramycin, Ofloxacin	<i>M. chelonae</i>	Amikacin c/3hrs. Gatifloxacin 0.3% Clarithromycin PO BID
5	23/M	OD	3 weeks	Bilateral LASIK. post surgery unilateral hyperemia, photophobia and tearing.	3.5 mm intralamellar central infiltrate	20/400	Multitreated with Ofloxacin, Vancomycin, Moxifloxacin	<i>M. chelonae</i>	Amikacin c/3hrs. Gatifloxacin 0.3% Clarithromycin PO BID

F=female, M=male, CF=count fingers, OS=left eye, OD=right eye, PO=per oral, BID=twice daily, DM=Diabetes Mellitus, VA= visual acuity, PKP=penetrating keratoplasty, LASIK=laser in situ keratomileusis

Table 6. Nontuberculous mycobacterial keratitis in patients of Asociación Para Evitar La Ceguera en México "Dr. Luis Sánchez Bulnes" I.A.P.

Velotta reported that nearly 90% of NTM keratitis after LASIK cases are unilateral, all of our cases presented in just one eye.

Infectious keratitis after penetrating keratoplasty (PKP) is not a frequent complication with an incidence ranging from 1.8% to 11.0%; however, this infection has a high risk of loss of corneal clarity. In our present analysis, the remaining 2 patients that underwent surgical procedures, developed nontuberculous mycobacterial keratitis posterior to penetrating keratoplasty. Both cases were promptly diagnosed after onset of symptoms, resulting in satisfactory outcomes and good final visual acuity [Table 7] [Figure 8,9]

Case	Surgical Treatment	Follow up	Outcome	Final Visual Acuity	Refraction
1	Flap amputation + scraping + irrigation with gatifloxacin 0.3% First PKP (<i>with recurrence</i>) Second PKP + Ahmed valve implant + ECCE & IOL	30 months	resolved	20/70	+8.00=-4.00x140°
2	None	18 months	resolved	20/30	Contact lens +3.50 D
3	None	10 months	resolved	20/30	Contact lens 8.30 Power -7.00, Diameter 9.6
4	None	3 months	resolved	20/20	-4.00=-3.00 X180°
5	None	3 months	resolved	20/60	-2.00=-1.00x45°

PKP=penetrating keratoplasty, ECCE=extracapsular, IOL=intraocular lens.

Table 7. Surgical treatment and outcome in nontuberculous mycobacterial keratitis in patients of Asociación Para Evitar La Ceguera en México "Dr. Luis Sánchez Bulnes" I.A.P.

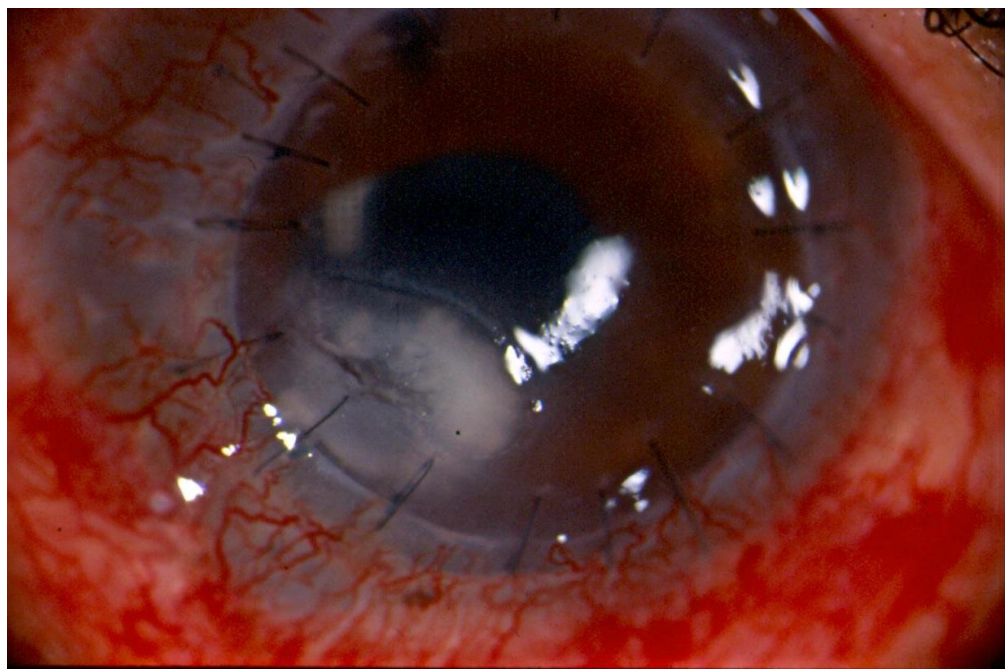


Figure 8. Patient 2, clinical examination 4 weeks after penetrating keratoplasty with conjunctival hyperemia and corneal infiltrate (3.0 x 2.0 mm) in graft-host junction caused by *Mycobacterium chelonae*.

8. Treatment

Management of this type of infectious keratitis often translates in a medical challenge. In cases of identified NTM corneal infection, there is considerable benefit from the use of combined antibiotics, since atypical mycobacteria have a slower growth rate compared to other bacteria and may become resistant to a single antibiotic class during the course of extended treatment.

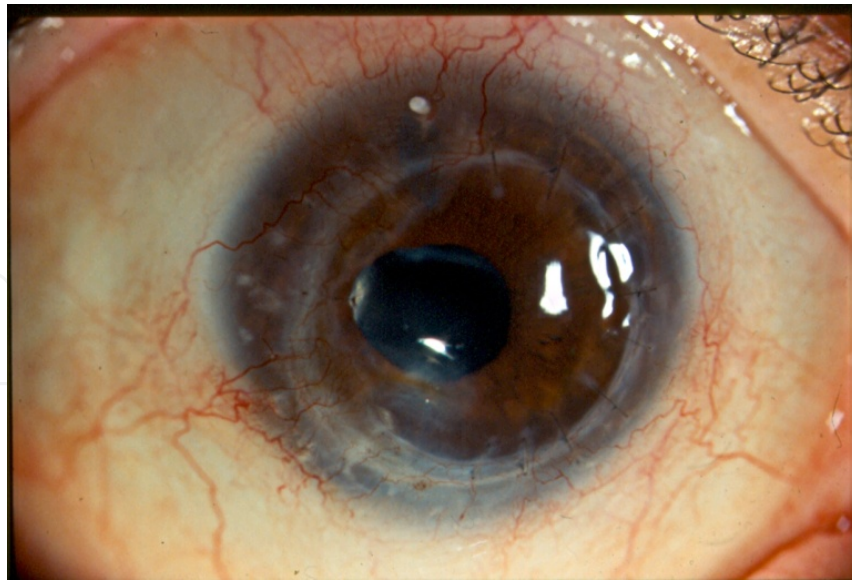


Figure 9. Patient 2, eighteen months after therapy discontinuation. Corneal graft is infection-free and clear in the visual axis; best-corrected vision of 20/30 was attained with a +3.50-D contact lens.

The base of treatment consists of a double approach; appropriate antibiotic and judicious surgical intervention. Such antimicrobial choice becomes complicated since a poor correlation exists between *in vitro* susceptibility profiles and the final clinical response. We recommend surgical debridement, depending on the case, to facilitate drug penetration to the interlamellar space. In some cases, flap amputation may be necessary, the rationale for this procedure is to lower the bacterial load, remove necrotic as well as infected tissue, and permit better antibiotic penetration. We recommend this surgical procedures in recalcitrant post-LASIK NTM keratitis to maintain the infection under control.

De La Cruz et al. suggest initial combined antibiotic therapy that includes at least 2 of the 3 most susceptible agents (clarithromycin, amikacin, and fourth-generation fluoroquinolones) for rapidly growing mycobacteria specially if known resistance has been documented. The initial therapy recommended for many years has been the use of topical Amikacin sulfate 20-40mg/mL. This antibiotic is the most frequently used agent in the treatment of NTM keratitis. In our institution we use amikacin sulfate (Amikin® 500mg injectable solution. Bristol-Myers Squibb de México S. de R.L. de C.V.) diluted to a concentration of 20mg/mL, one drop every hour and dose-response. Even though this antibiotic constitutes the first line of treatment against atypical mycobacterial keratitis, only a success rate of 30-40% has been reported. This therapeutic agent has also been associated with high epithelium toxicity when it is applied for a prolonged course.

We recommend the addition of two additional antibiotics to the drug scheme, such as a macrolide like clarithromycin and a fourth-generation fluoroquinolone like gatifloxacin. [Table 6] In our hospital we employ oral clarithromycin Klaricid H.P.® 500mg (Abbott Laboratories de México S.A. de C.V. México, D.F.) twice daily, and Zymar® (gatifloxacin 0.3% Allergan Labs, Irvine, CA).

Fluoroquinolone antibiotics are concentration-dependent killers. Therefore, they require a minimum inhibitory concentration (MIC) to be reached in order to be effective. In vitro studies have shown that fourth-generation fluoroquinolones are effective against atypical mycobacteria, inhibiting 90% of isolates after reaching its proper concentration.[23,43]

The fourth-generation fluoroquinolones have significant advantages over earlier generation fluoroquinolones in treating mycobacterial infections, including superior bactericidal activity, higher corneal concentrations, and decreased risk for bacterial resistance.

The reason for adding a fourth-generation fluoroquinolone to the therapeutic scheme is that 8-methoxy-fluoroquinolones such as gatifloxacin and moxifloxacin has shown better in vitro activity against these organisms, in comparison to second-generation fluoroquinolones like ciprofloxacin.

Furthermore, the molecular structures of moxifloxacin and gatifloxacin have a greater binding affinity for 2 of the enzymes necessary for bacterial DNA synthesis (deoxyribonucleic acid gyrase [also called topoisomerase II] and topoisomerase IV) in both gram-negative and gram-positive microorganisms. By inhibiting such enzymes, these bacteria require to undergo two genetic mutations in order to create resistance. Older fluoroquinolones adequately inhibit topoisomerase II in gram-negative microorganisms but are not as effective in inhibiting topoisomerase IV in gram-positive organisms.

The great effectiveness of fourth-generation fluoroquinolones rely due to their superior bactericidal activity, the ability to reach higher corneal concentration, and better resistance pattern. In a rabbit model, fourth-generation fluoroquinolones were found to be synergistic to our first-line drug options, amikacin and clarithromycin against *M. chelonae*. Lastly, considering antibiotic resistance as an emerging problem; Ford et al. reported in their study that more than 60% of atypical mycobacteria are unresponsive to second-generation fluoroquinolones. [5,34]

Lazar et al reported a torpid answer to the use of Rifampin in nontuberculous mycobacteria ocular infections. In our experience, we required to add a new antibiotic drug in patient 1 (Table 6), when we reached the three antibiotics suggested by diverse authors in literature (Amikacin, Clarythromicin and Gatifloxacin). We added topical rifampin to the scheme obtaining positive outcomes. We prepared a topical solution of Rifampin at our hospital by dissolving 300mg of Rifampin (Rifadin®) (SANOFI-AVENTIS de México, S.A. de C.V.) with 10mL of Sodium Hyaluronate (Lagricel® SOPHIA, S.A. de C.V., Laboratorios. Guadalajara, México) indicating a drop every hour and dose-response.

Management of mycobacterial keratitis usually requires a prolonged and intensive therapy consisting of topical and systemic medication. In our experience, medical treatment of NTM keratitis can prolong as long as 30 months. Shih et al have reported full months of therapy even when the appropriate antibiotic, chosen by drug sensitivity test results, is used. In [Table 8]we summarize our suggested treatment for the proper management of nontuberculous Mycobacterial keratitis.

Suggested treatment		
Triple Antibiotic Therapy	Topical	1. Amikacin 20 mg/mL 2. Fourth-generation fluoroquinolone (gatifloxacin)
	Systemic	3. Clarithromycin 500mg PO BID
* In case of resistance addition of Rifampin 30mg/mL.		
Surgical Therapy		1. Flap lift and irrigation
		2. Flap amputation in post-LASIK
		3. Biopsy and culture
		4. Penetrating keratoplasty

Table 8. We suggest a triple antibiotic treatment combined if needed with surgical therapy.

9. Modification to initial therapy

The medical response of mycobacterial keratitis to antibiotic therapy can be achieved by constant clinical observance. This can be difficult to appreciate in the first days of treatment due to increase in inflammation and local reaction to topical agents. The clinical response varies depending on the microorganism and pathogenicity of the mycobacteria, duration of the infection, risk factors involved and the patient's individual response (immunosuppression).

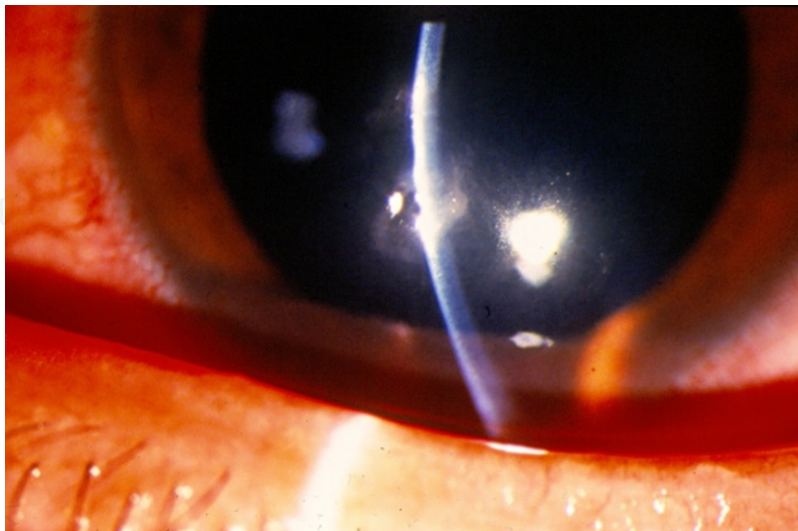


Figure 10. Patient 4 presented in the first clinical examination a paracentral infiltrate caused by *Mycobacterium chelonae*. Previous to initiation of proper antibiotic treatment. At this moment visual acuity was count fingers 2 meters.

If the chosen therapy is effective, some response should manifest within the first of 24 to 72 hours of appropriate treatment. [Figure 10,11]. Said response manifests with the decrease of stromal infiltrates and less anterior chamber inflammation in case it exists. [Figure 12, 13]

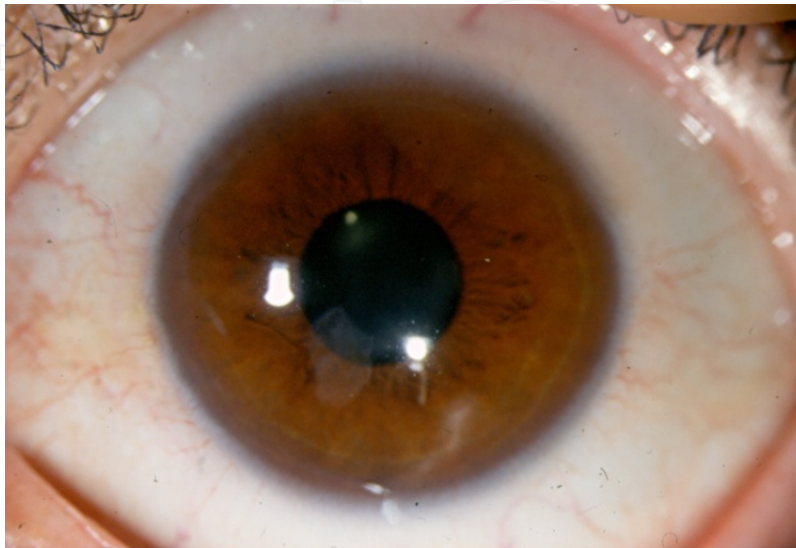


Figure 11. Patient 4 at 3 months follow-up after proper antibiotic treatment was applied. Final visual acuity was 20/30.

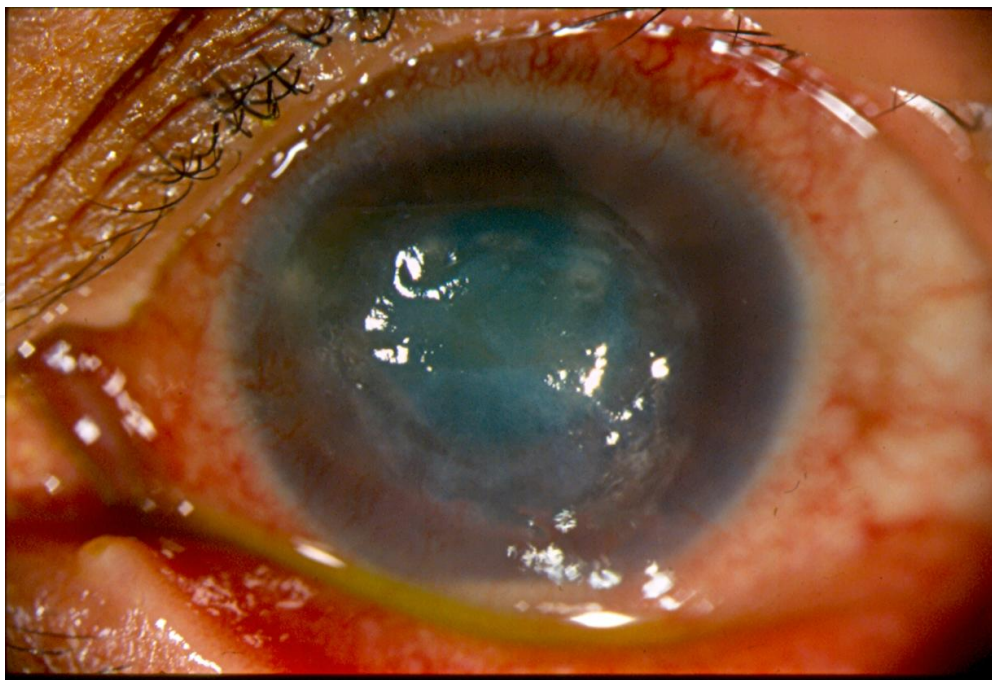

Figure 12. Patient 1 with preceding hypopyon (black arrow) and anterior chamber reaction who underwent a therapeutic flap amputation procedure.

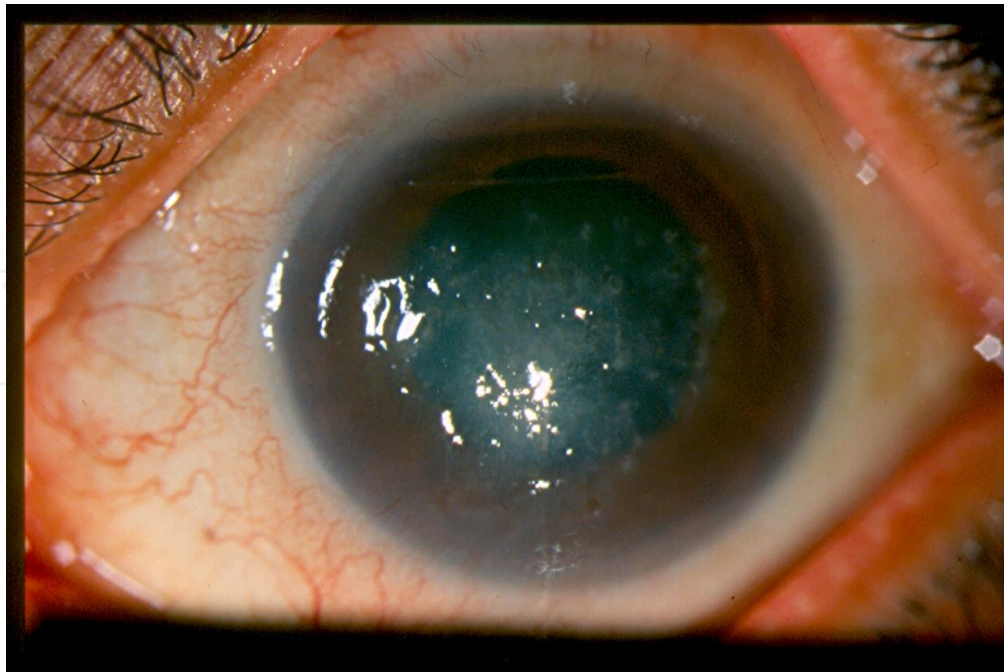


Figure 13. Absence of ahyopyon seen in Patient 1 as a manifestation of positive response to antibiotic treatment.

If clinical improvement exists at 48 hours of initiation of treatment, we encourage to continue the same pharmacological agents, reducing the administration time to 1 drop every 2 hours until completion of 5 days with night rest. After the 5 days, if further improvement exists, antibiotic doses should be decreased progressively in function of clinical response, drug tolerance and sensitivity tests results. Antibiotic with the best sensitivity should be the one chosen to continue the treatment for 2-3 more weeks.

Special caution should be kept when therapy is suspended, as some microorganisms may remain in corneal tissue. In this case, a prolonged treatment may be required.

If lesion progression occurs after 48 hours of initiation of treatment, manifested by evident increase in size, stromal thinning or incomplete resolution of symptoms, the ophthalmologist should consider a lack of sensitivity to the chosen treatment or a failure in the patient's attachment to the therapy. Culture results should be rechecked as well as sensitivity test results, as an addition of a different antimicrobial agent might be needed.[Table 9]

Positive clinical response parameters	Negative clinical response parameters
Peripheral corneal clearance of infiltrates and density reduction.	Increase in size or depth.
Decrease in stromal edema.	Stromal thinning.
Less anterior chamber inflammation.	Partial resolution of symptoms.
Corneal epithelial regeneration.	

Table 9. Response parameters associated with antibiotic therapy

10. Complementary therapy

Pain management: The cornea is a highly innervated tissue. Despite most of the times, these lesions tend to have an indolent course, on occasions, patients can refer any degree of pain, ranging from mild to severe. The clinician should administer a cyclopegic agent to ease the symptoms caused by ciliary spasms and to prevent the formation of sinequiae. We recommend the employment of cyclopentolate 1% eye drops or Atropine 1% collyrium every 12 hours.

Topical corticosteroids: Its role and appropriate moment of use is a controversial topic. Corticosteroids are applied to diminish the host's inflammatory response, capable of producing tissue destruction. Its use is also aimed to decrease the subsequent corneal cicatrization. Nevertheless, some potential adverse effects of these agents include bacterial growth stimulation by local immunosuppression, decrease in phagocytic activity, inhibition of collagen synthesis, drug-induced glaucoma and secondary cataract formation. Several experimental studies have shown a lack of harmful effects associated by addition of steroids to the preexistent bactericidal regime in keratitis. However, other studies documented an increase in bacterial growth with the addition of topical steroids to previous therapy. Due to the uncertain role of these agents in keratitis caused by nontuberculous mycobacteria, we recommend the use of low doses of steroids like fluorometholone (Flumetol® SOPHIA, S.A. de C.V., Laboratorios. Guadalajara, México) if it is considered appropriate, only when certainty exists of the infectious process being under control or in an inactive phase.

Alternate medical treatment: Authors have recommended the use of Azithromycin 2mg/mL or 1%, prepared Clarithromycin eye drops 10mg/mL, imipenem, tobramycin and systemic doxycyclin. We do not have experience with these drugs. [1,5]

Surgical treatment Conjunctival flap: Its purpose is aimed to provide blood vessels to the infected area, thus promoting curation. It is indicated in uncontrolled progression of the corneal lesion or infiltrates, limbal compromise with imminent scleritis or elevated risk of corneal perforation.

Therapeutic penetrating keratoplasty: It is difficult to perform in the initial stages of mycobacterium keratitis, furthermore it involves a higher incidence of complications and an inferior graft survival rate in comparison to optical PKP in an inactive process. We recommend to avoid this surgical option when possible. The indications for urgent therapeutic PKP are:

- Uncontrolled progression of the infection.
- Imminent risk of corneal perforation
- Confirmed corneal perforation.

We recommend maximal antibiotic therapy for 48 hours prior to surgery to decrease the number of bacterial colonies as much as possible and consequently the diminish the risk of endophthalmitis. Additional to topical antibiotics, we suggest the use of systemic antimicrobial and antiinflammatory agents in the preoperative period. The trepan employed

on the recipient's cornea should be of enough size to extract the entire infected area, and the donor's corneal graft should be 0.5mm bigger than the measurement made on the recipient's cornea. It is advisable to obtain cultures from one half of the obtained cornea tissue (including stains and special culture media), and the other half should be sent for histopathological study. Sutures should be placed separately due to intense inflammatory reaction. In the postoperative period, corticosteroid therapy should be continued as well as specific antibiotics. Systemic therapy should continue. Posterior to the complete resolution of corneal infection, an optical PKP is an option of treatment to seek visual rehabilitation, as seen in out patient that appears on [Table 7]. As a consequence of the long term infectious process caused by mycobacterium keratitis, secondary cataract formation can be induced by the production of toxins, iridocyclitis, treatment toxicity and corticosteroid usage. For this complication, and optic PKP combined with a cataract extraction and Ahmed valve implantation can be considered as a treatment option, as seen in patient 1 who developed glaucoma.[Table 6,7]

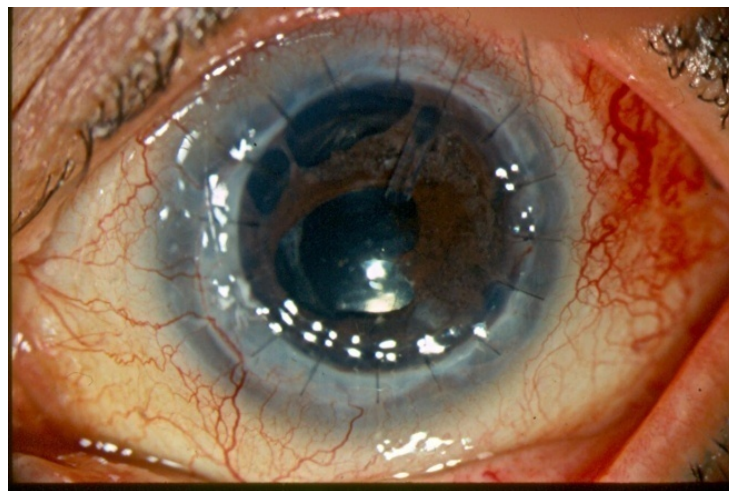


Figure 14. Patient 1 treated with optic PKP combined with Ahmed valve implantation and cataract extraction with colocation of intraocular lens posterior to the resolution of nontuberculous mycobacterial keratitis.

11. Conclusion

We describe our experience in patients who developed keratitis caused by nontuberculous mycobacteria. As the most common cause of post-LASIK keratitis is NTM, a greater degree of suspicion, recognition of typical clinical course and presentation, and knowledge of similar cluster of NTM keratitis prompts rapid institution of appropriate antibiotic therapy, granting this cases with a better prognosis in comparison with those of late diagnosis. Antibiotic resistance continues to be an emerging problem, thus a limitation in the coverage of this pharmacological agents exists. We emphasize the need for vigilance in the follow-up of patients. Appropriate adjustment of antimicrobial therapy may be required based on cultures and sensitivity tests when atypical mycobacteria are responsible for corneal infection.

We believe that fourth-fluoroquinolones adequately combined with first-line antibiotics constitute the best option so far to treat keratitis caused by atypical mycobacteria.

Acknowledgements

We express our gratitude to the cornea service and pathology service at Asociación Para Evitar La Ceguera en México "Hospital Dr. Luís Sánchez Bulnes" for their valuable contribution with images that helped making this chapter possible. Also to Miss. Elia Portugal for her assistance in the translation of this work.

Author details

Ana Lilia Pérez-Balbuena¹, David Arturo Ancona-Lezama¹, Lorena Gutiérrez-Sánchez¹ and Virginia Vanzzini-Zago²

1 Cornea Service. Asociación para Evitar la Ceguera en México I.A.P. "Hospital. Dr. Luis Sánchez Bulnes". Vicente García Torres, México D.F., México

2 Laboratory of Microbiology. Asociación para Evitar la Ceguera en México I.A.P. "Hospital. Dr. Luis Sánchez Bulnes". Vicente García Torres, México D.F., México

References

- [1] Moorthy RS, Valluri S, Rao NA. Major Review; Nontuberculous Mycobacterial Ocular and Adnexal Infections. *Surv Ophthalmol* 2012;57:202-235.
- [2] Pallikaris IG, Papatzanaki ME, Stathi EZ, et al. Laser in situ keratomileusis. *Lasers Surg Med* 1990;10:463-468.
- [3] Krachmer JH, Mannis MJ, Holland EJ. Cornea, Chapter 82. Nontuberculous Mycobacteria Keratitis. 3rd edition. Elsevier Mosby.
- [4] Chandra NS, Torres MF, Winthrop KL, Bruckner DA, Heidemann DG, Calvet HM, Yakrus M, Mondino BJ, Holland GN. Cluster of Mycobacterium chelonae keratitis cases following laser in-situ keratomileusis. *Am J Ophthalmol*. 2001;132(6):819-830.
- [5] Ford JG, Huang AJ, Pflugfelder SC, Alfonso EC, Forster RK, Miller D. Nontuberculous mycobacterial keratitis in south Florida. *Ophthalmology*. 1998;105(9):1652-1658.
- [6] Freitas D, Alvarenga L, Sampaio J, Mannis M, Sato E, Sousa L, Vieira L, Yu MC, Martins MC, Hoffling-Lima A, Belfort R Jr. An outbreak of Mycobacterium chelonae infection after LASIK. *Ophthalmology*. 2003;110(2):276-285.

- [7] Garg P, Bansal AK, Sharma S, Vemuganti GK. Bilateral infectious keratitis after laser in situ keratomileusis: a case report and review of the literature. *Ophthalmology*. 2001;108(1):121-125.
- [8] Kouyoumdjian GA, Forstot SL, Durairaj VD, Damiano RE. Infectious keratitis after laser refractive surgery. *Ophthalmology*. 2001 Jul;108(7):1266-1268.
- [9] Maloney RK. Cluster of *Mycobacterium chelonae* keratitis cases following laser in situ keratomileusis. *Am J Ophthalmol*. 2002;134(2):298-299.
- [10] Solomon A, Karp CL, Miller D, Dubovy SR, Huang AJ, Culbertson WW. *Mycobacterium* interface keratitis after laser in situ keratomileusis. *Ophthalmology*. 2001;108(12):2201-2208.
- [11] Sossi N, Feldman RM, Feldman ST, Frueh BE, McGuire G, Davis C. *Mycobacterium gordonae* keratitis after penetrating keratoplasty. *Arch Ophthalmol*. 1991;109(8):1064-1065.
- [12] Winthrop KL, Steinberg EB, Holmes G, Kainer MA, Werner SB, Winkler A, Vugia DJ. Epidemic and sporadic cases of nontuberculous mycobacterial keratitis associated with laser in situ keratomileusis. *Am J Ophthalmol*. 2003;135(2):223-224.
- [13] Pfyffer GE, Palicova F. *Mycobacterium*: General characteristics, laboratory detection, and staining procedures. In Versalovic J, Carroll KC, Tenover FC, Tenover FC, Jorgensen JH, Landry ML, Warnock DW. *Manual of Clinical Microbiology* 10th ed. ASM press. Washington DC. 472-502.
- [14] Runyon EH. Identification of mycobacterial pathogens using colony characteristics. *Am J Clin Pathol*. 1970;54:578-586.
- [15] Vincent V, Brown-Elliott BA, Jost KC Jr, et al. *Mycobacterium*: Phenotypic and Genotypic Identification, in Murray PR, Baron EJ, Jorgensen JH, Tenover FC, Tenover FC (eds) *Manual of Clinical Microbiology*. Vol. 1. Washington, DC, ASM Press, 2003, 8th ed, pp 560-658.
- [16] Broadway DC, Kerr-Muir MG, Eykyn SJ, Pambakian H. *Mycobacterium chelonae* keratitis: a case report and review of previously reported cases. *Eye* 1994; 8: 134-142.
- [17] Fowler AM, Dutton JJ, Fowler WC, et al. *Mycobacterium chelonae* canaliculitis associated with SmartPlug use. *Ophthalmol Plast Reconstr Surg*. 2008;24:241-243.
- [18] Chang WJ, Tse DT, Rosa RH Jr, et al. Periocular atypical mycobacterial infections. [see comment]. *Ophthalmology*. 1999;106:86-90.
- [19] Mauriello JA Jr. Atypical Mycobacterial Study G. Atypical mycobacterial infection of the periocular region after periocular and facial surgery. *Ophthalmol Plast Reconstr Surg*. 2003;19:182-188
- [20] Margo CE, Pavan PR. *Mycobacterium chelonae* conjunctivitis and scleritis following vitrectomy. *Arch Ophthalmol*. 2000;118:1125–1128.

- [21] Nash KA, Zhang Y, Brown-Elliott BA, et al. Molecular basis of intrinsic macrolide resistance in clinical isolates of *Mycobacterium fortuitum*. *J Antimicrob Chemother.* 2005; 55:170-177.
- [22] Benz MS, Murray TG, Dubovy SR, et al. Endophthalmitis caused by *Mycobacterium chelonae* abscess after intravitreal injection of triamcinolone. *Arch Ophthalmol.* 2003;121:271-273.
- [23] Velotta JT. Nontuberculous (atypical) mycobacterial keratitis after LASIK: current status and clinical implications. *Cornea.* 2005;24:245-255
- [24] Rola NH, Baha N, Hayham IS, Randa H, Johnny MK. Recalcitrant post-LASIK *Mycobacterium chelonae* Keratitis Eradicates after the Use of Fourth-Generation Fluoroquinolone. *Ophthalmology* 2006;113:950-954.
- [25] Lazar M, Nemet P, Bracha R, et al. *Mycobacterium fortuitum* keratitis. *Am J Ophthalmol* 1974;78:530-532.
- [26] Reviglio V, Rodriguez ML, Picotti GS, et al. *Mycobacterium Chelonae* Keratitis Following Laser in situ Keratomileusis. *J Refract Surg* 1998;14:357-360.
- [27] Mirate D, Hull D, Steel J, et al. *Mycobacterium chelonae* keratitis: a case report. *Br J Ophthalmol* 1983;67:324-327.
- [28] Zabel R, Mintsoulis G, MacDonald I. *Mycobacterium* keratitis in a soft contact lens wearer. *Can J Ophthalmol.* 1988;23:315-317.
- [29] Chang MA, Jain S, Azar DT. Infections following laser in situ keratomileusis: an integration of the published literature. *Surv Ophthalmol.* 2004;49:269-280.
- [30] Solomon R, Donnenfeld ED, Azar DT. Infectious keratitis after laser in situ keratomileusis: Results of an ASCRS survey. *J Cataract Refract Surg* 2003;29:2001-2006
- [31] Lin RT, Maloney RK- Flap complications associated with lamellar refractive surgery. *Am J Ophthalmol* 1999;127(2):129-136.
- [32] Machat J. LASIK complications and their management. In Machat J, editor: *Excimer laser refractive surgery: practice and principles*, Thorofare, NJ 1996, Slacc 359-400.
- [33] Alvarenga L, Fretias D, Hofling-Lima AL, et al. Infectious post-LASIK crystalline keratopathy caused by nontuberculous mycobacteria. *Cornea.* 2002;21:426-429.
- [34] De La Cruz J, Behlau I, Pineda R. Atypical mycobacteria keratitis after laser in situ keratomileusis unresponsive to fourth-generation fluoroquinolone therapy. *J Cataract Refract Surg* 2007;33:1318-1321.
- [35] Shukla PK, Kumar M, Keshava GBS. Mycotic keratitis: an overview of diagnosis and therapy. *Mycoses.* 2008;51:183-199.
- [36] Dart JKG, Saw VPJ, Kilvington S. *Acanthamoeba* keratitis: diagnosis and treatment update 2009. *Am J Ophthalmol.* 2009;148:487-499.

- [37] Knickelbein JE, Hendricks RL, Charukamnoetkanok P. Management of herpes simplex virus stromal keratitis: An evidence-based review. *SurvOphthalmol*. 2009;54:226-234.
- [38] Schonherr U, Naumann GO, Lang GK, et al. Sclerokeratitis caused by *Mycobacterium marinum*. *Am J Ophthalmol*. 1989;108:607-608
- [39] Donnenfeld ED, Kim TK, Holland EJ, Azar DT, Palmon FR, Rubenstein JB, Daya S, Yoo SH. American Society of Cataract and Refractive Surgery Cornea Clinical Committee. ASCRS White Paper. Management of infectious keratitis following laser in situ keratomileusis. *J Cataract Refract Surg* 2005;31:2008-2011.
- [40] Llovet F, de Rojas V, Interlandi E, Martín C, Cobo-Soriano R, Ortega-Usobiaga J, Baviera J. Infectiouskeratitia in 204586 LASIK procedures. *Ophthalmology* 2010;117:232-238.
- [41] Pérez-Balbuena AL, Vanzzini-Zago V, Garza M, Cuevas-Cancino D. Atypical *Mycobacterium* Keratitis Associated With Penetrating Keratoplasty: Case Report of Successful Therapy With Topical Gatifloxacin 0.3%. *Cornea* 2010;29:468-470.
- [42] Bullington RH Jr, Lanier JD, Font RL. Nontuberculous mycobacteria keratitis; report of two cases and review of the literature. *Arch Ophthalmol* 1992;110:519-524.
- [43] Hu F-R, Luh K-T. Topical ciprofloxacin for treating nontuberculous mycobacterial keratitis. *Ophthalmology* 1998;105:269-272.
- [44] Schleich BA, Alfonso E. Overview of the potency of moxifloxacin ophthalmic solution 0.5% (VIGAMOX®). *SurvOphthalmol* 2005;50(suppl):S7-S15.
- [45] Hamam RN, Nouredin B, Salti H, et al. Recalcitrant post-LASIK *Mycobacterium chelonae* keratitis eradicated after the use of fourth-generation fluoroquinolones. *Ophthalmology* 2006;113:950-954.
- [46] Hyon JY, Joo MJ, Hose S, et al comparative efficacy of topical gatifloxacin with ciprofloxacin, amikacin, and clarithromycin in the treatment of experimental *Mycobacterium chelonae* keratitis. *Arch Ophthalmol* 2004;122:1166-1169.
- [47] Shih et al have reported full months of therapy even when the appropriate antibiotic, chosen by drug sensitivity test results, is used. (Shih MH, Huang FC. Effects of Photodynamic Therapy on Rapidly Growing Nontuberculous Mycobacteria Keratitis. *Invest Ophthalmol Vis Sci*. 2011; 52:223-229.
- [48] Banoch PR, Hay GJ, McDonellPJ, et al. A rat model of bacterial keratitis :effects of antibiotics and corticosteroids. *Arch Ophthalmol* 1980;98:718-20.
- [49] Leibowitz HM, Kupferman A. Topically administered corticosteroids: effect with antibiotic treated bacterial keratitis. *Arch ophthalmol* 1980, 98: 1287-1290.

- [50] Pérez-Balbuena AL, Santander-García D, Vazzini-Zago V. Therapeutic Keratoplasty for Microbial Keratitis. In: Mosca L. Keratoplasties. Surgical Techniques and Complications. Rijeka: InTech; 2011.

IntechOpen

IntechOpen

