

We are IntechOpen, the world's leading publisher of Open Access books Built by scientists, for scientists

4,800

Open access books available

122,000

International authors and editors

135M

Downloads

Our authors are among the

154

Countries delivered to

TOP 1%

most cited scientists

12.2%

Contributors from top 500 universities



WEB OF SCIENCE™

Selection of our books indexed in the Book Citation Index
in Web of Science™ Core Collection (BKCI)

Interested in publishing with us?
Contact book.department@intechopen.com

Numbers displayed above are based on latest data collected.

For more information visit www.intechopen.com



Contributions to the Understanding of the Neural Bases of the Consciousness

Leon Dănilă and Mihail Lucian Pascu

Additional information is available at the end of the chapter

<http://dx.doi.org/10.5772/52688>

1. Introduction

Perhaps no concept is as difficult to define and understand as human consciousness. Its nature has been intensively debated for centuries by philosophers [1], for decades by psychologists [2], and by neuroscientists [3] as knowledge and techniques have advanced to the point where an experimental approach to such a complex issue is finally possible [4].

The cognitive revolution in psychology was paralleled by the development of the field of cognitive science, whose practitioners included neuroscientists, behavioral biologists, neurosurgeons, psychologists, psychiatrists, philosophers, linguists, sociologists, anthropologists and even physicists.

Over many centuries, philosophers and physicians, poets and priests have debated and written at great length on how mind may relate to brain.

And it is not surprising that neurosurgeons, from their unrivaled vantage point of dealing with the human brain, sometimes in conscious patients (as during epilepsy surgery), should seek answers to this seductive enigma.

There is no accepted definition of consciousness. While some take consciousness to be a unique substance, others say it is a special property, and still others claim it to be nothing more than the operation of the brain [5]. Other authors have shown that consciousness includes “what it is like” to be something. So, the role of subjectivity should be one component, if not the essential one in any definition of consciousness [6].

Consciousness has been also called “the last surviving mystery” [7]. Crick considered consciousness the central problem of biology [8]. According to [5], understanding consciousness implies to produce the quintessence of philosophy, psychology, neuroscience and several other fields of study.

Consciousness may be also defined as our awareness of our environment, our bodies and ourselves [9]. Awareness of ourselves implies an awareness of awareness, that is the conscious of being. Awareness of ourselves implies meta-cognition [9, 10]. Some authors emphasize consciousness as a momentary creation of a neural pattern which describes a relation between the organism and an object or event [11]. According to [12], consciousness is, quite literally, mind-boggling.

We consider that consciousness is an universal set of neurologic and mental or spiritual processes produced by the brain in awake state, which allows people to understand the mind of others (mind reading); it also allows an optimal social living to perform any kind of high normal behavior activity (social, political, professional, moral, ethic, religious, etc.) related to the self and the environment (family, society).

So, the two separate forms of consciousness are neurologic on one hand and mental or spiritual on the other. Although many theorists treat consciousness as single, all-or-nothing phenomenon, others distinguish between first-order consciousness and a meta-level of consciousness. For example, they may distinguish between consciousness and metaconsciousness [13], primary consciousness and higher-order consciousness [14], or core consciousness and extended consciousness [15]. Animals possess primary (core) consciousness which comprises sensory awareness, attention, perception, memory (or learning), emotion and action [12, 16]. In [16] it is also shown that every organism, even bacteria, would possess some degree of consciousness.

However, animals have got an inferior consciousness function. It is, of course, unclear at what phylogenetic level this assumption - about self-awareness and the environment - falls below the definition of consciousness as we noted it. According to [9], what differentiates humans from their fellow mammals, and gives humans what Edelman defines as secondary consciousness, depends upon language and the associated enrichment of cognition that allow humans to develop and to use verbal and numeric abstraction. Spoken and written language are human specializations. These mental capacities contribute to our sense of self as agents and as creative beings. This fact also determines the awareness of awareness that we assume our animal "collaborators" do not possess [9].

Many factors are involved in establishing the levels of consciousness commonly referred to as wakefulness and sleep. Such factors include the enormous driving of the cerebral cortex over the ascending activating and inhibiting systems and the influence of cyclic limbic activation of cerebral cortical areas. There are complex interconnections between these areas of the nervous system. But, the brain is such a complex structure that even now we know only a tiny portion of what is to be known about it. By dividing consciousness into various attributes - self-reflection, attention, memory, perception emotion, arousal, thoughts - and ordering these into a functional hierarchy, we can link anatomy and function. So, consciousness must be a function of numerous interacting systems. No single neural structure is necessary and sufficient for consciousness. Not all areas of the brain contribute equally to consciousness.

Our state of consciousness also includes accompanying autonomic responses such as changes in respiration, heart rate, or body temperature. Injuries that involve a considerable part of

tegmentum of the midbrain result in a profound coma because of the interruption of ascending multisynaptic activating system as well as descending hypothalamotegmental and dorsal longitudinal fasciculus path.

In humans, the complex system of mental and spiritual processes depends on, and is produced by the highest psychical activities, i.e. depends on, and is produced by the brain, making people to: use symbolic representation and language; reflect on the past and anticipate and plan for the future; transform thought into speech and action; logically record the personal experience and transmit it orally by writing and/or by drawing; participate in the progress and civilization; read other people's thoughts, judge correctly their intentions and act consequently; use abstractization and generalization to make new discoveries; know, spread and protect the ethical, moral and religious standards in order to live an optimal social life; organize behavior and extrapolate it in time; deal with cognitive novelty.

The prediction and comprehension of others' behavior are, evidently, very important aspects of social functioning.

The consciousness processes belong, in essence, to people who act by control mechanisms of psychological activities, generalization and abstractization mechanisms, exploring and handling of mental images to solve all the problems man is facing with.

In humans, the level of consciousness depends on the complexity of the brain ontogenetic evolution; the human brain makes culture and technology possible. We believe that the cerebral cortex is absolutely necessary for this function; machines that are responsive to sensory events and are capable of complex movements are not conscious. Some philosophers stress that the two defining characteristics of consciousness are: intentionality and subjectivity.

In [17] is pointed out that computers are not conscious because they lack intentionality. Computers have no clue about what exactly it is they are computing. In this respect, Searle [18] rebuts those who imagine that present-day computers (because their operations, in some ways, resemble mental processes) can already be considered to have the rudiments of consciousness. Searle emphasized that meaningful output from a computer, however sophisticated, cannot provide evidence for consciousness or self-awareness within it. Despite this argument, deflating simplistic assertions that extant machines exhibit rudimentary form of consciousness, Searle does not dispute the idea that in the future it is possible to construct conscious entities. Anyhow, machines that are responsive to sensory events and are capable of complex movements do not possess consciousness.

They do not refer to anything in the real world. Human mental computations are about something; they are grounded in reality. According to this point of view, the brainstem occupies the bottom of the totem pole, providing the basic arousal mechanism without which the higher brain regions cannot operate.

On the other hand, consciousness must be a function of numerous interacting systems. The major structures supposed to play a key role in the neural correlates of consciousness are: the brainstem, the midbrain, the cerebellum, the diencephalon (especially the hypothalamus and thalamus), the limbic system, and the cerebral cortex. There is the idea of being conscious versus unconscious.

Thus, the brain “language” can be conceptualized as the transmission of neural signals [19]. The “grammar” of the brain’s language system concerns the proper timing of neuronal impulses. Neuronal impulse timing is based upon proper integration and balance of excitatory and inhibitory processes [20].

Consciousness is a product of all cortical areas, but it exists only in association with the passage of the impulses through ever-changing circuits of the higher brainstem, mesencephal, diencephal, cortex and their cognitive operations.

So, consciousness is a function of numerous interacting systems. Certainly, without higher brain stem and diencephalic integration it cannot exist.

In fact, consciousness is not a single process but a collection of many processes, such as those associated with language, thinking, memory, emotion, feelings, seeing, executive function and so on.

In sum, there are: consciousness of the self; consciousness of the environment; and social cognition. Social cognition is a learned consciousness that allows us to make sense of another person’s actions and intentions.

Certainly, some anatomical formations and functional processes are much more important for consciousness than others.

Consciousness is not always the same. A person at different ages of his/her life is not thought to be equally conscious: young children are usually not considered to experience the same type of consciousness as healthy adults do. Indeed, part of the process of maturation is becoming fully conscious. Conscious state varies across the span of a day as we pass through various states of sleep and waking [21].

The sleep is intrinsically reversible; sufficient stimulation will return the individual to a normal waking state.

2. Patients and methods

In our attempt to demonstrate the presence of the ascending inhibitory system, the consciousness disorders and its modular aspect, a group of fifteen patients has been subjected to evaluation or surgery within National Institute of Neurology and Neurovascular Diseases in Bucharest. Thirteen of them have been diagnosed, respectively, with brain tumor, one patient with limbic encephalitis, and another one with brain cysticercosis. Patients’ average age was 41.5 years, the youngest being 21 and the oldest 73.

Ten (66.6%) of the patients were male. In 14 patients, the main examination was computed tomography (CT) and magnetic resonance imaging (MRI).

In the following, we will present the clinical symptomatology of every patient.

Case 1. A 21-year-old man presented himself with a sudden onset coma. MRI-scan revealed a bilateral ponto-mesencephalic hemorrhage triggered by a cavernoma. After total resection of

the cavernoma and hematoma, patient's status has improved significantly, presenting only a remaining minimal right side weakness and hemisensory deficit. Now the patient is a student, and his state is excellent.

Case 2. A 38-year-old woman was admitted with a history of logorrhea syndrome, with hyperkinesia, hyperwakefulness and hyperprosexia. The patient could sleep for only a short time, and then awake and was unable to fall back asleep. MRI-scan revealed a left petroclival meningioma which significantly compresses the superior part of the brainstem.

The postoperative evolution was very good. She remained for five weeks with mild hypoaesthesia on the left face but logorrhea syndrome with hyperkinesia disappeared.

Case 3. A 36-year-old man presented with intermittent increased intracranial pressure, paralysis of the conjugate upward gaze (Parinaud's sign), pseudo-Argyll-Robertson pupil and arousal disorders. A contrast-enhanced CT-scan revealed a tumor of the pineal area. Only 15% of the patients with tumors of the pineal area, which are compressing the dorsal part of the mesencephalon, also experienced arousal disorders. Postoperative, the patient remained clinically intact and arousal disorders disappeared.

Case 4. A 27-year-old man was admitted in the department of neurosurgery with headache, memory impairment, endocrinopathy (gonadal insufficiency, loss of libido and reduced masculine hair growth) and bitemporal hemianopsia. Neurobehavioral abnormalities manifested with intermittent hypersomnia, apathy, depression, and flattening of affect. Preoperative MRI demonstrates a large suprasellar, parasellar and intrasellar mass with a few calcifications (craniopharyngiomas). Symptoms reflect the tumor's close proximity to hypothalamic region, pituitary gland, optic apparatus, third ventricle and intracranial vessels.

The hypothalamus and its surrounding structures are especially important for the ascending activatory and inhibitory system and for the anatomy, physiology and pathology of the consciousness. Upward grown into the region of the hypothalamus, this tumor affected overall endocrine control.

After radical subfrontal resection, the patient remained in an excellent state and returned to full activity.

Case 5. A 29-year-old woman presented with left hemiparesis by compression of the adjacent internal capsule, palsies of vertical and lateral gaze, absence of convergence, retraction nystagmus, and mild sensory deficit in the opposite side of the body, including the trunk. Pain and thermal sensation were more affected than touch, vibration and position.

Involvement of ventral posterolateral and posteromedial nuclei of the thalamus causes loss or diminution of all forms of sensation on the opposite side of the body. Contrast medium-enhanced coronal and axial MRI shows a big right thalamic tumor.

The tumor was fully resected and thirty-five days after surgery was started radiation therapy using a 10 MeV linear accelerator. The clinical examination performed thirteen months after surgery, demonstrated a good health condition of the patient. However she remained with a mild sensory deficit and a hemiparesis, but she returned to an independent life.

Case 6. A 27-year-old woman complained of headaches which progressed to double vision, nausea and vomiting. At the neurologic examination, the presence of a slight Parinaud's syndrome was discovered.

Contrast-enhanced T1-weighted magnetic resonance images show a well-demarcated and homogeneously enhanced pineal body tumor. After its surgical resection, the final histological diagnose was of pineocytoma. Immunohistochemistry for neurofilament (68 kDa) showed numerous positive cell processes.

Immunohistochemistry of GFAP showed strong positivity in interstitial cells. Post-surgical evolution was excellent.

Case 7. A 56-year-old man presented with a sudden onset of coma and fever. Coronal and axial T1-weighted MRI scans revealed edematous, demyelination symmetrical infra- and supratentorial changes which involved the entire midbrain, both thalamic formations, bilateral basal ganglia, two-side temporo-occipital convolution and hippocampus; these were determined by encephalitis (limbic encephalitis). After 9 days of coma the patient died.

Case 8. A 56-year-old man, with a history of severe headaches, presented with taste and smell disorder, excessive euphoria accompanied by peculiar kind of compulsive, shallow and childish humor (moria), irritability, hypomania and puerilism.

The patient also shown disorders of attention and motility, distractibility, hyperreactivity, hyperkinesia, perseveration, emotional lability, cognitive dysfunction that impede the initiation and temporal organization of actions, and lack of initiative, wrong decision and instinctual disinhibition (sociopathy).

Contrast-enhanced computed tomography (CT) scan shows a giant size olfactory groove meningioma and displacement of anterior brain. Post-surgery, after complete resection of the tumor, the orbitofrontal syndrome disappeared almost completely.

Case 9. A 35-year-old woman was admitted to the department of neurosurgery with a bilateral meningioma of the anterior falx which compressed dorsolateral premotor and prefrontal cortex (Brodmann's areas 6, 8, 9, 10, and 46).

As symptoms, she had attention disorder directed to a particular item of sensorium or inner experience, and the capacity to suppress from inner experience items that can interfere with what is currently on focus. She was apathetic, disinterested in herself and in the world around her. Visuospatial neglect along with gaze abnormalities were also present because the lesion encroaches on area 8.

According to our experience, the apathy is present in all lateral-damage conditions, and is mostly apparent after large bilateral lesions of the frontal convexity.

Perseveration, dysexecutive syndrome with attention, working-memory and planning disorders were among the symptoms. Language disorders were directly linked to failure of temporal integration.

In this patient, depression was secondary to cognitive disorder. Postoperative, the frontal syndrome disappeared.

Case 10. A 42-year-old man presented with a 2-year history of subtle but progressive sensory aphasia, the inability to designate or name the different fingers of the two hands, and the inability to calculate and write (an incomplete Gerstmann's syndrome). The patient also showed constructional apraxia, alexia and misdirected and dissymmetric movement of the opposite limbs. MRI prior to surgery showed a left side parietal cystic astrocytoma. After extirpation of the tumor, all symptoms disappeared.

Case 11. A 39-year-old man was admitted with progressive left hemiparesis, tactile inattention, constructional apraxia, dressing apraxia, dysprosody, and anosodiaphoria. Preoperative CT-scan showed a tumor in the right parietal region.

Post-surgery, the patient improved his motor strength and was discharged after 3 weeks in a very good state, while the CT-scan demonstrates the complete removal of the tumor (fibrillary astrocytoma).

Case 12. A 46-year-old man was admitted with olfactory hallucination ("uncinate fits") often accompanied by a dreamy state of mind, auditory elementary hallucination when the patient heard the sound of running water, impaired recognition of melodies in the absence of words, and the usual tendency for the patient to report the current date as an earlier one. Coronal T1-weighted, gadolinium-enhanced MRI prior to surgery showed a large right-sided temporo-basal tumor (astrocytoma).

After complete removal of the tumor, the patient remained in a very good state. The patient improved very much and was discharged after 2 weeks.

Case 13. A 42-year-old woman was admitted to the department of neurosurgery with a failure to precisely grasp or touch an object under visual guidance (optic ataxia). This optic ataxia was detected when she tried to reach for an object. Patients with such unilateral lesions typically demonstrate greater impairment when reaching for items located in the hemispace, that is contralateral to the lesion, using the contralateral hand. Another symptom was visual inattention (simultanagnosia) which affected mainly the periphery of the visual field. Simultanagnosia was considered to be a disruption in spatial attention, which was associated with the inability to direct one's attention to more than one or to a few objects at the time.

The presence of simultanagnosia was tested by asking the patient to carry out tasks such as looking at a series of objects, and connecting a series of dots by a line or to examine and describe the events depicted in a complex visual image. Once he focused on one object in his visual field, the patient ignored or neglected all the other objects.

Therefore, optic apraxia and visual inattention have been described within a single visual field contralateral to the right parieto-occipital lesion (areas 7 and 19) (incomplete Balint's syndrome). Generally, patients with Balint's syndrome display three classic symptoms including simultanagnosia (visual inattention), optic ataxia, and ocular apraxia, but this patient had only two symptoms, so an incomplete Balint's syndrome. After total extirpation of the tumor, the patient Balint's syndrome disappeared.

Case 14. A 73-year-old man was admitted with a coma and deceased within 18 hours. On autopsy, more than 110 bilateral cortical and intracerebral metastases have been discovered,

originating from a melanocarcinoma situated in the right abdominal area, subject to surgery 7 months earlier.

Case 15. A 56-year-old man complained of headache, nausea, vomiting, cognitive dysfunction and drowsiness. The disease onset was sudden and progressive, with attention deficit (3 months before), memory disorder, disorientation, difficult walking and loss of continence. A magnetic resonance image showed multiple cysts in the parenchyma depicted as round hypointense lesions, sized at 5 mm at most. The respective lesions are disseminated bilaterally in the cortex and cerebral mass, surrounded by hyperintense areas with slight brain edema.

The histopathology examination based on a brain biopsy sample reported neurocysticercosis. The overall and neurological state of the patient deteriorated, and he deceased in the fifth day following in-hospital admission.

3. Results

From the analysis of the 15 presented cases, and also of those previously published in [22 - 24], we had ascertained several important results with reference to the state of consciousness and the alteration of the most important cerebral structures which are necessary for its achievement.

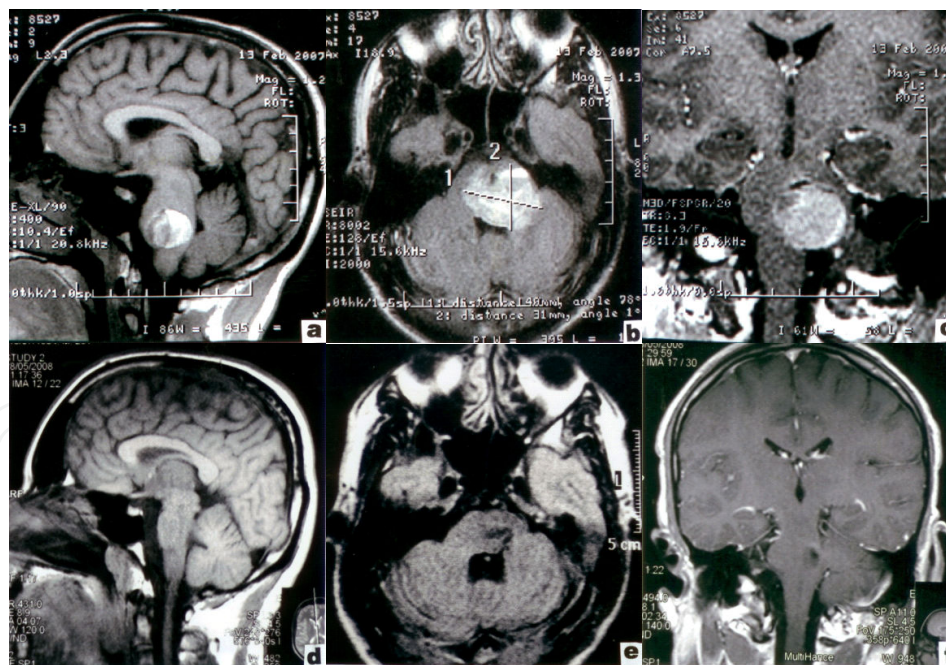


Figure 1. A 21-year-old man who presented with a history of sudden onset of coma. Sagittal (a), axial (b) and coronal (c) T1-weighted magnetic resonance imaging (MRI) scans revealed a gross pontine hemorrhage (1.9 cm) from a cavernous malformation that reached the surface of the floor of the fourth ventricle and in the cerebellopontine angle. The lesion was resected through a suboccipital approach. Sagittal (d), axial (e), and coronal (f) MRI scans, one year later, reveal no rest of the malformation. Two months after surgery, the patient presented with minimal right sided weakness and hemisensory deficits. (surgeon Leon Dănilă) (case 1).

Hence, we had reasoned clinically that the existence of the ascending reticular activating system (ARAS, further called AAS) and of the ascending reticular inhibitory system (ARIS, further called AIS), which are functioning interdependently, are essential for the functioning of the Central Nervous System (CNS).

In Fig. 1 (case 1), the pontomesencephalic hemorrhage caused the development of coma, and in case 2 the extra-axial pontomesencephalic compression led to the development of the logorrhea syndrome with hyperkinesia.

The respective compression has induced the reduction or the abolition of the function of the ascending reticular activating system and the diminution, to a greater or lesser extent, of its influence on the cerebral and especially on the cortical functions.

Hereinafter we shall reproduce comments concerning the existence and the functioning of the 2 ascending activating and inhibiting systems.

3.1. The brainstem

The brainstem is the portion of the central nervous system rostral to the spinal cord and caudal to the cerebral hemispheres.

The net-like appearance of the brainstem neurons led to the designation as “reticular formation”, a term that was originally used in a purely descriptive anatomical sense.

3.1.1. The reticular formation

The reticular formation (RF), beginning in the medulla and extending to the midbrain, plays a major role in the sleep-wakefulness cycles of animals and humans. It occupies a significant portion of the dorsal brainstem and forms a network of reticular fibers that synapse with, and modulate many ascending and descending fiber tracts.

Nuclei of RF receive afferent information from all sensory (visual, auditory, etc.) and motor systems as well as from other major structures of the brain, and project their axons upwards and downwards to virtually all parts of the nervous system. Through their connections with the thalamus, hypothalamus and directly to the cerebral cortex they can send information to, and receive it from all areas of the cortex. There are ascending (or forward) and descending (or backward) connections between them.

The RF is also known as the reticular activating system and the reticular inhibitory system [22, 23, 25]. The role of reticular formation is to awake or to get to sleep the cerebral cortex.

After waking, the cortex allows all modes of sensory processing (sight, hearing, touch, etc.) to combine with conscious thought and experience, in order to focus on some inputs and suppress others. Neuroscientists now recognize that the various nuclei within the brainstem serve many functions and that only a few participate in waking and sleeping.

Instead of being used in a descriptive analogical way, the reticular formation was promoted to a functional concept, a brainstem system, which, by virtue of its nonspecific connectivity,

could act as a kind of volume control for the degree of conscious arousal and sleeping and as a homeostatic system.

3.1.2. *Ascending (reticular) Activating System (AAS)*

In [26] is reported the innovation of the electroencephalogram (EEG), which is closely correlated with the level of consciousness of the patients. Since Berger's first observation, the various ongoing brain oscillations have been used successfully to characterize mental status such as sleep, waking state or vigilance and mental pathologies such as epilepsy. Sensory evoked potentials (EEG signals triggered by an external stimulation) have demonstrated that such mental factors as sensation, attention, intellectual activity, and planning of movement, have distinctive electrical correlates at the surface of the skull [27]. Afterwards, in [28, 29] were examined the EEG waveforms in cats into which the lesions of the brainstem were placed. It was found that after a transection between the medulla and the spinal cord, a preparation that he called the *encephale isolé*, or isolated brain, animals showed a desynchronized (low-voltage, fast-wave) EEG pattern and appeared to be fully awake [27 – 29]. When the neuraxis between the superior and inferior colliculus was transected, a preparation called the *cerveau isolé*, or isolated cerebrum, the EEG showed a synchronized, or high-voltage, slow-wave pattern indicative of deep sleep and the animals were behaviorally unresponsive. Bremer concluded that the forebrain fell asleep due to the lack of somatosensory and auditory sensory inputs.

The reticular activating system obtained this designation in [30] were one reported that it was stimulated electrically in anesthetized cats and that it was found that the stimulation produced a waking pattern of electrical activity in cat's cortex. When the lesions were placed in the paramedian reticular formation of the midbrain, the animals showed cortical-evoked responses to somatosensory or auditory stimuli, but the background EEG was synchronized and the animals were behaviorally unresponsive. These observations emphasized the midbrain reticular core as relaying important arousing influences to the cerebral cortex and this pathway was labeled the ascending reticular activating system (today named AAS).

The most important reticular nuclei for arousal and consciousness are the raphe nuclei and the central nuclei. These groups receive significant converging sensory input from all sensory modalities and project to the thalamus (i.e., intralaminar nuclei), cholinergic basal forebrain nuclei, and the entire cerebral cortex. An important component of the central reticular activating system is thought to be the noradrenergic nuclei, particularly the locus coeruleus, at the pontomesencephalic junction.

The centromedian and parafascicular nuclei, two of the intralaminar nuclei of the thalamus representing the rostral extent of the AAS, receive inputs from the spinothalamic, trigeminothalamic and multisynaptic ascending pathways (of the reticular formation) relaying pain sensation. As a result of their diffuse cortical connections, they are involved in the maintenance of arousal.

The neurons of the locus coeruleus project to the thalamus, hypothalamus, basal cholinergic nuclei, and the neocortex [31, 32]. Immediate coma results from the destruction of the central reticular nuclei at or above the upper pontine level.

Anyhow, AAS acts on the cerebral cortex through the thalamus, directly, and through the arousal caudal hypothalamic neurons (tuberomammillary nucleus) which are connected with suprachiasmatic nuclei (Fig. 2).

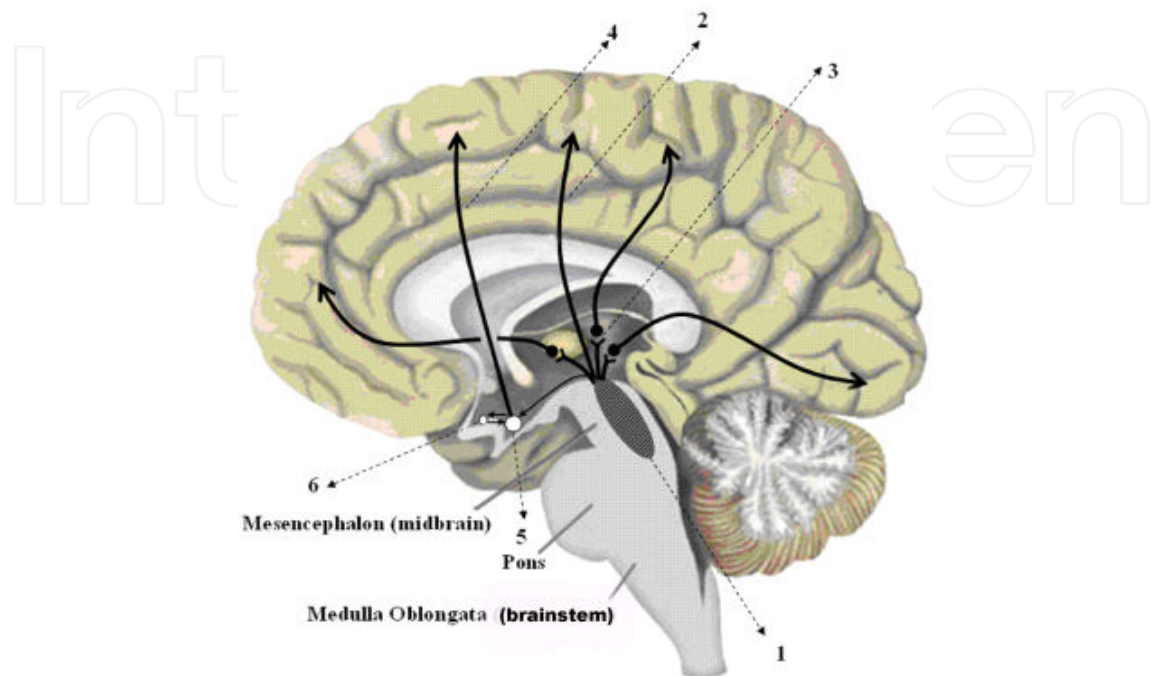


Figure 2. The Ascending Reticular Activating System (AAS) is found in the brainstem (1), and sends projections throughout the cortex: directly (2), through the thalamus (3), or through the hypothalamus (4), tuberomammillary neurons (5), which receive influence from suprachiasmatic nucleus (6).

As a result, the reticular formation comes to be known as the reticular activating system to maintain general arousal, and as the reticular inhibitory system for sleeping.

However, an exact physiologic role of the reticular activating system in consciousness is unclear. The awake condition, as well as the sleep, has many phases: a quick short phase, which is determined by the direct action of AAS on the cerebral cortex, a longer phase, during 24 hours, determined by indirect action of AAS on the cortex through the thalamus, and a rhythmical phase, determined by the AAS action on the cerebral cortex through the hypothalamus awaking system under the influence of the suprachiasmatic nucleus. These nuclei are serially interconnected with AAS not only in the forward, but also in the reverse direction (backward).

It is generally agreed that a key component of the reticular activating system is a group of cholinergic nuclei near the pons-midbrain junction that project to the thalamocortical neurons. The relevant neurons in the nuclei are characterized by high discharge rates during the waking. When stimulated, these nuclei cause “desynchronization” of the electroencephalogram (that is, a shift of EEG activity, from high-amplitude, synchronized waves to lower amplitude, higher-frequency, desynchronized ones).

In [33] it has been concluded that the intralaminar nuclei act not only as a thalamic pacemaker and as a relay for cortical arousal, but they are characterized also by the presence of cells responding to visual auditory and somesthetic stimuli. In [34] it is written “cortical and subcortical innervations of the intralaminar nuclei place them in a central position to influence distributed networks underlying arousal, attention, intention, working memory and sensorimotor integration, including gaze control”. Thus, there are three main types of thalamic projections: the specific (for vision, audition), the diffuse, and the projection to striatum (essentially, all from intralaminar nuclei). Diffuse intralaminar nuclei efferents are widely, though sparsely, distributed to most of neocortex: this is the diffuse projection that has to do with consciousness. One can understand how intralaminar nuclei could directly influence ideation, as ideation is a function of cortex [35].

Activity of these neurons is not, however, the only neuronal basis of wakefulness: the noreadrenergic neurons of the locus coeruleus; the serotonergic neurons of the raphe nuclei; and histamine-containing neurons in the tuberomammillary nucleus (TMN) of the hypothalamus are also involved. The locus coeruleus and raphe nuclei are modulated by the TMN neurons located near the tuberal region that synthesize the peptide orexin (also called hypocretin). Orexin promotes waking, and thus may have useful applications in jobs where operators need to stay alert. On the other hand, antihistamines inhibit the histamine-containing TMN network, and thus tend to make people drowsy [36].

Arousal systems are regulated not only by external stimuli, but also by control systems of the brain. For example, the frontal cortex, particularly the orbitofrontal area, regulates the thalamic reticular nucleus and the cholinergic basal forebrain structures. Patients with lesions in this area show deficits in arousal [37]. Cortical control is not limited to cholinergic modulation. In a work on the norepinephrine system [32], it is demonstrated the role of locus coeruleus - norepinephrine system in the prefrontal cortex function and cognitive control.

The frontal cortex also exerts an influence on the limbic system, which regulates emotional arousal. The anterior cingulate region is important in the self-regulation of arousal through its connections with the cholinergic basal forebrain [37].

In sum, AAS can exert both direct and indirect action on the cerebral cortex. However, the reticular formation which appears to be responsible for maintaining cortical arousal is not the same with consciousness.

3.1.3. *Ascending (reticular) Inhibitory System (AIS)*

According to case 2, it is impossible that the two important functions of the central nervous system, arousal and sleep, or activation and inhibition, depend only on AAS. The two compulsory conditions (arousal and sleep) cannot be determined or explained by the AAS activity or inactivity only.

In [22, 23, 25] is clinically demonstrated that, besides the AAS, there is an ascending reticular inhibitory system (AIS) as well, whose lesion leads to the appearance of the logorrhea syndrome with hyperkinesia, hyperwakefulness, and hyperprosexia.

Normally, during the 24 daily hours, after arousal follows sleep, which is based on AIS. The two reticular systems (AAS and AIS) are under the influence of the suprachiasmatic nucleus and of the awake and sleep centers in the hypothalamus.

As much as awake is determined by AAS, sleep, considered the most profound natural alteration of consciousness, is determined by AIS. It acts on the cerebral cortex directly, through the thalamus, through the ventrolateral preoptic (VLPO) nucleus of the hypothalamus, which, in its turn, is under the influence of the suprachiasmatic nucleus, and through the basal ganglia.

The lateral group of the reticular formation, localized in the pons and rostral part of the brainstem, gives origin to AIS. When AIS is activated, the cerebral cortex becomes inactive and the person is asleep. This system receives inhibitory signals from the cerebellum and sends output signals to the thalamus, to the hypothalamic sleeping center, and directly to the cerebral cortex (Fig. 3).

The raphe nuclei, in the midline of the brainstem, use serotonin as their primary neurotransmitter and have diffuse connections to the cerebral cortex and subcortical gray matter [38].

Thus, the correlated activity between reticular neurons leads to a strengthened connection, both excitatory and inhibitory. In the absence of inhibition, any external input, weak or strong, would generate more or less the same one-way pattern, an avalanche of excitatory stimuli involving the whole population [39]. Cortical networks gain their nonlinearity and functional complexity primarily from the inhibitory interneuronal system [40]. The specific firing patterns of principal cells in a network depend on the temporal and spatial distribution of inhibition. Without inhibition, and dedicated neural formation, excitatory circuits cannot accomplish anything useful [41]. Fast coupling of the excitatory and inhibitory influences can bring about a submillisecond precision of spike timing [40].

Anyhow, reticular nucleus efferents terminate in the immediately underlying thalamic nuclei and the reticular nuclei efferents are GABA-ergic (the neurons in reticular nuclei are exclusively inhibitory, using GABA as their transmitter) [35, 42]. Thus, thalamocortical communication can be simultaneously inhibited by this reticular nucleus efferents that terminate in the underlying thalamic nuclei. In the brain, and particularly in the cerebral cortex, there are multiple influences, both inhibitory and facilitatory. When a performance has been lost because the competence has lost some facilitation, the re-emergence of the performance can result simply from the subsidence of inhibition [43, 44]. The main point is that a loss of performance is not necessarily the result of damage to the competence for that performance; it may result from unbalanced or excessive inhibition of the competence [42].

Generally, the reticular formation of the brainstem is, in turn, influenced by circadian clocks located in the suprachiasmatic nuclei and the arousal (tuberomammillary nucleus) and sleeping (ventrolateral preoptic nucleus) centers of the hypothalamus. The clock adjusts periods of sleep and wakefulness to appropriate duration along the 24-hours cycle of light and darkness. So, in all structures of the nervous system, inhibition plays a pivotal role.

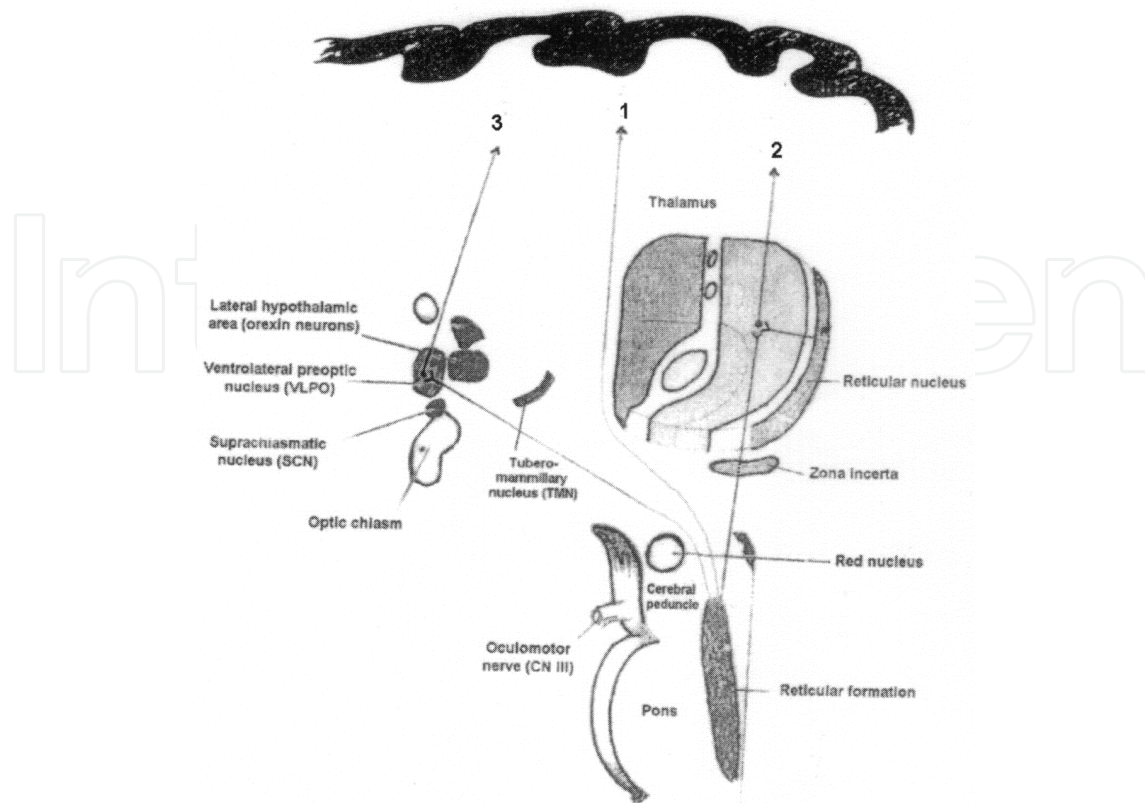


Figure 3. The Ascending Reticular Inhibitory System (AIS) is found in the brainstem, and sends projections throughout the cortex: directly (1), through the thalamus (2), or through the hypothalamus; ventrolateral preoptic nucleus - VLPO, (3), which receives influence from suprachiasmatic nucleus.

Thus, brain uses not only excitation, but also inhibition during its normal operations and behaviors. With no inhibitory cells in a network, depending on the temporal and spatial distribution and dedicated interneurons, excitatory circuits cannot accomplish anything useful [41]. Excitatory potentials dominate on the dendrites of principal cells, whereas only inhibitory postsynaptic potentials impinge upon the cell body (soma). Interneurons provide autonomy and independence to neighboring principal cells but they offer, at the same time, useful temporal coordination. The functional diversity of principal cells is enhanced by the domain-specific actions of GABA-ergic interneurons which can dynamically alter the qualities of the principal cells [41]. The separation of inputs in a network with only excitatory connections and circuits is not possible. Like all somatic functions, at all levels of the system, executive functions, beginning with attention, make use of inhibition for focus, contrast suppression of interference, order, and timeliness [45]. Inhibition enhances saliency and contrast. Inhibition appears essential for the control of impulsivity and a wide array of instinctual drives.

So, there are two opposing active processes that could summate, algebraically, a control excitatory reticular system and a control inhibitory one. Thus, the brain uses not only excitation, but also inhibition during its normal function.

Ascending output of the brainstem reticular formation not only subserves arousal and sleep but also contains information about other bodily states and other neural formation outside the

reticular formation. This is why ARAS and ARIS might be named ascending activatory system (AAS) and, respectively, ascending inhibitory system (AIS).

3.1.4. Clinical aspects

It is important to distinguish between alertness and impairment of the wakeful state. It is possible to be awake and not conscious, but it is impossible to be conscious and not awake. A combination of clinical lesion studies and animal data has identified the following major mechanisms through which alterations in consciousness are produced: disturbance of the ascending reticular system; bilateral lesions of the midbrain and diencephalon; and bilateral involvement of the cerebral cortex (hemispheres). To which degree the same damage will render unconsciousness to a person or another, remains to be clarified.

3.1.4.1. Coma

Destructive lesions of the brainstem may occur as a result of vascular disease, tumor, infection, or trauma. Unlike compressive lesions, which can often be reversed by removing a mass, destructive lesions cannot be reversed. Between the conscious state of mind and coma there are multiple intermediary stages that manifest through: confusion or lethargy, drowsiness, stupor, semicoma (light coma), locked-in syndrome persistent vegetative state, loss of consciousness in concussion (diffuse axonal injury).

We will shortly discuss below the most important of them.

3.1.4.2. Persistent vegetative state

The term persistent vegetative state was introduced in [46] to describe the state of preservation of autonomic function and primitive reflexes, without the ability to interact meaningfully with external environment.

The vegetative state has been differentiated from the newly introduced category of minimally conscious state (MCS) [47, 48]. In MCS, patients may show islands of relatively preserved brain response [49, 50], as well as fragments of behavior interpretable as signs of perception and voluntary movement that preclude the diagnosis of vegetative state [27]. Both, the vegetative and minimally conscious states need to be distinguished from the locked-in syndrome in which the patient is fully conscious but, due to a circumscribed brainstem lesion, is unable to communicate in any way other than by the lid closure and the vertical eye movements.

Overall, brain metabolism is less reduced in locked-in patients [51].

3.1.4.3. Diffuse axonal injury (loss of consciousness in concussion)

The mechanism of the loss of consciousness with a blow to the head is not completely understood.

Brief loss of consciousness, which in humans is not usually associated with any changes in CT and MRI scan, may be due to the shearing forces transiently applied to the ascending arousal

system at the mesodiencephalic junction. Physiologically, the concussion causes abrupt neural depolarization and promotes release of excitatory neurotransmitters. There is an efflux of potassium from cells with calcium influx into cells and sequestration in mitochondria leading to impaired oxidative metabolism. There are also alterations in the cerebral blood flow and in the glucose metabolism, all of which impair neuronal and axonal functions [52].

Concussion or hemorrhage into the dorsolateral mesopontine tegmentum may be visible on MRI, but diffuse axonal injury is generally not. Magnetic resonance spectroscopy may be useful in evaluating patients with diffuse axonal injury, who typically have a reduction in N-acetylaspartate as well as elevation of glutamate/glutamine and choline/creatine ratio [53 - 55].

3.1.4.4. *Logorrhea syndrome with hyperkinesia*

The activity in the reticular formation is the mechanism that induces the sleep, awakens one from sleep and brings one back to full consciousness.

Thus, damage in the reticular formation typically sends a person into coma because this is an on/off switch for all higher brain centers or determines the logorrhea syndrome with hyperkinesia [22, 23, 25]. In a study on the behavior of patients with brainstem tumors and another neurosurgical conditions, reported in [22, 23], it was observed that, apart from the locked-in syndrome, persistent vegetative state or coma, the patients may also manifest various other states, especially logorrhea syndrome with hyperkinesia, hyperwakefulness and hyperprosexia (Fig. 4, Case 2). In our opinion, the logorrhea syndrome with hyperkinesia, hyperwakefulness and hyperprosexia reflect a hyperconsciousness or, in other words, a super-arousal determined by the release of the AAS from the influence of AIS which is damaged.

Thus, the logorrhea syndrome with hyperkinesia is produced by the lesion of the AIS and is an argument in favor of the existence of AIS. The lesions found in our cases (pons, rostral part of the brainstem) mark the location of the AIS. In [56] is described a syndrome of hemiballism and logorrhea determined by a hematoma of the left subthalamic nucleus. The right hemiballism is explained by the influence on the subthalamic nucleus, but not the logorrhea. In our opinion, the image given in figure 1 of their article shows multiple subthalamic lesions which affect zona incerta; one knows that zona incerta has an inhibitory role [57].

So, we consider that in this case the logorrhea syndrome is given by the lesion produced to the zona incerta which is located in the immediate neighborhood of the subthalamic nucleus. AIS passes through zona incerta.

In sum, besides the other homeostatic systems, the reticular system (AAS and AIS) represents an actual regulator system of the entire neuraxis, as proven by its participation in the regulation of all the psychical processes (attention, memory, reasoning, behavior, etc.), speech, muscular tonus, and the physiognomy of movement.

In case 3, in spite of the presence of an important compression on the mesencephal, the respective patient has shown only a dorsal mesencephalic syndrome, without the alteration of the state of consciousness.

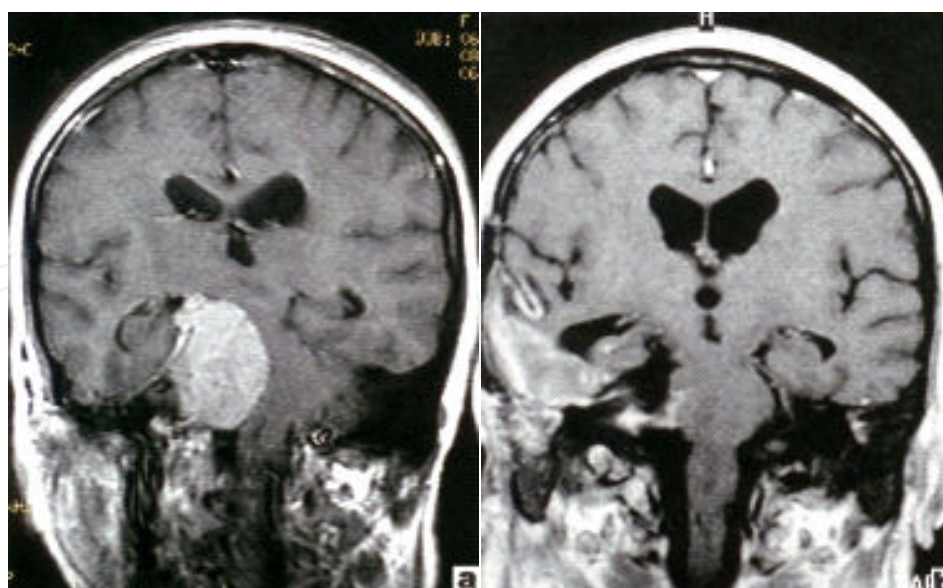


Figure 4. MRI studies of a petroclival meningioma (a) which compresses from outside the Brainstem and provokes logorrhea syndrome with hyperkinezia and hyperwakefulness. Postsurgery (b) this syndrome disappears (surgeon Leon Dănilă) (case 2).

When the tumor is bigger and it exerts a higher compression on this upper part of the brainstem, we are also faced with the development of coma, besides the above mentioned syndrome.

3.2. The midbrain (Mesencephalon)

The midbrain is the short portion of the brain between the pons and the cerebral hemispheres. It consists of tectum, contains the four corpora quadrigemina and two cerebral peduncles with tegmentum and crus cerebri.

The cerebral aqueduct, surrounded by the central gray matter, separates the tectum from the tegmentum. The cerebral peduncle consists of two parts: (1) a dorsal part, the tegmentum, and (2) a ventral part, the crus cerebri. These two parts are separated from each other by substantia nigra.

The midbrain tegmentum contains the trochlear and oculomotor nuclei, neural structures concerned with ocular and visual reflexes, the mesencephalic reticular formation, the red nuclei and many scattered collections of cells.

3.2.1. Dorsal midbrain syndrome

The midbrain may be forced downward through the tentorial opening by a mass lesion impinging upon it from the dorsal surface (Fig. 5, case 3).

The most common causes are masses in the pineal gland, in the posterior thalamus, or in upward transtentorial herniation which kinks the midbrain.

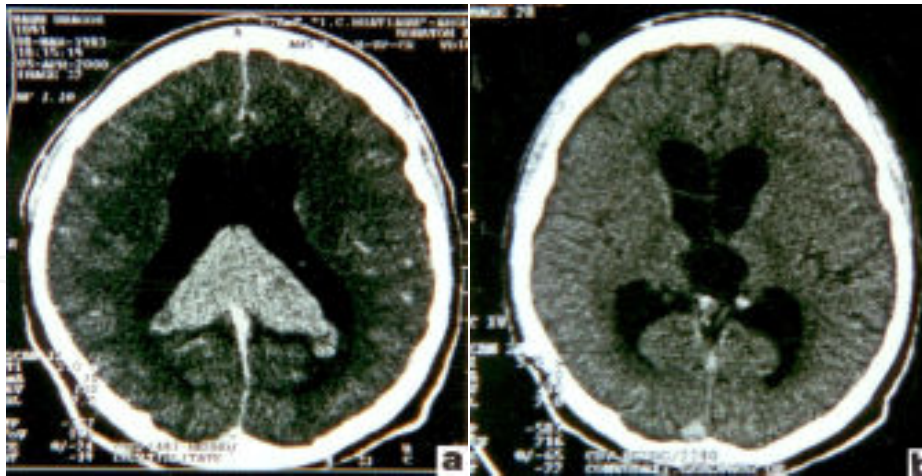


Figure 5. a) A contrast-enhanced axial CT-scan of a 36-year-old man with hydrocephalus and a large pineal region tumor, that was totally resected. Post-surgery, the patient remains clinically intact. (b) Axial CT-scan, 3 months postsurgery, confirming total removal of the tumor (germinoma) (surgeon Leon Dănilă) (case 3).

Primary midbrain hemorrhages, which may be of either type, are rare. Most of such patients present themselves with acute headache, alteration of consciousness and abnormal eye signs. Most of them recover completely from bleeds from cavernous angiomas, but some remain with mild neurologic deficit.

Pressure from this direction produces the characteristic dorsal midbrain syndrome manifested first by limited upgaze. In severe cases, the eyes may be fixed in forced, downward position. There may be also a deficit of convergent eye movements and associated pupilloconstriction. The presence of retractor nystagmus, in which all of the eye muscle contracts simultaneously to pull the globe back into the orbit, is characteristic.

Motor responses are difficult to obtain or result in extensor posturing. Motor tone and tendon reflexes may be heightened, and plantar responses are in extension.

If the cerebral aqueduct is compressed sufficiently to cause acute hydrocephalus, however, an acute increase in supratentorial pressure may ensue. This may cause an acute increase in downward pressure on the midbrain, resulting in sudden lapse into deep coma [58]. Most patients in whom the herniation can be reversed suffer chronic neurologic disability [59 - 60].

After the midbrain stage becomes complete, it is rare for patients to fully recover.

3.3. Diencephalon

The diencephalon contains: hypothalamus, thalamus, subthalamus (substantia nigra, zona incerta, the nucleus of the tegmental fields of Forel, ansa lenticularis, Forel's field H1 -thalamic fasciculus - Forel's field H2 – lenticular fasciculus –, and subthalamic fasciculus), metathalamus (medial geniculate body, and lateral geniculate body), and epithalamus (pineal body, habenular trigones, stria medullaris, and roof of the third ventricle).

In the following, we shall deal only with the role of the hypothalamus and thalamus in sleep, arousal, and circadian rhythm.

3.3.1. Hypothalamus

Fig. 6 (Case 4) is considered important because in it the hypothalamus was affected. The compression of this important part of the brain led to the appearance of several specific hormonal disorders and also to the alteration of the state of consciousness manifested by apathy, depression, flattened affectations, hyposomnia, as well as the development of confusional states.

In this case it has been affected the tuberomammillary nucleus in the caudal hypothalamus, as well as the connections of the hypothalamus with the suprachiasmatic nucleus, causing the development of hypersomnia and circadian rhythm disorders.

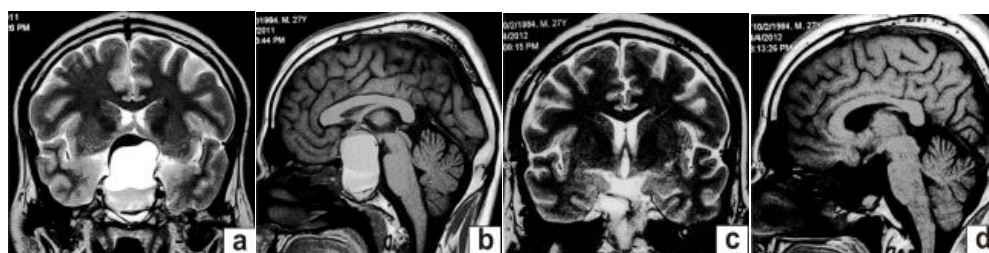


Figure 6. Preoperative T1-weighted coronal (a), and sagittal (b) magnetic resonance imaging (MRI)-scan demonstrates a large suprasellar, parasellar, and intrasellar mass. T2-weighted MRI-scan illustrates a few calcifications. MRI-scan (c and d) six months after radical subfrontal resection of the craniopharyngiomas (surgeon Leon Dănilă) (case 4).

We shall further present hereinafter several details concerning sleep and the hypothalamus function.

The hypothalamus is composed of about 22 small nuclei, the fiber system that passes through it and the pituitary gland. Although the hypothalamus comprises only about 0.3% of the brain weight, it takes part in nearly all aspects of motivated behavior, including sleeping, arousal, temperature regulation, emotional behavior, endocrine function, metabolism, sexual behavior, and movement [61, 62].

From our point of view, the ventrolateral preoptic nucleus (sleeping system), the tuberomammillary nucleus (arousal system), and the suprachiasmatic nucleus (day-night cycle system) are important.

The sleep is a circadian function, and although the suprachiasmatic nuclei are not essential for its generation, they are responsible for consolidation of sleep in cycles that occur within a circadian framework.

According to the results reported in [9], when humans go to sleep, they rapidly become less conscious. The initial loss of awareness of the external world that may occur when we are reading in bed is associated with the slowing of the EEG that is called Stage I. At sleep onset, although awareness of the outside world is lost, subject may continue to have visual imagery

and associated reflective consciousness. Even in the depths of non-REM stage IV sleep, when consciousness appears to be largely obliterated, the brain remains highly active and it is still capable of processing its own information. From PET and single neuron studies, it can safely be concluded that the brain remains about 80% active in the depths of sleep. Most of the brain activity is not associated with consciousness. Non-REM, stage IV is characterized by low-frequency, high-amplitude EEG, in which subjects may report not only some thought-like mentation but also movie-like dreams [63].

The circuitry through which AIS influences the sleep is localized in the upper pons and rostral parts of the brainstem and includes the hypothalamic ventrolateral preoptic nuclei, supra-chiasmatic nuclei, the thalamus, and the cerebral cortex. In [64] very good arguments are provided regarding the sleep and arousal. Nevertheless, in our opinion, the explanation of the sleep/wakefulness given by them as due to a flip-flop switch, to the influence of suprachiasmatic nucleus, to the homeostatic mechanism and to the allostatic mechanism is not enough. We believe that the explanation should also include the existence of the AAS and AIS, which are working also under the influence of the suprachiasmatic nucleus, homeostatic mechanisms, and allostatic mechanism, and which control the sleep.

The arousal, like sleep, exhibits more steps: a rapid one, which has a short lifetime and which is determined by the direct action of the AAS on the cerebral cortex; another, with a longer lifetime within the 24 hours, which is caused by indirect action of AAS on the cerebral cortex *via* thalamus; and the third, which is rhythmic and it is determined by the AAS action on the cerebral cortex *via* the hypothalamic arousal system that, in its turn, is found under the influence of the suprachiasmatic nucleus.

Some studies have demonstrated that the influence of the hypothalamus on arousal is not restricted to the tuberomammillary neurons in caudal hypothalamus. In particular, a prominent group of neurons confined to the lateral hypothalamus has been implicated in the sleep disorder known as narcolepsy [65].

These neurons express novel neuropeptides known as hypocretins or orexins and are differentially concentrated within the perifornical nucleus that surrounds the fornix in the tuberal hypothalamus. Mapping studies have shown that hypocretin (orexin) neurons are similar to tuberomammillary neurons in that they are confined to the hypothalamus and give rise to extensive projections throughout the neuraxis [66].

Human sleep occurs with circadian periodicity. Thus, humans have an internal “free-running clock” that operates even in the absence of information about the period of 24 hours [67 - 69]. This clock is controlled by the suprachiasmatic nucleus.

So, circadian rhythms provide temporal organization and coordination for physiological, biochemical, and behavioral variables in all eukaryotic organisms and in some prokaryotes. Circadian rhythms that are genetically determined, not learned [70- 72], are generated by an endogenous self-sustained pacemaker.

The pineal body synthesizes the sleep-promoting neurohormone melatonin and secretes it into the bloodstream where it modulates the sleep.

3.3.2. *Thalamus*

Although the thalamus is the first neurological structure at whose level begins the process of awareness, the result of the ablation of a single thalamus demonstrated that the female patient in Fig. 7 (case 5) has shown postoperatively only moderate sensitivity disorders on the opposite part of the body and a slight hemiparesis.

Nevertheless, the concomitant involvement of the right and left thalamus leads to the loss of consciousness and coma.

Although the thalamic physiology has been scarcely studied, and therefore limitedly understood, we present below several data concerning the extremely important and complex function of this component of the CNS.

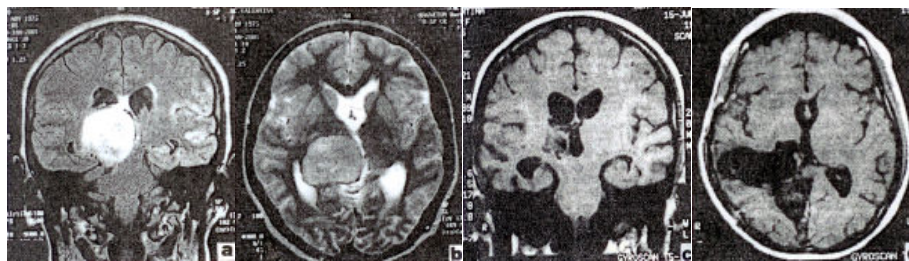


Figure 7. Contrast medium-enhanced coronal (a) and axial (b) magnetic resonance imaging showing a big right thalamic tumor that proved to be an astrocytoma. Thirteen months following resection and radiotherapy, coronal (c) and axial (d) magnetic resonance imaging demonstrates the absence of tumor. The patient was conscious and in good state (surgeon Leon Dănilă) (case 5).

The fundamental function of the thalamus is that of relay and it modulates peripheral information to the cerebral cortex and to the basal ganglia, keeping the somatosensory, mental, and emotional activity of a living individual in harmony.

With the exception of the thalamic reticular nucleus, all thalamic subnuclei possess thalamic projection neurons that relay processed information to the cerebral cortex. In addition, the thalamic subnuclei also have inhibitory GABA-ergic interneurons whose cell bodies and processes are confined to a single subnucleus. The reticular nucleus of the thalamus is a continuation into the diencephalon of the reticular formation of the brainstem. It receives inputs from the cerebral cortex and thalamic nuclei. The former are collaterals of corticothalamic projections, and the latter are collateral of thalamocortical projections. The reticular nucleus projects to other thalamic nuclei. The inhibitory neurotransmitter of this projection is GABA. The reticular nucleus is unique amongst the thalamic nuclei because its axons do not leave the thalamus. Based on its connections, the reticular nucleus plays a role in integrating and gating activities of the thalamic nuclei.

As the termination site for the reticular ascending system is considered, it is not surprising that the thalamus has an important arousal and sleep-producing function [52, 73 – 75] and that it alerts, activates or inhibits a specific processing and response system. Its involvement in attention shows up in diminished awareness of stimuli impinging on the opposite side the lesion (unilateral inattention) [22, 23, 76 - 78].

The ascending input to intralaminar nuclei can help explain consciousness of primitive percepts (non-cognitive component). So, ascending output of the brainstem reticular formation not only subserves arousal but also contains information about other states. Thus, other input to reticular formation comes from the spinothalamic system, trigeminal complex, and dentate nuclei in the cerebellum conveying proprioceptive signals. There are also ascending inputs to intralaminar nuclei from deep layers of the periaqueductal gray, substantia nigra and amygdala with affective information, and from the vestibular nuclei with information about body position [33, 52, 79, 80].

Intralaminar nuclei. These nuclei, embedded in the internal medullary lamina, consist of centralis, lateralis, paracentralis, central medial nuclei (anterior group), and centromedian and parafasciculus nuclei (posterior group) (Ohye, 2002). The latter are often called the centromedian-parafascicular complex.

The anterior group receives different projections from the spinothalamic tract, deep cerebellar nucleus, brainstem reticular formation, etc. The posterior group has a reciprocal connection with the basal ganglia. The efferent connection with the cerebral cortex is very wide and it was thought to be a diffuse projection. The intralaminar nuclei were classified as representatives of the “nonspecific system” rather than of the “specific system”, such as the thalamic station for the visual, auditory, or somatosensory system with definite modality - specific peripheral input.

3.3.3. Reticular nucleus

This nucleus is considered to be related to arousal, attention, cognitive function, etc. It plays a role in maintaining cortical activity in a disease state of epilepsy [52, 81, 82]. In [83] it was studied the human thalamus using microrecordings during stereotactic thalamotomy for dyskinesia and it was found verbal command neurons in this nucleus and in the adjacent area.

Surround-type inhibition mediated by thalamic reticular nuclei may selectively gate out extraneous stimuli while allowing focused relay important sensory data to the thalamocortical circuits, which endow a given neural activity pattern with the property of conscious perception [84]. But how is this neurophysiologic activity coordinated in time to produce a somewhat unified conscious stream? Data suggest the answer may lie in the acquisition of gamma synchrony, most commonly at approximately 40 Hz [85].

Gamma synchrony has also been hypothesized to “bind” disparate features of a given object, such as color, size, texture, and motion, into a temporally unified sensory stimulus [86].

On the other hand, thalamocortical neurons receive ascending projections from the locus coeruleus (noradrenergic), raphe nuclei (serotonergic), reticular junction (cholinergic), TMN (histaminergic) and project to cortical pyramidal cells. In the tonic firing state, thalamocortical neurons transmit information to the cortex that is correlated with the spike trains encoding peripheral stimuli [87, 88]).

In brief, the control of sleep and wakefulness depends on the brainstem and hypothalamic modulation of the thalamus and cortex.

3.3.4. Epithalamus

Fig. 8 (Case 6) did not confirm the presence of the sleep/vigil rhythm disorder as we should have expected. As a conclusion, the pineal gland has not a relevant role in the evolution of the state of consciousness.

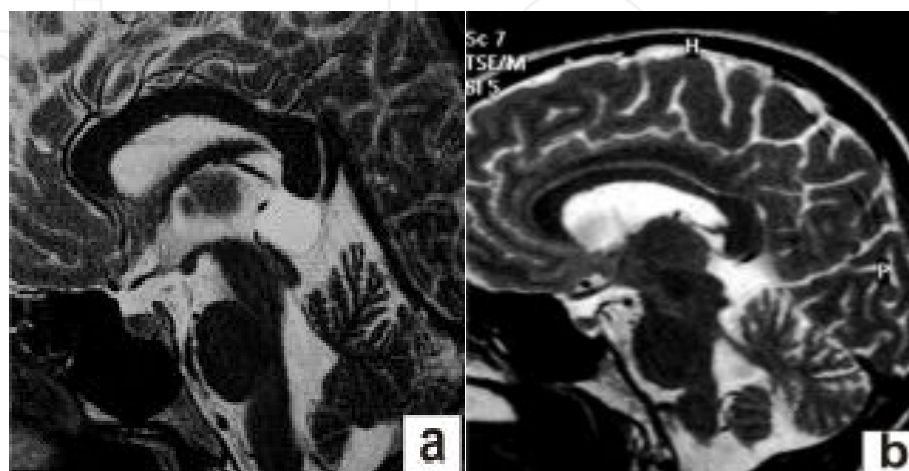


Figure 8. Sagittal (a) gadolinium-enhanced magnetic resonance images show a pineal body tumor (pineocytoma) before, and complete removal of it (b), (surgeon Leon Dănilă) (case 6).

The function of the epithalamus is not well understood. The production of the pineal hormone melatonin is cyclic with high levels of synthesis occurring at night and low levels during the day.

3.3.5. A destructive disease of the diencephalon

Unilateral thalamic or diencephalic lesions (tumors, hemorrhage, etc.) do not determine coma. Bilateral destructive lesions of the diencephalic region result in deep coma and death, despite an intact cortex.

Occasional inflammatory and infectious disorders may have a predilection for the diencephalon. Fatal familial insomnia, a prion disorder, is reported to affect the thalamus selectively, and this has been proposed as a cause of the sleep disorder although this produces hyperwakefulness, not coma [89]. Humans with bilateral damage to the region of the dorsal pons, midbrain, and thalamus (by trauma, brain tumor, viral or bacterial infection, ischemic or hemorrhagic stroke) may exhibit an impaired state of alertness, possibly becoming stuporose or comatose.

3.4. The limbic system and hippocampus

The bilateral limbic encephalitis lesions in Fig. 9 (case 7) where the cerebral cortex has remained unaffected by the above mentioned pathological process has led in a very short time to the development of coma and the death of the patient.

Broca first described and named the limbic lobe [90]. In a subsequent phase in speculation on the limbic lobe it was suggested that, in humans, this lobe is partially olfactory and is mainly concerned with emotional behavior. In addition, the amygdala was seen as part of limbic lobe [91, 92]. Finally, it was shown that the hippocampus projects *via* the fornix back to the hypothalamus [91]. This concept was developed further, insisting on the functional importance of certain regions of the neural axis, such as the septum, cingulate gyrus, orbitofrontal cortex, preoptic area, "limbic striatum" (including the nucleus accumbens, mesolimbic dopaminergic tract), nonspecific thalamic nuclei, hypothalamus and midbrain tegmental area, regions closely related to the amygdala and hippocampus [93]. These regions form a ring, or "limbus", around the base of the brain. Anterior cingulate cortex (ACC) is part of a neural circuit that mediates outcome-contingent changes in behavior [94 - 96] and processes fictive information in humans [97]. The ACC is interconnected with the orbitofrontal cortex which mediates fictive thinking in humans [98, 99].

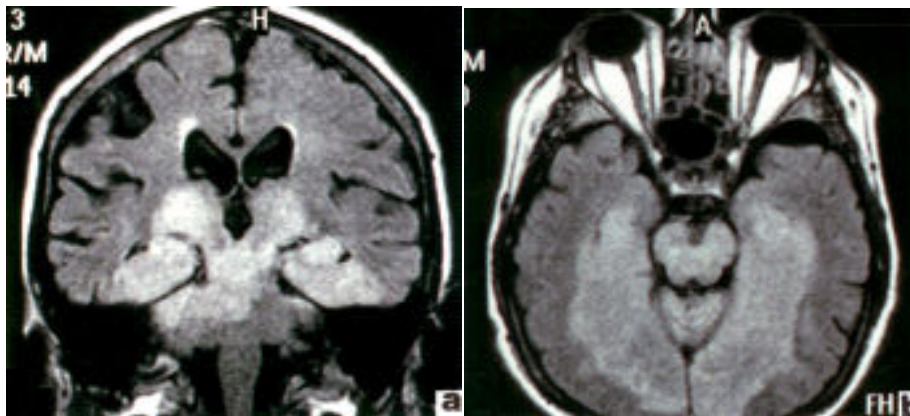


Figure 9. Coronal (a) and axial (b) T1-weighted magnetic resonance imaging scans revealed edematous, demyelination symmetrical changes infra- and supratentorial, which involve the entire midbrain, both thalamic formations, bilateral basal ganglia, two-side temporo-occipital convolution and hippocampus, determined by encephalitis (limbic encephalitis). After 9 days of coma, the patient died (case 7).

It was also hypothesized that neurons in the ACC, which monitors the consequences of actions and mediates subsequent changes in behavior, would respond to fictive reward information [100].

Generally, the hypothalamus allows to consider that the link between the limbic and endocrine system reasonable. The limbic system is now considered to be a functional unit. Areas around the limbic system are called paralimbic and have a more complex histologic structure. Anyhow, the limbic system makes a link between the external and the internal world.

3.4.1. Hippocampus

The hippocampus occupies the medial part of the floor of the temporal horn and is divided into three parts: head, body and tail. The hippocampus is bilaminar, consisting of the cornu Ammonis (or hippocampus proper) and the gyrus dentatus (or fascia dentata), with one lamina

rolled up inside the other. The possible functions of the hippocampus are divided into four categories: (1) learning and memory, (2) regulation of emotional behavior, (3) certain aspects of motor control, and (4) regulation of hypothalamic functions [101]. The hippocampus and related diencephalic structures form and consolidate declarative memories that are ultimately stored elsewhere.

The hippocampus is also involved in the regulation of the hypothalamo-hypophyseal axis. Through its projections to the paraventricular hypothalamic nucleus, it may inhibit the hypophyseal secretion of adrenocorticotrophic hormone (ACTH)[102 – 105].

3.4.2. *Amygdala*

The amygdala is a complex mass of gray matter buried in the anterior-medial portion of the temporal lobe, just rostral to the hippocampus. The amygdala and its interconnections with an array of neocortical areas in the prefrontal cortex and anterior temporal lobe, as well as several subcortical structures, appear to be especially important in the higher order processing of emotion.

The amygdala links cortical regions that process sensory information with hypothalamic and brainstem effector systems. In a review of the role of the amygdala in emotional processing, there were identified five areas in which there is evidence coming out from studies regarding the cognition-emotion interactions involving the amygdala: implicit emotional learning and memory; emotional modulation of memory; emotional influences on perception and attention; emotion and social behavior; emotion, inhibition and regulation [106].

3.5. The cerebral cortex

We consider that the most important logical scheme to shape and analyze the consciousness has a modular structure. The inner structure of all our behavior acts is multimodular and it is subordinated to a main module, in agreement with [107]: “In the brain everything is connected to everything”. In our opinion the module is one morphofunctional cortical specific unit (column, area, circumvolution, etc) related to selfconsciousness (physical, psychic), or to the structure and content of the external, objective environment (social, political, religious, physical, etc).

From the analysis of cases 8 - 15 it results that the injury of a part of the cerebral cortex or of a cerebral lobe leads to the partial alteration of certain components, or better said modules, of the state of consciousness. Thus, in Fig. 10 (case 8), where the orbital prefrontal region is compressed by the meningioma, there has been administered or has disappeared certain emotional functions such as response inhibition, stimulus significance, perception, memory and thought.

The reactivating process and the immediate memory has been the most affected. The moriatic orbitofrontal syndrome has asserted itself through emotional lability, impulsive behavior, sexual disinhibition, reduction of criticism, puerile euphoria, logorrhea, excessive joviality, urinary and stercoral gatism [108]. It has been shown that this region has a significant role in

the social and emotional behavior, as well as in the build-up of the new memory data [45, 109, 110]. The orbitofrontal module of the state of consciousness has an extremely important role in the social life.

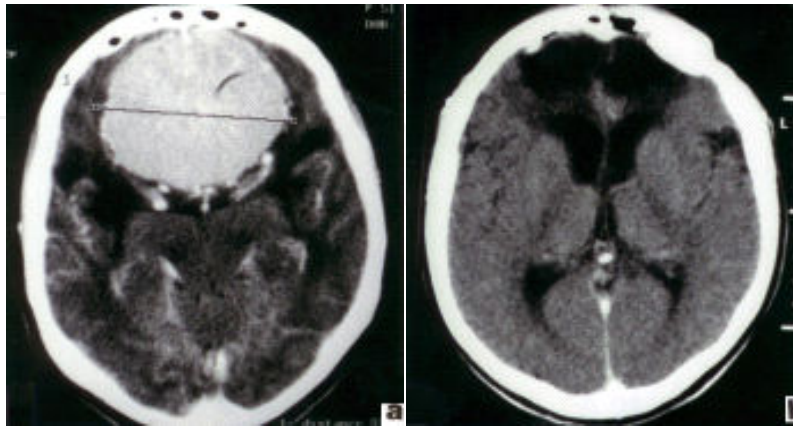


Figure 10. A preoperative contrast-enhanced computed tomographic (CT)-scan of a 56-year-old man shows a giant size olfactory groove meningioma, and displacement of anterior brain (a). The patient presented an orbitofrontal syndrome. Postoperative contrast-enhanced CT-scan showing no residual tumor (b) and the fact that the orbitofrontal syndrome disappeared (surgeon Leon Dănilă) (case 8).

The patient with lesions of the orbitofrontal cortex does not have adequate social abilities, in spite of the fact that he shows an intact cognitive processing of multiple tasks which are performed with great difficulty. Occasionally, the behavioral syndrome is so severely affected that it has been introduced the term of “acquired sociopathy” [111, 112].

Fig. 11 (Case 9) demonstrates the loss of another consciousness module relative to the functionality of the lateral prefrontal cortex, namely the areas 8, 9, 10 and 46.

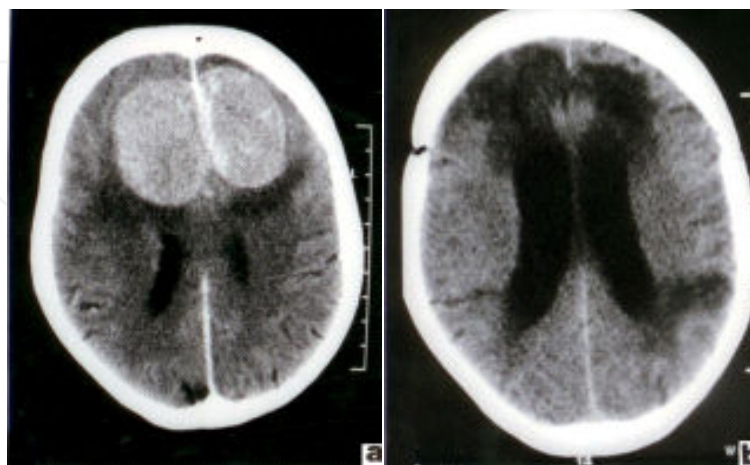


Figure 11. A preoperative contrast-enhanced computed tomographic (CT) scan of a 35-year-old woman shows a bilobed meningioma of the anterior falx (a). She has a dorsolateral frontal syndrome. Postoperative contrast-enhanced CT scan showing no residual tumor (b) and the fact that the frontal syndrome disappeared (surgeon Leon Dănilă) (case 9).

The injury of these areas leads to the alteration of a wide range of cognitive processes, such as the sustained and concentrated attention, the fluency and flexibility of thought in generating solutions for new circumstances, and the purpose-oriented adjustment of the adaptive behavior [45, 112, 113].

In Fig. 12 (case 10), the left parietal cystic astrocytoma has led to the development of Gerstmann's syndrome, another consciousness module which is specific for this lobe.

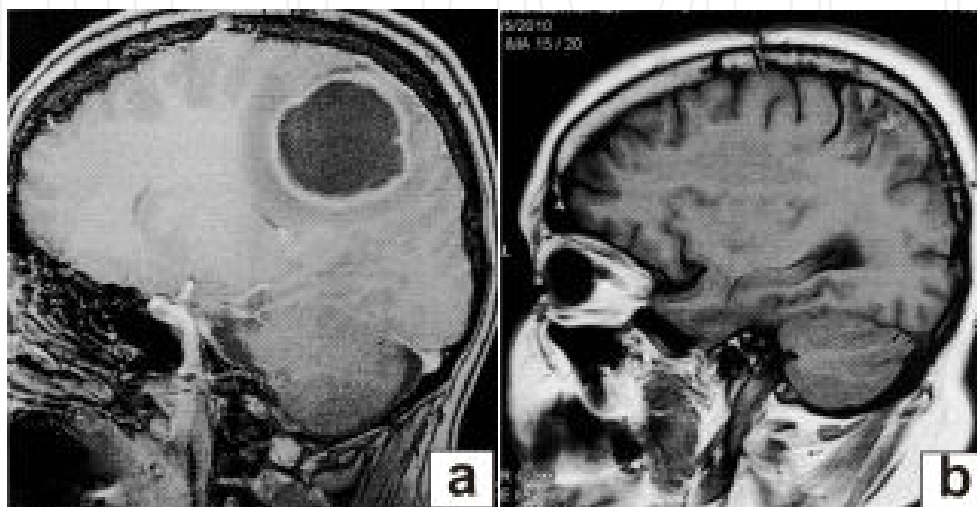


Figure 12. T1- enhanced sagittal MRI (a) demonstrates a large parietal cystic tumor in a 42-year-old man, presented with a 3 months history of a subtle sensory aphasia and Gerstmann's syndrome (incompletely). Postoperative sagittal MRI (b) demonstrates total tumor removal of a cystic astrocytoma and Gerstmann's syndrome disappeared (surgeon Leon Dănilă) (case 10).

If we consider the anterior (somatosensory) and posterior parietal zones as functionally distinct regions, we can identify two independent contributions of the parietal lobes. The anterior zone processes somatic sensations and perceptions; the posterior zone is specialized primarily for integrating sensory input from the somatic and visual regions and, to a lesser extent, from other sensory regions, mostly for the control of movement [21]. In 1924, Gerstmann described a patient with an unusual disorder subsequent to a left parietal stroke. Gerstmann's syndrome (left - right confusion, acalculia, and agraphia) provides the striking example of bilateral asomatognosia and is due to a left, or dominant parietal lesion [114].

The results of the examination of Fig. 13 (case 11) highlighted the right parietal module whose alteration leads to the occurrence of a series of symptoms which has been very well summarized by [115 - 117]. Tactile perseveration and hallucination of touch, cortical sensory loss, impaired recognition of objects, texture, two-point discrimination, stimulus localization, barognosis, vibratory sensation, position, sense, graphesthesia, hemianesthesia, tactile inattention, altered sensory adaptation time, anaesthesia, asymboly for pain, pseudothalamic pain syndrome, unilateral asomatognosia (Anton Babinski syndrome), anosognosia, amorphosynthesis, ideomotor and ideational apraxia, dressing apraxia, stereoanesthesia, astereognosias tactile agnosia etc.

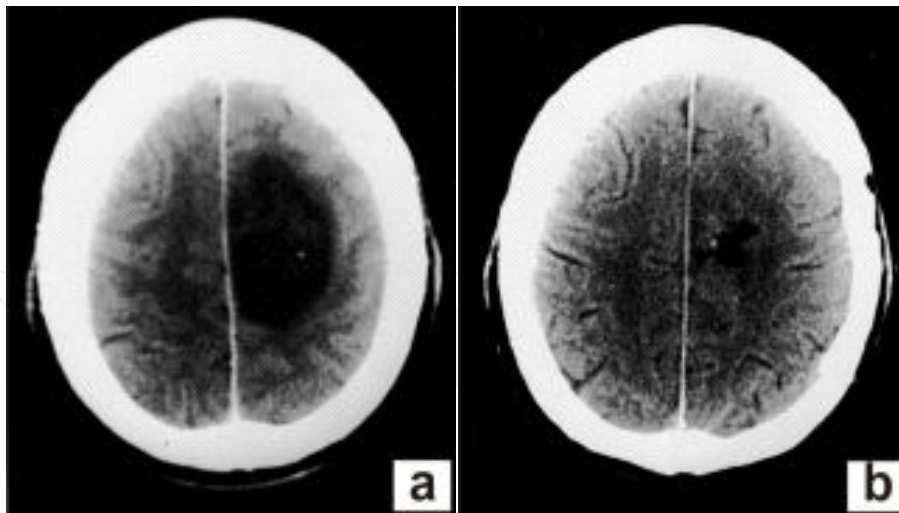


Figure 13. Preoperative CT-scan (a) of a 39-year-old man shows a tumor in the right parietal region. The patient was noted to have a left hemiparesis, tactile inattention and constructional apraxia, dysprosody, apraxia for dressing, and anosodiaphoria. Postoperative CT-scan (b) demonstrates the complete removal of the tumor (astrocytoma). Parietal syndrome disappeared (surgeon Leon Dănilă) (case 11).

So, patient's appreciation of self in relation to the environment is distributed. Some disorder occurs in the state of continuous consciousness of parts of the body, which depends on the influx of sensations and their association with past memories, the stream-of-life experiences, and the feelings that keep us continuously aware of ourselves [116]. The patients have an altered way of feeling and experiencing. It is tempting to view all these elusive clinical phenomena as manifestations of more general disturbances of the body-environmental schemata, but the evidence to support this view is insufficient [116].

In Fig. 14 (Case 12), the right temporal tumor demonstrates the presence of another modular appearance of the state of consciousness. The temporal lobes do not have a unitary function, in that they house the primary auditory cortex (Heschl's gyrus with area 41), the auditory association cortex, the visual cortex, the limbic cortex, and the amygdala and hippocampus.

Left temporal lesions are associated with deficits in processing speech sounds, whereas right temporal lesions are associated with deficits in processing certain aspects of music.

Right, but not left, temporal-lobe lesions lead to impairments in the recognition of face and facial expression. The temporal lobe is the great integrator of sensations, emotions, and behaviors and it is continuously active throughout life. So, the two sides play different roles in social recognition and have different effects on personality and consciousness.

The temporal lobe seems to be the site where all sensory modalities are integrated into ultimate self-awareness. The stream of thinking requires both language and memory function and both these functions involve the temporal lobes.

Long-term memory depends on the entire visual stream as well as on the paralimbic cortex of the medial temporal region.

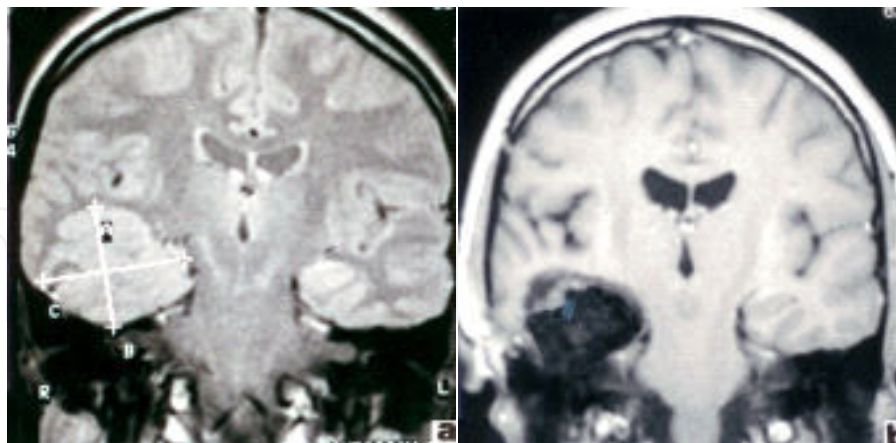


Figure 14. Preoperative coronal T1-weighted, gadolinium-enhanced magnetic resonance images (a) were obtained from a 46-year-old man and demonstrated a large right-sided temporo-basal astrocytoma; (b). image obtained after complete removal of the tumor. (surgeon Leon Dănilă) (case 12).

Patients with left posterior temporal lesions may show dysphasic symptoms in which they can recognize the broader categorization but have difficulty with the more specific ones.

The amygdala contributes to normal and abnormal emotional responses and experiences [112, 118, 119]. Epilepsy is not an unitary phenomenon and there is no reason to expect patients with epilepsy to have a specific personality type.

So, psychomotor symptoms may be defined as a “state of clouding of consciousness” [120].

The results of the examination of Fig. 15 (case 13) have revealed the absence of another module of the state of consciousness known as Balint’s syndrome. However, at the level of each lobe we can find several modules of the state of consciousness.

Their numbering and statistical assessment might lead to the calculation or estimation of the state of consciousness of each individual, in both normal and pathological states.

Hereinafter we shall underline the modular functions of the occipital lobe.

Extrastriate cortical areas are organized into two largely separate systems that eventually feed information into cortical association areas in the temporal and parietal lobe. Thus, the dorsal stream leads from the striate cortex into the parietal lobe. This system is responsible for spatial aspects of vision and for the speed of movement [121]. The ventral stream includes area V4 and leads from the striate cortex into the inferior part of the temporal lobe. This system is responsible for high-resolution form vision and object recognition, such as selectivity for shape, color, texture, and faces [121]. Some neuroimaging studies have implicated ventral occipito-temporal cortex in the nearly area, but distinct from fusiform face area, in the analysis of visual world form.

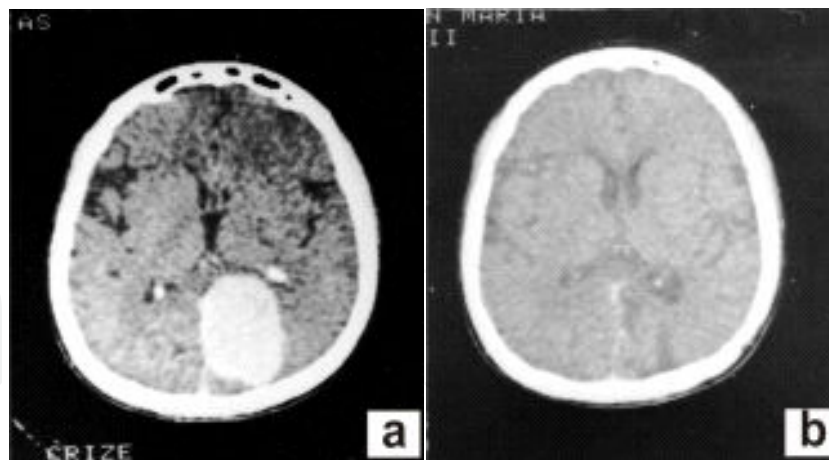


Figure 15. Preoperative contrast-enhanced CT-scan (a), showing a right side parasagittal parietooccipital meningioma in a 42-year-old woman who presented Balint's syndrome. Postoperative CT-scan demonstrates total removal of the tumor (b). After two months, Balint's syndrome disappeared (surgeon Leon Dănăilă) (case 13).

Primary visual cortex, also known as striate cortex (V1) is within, and adjacent to, the calcarine sulcus. V1 sends feedforward signals to many higher visual areas such as V2, V3, V4 and motion-sensitive area MT, to name a few [122].

So, in clinical description, a patient who suffered a stroke that damage the extrastriate region, thought to be comparable to area MT (middle temporal area) in the monkey, is unable to estimate the motion of objects.

Another example of a specific visual deficit as a result to extrastriate cortex is cerebral achromatopsia.

However, different cortical areas and neurons involved in processing specific kind of visual stimuli (color, orientation, motion, faces, objects, etc.), together with other cortical areas and subcortical structures (thalamus, hypothalamus, reticular formation, etc.) seem to play different roles in our conscious visual experience [123].

Combination of feedforward-feedback signals is important for awareness, because higher areas need to check the signals in nearby areas and confirm if they are getting the right message, or perhaps to link neural representation of an object to the specific features that make up the object [124].

Visual field deficits, visual agnosia, associative agnosia, apperceptive agnosia, simultanagnosia, prosopagnosia, visual object agnosia, disorder of reading, disorder of color processing, achromatopsia, color anomia, color agnosia, visual neglect, polyopsia, oscillopsia, cortical blindness (Anton's syndrome), topographical disorientation, defects in constructional skills, visual illusions (metamorphosias), visual hallucination, etc. are symptoms known by the neurologists for more than ninety years.

Brain lesions studies are important for understanding what brain areas may be necessary for certain kind of visual awareness - awareness of color, motion, faces, objects, or the capacity to be aware of seeing anything at all [124].

The results arising from the analysis of Fig. 16 (case 14) and of Fig. 17 (case 15) demonstrate that the bilateral cortical and subcortical lesions lead to the development of coma and death.

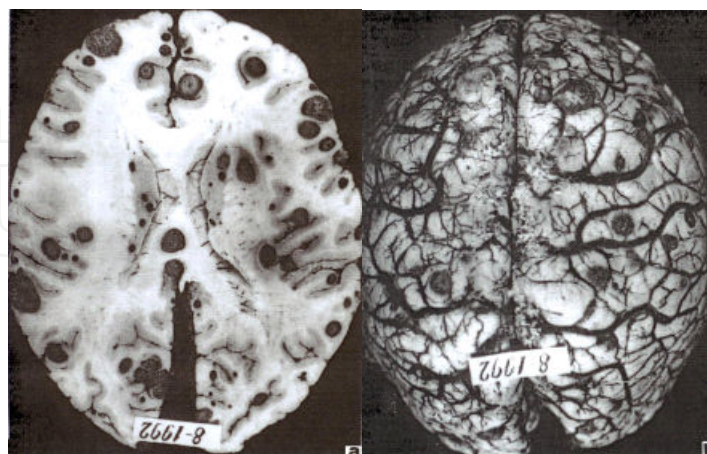


Figure 16. Bilateral, cortical and subcortical, showing more than 110 cerebral metastases (a) and (b). The primitive tumor was a melanocarcinoma (case 14).

The patients with catastrophic diseases and panhemispheric syndromes who are associated with intractable seizures, determined by Rasmussen's encephalitis, hemimegaencephalopathy, tuberous sclerosis, hamartomas, Sturge-Weber syndrome, and congenital hemiplegia or porencephaly, are subjected to hemispherectomy [125].

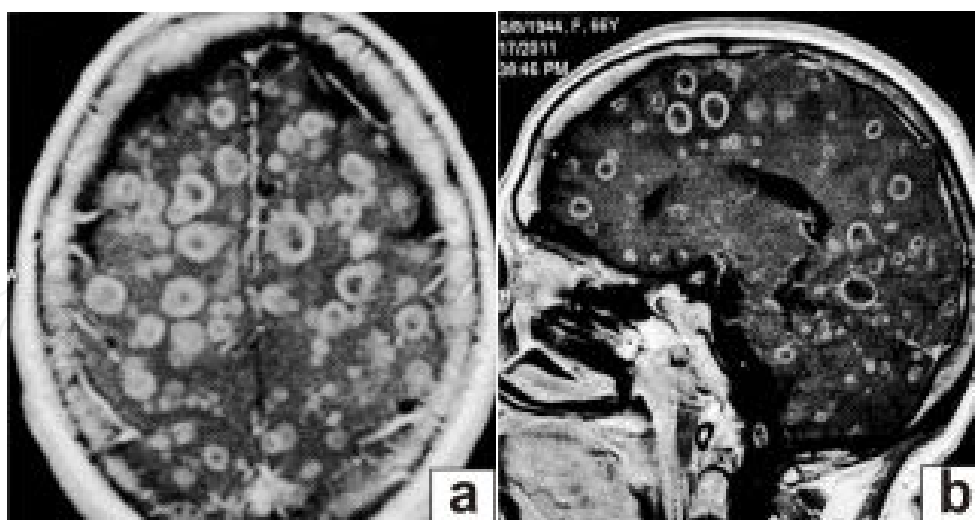


Figure 17. Fast spin-echo T1-weighted axial (a) and sagittal (b) images with enhanced contrast, reveal round, multiple parenchymal cysts in the acute encephalitic stage that are T2 hyperintense and T1 hypointense. These lesions were associated with central nervous system cysticercosis. Scolex are rarely visible as a small point in the interior of certain cysts.

After hemispherectomy, the respective patients remain conscious, but with more or less important deficits, depending on the excised hemisphere.

As a conclusion, the involvement of a single hemisphere leads to the disappearance of some of the consciousness modules, but not to its total loss.

The cerebral cortex of the cerebral hemispheres, the convoluted outer layer of gray matter composed of tens of billions of neurons and their synaptic connections, is the most highly organized correlation center of the brain, but the specific of cortical structures in mediating behavior is neither clear-cut nor circumscribed [126, 127]. This multitude of neurons sends a large number of axons in all directions, covered by supportive myelin. This forms the white matter of the cortex fills the large subcortical space.

The cerebral cortex receives sensory information from internal/external environment of the organism, processes this information and then decides on and carries out the response to it.

In general, the cerebral cortex supply much of the content and registration function of consciousness, including language, abstract reasoning, somatosensory visual and spatial abilities, map of the physical dimensions of the self, executive function, complex emotion, feelings, memory and ability to read other's mind. While the cortex is vital for cognitive functions, it interacts constantly with major satellite organs, notably the thalamus, basal ganglia, hypothalamus, cerebellum, brainstem, and limbic regions, among others.

In order to be conscious, to operate at normal parameters, to record and potentiate the internal and external sensory data and to correctly process them based on the previous individual experience, and to answer adequately, it is necessary that the cerebral cortex should be integer and aroused by the ascending activating system.

These considerations suggest that there might be multiple conscious awareness systems each of them supporting conscious awareness in different mental domains.

3.5.1. Unilateral and diffuse, bilateral cortical destruction

Different regions of the cerebral cortex have modular specific functions (somatic sensory and motor, visceral sensory and motor, integrative cognitive functions, speech functions, etc.) responsible for the high-order cognitive processing or conscious mind. These correspond to the Brodmann areas, as well as to each of the four cerebral lobes.

Being aware of the somatic and visceral ego refers to the ability of being conscious of the components of one's body, concrete activities and their status. Thus, a lesion of the parietal lobe leads to a destruction of the ego, which manifests through agnosia, such as asomatognosia (denial of one's own body part), finger agnosia, tactile agnosia, hemiosomatognosia.

The ideational consciousness refers to the ability of one person to be aware of their concrete activities, ideas and thoughts that are expressed through spoken or written words. A lesion of the frontal, parietal, occipital, temporal lobe and of the callous body leads to apraxia, Gerstman's syndrome, Balint's syndrome, akinetic mutism, aphasia and agraphia. Emotional consciousness refers to the ability of being aware of emotions. The frontal lobe and the left parietal lobe coordinate positive emotions, whereas the ones on the right side coordinate negative emotions.

We stress on the existence of the same discrete modules in the brain for each possible neuropsychological capacity. Adjacent modules communicate with each other more than do non-adjacent modules. So, the term of modular or functional localization of consciousness is used to indicate that certain functions can be localized to particular areas of the cerebral cortex. The mapping of cortical functions began with the inference made from the deficits produced by cortical lesions in humans.

As we have noticed, partial lesion of some Brodmann specialized areas or of one of the lobes, leads to the modular loss of consciousness. When the entire cerebral cortex is destroyed as well as the white matter of the two hemispheres, that globally depress neuronal activity, the consciousness level decreases and coma is produced. These causes of diseases include cortical and subcortical tumors, hypoxia, sedatives, hypnotics, neurotransmitter receptor antagonists, neural toxins, infectious diseases and metabolic diseases. Careful studies of split-brain patients make it clear that the right hemisphere has a consciousness of its own, even if it lacks the ability to communicate its experiences verbally.

4. Discussion

The consciousness processes belong to people who act by control mechanisms of psychological activities, generalization and abstractization mechanisms, as well as by exploring and handling of mental images to solve all the problems man is facing with. The consciousness level depends on the complexity of the brain ontogenetic evolution. It must be a function of numerous interacting systems.

Data based on our experience support this statement. In Table 1 we present a synthesis of the lesions produced to the brain modules for the patients/cases analyzed in this paper. All the damaged modules or circuits have as direct consequences modifications of the respective consciousness state of the patients as described in detail in the chapter Results.

According to Tononi and Laureys, consciousness can be dissociated from other brain functions, such as responsiveness to sensorial inputs, motor control, attention, language, memory, reflection, spatial frames of reference, the body and perhaps even the self [128]. We consider this point of view to be incorrect because consciousness cannot appear without these functions. It cannot be dissociated from them. The respective functions represent modules of the consciousness. The consciousness results from the respective cerebral activities. Lesions of some functions lead to modular disorder of the consciousness.

The major structures supposed to play a key role in the neural correlates of consciousness are: the brainstem, the diencephalon (the hypothalamus and thalamus), the limbic system (especially the hippocampus and amygdala), basal ganglia, cerebellum, and the cerebral cortex. The brainstem is the source of massive reticular formation pathways that activate or inhibit higher and lower brain centers. They are the core of the basic arousal and sleeping cycle.

The hypothalamus, the thalamus and the cerebral cortex are likely closely intertwined with RF which plays a key role in consciousness. In general, there are an ascending activating system (AAS) and an ascending inhibitory system (AIS).

However, AAS which appears to be responsible for maintaining cortical arousal is not the same with consciousness.

Sleep is based on ascending reticular inhibitory system. The two reticular systems (AAS and AIS) are under the influence of the suprachiasmatic nucleus and of the awake and sleep centers in the hypothalamus. So, as much as awake is determined by AAS, sleep, considered the most profound natural alteration of consciousness, is determined by AIS. AAS and AIS are not the neurological basis of consciousness but they rather constitute the necessary substrate for consciousness to emerge.

Lesions of AIS produced the logorrhea syndrome with hyperkinesia, hyperwakefulness and hyperprosexia. Bilateral lesions/destructions of the neurological formations (brainstem, midbrain, diencephalon, limbic system and cerebral cortex) lead to the loss of consciousness. The ascending inhibitory system is important in explaining the sleep and many other behavior aspects.

On the other side, the cerebral cortex and consciousness have a modular structure. AAS and AIS reach the cerebral cortex directly, through the thalamus and the hypothalamus. In order to be conscious, it is necessary that the cerebral cortex should be integer and aroused. Thus, to be conscious is equivalent of having access to information about the self and the environment and to have the capacity to read another individual's intention. The consciousness is the most developed form of expressing the personality. The self, similar to the ego, the spirit, the soul is the main expert in primary knowledge. So, consciousness is not equal to the awakened state of mind, as it involves functions of almost the entire brain. But different brain structures and functions have a certain role in generating consciousness. The consciousness, as a result of functions from almost entire brain, is composed by modules which have different important values and features.

Injuring one module only leads to partial modification of the conscious state. Thus, attention, memory, sensorial input, motor output, language, introspection/reflection, space, body and self, perception, imagination, gnosia, etc. are necessary prerequisite of consciousness. The measurement scale of the (actual) level of consciousness of a person in the awakened state of mind and under ordinary life condition is composed of several modules such as: being aware of the somatic, visceral, cognitive, emotional and spiritual ego, and being aware of the physical, spatial, social, socio-relational extra ego.

In the following we will analyse a few data about the implication of the cerebellum in the consciousness.

Throughout the lifespan, the cerebellum plays an essential and fundamental role in organization and expression of higher-level cognitive functions and consciousness. Cerebello-cortical and cortico-cerebellar circuits represent the neuroanatomic substrate. So, the feed forward connections from cortex to cerebellum and the feedback connections from cerebellum to cortex

are developed very early in life [129]. However, there is a topographical organization of the cerebellum, along antero-posterior and medial-lateral gradients. Thus, sensori-motor functions are primarily mapped in anterior regions of the cerebellum. Cognitive functions are primarily mapped in posterior and inferior cerebellar regions [130]. Lesions in the anterior lobes should generate motor deficits, and lesions in posterior lobes should result in cognitive impairment [131].

CASE / FIGURE IN THE TEXT	DAMAGED CIRCUITS OR MODULES
LESIONS OF AREA OR BRAIN CIRCUITS BETWEEN BRAINSTEM AND CEREBRAL CORTEX	
Case 1; Fig.1	Via the Ascending (reticular) activating system (AAS)
Case 2; Fig.4	Via the Ascending (reticular) inhibitory system (AIS)
LESIONS OF SOME SUBCORTICAL CENTERS	
Case 3; Fig.5	Pineal gland
Case 4; Fig.6	Hypothalamus
Case 5; Fig.7	Thalamus
Case 6; Fig.8	Pineal gland
Case 7; Fig.9	Limbic encephalitis
LESIONS OF BROADMANN CORTICAL CEREBRAL AREAS	
Case 8; Fig.10	Olfactory meningioma; lesions produced on cortical areas: 10; 11; 13; 14; 34; 35; 47.
Case 9; Fig.11	Bi-lobed meningioma of the anterior falx; lesions produced on cortical areas: 8; 9; 10; 46.
Case 10; Fig.12	Left parietal cystic astrocytoma; lesions produced on cortical areas: 7a, 7b and 5 which project the frontal areas 6, 8, 9.
Case 11; Fig.13	Right parietal fibrillary astrocytoma; lesions produced on cortical areas: 1; 2; 3a; 3b; 5; 7; 40.
Case 12; Fig.14	Right-sided temporobasal astrocytoma; lesions produced on cortical areas: 20; 28; 34; 36; 38.
Case 13; Fig.15	Right parieto-occipital meningioma producing lesions of the cortical areas: 7; 19.
Case 14; Fig.16	Cortical and intracerebral metastases producing lesions of all the cortical areas.
Case 15; Fig.17	Neurocysticercosis metastases producing lesions of all the cortical areas.

Table 1. Lesions produced in the brain modules shown by the reported cases

In addition, the medial-lateral gradient predicts that lesions within the vermal area should generate changes in affective/emotional functioning, while lesions in lateral region should result in cognitive deficits. Cognitive deficits include impairment in attention, planning, abstract thinking, and memory.

Children with involvement of the vermis, or “limbic cerebellum”, develop changes in personality functioning, such as irritability, emotional lability, and even autistic-like cognitive and behavioral features [132].

So, the cerebellum contributes to consciousness.

The cerebellar cognitive affective syndrome with his group of cognitive, emotional, and behavioral symptoms is a module of consciousness [133]. The picture of cognitive and affective characteristics of this syndrome is impaired in patients with posterior involvement of the cerebellum and in patients demonstrating pathology within the vermis.

The type and level of impairment that these patients demonstrated was undistinguishable from that observed in individuals demonstrating pathology within the cerebral cortex, because the cerebellum regulates neural signals in these regions of the brain [129].

Disturbances have been identified in executive functioning, like impaired planning, set-shifting, verbal fluency, abstract reasoning, visuospatial organization, working memory, episodic memory, and attention. Blunting of affect or disinhibited and inappropriate behavior, are characteristic of patients with midline cerebellar involvement.

General intellectual functioning was also affected.

Visuospatial deficits are characteristic of patients with left cerebellar lesions and verbal memory difficulty, with particular problems in working memory and are also characteristic of patients with right cerebellar infarcts [134]. Deficiencies in the performance of non-verbal tasks and deficits in prosody follow left cerebellar lesions. Impairment in verbal intelligence and higher-level language skills typically follow right cerebellar lesions. In addition, the language deficit observed with right cerebellar involvement does not occur in isolation. It is accompanied by cognitive deficits such as impairment in the shifting of attention and thinking or persevering behavior, as well as impairment in problem-solving. Residual functional deficits are common [135, 136].

So, there were visuospatial deficits and dysprosodia with left cerebellar hemispheric infarct and language difficulties and executive function deficit with right cerebellar hemisphere infarct. These localizations of the previous phenomena have been reported in [133 – 135, 137, 138].

The left lateral cerebellum is more active in procedural learning through the ipsilateral hand, but the right lateral cerebellum is activated in procedural learning regardless of hand [139, 140]. The role of the right cerebellum has been related to the refinement or timing of signals within the left dorsolateral prefrontal cortex. Patients with either focal or atrophic cerebellar damage have also been described as demonstrating impairment in cognitive sequence learning [141, 142].

On the other hand, the discovery of the existence and functions of the mirror-neurons, reported in [143, 144] led to the explanation of the learning by imitation, of the empathy, of the reading of other people's thoughts and to the understanding of the connection between the individual and universal consciousness. The development of the multitude of the specific human abilities took place only when the mirror-neurons multiplied and became concentrated in well localized zones within the cerebral cortex and in particular in the pre-frontal lobes.

5. Conclusions

According to our results, two reticular systems: ascending activating system – AAS and ascending inhibitory system – AIS, may be introduced as functional units that seem to play an important role in consciousness. Observing and correlating the status of the “hardware” of the brain whose subunits are affected by neurological diseases/accidents and by related neurosurgical interventions in humans with the induced modifications of the consciousness in the respective patients, we have been led to the conclusion: besides the already reported and accepted ascending activating system (AAS, formerly called ARAS) that has an important role in the consciousness state, an ascending inhibitory system (AIS) should be defined which acts so that in interaction with AAS the consciousness state may be controlled and kept under functional equilibrium. By points, our main conclusions are:

- The bilateral destruction of the reticular activating nuclei at the rostral pons and midbrain lead to loss of consciousness and the induction of coma.
- The damage of the ascending reticular inhibitory system leads to the appearance of the logorrhea syndrome with hyperkinesia, hyperwakefulness, and hyperprosexia.
- The ascending inhibitory system is very important in explaining the sleep and many other behaviors.
- AAS and AIS reach the cerebral cortex by three distinct ways: directly, through the thalamus, and through the hypothalamus.
- The sleep is controlled by the action of the AAS-AIS dipole.
- With respect to its functioning, the cerebral cortex may be compared to a continuous chess game between of the two systems, AAS and AIS, which act in perfect equilibrium, in order to perform all functions and behaviors of the individual.
- The cerebral cortex and consciousness have a modular structure.

Related to our conclusions, in Table 2 we present a more detailed synthesis of the relations between the lesions produced in the brain by the tumors operated neurosurgically and the modifications of the consciousness observed before and after operations. In this table are shown the specific connections between the brain (AAS and AIS included) lesions/tumors and the consciousness alterations, for each of the operated cases. The connections are made between the brain modules numbers (as generally known) [24, 25], the modules of the consciousness and their denominations on one hand (first two columns). On the other hand, are presented in the columns 3, 4 and 5, respectively, the case number and the corresponding figure, the modules of the consciousness that suffered modifications due to the lesions produced in the brain modules (in each operated case), and the coma/disease cases. As for the brain modules 9 and 10, in Table 2 no operated cases were shown by us in this chapter.

MODULE NUMBER**	CONSCIOUSNESS MODULE DENOMINATION	CASE ORDER / FIG. NUMBER	CONSCIOUSNESS MODULE(S) WHICH SUFFERED LESIONS	COMA / DECEASE***
ONE	COGNITIVE MODULE Discrimination, Identification, Classification, Elaboration, Plan & Decision taking	Case 1; Fig.1 Case 2; Fig.4	All modules 2; 5; 9	Coma -
TWO	MODULE FOR COMUNICATION AND LANGUAGE Mediates and Processes Information about the Self and the Environment	Case 3; Fig.5 Case 4; Fig.6	6; 9 6; 7; 9; 10	- -
THREE	AXIOLOGIC MODULE Socio-Cultural Standards, System of Individual Values and Individual Character	Case 5; Fig.7 Case 6; Fig.8	9; 10 9; 10	- -
FOUR	ADAPTATION MODULE Collection, Processing and Stocking Information about the Self and the Environment	Case 7; Fig.9 Case 8; Fig.10	All modules 1; 3; 4; 5; 7; 10	Coma and Decease -
FIVE	VOLITIVE MODULE Regulates the Superior Function of the Consciousness and the Function of Adjustment of ¹² the Subject to the External Challenges	Case 9; Fig.11 Case 10; Fig.	3; 7; 8; 9; 10 1; 2; 10	- -
SIX	MOTIVATION MODULE Internal and Homeostatic Reasons and the Signaling of the Internal States related to the Start-up of the Behavior devoted to satisfy the Physiological, Moral, Esthetic, Religious, Knowledge Needs.	Case 11; Fig. 13 Case 12; Fig. 14	1; 7; 9; 10 1; 10; 12	- -
SEVEN	AFECTIVE MODULE Regulates Positive and Negative Emotions	Case 13; Fig. 15 Case 14; Fig. 16	9; 10 All modules	- Coma and Decease
EIGHT	MEMORY MODULE Up-dates Knowledge Need to cope with the Current Tasks	Case 15; Fig. 17	All modules	Coma and Decease
NINE	MOTOR MODULE Mental Schemes and Programs that Control the Movements	No cases reported in this paper.		
TEN	SENTITIVO – SENZORIAL MODULE Contains Records of the Mental Schemes related to the Self and the Environment	No case reported in this paper		

* AAS and AIS act on Cerebral Cortex and Hypothalamus, in opposition to each other. Ex.: AAS acts on wakefulness center/ AIS acts on sleep activating center.

**The Module number refers to the generally defined consciousness modules.

***Lesions of all modules lead to coma with or without decease. Unless specified, coma/decease are not produced.

Table 2. Relations between lesions of the brain and modifications of the consciousness in the cases described in this paper*

From the data and the analysis dedicated to the description and understanding of the neurological bases of the consciousness it became obvious for us that this subject is not completely elucidated and there is still the need to further develop systematic and systemic research on this topic.

Author details

Leon Dănăilă¹ and Mihail Lucian Pascu^{2*}

*Address all correspondence to: mihai.pascu@inflpr.ro

1 National Institute of Neurology and Neurovascular Diseases, Bucharest

2 National Institute for Laser, Plasma and Radiation Physics, Bucharest

References

- [1] Haldane, E. S. Ross GRT. The philosophical works of Descartes. (translated by ES Haldane and GRT Ross, University Press, (1911).
- [2] Gray, J. A. The contents of consciousness: A neuropsychological conjecture. *Behavioral and Brain Science* (1995). , 18, 659-722.
- [3] Crick, F, & Koch, C. Toward a neurobiological theory of consciousness. *Seminars in Neuroscience* (1990). , 2, 263-275.
- [4] Grossman, R. G. Are current concepts and methods in neuroscience adequate for studying the neural basis of consciousness and mental activity? In: HM Pinsker, WD Willis Jr. (eds), *Information processing in the nervous system*. New York, Raven Press, (1980).
- [5] Dietrich, A. *Introduction to Consciousness*. Palgrave-Macmillan, (2007).
- [6] Nagel, T. What is it like to be a bat? *Philosophical Review* (1974). , 83, 435-451.
- [7] Dennett, D. C. *Consciousness Explained*, Little Brown, (1991).
- [8] Crick, F. *The Astonishing Hypothesis*. New York, Scribner, (1994).
- [9] Hobson, J. A. State of consciousness: normal and abnormal variation. In: PD Zelazov, M Marcovitch and E Thompson (ed), *The Cambridge Handbook of Consciousness*, Chapter 16. Cambridge, University Press, Cambridge, New York, (2007). , 435-444.
- [10] Lewis, M. The development of self-consciousness. In: J Roessler and N Eilan (eds) *Agency and self-awareness*. Oxford, Oxford University Press, (2003). , 275-295.

- [11] Damasio, A, & Mayer, K. Consciousness: An Overview of the Phenomenon and of Its Possible Neural Basis. In: Layers S, Tononi G (eds). *The neurology of consciousness. Cognitive Neuroscience and Neuropathology*. Academic Press, Amsterdam, Boston, Heidelberg, London, (2009). , 3-14.
- [12] Dehaeme, S. The eternal silence of neuronal spaces. *Science* (2012). , 336, 1507-1508.
- [13] Schooler, J. W. Representing consciousness: dissociations between experience and meta-consciousness. *Trends in Cognitive Sciences* (2002). , 6, 339-344.
- [14] Tononi, G, & Edelman, G. Consciousness and complexity. *Science* (1998). , 282, 1846-1851.
- [15] Damasio, A. R. *The feeling of what happens*. New York, Harcourt Press, (1999).
- [16] Edelman, G. M. *Bright air, brilliant fire: On the matter of the mind*. New York: Basic Books, (1992).
- [17] Searle, J. R. *The Rediscovery of the Mind*. Cambridge, MA: MIT Press, (1992).
- [18] Searle, J. R. In *Discussion, Toward a Science of Consciousness Conference*. Tucson, AZ, (2000).
- [19] Yamazaki, T, & Tanaka, S. The cerebellum as a liquid state machine. *Neural Networks* (2007). , 20, 290-297.
- [20] Hatta, T, Masui, T, Ito, E, Hasegawa, Y, & Matsuyama, Y. Relation between the prefrontal cortex and cerebro-cerebellar functions: evidence from the results of stabilometrical indexes. *Apply Neuropsychology* (2004). , 11, 153-160.
- [21] Kolb, B, & Whishaw, Q. I. *Fundamentals of Human Neuropsychology*. Fifth Edition, World Publishers, New York, (2003). , 345-369.
- [22] Danaila, L. *Clinical and experimental study on the reticular substance psychopathology (Romanian language)*. Graduating thesis, Faculty of Philosophy, University of Bucharest, 110, (1972).
- [23] Arseni, C, & Danaila, L. Logorrhea syndrome with hyperkinesia. *Eur Neurol* (1977). , 15, 183-187.
- [24] Danaila, L, & Pascu, M. L. *Lasers in Neurosurgery*. Ed Acad Romane, Bucharest, (2001).
- [25] Danaila, L, & Pascu, M. L. *Second International Symposium on Coma and Consciousness: Clinical, Social and Ethical Implications*, Berlin, June, EU COST ACTION BM0605. Abst. 21, (2009). , 4-5.
- [26] Berger, H. Ueber das electroenkephalogramm des menschen. *Arch Psychiatr Nervenkr* (1929). , 87, 527-570.
- [27] Zeman, A. Consciousness. *Brain* (2001). Pt. 7), 1263-1269.

- [28] Bremer, F. Cerveau isolé et physiologie du sommeil. *Comp. Rend. Soc. Biol* (1935). , 118, 1235-1242.
- [29] Bremer, F. Nouvelles recherches sur le mécanisme du sommeil. *Comp Rend Soc Biol* (1936). , 122, 460-464.
- [30] Moruzzi, G, & Magoun, W. H. Brainstem reticular formation and activation of the EEG. *Electroencephalography and Clinical Neurophysiology* (1949). , 1, 455-473.
- [31] Moore, R. Y, & Bloom, F. E. Central catecholamine system: Anatomy and physiology of the norepinephrine and epinephrine systems. *Ann Rev Neurosci* (1979). , 2, 113-168.
- [32] Minzenberg, M. J, Watrous, A. J, Yoon, J. H, Ursu, S, & Carter, C. Modafinil shifts human locus coeruleus to low-tonic, high-phasic activity during functional MRI. *Science* (2008). , 322, 1700-1702.
- [33] Mcguiness, C. M, & Krauthamer, G. M. The afferent projections to the centrum medianum of the cat as demonstrated by retrograde transport of horseradish peroxidase. *Brain Research* (1980). , 184, 255-269.
- [34] Schiff, N. D, & Plum, F. Web forum: The neurology of impaired consciousness: Global disorder and implied models.(1999). <http://athena.english.vt.edu/egi-bin/netforum/nic/a/>
- [35] Bogen, J. E. The thalamic intralaminar nuclei and the property of consciousness. In: PD Zelazov, M Moscovitch, E Thompson (eds), *The Cambridge Handbook of Consciousness*, Cambridge Univ, Press, (2007). , 775-807.
- [36] Willie, J. T, Chemelli, R. M, & Sinton, C. M. Distinct narcolepsy syndromes in orexin receptor-2 and orexin null mice: Molecular genetic dissection of non- REM and REM sleep regulatory processes. *Neuron* (2003). , 38, 715-730.
- [37] Marrocco, R. T, & Field, B. A. Arousal. In: V.S. Ramachandran (ed) *Encyclopedia of the Human Brain*. Amsterdam, Boston, London etc., Academic Press, (2002). , 223-236.
- [38] More, R. Y, Halaris, A. E, & Jones, B. E. Serotonin neurons of the midbrain raphe: Ascending projections. *J Comp Neurol* (1978). , 180, 417-438.
- [39] Hopfield, J. J, & Tank, D. W. Computing with neural circuits: A model. *Science* (1986). , 233, 625-633.
- [40] Pouille, F, & Scanziani, M. Enforcement of temporal fidelity in pyramidal cells by somatic feed-forward inhibition. *Science* (2001). , 293, 115-116.
- [41] Buzsaki, G. Diversity of cortical functions is provided by inhibition. In: G. Buzsaki (ed), *Rhythms of the Brain*, Oxford University Press, Cycle 3; (2006). , 61-79.
- [42] Bogen, J. E. Some neurophysiologic aspects of cons. *Semin Neurol* (1997). , 17, 95-103.
- [43] Sherrington, C. S. *Inhibition as a coordinative factor*. Elsevier, Amsterdam, (1932).

- [44] Von Monakow, C. ed). Localization of brain functions. Springfield, IL: CC Thomas. (1911).
- [45] Fuster, J. M. The Prefrontal Cortex. Fourth Edition. Amsterdam, Boston, Heidelberg, Academic Press Elsevier, (2009).
- [46] Jennet, B, & Plum, F. Persistent vegetative state after brain damage: A syndrome in research of a name. *Lancet* (1972). , 1, 734-737.
- [47] Giacino, J. T, Ashwal, S, & Childs, N. The minimally conscious state. Definition and diagnostic criteria. *Neurology* (2002). , 58, 349-353.
- [48] [48].Giacino, J. T. The minimally conscious state: defining the border of consciousness. *Progress in Brain Research* (2005). , 150, 381-395.
- [49] Schiff, N. D, Ribary, U, & Moreno, D. R. Residual cerebral activity and behavioural fragments can remain in the persistently vegetative brain. *Brain* (2002). , 215, 1210-1234.
- [50] Bly, M, Faymonville, M. E, & Peigneux, P. Auditory processing in severely brain injured patient: differences between the minimally conscious state and the persistent vegetative state. *Archives of Neurology* (2004). , 61, 233-238.
- [51] Levy, D. E, Sidtis, J. J, Rottenberg, D. A, & Jarden, J. O. Differences in cerebral blood flow and glucose utilization in vegetative versus locked-in patients. *Annals of Neurology* (1987). , 22, 673-682.
- [52] Giza, C. C, & Hovda, D. A. The neurometabolic cascade of concussion. *J Athl Train* (2001). , 36, 228-235.
- [53] Adams, J. H, Graham, D, & Jennett, B. The neuropathology of the vegetative state after an acute brain insult. *Brain* (2000). , 123-1327.
- [54] Brooks, W. M, Friedman, S. D, & Gasparovic, C. Magnetic resonance spectroscopy in traumatic brain injury. *J. Head Trauma Rehabil* (2001). , 16-149.
- [55] Schutter, L, Tong, K. A, & Holshouser, B. A. Proton MRS in acute traumatic brain injury: role for glutamate/glutamine and choline for outcome prediction. *J Neurotrauma* (2004). , 21, 1693-1705.
- [56] Trillet, M, Vighetto, A, & Croisile, N. Hémiballisme avec libération thymo-affective et logorrhée par hématorne du noyau sous-thalamique gauche. *Rev. Neurol (Paris)* (1995). , 151, 416-419.
- [57] Jones GJ The Thalamus. Second edition Vol I and II. Cambridge, New York, Melbourne. Cambridge, University Press, (2007).
- [58] Posner, J. B, Saper, C. B, Schiff, N. D, & Plum, F. eds). Plum and Posner's Diagnosis of Stupor and Coma. Fourth Edition. Chapter 3. Structural causes of stupor and coma. Oxford University Press, (2007). , 88-118.
- [59] Brendler, S. J, & Selverstone, B. Recovery from decerebration. *Brain* (1970). , 93, 381-392.

- [60] Zervas, N. T, & Hedley-whyte, J. Successful treatment of cerebral herniation in five patients. *N Engl J Med* (1972). , 286, 1075-1077.
- [61] Gaus, S. E, Strecker, R. E, Tate, B. A, Parker, R. A, & Saper, C. B. Ventrolateral preoptic nucleus contains sleep-active, galaninergic neurons in multiple mammalian species. *Neuroscience* (2002). , 115, 285-294.
- [62] Szymusiak, R, Alam, N, Steininger, T. L, & Mcginty, D. Sleep-waking discharge patterns of ventrolateral preoptic anterior hypothalamic neurons in rats, *Brain Res* (1998). , 803, 178-188.
- [63] Bosinelli, M. Mind and consciousness during sleep. *Behavioural Brain Research* (1995). , 69, 195-201.
- [64] Saper, C. B, Scammell, T. E, & Lu, J. Hypothalamic regulation of sleep and circadian rhythms. *Nature* (2005). , 437, 1257-1263.
- [65] Card, J. P, Swanson, L. W, & Moore, R. Y. The hypothalamus: An overview of regulatory system. In: *Fundamental Neuroscience* (M Zigmond, FE Bloom SC Landis, L Roberts, LR Squire Eds), Academic Press, San Diego, (1999). , 1013-1026.
- [66] Parent, A. Hypothalamus. In: *Carpenter's Human Neuroanatomy*, 9th ed, Williams and Wilkins, Baltimore, (1997). , 706-743.
- [67] Aschoff, J. Circadian rhythms in man. *Science* (1965). , 148, 1427-1432.
- [68] Hobson, J. A. *Sleep*. New York, Scientific American Library, (1989).
- [69] Colwell, C. S, & Michel, S. Sleep and circadian rhythms: Do sleep centers talk to the clock? *Nature Neurosci* (2003). , 10, 1005-1006.
- [70] Hall, J. C. Genetics of circadian rhythms. *Ann. Rev Genet* (1990). , 24, 659-694.
- [71] Rosato, E, Piccin, A, & Kyriacou, C. P. Molecular analysis of circadian behavior. *Bioassays* (1997). , 19, 1075-1082.
- [72] Von Schantz, M, & Archer, S. N. Clocks, genes and sleep. *J Roy Soc Med* (2003). , 96, 486-489.
- [73] Green, S. *Physiological psychology*. New York, Routledge and Kegan Paul, (1987).
- [74] Steriade, M, Jones, E. G, & Linas, R. R. *Thalamic oscillations and signaling*. New York, Wiley, (1990).
- [75] La Berge D. Networks of attention. In: MS Gazzaniga (ed). *The new cognitive neuroscience* (2nd ed). Cambridge MA, MIT Press, (2000).
- [76] Ojemann, G. A. Common cortical and thalamic mechanisms for language and motor functions. *American Journal of Physiology* (1984). , 246, 901-903.

- [77] Posner, M. I. Structures and functions of selective attention. In: Boll and BK Bryant (eds), *Clinical neuropsychology and brain function: Research, measurement, and practice*. Washington DC, American Psychological Association, (1988).
- [78] Heilman, K. M, Watson, R. T, & Valenstein, E. Neglect and related disorders. In: KM Heilman and E Valenstein (eds), *Clinical neuropsychology* (4th ed). New York, University Press, (2003).
- [79] Kaufman, E. F, & Rosenquist, A. C. Afferent connections of the thalamic intralaminar nuclei in the cat. *Brain Research* (1985). , 335, 281-296.
- [80] Royce, G. J, Bromley, S, & Gracco, C. Subcortical projections to the centromedian and parafascicular thalamic nuclei in the cat. *Journal of Comparative Neurology* (1991). , 306, 129-155.
- [81] Ohye, C. Thalamus. In: *The Human Nervous System* (G. Paxinos ed.) Academic Press, San Diego, (1990). , 439-468.
- [82] Ohye, C. Thalamotomy for Parkinson's disease and other types of tumor. Part 1: Historical background and technique. In: *Textbook of Stereotactic and Functional Neurosurgery* (PL Gildenberg, RR Tasker Eds), McGraw-Hill, New York, (1998). , 1167-1178.
- [83] Ohye, C. Thalamus and thalamic damage. In: VS Ramachandran (ed), *Encyclopedia of the human brain* Academic Press, Amsterdam, Boston, London, (2002).,4, 575-597., 4
- [84] Ames, C, & Marshall, L. Differential diagnosis of altered states of consciousness. In: HR Winn (ed), *Youmans Neurological Surgery*. Fifth Edition, Saunders, Philadelphia. Pennsylvania, (2003), 1, 277-299., 1
- [85] Gray, C. M. Viana di Prisco G. Stimulus dependent neuronal oscillations and local synchronization in striate cortex of the alert cat. *J Neurosci* (1997). , 17, 3239-3253.
- [86] Singer, W, & Gray, C. M. Visual feature integration and the temporal correlation hypothesis. *Ann Rev Neurosci* (1995). , 18, 555-586.
- [87] Steriade, M. Basic mechanisms of sleep generation. *Neurol* (1992). , 42, 9-18.
- [88] Steriade, M. Coherent oscillations and short-term plasticity in corticothalamic networks. *TINS* (1999). , 22, 337-345.
- [89] Della Porta PMaiolo AT, Negri VU. Cerebral blood flow and metabolism in therapeutic insulin coma. *Metabolism* (1964). , 13, 131-140.
- [90] Broca, P. Anatomie comparée des circonvolutions cérébrales. Le grand lobe limbique et la scissure limbique dans la série des mammifères. *Rev Anthropol* (1878). , 1, 385-398.
- [91] Papez, J. W. A proposed mechanism of emotion. *Arch Neurol Psychiatry* (1937). , 38, 725-743.
- [92] Brodal, A. The hippocampus and the sense of smell. A review. *Brain* (1947). , 70-179.

- [93] Nauta WJH. Hippocampal projections and related neural pathways to the midbrain in the cat. *Brain* (1958). , 81, 319-340.
- [94] Ito, S, Stuphorn, V, Brown, J. W, & Schall, J. D. Performance monitoring the anterior cingulate cortex during saccade countermanding. *Science* (2003).
- [95] Kerns, J. G, & Cohen, J. D. MacDonald AW, Cho YR, Stenger AV, Carter SC. Anterior cingulate conflict monitoring and adjustments in control. *Science* (2004). , 303, 1023-1026.
- [96] Kennerley, S. W, Walton, M. E, Behrens, E. J, & Buckley, M. Rushworth MSF. Optimal decision making and the anterior cingulate cortex. *Nature Neuroscience* (2006). , 940-947.
- [97] Chiu, P. H, Lohrent, T. M, & Montague, P. R. Smokers' brains compute, but ignore, a fictive error signal in a sequential investment task. *Nature Neuroscience* (2008). , 11, 514-520.
- [98] Camille, N, Coricelli, G, Sallet, J, Pradat-diehl, P, Duhamel, J. R, & Sirigu, A. The involvement of the orbitofrontal cortex in the experience of regret. *Science* (2004). , 1167-1170.
- [99] Ursu, S, & Carter, C. S. Outcome representations, counterfactual comparisons and the human orbitofrontal cortex: implications for neuroimaging studies of decision-making. *Cognitive brain research* (2005).
- [100] Hayden, B. Y, Pearson, J. M, & Platt, M. L. Fictive reward signals in the anterior cingulate cortex. *Science* (2009). , 324, 948-950.
- [101] Duvernoy, H. M. *The Human Hippocampus*. Third Ed, Springer Verlag, Berlin, Heidelberg, (2005).
- [102] Jacobs, M. S, Mc Farland, W. L, & Morgane, P. J. The anatomy of the brain of the bottlenose dolphin (*Tursiops truncatus*). Rhinic lobe (rhinencephalon): the archicortex. *Brain Res Bull* (1979). Suppl 1,, 1-108.
- [103] Teyler, T. J, Vardaris, R. M, Lewis, D, & Rawitch, A. B. Gonadal steroid: effects of excitability of hippocampal pyramidal cells. *Science* (1980). , 209, 1017-1019.
- [104] Herman, J. P. Schäfer MKH, Young EA, Thompson R, Douglas J, Akil H, Watson SJ. Evidence for hippocampal regulation of neuroendocrine neurons of the hypothalamo-pituitary-adrenocortical axis. *J Neurosci* (1989). , 9, 3072-3082.
- [105] Diamond, D. M, Fleshner, M, Ingersoll, N, & Rose, G. M. Psychological stress impairs spatial working memory: relevance to electrophysiological studies of hippocampal function. *Behav. Neurosci* (1996). , 110, 661-672.
- [106] Phelps, E. A. Le Doux JE. Contributions of the amygdala to emotion processing from animal models to human behavior. *Neuron* (2005). , 48, 175-187.

- [107] Laurente De No R. The structure of the cerebral cortex. In J.F. Fulton (ed.). *Physiology of the nervous system*. Ed.3. Oxford Univ. Press, New York, (1949). , 288-330.
- [108] Roberts, A. C, Robbins, T. W, & Weiskrantz, L. *The Prefrontal Cortex Executive and Cognitive Functions*. Oxford University Press, New York, (1998).
- [109] Morecraft, R. J, & Yeterian, E. Prefrontal cortex. *Enciclopedia of Human Brain* (2002). , 4, 11-26.
- [110] Miller, B. L, & Cummings, J. L. *The Human Frontal Lobe. Functions and Disorders*. Second Edition. The Guilford Press. New York, London, (2007).
- [111] Damasio, A. R. *Descartes' error: Emotion, reason, and the human brain*. New York, Putnam, (1994).
- [112] Danaila, L, & Golu, M. *Handbook of Neuropsychology, (in Romanian)* Editura Medicală București, (2006)., 2, 15-74., 2
- [113] Duncan, J, & Emslie, H. Williams. Intelligence and the frontal lobe: the organization of goal-directed behavior. *Cogn Psychol* (1996). , 30, 257-303.
- [114] Gerstmann, J. Fingeragnosie: eine umschriebene Störung der Orientierung am eigenen Körper. *Wien Klin Wschr* (1924). , 37, 1010-1012.
- [115] Critchley, M. *The Parietal Lobes*. London, (1953).
- [116] Adams, R. D, Victor, M, & Ropper, A. H. *Principles of Neurology*. Sixth Edition. McGraw-Hill, New York, St Louis, San Francisco, (1997). , 454-459.
- [117] Bradley, W. G, Daroff, R. B, & Fenichel, G. M. Marsden CD (eds), *Neurology in Clinical Practice. Principles of Diagnosis and Management*. 1, 703-706.
- [118] Buchtel, H. A. Temporal Lobes. In: VS Ramachandran (ed.), *Encyclopedia of the Human Brain*. Academic Press, Amsterdam, Boston, London, (2002).,4, 569-574., 4
- [119] Danaila, L, & Craciun, E. *Neuropsychology (in Romanian)*, Ed. Renaissance, București, (2008).
- [120] Fenton, G. W. Psychiatric Disorders of Epilepsy: Classification and Phenomenology. In: EH Reynolds and MR Trimble, *Epilepsy and Psychiatry*, Churchill Livingstone, Edinburgh, (1981).
- [121] Purves, D, Augustine, G. J, & Fitzpatrick, D. Central visual pathways. In: D Purves, Augustine GJ, Fitzpatrick D et al., (eds), *Neuroscience*. Third Edition. Chapter 11, Sinauer Associates Inc Publishers. Sunderland, Massachusetts USA, (2004). , 259-282.
- [122] Felleman, D. J, & Van Essen, D. C. Distributed hierarchical processing in the primate cerebral cortex. *Cerebral Cortex* (1991). , 1, 1-47.
- [123] Rees, G, Kreiman, G, & Koch, C. Natural correlates of consciousness in human. *Nat Rev Neurosci* (2002). , 3, 261-270.

- [124] Tong, F, & Pearson, P. Vision. In: BJ Bass and MN Gage (eds.), *Cognition, Brain and Consciousness*. Amsterdam, Boston, Heidelberg. Academic Press, (2007). , 149-182.
- [125] Cramer, J. A, Perrine, K, & Devinsky, O. Development and cross-cultural translation of a 31-item quality of life in epilepsy inventory. *Epilepsia* (1998). , 39, 81-88.
- [126] Collins, R. C. Cerebral Cortex. In: AL Pearlman and RC Collins (eds.), *Neurobiology of disease*, New York, Oxford University Press, (1990).
- [127] Franckowiak RSJ, Friston KJ, Frith CD, Dolan RJ, Mazziota JC. *Human brain function*. San Diego, Academic Press, (1997).
- [128] Tononi, G, & Laureys, S. The neurology of consciousness: an overview. In: S Laureys and G Tononi (eds), *The Neurology of Consciousness: Cognitive Neuroscience and Neuropathology*. Academic Press, Amsterdam, Boston, Heidelberg, (2009). , 375-412.
- [129] Koziol, L. F, & Budding, D. E. *Subcortical structures and cognition*. Springer, New York, (2009). , 125-165.
- [130] Kalashnikova, L. A, Zueva, Y. V, Pugacheva, O. V, & Korsakova, N. K. Cognitive impairments in cerebellar infarcts. *Neuroscience and Behavior Physiology* (2005). 35, 773-779.
- [131] Hu, D, Shen, H, & Zhou, Z. Functional asymmetry in the cerebellum: a brief review, *Cerebellum* (2008).
- [132] Guzzetta, F, Mercuri, E, & Spano, M. Congenital lesions of cerebellum. In: A Benton, E De Renzi, D Riva (eds). *Localization of brain lesions and development functions*. London, John Libbey, (2000). , 147-152.
- [133] Schmahmann, J. D. Disorders of the cerebellum. Ataxia, dysmetria of thought, and the cerebellar cognitive affective syndrome. *Journal of Neuropsychiatry and Clinical Neurosciences* (2004). , 16, 367-378.
- [134] Hokkanen, L. S, Kauranen, V, Roine, R. O, Salonen, O, & Kotila, M. Subtle cognitive deficits after cerebellar infarcts. *Eur J Neurol* (2006). , 13, 161-170.
- [135] Riva, D, & Giorgi, C. The contribution of the cerebellum to mental and social functions in developmental age. *Fiziol Cheloveka* (2000). , 26, 27-31.
- [136] Steinlin, M, Imfeld, S, & Zulauf, P. Neuropsychological long-term sequelae after posterior fossa tumour resection during childhood. *Brain* (2003). , 126, 1998-2008.
- [137] Riva, D, & Giorgi, C. The cerebellum contributes to higher functions during development: Evidence from series of children surgically treated for posterior fossa tumours. *Brain* (2000). , 123, 1051-1061.
- [138] Gordon, N. The cerebellum and cognition. *European Journal of Pediatric Neurology* (2007). , 11, 232-234.

- [139] Torriero, S, Oliveri, M, & Koch, G. Interference of left and right cerebellar γ TMS with procedural learning. *Journal of Cognitive Neuroscience* (2004). , 16, 1605-1611.
- [140] Torriero, S, Oliveri, M, & Koch, G. Cortical networks of procedural learning: Evidence from cerebellar damage. *Neuropsychologia* (2007). , 45, 1208-1214.
- [141] Leggio, M. G, Todesco, A. M, & Chiricozzi, F. R. Cognitive sequencing impairment in patients with focal or atrophic cerebellar damage. *Brain* (2008). , 131, 1332-1343.
- [142] Edelman, G. M, & Tononi, G. *An universe of consciousness*. New York: Basic Books, (2000).
- [143] Rizzolatti, G, Foggassi, L, & Gallese, V. Neurophysiological mechanisms underlying the understanding and imitation of action. *Nature Review: Neuroscience* (2001). , 2, 661-670.
- [144] Rizzolatti, G, & Craighero, L. The mirror-neurons system. *Annual review of Neuroscience* (2004). , 27, 169-192.