

We are IntechOpen, the world's leading publisher of Open Access books Built by scientists, for scientists

4,800

Open access books available

122,000

International authors and editors

135M

Downloads

Our authors are among the

154

Countries delivered to

TOP 1%

most cited scientists

12.2%

Contributors from top 500 universities



WEB OF SCIENCE™

Selection of our books indexed in the Book Citation Index
in Web of Science™ Core Collection (BKCI)

Interested in publishing with us?
Contact book.department@intechopen.com

Numbers displayed above are based on latest data collected.

For more information visit www.intechopen.com



The Skin and Viral Liver Disease

Mastrolonardo M.

Additional information is available at the end of the chapter

<http://dx.doi.org/10.5772/56140>

1. Introduction

It is undisputable that a multifaceted biological interplay exists between the skin and the liver.

The integument can firstly be viewed as a 'gate' through which hepatotropic viruses may access the blood stream. In this respect, one may think of the huge number of B and C virus hepatitis that must have been acquired in a more or less distant past due to either intravenous drug consumption, use of contaminated equipment in beauty and health care-related procedures, or even dermal tattooing. Moreover, one may consider that some cases of herpes simplex virus hepatitis have been reported in the literature which are not unlikely ascribable to systemic dissemination from primary muco-cutaneous lesional *foci*.

Yet, the skin may also be viewed as a 'mirror' capable of projecting on the body surface more or less specific *echoes* of disease conditions involving the liver. A recent review of the issue by Hazin and coworkers [1] is introduced by the following simple but just as brilliant statement: "Dysfunction in the body's second largest organ, the liver, often yields changes in the body's largest organ, the skin". The most trivial paradigm sustaining such an obvious assumption is *jaundice* when it is sustained by primary failure of hepatocytes to perform one of their main functions, that is to conjugate bilirubin into a secretable form. However, further and less obvious paradigms, such as cutaneous manifestations of mixed cryoglobulinemia in HCV infected patients, will also be discussed.

Since the issue that will be specifically reviewed in this chapter is all the many possible links between skin and virus-induced liver disease, this introductory framework is to be completed by mentioning the not unusual circumstances in which neither the skin nor the liver disease in itself, but treatments undertaken to cure a disease of one of the two organs may have undesired consequences on the other one. This seems obviously true thinking of some double-edged risky circumstances in which either worsening of psoriasis in patients undergoing

interferon plus ribavirin therapy, or reactivation of latent viral infections under immunosuppressive treatment of the skin disease, is observed.

2. The skin as a 'gate' for hepatotropic virus infections

2.1. Tattooing as risk factor for viral liver disease

Tattooing has been practiced for many centuries worldwide, and is a well-established risk factor for transfusion-transmitted diseases, including HBV and HCV [2]. A recent meta-analysis highlights that the above menace is still currently far from being remote, especially in certain at-risk categories (such as prison inmates and subjects undergoing home-made procedures without proper aseptic techniques) [3].

2.2. Rare forms of viral hepatitis caused by agents which usually involve only the skin

After primary infection, in the absence of any severe immune deficiency condition, *herpesviruses* like Herpes Simplex Viruses (HSV) type 1 or 2, and Varicella-Zoster virus (VZV) establish latency by remaining dormant in the dorsal root nerve ganglia. Viral reactivation results in cutaneous or muco-cutaneous manifestations that usually run an overall benign course (Fig 1, 2, 3), with an inflamed vesicular and/or bullous rash which is customarily restricted to a limited district of the body surface. Though in some patients rather impressive clinical *scenarios* may be observed (Fig. 4, 5 and 6), herpetic lesions tend to heal within few weeks, with no or only minor scarring and dyschromic sequelae. As for VZV, post-herpetic neuralgia develops quite rarely, and is the worst occurrence reported after skin manifestations have faded.

In otherwise healthy subjects, disseminated herpes simplex virus hepatitis have been reported very exceptionally. In one case described by Miyazaki and coworkers in 1991 [4], the possibility that patient's mucosal herpetic lesions might have behaved as a 'gate' for a large virus *inoculum* leading to visceral involvement either directly or after having overwhelmed local immune defenses has been considered.

By contrast, HSV and VZV hepatitis are possible in patients whose cell-mediated immunity is severely impaired, for instance in malignancy or organ transplanted patients [5]. In these cases, the skin rash may either be absent, coincide with, or supervene after visceral involvement. When cutaneous lesions are present, severity of skin involvement is often significantly increased compared to standard clinical pictures both in terms of number of lesions, diffusion over the body surface, and severity of tissue impairment. Notably, in a recent review of 74 cases of herpes simplex hepatitis [6], Sharma and Mosunjac highlighted that proper diagnosis was delayed in more than two-third of cases, despite a herpetic muco-cutaneous involvement was present in at least 70% of patients. Conversely, the occurrence of an unexplained impairment of liver function tests in an immunocompromised patient exhibiting skin herpetic lesions should always arouse a high degree of suspicion of visceral dissemination [7]. Fulminating herpetic hepatitis is a life-threatening occurrence, but it can be treated effectively if therapy is

started early. Inclusion of herpes virus in the differential diagnosis procedures is thus mandatory.

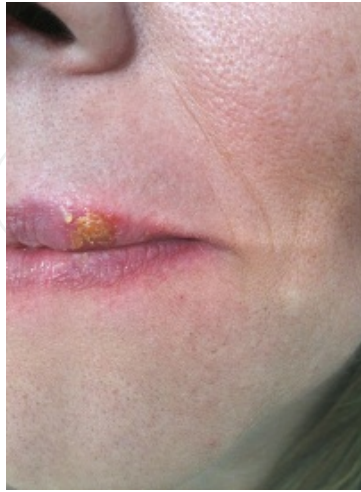

Figure 1. Herpes simplex labialis

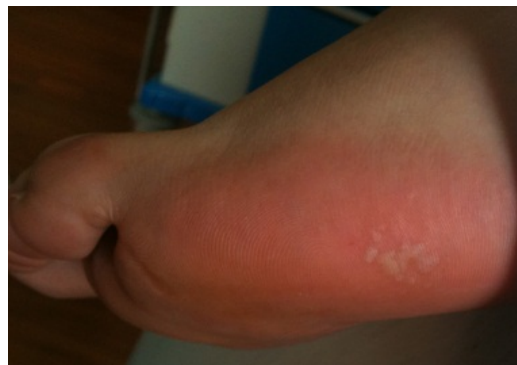

Figure 2. Herpes simplex on the foot: an unusual localization

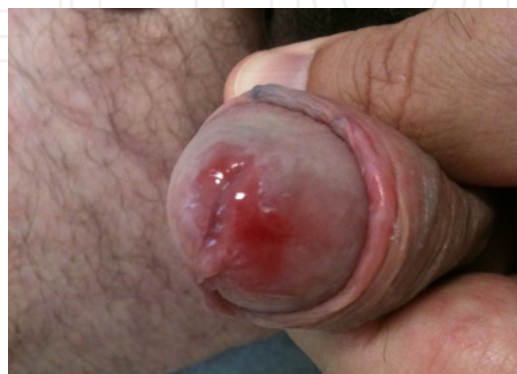

Figure 3. Herpes simplex proenitalis

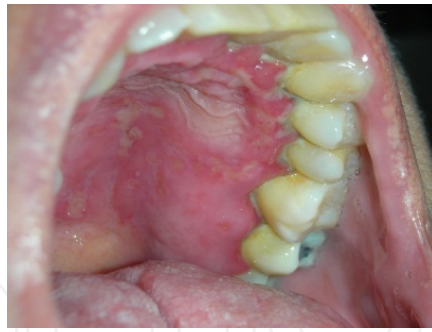

Figure 4. Severe herpetic gingivostomatitis

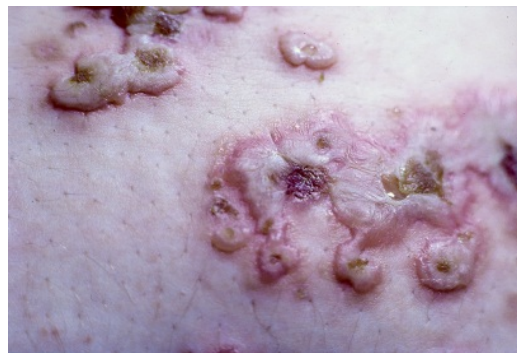

Figure 5. Severe cutaneous herpes simplex with extensive vesico-bullous elements

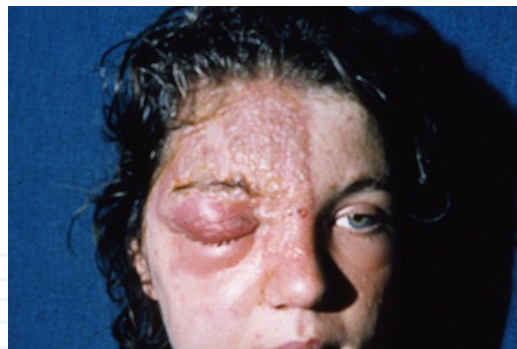

Figure 6. Severe, necrotic and hemorrhagic herpes zoster

3. Skin manifestations occurring in viral liver disease

3.1. Skin manifestations related to HCV

Cutaneous manifestations of *acute* infection are sporadic and show no substantial specificity, ranging from urticaria, erythema multiforme, leukocytoclastic vasculitis to erythema nodo-

sum. On the contrary, there exists a wide panel of skin conditions linked, to a varying degree, with *chronic* HCV infection [8, 9]. The occurrence of skin disorders of any type has been in fact reported in up to 17% of HCV patients (Table 1) [10]. In this context, the association with the 'big three' i.e. mixed cryoglobulinemic vasculitis, porphyria cutanea tarda and lichen planus show the highest robustness on both biological and epidemiological ground. On the other hand, the clinical alliance between HCV and a broad list of other skin conditions has not yet received sufficient support [9, 11]. In this context, anecdotal reports have mostly been made in the literature of associations with pityriasis rubra pilaris [12], sarcoidosis [13], vitiligo [8], cholestatic and non-cholestatic pruritus [14, 15], prurigo nodularis [16], cutaneous polyarteritis nodosa [17], pyoderma gangrenosum [18], subacute cutaneous lupus erythematosus [19], primary localized cutaneous amyloidosis [20], pigmented purpuric dermatosis [21], actinic porokeratosis [22], pityriasis lichenoides [23], generalized granuloma annulare [24], disseminated Kaposi's sarcoma [25] and necrolytic acral erythema [26]. Of note, in most of the above circumstances it seems quite difficult to sift consistently the direct contribution of HCV infection *per se* from that attributable to antiviral treatment. A data set which is therefore of the outmost relevance in this regard is that provided by an U.S. nationwide hospital-based case-control study in which El-Serag and coworkers [8] surveyed comorbidity in as many as 34,204 HCV-infected subjects, the vast majority of whom (notably, >95%) were naïve to antiviral therapy. In this study, the aforementioned strong association with cryoglobulinemia, porphyria cutanea tarda and lichen planus found an authoritative confirmation. However, a statistically significant link was also observed with vitiligo, but this finding did not receive further comparable support from the rest of the literature, and remains rather inexplicable.

3.1.1. Mixed cryoglobulinemic vasculitis

Cryoglobulins are a family of anomalous proteins which tend to precipitate at low temperatures (<37°C), such as those currently found in the extremities (namely hands, feet, ear and nose). The prototype of cryoglobulinaemic diseases in HCV infected patients is 'mixed cryoglobulinemia' (MC). Of note, up to more than a half of HCV-infected patients show circulating cryoglobulins, and rates of 30 to 100% of HCV positive serologies have been reported in carriers of circulating cryoglobulins, with an unexplained predominance in the Mediterranean basin.

In MC tissue damage results from deposition of immune complexes containing rheumatoid factor, polyclonal IgG, complement and HCV RNA on endothelial surfaces of small- to medium-sized vessels, which in turn leads to vascular inflammation. The prevalent histological pattern of MC is neutrophilic 'leukocytoclastic' vasculitis; however, 'necrotizing' vasculitis, with intimal fibrinoid necrosis and infiltration of the entire vessel wall and perivascular space, may also be observed [27].

The skin is one of the most commonly affected organs, along with kidneys and peripheral nerves. Thus, the dermatologist may play a helpful role in early detection of previously unrecognized HCV infections. In fact, the appearance of cutaneous lesions on extremities, particularly in cooler weather, must always raise clinical suspicion. The spectrum of skin involvement in MC ranges widely from 'palpable purpura' (which is the absolutely prevalent

Disorders with an obvious linkage with HCV

- mixed cryoglobulinemic vasculitis
- porphyria cutanea tarda
- lichen planus

Other skin diseases described in association with HCV

- pityriasis rubra pilaris
 - sarcoidosis
 - vitiligo
 - cholestatic and non-cholestatic pruritus
 - prurigo nodularis
 - cutaneous polyarteritis nodosa
 - pyoderma gangrenosum
 - subacute cutaneous lupus erythematosus
 - primary localized cutaneous amyloidosis
 - pigmented purpuric dermatosis
 - actinic porokeratosis
 - pityriasis lichenoides
 - generalized granuloma annulare
 - disseminated Kaposi's sarcoma
 - necrolytic acral erythema
-

Table 1. Skin manifestations in hepatitis C infection

clinical scenario) [9] to urticarial vasculitis, necrotizing vasculitis, isolated necrotic ulcers, acral ischemias, acrocyanosis, and livedo reticularis (Figure 7 and 8). Of note, even in cases characterized by the highest clinical severity, the skin behaves very often like a sort of 'emuntory system', with poor or absent signs of internal organ involvement. Systemic vasculitis, involving the kidneys, the heart, the central nervous system and other viscera, is in fact unusual. First-line treatment of MC diseases consists of associated pegylated INF- α and ribavirin. In patients who are intolerant to antivirals, or those with severe systemic disease, or those who have failed to reach SVR after antiviral therapy, symptomatic treatment with plasmapheresis, steroids or rituximab should be considered [27].

3.1.2. *Porphyria cutanea tarda*

Porphyria cutanea tarda (PCT) is related to a deficient activity of the heme synthetic enzyme uroporphyrinogen decarboxylase (UROD), which may in turn be sustained by either UROD gene mutations or acquired liver insufficiency [28]. A strong association has been reported between acquired PCT and HCV infection. HCV prevalence in PCT sufferers is significantly

higher than that reported in the general population. Prevalence rates range from 17 to 65%, the latter having been reported in Southern Europe [29, 30]. However, HCV alone is not likely to cause the disease, but it is thought to be a strong trigger for the development of deranged porphyrin metabolism in subjects with other known predisposing factors (such as, alcohol abuse or iron overload) [31].

Laboratory diagnosis is based on detection of increased levels of uro-carboxyl porphyrins and heptacarboxyporphyrins in the urine, and on the presence of isocoproporphyrin in the feces. Due to its porphyrin content, the urine of PCT patients is discoloured (chiefly after air and light exposure), while all 'iron tests' are negative. On clinical ground, diagnosis derives from an array of dermatological findings, as follows: vesicular or vesico-bullous swellings on skin sites subjected to even minor actinic and/or mechanic traumas; ensuing eroded areas that take weeks or months to heal; scarred and/or melasma-like hyperpigmented patches; keratin-filled milial cysts; lilac erythematous rash of periorbital areas; hypertrichosis on the lateral aspects of the face; chloracne; skin dystrophic calcifications with ulceration; alopecia; and onycholysis.

3.1.3. *Lichen planus*

Lichen planus (LP) [32] is an inflammatory immune mediated disease of the skin and/or mucous membranes most commonly affecting middle-aged adults of both sexes, the etiology of which has not yet been fully clarified. The occurrence of the disease in the general population is rare. Prevalence rates of 0.1 to 0.3 have been calculated for cutaneous LP, and of 1.15 to 2.3 for mucous (oral) LP. However, the persisting lack of aim-oriented studies based on standardized methods and criteria results in some uncertainty [33].

Clinically, cutaneous LP is characterized by flat, polygonal, lilac red papules which may remain isolated, or merge into larger plaques (Figure 9 and 10). The rash has an unpredictable duration, from few weeks to several months or years. Lesions may resolve with atrophy, scarring or brownish hyperpigmentation. The flexor aspects of the limbs, the upper back, and the lumbar region are frequently involved, but the disease can spread over the entire body surface. Hair and nails may also be affected. Severe, recalcitrant itch is very common. Mucous LP chiefly affects the mouth and, less frequently, genitalia, conjunctiva, and esophagus. The mucosal lesions consist of erosive erythematous patches (Figure 11), or horny micro-papules arranged in a reticular pattern recalling a lace network (or a sprinkle of lime) (Figures 12 and 13), or a combination of both (Figure 14). The erosive variant is usually accompanied by intense burning sensations.

LP histology is the prototype of a morphological scenario that has traditionally been referred to as "lichenoid tissue reaction/interface dermatitis", in which a band-like mononuclear cell inflammatory infiltrate in the papillary dermis obscuring the dermal-epidermal junction (DEJ) is seen, coupled with more or less pronounced epithelial changes, as follows: hydropic/vacuolar degeneration in the basal cell layer, scanty 'ghost' epithelial cells ('colloid bodies'), spongiosis and clefting at the DEJ ('Max Joseph spaces'), irregular acanthosis and thickening of the granular layer, dense hyperkeratosis, disappearance of intra-epidermal melanocytes along with melanin 'leakage' into the dermis (*pigmentary incontinence*) (Figure 15).

The pathogenesis of LP has not yet been fully elucidated, however the disease is universally alleged to be an autoimmune disease. The prominence of certain HLA haplotypes (such as, HLA-DR1), or detection of cytokine gene polymorphisms in some case series [34], support a genetic predisposition to the disease. The basal epidermis injury observed in LP is attributed to cytotoxic T lymphocytes, which in fact predominate into the infiltrate along with minor subpopulations of macrophages and dendritic cells. In this context, a significant role of plasmacytoid dendritic cells has been also recognized. In fact, these cellular effectors are viewed as the driving force to the end-stage T cell-mediated epidermal damage, in that they would be able to give rise to an inflammatory type I interferon signaling pathway which, in turn, would amplify and maintain cytotoxic T cell attack to keratinocytes [35]. Cross-reactivity between endogenous and environmental antigens is widely suspected, but the exact nature of the triggering antigen is still obscure. Among the putative exogenous factors involved in LP, one of the most outstanding candidates appears to be HCV. An ample body of biological evidences supporting this view exists in the literature, and has been reviewed in recent years [36, 37]. However, the conclusive proof of the causal linkage between HCV and LP is still lacking. These circumstances have recently led Baccaglini and coworkers [37] to launch somewhat provocatively the subversive hypothesis of a fake association via a 'third factor' consisting of a still unidentified *confounder*.

However, at least on epidemiological grounds, the existence of a 'two-way' association between LP and HCV infection seems currently beyond question worldwide. On these regard, two well-designed meta-analyses have been recently carried out showing that LP sufferers have an odds ratio of being HCV seropositive up to 5.4 times higher compared to controls, and that the risk of having LP is up to 4.47 times higher in HCV patients than in seronegative controls [38, 39]. On the basis of these circumstances, screening for anti-HCV antibodies is substantially advisable in patients with LP, especially in countries with the highest seroprevalence rates. In this regard, it has been suggested that routine HCV testing would be cost-effective in geographical districts in which HCV prevalence is 7% or more [40]. Yet, in the absence of standardized criteria and guidelines, individual case-by-case screening strategies are more suitably recommended [37].

This section is to be concluded by underscoring that *true* cases of idiopathic LP need sometimes to be differentiated from so-called *lichenoid eruptions* (LE), which somehow resemble LP on both clinical and histological grounds [41]. LE are often caused by (and develop at sites of) contact with dental restorative amalgams or stomatological devices, due to their content of methacrylic acid esthers, nickel, mercury, copper and gold [32]. However, LE may be also induced by a huge array of systemic drugs whose number is in steady increase [42], ranging from angiotensin-converting enzyme inhibitors to non-steroidal anti-inflammatory drugs, antimalarials and proton pump inhibitors. The reader should be aware that the list includes the agents employed for treatment HCV infection, interferon and ribavirin [43]. In such occurrences, LE may either be exanthematic, or stay confined to oral mucosa, or just involve the site of interferon injection [43].

3.2. Skin manifestations related To HBV

Both range and frequency of extrahepatic manifestations in patients with HBV infection are considerably lower compared with those observed in HCV infected subjects [44, 45]. A French multicenter, retrospective, cross-sectional study of 190 patients with chronic hepatitis B has rated the overall incidence of clinical and biologic extrahepatic manifestations to be 16% and 15%, respectively [46]. As more specifically regards the skin, vasculitis, psoriasis and pruritus were found to occur in only 1% of cases each. Of note, in striking contrast with HCV populations, in HBV patients cryoglobulinemia and related disease manifestations have been reported in only 2% of cases. Many clinical and laboratory observations have long cast significant doubts on the actual biological relevance of this association. On this regard, literature yields rates up to 15% for cryoglobulin detection in HBV patients, although no signs or symptoms of related vasculitis are observed in the great majority of cases [47].

Both cutaneous and non-cutaneous extrahepatic manifestations of HBV infection have been largely attributed to deposition of circulating immune complexes (IC) containing HBs and/or possibly HBe antigens. Alternatively, induction of local IC formation by viral antigens, interaction between tissue antigens and virus-induced autoantibodies, or direct tissue damage by viral replication have also been invoked. However, this issue remains highly controversial [45, 48, 49].

Cutaneous manifestations of HBV infection (Table 2) are observed both in the incubation, prodromal phase and in chronic state of disease. In the former, a clinical scenario in which intermingled signs of either a mild 'flu-like' or a more serious 'serum sickness-like' syndrome have been described. In this phase, up to 30% of the patients may have fever, weakness, headaches, arthralgias/myalgias, and glomerulonephritis which not infrequently develop in association with varied dermatological manifestations, such as non-specific (toxic) erythema, urticaria, angio-oedema, erythema multiforme, erythema nodosum, Henoch-Schonlein (rheumatoid) purpura, or palpable purpura [44, 45, 50-53]. Other extrahepatic manifestations of HBV infection in which skin involvement is either a prominent feature or an ancillary finding include Gianotti-Crosti syndrome and polyarteritis nodosa, respectively.

3.2.1. *Gianotti-crosti syndrome*

Gianotti-Crosti syndrome (GCS) [54], also termed 'papular acrodermatitis of childhood', is a peculiar, self-limited and largely asymptomatic skin eruption featuring almost monomorphic papular or papulovesicular lesions located mainly on the face and distal aspects of the four limbs (Figure 16). Mucosal involvement is never described. Histology is noncontributory, with upper dermis perivascular round cellular infiltrates and endothelial swelling as the prevailing findings. Children aged from a few months to 15 years (with a peak between 1 and 6 years) are mostly involved, but adults (of note, only females) may be also affected. Spontaneous recovery usually occurs within 25 to 45 days. Systemic findings, which are observed rarely, include malaise, fever or diarrhea. Limited lymphadenopathy, splenomegaly and hepatomegaly are sometimes detected. When present, hepatitis is usually anicteric. Originally described as in strict conjunction with sole HBV infection, GCS has been subsequently linked to an array of infectious agents, including other viruses (such as, HAV, CMV and EBV) and

bacteria (such as, *Borrelia burgdorferi* and β -hemolytic streptococci). Neither viral bodies nor viral antigens have ever been demonstrated in the context of skin lesions, and the pathogenesis of GCS remains largely unclear. Current views on the issue span from a role of immune complex deposition to occurrence of virus-related delayed hypersensitivity reactions. Furthermore, an association between immunization and GCS has long been outlined, with anti-HBV and anti-HAV vaccinations being included in the list of triggering factors [54-57]. Remarkably, it has been proposed that occurrence of GCS after the first vaccine administration does not contraindicate completion of the immunization protocol, as GCS does not recur after the subsequent boosting injections [55]. Finally, in addition to that with GCS, an association has also been reported between HBV infection and a much rarer, but equally peculiar skin eruption involving the extremities, i.e. so-called 'papular-purpuric gloves and socks syndrome', in which a triggering role of HBV (along with other infections such as measles, parvovirus B19, coxsackie B6 and cytomegalovirus) has been assumed [58].

3.2.2. *Polyarteritis nodosa*

Recognition of a strong linkage between HBV and polyarteritis nodosa (PAN) dates back to the 1970s. Rates of prevalence of positive HBV serologies have been estimated up to 50% among PAN patients. However, these figures have decreased significantly over the last four decades, and are currently less than 5% [45]. A major role in this respect must have been played by improved blood transfusion safety measures, other general hygiene precautions and extensive vaccination campaigns. The pathogenesis has largely been attributed to deposition of immune complexes containing HBsAg. Of note, unlike other forms of PAN, in HBV-related PAN serum antineutrophilic cytoplasmic antibodies (ANCA) are only exceptionally detected. Histologically, PAN is characterized by transmural, usually segmental, necrotizing infiltration of medium-to-small vessels resulting in ischaemia, infarcts and haemorrhage, which ultimately lead to end-organ damage. If untreated, the course of PAN is often protracted, and symptoms and signs of multi-organ involvement are generally observed. Organs more commonly affected are kidneys, heart, gut and peripheral nerves. Cutaneous PAN has also been reported in 10 to 50% of cases, depending on the case series examined. Livedo reticularis and painful subcutaneous nodules (usually along the arteries of the lower limbs) are commonly described. Nodules ulceration and distal gangrene are frequent findings as well [44, 59, 60].

Further anecdotal reports of skin disorders observed in conjunction with HBV infection include acanthosis nigricans [61] and generalized granuloma annulare [62]. Finally, the association with lichen planus (LP), which is now undisputed in HCV infection, is instead highly controversial in HBV carriers. A number of earlier studies have provided some support for this view, but such biological alliance has more recently received repeated confutations [63, 64] and is currently considered unfounded.

3.2.3. *Skin unfavorable effects of HBV immunization*

Hepatitis B vaccination may also be hazardous for the skin. In this respect, the following dermatological undesired manifestations have been reported: erythema nodosum [65], generalized granuloma annulare [66], Gianotti-Crosti syndrome [54, 56, 67], cutaneous

-
- urticaria
 - angio-oedema
 - non-specific (toxic) erythema
 - erythema multiforme commonly observed in the prodromal phase of infection
 - erythema nodosum
 - Henoch-Schonlein purpura
 - palpable purpura
 - Gianotti-Crosti syndrome ('papular acrodermatitis of childhood')
 - polyarteritis nodosa
 - acanthosis nigricans
 - generalized granuloma annulare
 - lichen planus (highly controversial)
-

Table 2. Skin manifestations in hepatitis B infection

polyarteritis nodosa [68] and pityriasis rosea-like rash [68], lichen planus [69], lichenoid and pseudolymphomatous reactions confined to site of injection [70], and generalized pseudolymphomatous reactions [71].

3.3. Skin manifestations related to HAV

Apart from the 'paradigm' of jaundice, HAV infection is very occasionally linked to significant cutaneous side-events. Few reports have been made of urticaria, purpura or other exanthemas [72]. A case of Henoch-Schönlein purpura has been described after immunization [73].

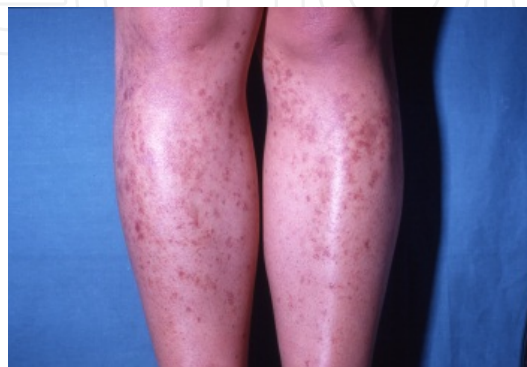

Figure 7. Palpable purpura

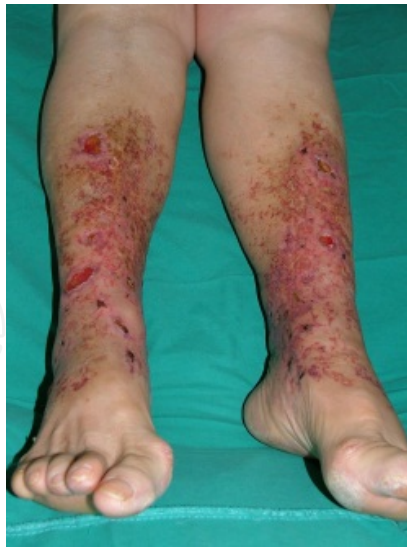

Figure 8. Nodular, necrotic vasculitis

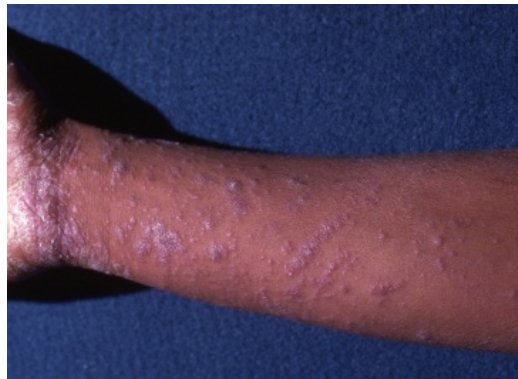


Figure 9. Cutaneous lichen planus (LP): flat, polygonal, lilac red-coloured pruritic papules (Courtesy of Professor M. Lomuto, Bari, Italy)

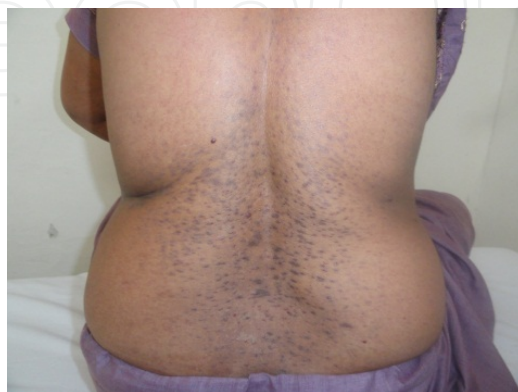

Figure 10. Cutaneous LP (Courtesy of Professor A. J. Kanwar, Chandigarh, India)

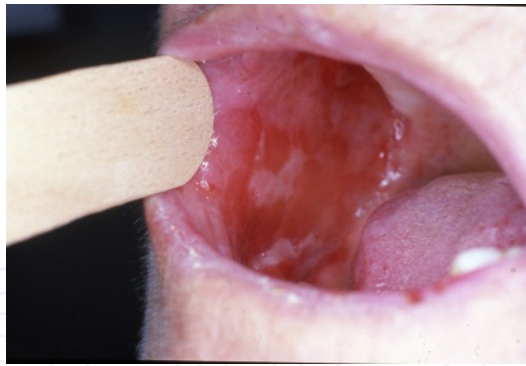


Figure 11. Mucous LP: erosive variant (Courtesy of Professor M. Lomuto, Bari, Italy)

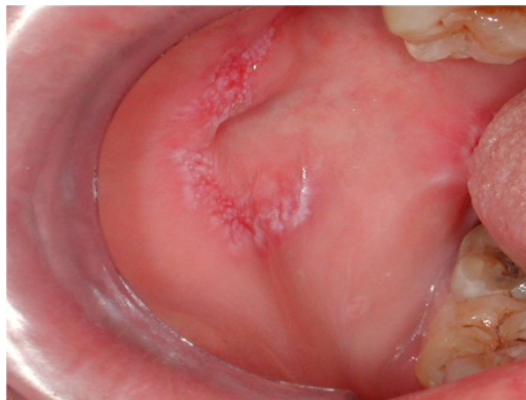


Figure 12. Mucous LP: papular, hyperkeratotic variant ('lace network' pattern) (Courtesy of Professor M. Lo Muzio, Foggia, Italy)

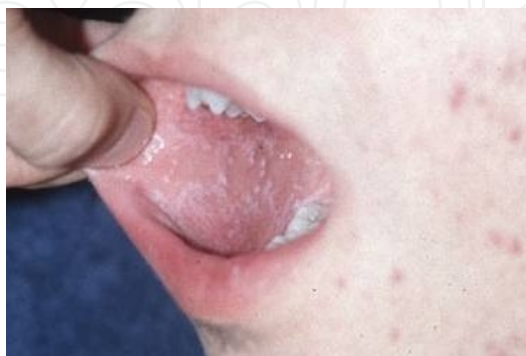

Figure 13. Mucous LP: papular, hyperkeratotic variant ('sprinkle of lime' pattern) (Courtesy of Professor E. Bonifazi, Bari, Italy)

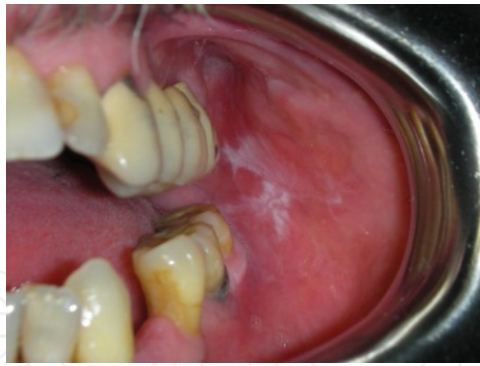

Figure 14. Mucous LP: mixed type, with a combination of erosive and hyperkeratotic lesions (Courtesy of Professor M. Lo Muzio, Foggia, Italy)

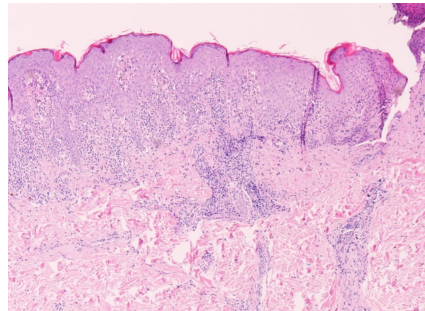


Figure 15. Histological picture of LP: a fully developed prototype of so-called “lichenoid tissue reaction/interface dermatitis” (Courtesy of Professor P. Bufo, Foggia, Italy)

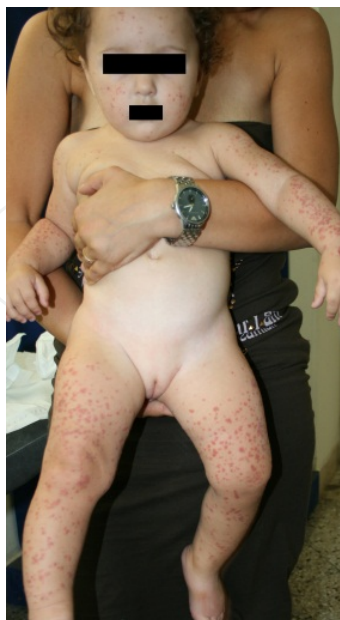

Figure 16. Gianotti-Crosti syndrome ('papular acrodermatitis of childhood') (Courtesy of Professor E. Bonifazi, Bari, Italy)

4. Skin manifestations associated with treatment of viral liver disease

4.1. Skin adverse effects related to 'standard of care' treatment of chronic HCV infection

The 'fingerprint detector' effect

The combination of pegylated interferon α (PEG-INF) and ribavirin (RBV), which is the current 'standard of care' (SOC) in the management of chronic HCV infection, has significantly improved the treatment outcome. Due to the side effect profile of both drugs, a considerable number of chronic hepatitis C patients are ineligible for PEG-INF/RBV-based treatment because of medical contraindications. Moreover, vast rates of patients are unable to tolerate antiviral therapy, and account for nearly 10% of premature treatment discontinuations [74, 75].

More specifically regarding skin adverse events (AEs), in a recent large-scale prospective study of 2871 Japanese patients, dermatologic undesired manifestations were the third most common reason for therapy withdrawal [75]. INF alone may give rise to a wide variety of cutaneous AEs, the frequency of which has been estimated from 13 to 23%, and the association with RBV has led to an increased incidence of skin AEs compared to those observed during INF monotherapy era [75-80]. Cutaneous AEs related to SOC treatment may be divided into three major groups: local reactions occurring at INF injection sites (Figure 17); non-local or generalized reactions; and signs of hypothyroidism caused by INF-induced autoimmune thyroiditis (Table 3). Local reactions are more consistently ascribable to the action of INF alone. By contrast, not local or generalized manifestations have to be linked to both agents, considering that the modes of action of INF and RBV are rather intermingled and their individual contribution seem thus quite undistinguishable. As shown in the table, a long array of cutaneous manifestations have been observed. Some reports are almost anecdotal, while the *triad* pruritus, skin xerosis and eczematous lesions are the principal hallmark of 'hepatitis C treatment-associated dermatitis' according to an in-depth review recently carried out by Lübke and coworkers [81]. *Xerosis* is customarily spread over the entire body surface. *Pruritus* is also generalized, and is not rarely refractory to standard antihistamine agents. *Eczema*, which mainly affects the extensor aspects of limbs and sites exposed to friction (Figure 18 and 19), has been reported to sometimes take the appearance of so-called 'nummular' (discoid) eczema (Figure 20 and 21 or prurigo nodularis (Figure 22).

As regards 'eczema', an extensive discussion of the vast archipelago of disease conditions which are currently collected under such term in the dermatological literature [82] is beyond the scope of the present textbook. However, a brief digression on the matter will perhaps be useful to the reader. Clinically, along with variable degrees of itching and soreness, eczematous dermatoses display a variety of signs which range from acute to chronic forms as follow: erythema, vesiculation, exudation, excoriation, fissuring, dryness, scaling, hyperkeratosis, papulation and lichenification (Figure 23.A to -C). Accordingly, histological hallmarks vary from epidermal oedema ('spongiosis'), thickening of spinous and horny layers ('acanthosis' and 'hyperkeratosis', respectively) and more or less dense round cell infiltrates in the dermis. The simplest classification framework of eczemas implies division into two forms, i.e. exogenous and endogenous. Exogenous forms (also referred to as 'contact dermatitis') result from direct exposure of the skin surface to toxic agents ('irritant contact dermatitis') or allergens ('allergic

contact dermatitis'). Cell-mediated (not humoral), 'delayed'-type hypersensitivity is involved in the latter. As a counterpart, in the endogenous forms all the other forms of eczema (ranging from atopic eczema to so-called *discoid* or *nummular* eczema) which are not attributable to any recognizable contact offender, and whose pathomechanisms still remain largely obscure are to be included.

Interferon-related injection site (local) reactions

- ill-defined, roundish, pruritic, self-recovering erythematous patches (Figure 17)
- vesico-bullous rashes
- Skin necrosis
- Dermal mucinosis
- Sarcoidosis
- Foreign body granulomatous reaction
- Lichen planus
- Patchy hypermelanosis
- Vasculitis
- Vitiligo
- Alopecia

Non local, or generalized reactions

- Generalized pruritus
- Skin xerosis
- Eczema
- Generalized nummular eczema
- Prurigo-like eruptions
- Meyerson's phenomenon ('halo dermatitis') around melanocytic naevi
- Fixed drug eruption
- Nonspecific erythematous or maculopapular exanthemas
- Nonspecific 'acantholytic dermatitis'
- Grover's disease
- Dry pulpitis and fissured fingers
- Vitiligo
- Sarcoidosis
- Tongue hyperpigmentation
- Psoriasiform drug eruptions
- Psoriasis (triggered or worsened)
- Lichen planus (triggered or worsened) and other lichenoid eruptions

- Cryoglobulinemic vasculitis (worsened)
- Leukocytoclastic vasculitis
- Pyoderma gangrenosum
- Polyarteritis nodosa
- Dermatitis herpetiformis and/or other gluten hypersensitivity states
- Rosacea fulminans
- Systemic lupus erythematosus
- Systemic sclerosis
- Alopecia areata and universalis
- Dystrophic alopecia and diffuse thinning of the hair
- Diffuse or localized hypertrichosis
- Hair curling
- Hair repigmentation
- Eyebrow and eyelash

Skin and hair signs of hypothyroidism caused by INF-induced autoimmune thyroiditis

- diffuse skin hyperkeratotic thickening
- scalp and body hair dryness and coarseness
- diffuse loss of scalp hair
- slow growth, dystrophy and atrophy of nails
- skin pallor
- carotenemia with skin yellowing (more prominently, on the palms, soles, and in the nasolabial folds)
- impaired wound healing
- petechial purpuric patches

References cited in this table are partly compiled from the works of Cacoub and coworkers [78], Mistry and coworkers [77], Lübke and coworkers [81], and Jadali [89].

Table 3. Cutaneous adverse events reported under INF *plus* RBV treatment of patients with chronic HCV infection

The '*fingerprint detector*' effect - According to what has been said above, eczematous manifestations occurring during treatment for HCV infection may be classified as 'endogenous'. This seems appropriate also considering that no data are currently available in the literature concerning possible past history of delayed-type hypersensitivity conditions or present skin reactivity to standard contact allergen series in patients developing eczema under treatment for HCV infection. In this context, it might be hypothesized that the combination of INF and RBV acts as a sort of '*fingerprint detector*' over the skin surface being able to unmask and trigger reactivation of clones of skin-resident T cells that could have been primed at any time in the past via indeterminable antigenic challenges, without ever exceeding the threshold which could have given rise to overt clinical manifestations. Indeed, the skin is the outermost

barrier against a huge number of environmental threats, including chemical and infectious agents. So that the magnitude of immune host defense reactions taking place at any moment in the skin are immeasurable. Since its first description by Streiler in 1989 [83], the so-called 'skin-associated lymphoid tissue' has acquired an ever-increasing number of immunological prerogatives, including the capacity of keratinocytes (an ectodermal cell lineage), in concert with Langerhans cells and dermal dendritic cells, to play a role in antigen-presenting processes and, additionally, to prime naïve skin-reactive T cells directly [84]. Thus, some evidence has been provided to look at the skin as a true lymphoid organ in its ability to mount an immune response framework within its own milieu. Yet, there is still insufficient information on biological mechanisms driving leukocyte migration and homing to target tissues in immune responses and inflammation [85]. However, the hypothesis that memory CD8 T cells are able to persist as a stable, 'dormant' population in the skin after specific priming has taken place, has received authoritative confirmations from studies performed on both lichen planus (Figure 9 to 14) [86] and fixed drug eruption (Figure 24) [87], two prototypes of a vast group of skin conditions (comprehensively referred to as 'lichenoid tissue reaction/interface dermatitis') in which a common role of antigen presenting cell-mediated type I interferon signaling has been assumed [35]. Taken as a whole, all these data might provide the key to at least theoretically closing the pathogenetic loop linking treatment and occurrence of the otherwise clinically 'no sense' eczematous rashes in patients with HCV infection. However, a body of evidence which is strict enough to fully clarify the exact mechanisms underlying eczema and each of the many other skin AEs (Table 3) attributed to PEG-INF/RBV is still lacking. Yet, one might consider that notwithstanding the specific clinical and histological characteristics exhibited by each of the skin unfavorable events observed, many of them show a mixed type III and IV hypersensitivity reaction pattern in which Th-1 shifted inflammatory clones are likely to drive the inflammatory process. In such an immunopathogenetic framework, both the well-known proinflammatory properties of interferon and the multifaceted immune enhancing effects exerted by ribavirin on Th-1 cell mediated processes [88], may well intervene by worsening the course of pre-existing conditions, or triggering the new onset of diseases in subjects who would otherwise be unaffected clinically.

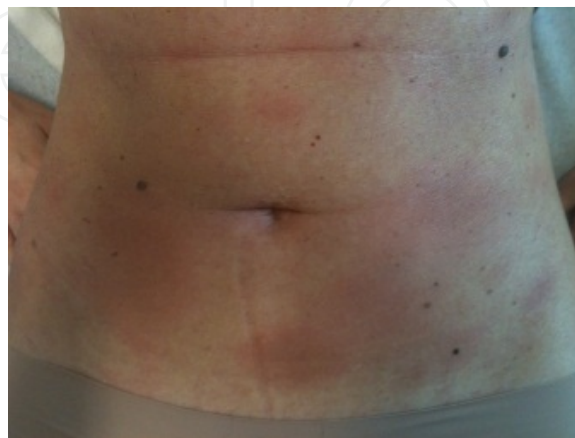

Figure 17. Erythematous patches at the site of injection of INF

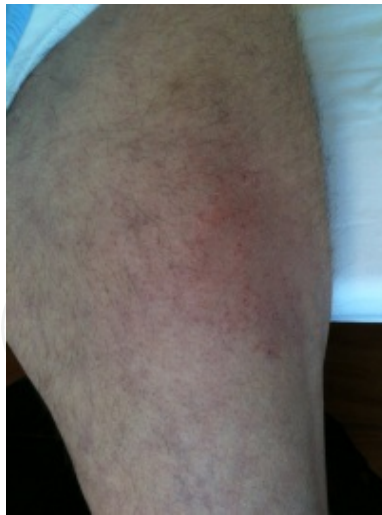

Figure 18. Vague eczematous patches on the extensor aspects of the limbs

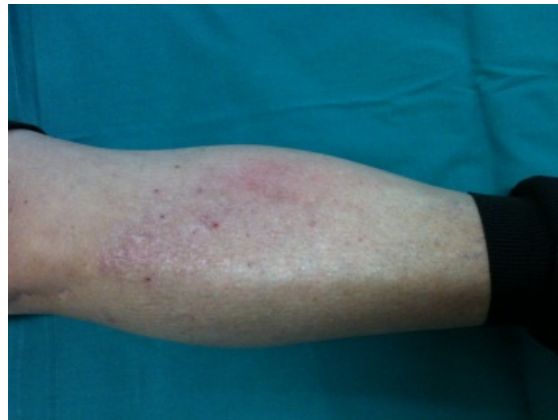

Figure 19. Eczema involving areas exposed to friction

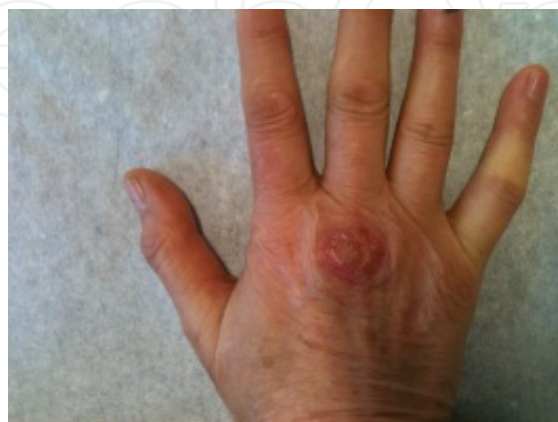

Figure 20. A 'coin' shaped, sharply demarcated eczematous lesion (*nummular eczema*)

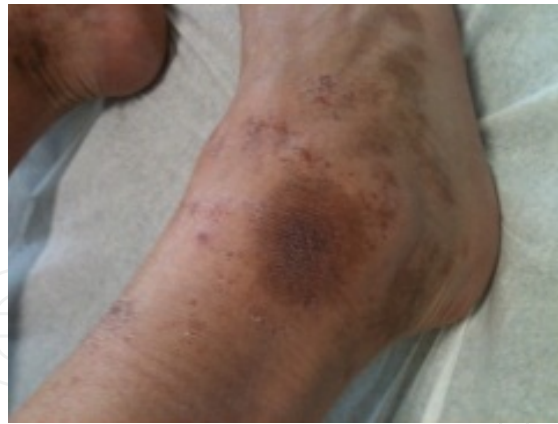

Figure 21. Nummular eczema: dyschromic sequelae

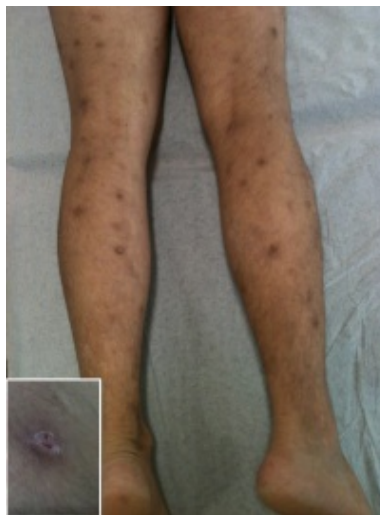

Figure 22. Prurigo nodularis - Bottom left corner: closeup of an excoriated nodule

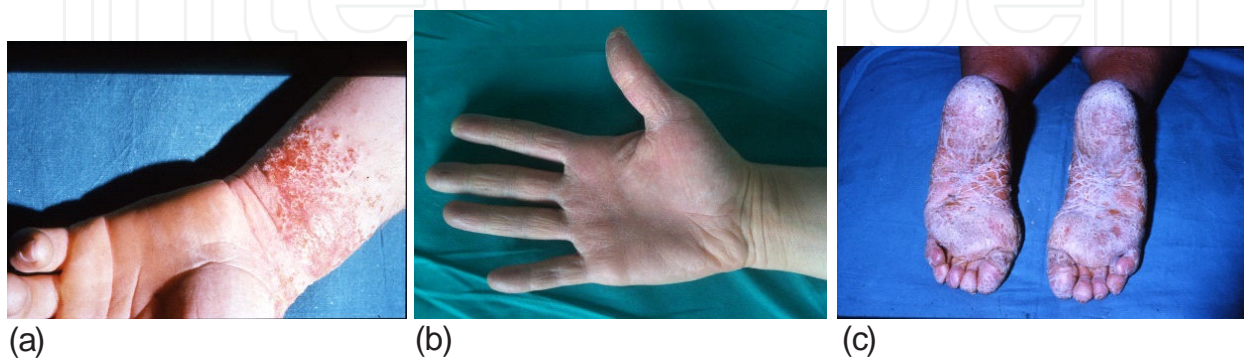


Figure 23. Clinical grading of eczema: A, acute; B, subacute; C, chronic

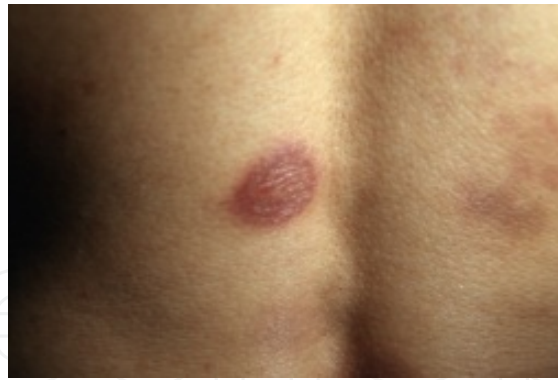

Figure 24. Fixed drug eruption (Courtesy of Doctor R. Pellicano, San Giovanni Rotondo, Italy)

4.2. Skin adverse effects related to newly developed agents for treatment of chronic HCV infection

'Telaprevir dermatitis': what are we dealing with?

The recent introduction of the NS3/4A protease inhibitors telaprevir and boceprevir, the first direct-acting antiviral agents (DAAs) approved for treatment of chronic infection with genotype 1 HCV in conjunction with PEG-INF and RBV, has led to increased viral response rates. Although PEG-INF plus RBV are still responsible for the majority of adverse effects related to 'triple therapy', DAA have been reported to induce exacerbation of traditional adverse events and development of new undesired occurrences.

As more specifically regards skin unfavorable manifestations, telaprevir seems to play a major role. Pruritus, independent of, or associated with skin manifestations are in fact the most significant cutaneous AEs [78, 90]. The analysis of the safety profile exhibited by telaprevir in the phase 1 to 3 studies available in the literature has yielded the almost invariable finding of consistently increased frequency rates of skin rashes appearing during telaprevir treatment phases compared with those occurring under SOC regimens. Rashes of any severity have been in fact reported in 36 to 82% of patients [90-93], and seemed to be virtually indistinguishable from the PEG-INF/RBV-related rashes, having 'dry skin', 'pruritus' and 'eczema' as prominent features. It has also been noted that some rashes were of greater severity and occurred on a larger body surface area (BSA), but in the vast majority of cases the BSA 30% limit was not exceeded. Of note, these rashes have been reported to largely occur during the first weeks of treatment and recover after telaprevir withdrawal.

Some efforts have recently been made to conceive strategy protocols of early intervention to minimize treatment-linked AEs. As for skin AEs, in the trials carried out by Jacobson and coworkers [94] and Zeuzem and coworkers [95] a 'rash management plan' was established and the intensity of rash was accordingly graded as *grade 1* (mild, localized to one or several sites); *grade 2* (moderate, with a diffuse skin eruption involving up to 50% of the body surface); and *grade 3* (severe, involving more than 50% of the body surface, or rash with the appearance of substantial systemic signs or symptoms). In patients with a progressive grade 2 rash, or any grade 3 rash telaprevir administration was stopped, while continuing PEG-INF/RBV treat-

ment. In case of worsening of the rash within the subsequent 7 days, RBV (and possibly PEG-INF) was to be discontinued as well (Table 4.A) [94, 95].

Severe rashes were observed in only 3-7% of patients, with some cases featuring Stevens-Johnson syndrome, toxic epidermal necrolysis, acute generalized exanthematous pustulosis, or 'drug rash with eosinophilia and systemic symptoms' (DRESS) syndromes. As a whole, however, only in 4-7% of subjects enrolled in clinical trials was telaprevir discontinued owing to skin rash. The absolute majority of skin rashes were instead *mild to moderate*, and were quite easily controlled through oral anti-histamines, topical emollients and/or high-to-mean potency steroid ointments [96].

There is a great number of reports concerning prevalence of and clinical warnings raised by telaprevir-induced dermatologic manifestations. However, to the best of my knowledge, no evidence is yet available in the literature giving '*telaprevir dermatitis*' some taxonomical profiling at least on morphological grounds. At the time of this writing, those of Cacoub and coworkers [78], Dupin and coworkers [97], Kumada and coworkers [93] and Awwad and coworkers [98] are the sole papers in the literature reporting some iconography of telaprevir-related dermatological AEs. Skin lesions are almost invariably and vaguely referred to as 'primarily eczematous' or 'maculopapular', and, as such, indeed appear to be rather indiscernible from those allegedly linked to PEG-INF/RBV. No or little information is available on cases that are 'not eczematous'. Could they be alternatively urticarial, dermographical, or polymorphic? When the rash is 'eczematous', are the skin lesions haphazard or symmetrical? Had any of these eczematous patients a history of delayed-type hypersensitivity and/or was he subsequently skin tested? Related to these circumstances, one should consider that the clinical grading of skin AEs (as described above), and thus the possibility of driving decision-making algorithms, currently lie on the need to assess severity of the skin rash through criteria that are not strict enough to prevent some unpredictable levels of intra- and inter-observer variability. In this respect, one may consider the rather significant differences existing in 'rash management strategies' conceived by different research groups (see Table 4.A and 4.B for comparison). Consequently, extensive dermatologist-oriented surveys are still warranted to better define the clinical edges (if any) of '*telaprevir dermatitis*' and possibly shed new light on the pathophysiology of such largely unexplained occurrences.

The same insufficiencies observed in morphological assessment of AEs related to telaprevir also involve studies carried out with other DAAs, which seem however to bear an overall lower potential of inducing dermatological unfavorable manifestations compared to the former. In this regard, in two recent phase 3 trials [99, 100] in which boceprevir was administered in combination with PEG-INF plus RBV for up to 44 weeks after a 4-week 'lead-in' phase with SOC agents, skin AEs (such as, 'rash' and 'dry skin') were observed in consistently lower rates of patients compared to telaprevir studies, and in no case were they the reason for pre-term discontinuation of treatment. Interestingly, in the trial involving naïve subjects [99], frequency of 'pruritus', 'rash' and 'dry skin' were

found to be not significantly different between SOC and boceprevir groups. Instead, in the trial involving non-naïve subjects [100], 'rash' and 'dry skin' were reported in up to 17 and 22% of patients, respectively, and between-arm differences with respect to this were found to be significant. Reasons for the above discordances appear definitely obscure.

Concerning possible reasons for the striking differences observed between telaprevir and boceprevir in terms of cutaneous (and noncutaneous) pathogeneticity, the obviously different chemical structures of the two agents may well account for most of *intrinsic* differences in specific harmful potentials. However the different treatment protocols applied (telaprevir associated with SOC agents at the beginning of the trial period, while boceprevir started only after a lead-in phase of SOC alone) could also be taken into consideration as being able to influence type and severity of undesired complaints. Particularly regarding skin AEs, one might speculate that PEG-INF and RBV, being delivered in association with telaprevir from the beginning of the trial, act as 'proinflammatory boosters' by virtue of their multifarious immunomodulating actions which would be able to create a sort of synergy with telaprevir noxious capacity.

As for other developing DAAs, the protease inhibitor BI 201335 has also to be considered. A small trial enrolling 53 chronic HCV genotype-1 patients (34 treatment-naïve and 19 treatment-experienced subjects) evaluated efficacy and safety profiles of 'multiple rising dose' regimens of BI 201335 in the short-term (4 weeks) [101]. In this study, no skin AEs during therapy with BI 201335 alone were reported. 'Mild rash or photosensitivity' was observed only in four patients during combined treatment with SOC agents, but in no case did this cause pre-term treatment discontinuation. It should additionally be reported that, according to interim (12 weeks) outcome analyses of an earlier study of BI 201335 with PegIFN/RBV in 288 patients in the long-term (24 weeks) [102], 'mostly mild to moderate rash and photosensitivity reactions' were referred to as the most frequent adverse events, along with gastrointestinal disorders. 'Severe rash' was observed in 0.7-1.3% of subjects receiving daily BI 201335 doses of 240mg, while this rate increased up to 5.7% in patients undergoing daily doses of 480 mg. Finally, in a phase 1b open-label trial, 34 treatment-naïve patients with chronic HCV-1 infection were randomized to receive an association of the polymerase inhibitor BI 207127 (400 to 600 mg 3 times daily) and BI 201335 (120 mg once daily) plus RBV (1000 to 1200 mg per day) for 4 weeks [103]. In this study a 'rash management plan' was established and the intensity of skin AEs was accordingly graded as *mild* (localized), *moderate* (diffuse, 30% to 70% body surface area), or *severe* (diffuse generalized, mucous membrane involvement, organ dysfunction, signs of anaphylaxis, or life threatening). A part from mild gastrointestinal disorders (diarrhea, nausea, vomiting), a mild 'rash or photosensitivity reaction' was observed in 42% of subjects receiving the highest daily dosages. Yet, due to drug overlap within the treatment regimens, it was not possible to ascribe any of these AEs to an individual compound. Nevertheless, no *severe* AEs were observed, and no AE-related pre-term discontinuation of treatment occurred throughout the study period.

| Rash severity | Description | Early intervention strategy protocol |
|----------------|--|---|
| <i>Grade 1</i> | <i>mild</i> , localized to one or several sites | Stable <i>mild/moderate</i> rash → Medical management performed at the discretion of the investigator |
| <i>Grade 2</i> | <i>moderate</i> , with a diffuse skin eruption involving up to 50% of the body surface | |
| <i>Grade 3</i> | <i>severe</i> , involving more than 50% of the body surface, or rash with the appearance of substantial systemic signs or symptoms | Progressive <i>moderate</i> rash, or <i>severe</i> rash → telaprevir discontinued ↓ Rash not improving within 7 days → RBV ± PEG-INF discontinued (suggested) |

Table 4.A Telaprevir - Skin AEs severity scale and rash management plan according with Jacobson et al [94] and Zeuzem et al [95]

| Rash severity | Description | Early intervention strategy protocol |
|----------------|---|---|
| <i>Grade 1</i> | Localized skin lesions | Routine, non specific management |
| <i>Grade 2</i> | Diffuse or multiple skin lesions | Telaprevir discontinued PEG-IFN and RBV reduced or discontinued, as required Dermatologists' consultation for diagnosis and specific cares |
| <i>Grade 3</i> | Skin lesions covering >50% of the body surface or rashes with some characteristics such as bullae, ulceration of mucous membrane, epidermal detachment, target lesion or significant systemic signs | |
| <i>Grade 4</i> | Stevens–Johnson syndrome and drug rashes with eosinophilia and systemic symptoms (DRESS) | |

Table 4.B Telaprevir - Skin AEs severity scale and rash management plan according with Kumada et al [93]

4.3. Skin adverse effects related to treatment of HBV infection

Current mainstays of treatment for HBV infection are interferon (INF) and nucleotide/nucleoside analogues (NAs), which are used following standardized guidelines in both 'first line, definite duration' and 'long-term, indefinite duration' protocols [104]. Considering, on one hand, the high diffusion of HBV infection in the general population [105] and the significant amounts of these agents that must have been, and are delivered worldwide accordingly, and on the other hand, the vast arrays of skin unfavorable manifestations observed under treatment for HCV infection (see above paragraph), the substantial paucity in the literature of systematic reviews or clinical reports on cutaneous side effects occurring in association with HBV treatment is somewhat surprising. The difference will be evident at a glance by comparing

Table 3 and 5. One may confidently infer that NAs are overall biologically inert within the 'skin milieu', but interferon does remain a shared weapon in the treatment of both viral agents, and has been the backbone tool in the management of HBV infection for many years before the advent of NAs. Differences in the prevalence rates of HBV and HCV infection worldwide, or mere underreporting could be well invoked in this respect. Yet, a possible explanation of such striking divergence between INF impact on the skin of patients with HBV and HCV infection could also lie in the more faithful hepatotropism of HBV compared to HCV. The latter has indeed been found in many tissue other than liver [106, 107], skin included [108, 109]. These circumstances might suggest a possible (yet indeterminable) synergy in skin pathogenicity between INF and HCV, which could play some direct role in local promotion of INF-related skin untoward manifestations in HCV but not in HBV patients. Another explanatory hypothesis could lie on the unique capacity of HCV (not ascribed to HBV) to induce B cell lymphoproliferation and trigger a number of autoimmune processes.

4.3.1. Skin events related to INF

Apart from the almost invariable occurrence of an erythematous roundish plaque at the injection site (Figure 17), administration of INF in HBV patients has been implicated in the following undesired effects (Table 5): skin necrosis at the injection site [110], angioedema-urticaria syndrome [111], diffuse patchy erythematous rash [112], morbilliform exanthema [113], psoriasis [114, 115], vitiligo [115], lichen planus [116], ocular trichomegaly [117].

4.3.2. Skin events related to NAs

The potential exhibited by these agents to sustain any skin pathogenicity appears to be overall contained. Not better specified 'rash and/or anaphylaxis' have been recently assumed to be 'infrequent' [1/10³ to 1/10⁴: tenofovir), 'common' [1/10 to 1/10²: lamivudine, telbivudine and adefovir) or 'with unknown frequency' (entecavir) [104]. Reports on NAs-related skin untoward effects are quite scanty in the literature. Lamivudine has been reported in relation with an ichthyosiform eruption in a patient with chronic HBV infection [118]. Clinical and histological iconography is also available of a severe, diffuse eczematous rash observed in an additional case of HBV infection in a Korean-language paper [119]. Reports of other skin AEs related to lamivudine refer to subject with HIV infection [120]. Entecavir has been reported to cause a diffuse maculopapular rash in one HBV patient [121] and an 'immediate allergy' erythematous eruption in an additional HBV patient [122]. Tenofovir has been implicated in development of a maculopapular rash on the face, extremities and trunk observed in HIV patients [123]. Adefovir has been found to trigger a case of Stevens-Johnson/toxic epidermal necrolysis overlap syndrome in a patient with HBV infection [124].

5. Virus-related liver hazards related to treatment of skin diseases

Treatment of a wide variety of skin inflammatory, immune mediated disorders poses a concrete risk for hepatic disease and toxicity. Possible undesired liver injuries are constantly a significant limitation in case management with a great number of pharmaceutical agents.

Injection site (local) reactions

- ill-defined, roundish, pruritic, self-recovering erythematous patches (figure 17)
- skin necrosis

Non local, or generalized reactions

- angioedema-urticaria syndrome
- diffuse patchy erythematous rash
- morbilliform exanthema
- psoriasis
- vitiligo
- lichen planus
- ocular trichomegaly

A – related to INF

Lamivudine:

- ichthyosiform eruption
- severe, diffuse eczematous rash

Entecavir:

- diffuse maculopapular rash
- erythematous eruption

Adefovir:

- Stevens-Johnson/toxic epidermal necrolysis overlap syndrome

B – related to NAs

Table 5. Skin adverse effects under treatment of HBV infection

Hepatotoxicity can derive directly from many drugs used in the treatment of psoriasis, such as methotrexate, ciclosporin or retinoids. Potential hazards may also indirectly result from drugs used to contrast unfavorable complications of dermatological treatment regimens, such as reactivated tuberculosis necessitating isoniazid or rifampicin administration. Also, unsurveyed administration of immunomodulating/immunosuppressive agents, ranging from corticosteroids to TNF- α antagonists, may be also associated with exacerbation of an underlying chronic viral hepatitis [125-127].

An in-depth analysis of all skin disorders the treatment of which may result in liver injury is certainly beyond the scope of this chapter. Instead, I will only concisely focus on systemic therapy of moderate-to-severe psoriasis (Table 6), in view of the fact that psoriasis is the leading item in cutaneous immune mediated pathology affecting 1 to 3% of population in Western industrialized countries [128]. Notably, it has been estimated that more than 11 million people suffer from psoriasis in Europe [129, 130]. Severity of psoriasis is 'quantitatively' assessed through so-called 'psoriasis area-and-severity index' (PASI), whose score ranges from 0 to 72

(with higher scores indicating more severe disease). Overall, patients with PASI scores of 12 or higher are candidates to systemic treatment. Yet, the magnitude of disease severity is also to be evaluated 'qualitatively', considering that the skin condition may often lead to substantial burden in terms of disability and psychosocial stigmatization (I believe that the reader will readily agree on this view after taking a look at figures 25.A to -D). In this regard, it has been calculated that impairment of physical and mental functioning in psoriatic patients is not consistently different from that observed in subjects with major medical illnesses, such as cancer, heart disease, chronic respiratory disease or type 2 diabetes [131]. Also, it should be underlined that a striking discrepancy between the objective 'weight' of the disease on clinical ground and the patients' subjective appraisal of the skin problem 'dimension' often exists [132]. The degree of patient dissatisfaction with treatment outcome is frequently high, and significant levels of intentional noncompliance with prescribed regimens are not uncommon accordingly [133].

Huge numbers of patients with psoriasis undergo systemic treatment, and thus are subject to some risk of undesired liver injury. In this context, the possibility of reactivation of chronic hepatitis B and C is of significant concern. As for Europe, the recently audited 'European S3-Guidelines on the systemic treatment of psoriasis vulgaris' [134] reflect a high level of physician awareness about this risk. 'Active chronic hepatitis B' and 'hepatitis C', respectively, are listed as absolute and relative contraindications on use of many systemic treatments. Accordingly, pre-treatment necessary measures include HBV/HCV serology and liver function tests. Liver enzymes are also to be evaluated throughout the treatment period at regular intervals. Moreover, some caveats concerning the use of anti-TNF α biologic agents (such as infliximab, etanercept, alefacept, efalizumab) in chronic carriers of HBV and HCV have been explicitly expressed [134]. Pre-treatment or concomitant use of antiviral agents has been assumed to allow systemic treatment use in some trials involving non-dermatological (Crohn's disease) patients, with no reports of viral reactivation under high potency regimens [135]. Co-administration of lamivudine has also been considered in the management of HBsAg carrier psoriatic patients [136, 137]. However, concerns are raised by the recognized risk of viral resistance development and acute disease flare occurrence after prolonged use of lamivudine. Thus, more studies are warranted to reliably assess whether antiviral prophylaxis is a viable option in the management of chronic inflammatory conditions.

5.1. Safety profile of traditional ('nonbiologic') and anti-TNF α ('biologic') agents in viral hepatitis patients

First, it must be strongly emphasized that reliable assessment of the safety profile of systemic agents employed in the treatment of moderate-to-severe psoriasis is inherently biased by many factors. Available information from randomized trials is often poor owing to low sample size and insufficient power to ascertain safety outcome conclusively [138]. Furthermore, clinical trials typically involve healthy patients or, at least, not 'difficult-to-treat' cases. In this regard, an inadequate representation in case populations of subjects with some relevant covariates, such as pediatric or elderly age, pregnancy or breastfeeding, history of kidney or liver disease, cancer, HIV, HBV and HCV infection, has been consistently documented [139-141]. Taken as

a whole, these circumstances dictate extreme caution in extrapolating results to the broader population of patients in day-to-day clinical practice.

5.1.1. HBV setting

Many papers can be found in the literature reporting TNF α inhibitors to worsen chronic HBV disease in subjects suffering from noncutaneous diseases, such as rheumatic conditions or Crohn's disease [142-144]. Instead, I found only one case concerning a patient with psoriasis vulgaris and psoriatic arthropathy caused by adalimumab [126]. An additional case, related to infliximab, was reported in the results of a questionnaire-based survey involving a nationwide sample of physician members of the American Academy of Dermatology in 2011 [145]. As for nonbiologic treatment-related events, a retrospective study carried out on ninety-eight patients undergoing prolonged corticosteroid treatment for psoriasis-unrelated skin conditions (namely, pemphigus vulgaris and dermatomyositis) showed only four cases of HBV reactivation, two of whom had a fatal outcome [125].

Reasons for such low reporting rates remain to be fully clarified. A role of so-called 'Weber effect' [146], or other factors possibly affecting spontaneous reporting of adverse events, might be invoked. Alternatively, a consistently high level of alertness among dermatologists might be assumed. In this respect, it can incidentally be considered that since 2005 all Italian dermatologists involved in the management of psoriasis with 'biologic' and 'nonbiologic' systemic agents have to mandatorily adhere to the well-established pharmacovigilance roadmap dictated by the so-called 'Psocare' program.¹ Moreover, another independent aim-oriented dermatology registry network, the Psonet (<http://www.psonet.eu>) [129, 147], has more recently branched off from the Psocare program in order to merge data and strategy protocols from most European countries, along with Israel and Australia. Properly surveyed administration of anti-TNF α agents in HBV patients has been reported to be an overall safe treatment option in the setting of both noncutaneous inflammatory conditions [148, 149] as well as psoriasis [136, 150, 151]. However, the use of systemic ('biologic' or 'nonbiologic') agents in psoriatic patients who are chronic carriers of HBV is only an end-line tool in the ranking of therapeutic options, phototherapy and/or topical agents being more properly recommended (Table 7) [139].

5.1.2. HCV setting

Despite the wide range of noncutaneous inflammatory diseases in which TNF α inhibitors are now used as well-established therapeutic tools, literature yields only few papers in which these

¹ Psocare is an Italian joint venture of psoriasis patients, dermatologists, epidemiologists and drug safety experts who are proactively involved since 2005 in a nationwide process linking drug prescription data to information on treatment outcome, such as effectiveness and long-term safety. Registration and participation to Psocare program, which is funded by the Italian Drug Administration Agency (AIFA), is mandatory to administer conventional treatments (including phototherapy) and new generation biologics. To date, Italian regional health authorities have appointed nearly 150 reference centers, in which patients' admission and follow-up visits are carried out, and demographic and lifestyle characteristics, disease severity, treatment exposure, treatment outcome, and any medical event (i.e. new diagnoses, hospitalizations, outpatient specialist visits) are registered. Before starting therapy, and throughout the treatment period, patients are rigidly evaluated according to standardized guidelines aimed at assuring the closest postmarketing surveillance of effectiveness and safety of systemic agents.

agents are reported to worsen HCV disease in subjects suffering from sole rheumatoid arthritis [141, 152-156]. TNF α inhibitors have also been assayed in HCV patients suffering from psoriasis. In this context, a number of small case series or anecdotal cases have been reported in which etanercept, efalizumab and alefacept do not induced HCV exacerbation. Of note, mild improvement in viral load and/or liver function tests were also observed in many of these cases [151, 157-170]. Only in one case, described by Ventura and coworkers [163], a significant increase of viral load (from 1.52×10^4 to 1.94×10^6 IU/mL), not coupled with increased liver enzymes, was observed after a 6-month therapy and led to treatment discontinuation. On the basis of such evidence, the overall harmful impact of anti-TNF α therapies in the setting of chronic HCV infection may appear to be lower than that exhibited in HBV infection. Indeed, the TNF α cascade has been consistently involved in the pathogenesis of liver damage, scar formation and fibrosis in chronic hepatitis C, and promising data have been reported suggesting a protective role of TNF α inhibitors against both INF-RBV-related undesired effects and virus-related hepatocyte injury [171]. Nevertheless, treatment of HCV infected psoriasis populations is subject to the same caution expressed by current guidelines for the management of patients who are chronic carriers of HBV [134]. Concerning this aspect, two different authority panels have recently audited all pros and cons, and drawn up a ranking list each of therapeutic options for treatment of moderate-to-severe psoriasis in HCV patients (Tables 8.A and B) [139, 172].

As for traditional 'nonbiologic' therapy, to the best of my knowledge, literature remains substantially silent with regard to acute flares of hepatitis deriving from treatment of psoriasis or other skin inflammatory conditions. I was able to find just one case of HCV reactivation occurring in a psoriatic patient after reduction of daily ciclosporin dosage [127]. By contrast, many cases of HCV reactivation have been reported during tapering of ciclosporin regimens in noncutaneous disease settings, such as bone marrow transplanted subjects [173]. In my opinion, reasons for possible underreporting in the dermatological literature of any drug-related liver undesired effects in the HCV setting are very likely to be the same as those discussed in paragraph 4.1.1.

As shown in Table 6, the management of moderate-to-severe psoriasis lies in a wide panel of agents which may often be a double-edged weapon owing to their broad immunosuppressive action. This concern is prompting continuous efforts to develop pharmacological agents (such as the new anti-interleukin-17 antibodies) [174-176] which are able to interfere with the TNF α cascade as downstream as possible, and are thus more likely to significantly lower the risk for side-effects related to impaired immune surveillance. Nevertheless, in more or less recent years (i.e., well after the breakthrough of 'TNF α inhibitor era') some faint interest has been renewed for traditional psoriasis treatment modalities, eg so-called *Goeckerman treatment* [177] or oral ciclosporin [178, 179]. In my view, the debate 'biologics versus nonbiologics' for management of skin inflammatory conditions is on the whole still highly controversial, and the decision-making process in daily clinical practice seems to be more conveniently left to the physician's wisdom.

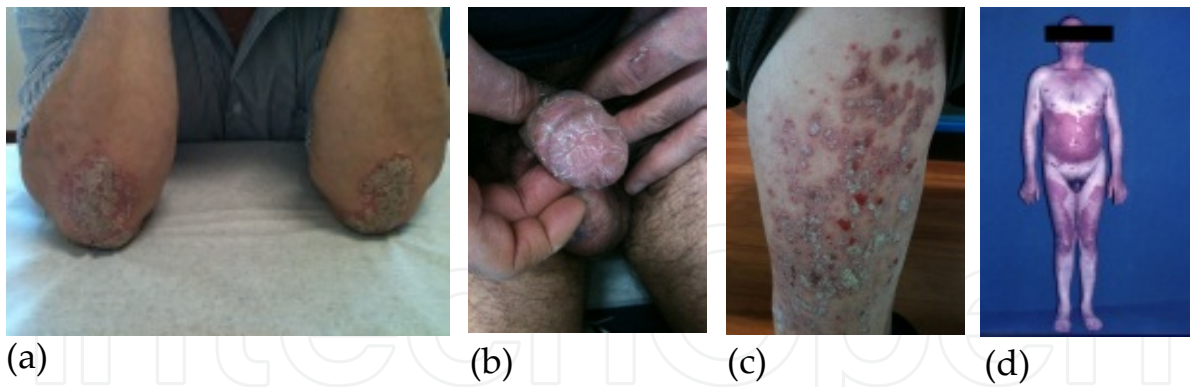


Figure 25. Psoriasis

| | |
|----------------------|--------------|
| -Methotrexate | -Alefacept |
| -Thioguanine | -Efalizumab |
| -Ciclosporin | -Ustekinumab |
| -Retinoids | -Ixekizumab |
| -Fumaric acid esters | -brodalumab |
| -Adalimumab | -secukinumab |
| -Etanercept | -tofacitinib |
| -Infliximab | |

Table 6. Systemic therapy for psoriasis

| Rank | Therapeutic option |
|------|--|
| 1 | UV-B narrowband |
| 2 | UV-B broadband |
| 3 | Topical corticosteroids |
| 4 | UV plus topical anthralin, or crude coal tar (*) |
| 5 | Topical steroids and calcipotriene |
| 6 | UV-A plus psoralen (P-UV-A) |
| 7 | UV plus acitretin |
| 8 | Efalizumab |
| 9 | Acitretin |

UV = ultraviolet phototherapy; (*) Goeckerman treatment [177]

Table 7. Ranking of therapeutic options for treatment of moderate-to-severe psoriasis in chronic carriers of HBV. From: Strober et al [139], modified

| Rank | Therapeutic option |
|------|--|
| 1 | Etanercept |
| 2 | UVB narrowband |
| 3 | TNF-inhibitor (without concern for any individual drug) |
| 4 | Adalimumab |
| 5 | UVB broadband |
| 6 | Infliximab |
| 7 | Topical corticosteroid in combination with calcipotriene |
| 8 | Topical corticosteroids |
| 9 | Efalizumab |
| 10 | Alefacept |

A: From: Strober et al [139], modified

| Rank | Therapeutic option |
|-------------|--------------------|
| First line | UVB narrowband |
| | UVB broadband |
| | Topical therapies |
| Second line | Acitretin |
| | Etanercept |
| | Infliximab |
| | Adalimumab |
| | PUVA |
| Third line | Alefacept |
| | Cyclosporine |
| | Efalizumab |
| | Azathioprine |

B: From: Frankel et al [180], modified

Table 8. Ranking of therapeutic options for treatment of moderate-to-severe psoriasis in chronic carriers of HCV

Author details

Mastrolonardo M.

Address all correspondence to: m.mastrolonardo@unifg.it

Department of Dermatology, University of Foggia, Foggia, Italy

References

- [1] Hazin, R. Abu-Rajab Tamimi TI, Abuzetun JY, Zein NN. Recognizing and treating cutaneous signs of liver disease. *Cleve Clin J Med* (2009). Oct;; 76(10), 599-606.
- [2] Nishioka, S, & Gyorkos, T. W. Tattoos as risk factors for transfusion-transmitted diseases. *Int J Infect Dis* (2001). , 5(1), 27-34.
- [3] Jafari, S, Buxton, J. A, Afshar, K, Copes, R, & Baharlou, S. Tattooing and risk of hepatitis B: a systematic review and meta-analysis. *Can J Public Health* (2012). May;; 103(3), 207-212.
- [4] Miyazaki, Y, Akizuki, S, Sakaoka, H, Yamamoto, S, & Terao, H. Disseminated infection of herpes simplex virus with fulminant hepatitis in a healthy adult. A case report. *APMIS* (1991). Nov;; 99(11), 1001-1007.
- [5] Angarone, M, & Ison, M. G. Prevention and early treatment of opportunistic viral infections in patients with leukemia and allogeneic stem cell transplantation recipients. *J Natl Compr Canc Netw* (2008). Feb;; 6(2), 191-201.
- [6] Sharma, S, & Mosunjac, M. Herpes simplex hepatitis in adults: a search for mucocutaneous clues. *J Clin Gastroenterol* (2004). Sep;; 38(8), 697-704.
- [7] Arkin, L. M, Castelo-Soccio, L, & Kovarik, C. Disseminated herpes simplex virus (HSV) hepatitis diagnosed by dermatology evaluation. *Int J Dermatol* (2009). Sep;; 48(9), 1020-1021.
- [8] El-Serag, H. B, Hampel, H, Yeh, C, & Rabeneck, L. Extrahepatic manifestations of hepatitis C among United States male veterans. *Hepatology* (2002). Dec;; 36(6), 1439-1445.
- [9] Reborá, A. Skin diseases associated with hepatitis C virus: facts and controversies. *Clin Dermatol* (2010). Sep;; 28(5), 489-496.
- [10] Cacoub, P, Renou, C, Rosenthal, E, Cohen, P, Lhoury, I, Loustaud-ratti, V, et al. Extrahepatic manifestations associated with hepatitis C virus infection. A prospective multicenter study of 321 patients. The GERMIVIC. Groupe d'Etude et de Recherche en Medecine Interne et Maladies Infectieuses sur le Virus de l'Hepatite C. *Medicine* (Baltimore) (2000). Jan;; 79(1), 47-56.
- [11] Sterling JC. Virus infections. In: Burns T, Breathmach S, Cox N, Griffiths C (ed.) *Rook's Textbook of Dermatology*. Oxford: Wiley-Blackwell; 2010. p33.1-81.
- [12] Cecchi, R, Giomi, A, Tuci, F, Bartoli, L, & Seghieri, G. Pityriasis rubra pilaris, lichen planus, alopecia universalis and vitiligo in a patient with chronic viral hepatitis C. *Dermatology* (1994). , 188(3), 239-240.

- [13] Ramos-casals, M, Mana, J, Nardi, N, Brito-zeron, P, Xaubet, A, Sanchez-tapias, J. M, et al. Sarcoidosis in patients with chronic hepatitis C virus infection: analysis of 68 cases. *Medicine (Baltimore)* (2005). Mar;; 84(2), 69-80.
- [14] Lewiecki, E. M, & Rahman, F. Pruritus. A manifestation of iron deficiency. *JAMA* (1976). Nov 15;; 236(20), 2319-2320.
- [15] Cribier, B, Samain, F, Vetter, D, Heid, E, & Grosshans, E. Systematic cutaneous examination in hepatitis C virus infected patients. *Acta Derm Venereol* (1998). Sep;; 78(5), 355-357.
- [16] Soyly, S, Gul, U, & Kilic, A. Cutaneous manifestations in patients positive for anti-hepatitis C virus antibodies. *Acta Derm Venereol* (2007). , 87(1), 49-53.
- [17] Soufir, N, Descamps, V, Crickx, B, Thibault, V, Cosnes, A, Becherel, P. A, et al. Hepatitis C virus infection in cutaneous polyarteritis nodosa: a retrospective study of 16 cases. *Arch Dermatol* (1999). Aug;; 135(8), 1001-1002.
- [18] Keane, F. M. MacFarlane CS, Munn SE, Higgins EM. Pyoderma gangrenosum and hepatitis C virus infection. *Br J Dermatol* (1998). Nov;; 139(5), 924-925.
- [19] Bockle, B. C, Baltaci, M, Ratzinger, G, Graziadei, I, Vogel, W, Sepp, N. T, & Hepatitis, C. and autoimmunity: a therapeutic challenge. *J Intern Med* (2012). Jan;; 271(1), 104-106.
- [20] Abe, M, Kawakami, Y, Oyama, N, Nakamura-wakatsuki, T, & Yamamoto, T. A rare co-occurrence of primary localized cutaneous amyloidosis and chronic C type hepatitis. *Int J Dermatol* (2010). Aug;; 49(8), 960-962.
- [21] Dessoukey, M. W, Abdel-dayem, H, Omar, M. F, & Al-suweidi, N. E. Pigmented purpuric dermatosis and hepatitis profile: a report on 10 patients. *Int J Dermatol* (2005). Jun;; 44(6), 486-488.
- [22] Kono, T, Kobayashi, H, Ishii, M, Nishiguchi, S, & Taniguchi, S. Synchronous development of disseminated superficial porokeratosis and hepatitis C virus-related hepatocellular carcinoma. *J Am Acad Dermatol* (2000). Nov;43(5 Pt 2):966-968.
- [23] Zechini, B, Teggi, A, Antonelli, M, Persechino, S, Pranteda, G, Versace, I, et al. A case report of pityriasis lichenoides in a patient with chronic hepatitis C. *J Infect* (2005). Aug;51(2):EE25., 23.
- [24] Granel, B, Serratrice, J, Rey, J, Bouvier, C, Weiller-merli, C, Disdier, P, et al. Chronic hepatitis C virus infection associated with a generalized granuloma annulare. *J Am Acad Dermatol* (2000). Nov;43(5 Pt 2):918-919.
- [25] Baglieri, F, & Scuderi, G. Disseminated Kaposi's sarcoma and HCV infection: only a casual relationship? A case report. *G Ital Dermatol Venereol* (2009). Jun;; 144(3), 317-320.

- [26] Kapoor, R, & Johnson, R. A. Necrolytic acral erythema. *N Engl J Med* (2011). Apr 14;; 364(15), 1479-1480.
- [27] Ramos-casals, M, Stone, J. H, Cid, M. C, & Bosch, X. The cryoglobulinaemias. *Lancet* (2012). Jan 28;; 379(9813), 348-360.
- [28] Frank, J, & Poblete-gutierrez, P. Porphyria cutanea tarda--when skin meets liver. *Best Pract Res Clin Gastroenterol* (2010). Oct;; 24(5), 735-745.
- [29] Chuang, T. Y, Brashear, R, & Lewis, C. Porphyria cutanea tarda and hepatitis C virus: a case-control study and meta-analysis of the literature. *J Am Acad Dermatol* (1999). Jul;; 41(1), 31-36.
- [30] Gisbert, J. P, Garcia-buey, L, Pajares, J. M, & Moreno-otero, R. Prevalence of hepatitis C virus infection in B-cell non-Hodgkin's lymphoma: systematic review and meta-analysis. *Gastroenterology* (2003). Dec;; 125(6), 1723-1732.
- [31] Ryan, C. F, Sendi, H, Bonkovsky, H. L, & Hepatitis, C. porphyria cutanea tarda and liver iron: an update. *Liver Int* (2012). Jul;; 32(6), 880-893.
- [32] Breathmach S. Lichen planus and lichenoid disorders. In: Burns T, Breathmach S, Cox N, Griffiths C (ed.) *Rook's Textbook of Dermatology*. Oxford: Wiley-Blackwell; 2010. p41.1-28.
- [33] Carrozzo, M. How common is oral lichen planus? *Evid Based Dent* (2008). , 9(4), 112-113.
- [34] Carrozzo, M, Dametto, E, Fasano, M. E, Arduino, P, Bertolusso, G, et al. Cytokine gene polymorphisms in hepatitis C virus-related oral lichen planus. *Exp Dermatol* (2007). Sep;; 16(9), 730-736.
- [35] Sontheimer, R. D. Lichenoid tissue reaction/interface dermatitis: clinical and histological perspectives. *J Invest Dermatol* (2009). May;; 129(5), 1088-1099.
- [36] Farhi, D, & Dupin, N. Pathophysiology, etiologic factors, and clinical management of oral lichen planus, part I: facts and controversies. *Clin Dermatol* (2010). Jan;; 28(1), 100-108.
- [37] Baccaglioni L, Thongprasom K, Carrozzo M, Bigby M. Urban legends series: lichen planus. *Oral Dis* 2012; 19(2) 128-143.
- [38] Lodi, G, Pellicano, R, & Carrozzo, M. Hepatitis C virus infection and lichen planus: a systematic review with meta-analysis. *Oral Dis* (2010). Oct;; 16(7), 601-612.
- [39] Shengyuan, L, Songpo, Y, Wen, W, Wenjing, T, Haitao, Z, & Binyou, W. Hepatitis C virus and lichen planus: a reciprocal association determined by a meta-analysis. *Arch Dermatol* (2009). Sep;; 145(9), 1040-1047.
- [40] Lapane, K. L, Jakiche, A. F, Sugano, D, Weng, C. S, & Carey, W. D. Hepatitis C infection risk analysis: who should be screened? Comparison of multiple screening strat-

- egies based on the National Hepatitis Surveillance Program. *Am J Gastroenterol* (1998). Apr; 93(4), 591-596.
- [41] Van Dh, V, Antoine, J. L, & Lachapelle, J. M. Histopathological discriminant criteria between lichenoid drug eruption and idiopathic lichen planus: retrospective study on selected samples. *Dermatologica* (1989). , 179(1), 10-13.
- [42] Breathmach SM. Drug reactions. In: Burns T, Breathmach S, Cox N, Griffiths C (ed.) *Rook's Textbook of Dermatology*. Oxford: Wiley-Blackwell; 2010. p75.1-177.
- [43] Giuliani, M, Lajolo, C, Sartorio, A, Scivetti, M, Capodiferro, S, & Tumbarello, M. Oral lichenoid lesions in HIV-HCV-coinfected subjects during antiviral therapy: 2 cases and review of the literature. *Am J Dermatopathol* (2008). Oct; 30(5), 466-471.
- [44] Han, S. H. Extrahepatic manifestations of chronic hepatitis B. *Clin Liver Dis* (2004). May; 8(2), 403-418.
- [45] Terrier B, Cacoub P. Virus de l'hépatite B, manifestations extrahépatiques immunologiques et risque de réactivation virale [Hepatitis B virus, extrahepatic immunologic manifestations and risk of viral reactivation]. *Rev Med Interne* 2011; 32(10) 622-627.
- [46] Cacoub, P, Saadoun, D, Bourliere, M, Khiri, H, Martineau, A, Benhamou, Y, et al. Hepatitis B virus genotypes and extrahepatic manifestations. *J Hepatol* (2005). Nov; 43(5), 764-770.
- [47] Shusterman, N, London, W. T, & Hepatitis, B. and immune-complex disease. *N Engl J Med* (1984). Jan 5; 310(1), 43-46.
- [48] Shusterman, N, London, W. T, & Hepatitis, B. and immune-complex disease. *N Engl J Med* (1984). Jan 5; 310(1), 43-46.
- [49] Han, S. H. Extrahepatic manifestations of chronic hepatitis B. *Clin Liver Dis* (2004). May; 8(2), 403-418.
- [50] Caroli, J. Serum-sickness-like prodromata in viral hepatitis: Caroli's triad. *Lancet* (1972). Apr 29; 1(7757), 964-965.
- [51] Tabata, N, Kato, T, Noguchi, K, Ueno, Y, & Tagami, H. Erythema multiforme following the exacerbation of hepatitis B virus infection. *Int J Dermatol* (1999). Jan; 38(1), 52-53.
- [52] van ARde Pagter AP, van Genderen PJ. Urticaria and periorbital edema as prodromal presenting signs of acute hepatitis B infection. *J Travel Med* (2011). May; 18(3), 224-225.
- [53] Wu, Y. L, Tsai, M. H, & Liu, L. L. Erythema nodosum and hepatitis B: a case report and literature review. *J Microbiol Immunol Infect* (2008). Oct; 41(5), 437-439.
- [54] Brandt, O, Abeck, D, Gianotti, R, & Burgdorf, W. Gianotti-Crosti syndrome. *J Am Acad Dermatol* (2006). Jan; 54(1), 136-145.

- [55] Haug, S, Schnopp, C, Ring, J, Folster-holst, R, & Abeck, D. Gianotti-Crosti syndrome following immunization]. *Hautarzt* (2002). Oct;; 53(10), 683-685.
- [56] Karakas, M, Durdu, M, Tuncer, I, & Cevlik, F. Gianotti-Crosti syndrome in a child following hepatitis B virus vaccination. *J Dermatol* (2007). Feb;; 34(2), 117-120.
- [57] Sagi, E. F, Linder, N, & Shouval, D. Papular acrodermatitis of childhood associated with hepatitis A virus infection. *Pediatr Dermatol* (1985). Nov;; 3(1), 31-33.
- [58] Guibal, F, Buffet, P, Mouly, F, Morel, P, & Rybojad, M. Papular-purpuric gloves and socks syndrome with hepatitis B infection. *Lancet* (1996). Feb 17;347(8999):473.
- [59] Turki, S, Guillevin, L, Dallot, A, Jarrousse, B, Vernier, I, Laroche, L, et al. Nodular and granulomatous form of periarteritis nodosa caused by the hepatitis B virus]. *Ann Dermatol Venereol* (1994). , 121(4), 325-327.
- [60] Cox NH, Jorizzo JL, Bourke JF et al. Vasculitis, neutrophilic dermatoses and related disorders. In: Burns T, Breathmach S, Cox N, Griffiths C (ed.) *Rook's Textbook of Dermatology*. Oxford: Wiley-Blackwell; 2010. p50.1-138.
- [61] Chrysomali, E, Piperi, E, & Sklavounou-andrikopoulou, A. Oral acanthosis nigricans in chronic hepatitis B with a 21-year follow up. *J Dermatol* (2011). Dec;; 38(12), 1172-1176.
- [62] Askin, U, Durdu, M, & Senel, E. Generalized granuloma annulare in a patient with myelocytic leukemia and chronic hepatitis B virus infection. *Indian J Dermatol Venereol Leprol* (2009). May;; 75(3), 287-289.
- [63] Birkenfeld, S, Dreier, J, Weitzman, D, & Cohen, A. D. A study on the association with hepatitis B and hepatitis C in 1557 patients with lichen planus. *J Eur Acad Dermatol Venereol* (2011). Apr;; 25(4), 436-440.
- [64] Bokor-bratic, M. Lack of evidence of hepatic disease in patients with oral lichen planus in Serbia. *Oral Dis* (2004). Sep;; 10(5), 283-286.
- [65] Goolsby, P. L. Erythema nodosum after Recombivax HB hepatitis B vaccine. *N Engl J Med* (1989). Oct 26;; 321(17), 1198-1199.
- [66] Wolf, F, Grezard, P, Berard, F, Clavel, G, & Perrot, H. Generalized granuloma annulare and hepatitis B vaccination. *Eur J Dermatol* (1998). Sep;; 8(6), 435-436.
- [67] Tay, Y. K. Gianotti-Crosti syndrome following immunization. *Pediatr Dermatol* (2001). May;18(3):262.
- [68] De KFNaeyaert JM, Hindryckx P, Elewaut D, Verplancke P, Peene I, et al. Immune-mediated pathology following hepatitis B vaccination. Two cases of polyarteritis nodosa and one case of pityriasis rosea-like drug eruption. *Clin Exp Rheumatol* (2000). Jan;; 18(1), 81-85.

- [69] Calista, D, & Morri, M. Lichen planus induced by hepatitis B vaccination: a new case and review of the literature. *Int J Dermatol* (2004). Aug; 43(8), 562-564.
- [70] Stavrianeas, N. G, Katoulis, A. C, Kanelleas, A, Hatziolou, E, & Georgala, S. Papulonodular lichenoid and pseudolymphomatous reaction at the injection site of hepatitis B virus vaccination. *Dermatology* (2002). , 205(2), 166-168.
- [71] Pham-ledard, A, Vergier, B, Doutre, M. S, & Beylot-barry, M. Disseminated cutaneous lymphoid hyperplasia of 12 years' duration triggered by vaccination. *Dermatology* (2010). , 220(2), 176-179.
- [72] Cox NH, Coulson IH. Systemic disease and the skin. In: Burns T, Breathmach S, Cox N, Griffiths C (ed.) *Rook's Textbook of Dermatology*. Oxford: Wiley-Blackwell; 2010. p62.1-121.
- [73] Jariwala, S, Vernon, N, & Shliozberg, J. Henoch-Schonlein purpura after hepatitis A vaccination. *Ann Allergy Asthma Immunol* (2011). Aug; 107(2), 180-181.
- [74] Mchutchison, J. G, Lawitz, E. J, Shiffman, M. L, Muir, A. J, Galler, G. W, Mccone, J, et al. Peginterferon alfa-2b or alfa-2a with ribavirin for treatment of hepatitis C infection. *N Engl J Med* (2009). Aug 6; 361(6), 580-593.
- [75] Ogawa, E, Furusyo, N, Kajiwara, E, Takahashi, K, Nomura, H, Tanabe, Y, et al. Evaluation of the adverse effect of premature discontinuation of pegylated interferon alpha-2b and ribavirin treatment for chronic hepatitis C virus infection: results from Kyushu University Liver Disease Study. *J Gastroenterol Hepatol* (2012). Jul; 27(7), 1233-1240.
- [76] Sookoian, S, Neglia, V, Castano, G, Frider, B, Kien, M. C, & Chohuela, E. High prevalence of cutaneous reactions to interferon alfa plus ribavirin combination therapy in patients with chronic hepatitis C virus. *Arch Dermatol* (1999). Aug; 135(8), 1000-1001.
- [77] Mistry, N, Shapero, J, & Crawford, R. I. A review of adverse cutaneous drug reactions resulting from the use of interferon and ribavirin. *Can J Gastroenterol* (2009). Oct; 23(10), 677-683.
- [78] Cacoub, P, Bourliere, M, Lubbe, J, Dupin, N, Buggisch, P, Dusheiko, G, et al. Dermatological side effects of hepatitis C and its treatment: patient management in the era of direct-acting antivirals. *J Hepatol* (2012). Feb; 56(2), 455-463.
- [79] Brok, J, Gluud, L. L, & Gluud, C. Ribavirin plus interferon versus interferon for chronic hepatitis C. *Cochrane Database Syst Rev* (2010). CD005445.
- [80] Vazquez-lopez, F, Manjon-haces, J. A, Perez-alvarez, R, & Perez-oliva, N. Eczema-like lesions and disruption of therapy in patients treated with interferon-alfa and ribavirin for chronic hepatitis C: the value of an interdisciplinary assessment. *Br J Dermatol* (2004). May; 150(5), 1046-1047.

- [81] Lubbe, J, Kerl, K, Negro, F, & Saurat, J. H. Clinical and immunological features of hepatitis C treatment-associated dermatitis in 36 prospective cases. *Br J Dermatol* (2005). Nov;; 153(5), 1088-1090.
- [82] Berth-Jones J. Eczema, lichenification, prurigo and erythroderma. In: Burns T, Breathmach S, Cox N, Griffiths C (ed.) *Rook's Textbook of Dermatology*. Oxford: Wiley-Blackwell; 2010. p23.1-51.
- [83] Streiler JW. Skin-associated lymphoid tissues (SALT): origins and functions. *J Invest Dermatol* 1983; 80 (suppl) 12s-16s.
- [84] Kim, B. S, Miyagawa, F, Cho, Y. H, Bennett, C. L, Clausen, B. E, & Katz, S. I. Keratinocytes function as accessory cells for presentation of endogenous antigen expressed in the epidermis. *J Invest Dermatol* (2009). Dec;; 129(12), 2805-2817.
- [85] Von Andrian, U. H. Mackay CR. T-cell function and migration. Two sides of the same coin. *N Engl J Med* (2000). Oct 5;; 343(14), 1020-1034.
- [86] Lodi, G, Scully, C, Carrozzo, M, Griffiths, M, Sugerman, P. B, & Thongprasom, K. Current controversies in oral lichen planus: report of an international consensus meeting. Part 1. Viral infections and etiopathogenesis. *Oral Surg Oral Med Oral Pathol Oral Radiol Endod* (2005). Jul;; 100(1), 40-51.
- [87] Shiohara, T, & Mizukawa, Y. The immunological basis of lichenoid tissue reaction. *Autoimmun Rev* (2005). Apr;; 4(4), 236-241.
- [88] Langhans, B, Nischalke, H. D, Arndt, S, Braunschweiger, I, Nattermann, J, Sauerbruch, T, et al. Ribavirin exerts differential effects on functions of Cd4+ Th1, Th2, and regulatory T cell clones in hepatitis C. *PLoS One* (2012). e42094.
- [89] Jadali, Z. Dermatologic manifestations of hepatitis C infection and the effect of interferon therapy: a literature review. *Arch Iran Med* (2012). Jan;; 15(1), 43-48.
- [90] Barritt, A. S, & Fried, M. W. Maximizing opportunities and avoiding mistakes in triple therapy for hepatitis C virus. *Gastroenterology* (2012). May;; 142(6), 1314-1323.
- [91] Hayashi, N, Okanou, T, Tsubouchi, H, Toyota, J, Chayama, K, & Kumada, H. Efficacy and safety of telaprevir, a new protease inhibitor, for difficult-to-treat patients with genotype 1 chronic hepatitis C. *J Viral Hepat* (2012). Feb;19(2):ee142., 134.
- [92] Cunningham, M, & Foster, G. R. Efficacy and safety of telaprevir in patients with genotype 1 hepatitis C infection. *Therap Adv Gastroenterol* (2012). Mar;; 5(2), 139-151.
- [93] Kumada, H, Toyota, J, Okanou, T, Chayama, K, Tsubouchi, H, & Hayashi, N. Telaprevir with peginterferon and ribavirin for treatment-naive patients chronically infected with HCV of genotype 1 in Japan. *J Hepatol* (2012). Jan;; 56(1), 78-84.

- [94] Jacobson, I. M, Mchutchison, J. G, & Dusheiko, G. Di Bisceglie AM, Reddy KR, Bzowej NH, et al. Telaprevir for previously untreated chronic hepatitis C virus infection. *N Engl J Med* (2011). Jun 23;; 364(25), 2405-2416.
- [95] Zeuzem, S, Andreone, P, Pol, S, Lawitz, E, Diago, M, Roberts, S, et al. Telaprevir for retreatment of HCV infection. *N Engl J Med* (2011). Jun 23;; 364(25), 2417-2428.
- [96] FDA Antiviral Drugs Advisory Committee Telaprevir Briefing Document April 28. (2011).
- [97] Dupin, N, Mallet, V, Carlotti, A, Vallet-pichard, A, & Pol, S. Severe skin rash in case of readministration of telaprevir in a patient who previously experienced a non severe rash. *Hepatology* (2012). Jun;; 55(6), 2042-2043.
- [98] Awwad, A, Renard, P, Pouzoulet, J, Sigal, M. L, & Mahe, E. Perianal ulcerations with telaprevir]. *Ann Dermatol Venereol* (2012). May;; 139(5), 391-392.
- [99] Poordad, F, & Mccone, J. Jr., Bacon BR, Bruno S, Manns MP, Sulkowski MS, et al. Boceprevir for untreated chronic HCV genotype 1 infection. *N Engl J Med* (2011). Mar 31;; 364(13), 1195-1206.
- [100] Bacon, B. R, Gordon, S. C, Lawitz, E, Marcellin, P, Vierling, J. M, Zeuzem, S, et al. Boceprevir for previously treated chronic HCV genotype 1 infection. *N Engl J Med* (2011). Mar 31;; 364(13), 1207-1217.
- [101] Manns, M. P, Bourliere, M, Benhamou, Y, Pol, S, Bonacini, M, Trepo, C, et al. Potency, safety, and pharmacokinetics of the NS3/4A protease inhibitor BI201335 in patients with chronic HCV genotype-1 infection. *J Hepatol* (2011). Jun;; 54(6), 1114-1122.
- [102] Sulkowski M, Bourliere M, Bronowicki J-P et al. SILEN-C2: early antiviral activity and safety of BI 201335 combined with peginterferon alfa-2a and ribavirin (PegIFN/RBV) in chronic HCV genotype-1 patients with non-response to PegIFN/RBV. *J Hepatol* 2010; 52 (suppl) s462-s643
- [103] Zeuzem, S, Asselah, T, Angus, P, Zarski, J. P, Larrey, D, Mullhaupt, B, et al. Efficacy of the protease inhibitor BI 201335, polymerase inhibitor BI 207127, and ribavirin in patients with chronic HCV infection. *Gastroenterology* (2011). Dec;; 141(6), 2047-2055.
- [104] Carosi, G, Rizzetto, M, Alberti, A, Cariti, G, Colombo, M, Craxi, A, et al. Treatment of chronic hepatitis B: update of the recommendations from the 2007 Italian Workshop. *Dig Liver Dis* (2011). Apr;; 43(4), 259-265.
- [105] European Association for the Study of the Liver. EASL clinical practice guidelines: management of chronic hepatitis B. *J Hepatol* 2009; 50(1) 227-242
- [106] De VSDe R, V, Sansonno D, Sorrentino D, Corte RL, Pivetta B, et al. Gastric mucosa as an additional extrahepatic localization of hepatitis C virus: viral detection in gas-

- tric low-grade lymphoma associated with autoimmune disease and in chronic gastritis. *Hepatology* (2000). Jan; 31(1), 182-189.
- [107] Fletcher, N. F, & Mckeating, J. A. Hepatitis C virus and the brain. *J Viral Hepat* (2012). May; 19(5), 301-306.
- [108] Sansonno, D, Cornacchiulo, V, Iacobelli, A. R, Di, S. R, Lospalluti, M, & Dammacco, F. Localization of hepatitis C virus antigens in liver and skin tissues of chronic hepatitis C virus-infected patients with mixed cryoglobulinemia. *Hepatology* (1995). Feb; 21(2), 305-312.
- [109] Crowson, A. N, Nuovo, G, Ferri, C, & Magro, C. M. The dermatopathologic manifestations of hepatitis C infection: a clinical, histological, and molecular assessment of 35 cases. *Hum Pathol* (2003). Jun; 34(6), 573-579.
- [110] Kontochristopoulos, G, Stavrinou, C, Aroni, K, & Tassopoulos, N. C. Cutaneous necrosis by subcutaneous injection of a-interferon in a patient with chronic type B hepatitis. *J Hepatol* (1996). Aug; 25(2):271.
- [111] Kilic, M, Dogan, Y, Taskin, E, Sen, Y, & Kalpaklioglu, A. F. Desensitization protocol administered successfully with interferon-alpha 2a in a child with chronic hepatitis B infection. *J Investig Allergol Clin Immunol* (2010). , 20(5), 447-448.
- [112] Milkiewicz, P, Yim, C, Pache, I, & Heathcote, J. Diffuse skin reaction in patient with hepatitis B, treated with two different formulations of pegylated interferon. *Can J Gastroenterol* (2005). Nov; 19(11), 677-678.
- [113] Barut, S, Yuksek, J, Sezer, E, Gunal, O, & Koseoglu, D. Morbilliform drug eruption due to pegylated alpha-interferon can show complete regression after switching to non-pegylated interferon. *J Dermatol* (2011). May; 38(5), 479-481.
- [114] Ketikoglou, I, Karatapanis, S, Elefsiniotis, I, Kafiri, G, & Moulakakis, A. Extensive psoriasis induced by pegylated interferon alpha-2b treatment for chronic hepatitis B. *Eur J Dermatol* (2005). Mar; 15(2), 107-109.
- [115] Seckin, D, Durusoy, C, & Sahin, S. Concomitant vitiligo and psoriasis in a patient treated with interferon alfa-2a for chronic hepatitis B infection. *Pediatr Dermatol* (2004). Sep; 21(5), 577-579.
- [116] Dalekos, G. N, Christodoulou, D, Kistis, K. G, Zervou, E. K, Hatzis, J, & Tsianos, E. V. A prospective evaluation of dermatological side-effects during alpha-interferon therapy for chronic viral hepatitis. *Eur J Gastroenterol Hepatol* (1998). Nov; 10(11), 933-939.
- [117] Ozdogan, M, Gur, G, Kadayifcilar, S, Boyacioglu, S, Ozgur, O, & Teletar, H. An unusual adverse effect of interferon: hypertrichosis of the eyelashes. *J Interferon Cytokine Res* (2000). Jul; 20(7), 633-634.

- [118] Kaptanoglu, A. F, & Kutluay, L. Ichthyosiform eruption associated with lamivudine in a patient with chronic hepatitis-B infection. *Int J Clin Pract* (2005). Oct;, 59(10), 1237-1238.
- [119] Kim, S. B, & Seo, P. J. Baik dS, Yun SY, Kim BH, Shin JE, et al. [A case of severe skin eruption caused by lamivudine in a patient with chronic hepatitis B]. *Korean J Gastroenterol* (2006). Oct;, 48(4), 281-285.
- [120] Atzori, L, Pinna, A. L, Pilloni, L, Ferreli, C, Pau, M, & Aste, N. Bullous skin eruption in an HIV patient during antiretroviral drugs therapy. *Dermatol Ther* (2008). Oct;21 Suppl 2:SS34., 30.
- [121] Yamada, S, Sawada, Y, & Nakamura, M. Maculopapular-type drug eruption caused by entecavir. *Eur J Dermatol* (2011). Jul;, 21(4), 635-636.
- [122] Sugiura, K, Sugiura, M, Takashi, T, Naoki, H, & Itoh, A. Immediate allergy, drug-induced eruption, by entecavir. *J Eur Acad Dermatol Venereol* (2009). Apr;, 23(4), 487-489.
- [123] Lockhart, S. M, Rathbun, R. C, Stephens, J. R, Baker, D. L, Drevets, D. A, Greenfield, R. A, et al. Cutaneous reactions with tenofovir disoproxil fumarate: a report of nine cases. *AIDS* (2007). Jun 19;, 21(10), 1370-1373.
- [124] Chattopadhyay, P, & Sarma, N. Adefovir-induced Stevens-Johnson syndrome and toxic epidermal necrolysis overlap syndrome. *Singapore Med J* (2011). Feb; 52(2):ee34., 31.
- [125] Yang, C. H, Wu, T. S, & Chiu, C. T. Chronic hepatitis B reactivation: a word of caution regarding the use of systemic glucocorticosteroid therapy. *Br J Dermatol* (2007). Sep;, 157(3), 587-590.
- [126] Kouba M, Rudolph SE, Hrdlicka P, Zuber MA. Hepatitis-B-Reaktivierung unter TNF- α -Blocker-Therapie mit Adalimumab bei Psoriasis-Arthritis [Hepatitis-B reactivation during treatment with tumor necrosis factor-alpha blocker adalimumab in a patient with psoriasis arthritis]. *Dtsch Med Wochenschr* 2012; 137(1-2) 23-26.
- [127] Miura, H, Itoh, Y, Matsumoto, Y, Tani, M, Tanabe, N, Isonokami, M, et al. Long-term administration of cyclosporin A to HCV-antibody-positive patients with dermatologic diseases. *Int J Dermatol* (1999). Apr;, 38(4), 310-314.
- [128] Nestle, F. O, Kaplan, D. H, & Barker, J. Psoriasis. *N Engl J Med* (2009). Jul 30;, 361(5), 496-509.
- [129] Lecluse LL, Naldi L, Stern RS, Spuls PI. National registries of systemic treatment for psoriasis and the European 'Psonet' initiative. *Dermatology* 2009; 218(4) 347-356.
- [130] Huerta, C, Rivero, E, & Rodriguez, L. A. Incidence and risk factors for psoriasis in the general population. *Arch Dermatol* (2007). Dec;, 143(12), 1559-1565.

- [131] Rapp, S. R, Feldman, S. R, Exum, M. L, & Fleischer, A. B. Jr., Reboussin DM. Psoriasis causes as much disability as other major medical diseases. *J Am Acad Dermatol* (1999). Sep;41(3 Pt 1):401-407.
- [132] Stern, R. S, Nijsten, T, Feldman, S. R, Margolis, D. J, & Rolstad, T. Psoriasis is common, carries a substantial burden even when not extensive, and is associated with widespread treatment dissatisfaction. *J Investig Dermatol Symp Proc* (2004). Mar;; 9(2), 136-139.
- [133] Richards, H. L, Fortune, D. G, Sullivan, O, Main, T. M, & Griffiths, C. J. CE. Patients with psoriasis and their compliance with medication. *J Am Acad Dermatol* (1999). Oct;; 41(4), 581-583.
- [134] Pathirana, D, Ormerod, A. D, Saiag, P, Smith, C, Spuls, P. I, Nast, A, et al. European S3-guidelines on the systemic treatment of psoriasis vulgaris. *J Eur Acad Dermatol Venereol* (2009). Oct;23 Suppl , 2, 1-70.
- [135] Del, V. G-S, Gomez-camacho, F, Poyato-gonzalez, A, Iglesias-flores, E. M, De Dios-vega, J. F, & Sancho-zapatero, R. Infliximab therapy in a patient with Crohn's disease and chronic hepatitis B virus infection. *Inflamm Bowel Dis* (2004). Sep;; 10(5), 701-702.
- [136] Cassano, N, Mastrandrea, V, Principi, M, & Loconsole, F. De TN, Di LA, et al. Anti-tumor necrosis factor treatment in occult hepatitis B virus infection: a retrospective analysis of 62 patients with psoriatic disease. *J Biol Regul Homeost Agents* (2011). Apr;; 25(2), 285-289.
- [137] Vigano, M, Degasperi, E, Aghemo, A, Lampertico, P, & Colombo, M. Anti-TNF drugs in patients with hepatitis B or C virus infection: safety and clinical management. *Expert Opin Biol Ther* (2012). Feb;; 12(2), 193-207.
- [138] Bongartz, T, Sutton, A. J, Sweeting, M. J, Buchan, I, Matteson, E. L, & Montori, V. Anti-TNF antibody therapy in rheumatoid arthritis and the risk of serious infections and malignancies: systematic review and meta-analysis of rare harmful effects in randomized controlled trials. *JAMA* (2006). May 17;; 295(19), 2275-2285.
- [139] Strober, B, Berger, E, Cather, J, Cohen, D, Crowley, J. J, Gordon, K. B, et al. A series of critically challenging case scenarios in moderate to severe psoriasis: a Delphi consensus approach. *J Am Acad Dermatol* (2009). Jul;61(1 Suppl 1):SS46., 1.
- [140] Garcia-doval, I, Carretero, G, Vanaclocha, F, Ferrandiz, C, Dauden, E, Sanchez-carazo, J. L, et al. Risk of serious adverse events associated with biologic and nonbiologic psoriasis systemic therapy: patients ineligible vs eligible for randomized controlled trials. *Arch Dermatol* (2012). Apr;; 148(4), 463-470.
- [141] Brunasso, A. M, Puntoni, M, Gulia, A, & Massone, C. Safety of anti-tumour necrosis factor agents in patients with chronic hepatitis C infection: a systematic review. *Rheumatology (Oxford)* (2011). Sep;; 50(9), 1700-1711.

- [142] Ostuni, P, Botsios, C, Punzi, L, Sfriso, P, & Todesco, S. Hepatitis B reactivation in a chronic hepatitis B surface antigen carrier with rheumatoid arthritis treated with infliximab and low dose methotrexate. *Ann Rheum Dis* (2003). Jul; 62(7), 686-687.
- [143] Wendling, D, Auge, B, Bettinger, D, Lohse, A, Le, H. G, Bresson-hadni, S, et al. Reactivation of a latent precore mutant hepatitis B virus related chronic hepatitis during infliximab treatment for severe spondyloarthritis. *Ann Rheum Dis* (2005). May; 64(5), 788-789.
- [144] Madonia, S, Orlando, A, Scimeca, D, Olivo, M, Rossi, F, & Cottone, M. Occult hepatitis B and infliximab-induced HBV reactivation. *Inflamm Bowel Dis* (2007). Apr; 13(4), 508-509.
- [145] Stine, J. G, Bass, M, Ibrahim, D, Khokhar, O. S, & Lewis, J. H. Dermatologists' awareness of and screening practices for hepatitis B virus infection before initiating tumor necrosis factor-alpha inhibitor therapy. *South Med J* (2011). Dec; 104(12), 781-788.
- [146] Hartnell, N. R, & Wilson, J. P. Replication of the Weber effect using postmarketing adverse event reports voluntarily submitted to the United States Food and Drug Administration. *Pharmacotherapy* (2004). Jun; 24(6), 743-749.
- [147] <http://www.psonet.eu>.
- [148] Roux, C. H, Brocq, O, Breuil, V, Albert, C, & Euller-ziegler, L. Safety of anti-TNF-alpha therapy in rheumatoid arthritis and spondylarthropathies with concurrent B or C chronic hepatitis. *Rheumatology (Oxford)* (2006). Oct; 45(10), 1294-1297.
- [149] Sakellariou, G. T, & Chatzigiannis, I. Long-term anti-TNFalpha therapy for ankylosing spondylitis in two patients with chronic HBV infection. *Clin Rheumatol* (2007). Jun; 26(6), 950-952.
- [150] Conde-taboada, A, Munoz, J. P, Munoz, L. C, & Lopez-bran, E. Infliximab treatment for severe psoriasis in a patient with active hepatitis B virus infection. *J Am Acad Dermatol* (2009). Jun; 60(6), 1077-1080.
- [151] Prignano, F, Zanieri, F, Milani, S, & Lotti, T. Switch from etanercept to efalizumab in a psoriatic patient with HCV infection: a case report. *Dermatol Ther* (2009). Jul; 22(4), 386-390.
- [152] Pritchard, C. Etanercept and hepatitis C. *J Clin Rheumatol* (1999). Jun;5(3):179.
- [153] Cansu, D. U, Kalifoglu, T, & Korkmaz, C. Short-term course of chronic hepatitis B and C under treatment with etanercept associated with different disease modifying antirheumatic drugs without antiviral prophylaxis. *J Rheumatol* (2008). Mar; 35(3), 421-424.
- [154] Ferri, C, Ferraccioli, G, Ferrari, D, Galeazzi, M, Lapadula, G, Montecucco, C, et al. Safety of anti-tumor necrosis factor-alpha therapy in patients with rheumatoid arthritis and chronic hepatitis C virus infection. *J Rheumatol* (2008). Oct; 35(10), 1944-1949.

- [155] Kaur, P. P, Chan, V. C, & Berney, S. N. Histological evaluation of liver in two rheumatoid arthritis patients with chronic hepatitis B and C treated with TNF-alpha blockade: case reports. *Clin Rheumatol* (2008). Aug;; 27(8), 1069-1071.
- [156] Li, S, Kaur, P. P, Chan, V, & Berney, S. Use of tumor necrosis factor-alpha (TNF-alpha) antagonists infliximab, etanercept, and adalimumab in patients with concurrent rheumatoid arthritis and hepatitis B or hepatitis C: a retrospective record review of 11 patients. *Clin Rheumatol* (2009). Jul;; 28(7), 787-791.
- [157] Cecchi, R, & Bartoli, L. Psoriasis and hepatitis C treated with anti-TNF alpha therapy (etanercept). *Dermatol Online J* (2006).
- [158] Linardaki, G, Katsarou, O, Ioannidou, P, Karafoulidou, A, & Boki, K. Effective etanercept treatment for psoriatic arthritis complicating concomitant human immunodeficiency virus and hepatitis C virus infection. *J Rheumatol* (2007). Jun;; 34(6), 1353-1355.
- [159] De SCParadisi A, Capizzi R, Carbone A, Siciliano M, Amerio PL. Etanercept therapy in two patients with psoriasis and concomitant hepatitis C. *J Am Acad Dermatol* (2006). Jun;; 54(6), 1102-1104.
- [160] Piccolo, D, Di, C. A, Fargnoli, M. C, Paoloni, M, Vecchiotti, S, & Peris, K. Effective control of psoriasis by etanercept in a patient with HCV-related diseases. *Eur J Dermatol* (2008). Jul;; 18(4), 459-460.
- [161] Alcaide, A. J, Barrera, M. V, Habicheyn, S, Lopez, N, Mendiola, M. V, & Herrera, E. Safety of etanercept therapy in a patient with psoriasis, Down's syndrome and concomitant hepatitis C virus infection. *J Eur Acad Dermatol Venereol* (2008). Dec;; 22(12), 1514-1516.
- [162] Behnam, S. E, Hindiyeh, R, Fife, D. J, & Jeffes, E. W. III, Wu JJ. Etanercept as prophylactic psoriatic therapy before interferon-alpha and ribavirin treatment for active hepatitis C infection. *Clin Exp Dermatol* (2010). Jun;; 35(4), 397-398.
- [163] Ventura, F, Gomes, J, Duarte, M. L, Fernandes, J. C, & Brito, C. Efficacy and safety of etanercept in patients with psoriasis and hepatitis C. *Eur J Dermatol* (2010). Nov;; 20(6), 808-809.
- [164] Rokhsar, C, Rabhan, N, & Cohen, S. R. Etanercept monotherapy for a patient with psoriasis, psoriatic arthritis, and concomitant hepatitis C infection. *J Am Acad Dermatol* (2006). Feb;; 54(2), 361-362.
- [165] Paradisi, A, Caldarola, G, Capizzi, R, Siciliano, M, Annichiarico, E, Vecchio, F. M, et al. Safety of etanercept in patients with psoriasis and hepatitis C virus assessed by liver histopathology: preliminary data. *J Am Acad Dermatol* (2010). Jun;; 62(6), 1067-1069.
- [166] Allen E, Hurley Y, Leonardi C. Etanercept therapy in psoriasis patients with underlying hepatitis C. *J Am Acad Dermatol* 2005; 52 (3) s1.

- [167] Esposito M, Bianchi L, Mazzotta A et al. Influence of etanercept on serum-related liver related tests and viral load values in patients with psoriasis and hepatitis C infection. *J Am Acad Dermatol* 2007; 56 (Suppl 2) P2700.
- [168] Magliocco, M. A, & Gottlieb, A. B. Etanercept therapy for patients with psoriatic arthritis and concurrent hepatitis C virus infection: report of 3 cases. *J Am Acad Dermatol* (2004). Oct;, 51(4), 580-584.
- [169] Gisondi, P, Prignano, F, Grossi, P, Lotti, T, & Girolomoni, G. Treatment of psoriasis with efalizumab in patients with hepatitis C viral infection: report of five cases. *Dermatology* (2009). , 219(2), 158-161.
- [170] Thaci, D, Patzold, S, Kaufmann, R, & Boehncke, W. H. Treatment of psoriasis with alefacept in patients with hepatitis C infection: a report of two cases. *Br J Dermatol* (2005). May;, 152(5), 1048-1050.
- [171] Zein, N. N. Etanercept as an adjuvant to interferon and ribavirin in treatment-naive patients with chronic hepatitis C virus infection: a phase 2 randomized, double-blind, placebo-controlled study. *J Hepatol* (2005). Mar;, 42(3), 315-322.
- [172] Frankel, A. J, Van Voorhees, A. S, Hsu, S, Korman, N. J, Lebwohl, M. G, Bebo, B. F, et al. Treatment of psoriasis in patients with hepatitis C: from the Medical Board of the National Psoriasis Foundation. *J Am Acad Dermatol* (2009). Dec;, 61(6), 1044-1055.
- [173] Akiyama, H, Yoshinaga, H, Tanaka, T, Hiruma, K, Tanikawa, S, Sakamaki, H, et al. Effects of cyclosporin A on hepatitis C virus infection in bone marrow transplant patients. Bone Marrow Transplantation Team. *Bone Marrow Transplant* (1997). Dec;, 20(11), 993-995.
- [174] Leonardi, C, Matheson, R, Zachariae, C, Cameron, G, Li, L, Edson-heredia, E, et al. Anti-interleukin-17 monoclonal antibody ixekizumab in chronic plaque psoriasis. *N Engl J Med* (2012). Mar 29;, 366(13), 1190-1199.
- [175] Papp, K. A, Leonardi, C, Menter, A, Ortonne, J. P, Krueger, J. G, Kricorian, G, et al. Brodalumab, an anti-interleukin-17-receptor antibody for psoriasis. *N Engl J Med* (2012). Mar 29;, 366(13), 1181-1189.
- [176] Hueber, W, Patel, D. D, Dryja, T, Wright, A. M, Koroleva, I, Bruin, G, et al. Effects of AIN457, a fully human antibody to interleukin-17A, on psoriasis, rheumatoid arthritis, and uveitis. *Sci Transl Med* (2010). Oct 6;2(52):52ra72.
- [177] Serrao, R, & Davis, M. D. Goeckerman treatment for remission of psoriasis refractory to biologic therapy. *J Am Acad Dermatol* (2009). Feb;, 60(2), 348-349.
- [178] Brunasso AMGCyclosporine as monotherapy for psoriasis in the setting of chronic HCV infection. In: Michetti P FLed, ed. 12 ed. (2012). , 52-349.

- [179] Di, L, & Albertini, V. G. Treatment of psoriasis with cyclosporine in patients with hepatitis C infection: risk or opportunity? *J Am Acad Dermatol* (2010). Aug;; 63(2), 342-343.
- [180] Frankel, A. J, Van Voorhees, A. S, Hsu, S, Korman, N. J, Lebwohl, M. G, Bebo, B. F, et al. Treatment of psoriasis in patients with hepatitis C: from the Medical Board of the National Psoriasis Foundation. *J Am Acad Dermatol* (2009). Dec;; 61(6), 1044-1055.

IntechOpen

IntechOpen