

# We are IntechOpen, the world's leading publisher of Open Access books Built by scientists, for scientists

**4,800**

Open access books available

**122,000**

International authors and editors

**135M**

Downloads

Our authors are among the

**154**

Countries delivered to

**TOP 1%**

most cited scientists

**12.2%**

Contributors from top 500 universities



**WEB OF SCIENCE™**

Selection of our books indexed in the Book Citation Index  
in Web of Science™ Core Collection (BKCI)

Interested in publishing with us?  
Contact [book.department@intechopen.com](mailto:book.department@intechopen.com)

Numbers displayed above are based on latest data collected.

For more information visit [www.intechopen.com](http://www.intechopen.com)



---

# Relationship Between Ox-LDL, Immune Cells, Atheroma Dimensions and Angiographic Measurements Assessed by Coronary Angiography and Intravascular Ultrasound

---

Catarina Ramos, Patrícia Napoleão,  
Rui Cruz Ferreira, Cristina Fondinho, Mafalda Selas,  
Miguel Mota Carmo, Ana Maria Crespo and  
Teresa Pinheiro

Additional information is available at the end of the chapter

<http://dx.doi.org/10.5772/54084>

---

## 1. Introduction

In this chapter we report on the relationship between angiographic findings, measured by coronary angiography (CA) and intravascular ultrasound virtual histology (IVUS-VH) modalities, and indicators of vascular inflammation in the context of coronary artery disease (CAD). We sought to explore *in vivo* the relationship between patient demographics, anthropometric measures, risk factors, soluble biomarkers and plaque composition or its morphological characteristics.

The interplay of inflammatory cells, cytokines and indicators of cell death may concur to the plaque phenotype in the context of coronary artery disease. Therefore, the lymphocyte populations expressing CD4 and CD8, the circulating levels of oxidized low density lipoprotein (ox-LDL), which may be primarily originated in the atheroma, the levels of tumour necrosis factor alpha (TNF- $\alpha$ ) and of soluble Fas ligand (sFasL), which may reflect the inflammatory response and vascular apoptosis, were studied.

These biomarkers would provide useful tools to improve medical diagnosis of the clinical atheroma. Noninvasive identification of high-risk/vulnerable coronary atherosclerotic plaques is one of the ultimate goals of coronary imaging and would dramatically improve risk

stratification of both symptomatic and asymptomatic patients [1]. Therefore, correlations between plaque composition, bio-indicators and the severity of cardiac events may provide unique information about plaque type to enhance the precision of clinical and laboratory variables used to assess patients at risk of CAD.

### 1.1. Coronary artery disease

Coronary artery disease is still the main cause of death worldwide and coronary atherothrombosis is the leading cause of death in the United States and Europe [2,3]. A large number of individuals who die suddenly of CAD due to atherosclerosis have no previous symptoms [4].

Atherosclerosis is a chronic pathological process of the vasculature characterized by focal arterial wall inflammation that leads to plaque build-up, intraluminal narrowing, and atherothrombotic stenosis or occlusion with distal organ damage [5,6]. The atherosclerotic lesion is a thickening of the artery intima that consists of inflammatory and smooth muscle cells [7], as well as connective-tissue, lipids and debris [8]. The atheroma formation is initiated by an accumulation of lipid-laden cells beneath the endothelium, denominated fatty streak [9,10]. As atherosclerosis progresses from a benign phenotype, the atheroma becomes fibrotic, with a large necrotic core. Also, the plaque becomes more inflamed, resulting in an infiltration of macrophages and T-lymphocytes to the metabolically active fibrous cap [3]. Disintegration of foam cells and production of matrix metalloproteinases by activated leukocytes have detrimental consequences leading to the destabilization of lipid rich cores and the thinning of the fibrous cap [8]. This leads to a rupture-prone thin-cap fibroatheroma. The plaque rupture may cause arterial thrombosis, which results in a clinical spectrum of presentations ranging from sudden cardiac death, due to coronary occlusion, to an asymptomatic event with plaque progression [3]. In fact, the rupture of vulnerable atherosclerotic plaque is the cause of most acute coronary syndromes, e.g. myocardial infarction and unstable angina [8,11].

Atherosclerotic plaque stability is related to histological composition however biomarkers for the disease severity are still lacking today [12-14]. Multiple evidences link risk factors for atherosclerosis and its complications with altered histology, including the operation of both innate and adaptive immunity and the balance of stimulatory and inhibitory pathways that regulate their participation in atheroma formation and complication [15].

The early involvement of monocytes and macrophages in atherosclerosis is initiated with endothelial cell activation. Several protein mediators, specifically cytokines and chemokines, and LDL oxidative modification [16], direct monocyte migration to the intima and promote their maturation into macrophages, which are retained in the lesion [17,18]. These pro-inflammatory monocytes propagate the innate response by expressing high levels of pro-inflammatory cytokines and other macrophages mediators including metalloproteinases [6,19,20]. Dendritic cells that populate atherosclerotic plaques can present antigens to T-cells, which mount a cellular immune response [21]. These immune cells are also involved in thrombosis. Coagulation proteins elicit the expression of pro-inflammatory cytokines and mediators that interact with toll-like receptors of immune cells. These events promote endothelial cell apoptosis [22,23].

The ox-LDL has been described as a relevant pro-atherogenic autoantigen and its inflammatory and immunogenic activity has been implicated in atherosclerosis development and CAD [14,24]. Experimental data showed that ox-LDL is formed in the arterial wall where it is internalized by macrophages to form foam cells, contributing to the plaque progression [14]. The co-localization of ox-LDL with lymphocytes and monocyte-derived cells in the human atherosclerotic lesions reinforce the pro-atherogenic and immunogenic properties of ox-LDL, which was verified *in vitro* [24]. Eventually, ox-LDL formed in the arterial wall is released in the circulation [13], being their circulating levels strongly associated with angiographically documented coronary artery disease [25]. The proximity of ox-LDL and inflammatory cells, such as lymphocyte populations, in the atherosclerotic plaque may accelerate macrophage activity and therefore promote atherogenesis [26]. The T-cells expressing CD4 surface marker recognize antigens presented by dendritic cells and macrophages. The T-cell expressing CD8 when activated are capable of killing smooth muscle cells and macrophages. Both CD4 and CD8 T cells share the capacity to recognize protein antigens bound to histocompatibility molecules on cell surfaces [27].

Thus, the *in vivo* identification of plaque vulnerability whether by characterizing its components or by providing measures of plaque-related oxidative and inflammation markers may improve diagnostic and eventually allow the detection of vulnerable atheroma before rupture.

## 1.2. Coronary angiography

Since its implementation over 30 years ago, invasive coronary angiography has become the standard clinical method for describing the coronary arteries and the “gold standard” for diagnosing CAD. The use of contrast-enhanced coronary angiography has been introduced for stenosis detection and for assessing blood flow in the epicardial arteries. The approach based on edge-detection algorithms has also been proposed as an emerging tool for the detection, characterization, and quantification of coronary atherosclerotic plaques [11].

The increased understanding of atherosclerosis has highlighted inherent limitations of coronary angiography as a technique for the assessment of coronary atherosclerotic plaques. Angiography provides a 2-dimensional view of the arterial lumen, but with no visualization of the vessel wall. Atherosclerosis primarily affects the arterial wall and since only the lumen is displayed, angiography does not provide extensive information about the plaque [28,29] and may obscure the true plaque burden, leading to an underestimation of plaque severity [3]. Also, the atherosclerotic plaque initially grows in an outwardly manner, expanding to the vessel wall, a process denominated positive remodeling. Therefore, as a result of positive remodeling, angiography frequently fails to detect the early stages of atherosclerosis. Although positively remodeled lesions do not restrict blood flow, they may be unstable and may contribute to the onset of acute coronary syndromes [30]. Furthermore, because putative sites of stenosis are compared with an apparently normal arterial segment, angiography often fails to detect diffuse disease in which a large portion of the artery is impacted by atherosclerotic disease. Both positive remodeling and diffuse disease are common in atherosclerotic progression and may be determinants of clinical outcome.

Also, the assessment of angiograms is solely visual and, consequently, subject to significant variation in image interpretation (observer bias) which may lead to a significant underestimation of lesion severity [30].

Assessing the atheroma dimensions by coronary angiography (CA) has been more recently surpassed by new methods for cardiovascular imaging using ultrasound [28,29,31] and multislice CT [32-34], which allow a more accurate and complete imaging of atherosclerotic coronary vessels.

### 1.3. Intravascular ultrasound

Intravascular ultrasound (IVUS), a catheter-based technique that provides high resolution cross-sectional images of the coronary vessel *in vivo*, is a tomographic technique that permits two-dimensional visualization of the arterial wall and allows further characterization of its individual layers. Thus, IVUS is a unique imaging modality for the direct examination of vessel dimensions and arterial wall characteristics in live subjects.

The coronary artery is inspected by a catheter incorporating a miniature ultrasound transducer, which emits high-frequency ultrasound, usually in the range of 20 to 50 MHz providing an axial resolution of about 100–200  $\mu\text{m}$ . Lateral resolution of the ultrasonic waves is less specific and may vary depending on imaging depth and beam width, averaging around 250  $\mu\text{m}$  [35].

Given their proximity to the plaque, intravascular catheters have the inherent advantage of a high signal-to-noise ratio [3]. The information obtained through IVUS imaging depicts the morphological characteristics of the atheromatous plaque and is used to illustrate the geometrical configuration of its layers and architecture. Most clinical centers use a pullback system to withdraw the catheter at a constant rate of 0.5 mm/s following its initial deployment distal to the area of interest. As the transducer is moved through the artery, ultrasonic reflections are electronically converted to cross-sectional images [31]. This IVUS modality is called “virtual histology” IVUS (IVUS-VH) and allows the identification of the composition of atherosclerotic plaques by discriminating varying echolucent regions within the atheroma [12]. Four plaque components, fibrotic, fibro-fatty, calcification and necrotic core, can be identified as they exhibit a defined radiofrequency spectrum, which can be analyzed and mathematically transformed into a color-coded representation of the plaque composition [36].

Therefore, IVUS imaging delivers precise geometric measurements of the coronary wall and lumen and enables the identification of different types of plaques according to their content in lipid, fibrin calcium and necrotic tissues [12,32,37,38]. The evaluation of lipid deposits contents commonly associated to vulnerable plaques and positive remodeling has been used to assess lesion severity [39]. In addition, three-dimensional IVUS image reconstruction is possible and is essential for proper assessment of the longitudinal distribution of the plaque [36], because multiple plaque morphologies varying from a fibrotic stable plaque to sites containing large lipids/necrotic cores can be found in a single arterial segment.

Because of its methodology, IVUS is not subject to the same limitations as angiography. Not only is IVUS more sensitive than angiography for the detection of stenosis, it can also identify diffuse disease and positive remodeling of the vessel wall. Furthermore, since IVUS allows the identification of morphologic characteristics of vulnerable plaques, it may be helpful in the characterization of atherosclerotic plaque formation [31,40] and in the detec-

tion of plaques with a high risk of spontaneous rupture [31]. However, coronary angiography is still regarded by many as the principal imaging technique for guiding coronary interventions. Recently, the correlation of coronary artery geometric measurements using both CA and IVUS has been reported [41-43], calling the attention for the value of IVUS alone or in conjugation with VH as precise measurements of plaque geometric parameters and tissue histological characteristics can be obtained with this modality.

## 2. Methods

### 2.1. Study design and participants

Individual data and blood samples were obtained from patients enrolled in a prospective study performed at the Cardiology Service of Santa Marta Hospital (CHLC, Lisbon, Portugal). The study was designed to investigate the association of circulating levels of ox-LDL, TNF- $\alpha$ , sFasL and T-lymphocytes with angiographic data and atherosclerotic plaque morphological and biological characteristics.

Patients, men and women aged between 56 and 71 years old with suspected and known coronary artery disease were included in the study. A total of 35 subjects were eligible to participate: 4 patients with ST-elevation myocardial infarction (STEMI), 7 patients with non-ST elevation myocardial infarction (NSTEMI), 11 stable angina (SA) patients, 10 unstable angina (UA) patients and 3 silent ischemia patients (SI). All patients underwent standard diagnostic procedures and treated accordingly. Acute coronary syndrome patients were enrolled in the first 24 hours of hospital admission, although the time period from the onset of chest pain to the intervention was less than 9 hours for the majority of them. Demographic information and history, including traditional risk factors for CAD were obtained at study entry. Evaluations included cardiac testing and imaging, cardiac characteristics and procedures, such as angioplasty and stenting. Coronary angiography and IVUS-VH data was recorded. One pre-specified study lesion was identified in each patient. An anatomical segment containing the entirety of the study lesion was then selected, which could be easily identified based on standard anatomical landmarks on two modalities (CA and IVUS-VH). All patients received standard care therapy after discharge including dual antiplatelet therapy after angioplasty.

Subjects with age above 85, significant co-morbidities as peripheral artery disease or carotid artery disease, known antecedents of malignance or infectious diseases, chronic renal insufficiency, concurrent inflammatory disorders, malignant neoplasm or infection and previous myocardial infarction in the previous 5 years were not enrolled. Also, patients were ineligible if coronary anatomy was inappropriate for IVUS.

The study protocol was approved by the CHLC Ethical Committee board and all patients signed an informed consent accepting their participation before study enrollment.

### 2.2. Patient characterization

All subjects were characterized demographically, clinically and biochemically (Table I).

Diabetes was diagnosed on the basis of fasting plasma glucose concentration  $\geq 7.0$  mmol/l (126 mg/dl) or 2h plasma glucose  $\geq 11.1$  mmol/l (200 mg/dl) or confirmed as clinically known and treated diabetes mellitus. Subjects were diagnosed hypertensive if they were documented to have systolic blood pressure  $\geq 140$  mmHg and/or diastolic blood pressure  $\geq 90$  mmHg or were already on anti-hypertensive therapy. Dyslipidaemia was identified in subjects who had total serum cholesterol level  $\geq 190$  mg/dl and/or serum triglycerides  $\geq 180$  mg/dl or were on lipid-lowering medication. Smoking was defined as the inhaled use of cigarettes, cigars or pipes in any quantity. Subjects who smoked within the previous year were also defined as smokers.

Patients characterization		
<b>Demographics</b>	Male sex (n, %)	23, 66
	Age (y)	63 (56 – 71)
	Weight (kg)	75 (67 – 80)
	Height (m)	1.7 (1.6 – 1.7)
	BMI (kg/m <sup>2</sup> )	27.3 (23.7 – 29)
<b>Risk factors / Co-morbidities</b>	Smoking (n, %)	6, 34
	Hypercholesterolemia (n, %)	25, 71
	Arterial hypertension (n, %)	25, 71
	Diabetes mellitus (n, %)	8, 23
<b>Previous medication</b>	Aspirin (n, %)	18, 51
	ACE Inhibitors (n, %)	16, 46
	Anti-platelets (n, %)	14, 40
	$\beta$ - blockers (n, %)	15, 43
	Statins (n, %)	25, 7
<b>Biochemical analysis</b>	Total cholesterol (mg/dl)	156 (133 – 188)
	LDL (mg/dl)	104 (82 – 127)
	HDL (mg/dl)	36 (27 – 45)
	Triglycerides (mg/dl)	85 (59 – 127)
	Glucose (mg/dl)	111 (95 – 137)
	Leucocytes ( $\times 10^3/\mu\text{l}$ )	6.8 (5.4 – 8.5)
	Neutrophils ( $\times 10^3/\mu\text{l}$ )	4.4 (3.3 – 5.7)
	Lymphocytes ( $\times 10^3/\mu\text{l}$ )	1.8 (1.3 – 2.7)
	Monocytes ( $\times 10^3/\mu\text{l}$ )	0.5 (0.3 – 0.8)
	Platelets ( $\times 10^3/\mu\text{l}$ )	190 (156 – 235)
	CK (U/l)	84 (47 – 169)
	CRP (mg/l)	5.3 (2.5 – 18.4)
Pro-BNP (pg/ml)	203 (64 – 916)	

**Table 1.** Patients demographic, clinical and biochemical characterization. Results are presented in median (Q25 – Q75) unless otherwise specified.

### 2.3. Percutaneous angiography

All patients were clinically evaluated for the extension of coronary artery disease through the characterization of lesion morphology to define the coronary stenosis, the number of diseased vessels, the thrombolysis in myocardial infarction (TIMI) risk score, which refers to the level of coronary blood flow assessed during coronary angiography (ranging from 3 – complete perfusion, to 0 – total occlusion), lesion length and the presence of calcium and/or thrombi in the lesions. The number and type of stents positioned in patients undergoing coronary angiography were also recorded. A coronary stenosis was considered clinically significant (high-grade) as a  $\geq 70\%$  narrowing in the luminal diameter. Multivessel disease was defined when more than one major coronary artery presented high-grade stenosis: left anterior descending artery (LAD); right coronary artery (RCA); left circumflex artery (LCX).

Patients angiographic characterization		
Stenosis (%)		87.5 (70 – 91)
Lesion length (mm)		18.5 (13– 28)
Multivessel (n, %)		6, 19
Diseased vessels (n, %)	0	4, 11
	1	20, 57
	2	7, 20
	3	2, 6
	4	2, 6
Lesions (n, %)	0	4, 11
	1	17, 49
	2	6, 17
	3	2, 6
	4	4, 11
Culprit vessel (n, %)	LAD / TC	20, 61
	RCA	11, 31
	LCX	2, 6
TIMI score (n, %)	0	1, 3
	3	26, 74
Lesion type (n, %)	A	3, 9
	B	17, 49
	C	2, 6
Lesion morphology (n, %)	Concentric	5, 14
	Eccentric	20, 57

**Table 2.** Patients angiographic characterization. Results are presented in median (Q25–Q75) unless otherwise specified.

The extent (severity) of CAD was assessed following a graded angiographic system based on previous reports by others [43, 44]. The number of diseased vessels, number of lesions, culprit lesion and TIMI were the contributing parameters. The severity score was calculated on the basis of the sum of individual scores assigned to each parameter assuming normal



arteries as grade "0": a) each vessel with  $\geq 70\%$  stenosis lesions contributed as 2, and vessels with  $< 70\%$  stenosis lesions contributed as 1; b) each lesion treated contributed as 1; c) the most severe lesions were graded 3 when occurring in LAD, 2 in RCA and 1 in LCX; d) the TIMI values contributed as 0 = no occlusion to 3 = total occlusion.

#### **2.4. Intravascular ultrasound (IVUS)**

The IVUS-VH acquisition was performed using a EagleEye catheter (20 MHz) at pullback speed of 0.5 mm/sec. The IVUS data was recorded for the reconstruction of the radiofrequency backscatter information using In-Vision gold commercial software (Volcano Corporation, USA).

For each lesion, vessel and lumen area data were obtained for every cross-section throughout the region of interest and lesion borders were established using the leading edges of external elastic lamina (EEL) and the luminal contour. Minimal lumen diameter and reference diameter were measured and percentage of diameter stenosis was calculated. The composition of coronary atheroma was assessed using spectral analysis of backscatter RF signals. The percentages of fibrotic, fibro-fatty, calcified and necrotic core were assessed. Atheroma area and volume were obtained after EEL and lumen diameter (LD) measures were completed at the lumen/plaque boundary and at the media/adventitia boundary in each cross-section forming the region of interest.

Atheroma or plaque area (PA) was determined as the difference between EEL and lumen areas. The plaque burden was calculated as the plaque cross sectional area divided by the EEL area and multiplying by 100. IVUS measurements were recorded at three different regions-of-interest of the selected lesion: larger stenosis region cross-section and distal and proximal cross-sections. Median values and 25% and 75% quartile intervals for the various parameters measured and/or calculated are listed in Table 3.

#### **2.5. Blood sampling and laboratory assays**

Peripheral blood was drawn from all patients into blood collection tubes (Vacuette) with appropriate anti-coagulant, and centrifuged at 2500 rpm for 10 minutes. Serum and plasma were collected and stored at  $-80^{\circ}\text{C}$  until analysis, for a period not exceeding 6 months. Samples were thawed only once.

Levels of glucose, creatinine kinase, troponin T, N-terminal pro-brain natriuretic peptide (NT-proBNP) and C-reactive protein (CRP), blood cells count and lipid profile were routinely measured in the hospital. Plasma concentrations of ox-LDL and sFasL and serum concentrations of TNF- $\alpha$  were measured by enzyme-linked immunosorbent assays (ELISA) commercial kits (R&D Systems).

All the assays were performed according to the manufacturer's recommendations. Each sample was measured in duplicate; intra-assay variation among the duplicates for all samples was  $< 10\%$ .

Lymphocyte populations were analyzed by flow cytometry (FASCalibur, BD) in whole blood lysed with lysing solution (BD). The following antibodies were used: PerCP mouse anti-human CD45 (2D1, BD Pharmigen), FITC mouse anti-human CD3 (HIT3a, BD Pharmigen), APC mouse anti-human CD4 (RPA-T4, BD Pharmigen), PE mouse anti-human CD8 (RPA-T8, BD Pharmigen).

Atherosclerotic plaque characterization			
Stenosis (%)	Larger stenosis region		77.6 (65 – 84)
	Proximal region		49 (40 – 58)
	Distal region		48.1 (37 – 59.5)
Fibrotic tissue (%)	Larger stenosis region		58.5 (51 – 75)
	Proximal region		61.7 (48 – 75.5)
	Distal region		59 (43 – 74.5)
Fibro-fatty tissue (%)	Larger stenosis region		9.6 (6.4 – 18)
	Proximal region		13 (5 – 17.5)
	Distal region		9 (4.7 – 20)
Calcified tissue (%)	Larger stenosis region		11 (2.7 – 17)
	Proximal region		6 (0.3 – 14.2)
	Distal region		12.8 (0.5 – 22)
Necrotic core (%)	Larger stenosis region		16.5 (8 – 22)
	Proximal region		17.4 (8 – 24)
	Distal region		16.5 (10 – 24)
Lumen	diameter (mm)	Minimum	2.1 (1.8 – 2.3)
		Maximum	2.4 (2.1 – 3)
		Median	2.2 (1.9 – 2.7)
	area (mm <sup>2</sup> )	3.8 (2.9 – 5.1)	
External elastic lamina	diameter (mm)	Minimum	4.3 (4 – 4.6)
		Maximum	4.9 (4.5 – 5.1)
		Median	4.6 (4.2 – 4.9)
	area (mm <sup>2</sup> )	17.2 (15 – 19)	
Plaque area (mm <sup>2</sup> )		13 (10 – 15)	
Plaque burden (%)		77.4 (65 – 84)	

**Table 3.** Atherosclerotic plaque measurements obtained by IVUS-VH. Results of the plaque morphology and composition are presented in median (Q25 – Q75).

## 2.6. Statistical analysis

Data were summarized and represented (box-plots) as median and inter-quartiles 25% and 75% (Q25-Q75) for continuous variables and as proportions for categorical variables. Non-continuous variables were analyzed using a 2x2 table and  $\chi^2$  test. Continuous varia-

bles, such as plaque measures at proximal, distal and larger stenosis region cross-sections of the plaque, transformed into categorical variables based on median values. Differences between classes of variables were compared using a Mann-Whitney test. Associations between variables, angiographic data and IVUS measures were evaluated using non-parametric Spearman correlations.

The calculations were performed using SPSS (v. 19.0, IBM 2010) and linear regressions were made using OriginLab (v. 7.5 SR6, OriginLab Comp, 2006).

### 3. Results

The atherosclerotic plaque physical characteristics and composition obtained by IVUS were studied and related with the severity of CAD following CA scores. These parameters were also associated with plaque-related oxidative and inflammation bio-indicators measured in the blood. The inter-relations between the parameters measured are described below.

#### 3.1. Analysis of plaque components along the lesion

The composition of the plaque along its length in terms of fibrotic, fibro-fatty, necrotic and calcified tissues assessed by IVUS-VH can be inferred from data listed in Table 3. Measurements were carried out along the plaque at three plaque regions. Therefore, larger stenosis region, proximal and distal cross-sections were studied.

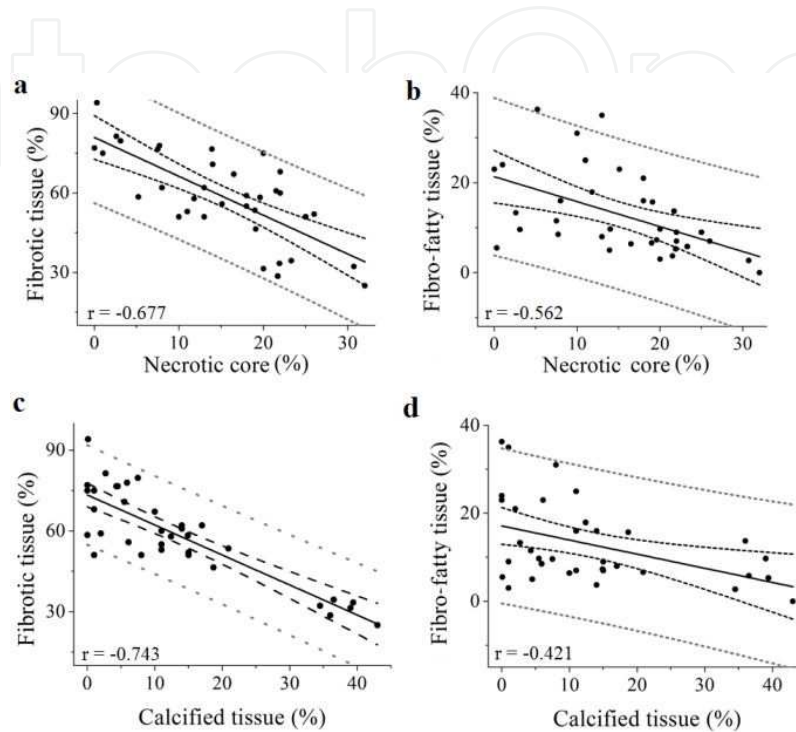
The variations observed between proximal, distal and larger stenosis region cross-sections did not reach statistical significance, although major variations were also observed in fibro-fatty and calcified tissues. To further analyze the plaque composition, the associations between the fibrotic, fibro-fatty, calcified and necrotic components of the plaque were assessed.

In the overall, high fibrotic and fibro-fatty tissue contents were correlated to low content of calcified tissue and low necrotic core (Fig. 1).

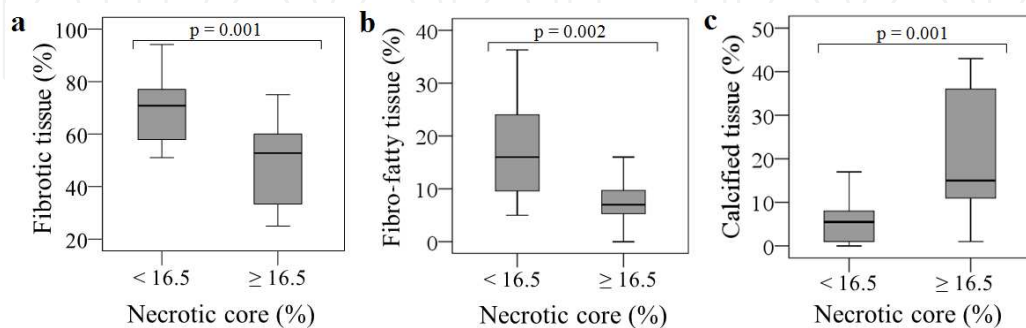
The necrotic core content was positively correlated with calcified tissue ( $r=0.675$ ,  $p<0.001$ ). The correlation values were more representative in the region with larger stenosis, although the associations were observed in proximal and distal cross-sections.

Categorizing the plaque necrotic core and calcified tissue contents by the median value, it was confirmed that these two components were significantly associated with the fibrotic and fibro-fatty tissues. Plaques with large areas of necrotic core ( $\geq 16.5\%$ ) had low percentage of fibrotic ( $p=0.001$ ) and fibro-fatty ( $p=0.002$ ) tissues and these levels were significantly different from those in plaques with necrotic core  $<16.5\%$ . Moreover, the percentage of calcium content increased in plaques with necrotic core content  $\geq 16.5\%$  relative to plaques with necrotic core below  $16.5\%$  ( $p=0.001$ ) (Fig. 2). These differences were valid and equally significant along the plaque length, i.e. for distal, proximal and larger stenosis region cross-sections.

However, when the plaque components were analyzed relative to the calcified tissue content of plaques (cut-point and median value of 11%) only the plaque fibrotic content could be discriminated in the larger stenosis region (Q25-Q75=58.8-77.5% fibrotic tissue for calcified tissue <11%; Q25-Q75=33.1-58.7% fibrotic tissue for calcified tissue  $\geq$ 11%;  $p < 0.001$ ).



**Figure 1.** Correlation of necrotic core (a and b) and calcified tissue (c and d) with fibrotic tissue ( $r = -0.677$ ,  $p < 0.001$  and  $r = -0.743$ ,  $p < 0.001$ , respectively) and fibro-fatty tissue ( $r = -0.562$ ,  $p < 0.001$ ,  $r = -0.421$  and  $p = 0.012$ , respectively) in the larger stenosis region. Solid line represents the linear regression, black dashed lines represent 95% confidence bands and grey dashed lines represent prediction bands.

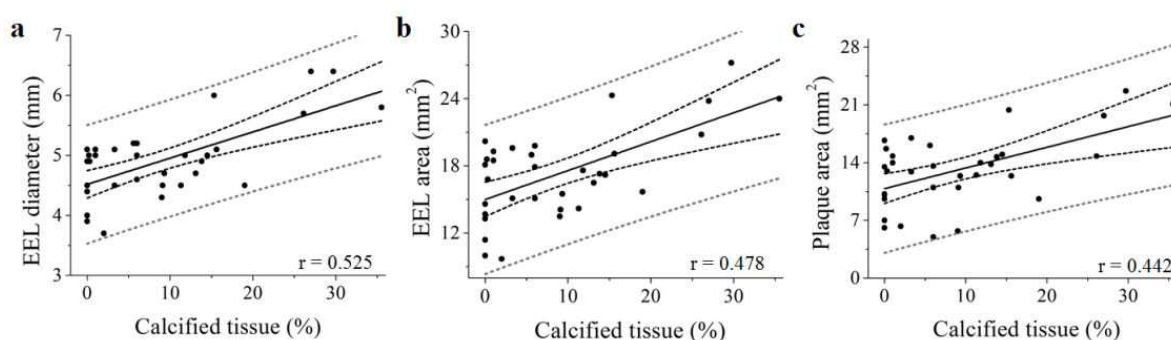


**Figure 2.** Box-plots of plaque content in fibrotic (a), fibro-fatty (b) and calcified (c) tissues according to the necrotic core levels <16.5% and  $\geq$ 16.5% in the larger stenosis region.

### 3.2. Association between plaque components and plaque morphology

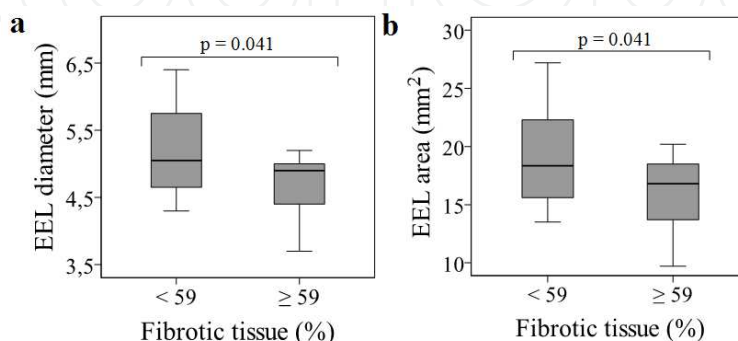
Measures of the EEL diameter and area, lumen diameter and area, plaque area and plaque burden were related with the plaque composition in order to assess whether the correlations between these parameters could identify plaque types. It was observed that associations between morphology and components of the plaque varied along the lesion. The relationship between the plaque content in calcified and fibrotic tissues and plaque morphology was only verified in proximal cross-sections of the plaques.

It was observed that the calcified tissue content was positively correlated with the EEL diameter ( $r=0.525$ ,  $p=0.001$ ), the EEL area ( $r=0.478$ ,  $p=0.004$ ) and plaque area ( $r=0.442$ ,  $p=0.008$ ) in proximal cross-sections (see Fig. 3).



**Figure 3.** Correlation of calcified tissue content in the proximal region with EEL maximum diameter (a) and plaque area (b). Solid line represents the linear regression, black dashed lines represent 95% confidence bands and grey dashed lines represent prediction bands.

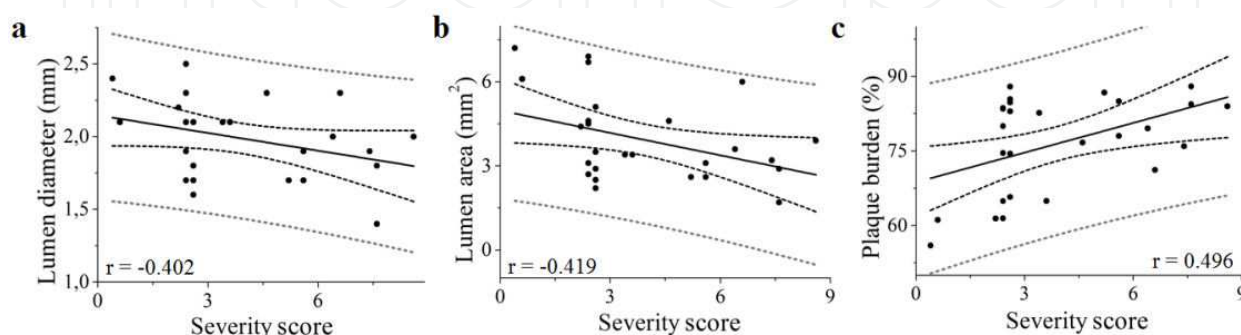
Also in the proximal region of the plaques, the fibrotic content discriminated plaque sizes as expressed by the EEL diameter and area. Both EEL diameter and area were significantly higher for fibrotic tissue percentages below median value ( $<59\%$ ) by report to plaques with fibrotic tissue percentages above median ( $p=0.041$ ) (Fig. 4).



**Figure 4.** Variations of EEL diameter (a) and area (b) according to fibrotic content  $<59\%$  and  $\geq 59\%$  in the proximal region.

### 3.3. Coronary angiography data versus IVUS measures

The IVUS-derived measures of coronary atherosclerotic plaques were evaluated having into account the severity score established with angiographic data. Severity of CAD was found to be unambiguously associated to vessel lumen decrease and increased plaque burden. The severity score was negatively correlated with the plaque geometry IVUS VH-derived measures, such as lumen diameter ( $r=-0.402$ ,  $p=0.038$ ) and lumen area ( $r=-0.419$ ,  $p=0.03$ ), and positively correlated with plaque burden ( $r=0.496$ ,  $p=0.009$ ) as can be depicted in Fig. 5.



**Figure 5.** Correlation of angiographic severity with IVUS-derived measures of the atherosclerotic plaque: a) lumen diameter; b) lumen area; and c) plaque burden. Solid line represents the linear regression, black dashed lines represent 95% confidence bands and grey dashed lines represent prediction bands.

### 3.4. Association of soluble biomarkers and T-cells with IVUS and angiography derived measures

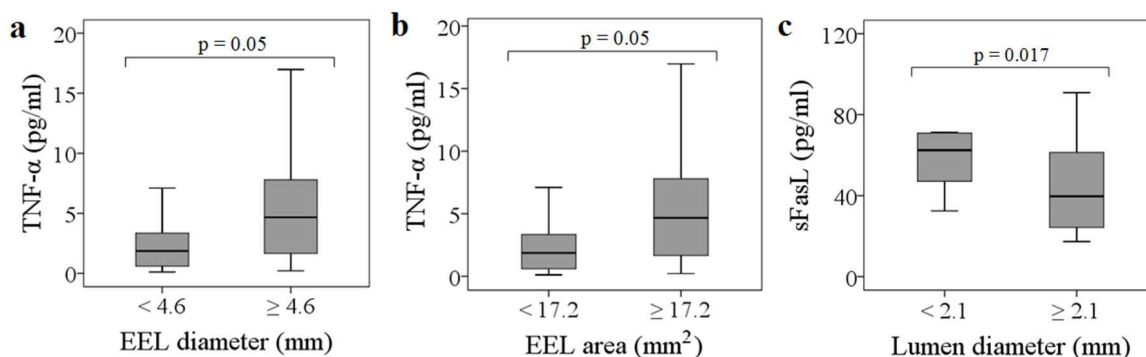
The relationship between the levels of indicators of oxidation and inflammation in the blood circulation with IVUS- and angiography-derived measures of the atherosclerotic plaque was examined with the aim of establishing relevant associations between biomarkers and plaque type.

Indicators of the inflammatory process associated to cell activation and apoptosis, such as TNF- $\alpha$  and sFasL, were determined. Also the concentration of ox-LDL in circulation was assessed as a measure of plaque outflow and inflammation. The variations observed in the concentration levels of these parameters were studied relative to the plaque IVUS-derived measures and angiographic data and severity score.

Several associations were observed between the plaque morphology and components, such as fibrotic, fibro-fatty and necrotic core, with CD4<sup>+</sup> and CD8<sup>+</sup> T-cell populations and TNF- $\alpha$ , sFasL and ox-LDL concentrations in the blood circulation. Due to the limited number of patients enrolled in this prospective study and to improve statistical results enabling the concurrent evaluation of IVUS and angiographic data, including the severity score, IVUS variables (see variables listed in Table 3) were categorized using the median value as cut-off point.

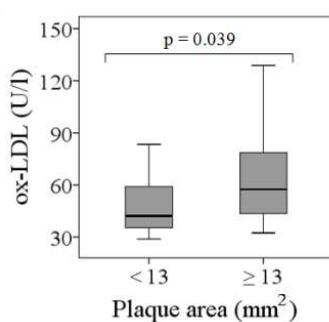
Following this procedure, and in what concerns soluble biomarkers, it was observed that sFasL, TNF- $\alpha$  and ox-LDL levels in circulation were strongly associated to the median values of lumen and plaque dimensions.

The concentration of TNF- $\alpha$  significantly increased for large plaque areas, as expressed by EEL diameter and area ( $p=0.05$  in both cases), whereas sFasL concentrations increased with diminished lumen diameters ( $p=0.017$ ), as can be depicted in Fig. 6.



**Figure 6.** Box-plot representation of the TNF- $\alpha$  and sFasL concentrations relative to indicators of plaque dimensions: a) EEL diameter categories <4.6 mm and  $\geq 4.6$  mm; b) EEL area categories <17.2 mm<sup>2</sup> and  $\geq 17.2$  mm<sup>2</sup>; c) Lumen diameter categories <2.1 mm and  $\geq 2.1$  mm

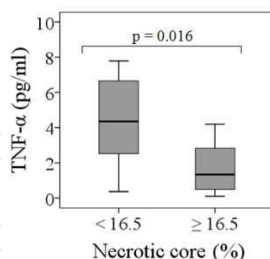
The concentrations of ox-LDL in plasma were significantly associated with plaque area as can be depicted in Fig. 7. Large plaque areas, above median value (area  $\geq 13$  mm<sup>2</sup>), were associated with high ox-LDL concentrations whereas plaque areas below 13 mm<sup>2</sup> were associated with low ox-LDL concentrations, and the differences between median concentration values of ox-LDL in the two groups were significant ( $p=0.039$ ).



**Figure 7.** Box-plot representation of ox-LDL concentrations according to plaque area categories <13 mm<sup>2</sup> and  $\geq 13$  mm<sup>2</sup>.

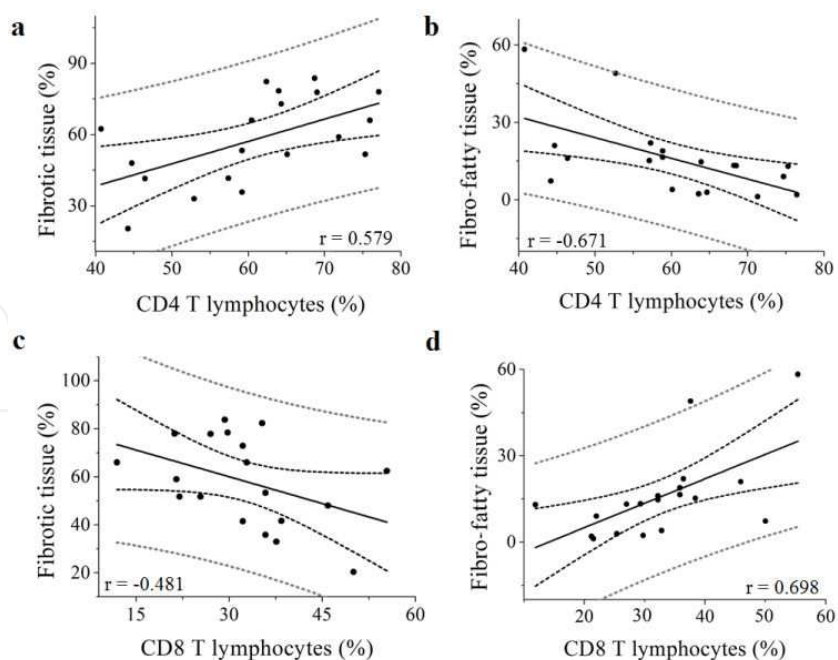
Concerning the plaque components, only the necrotic content assessed in the plaque region with larger stenosis could be associated with TNF- $\alpha$  concentration in circulation. High concentrations of TNF- $\alpha$  were associated with low necrotic core contents contrasting with the

significantly lowered TNF- $\alpha$  concentrations ( $p=0.016$ ) observed in plaques with large necrotic cores ( $\geq 16.5\%$ ) (Fig. 8)



**Figure 8.** Box-plot representation of TNF- $\alpha$  concentrations according to the necrotic core categories in the larger stenosis region, <16.5 % and  $\geq 16.5$  %.

In what concerns T-cell CD3<sup>+</sup> populations expressing CD4 and CD8, it was observed that the percentage of T-cells expressing CD3CD8 were associated with the plaque dimensions (T-cell CD3<sup>+</sup>CD8<sup>+</sup> vs EEL diameter  $r=-0.518$ ,  $p=0.019$ ; T-cell CD3<sup>+</sup>CD8<sup>+</sup> vs EEL area  $r=-0.530$ ,  $p=0.016$ ). T-cells, both CD3<sup>+</sup>CD4<sup>+</sup> and CD3<sup>+</sup>CD8<sup>+</sup>, were correlated with the plaque fibrotic and fibro-fatty tissue components along the plaque length, i.e. from distal to proximal regions. Likely, CD3<sup>+</sup>CD4<sup>+</sup> lymphocytes were positively correlated with fibrotic tissue ( $r=0.579$ ,  $p=0.009$ ) whereas CD3<sup>+</sup>CD8<sup>+</sup> cells were negatively correlated ( $r=-0.481$ ,  $p=0.037$ ) (see Fig. 9 a and c).



**Figure 9.** Correlation between plaque fibro-fatty and fibrotic tissue content and CD4<sup>+</sup> and CD8<sup>+</sup> T lymphocytes. Solid line represents the linear regression, black dashed lines represent 95% confidence bands and grey dashed lines represent prediction bands.



An opposite relationship was found between fibro-fatty tissue component and CD3<sup>+</sup>CD4<sup>+</sup> lymphocytes (Fig. 9 b and d). The CD3<sup>+</sup>CD4<sup>+</sup> lymphocytes were negatively correlated with fibro-fatty tissue ( $r = -0.671$ ,  $p = 0.002$ ) and CD3<sup>+</sup>CD8<sup>+</sup> were positively correlated ( $r = 0.698$ ,  $p = 0.001$ ).

#### 4. Discussion

This prospective study showed that plaque composition is related to plaque morphology and these characteristics were associated with the concentration of biomarkers in blood circulation.

Plaques with higher content in necrotic core showed lower fibrotic and fibro-fatty contents and larger areas of calcified tissue. Increased EEL diameter and area were associated to larger fibrotic and calcium contents, linking these two components to plaques protruding in the vessel wall rather than high-stenosis regions. Together these observations suggest that plaque vulnerability is not strictly linked to high-grade stenosis. Also the angiographic disease severity score was associated with plaque burden. This is in agreement with previous studies demonstrating that plaque ruptures typically occur in large and complex plaques [1,30], and that coronary calcification is associated to acute coronary syndromes [37] and independently predicts all-cause mortality in CAD in addition to traditional risk factors [46]. Prior studies reported that shear stress and circumferential wall stress play an important role in plaque rupture [47]. Sano *et al.* [31] demonstrated that the percentage of fibrous area was the most sensitive parameter for classifying the plaques causing acute coronary syndrome. Also the percentage of lipid area was significant in the classification of vulnerable plaques [31]. Evidences are accumulating by coronary angiography and IVUS and other imaging modalities showing that plaque complexity associates to vulnerable plaques [11,31,37]. Therefore, to differentiate vulnerable plaques from stable plaques, the fragile part of the atheromatous plaque is of major interest and both tissue characteristics of coronary plaques and mechanical stresses on coronary plaques should be taken into account.

Plaque rupture is related to the process in which fibrous caps over lipid core become fragile [3]. Several *in vitro* studies support that continuous inflammatory stimulus in the plaque driven by the infiltration of monocytes, macrophages and T-lymphocytes in the lesion, ultimately lead to disintegration of foam cells, and release of cytokines, such as TNF- $\alpha$ , and matrix metalloproteinases [6,7,18-20]. All this causes the destabilization of plaque lipid rich cores and the thinning of the fibrous cap [3,8].

We have previously demonstrated [48] that the susceptibility of a plaque to rupture is not strictly linked to significant stenosis. This prospective study supports our previous findings as positive associations between plaque dimensions i.e., EEL diameter and area independent of high-stenosis regions, and the concentrations of TNF- $\alpha$  were found. TNF- $\alpha$  is involved in endothelial cells activation and in the inflammatory response amplification [9,20]. Increasing levels of this pro-inflammatory cytokine promote a continuous systemic inflammatory stimulation that can trigger and/or amplify local inflammatory responses and therefore express

the extent of vascular inflammation. Also the relationship found between TNF- $\alpha$  concentration in blood and the percentage of necrotic core area suggests an association between an exacerbation of inflammation and the thinning of the fibrous cap with increases of fibrous and fibro-fatty areas as plaque evolves [30,31].

In addition the process of apoptosis is an important mechanism in the pathophysiology of atherosclerosis. Atherosclerotic plaques include large numbers of apoptotic cells and related receptors, such as FasL, which is a type II membrane protein that induces apoptosis when it binds to its membrane receptor Fas. FasL is expressed by activated T lymphocytes, as well as endothelial cells [49]. It was observed in this study that decreases of lumen diameter as occurring in disease exacerbation, favored the elevation of sFasL in circulation. This supports the view that one of the control mechanisms elicited by FasL in CAD may be the prevention of inflammation by destruction of the activated inflammatory cells invading vascular tissues via FasL/Fas-mediated apoptosis [49,50]. In fact, in this study the percentage of T-cells expressing CD4 and CD8 were associated to the percentage of fibrous and fibro-fatty area reinforcing the notion that Th1 cellular immunity is taking place during the disease process [6]. Also, the opposite relationship between the percentage of CD4<sup>+</sup> and CD8<sup>+</sup> T-cells and the plaque percentage of fibrous and fibro-fatty areas, as observed in this study call the attention for the balanced action of these immune cells in CAD. However, the role of specific immune responses has remained unclear. Evidence is accumulating that T-cells homing the vessel wall contribute to inflammation [6,9] and that T-cell expressing CD4 promote atherosclerosis particularly when activated by LDL modified by oxidative processes [26,27]. The T-cells expressing CD8, when activated, trigger caspase pathways. However, CD4<sup>+</sup> and CD8<sup>+</sup> T produce different effectors molecules and then effect different cells and pathways, although redundancy of mechanisms has been described pointing to the importance of lymphocyte homeostasis in disease.

The positive association of plaque area with ox-LDL concentrations in plasma can also be considered a marker of plaque instability and/or plaque rupture [51,52] in addition to disease severity. Extensive experimental data shows that ox-LDL is formed in the arterial wall [14,16] contributing to the plaque progression. It is accepted that ox-LDL in circulation is originated in the vessel wall, being their circulating levels strongly associated to angiographically documented CAD [25]. Increases in plaque area, and therefore in regions where lumen decreases relative to circumferential EEL, may favor plaque outflow. In these regions the vessel wall is exposed to shear stress that may contribute to endothelial denuding and plaque cap erosion [47].

The current forms of imaging enable atherosclerosis assessment at the later stage when the vascular morphology has changed dramatically. However, the evaluation of plaque characteristics by angiography and IVUS-VH was associated to circulating biomarkers levels, and these indicators may reflect plaque vulnerability. The *in vivo* identification of plaque vulnerability whether by characterizing its components or by providing measures of oxidative and inflammation markers may improve diagnostic and eventually allow the detection of vulnerable atheroma before rupture. The relations among the plaque components – fibrotic, fibro-fatty calcified and necrotic core – and plaque dimensions, may be important in the

characterization of the plaque and in the assessment of its development. Also, circulating ox-LDL, sFasL, TNF- $\alpha$  and lymphocyte populations may be viable targets to follow as they may reflect the global extent of atherosclerosis and may provide useful information on patient's evolution, together with quantitative angiography-derived plaque parameters. The approach may be incorporated in carefully designed clinical studies for the assessment of coronary atherosclerosis.

## 5. Study limitations

This prospective study is a single-centre study that has a number of limitations. The small number of patients enrolled did not allow association of parameters with clinical presentation. The measurements of biomarkers that entered into the study do not reflect chronic circulating levels, as more than 50% of patients presented with acute coronary syndromes (STEMI, NSTEMI and UA), which transiently alters levels of inflammatory biomarkers. Some of the measurements may be confounded by concomitant treatments (medication, stenting, etc.), which could not be estimated due to the reduced number of patients. We also wish to emphasize that all angiography and IVUS studies are limited to the analysis of a relatively short segment of coronary arterial tree that does not fully reflect disease characteristics elsewhere. The results obtained of plaque components were not confirmed by histology or other diagnostic modalities, such as optical coherent tomography.

## 6. Conclusions

The present study using angiography and IVUS-VH revealed that the atherosclerotic plaque components and dimensions were related to the concentration of biomarkers in the blood circulation. We reported on the vascular tissue characteristics that may be associated with vulnerable plaques and the incremental value of biomarkers in addition to invasive imaging modalities.

The association of ox-LDL, sFasL and TNF- $\alpha$  circulating levels with lumen dimension and plaque dimension suggest that these indicators may express not only plaque rupture but plaque vulnerability as well. Also the association of TNF- $\alpha$  and T lymphocytes expressing CD4 and CD8 with plaque percentage of fibrous, fibro-fatty, and necrotic core areas may contribute to an *in vivo* assessment of vascular inflammation and vulnerable plaques and their detection before rupture.

The results suggest that these biomarkers have clinical implications for identifying vulnerable plaques as well as vulnerable patients. Further studies are needed to evaluate the impact of these biomarkers and angiography and IVUS-VH derived measures on clinical presentation.

## Acknowledgements

This work was supported by Fundação para a Ciência e Tecnologia (PIC/IC/82734/2007 and SFRM/BPD/6308/2009); and by Liga dos Amigos do Hospital de Santa Marta.

## Author details

Catarina Ramos<sup>1</sup>, Patrícia Napoleão<sup>2</sup>, Rui Cruz Ferreira<sup>3</sup>, Cristina Fondinho<sup>3</sup>, Mafalda Selas<sup>3</sup>, Miguel Mota Carmo<sup>4</sup>, Ana Maria Crespo<sup>4</sup> and Teresa Pinheiro<sup>1\*</sup>

\*Address all correspondence to: [murmur@itn.pt](mailto:murmur@itn.pt)

1 IST/ITN Instituto Superior Técnico, Universidade Técnica de Lisboa, Sacavém, Portugal

2 Unidade de Biologia Microvascular e Inflamação, Instituto de Medicina Molecular, Faculdade de Medicina da Universidade de Lisboa, Lisboa, Portugal

3 Serviço Cardiologia, Hospital Santa Marta, Centro Hospitalar Lisboa Central, Lisboa, Portugal

4 Centro de Estudos de Doenças Crónicas, Faculdade de Ciências Médicas, Universidade Nova de Lisboa & Serviço Cardiologia, Hospital Santa Marta Centro Hospitalar Lisboa Central, Lisboa, Portugal

CESAM & Departamento de Biologia Animal, Faculdade de Ciências da Universidade de Lisboa, Lisboa, Portugal

## References

- [1] Hoffmann U, Moselewski F, Nieman K, Jang IK, Ferencik M, Rahman AM, Cury RC, Abbara S, Joneidi-Jafari H, Achenbach S, Brady TJ, Noninvasive Assessment of Plaque Morphology and Composition in Culprit and Stable Lesions in Acute Coronary Syndrome and Stable Lesions in Stable Angina by Multidetector Computed Tomography, *Am Coll Cardiol* 2006; 47: 1655– 62
- [2] Red-Horse K, Ueno H, Weissman IL, Krasnow MA, Coronary arteries form by developmental reprogramming of venous cells, *Nature* 2010; 464: 549-553
- [3] Stone GW, Maehara A, Mintz GS, The Reality of Vulnerable Plaque Detection, *JACC: Cardiovascular Imaging* 2011; 4: 902-904
- [4] Roger VL, Go AS, Lloyd-Jones DM, Adams RJ, Berry JD, Brown TM, Carnethon MR, Dai S, de Simone G, Ford ES, Fox CS, Fullerton HJ, Gillespie C, Greenlund KJ, Hail-

- pern SM, Heit JA, Ho PM, Howard VJ, Kissela BM, Kittner SJ, Lackland DT, Lichtman JH, Lisabeth LD, Makuc DM, Marcus GM, Mozaffarian D, Mussolino ME, Nichol G, Paynter NP, Rosamond WD, Sorlie PD, Stafford RS, Turan TN, Turner MB, Wong ND, Wylie-Rosett J, Heart Disease and Stroke Statistics—2011 Update, *Circulation* 2011; 123: e18-e209
- [5] Ross R, Atherosclerosis — An Inflammatory Disease, *N Engl J Med* 1999; 340: 115-126
- [6] Libby P, Ridker PM, Hansson GK, Inflammation in Atherosclerosis: From Pathophysiology to Practice, *J. Am. Coll. Cardiol.* 2009; 54: 2129-2138
- [7] Galkina E, Ley K, Vascular Adhesion Molecules in Atherosclerosis, *Atherosclerosis* 2007; 27: 2292 - 2301
- [8] Vancraeynest D, Pasquet A, Roelants V, Gerber BL, Vanoverschelde JJ, Imaging the Vulnerable Plaque, *J Am Coll Cardiol* 2011; 57: 1961–79
- [9] Hansson GK, Inflammation, Atherosclerosis, and Coronary Artery Disease, *N Engl J Med* 2005; 352: 1685-95
- [10] Goldstein JL, Ross MS, Regulation of low-density lipoprotein receptors: implications for pathogenesis and therapy of hypercholesterolemia and atherosclerosis, *Circulation* 1987; 76: 504-507
- [11] Goldstein JA, Demetriou D, Grines CL, Pica M, Shoukfeh M, O'Neill WW, Multiple complex coronary plaques in patients with acute myocardial infarction, *New Engl J Med* 2000; 343: 915-22
- [12] Fayad ZA, Fuster V, Clinical imaging of the high-risk or vulnerable atherosclerotic plaque, *Circ. Res.* 2001; 89: 305-316
- [13] Choi SH, Chae A, Miller E, Messig M, Ntanios F, DeMaria AN, Nissen SE, Witztum JL, Tsimikas S, Relationship Between Biomarkers of Oxidized Low-Density Lipoprotein, Statin Therapy, Quantitative Coronary Angiography, and Atheroma Volume, *J Am Coll Cardiol* 2008; 52: 24-32
- [14] Greco TP, Conti-Kelly AM, Anthony JR, Greco Jr T, Doyle R, Boisen M, Kojima K, Pharm BA, Matsuura E, Lopez LR, Oxidized-LDL/ $\beta_2$ -Glycoprotein I Complexes Are Associated With Disease Severity and Increased Risk for Adverse Outcomes in Patients With Acute Coronary Syndromes, *Am J Clin Pathol* 2010;133:737-743
- [15] Bronas UG, Dengel DR, Influence of Vascular Oxidative Stress and Inflammation on the Development and Progression of Atherosclerosis, *Am J of Lifestyle Med* 2010; 4: 521 - 534
- [16] Tabas I, The Role of Endoplasmic Reticulum Stress in the Progression of Atherosclerosis, *Circ Res* 2010; 107: 839-850
- [17] van Gils JM, Derby MC, Fernandes LR, Ramkhelawon B, Ray TD, Rayner KJ, Parathath S, Distel E, Feig JL, Alvarez-Leite JI, Rayner AJ, McDonald TO, O'Brien KD,

- Stuart LM, Fisher EA, Lacy-Hulbert A, Moore KJ, The neuroimmune guidance cue netrin-1 promotes atherosclerosis by inhibiting the emigration of macrophages from plaques, *Nature Immunology* 2012; 13: 136–143
- [18] Mallat Z, Taleb S, Ait-Oufella H, Tedgui A, The role of adaptive T cell immunity in atherosclerosis, *J. Lipid Res.* 2009; 50: S364–S369
- [19] Keaney Jr JF, Immune Modulation of Atherosclerosis, *Circulation* 2011; 124: e559 - e560
- [20] Zerneck A, Weber C, Chemokines in the vascular inflammatory response of atherosclerosis, *Cardiovasc Res* 2010; 86: 192 – 201
- [21] An G, Wang H, Tang R, Yago T, McDaniel JM, McGee S, Huo Y, Xia L, P-selectin glycoprotein ligand-1 is highly expressed on Ly-6Chi monocytes and a major determinant for Ly-6Chi monocyte recruitment to sites of atherosclerosis in mice, *Circulation* 2008; 117: 3227–37
- [22] Viemann D, Barczyk K, Vogl T, Fischer U, Sunderkötter C, Schulze-Osthoff K, Roth J, MRP8/MRP14 impairs endothelial integrity and induces a caspase-dependent and independent cell death program, *Blood* 2007; 109: 2453-2460
- [23] Ray KK, Morrow DA, Sabatine MS, Shui A, Rifai N, Cannon CP, Braunwald E, Long-Term Prognostic Value of Neopterin: A Novel Marker of Monocyte Activation in Patients With Acute Coronary Syndrome, *Circulation* 2007; 115: 3071 - 3078
- [24] Lopes-Virella MF, Virella G, Clinical Significance of the Humoral Immune Response to Modified LDL, *Clin Immunol.* 2010; 134(1): 55–65
- [25] Tsimikas S, Brilakis ES, Miller ER, McConnell JP, Lennon RJ, Kornman KS, Witztum JL, Berger PB, Oxidized Phospholipids, Lp(a) Lipoprotein, and Coronary Artery Disease, *N Engl J Med* 2005; 353: 46-57.
- [26] Greco TP, Conti-Kelly AM, Greco Jr T, Doyle R, Matsuura E, Anthony JR, Lopez LR, Newer Antiphospholipid Antibodies Predict Adverse Outcomes in Patients With Acute Coronary Syndrome, *Am J Clin Pathol* 2009; 132: 613-620
- [27] Ludewig B, Freigang S, Jäggi M, Kurrer MO, Pei YC, Vlk L, Odermatt B, Zinkernagel RM, Hengartner H, Linking immune-mediated arterial inflammation and cholesterol-induced atherosclerosis in a transgenic mouse model, *Proc Natl Acad Sci U S A* 2000; 97: 12752–7
- [28] Peters RJ, Kok WE, Pasterkamp G, Von Birgelen C, Prins M, Serruys PW, Videodensitometric quantitative angiography after coronary balloon angioplasty, compared to edge-detection quantitative angiography and intracoronary ultrasound imaging, *Eur Heart J* 2000; 21: 654–661
- [29] Leber AW, Knez A, von Ziegler F, Becker A, Nikolaou K, Paul S, Wintersperger B, Reiser M, Becker CR, Steinbeck G, Boekstegers P, Quantification of Obstructive and

- Nonobstructive Coronary Lesions by 64-Slice Computed Tomography, *J Am Coll Cardiol* 2005; 46: 147-154
- [30] Böse D, von Birgelen C, Erbel R, Intravascular Ultrasound for the Evaluation of Therapies Targeting Coronary Atherosclerosis, *J Am Coll Cardiol* 2007; 49:925-32
- [31] Sano K, Kawasaki M, Ishihara Y, Okubo M, Tsuchiya K, Nishigaki K, Zhou X, Minatoguchi S, Fujita H, Fujiwara H, Assessment of Vulnerable Plaques Causing Acute Coronary Syndrome Using Integrated Backscatter Intravascular Ultrasound, *J Am Coll Cardiol* 2006; 47: 734-41
- [32] Springer I, Dewey M, Comparison of multislice computed tomography with intravascular ultrasound for detection and characterization of coronary artery plaques: a systematic review, *Eur J Radiol* 2009; 71: 275-82.
- [33] Gao D, Ning N, Guo Y, Ning W, Niu X, Yang J, Computed tomography for detecting coronary artery plaques: a meta-analysis, *Atherosclerosis* 2011; 219: 603-9.
- [34] van der Giessen AG, Toepker MH, Donnelly PM, Bamberg F, Schlett CL, Raffle C, Irlbeck T, Lee H, van Walsum T, Maurovich-Horvat P, Gijzen FJ, Wentzel JJ, Hoffmann U, Reproducibility, accuracy, and predictors of accuracy for the detection of coronary atherosclerotic plaque composition by computed tomography: an ex vivo comparison to intravascular ultrasound, *Invest Radiol*. 2010; 45: 693-701
- [35] Rodriguez-Granillo GA, García-García HM, Mc Fadden EP, Valgimigli M, Aoki J, de Feyter P, Serruys PW. In Vivo Intravascular Ultrasound-Derived Thin-Cap Fibroatheroma Detection Using Ultrasound Radiofrequency Data Analysis. *J Am Coll Cardiol* 2005; 46: 2038-42
- [36] Calvert PA, Obaid DR, O'Sullivan M, Shapiro LM, McNab D, Densem CG, Schofield PM, Braganza D, Clarke SC, Ray KK, West NEJ, Bennett MR, Association Between IVUS Findings and Adverse Outcomes in Patients With Coronary Artery Disease, *JACC: Cardiovascular Imaging*, 2011; 4: 894-901
- [37] Nakamura T, Kubo N, Funayama H, Sugawara Y, Ako J, Momomura S, Plaque characteristics of the coronary segment proximal to the culprit lesion in stable and unstable patients, *Clin. Cardiol*. 2009; 32: e9-e12
- [38] Stähr PM, Höfflinghaus T, Voigtländer T, Courtney BK, Victor A, Otto M, Yock PG, Brennecke R, Fitzgerald PJ, Discrimination of Early/Intermediate and Advanced/Complicated Coronary Plaque Types by Radiofrequency Intravascular Ultrasound Analysis, *Am J Cardiol*. 2002; 9: 19-23
- [39] Costa MA, Kozuma K, Gaster AL, van Der Giessen WJ, Sabate M, Foley DP, Kay I, Ligthart J, Thayssen P, van den Brand MJ, de Feyter PJ, Serruys P, Three dimensional intravascular ultrasonic assessment of the local mechanism of restenosis after balloon angioplasty. *Heart* 2001; 85: 73-79.
- [40] Amato M, Montorsi P, Ravani A, Oldani E, Galli S, Ravagnani PM, Tremoli E, Baldassarre D, Carotid intima-media thickness by B-mode ultrasound as surrogate of

- coronary atherosclerosis: correlation with quantitative coronary angiography and coronary intravascular ultrasound findings, *European Heart Journal*, 2007; 28: 2094–2101
- [41] Voros S, Rinehart S, Qian Z, Vazquez G, Anderson H, Murrieta L, Wilmer C, Carlson H, Taylor K, Ballard W, Karpaliotis D, Kalynych A, Brown C, Prospective Validation of Standardized, 3-Dimensional, Quantitative Coronary Computed Tomographic Plaque Measurements Using Radiofrequency Backscatter Intravascular Ultrasound as Reference Standard in Intermediate Coronary Arterial Lesions, *J Am Coll Cardiol Intv* 2011; 4: 198–208
- [42] Peters RJG, Kok WEM, Pasterkamp G, von Birgelen C, Prins M, Serruys PW on behalf of the PICTURE study group. Videodensitometric quantitative angiography after coronary balloon angioplasty, compared to edge-detection quantitative angiography and intracoronary ultrasound imaging. *Eur Heart J* 2000; 21: 654–661
- [43] Leber AW, Knez A, von Ziegler F, Becker A, Nikolaou K, Paul S, Wintersperger B, Reiser M, Becker CR, Steinbeck G, Boekstegers P, Quantification of Obstructive and Nonobstructive Coronary Lesions by 64-Slice Computed Tomography A Comparative Study With Quantitative Coronary Angiography and Intravascular Ultrasound. *J Am Coll Cardiol* 2005; 46: 147–54.
- [44] Naruko T, Furukawa A, Yunoki K, Komatsu R, Nakagawa N, Matsumura Y, Shirai N, Sugioka K, Takagi M, Hozumi T, Itoh A, Haze K, Yoshiyama M, Becker AE, Ueda M. Increased expression and plasma levels of myeloperoxidase are closely related to the presence of angiographically-detected complex lesion morphology in unstable angina. *Heart* 2010; 96: 1716-1722.
- [45] Yun KH, Mintz GS, Farhat N, Marso SP, Taglieri N, Verheye S, Foster MC, Margolis MP, Templin B, Xu K, Dressler O, Mehran R, Stone GW, Maehara A, Relation Between Angiographic Lesion Severity, Vulnerable Plaque Morphology and Future Adverse Cardiac Events (from the Providing Regional Observations to Study Predictors of Events in the Coronary Tree Study), *Am J Cardiol*. 2012; 110: 471-7.
- [46] Budoff MJ, Shaw LJ, Liu ST, Weinstein SR, Mosler TP, Tseng PH, Flores FR, Callister TQ, Raggi P, Berman DS. Long-term prognosis associated with coronary calcification. *J Am Coll Cardiol* 2007;49:1860-70.
- [47] Cheng GC, Loree HM, Kamm RD, Fishbein MC, Lee RT. Distribution of circumferential stress in ruptured and stable atherosclerotic lesions: a structural analysis with histopathological correlation. *Circulation* 1993;87: 1179 – 87.
- [48] P. Napoleão, M. Selas, C. Ramos, A. Turkman, V. Andreozzi, M. Mota Carmo, A. M. Viegas-Crespo, R. Cruz Ferreira, T. Pinheiro. The Role of Inflammatory Biomarkers in the Assessment of Coronary Artery Disease. In: Branislav Baskot (ed.) *Coronary Angiography - Advances in Noninvasive Imaging Approach for Evaluation of Coronary Artery Disease*: InTech; 2011. p281-314.



- [49] Sata M, Walsh K. TNF-alpha regulation of Fas ligand expression on the vascular endothelium modulates leukocyte extravasation. *Nat Med* 1998; 4 :415-420.
- [50] Blanco-Colio LM, Martín-Ventura JL, Tuñón J, García-Camarero T, Berrazueta JR, Egido J. Soluble Fas ligand plasma levels are associated with forearm reactive hyperemia in subjects with coronary artery disease: a novel biomarker of endothelial function? *Atherosclerosis*. 2008;201:407-12.
- [51] P. Napoleão, M. Selas, A. Toste, A. Turkman, V. Andreozzi, A.M. Viegas-Crespo, T. Pinheiro, R. Cruz Ferreira. Serial changes of oxidized low-density lipoprotein associated with culprit vessel in ST-elevation myocardial infarction – a promising marker? *Rev Port Cardiol* 2009;28:303-308.
- [52] M. Mota Carmo, P. Napoleão, S. Andrade, A.M. Selas, C. Freixo, A Turkman, V. Andreozzi, A.M. Viegas-Crespo, T. Pinheiro, R.C. Ferreira, High Oxidized LDL Associate to Low T-Lymphocytes in Acute Myocardial Infarction. *Circulation* 2010;122: E161.